




### Key reference documents

- [Mpox health topic page](#) (Geneva: World Health Organization, 2022).
- [Mpox fact sheet](#) (Geneva: World Health Organization; 2022).



### Case definitions

#### WHO suggested outbreak case definition

##### Suspected case

- A person who is a contact of a probable or confirmed mpox case in the 21 days before the onset of signs or symptoms, and who presents with any of the following: acute onset of fever ( $>38.5^{\circ}\text{C}$ ), headache, myalgia (muscle pain/body aches), back pain, profound weakness or fatigue.

**OR**

- A person presenting since 01 January 2022 with an unexplained acute skin rash, mucosal lesions or lymphadenopathy (swollen lymph nodes). The skin rash may include single or multiple lesions in the ano-genital region or elsewhere on the body. Mucosal lesions may include single or multiple oral, conjunctival, urethral, penile, vaginal, or ano-rectal lesions. Ano-rectal lesions can also manifest as ano-rectal inflammation (proctitis), pain and/or bleeding.

**AND**

for which the following common causes of acute rash or skin lesions do not fully explain the clinical picture: varicella zoster, herpes zoster, measles, herpes simplex, bacterial skin infections, disseminated gonococcus infection, primary or secondary syphilis, chancroid, lymphogranuloma venereum, granuloma inguinale, molluscum contagiosum, allergic reaction (e.g., to plants); and any other locally relevant common causes of papular or vesicular rash.

N.B. It is not necessary to obtain negative laboratory results for listed common causes of rash illness in order to classify a case as suspected. Further, if suspicion of mpox infection is high due to either history and/or clinical presentation or possible exposure to a case, the identification of an alternate pathogen which causes rash illness should not preclude testing for mpox, as co-infections have been identified.

##### Probable case

A person presenting with an unexplained acute skin rash, mucosal lesions or lymphadenopathy (swollen lymph nodes). The skin rash may include single or multiple lesions in the ano-genital region or elsewhere on the body. Mucosal lesions may include single or multiple oral, conjunctival, urethral, penile, vaginal, or ano-rectal lesions. Anorectal lesions can also manifest as ano-rectal inflammation (proctitis), pain and/or bleeding.

## AND

One or more of the following:

- has an epidemiological link<sup>1</sup> to a probable or confirmed case of mpox in the 21 days before symptom onset
- Identifies as gay, bisexual or other man who has sex with men
- has had multiple and/or casual sexual partners in the 21 days before symptom onset
- has detectable levels of anti-orthopoxvirus (OPXV) IgM antibody<sup>2</sup> (during the period of 4 to 56 days after rash onset); or a four-fold rise in IgG antibody titre based on acute (up to day 5-7) and convalescent (day 21 onwards) samples; in the absence of a recent smallpox/mpox vaccination or other known exposure to OPXV
- has a positive test result for orthopoxviral infection (e.g., OPXV-specific PCR without MPXV-specific PCR or sequencing)<sup>3</sup>

## Confirmed case:

A person with laboratory confirmed mpox virus infection by detection of unique sequences of viral DNA by real-time polymerase chain reaction (PCR)<sup>3</sup> and/or sequencing.

## Discarded case:

A suspected or probable case for which laboratory testing of lesion fluid, skin specimens or crusts by PCR and/or sequencing is negative for MPXV<sup>3</sup>.

Conversely, a retrospectively detected probable case for which lesion testing can no longer be adequately performed (i.e., after the crusts fall off) and no other specimen is found PCR-positive, would remain classified as a probable case. A suspected or probable case should not be discarded based on a negative result from an oropharyngeal, anal or rectal swab.

<sup>1</sup> The person has been exposed to a probable or confirmed mpox case. Please see below definition of a contact.

<sup>2</sup> Serology can be used for retrospective case classification for a probable case in specific circumstances such as when diagnostic testing through PCR of skin lesion specimens has not been possible, or in the context of research with standardized data collection. The primary diagnostic test for mpox diagnosis is PCR of skin lesion material or other specimen such as an oral or nasopharyngeal swab as appropriate. Serology should not be used as a first line diagnostic test.

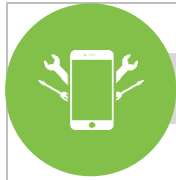
<sup>3</sup> PCR on a blood specimen may be unreliable and should also not be used alone as a first line diagnostic test. If blood PCR is negative and was the only test done, this is not sufficient to discard a case that otherwise meets the definition of a suspected or probable case. This applies regardless of whether the blood PCR was for OPXV or MPXV specific.

## Definition of a contact

A person who has been exposed to an infected person during the infection period i.e., the period beginning with the onset of the index case's first symptoms and ending when all scabs have fallen off, and who has one or more of the following exposures with a probable or confirmed case of mpox:

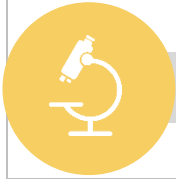
- direct skin-to-skin and skin-to-mucosal physical contact (such as touching, hugging, kissing, intimate or sexual contact)
- contact with contaminated materials such as clothing or bedding, including material dislodged from bedding or surfaces during handling of laundry or cleaning of contaminated rooms
- prolonged face-to-face respiratory exposure in close proximity
- respiratory exposure (i.e., possible inhalation of) or eye mucosal exposure to lesion material (e.g., scabs/crusts) from an infected person
- the above also apply for health workers potentially exposed in the absence of proper use of appropriate personal protective equipment (PPE)<sup>4</sup>

<sup>4</sup> [Clinical Management and Infection Prevention and Control for Monkeypox: Interim rapid response guidance – 10 June 2022](#)




## Data collection tools

- Case investigation form: [Mpox Case investigation form \(CIF\) and minimum dataset Case reporting form \(CRF\)](#)
- Electronic tools: [Godata website](#)



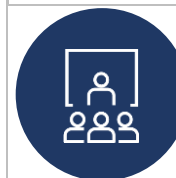
## Laboratory confirmation

- [Laboratory testing for Mpox virus: interim guidance](#), 23 May 2022. World Health Organization.



## Response tools and resources

- [Surveillance, case investigation and contact tracing for Mpox, Interim guidance](#) (Geneva; World Health Organization, 22 December 2022).
- [Clinical Management and Infection Prevention and Control for Monkeypox: Interim rapid response guidance](#) (Geneva, World Health Organization, 10 June 2022)
- [Vaccines and immunization for Mpox: interim guidance](#) (Geneva, WHO, World Health Organization, 16 November 2022)



## Training

### English

- [Mpox: Introduction for African outbreak contexts](#) (Geneva: World Health Organization; 2020)
- [Mpox epidemiology, preparedness and response for African outbreak contexts: Open WHO course](#). (Geneva: World Health Organisation; 2020).

### Français

- [Variole du singe : Cours d'introduction aux contextes d'épidémies en Afrique](#) (Geneva: World Health Organization 2020).
- [Variole du singe : Épidémiologie, préparation et réponse aux contextes d'épidémies en Afrique](#) (Geneva: Organisation Mondiale de la Santé ; 2022).



## Other resources

- [WHO's Science in 5: Mpox](#) (Geneva: World Health Organization; 2022)
- [Managing epidemics: Key facts about major deadly diseases \(page 170\)](#) (Geneva: World Health Organization; 2018).
- [Emergence of Mpox in West Africa and Central Africa, 1970–2017](#). Weekly Epidemiological Record No. 11, 16 March 2018.