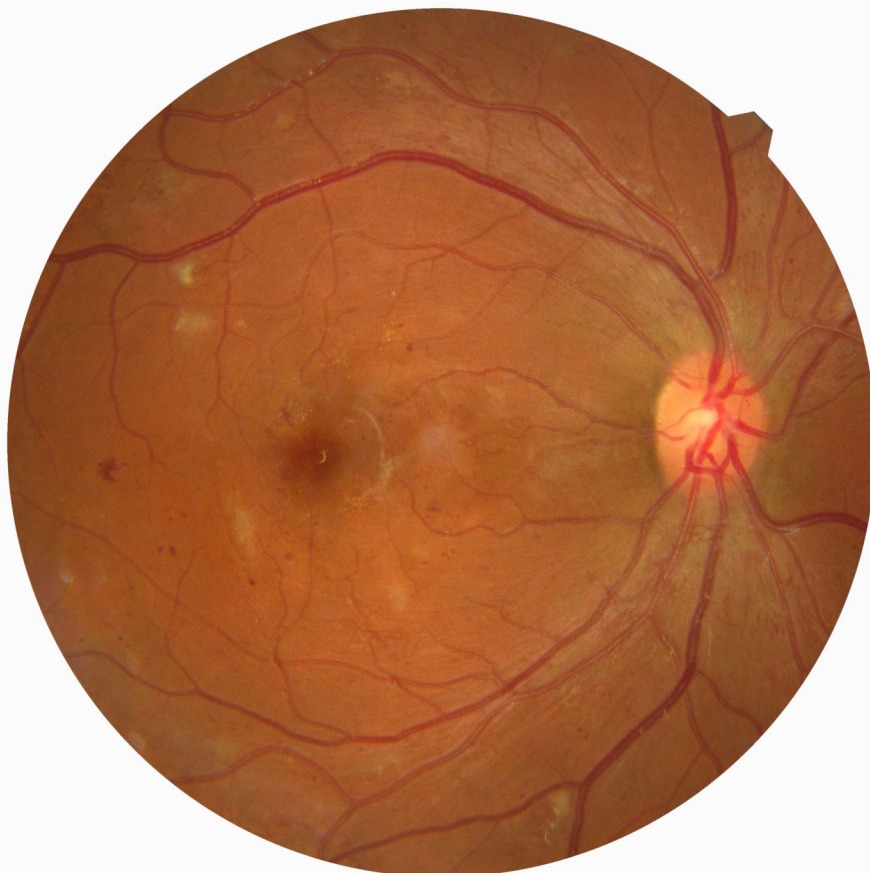




*Government of the Republic of Malawi
Ministry of Health*

National Guidelines for Diabetic Eye Care



December 2021

Contents

Contents	1
Foreword	2
Acknowledgements	3
1. Introduction.....	4
2. Screening Guidelines.....	8
3. Detailed Ophthalmic Assessment of Diabetic Retinopathy	10
4. Treatment of Diabetic Retinopathy	13
5. Treatment for Diabetic Macular Edema (DME)	16
6. Indications for Vitrectomy.....	18
7. Management of Diabetic Retinopathy in Special Circumstances	19
8. List of Suggested Indicators for Evaluation of DR Programs	20
9. Equipment for diabetic retinopathy services.....	21
10. Drugs for diabetic retinopathy services.....	24
11. Human resources for screening and treatment of DR.....	25
Annex A. Technique for PRP	26
Annex B. Recommended practice for Intravitreal Injection	29

Foreword

Diabetic retinopathy (DR) is a micro vascular complication of Diabetes mellitus (DM) that affects over a third of persons with Diabetes mellitus. Diabetic retinopathy is an increasingly-important cause of vision loss in Malawi and it is preventable through early detection and treatment.

The Ministry of Health developed the National Guidelines for Diabetic Eye Care to provide evidence-based, clinical guidance for the screening and management of diabetic retinopathy. The guidelines were largely adapted from the Guidelines for Diabetic Eye Care which were developed by the International Council of Ophthalmology.

The scope of the guidelines is largely on the requirements for the screening and detection of diabetic retinopathy, and the appropriate assessment and management of patients with diabetic retinopathy. Although they are prepared primarily for eye care and diabetes care providers, they are relevant to other health workers offering preventive health services at primary, secondary and tertiary health care levels.

The management of diabetic retinopathy often requires an individualized approach to patient care based on patients' severity of disease and social circumstances among other factors. Thus these guidelines are advisory and are not intended as a set of rules to replace case by case clinical judgement. However, it is anticipated that that these guidelines will help in standardizing the care for patients with diabetic retinopathy across the country.

The National Guidelines for Diabetic Eye Care have been made possible by consensus view of a representative panel of internal medicine professionals involved in diabetes care, public health professionals and ophthalmologists from Malawi. The guidelines have been adapted specific to the Malawian context and it is anticipated that they will be a valuable resource in the prevention and management of diabetic retinopathy in the country.



Dr Charles Mwansambo
Secretary for Health

Acknowledgements

The development and compilation of these guidelines was possible through extensive consultation with various stakeholders involved in diabetes and diabetic retinopathy management across Malawi. The ministry of health acknowledges with gratitude the Lions Clubs International Foundation (LCIF) in collaboration with the World Health Organization (WHO) for supporting the guidelines development process. We are particularly thankful to Ms Karen Kilberg (LCIF) for her administrative input and to Dr Silvio Paolo Mariotti (WHO, Geneva) for his technical contribution.

We would like to acknowledge input from the following: Mr Michael Masika (Ministry of Health), Dr Kaponda Masiye (Ministry of Health), Professor Khumbo Kalua (Director, Blantyre Institute for Community Outreach), Dr Joseph Msosa (Vitreoretinal surgeon, Kamuzu Central Hospital), Dr Gerald Msukwa (Paediatric Ophthalmologist, Queen Elizabeth Central Hospital), Dr Amos Nyaka (Oculoplastics specialist, Kamuzu Central Hospital), Dr Vincent Moyo (Oculoplastics specialist, Nkhoma Eye Hospital), Dr Petros Kayange (Medical Retina Specialist, Kamuzu University of Health Sciences), Dr Patty Mopamboli (Ophthalmologist, Mzuzu Central Hospital), Dr Esther Misanjo (Ophthalmologist, Zomba Central Hospital), Mr Byson Kapatamoyo (Optometrists, Mangochi District Hospital), Mrs Elizabeth Chimbalangondo (Nurse, Queen Elizabeth Central Hospital), Mr Kenasi Kasinje (Technical Adviser on Planning and Governance, Ministry of Health), Mr Wilfred Dodoli (Programme Officer, World Health Organization), Dr Tamara Phiri (Internal medicine specialist, Queen Elizabeth Central Hospital) and Dr Thandi Mwalukomo (Internal medicine specialist, Kamuzu University of Health Sciences).

Finally, we are grateful to Dr Shaffi Mdala (Ophthalmologist, Queen Elizabeth Central Hospital) and Dr Thokozani Zungu (Ophthalmologist, Kamuzu University of Health Sciences) for providing technical direction in the development of the guidelines.

1. Introduction

Diabetes mellitus (DM) is a global epidemic with significant morbidity. Diabetic retinopathy (DR) is the specific microvascular complication of DM and affects 1 in 3 persons with DM. DR remains a leading cause of vision loss in working adult populations. Patients with severe levels of DR are reported to have poorer quality of life and reduced levels of physical, emotional, and social well-being, and they utilize more health care resources.

Epidemiological studies and clinical trials have shown that optimal control of blood glucose, blood pressure, and blood lipids can reduce the risk of developing retinopathy and slow its progression. Timely treatment with laser photocoagulation, and increasingly, the appropriate use of intraocular administration of vascular endothelial growth factor (VEGF) inhibitors can prevent visual loss in vision-threatening retinopathy, particularly diabetic macular edema (DME). Since visual loss may not be present in the earlier stages of retinopathy, regular screening of persons with diabetes is essential to enable early intervention.

1.1. Epidemiology of Diabetic Retinopathy

In many countries, DR is the most frequent cause of preventable blindness in working-aged adults. A Global meta-analysis study reported that 1 in 3 (34.6%) had any form of DR in the US, Australia, Europe and Asia. It is also noted that 1 in 10 (10.2%) had vision threatening DR (VTDR) i.e., PDR and/or DME. In the 2010 world diabetes population, more than 92 million adults had any form of DR, 17 million had PDR, 20 million had DME and 28 million had VTDR.

Malawi has an adult population prevalence of diabetes of approximately 1.6%. A previous hospital based study found a high prevalence of sight threatening DR in persons attending diabetes clinics in Malawi, ten times higher than recent European studies.

DR develops with time and is associated with poor control of blood sugar, blood pressure and blood lipids. The longer someone has had DM, and the poorer their control, the higher their risk of developing DR. Although good control reduces the annual incidence of developing DR, it does not necessarily reduce the lifetime risk of developing DR, so everyone with DM is at risk.

The overall prevalence of DR in a community is also influenced by the number of people diagnosed with early DM. In low-/intermediate resource settings with less advanced health care systems, fewer people with early DM will have been diagnosed because early stage of DM is asymptomatic. People may be diagnosed with diabetes only when symptomatic or complications have occurred. Thus, the prevalence of DR in people with newly diagnosed DM will be high, resulting in a somewhat higher overall prevalence of DR.

1.2 Classification of Diabetic Retinopathy

The classic retinal lesions of DR include microaneurysms, hemorrhages, venous beading (venous caliber changes consisting of alternating areas of venous dilation and constriction), intraretinal microvascular abnormalities, hard exudates (lipid deposits), cotton-wool spots (ischemic retina leading to accumulations of axoplasmic debris within adjacent bundles of ganglion cell axons), and retinal neovascularization. These findings can be utilized to classify eyes as having one of two phases of DR.

1.2.1 Nonproliferative Diabetic Retinopathy (NPDR)

Eyes with nonproliferative DR (NPDR) have not yet developed neovascularization, but may have any of the other classic DR lesions. Eyes progress from having no DR through a spectrum of DR severity that includes mild, moderate and severe NPDR. Correct identification of the DR severity level of an eye allows a prediction of risk of DR progression, visual loss, and determination of appropriate treatment recommendations including follow-up interval. Annex Table 1 details the signs associated with DR.

1.2.2 Proliferative Diabetic Retinopathy (PDR)

Proliferative diabetic retinopathy (PDR) is the most advanced stage of DR and represents an angiogenic response of the retina to extensive ischemia from capillary closure. Retinal neovascularization is typically characterized as being new vessels on the disc (NVD) or new vessels elsewhere (NVE) along the vascular arcades. NVE often occurs at the interface between perfused and non-perfused areas of retina. Annex Table 2 includes the signs associated with PDR.

The stages of DR, from nonproliferative to proliferative DR, can be categorized using the simple International Classification of DR scale shown in Table 1.

1.2.3 Diabetic Macular Edema (DME)

Diabetic macular edema (DME) is an additional important complication that is assessed separately from the stages of retinopathy, as it can be found in eyes at any DR severity level and can run an independent course. Currently, diabetic eyes are generally classified as having no DME, noncentral-involved DME, or central-involved DME. The determination of DME severity based on these 3 categories will determine the need for treatment and follow-up recommendations.

The stages of DR can be classified using the International Classification of DR Scale shown in Table 1. Based on this Classification, referral decisions can be made (Table 2). It is important to remember that advanced stages of DR and DME may be present even in patients who are not experiencing visual symptoms. An online self-directed course on the grading of diabetic retinopathy is available at: drgrading.iehu.unimelb.edu.au

Table 1: International Classification of Diabetic Retinopathy and Diabetic Macular Edema

Diabetic Retinopathy	Findings Observable on Dilated Ophthalmoscopy
No apparent DR	No abnormalities
Mild nonproliferative DR	Microaneurysms only
Moderate nonproliferative DR	Microaneurysms and other signs (e.g., dot and blot hemorrhages, hard exudates, cotton wool spots), but less than
Severe nonproliferative DR	Moderate nonproliferative DR with any of the following: <ul style="list-style-type: none"> • Intraretinal hemorrhages (≥ 20 in each quadrant); • Definite venous beading (in 2 quadrants); • Intraretinal microvascular abnormalities (in 1 quadrant);
Proliferative DR	Severe nonproliferative DR and 1 or more of the following: <ul style="list-style-type: none"> • Neovascularization • Vitreous/preretinal hemorrhage

Diabetic Macular Edema	Findings Observable on Dilated Ophthalmoscopy
No DME	No retinal thickening or hard exudates in the macula
Noncentral-involved DME	Retinal thickening in the macula that does not involve the central subfield zone that is 1mm in diameter
Central-involved DME	Retinal thickening in the macula that does involve the central subfield zone that is 1mm in diameter

Hard exudates are a sign of current or previous macular edema. DME is defined as retinal thickening, and this requires a three-dimensional assessment that is best performed by a dilated examination using slit-lamp biomicroscopy and/or stereo fundus photography.

Table 2. Re-examination and referral recommendations based on international classification of diabetic retinopathy* and diabetic macular edema for low-/intermediate resource settings

Classification	Re-examination or next screening schedule	Classification
No apparent DR, mild nonproliferative DR and no DME	Re-examination in 1 year	Referral not required
Mild nonproliferative DR	1-2 year	Referral not required
Moderate nonproliferative DR	6-12 months	Referral required
Severe nonproliferative DR	< 3 months	Referral required
PDR	< 1 month	Referral required
Diabetic Macular Edema (DME)		
Classification	Re-examination or next screening schedule	Referral to ophthalmologist
Noncentral-involved DME	3 months	Referral not required (referral recommended if laser resources available)
Central-involved DME	1 month	Referral required

* In cases where diabetes is controlled.

2. Screening Guidelines

2.1 Screening Guidelines

Screening for DR is an important aspect of DM management worldwide. Even if an adequate number of ophthalmologists are available, using ophthalmologists or retinal subspecialists to screen every person with DM is an inefficient use of resources.

A screening exam could ideally include a complete ophthalmic examination with refracted visual acuity and state-of-the-art retinal imaging. However, in our setting, the minimum examination components to assure appropriate referral should include a screening visual acuity exam and retinal examination adequate for DR classification. Vision should be tested prior to pupil dilation. **Annex Flowchart 1** shows an example of the screening process for DR.

The screening vision exam should be completed by trained personnel in any of the following ways, depending on resources:

- Refracted visual acuity examination using a 3- or 4-meter visual acuity lane and a high contrast visual acuity chart.
- Presenting visual acuity examination using a near or distance eye chart and a pin-hole option if visual acuity is reduced.
- Presenting visual acuity examination using a 6/12 equivalent handheld chart consisting of at least 5 standard letters or symbols and a pin-hole option if visual acuity is reduced.

A retinal examination may be accomplished in the following ways:

- Direct or indirect ophthalmoscopy or slit-lamp biomicroscopic examination of the retina.
- Retinal (fundus) photography (including any of the following: widefield to 30°; mono- or stereo-dilated or undilated). This could be done with or without accompanying optical coherence tomography (OCT) scanning. This could also include telemedicine approaches. (**Annex Table 3**)
- For the retinal examination, the examiner must be well trained to perform ophthalmoscopy or retinal photography and be able to assess the severity of DR.

Using adequate information from the visual acuity and retinal examinations, one can decide on an appropriate management plan, as outlined in **Table 2**. The plan may be modified based on individual patient requirements.

Patients with less than adequate retinal assessment should be referred to an ophthalmologist unless it is obvious that there is no DR, or at most, only mild nonproliferative DR (i.e., microaneurysms only). In addition, persons with unexplained visual-acuity loss should be referred.

As part of a screening exam, persons with diabetes should be asked about their diabetes control, including blood glucose, blood pressure, and serum lipids. In addition, women should be asked if they are or could be pregnant. Inadequate control and pregnancy may require further appropriate medical intervention.

2.2 Referral Guidelines

Minimum referral guidelines are as follows:

- i. Visual acuity below 6/12 or symptomatic vision complaints
- ii. If DR can be classified according to the simplified International Classification of DR (**Table 1**), they should be referred accordingly (**Table 2**).

3. Detailed Ophthalmic Assessment of Diabetic Retinopathy

3.1 Initial Patient Assessment

Detailed patient assessment should include a complete ophthalmic examination, including visual acuity and the identification and grading of severity of DR and presence of DME for each eye. The patient assessment should also include the taking of a patient history focused on diabetes and its modifiers.

3.1.1 Patient History (Key Elements)

- Duration of diabetes
- Past glycemic control (hemoglobin A1c)
- Medications (especially insulin oral hypoglycemics, antihypertensives, and lipid-lowering drugs)
- Systemic history (e.g., renal disease, systemic hypertension, serum lipid levels, pregnancy)
- Ocular history

3.1.2. Initial Physical Exam (Key Elements)

- Visual acuity
- Measurement of intraocular pressure (IOP)
- Gonioscopy when indicated (e.g., when neovascularization of the iris is seen or in eyes with increased IOP)
- Slit-lamp biomicroscopy
- Fundus examination

3.1.3 Fundus Examination Assessment Methods

Currently, the two most sensitive methods for detecting DR are retinal photography and slit-lamp biomicroscopy through dilated pupils. Both depend on interpretation by trained eye health professionals. Other methods are listed in Annex Table 3.

Fundus photography has the advantage of creating a permanent record, and for that reason, it is the preferred method for retinopathy assessment. However, well-trained observers can identify DR without photography and there are many situations in which that would be the examination of choice.

The use of all instruments requires training and competence but more skill is needed for indirect ophthalmoscopy and slit-lamp biomicroscopy than for fundus photography. Newer, semi-automatic non-mydratic fundus cameras can be very easy to use. Media opacities will lead to image/view degradation and all photographs/images must be reviewed by trained personnel.

3.2. Follow-up Examination of Patients with Diabetic Retinopathy

In general, the follow-up history and examination should be similar to the initial examination. The assessment of visual symptoms, visual acuity, measurement of IOP, and fundus examination are essential.

3.2.1 Follow-up History

- Visual symptoms
- Glycemic status (hemoglobin A1c)
- Systemic status (e.g., pregnancy, blood pressure, serum lipid levels, renal status)

3.2.2 Follow-up Physical Exam

- Visual Acuity
- Measurement of IOP
- Gonioscopy when indicated
- Slit-lamp biomicroscopy
- Fundus examination

3.2.3 Ancillary Tests (Central hospitals)

- OCT is the most sensitive method to identify DME. OCT can provide quantitative assessment of DME to determine the severity of DME. Retinal map scan is useful in locating the area with retinal thickening; single scan is useful in detailing the types of DME as diffuse, cystic changes, sub-retinal fluid/detachment, and vitreoretinal traction.
- Fundus photography is a useful way of recording the disease activity. It is useful in determining detailed severity of the disease.
- Fluorescein angiography is not required to diagnose DR, proliferative DR or DME, all of which are diagnosed by means of fundus examination.
- Fluorescein angiography can be used as a guide to evaluate retinal non-perfusion area, presence of retinal neovascularization, and microaneurysms or macular capillary non-perfusion in DME.

3.2.4 Patient Education

- Discuss results of exam and implications.
- Encourage patients with DM but without DR to have annual screening eye exams. All patients being managed for DM at primary health care level need to be reminded of the need for a routine eye examination at secondary level at least once a year.
- Inform patients that effective treatment for DR depends on timely intervention, despite good vision and no ocular symptoms.
- Educate patients about the importance of maintaining near-normal glucose levels, near-normal blood pressure and to control serum lipid levels.
- Communicate with the general physician (e.g., family physician, internist, or endocrinologist) regarding eye findings.

- Provide patients whose conditions fail to respond to surgery and for whom treatment is unavailable with proper professional support (i.e., offer referrals for counseling, rehabilitative, or social services as appropriate).
- Refer patients with reduced visual function for vision rehabilitation and social services.
- Refer patients who have underwent treatment, including PRP and surgery, on timely follow-up.

Table 3. Follow-up Schedule and Management based on Diabetic Retinopathy Severity

Diabetic Retinopathy Severity	Follow-up Schedule for management by ophthalmologists
No apparent DR	Re-examination in 1-2 years; This may not require re-examination by an ophthalmologist
Mild nonproliferative DR	1-2 years; This may not require re-examination by an
Moderate nonproliferative DR	6-12 months
Severe nonproliferative DR	< 1 month
Proliferative DR	<1 month; Consider pan-retinal photocoagulation.
Stable (Treated) PDR	6-12 month
Diabetic Macular Edema severity	Follow-up Schedule for management by ophthalmologists
Noncentral-involved DME	3-6 month
Central-involved DME	1-3 month; Consider focal laser photocoagulation or anti-VEGF therapy
Stable DME	3-6 month

4. Treatment of Diabetic Retinopathy

4.1 Central Hospitals

- i. Optimize medical treatment: Improve glycemic control if HbA1c > 58 mmol/mol (>7.5%) as well as associated systemic hypertension or dyslipidemia.
- ii. No DR, Mild or Moderate NPDR: Follow at recommended intervals with dilated eye examinations and retinal imaging as needed. Treat DME as needed (see below).
- iii. Severe NPDR: Follow closely for development of PDR. Consider early panretinal photocoagulation for patients at high risk of progression to PDR or poor compliance with follow-up. There are benefits of early panretinal photocoagulation at the severe NPDR stage for patients with type 2 diabetes. Other factors, such as poor compliance with follow-up, impending cataract extraction or pregnancy, and status of fellow eye will also help in determining the timing of the panretinal photocoagulation.
- iv. PDR: Treat with panretinal photocoagulation (PRP). There is increasing evidence from clinical trials demonstrating anti- VEGF injections (ranibizumab) as a safe and effective treatment of PDR through at least 2 years and that other intravitreal anti-VEGF agents (i.e. aflibercept and bevacizumab) are also highly effective against retinal neovascularization.

4.2 District hospitals

- i. Generally similar to above. PRP is preferred for the treatment of severe NPDR and PDR, thus patients with these grades of retinopathy must be referred to an ophthalmologist for treatment.

4.3 Panretinal Photocoagulation (PRP)

4.3.1 Pre-treatment Discussion with Patients

- Patients usually need numerous follow-up visits and may require supplementary laser treatment.
- PRP reduces the risk of visual loss and blindness.
- Although laser treatment is effective, some patients may still develop vitreous hemorrhage. The hemorrhage is caused by the diabetes and not by the laser; it may mean the patient needs more laser treatment.
- Laser treatment often reduces peripheral and night vision; treatment may moderately reduce central vision.
- The conventional long pulse 100ms PRP treatments are associated with loss of vision. The recommended short pulse 20-30ms PRP treatments are less likely to cause this complication.

4.3.2 Lenses for PRP

- The three-mirror Goldmann contact lens has a central opening for treating the posterior pole, and side mirrors for treating the mid peripheral and peripheral retina.

Disadvantages: small field of view, which requires continual manipulation of the lens to complete treatment. Spot size is set at 500µm.

- Newer wide-angle contact lenses are often used. Although the image is inverted, there is a large field of view allowing for many burns with the field while easily maintaining orientation to the disc and macula. The optics of these wide-angle lenses will affect the laser spot size on the retina (Table 4). Wide-angle indirect ophthalmoscopy lenses provide an inverted image, but show a large field of view and a magnification of the spot in the retina (Table 4). Scatter treatment can be applied to a large area of retina in a single image, and it is easy to visualize the disc and the macula.

Table 4: Laser Spot Size Adjustment Required for Different Lenses Contact

Lens	Field of Vision	Axial magnification	Spot magnification	Spot Size Setting for ~500 µm
Mainster Wide-	125°	0.46	1.50x	300µm
Volk TransEquator	120-125°	0.49	1.43x	300µm
Volk	130-135°	0.27	1.92x	200 to 300µm
Mainster PRP 165	160°	0.27	1.96x	200 to 300 µm

4.3.3 Technique for PRP (refer to Annex A for more details)

- i. The pupil should be fully dilated and topical anesthesia is used. Retrobulbar or subtenons anesthesia to reduce pain and decrease eye motion can be employed as necessary.
- ii. Typical initial settings on the Argon laser would be 500 µm spot size, a 0.1 second exposure and 250-270 mw power. The power is gradually increased until a whitish reaction is obtained on the retina. The lesions are placed 1 burn width apart. (Table 5).
- iii. A total of 1600-3000 burns are placed in 1 or more sittings, carefully avoiding the macular area and any areas of tractional elevation of the retina. The burns are placed 2 to 3 disc diameters away from the center of the macula and 1-disc diameter away from the disc, usually outside the arcades and extended peripherally up to the equator and beyond.
- iv. Laser treatment should not be applied over major retinal veins, preretinal hemorrhages, darkly pigmented chorioretinal scars, or within 1 DD (200-300 µm) of center of macula, so as to avoid risk of hemorrhage or large scotomas.
- v. Other considerations:
 - PRP is typically performed in 2-3 sessions.
 - Additional photocoagulation is needed if there is evidence of worsening of proliferative DR.
 - Add laser burns in between scars of initial treatment further peripherally and also at the posterior pole, sparing the area within 500-1500 µm from the center of the macula.
 - Favor quadrants with active new vessels or areas with intraretinal microvascular

abnormalities where scars are more widely spaced and areas of severe ischemia not previously treated, such as the temporal part of the posterior pole.

- There is increasing use of multi-spot laser machine.

Table 5. The burn characteristics for panretinal photocoagulation:

Size (on retina):	500 μm
Exposure	0.05 to 0.1 seconds recommended. 0.02 or 0.03 seconds can be considered for use in High Resource Settings (in certain laser machines, where applicable).
Intensity	mild white (i.e. 2+ to 3+ burns)
Distribution	Mild and moderate PDR: Edges 1 burn width apart Severe PDR: Edges 0.5 to 0.75 burn width apart
Number of sessions/sittings	1 to 3
Nasal proximity to disk	No closer than 500 μm
Temporal proximity to center	No closer than 3000 μm
Superior/inferior limit	No further posterior than 1 burn within the temporal arcades
Extent	Arcades (~3000 μm from the macular center) to at least the equator
Total number of burns	1200 – 1600 There may be instances where 1200 burns are not possible such as the development of vitreous hemorrhage or inability to complete a sitting precluding completion of the PRP session. Similarly, there may be clinical situations in which more than 1600 burns are needed such as initial difficulty with laser uptake due to media opacity. Below is a guide for 20ms PRP and 100ms PRP: Mild PDR: 20ms PRP ETDRS laser 100ms 2400-3500 burns 1200-1800 burns Moderate PDR: 20ms PRP ETDRS laser 100ms 4000-5000 burns 2000-2500 burns Severe PDR: 20ms PRP ETDRS laser 100ms 5500-6000 burns 2000-2500
Wavelength	Green or yellow (red can be used if vitreous hemorrhage is present)

5. Treatment for Diabetic Macular Edema (DME)

- i. Optimize medical treatment: Improve glycemic control if HbA1c > 58 mmol/mol (>7.5%) as well as associated systemic hypertension or dyslipidemia.
- ii. DME without central involvement: May observe until there is progression to central involvement, or consider focal laser to leaking microaneurysms if thickening is threatening the fovea (Annex Flowchart 2). No treatment is applied to lesions closer than 300-500 µm from the center of the macula.
- iii. Central-involved DME and good visual acuity (better than 6/9 or 20/30): 3 treatment options being evaluated in an ongoing clinical trial: (1) careful follow-up with anti-VEGF treatment only for worsening DME; (2) intravitreal anti- VEGF injections; or (3) laser photocoagulation with anti-VEGF, if necessary.
- vi. Central-involved DME and associated vision loss (6/9 or 20/30 or worse): intravitreal anti-VEGF treatment (e.g., with ranibizumab [Lucentis] 0.3 or 0.5mg, bevacizumab [Avastin] 1.25mg, or aflibercept [Eylea] 2mg therapy). Consideration should be given to monthly injections followed by treatment interruption and re-initiation based on visual stability and OCT (Annex Flowchart 3). Patients should be monitored almost monthly with OCT to consider the need for treatment. Typically, the number of injections is 8-10 in the first year, 2 or 3 during the second year, 1 to 2 during the third year, and 0 to 1 in the fourth and fifth years of treatment. For eyes with persistent retinal thickening despite anti-VEGF therapy, consider laser treatment after 24 weeks. Treatment with intravitreal triamcinolone may also be considered, especially in pseudophakic eyes. Injections are given 3.5 to 4 mm behind the limbus in the inferotemporal quadrant under topical anesthesia using a sterile technique (see Annex B for details).
- iv. DME associated with proliferative DR: monotherapy with intravitreal anti-VEGF therapy should be considered with re-evaluation for need for PRP versus continued anti-VEGF once the DME resolves.
- v. Vitreomacular traction or epiretinal membrane on OCT: pars plana vitrectomy may be indicated.

Important

Focal laser is preferred if intravitreal injection of anti-VEGF agents are not available or if monthly follow up is not possible. Bevacizumab (Avastin) is an appropriate alternative to ranibizumab (Lucentis) or aflibercept (Eylea). Laser can be applied earlier to areas of persistent retinal thickening in eyes unresponsive to anti-VEGF treatment.

5.3 Laser Technique for Diabetic Macular Edema

- i. Modified ETDRS guidelines recommends focal laser treatment of microaneurysms and grid treatment of areas of diffuse leakage and focal nonperfusion within 2DD of center of the macula. There is increasing evidence that laser for microaneurysms is not recommended and multiple re-treatments of microaneurysms can lead to heavy retinal laser burns and future laser scars and central scotomas. (Table 6)

ii. Laser parameters used are 50-100 μm spot size, 120-150 mW energy and very light gray intensity of the burn. Care is taken to demarcate and avoid the foveal avascular zone.

iii. If DME is associated with large areas of macular ischemia, only the areas of retinal thickening are treated.

Table 6. Modified-ETDRS and the Mild Macular Grid Laser Photocoagulation Techniques

Focal direct laser	
Directly treat all leaking microaneurysms in areas of retinal thickening between 500 and 3000 μm from the center of the macula (but not within 500 μm of disc). Change in microaneurysms color with direct treatment is not required, but at least a mild gray-white burn should be evident beneath all microaneurysms.	
Burn size	50-100 μm
Burn duration	0.05 to 0.1 sec
Wavelength	Green to yellow wavelengths
Grid laser	
Applied to all areas with diffuse leakage or non-perfusion area. Treat the area 500 to 3000 μm superiorly, nasally and inferiorly from the center of the macula, and 500 to 3500 μm temporally from macular center. No burns are placed within 500 μm of disc. Aim barely visible (light gray) laser burn and each burn should be at least two visible burn widths apart.	
Burn size	50-100 μm
Burn duration	0.05 to 0.1 sec
Wavelength	Green to yellow wavelengths

6. Indications for Vitrectomy

The number of patients requiring vitrectomy would be low in the context of an effective DR screening system. The following are the indications of vitrectomy:

- i. Severe vitreous hemorrhage of 1–3 months' duration or longer that does not clear spontaneously. Earlier intervention may be warranted in low-/intermediate resource settings as the underlying PDR disease may have been previously untreated and highly advanced. In these settings it may be reasonable to perform vitrectomy in eyes with vitreous hemorrhage of 4 -6 weeks' duration that has not cleared spontaneously. Visual prognosis is better with earlier intervention.
- ii. Advanced active proliferative DR that persists despite extensive PRP. Surgery is reasonable in eyes with recurrent episodes of vitreous haemorrhage from PDR due to persistent vessels despite PRP or mechanical traction on NV.
- iii. Traction macular detachment of recent onset. Fovea-threatening or progressive macula-involving traction detachments benefit from surgical management.
- iv. Combined traction-rhegmatogenous retinal detachment.
- v. Tractional macular edema or epiretinal membrane involving the macula. This includes vitreomacular traction.

7. Management of Diabetic Retinopathy in Special Circumstances

7.1 Pregnancy

Progression of DR is a significant risk in pregnancy. The following are recommendations:

- i. Patients with pre-existing diabetes planning pregnancy should be informed on the need for assessment of DR before and during pregnancy. Pregnant women with pre-existing diabetes should be offered retinal assessment following their first antenatal clinic appointment and again at 28 weeks if the first assessment is normal. If any DR is present, additional retinal assessment should be performed at 16-20 weeks.
- ii. Diabetic retinopathy should not be considered a contraindication to rapid optimisation of glycaemic control in women who present with a high HbA1c in early pregnancy but retinal assessment is essential.
- iii. Diabetic retinopathy should not be considered a contraindication to vaginal birth.

7.2 Management of Cataract

DR progresses faster after cataract surgery, so principles of management are as follows:

- i. Mild cataract - carefully assess DR status. Patients without vision loss with clear fundus view may not require cataract surgery.
- ii. Moderate cataract - carefully assess DR status. Attempt to treat any severe NPDR with laser PRP, and/or DME with focal/grid laser or anti-VEGF therapy, before cataract surgery. Once DR/DME is stable, consider cataract surgery to improve vision.
- iii. Severe to advanced cataract with poor fundus view - if DR status cannot be adequately assessed, consider early cataract surgery followed by assessment and treatment as necessary. If DME is present, consider anti-VEGF before surgery, at the time of surgery, or after surgery if DME is discovered when the media is cleared.

Cataract extraction in diabetic patients as compared to non-diabetic patients is associated with higher risks of reported complications such as capsular contraction and opacification. There is also a potential risk that diabetic eye disease may progress as a direct result of cataract surgery. This depends on the level of retinopathy and maculopathy at the time of surgery, whether surgery was complicated or uncomplicated and blood sugar control.

There are no evidence-based cut off values on the blood sugar range within which it is safer to perform cataract surgery. It is however advisable to take steps to optimize blood sugar levels in preparing for cataract surgery.

It is also advisable to avoid performing cataract surgery in patients with diabetes during outreach surgical camps in facilities where there are no DR treatment services. Surgeons should consider referring the patient to a center with facilities that would enable peri-operative evaluation and treatment for DR or DME.

8. List of Suggested Indicators for Evaluation of DR Programs

- i. Prevalence of diabetic retinopathy and DME related blindness and visual impairment*
- ii. Proportion of blindness and visual impairment due to DR*
- iii. Last eye examination for DR among known persons with diabetes (males/females) *
 - Never had eye examination for DR
 - 0–12 months ago
 - 13–24 months ago
 - >24 months ago
 - Could be simplified as: never/0-12 months ago/> months ago
- iv. Number of patients who were examined for DR during last year
- v. Number of patients who received laser and/or anti-VEGF treatment/surgery during last year
- vi. Number of patients that receive first PRP laser for screen positive/newly-diagnosed PDR
- vii. Tool for the Assessment of Diabetic Retinopathy and Diabetes Management Systems (WHO-TADDS)

This absolute number could be used to define ratios such as:

- viii. Number of patients who received laser and/or anti-VEGF treatments per million general population per year. [equivalent to Cataract Surgical Rate (CSR)]
 - ix. Number of patients who received laser and/or anti-VEGF treatments per number of patients with diabetes in a given area (hospital catchment area, health district, region, country)
 - Numerator: number of laser and/or anti-VEGF treatments during the last year
 - Denominator: number of patients with diabetes (population x prevalence of DM; source: IDF Atlas)
 - x. Number of patients who received laser and/or anti-VEGF treatments per number of persons with vision- threatening DR in a given area (hospital catchment area, health district, region, country)
 - Numerator: number of laser and/or anti-VEGF treatments during the last year
 - Denominator: number of patients with vision-threatening DR (population x prevalence of DM x 0.117; source: IDF Atlas)
- * Data available from RAAB surveys
- Estimated average prevalence of vision-threatening DR.
- xi. Number of ophthalmologists administering laser and/or anti-VEGF treatments per million general population per year in a given area (hospital catchment area, health district, region, country)

9. Equipment for diabetic retinopathy services

Core/essentials for screening, initial assessment, and follow-up:

- Nonmydriatic retinal (fundus) camera (recommended for screening).
- Indirect ophthalmoscopy (optional for screening, panoramic view, low magnification). Pupils must be dilated.
- Noncontact biconvex indirect lenses used with the slit lamp (90 D for screening, 78 D for more magnification).
- Direct ophthalmoscopy (optional for screening). Pupils must be dilated.
- Three-mirror contact lens used with slit lamp for stereoscopic and high-resolution images of the macula (evaluation of macular edema). Pupils must be dilated.
- Slit-lamp biomicroscope.
- Amsler grids

- Laser equipment: Currently, the most used lasers are (1) The green laser 532 nm, frequency-doubled Nd:YAG or 514 nm argon laser. The 810 nm infrared laser, or diode laser – this causes deeper burns with a higher rate of patient discomfort, but tend to be cheaper, is effective, and requires less maintenance.

Recommended in tertiary/referral centres:

- OCT
- Fluorescein angiography
- Mydriatic retinal photography (large field conventional fundus camera)
- Green lasers are the most used, but the pattern-laser method, with a predetermined multispot treatment cascade and the 577 nm yellow laser can be used in selected cases

Table 7: Equipment needed for a vitreoretinal surgery service

ITEM	DESCRIPTION
EQUIPMENT	
Operating microscope	
Operating microscope spare bulbs	
High-Speed Vitreous Cutter	DORC or Gueder (cutting speed of 10,00 - 16,000 cuts/min)
Binocular indirect ophthalmo microscope (BIOM) system	
28 D lens	For fundoscopy
2.2 D lens	For fundoscopy
25 D lens	For fundoscopy
Vitreotomy Machine	“Stellaris PC” from Bosch and Laumb OR “Constellation” from Alcon
Laser Device	532-nm diode laser
Cryo console	DORC, ERBE

Fluorescein angiography machine	For investigating retinal pathologies eg diabetic retinopathy
Cryotherapy machine	For retinal detachment surgery
Ocular ultrasound machine	For assessing posterior segment disease
Adjustable chairs for surgeons	
Sonographic cleaner	For cleaning delicate vitreoretinal surgery instruments
Adjustable operating bed	
Air pressure machine	for the vitrectomy unit
Recovery room monitors	For monitoring patients after surgery
Anesthesia machine	Up to date machines
Schiotz tonometer	For checking intraocular pressure during vitrectomy
Optical coherence tomography machine.	For investigating retinal pathologies eg diabetic retinopathy
Fundus camera	
Laser photocoagulation unit	For treatment of retinal pathologies eg diabetic retinopathy
Slit lamps	Haag Streit
90 D lens	For fundoscopy
78 D lens	For fundoscopy
60 D lens	For fundoscopy
Electronic ETDRS visual acuity examination set.	For accurate visual acuity assessment
Refraction set	
Glucometers	Checking blood sugar for diabetic patients
SET FOR PARS PLANA VITRECTOMY	NB: All items listed below make ONE SET
1x Lid speculum	
2. 1x Irrigating cannula	Geuder G-15180 (for irrigation of the eye)
3. 1x Dressing forceps, serrated	Geuder G-18781
1x Tissue forceps, 1 x 2 teeth	Geuder G-18791
5. 1x Castroviejo suturing forceps, straight	Geuder G-19023
6. 1x Barraquer cilia forceps	Geuder G-18750 (for suturing)
7. 1x Trocar forceps.	DORC 1276.2 (for removal of the trocars)
8. 1x Eye scissors, straight pointed-pointed.	Geuder G-19350
9. 1x Vannas capsulotomy scissors.	Geuder G-19760
10. 1x Halsted mosquito forceps, curved serrated.	Geuder G-18181
11. 1x Hartmann mosquito forceps, straight serrated.	Geuder G-18170 (for washing the eye)
12. 1x Barraquer needle holder, curved, without lock.	Geuder G-17500
13. 1x Sclera depressor, double ended.	Geuder G-32715
14. 1x Braunstein fixed caliper.	Bausch & Lomb E2402 (Scleral marker 3.5 mm and 4.0 mm)

15. 1x Trocar Cannula 23 Gauge (valved)	Alcon or DORC or Geuder or Oertli
16. 1x Trocar Cannula 25 Gauge (valved)	Alcon or DORC or Geuder or Oertli
17. 1x Scleral Marker	
18. 1x Fragmatome 23 G	
19. 1 x Fragmatome 20 G	
20. 1 x Fixed endoillumination probe	Chandelier (Synergetics, Alcon or DORC)
21. 1x Hand held endoillumination probe	Light probe (Synergetics, Alcon or DORC)
22. Charles Flute Instrument	aspirates liquid by capillary force and pressure difference.
23. Scleral depressor	
24. Laser probe	
25. Combined Laser and Light Fiber Hand Piece	
26. 1x Endodiathermy Probe	for cauterizing bleeding retinal vessels
27. 1 x Exodiathermy Probe	for cauterizing bleeding episcleral vessels
For macular surgery	
28. Alcon Scraper	
29. Atkinson Cannula	
30. Tano Diamond Dusted Membrane Scraper	For internal limiting membrane peeling
31. Membrane Pic	
32. Eckardt Forceps and Endgripping Forceps	
Instruments for Peeling for Diabetic Retinopathy and Traction retinal Detachment with PVR	
33. Serrated (Jaws) Forceps	
34. Straight or Horizontal Scissors	
35. Knob Spatula	
36. Retinectomy Scissors (Vertical Scissors)	
37. Instruments for Intraocular Foreign Body removal	17G, 19G, and 20G foreign body forceps.
38. Caliper	
39. Anterior chamber maintainer	
PHACOEMULSIFICATION INSTRUMENTS	
Phacoemulsification Machine	
Phaco Hand Piece, tip and accessory pack with silicone sleeve	
Irrigation- Aspiration tip (co-axial)	
Bimanual irrigation hand pieces (2 sets)	
Keratome (bevel up) 2.7-3.5mm	
Knife, MVR 19G	
Phaco chopper	
Spatula, fine iris	
Forceps, IOL folding and inserting	

10. Drugs for diabetic retinopathy services

- Tropicamide eye drops (with phenylephrine) – for pupillary dilatation during DR screening
- Bevacizumab (Avastin) – for intravitreal injection to treat DME
- Triamcinolone acetonide – for intravitreal injection to treat DME

Table 8: Gases and drugs needed for vitreoretinal surgery

GASES REQUIRED FOR VITREORETINAL SURGERY	Description
Sulfur hexafluoride (SF6)	
Hexafluoroethane (C2F6)	
Octafluoropropane (C3F8)	
LIQUIDS REQUIRED FOR VITREORETINAL SURGERY	
Perfluorocarbon	(PFCL, “heavy water”)
Light Silicone Oils	1000 csts (centistokes), 1300 csts, 2000 csts, and 5000 csts
Heavy Silicone Oils	(Densiron 68® and Oxane Hd®)
DYES FOR VITREOUS AND MEMBRANES	
triamcinolone acetonide	
trypan blue	(Monoblue®, Membrane Blue®)
Brilliant Blue G	(Brilliant Peel®, ILM-Blue®, MembraneBlue-Dual®).

11. Human resources for screening and treatment of DR

It may not be feasible to have DR screening performed by ophthalmologists. Ophthalmic clinical officers (OCOs) and optometrists can perform DR screening using ophthalmoscopes or slit lamp biomicroscopes. Where retinal photography is available, ophthalmic nurses could also perform screening and grading along with OCOs and optometrists.

With regard to treatment, there is a need for ophthalmologists trained in administering laser treatment for DR and intravitreal anti-VEGF injections for DME. In addition, there is a need for vitreo-retinal surgeons to perform surgery in patients with posterior segment complications from DR.

Annex A. Technique for PRP

1. If there is a significant anxiety and pain with slit-lamp PRP, then patient can undergo indirect PRP in theatre using subtenon's block. The eye movements are restricted by retrobulbar/subtenons anesthesia. The peripheral retinal zones may not be visualized adequately and remain poorly treated by laser. This is often evident by the posterior pole "pepper-pot" configuration of PRP laser.
2. Indirect PRP with subtenons anesthesia enables indented scleral laser application to up to the posterior border of the ora serrata. In PDR, the mid-peripheral retina up to the ora serrata is the zone of highest retinal ischemia as confirmed with widefield Optos studies.

In the last 5 years, conventional long-pulse duration PRP treatment has changed. This is reflected in the new RCOphth Diabetic Retinopathy Guidelines 2012 published in the UK. The DRCRNet recommendations outlined in Table 5 are not routinely undertaken, as 1200-1600 burns delivered over 1-3 sittings is neither an efficient nor cost-effective treatment schedule for any resource-poor or resource-rich setting. In light of new short pulse settings, use of pattern scan laser, and new concepts on laser burn tissue interactions for PRP laser, laser practitioners globally are changing laser PRP treatment paradigms. There is a significant body of evidence to demonstrate that short pulse PRP laser treatment will produce less laser burn scarring, less damage to the visual field, and is less damaging to the retina than conventional long pulse 100ms PRP treatment. This is highlighted in the following section extracted from the UK RCOphth 2012 guidelines.

Section 9.2.7 Healing Responses (Diabetic Retinopathy Guidelines 2012)

The in vivo effects of 20ms burns have been demonstrated in animal studies. A potential explanation for laser burn healing responses is related to fluence, which is calculated as $(\text{power} \times \text{time})/\text{area}$. The fluence required to produce a threshold ETDRS type PRP burn on the retina is significantly lower for a pulse duration of 20ms compared with conventional 100ms pulse duration. A lower fluence laser dose results in fewer structural alterations in the outer retina. At shorter and longer pulse durations, the RPE absorbs the laser light and is destroyed, and the adjacent RPE proliferates to fill the area destroyed. However, at shorter pulse duration, there is photoreceptor in-filling to sites of laser injury with healing responses produced over time.

The MAPASS study showed that 20ms burns allow the tissues to undergo a healing response that may not occur after standard- duration (100-200ms) photocoagulation. This healing response is associated with a significant reduction in burn size across time for 20ms pulse duration, with no significant disruption to either the inner retina or the basal RPE. Higher-fluence 100ms burns developed larger defects due to thermal blooming and collateral damage, with no alteration in burn size across time or any healing laser-tissue interactions. Furthermore, at 6-months, the 20ms laser burns reduced in size without any overlapping laser scars, as the laser burns show healing responses over time. Hence, at different pulse durations, fluence should be titrated to achieve threshold burns in the outer retina, allowing for healing of laser burns and minimisation of photoreceptor injury.

The short pulse (10-30ms) laser burn healing responses have since been reproduced by a number of International groups in the USA and Europe. For visible end-point laser

PRP, a 20ms exposure time is preferable for PRP. This pulse duration can be achieved with standard laser systems as well as with the pattern scan laser systems. Exposure time should be titrated for individual patient as well as depending on laser reaction observed at given laser power setting. Subthreshold PRP is not effective in treating PDR, and there is a risk of bleeding complications due to under-treatment with a subthreshold PRP regimen. Below are the recommendations from the UK RCOphth 2012 guidelines, with 20ms laser settings.

Laser PRP Settings

1) Pulse Duration and Spot Size

Use a 400µm retinal spot size. Smaller retinal spot size, e.g. 200µm and 300µm may lead to excessive higher fluence and risks of Bruch's rupture at 20ms exposure time. Furthermore, following laser burn healing, the final laser spot (burn) may be <100-150µm and patient will require more PRP treatment.

2) Laser burn spacing

Laser burns should be placed 1-burn widths apart for mild and moderate PDR. The space between the laser burns can be reduced for example, 0.5-burn widths apart for severe PDR, TRD and vitreous hemorrhage, with a higher density and number of laser spots.

3) Laser burn intensity

Laser surgeon should aim for a barely-visible, grey/white burn reaction on retina after laser application as the designated threshold. The laser surgeon should be aware that the laser burn intensity at 20ms will increase up to 1 minute after retinal application.

4) Retinal surface coverage

The PRP should be applied as far peripheral as possible using the laser contact lens, up to the ora serrata as the main areas of retinal ischemia in PDR exist in the far-peripheral retina while areas of ischemic penumbra is likely to be in pre-equatorial zones.

Laser Strategy for Primary PRP

1) Early PDR

Primary PRP should be completed by 2 weeks, fractionated if needed (1200- 1800 burns ETDRS strategy). If shorter duration of laser pulse (20ms) used, consider increasing number of laser burns appropriately, Based on laser burn ablation studies, approximately 2400-3500 burns using 20ms PRP are recommended for early PDR. Patient review: 4 months [in non-pregnant patient].

2) Moderate PDR/High-risk PDR

Primary PRP should be completed by 2 weeks, fractionated if needed (2000 -2500 burns ETDRS strategy). If shorter duration of laser pulse (20ms) used, consider increasing number of laser burns. Based on laser burn ablation studies, approximately 4000-5000 burns using 20ms PRP are recommended for early PDR. A complete PRP treatment should be completed over 4 weeks with aiming to deliver more laser spots in the initial sessions. (Level A)

Patient review: 3 months [in non-pregnant patient], however in poorly controlled diabetics, review interval should be shortened.

3) Severe PDR/High-risk PDR

These cases are high risk of continued traction and hemorrhagic complications following PRP. Laser surgeon should aim to deliver full PRP coverage of peripheral retina (3000 burns ETDRS) over 2-3 sessions in 3-4 weeks. If shorter duration of laser pulse (20ms) used, consider increasing number of laser burns appropriately. Based on laser burn ablation studies, approximately 5500-6000 burns using 20ms PRP are recommended for early PDR. The complete PRP treatment should be completed over 4 weeks with aiming to deliver more laser spots in initial sessions. (Level A)

Annex B. Recommended practice for Intravitreal Injection

Intravitreal injections may be performed in an office setting, or an operating room.

Bilateral Injections-The injection for each eye should be considered to be a separate procedure and should be performed accordingly, using separate site preparation and individual syringes, needles, a different medication batch, etc.

Gloves

Sterile or nonsterile gloves may be used.

Talking and use of masks

Minimizing speaking and/or by the use of surgical masks during the injection preparation and procedure is recommended.

Application of Povidone–Iodine to the Ocular Surface and Eyelids

Povidone–iodine (5–10%) should be the last agent applied to the intended injection site before injection. Povidone–iodine may also be applied to the eyelid margins and eyelashes. After the final application of povidone–iodine, the eyelashes and lid margins should not be allowed to come into contact with the injection site until the injection has been completed.

Topical Anesthetics

Topical anesthetics should be applied to minimize patient discomfort.

Site of Injection

Intravitreal injections should be given between the horizontal and vertical rectus muscles at the pars plana, 3.5 to 4.0 mm posterior to the limbus. Quadrant selection should be dictated by both patient-specific considerations and injecting physician preference. A simple perpendicular injection approach is both convenient and preferred in most settings.

Needle Gauge and Length

A 30-gauge or smaller needle is generally preferred for anti-VEGF agents or non-viscous solutions. Larger bore needles can be considered for suspensions (e.g., steroids) and for solutions of higher viscosity. Needle length should be 5/8 inch (18 mm) or shorter but long enough to allow for complete penetration of the pars plana.

Protocol: Sequence of Events

1. Either surgical masks should be used or both the patient and providers should minimize speaking during the injection preparation and procedure;
2. Take a procedural time-out to verify patient, agent, and laterality;
3. Apply liquid anesthetic drops to the ocular surface;
4. Apply povidone–iodine to the eyelashes and lid margins (optional, most use 10%);

5. Retract the eyelids away from the intended injection site;
6. Apply povidone–iodine (most use 5%) to the conjunctival surface, including the intended injection site, at least 30 seconds before injection;
7. If additional anesthetic is applied, reapply povidone–iodine to the intended injection site immediately before injection (most use 5%);
8. Insert the needle perpendicular to the sclera, 3.5 to 4.0 mm posterior to the limbus between the vertical and horizontal rectus muscles.

Annex Table 1. Features of Diabetic Retinopathy (also see the photographs continued in the annex).

Feature	Description	Assessment Considerations
Microaneurysms	Isolated, spherical, red dots of varying size. They may reflect an abortive attempt to form a new vessel or may simply be a weakness of capillary vessel wall through loss of normal structural integrity.	They are easiest seen on fluorescein angiography
Dot hemorrhages	Dot hemorrhages cannot always be differentiated from microaneurysms as they are similar in appearance but with varying size.	The term dot hemorrhage/microaneurysm (H/Ma) is often used.
Blot hemorrhages	Formed where clusters of capillaries occlude leading to formation of intraretinal blot hemorrhages.	The lesion can be seen to be in the outer plexiform layer on fluorescein angiography where it does not mask the overlying capillary bed unlike dot and flame hemorrhages, which lie more superficially in the retina.
Cotton wool spots	These represent the swollen ends of interrupted axons where build-up of axoplasmic flow occurs at the edge of the infarct.	These features are not exclusive to DR and do not in themselves appear to increase the risk of new vessel formation. For example, they may occur in hypertension HIV/ AIDS.

<p>Intraretinal microvascular anomalies</p>	<p>These are dilated capillary remnants following extensive closure of capillary network between arteriole and venule. Associated features include:</p> <ul style="list-style-type: none"> • Venous beading (foci of venous endothelial cell proliferation that have failed to develop into new vessels), • Venous reduplication (rare), • Venous loops (thought to develop due to small vessel occlusion and opening of alternative circulation) and • Retinal pallor and white vessels 	<p>They are easiest seen on fluorescein angiography.</p>
<p>Macular changes in nonproliferative retinopathy – Macular edema – Macrovascular disease</p>	<p>Thickening of retina takes place due to accumulation of exudative fluid from damaged outer blood-retina barrier (extracellular edema) or as a result of hypoxia, leading to fluid accumulating within individual retinal cells (intracellular edema). It may be focal or diffuse. Flame hemorrhage and cotton wool spot formation. May occur due to arteriolar occlusion, without capillary occlusion, which frequently affects the horizontal nerve fiber layer of the retina.</p>	<p>The appearance of macular edema can be appreciated on stereoscopic examination or inferred by the presence of intraretinal exudate.</p>
<p>Optic disc changes</p>	<p>Occasionally swollen optic discs may be seen (diabetic papillopathy) in diabetic patients.</p>	<p>In diabetic papillopathy, vision is usually not significantly impaired.</p>

Annex Table 2. Features of Proliferative Diabetic Retinopathy.

Feature	Description	Assessment Considerations
New vessels at the disc (NVD)	New vessels at the discs usually arise from the venous circulation on the disc or within 1 disc diameter of the disc NVD.	In order to differentiate NVD from fine normal small blood vessels note that the latter always taper to an end and do not loop back to the disc, while NVD always loop back, may form a chaotic net within the loop, and have the top of the loop of wider diameter than the base.
New vessels elsewhere (NVE)	New vessels, which usually occur along the border between healthy retina and areas of capillary occlusion.	Not to be confused with intraretinal microvascular abnormalities, which occur within areas of capillary occlusion.
Other sites of new vessels	New vessel formation on the iris (NVI) is uncommon but represents potentially more advanced ischemic changes. New vessel formation on the anterior hyaloid surface occurs rarely postvitrectomy if insufficient laser has been applied to the peripheral retina.	It is useful to perform gonioscopy in such cases to exclude new vessels in the anterior chamber angle (NVA), which can lead to neovascular glaucoma.
Fibrous proliferation	In proliferative retinopathy, new vessels grow on a platform of glial cells	

Adapted from British The Royal College of Ophthalmologists Diabetic Retinopathy Guidelines December 2012.

Annex Table 3: Available Assessment Instruments and Their Advantages and Disadvantages

Technique	Recommendation	Comments
Direct ophthalmoscopy [#]	<ul style="list-style-type: none"> • Core for management • Pupils must be dilated 	<p><u>Advantages</u></p> <ul style="list-style-type: none"> • Mobile • Inexpensive <p><u>Disadvantages</u></p> <ul style="list-style-type: none"> • Requires pupil dilation • Small field • Low sensitivity: even with a trained practitioner and red free illumination, small microvascular abnormalities may be difficult to detect • Less effective than slit- lamp biomicroscopy through dilated pupils • No ability to retrospectively audit
Indirect ophthalmoscopy [#]	<ul style="list-style-type: none"> • Core for management • Pupils must be dilated 	<p><u>Advantages</u></p> <ul style="list-style-type: none"> • Mobile • Large field • Relatively inexpensive <p><u>Disadvantages</u></p> <ul style="list-style-type: none"> • Requires pupil dilation • Even with a trained practitioner and red free illumination, small microvascular abnormalities may be difficult to detect • Less effective than slit- lamp biomicroscopy through dilated pupils • No ability to retrospectively audit
Slit-lamp biomicroscopy	<ul style="list-style-type: none"> • Core for management 	<p><u>Advantages</u></p> <ul style="list-style-type: none"> • Large field <p><u>Disadvantages</u></p> <ul style="list-style-type: none"> • Requires pupil dilation • Immobile • Requires special lenses • No ability to retrospectively audit

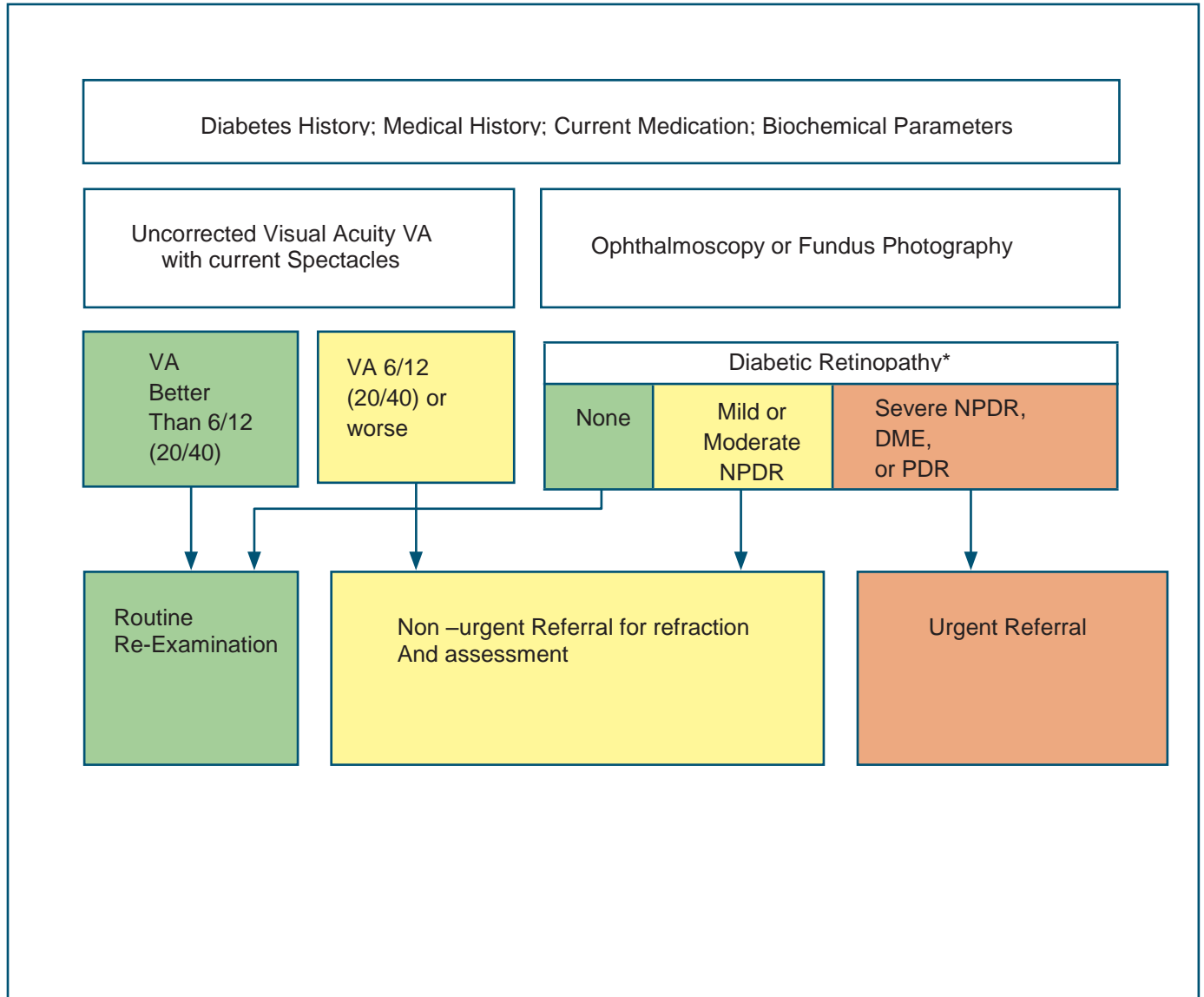
Nonmydriatic retinal photography	<ul style="list-style-type: none"> • Optional for screening and management 	<p><u>Advantages</u></p> <ul style="list-style-type: none"> • Large field • Can be used by non- medically trained staff • No dilation required in 80-90% of cases • Some are portable - can be transported to the community in mobile units • Can be linked to computers and images can be stored for the long term • Allows objective comparison of the same person, or between different groups of people, examined at different times or by different professionals • Can be used as a patient education tool, giving immediacy and personal relevance • Readily recalled for evaluation of screener performance and audit of grading • Auditable <p><u>Disadvantages</u></p> <ul style="list-style-type: none"> • Relatively expensive • A dark space is required for maximum pupil dilation
----------------------------------	---	---

(Continued) Annex Table 3: Available Assessment Instruments and Their Advantages and Disadvantages

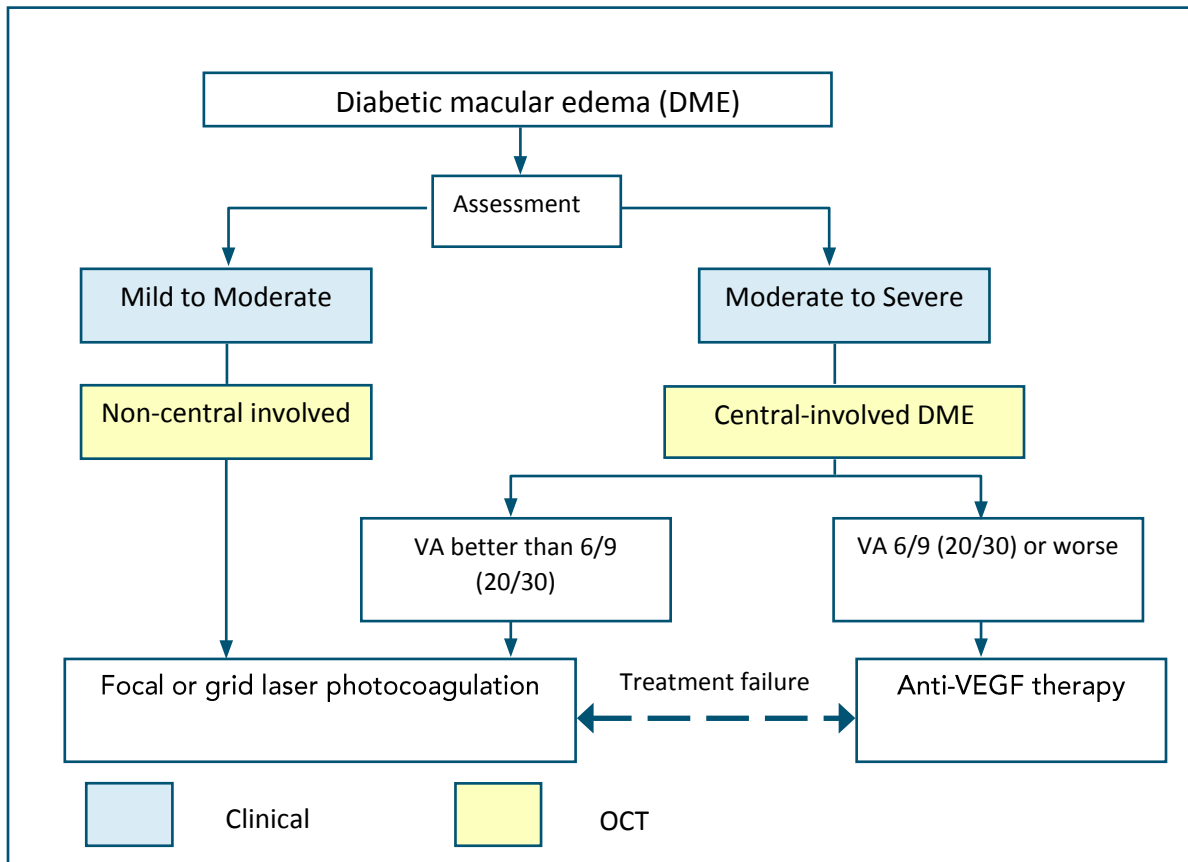
Technique	Recommendation	Comments
Nonmydriatic retinal photography used with mydriasis	<ul style="list-style-type: none"> • Optional for screening and management 	<p><u>Advantages</u></p> <ul style="list-style-type: none"> • As above except pupils are dilated for better quality photos <p><u>Disadvantages</u></p> <ul style="list-style-type: none"> • As above • Requires pupil dilation

<p>Mydriatic retinal photography (conventional fundus camera)</p>	<ul style="list-style-type: none"> • Optional for screening and management 	<p><u>Advantages</u></p> <ul style="list-style-type: none"> • Large field <p><u>Disadvantages</u></p> <ul style="list-style-type: none"> • Requires pupil dilation • Expensive • Bright flash constricts the pupil for a long time
<p>Fluorescein angiography</p>	<ul style="list-style-type: none"> • Not recommended for screening and optional for management 	<p><u>Advantages</u></p> <ul style="list-style-type: none"> • Only method of assessing capillary circulation <p><u>Disadvantages</u></p> <ul style="list-style-type: none"> • Invasive and needs general health status assessment • Expensive • Dilatation needed. Cannot be used by non- medically trained staff
<p>OCT</p>	<ul style="list-style-type: none"> • Optional for screening and management 	<p><u>Advantages</u></p> <ul style="list-style-type: none"> • One of the best ways to assess macular edema (retinal thickening and intraretinal edema) <p><u>Disadvantages</u></p> <ul style="list-style-type: none"> • Expensive • Dilatation needed • Cannot be used by non-medically trained staff

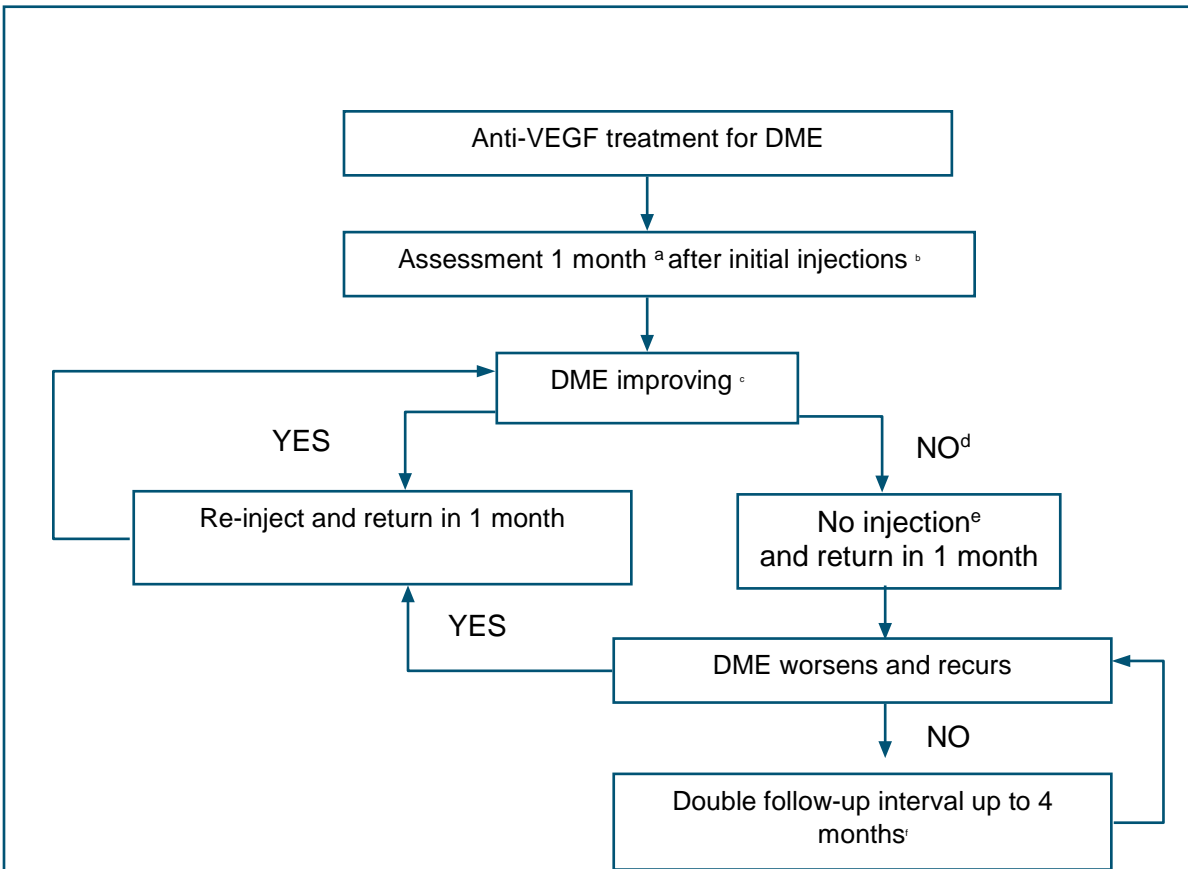
Annex Flowchart 1. Screening for Diabetic Retinopathy



Annex Flowchart 2: Treatment decision tree of DME based on Central-Involvement and Vision



Annex Flowchart 3: Anti-VEGF treatment decision tree based on the DRCR.net re- treatment and follow-up schedule



a. In the DRCR.net study, 4-week, not 1-month, intervals were used.

b. The DRCR.net study required 4 injections of intravitreal ranibizumab every 4 weeks initially; it is not known whether a different number of injections initially would have worked as well. DRCR.net also required 2 additional injections at months 5 and 6 if edema persisted and success had not been met, even in the absence of improvement.

c. Relevant details from the DRCR.net study: 1) DRCR.net "improvement" on Zeiss Stratus OCT >10% decrease in central subfield thickness; 2) Even if no longer improving on OCT, injections continued if VA "improvement" (unless 6/6 or better); 3) VA improvement defined as 5 or more letter increase on Electronic ETDRS Visual Acuity Test.

d. In the DRCR.net study, if focal/grid laser was deferred at baseline, it was added at or after 24 weeks if edema still present and OCT central subfield and vision no longer improving.

e. In the DRCR.net study, all patients received at least 4 injections 4 weeks apart. The decision to re-inject was at investigator discretion, starting at 16 weeks for "success", defined as VA better than 6/6 or OCT central subfield <250µm. Starting at 24 weeks, re-injection was also at investigator discretion if no improvement in OCT central subfield or vision.

f. The DRCR.net study continued to follow-up every 4 weeks through the 52-week visit and did not permit extension of follow-up until after the 52 week visit. If injection was withheld due to no improvement or success at 3 consecutive visits following the week 52 visit, follow-up interval was doubled to 8 weeks and then again to 16 weeks if still no change.

VEGF=vascular endothelial growth factor

DME=diabetic macular edema

VA=visual acuity



Lions Clubs International
FOUNDATION



**World Health
Organization**