

# INTERACTIVE ATLAS OF LEISHMANIASIS IN THE AMERICAS



Clinical Aspects and  
Differential Diagnosis

# PAHO



Pan American  
Health  
Organization



World Health  
Organization  
REGIONAL OFFICE FOR THE  
Americas



# INTERACTIVE ATLAS OF LEISHMANIASIS IN THE AMERICAS



Clinical Aspects and  
Differential Diagnosis

EDITORS: Ana Nilce S. Maia-Elkhoury  
Carlos Arturo Hernández  
Clemencia Ovalle-Bracho  
Jaime Soto  
Samantha Valadas

# PAHO



Pan American  
Health  
Organization



World Health  
Organization  
REGIONAL OFFICE FOR THE  
Americas

Washington, D. C.

2020

Interactive Atlas of Leishmaniasis in the Americas:  
Clinical Aspects and Differential Diagnosis

© Pan American Health Organization, 2020

ISBN: 978-92-75-12190-0

eISBN: 978-92-75-12191-7

Some rights reserved. This work is available under the Creative Commons Attribution-NonCommercial-ShareAlike 3.0 IGO license (CC BY-NC-SA 3.0 IGO);

<https://creativecommons.org/licenses/by-nc-sa/3.0/igo/deed.es>).



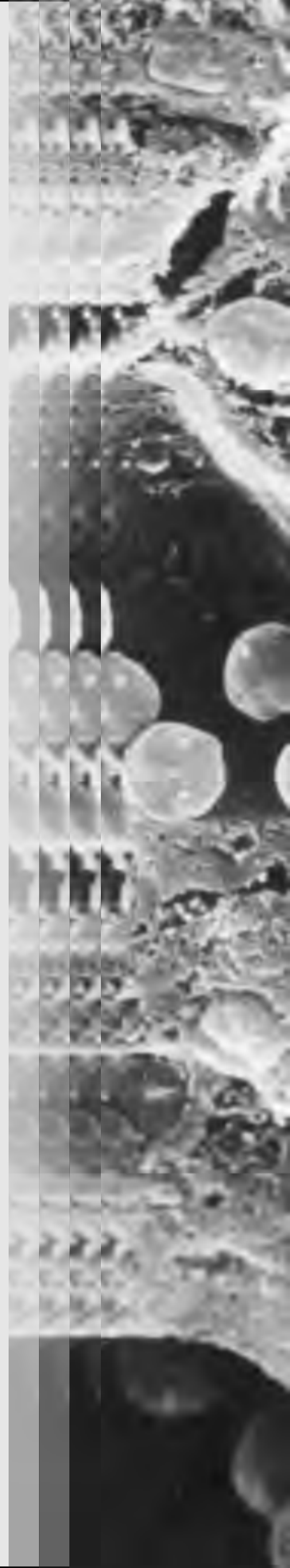Under the terms of this license, this work may be copied, redistributed, and adapted for non-commercial purposes, provided the new work is issued using the same or equivalent Creative Commons license and it is appropriately cited, as indicated below. In any use of this work, there should be no suggestion that the Pan American Health Organization (PAHO) endorses any specific organization, product, or service. Use of the PAHO logo is not permitted.

**Adaptations:** If this work is adapted, the following disclaimer should be added along with the suggested citation: “This is an adaptation of an original work by the Pan American Health Organization (PAHO). Views and opinions expressed in the adaptation are the sole responsibility of the author(s) of the adaptation and are not endorsed by PAHO.”

**Translation:** If this work is translated, the following disclaimer should be added along with the suggested citation: “This translation was not created by the Pan American Health Organization (PAHO). PAHO is not responsible for the content or accuracy of this translation.”

**Suggested citation:** *Interactive Atlas of Leishmaniasis in the Americas: Clinical Aspects and Differential Diagnosis*. Washington, D.C.: Pan American Health Organization; 2020. License: CC BY-NC-SA 3.0 IGO.

**Cataloguing-in-Publication (CIP) data:** are available at <http://apps.who.int/iris/>.



**Sales, rights, and licensing:** To purchase PAHO publications, visit [www.publications.paho.org](http://www.publications.paho.org). To submit requests for commercial use and queries on rights and licensing, visit [www.paho.org/permissions](http://www.paho.org/permissions).

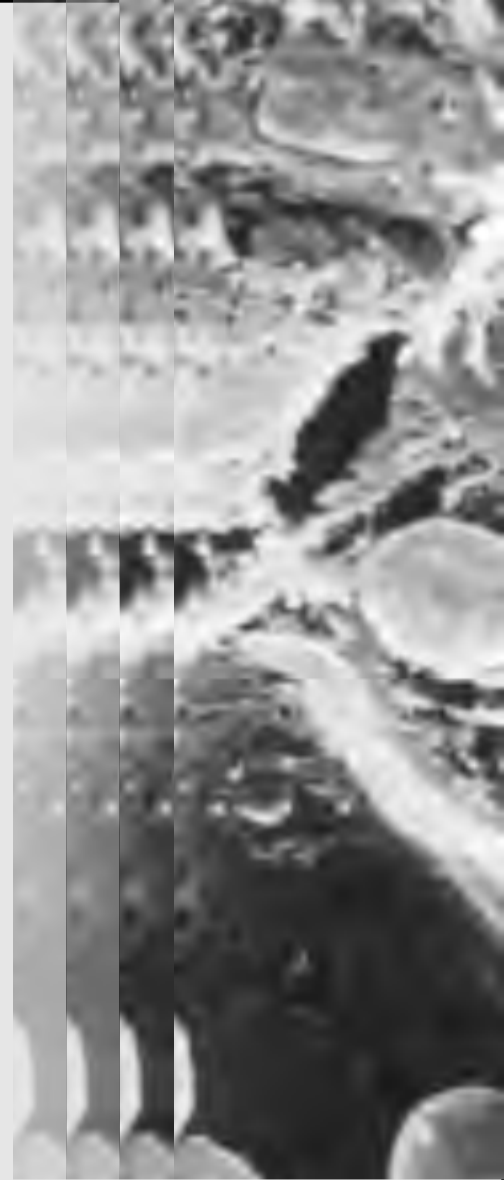
**Third-party materials:** If material that is attributed to a third party, such as tables, figures, or images, is reused from this work, it is the user's responsibility to determine whether permission is needed for that reuse and to obtain permission from the copyright holder. The risk of claims resulting from infringement of any third-party-owned material or component from this work rests solely with the user.

**General disclaimers:** The designations employed and the presentation of the material in this publication do not imply the expression of any opinion whatsoever on the part of PAHO concerning the legal status of any country, territory, city, or area or of its authorities, or concerning the delimitation of its frontiers or boundaries. Dotted and dashed lines on maps represent approximate border lines for which there may not yet be full agreement.

The mention of specific companies or of certain manufacturers' products does not imply that they are endorsed or recommended by PAHO in preference to others of a similar nature that are not mentioned. Errors and omissions excepted, the names of proprietary products are distinguished by initial capital letters.

All reasonable precautions have been taken by PAHO to verify the information contained in this publication. However, the published material is being distributed without warranty of any kind, either expressed or implied. The responsibility for the interpretation and use of the material lies with the reader. In no event shall PAHO be liable for damages arising from its use.

CDE/VT/2020



**Editorial Coordination:**

Carlos Arturo Hernández

**Photographs and Illustrations:**

**Compilation:**

Ana Nilce S. Maia-Elkhoury  
Samantha Valadas

**Initial Selection:**

Carlos Arturo Hernández

**Digital Retouching and Edition:**

David Arturo Hernández-Mora

**Final Selection:**

Carlos Arturo Hernández  
Jaime Soto  
Ana Nilce S. Maia-Elkhoury

**Style Correction:**

Carlos Arturo Hernández  
María Cristina Mora

**Design and Layout:**

David Arturo Hernández-Mora

# INDEX

Preface .....	XI
Authors .....	XIII
Reproductions from Publications .....	XVII
Photographs and Illustrations .....	XVII
Acknowledgements .....	XXX
<b>CHAPTER 1. OVERVIEW</b>	<b>1</b>
<b>Definition</b> .....	<b>2</b>
<i>Óscar Daniel Salomón</i>	
<b>A Brief History of   Leishmaniases in the Americas</b> .....	<b>5</b>
<i>Jeffrey Jon Shaw</i>	
<b>Parasites</b> .....	<b>20</b>
<i>Elisa Cupolillo</i>	
<b>Vectors</b> .....	<b>43</b>
<i>Óscar Daniel Salomón</i>	
<b>Reservoirs</b> .....	<b>53</b>
<i>André Luiz Rodrigues Roque and Ana María Jansen</i>	
<b>Epidemiological Situation of the Leishmaniases</b>	<b>66</b>
<i>Ana Nilce Silveira Maia-Elkhoury and Samantha Yuri Oshiro     Branco Valadas</i>	
<b>CHAPTER 2. IMMUNOPATHOGENESIS OF LEISHMANIASSES</b>	<b>82</b>
<i>María Adelaida Gómez, María del Mar Castro and Nancy Gore Saravia</i>	
<b>Microbiology</b> .....	<b>83</b>
<b>Pathogenesis</b> .....	<b>86</b>
• <b>Cutaneous and mucosal leishmaniasis</b> .....	<b>87</b>
• <b>Visceral leishmaniasis</b> .....	<b>94</b>
• <b>Asymptomatic infection</b> .....	<b>95</b>
<b>Immunological Response</b> .....	<b>96</b>

# INDEX

## CHAPTER 3. CUTANEOUS LEISHMANIASIS 100

*Clemencia Ovalle-Bracho, Carlos Arturo Hernández, Ana Nilce Silveira Maia-Elkhoury, Sandra Muvdi-Arenas, Claudia Arenas, Gerzaín Rodríguez, Paulo Roberto Lima Machado, Jackson Mauricio Lopes Costa, Carolina Camargo and Jaime Soto*

Localized Cutaneous Leishmaniasis .....	102
• Definition, agents, vectors and reservoirs .....	102
• Clinical manifestations .....	104
• Laboratory diagnosis .....	176
• Treatment and follow-up .....	178
Disseminated Leishmaniasis .....	182
• Definition, agents, vectors and reservoirs .....	182
• Clinical manifestations .....	184
• Laboratory diagnosis .....	188
• Treatment and follow-up .....	189
Diffuse Cutaneous Leishmaniasis .....	190
• Definition, agents, vectors and reservoirs .....	190
• Clinical manifestations .....	191
• Laboratory diagnosis .....	197
• Treatment and follow-up .....	197
Atypical Cutaneous Leishmaniasis .....	198

## CHRONIC RELAPSING CUTANEOUS LEISHMANIASIS 200

*Jaime Soto*

## DIFFERENTIAL DIAGNOSIS 221

*Jaime Soto, Carlos Arturo Hernández, Ana Nilce Silveira Maia-Elkhoury, Gerzaín Rodríguez, Clemencia Ovalle-Bracho, Claudia Arenas and Carolina Camargo*

Infections .....	229
• Pyogenous bacterial ulcers .....	229
• Ecthyma .....	229
• Impetigo .....	229
• Furunculosis .....	235

## INDEX

• Primary syphilis .....	235
• Nontuberculous mycobacteria .....	235
• Cutaneous tuberculosis .....	239
• Scrofuloderma .....	241
• Lupus vulgaris .....	247
• Leprosy .....	250
• Chromomycosis .....	258
• Sporotrichosis .....	263
• Histoplasmosis .....	271
• Lobomycosis .....	279
• Paracoccidioidomycosis .....	284
<b>Inflammatory and Reactive Diseases .....</b>	<b>289</b>
• Venous ulcers .....	289
• Arterial ulcers .....	297
• Mixed vascular ulcers .....	299
• Infections in vascular ulcers .....	303
• Vascular diseases .....	307
• Diabetic ulcer .....	308
• Discoid lupus .....	309
• Psoriasis .....	311
• Dermal necrosis .....	313
• Sickle cell anemia .....	314
• Traumatic ulcers .....	315
• Insect bites .....	317
• Pyoderma gangrenosum .....	318
• Cutaneous sarcoidosis .....	321
• Granuloma faciale .....	324
• Banal ulcer .....	324
<b>Malignant Neoplasms .....</b>	<b>325</b>
• Basal cell carcinoma .....	325
• Squamous cell carcinoma .....	333
• Keratoacanthoma .....	341
• Cutaneous lymphoma .....	344
• Lymphocytoma cutis .....	347
• Hemangioma .....	347
• Kaposi's sarcoma .....	347



# INDEX

## **CHAPTER 4. 356** **MUCOSAL LEISHMANIASIS**

*Alejandro Llanos-Cuentas, Edgar M. Carvalho, Paulo Roberto Lima Machado, Braulio Valencia, Ana Pilar Ramos and Jaime Soto*

Definition, Agents, Vectors and Reservoirs .....	357
Clinical Manifestations .....	360
Laboratory Diagnosis .....	437
Treatment .....	438
Follow-up .....	442

### **DIFFERENTIAL DIAGNOSIS ..... 443**

*Jaime Soto, Carlos Arturo Hernández, Ana Nilce Silveira Maia-Elkhoury, Gerzaín Rodríguez, Clemencia Ovalle-Bracho, Claudia Arenas and Carolina Camargo*

Infections .....	445
• Paracoccidioidomycosis .....	445
• Leprosy.....	451
• Tuberculosis .....	455
• Histoplasmosis .....	455
• Syphilis.....	455
• Rhinoscleroma .....	463
• Rhinosporidiosis .....	463
• Rhinoentomophthoromycosis .....	463
• Mucormycosis .....	463
Tumors .....	475
• Adenoma .....	475
• Basal cell carcinoma .....	477
• Squamous cell carcinoma .....	477
• Epidermoid carcinoma .....	482
• Cutaneous nasal T cell lymphoma .....	482
Miscellaneous .....	487
• Banal perforation of the nasal septum .....	487

# INDEX

- Rhinophyma ..... 488
- Sarcoidosis ..... 488
- Cocaine use ..... 488
- Granulomatosis with polyangiitis  
(previously known as Wegener's granulomatosis) .. 488

## **CHAPTER 5. VISCERAL LEISHMANIASIS, POST-KALA-AZAR AND PARA-KALA- AZAR DERMAL LEISHMANIASIS 493**

### **VISCERAL LEISHMANIASIS ..... 494**

*Dorcas Lamounier Costa and Carlos Henrique Nery Costa*

- Definition, Agent, Vectors and Reservoirs..... 495
- Clinical Manifestations ..... 497
  - In immunosuppressed patients ..... 512
- Differential Diagnosis ..... 513
- Laboratory Diagnosis ..... 514
- Treatment ..... 517
  - In immunosuppressed patients ..... 518
- Follow-up and Criteria for Cure..... 519

### **POST-KALA-AZAR AND PARA-KALA-AZAR DERMAL LEISHMANIASIS ..... 521**

*José Angelo Lauletta Lindoso*

- Post-Kala-Azar Dermal Leishmaniasis..... 522
- Para-Kala-Azar Dermal Leishmaniasis..... 525

### **CLINICAL CASE ..... 526**

*Mônica Elinor Alves Gama, Diego Aguiar, Leônidas Lopes Braga  
Júnior, Cláudia Maria de Castro Gomes, Dewton de Moraes Vasconce-  
los and José Angelo Lauletta Lindoso*

## **APPENDIX 533**

- Table Index ..... 534
- Figure Subject Index ..... 537

## PREFACE

In the Region of the Americas, the leishmaniasis are a group of diseases caused by various species of *Leishmania*, which cause a set of clinical syndromes in infected humans that can involve the skin, mucosa, and visceral organs. The spectrum of clinical disease is varied and depends on the interaction of several factors related to the parasite, the vector, and the host.

Cutaneous leishmaniasis is the form most frequently reported in the Region and nearly 90% of cases present single or multiple localized lesions. Other cutaneous clinical forms, such as disseminated and diffuse cutaneous leishmaniasis, are more difficult to treat and relapses are common. The mucosal form is serious because it can cause disfigurement and severe disability if not diagnosed and treated early on. Visceral leishmaniasis is the most severe form, as it can cause death in up to 90% of untreated people.

In the Americas, clinical differences can be frequently found between endemic countries, mainly in the cutaneous form. Furthermore, many other diseases can be confused clinically with the different presentations of leishmaniasis and this is one of the greatest challenges for diagnosticians of the disease, who must also be aware of epidemiological reports and the patient's clinical history.

This *Interactive Atlas of Leishmaniasis in the Americas: Clinical Aspects and Differential Diagnosis* is a joint effort of the Pan American Health Organization, experts on this subject, and other collaborators, with support from the Federico Lleras Acosta University Hospital Dermatology Center of Colombia and the health ministries of the countries of the Region. This is an important and innovative publication that takes a practical approach to the subject, allowing professionals to interactively search for and study photographs and illustrations that reflect their daily work in the health services.

The atlas discusses the main concepts and knowledge about leishmaniasis in the Americas, illustrating the clinical situation of these diseases in 10 endemic countries, through 1,029 photographs and illustrations that can be viewed on smartphones, tablets, and desktop or laptop computers. We believe the material will be valuable for all students and professionals at all levels of health care, including those in other continents, when treating patients infected in the Americas.

Ana Nilce S. Maia-Elkhoury  
Regional Advisor on Leishmaniasis  
Neglected, Tropical, and Vector-Borne Diseases Unit  
Department of Communicable Diseases and Environmental  
Determinants of Health  
Pan American Health Organization

## AUTHORS

### *Diego Aguilar*

Infectious Diseases Service, University Hospital, Federal University of Maranhão, São Luís (Maranhão, Brazil)

### *Claudia Arenas*

Federico Lleras Acosta Dermatology Center, Bogota (Colombia)

### *Leônidas Lopes Braga Júnior*

Infectious Diseases Service, University Hospital, Federal University of Maranhão, São Luís (Maranhão, Brazil)

### *Carolina Camargo*

Federico Lleras Acosta Dermatology Center, Bogota (Colombia)

### *Edgar M. Carvalho*

Gonçalo Moniz Institute, Oswaldo Cruz Foundation (Fiocruz), Immunology Service, Salvador (Bahia, Brazil)

### *María Del Mar Castro*

International Medical Training and Research Center (CIDEIM), Cali (Valle, Colombia); ICESI University, Cali (Valle, Colombia)

### *Dorcas Lamounier Costa*

Federal University of Piauí, Teresina (Piauí, Brazil)

### *Jackson Mauricio Lopes Costa*

Gonçalo Moniz Institute, Oswaldo Cruz Foundation (Fiocruz), Salvador (Bahia, Brazil)

### *Carlos Henrique Nery Costa*

Federal University of Piauí, Teresina (Piauí, Brazil)

***Elisa Cupolillo***

Leishmaniasis Research Laboratory, Oswaldo Cruz Institute, Oswaldo Cruz Foundation (Fiocruz), Rio de Janeiro (Rio de Janeiro, Brazil)

***Mônica Elinor Alves Gama***

Department of Medicine III, Federal University of Maranhão, São Luís (Maranhão, Brazil)

***Cláudia Maria De Castro Gomes***

Department of Pathology, School of Medicine, University of São Paulo, São Paulo (São Paulo, Brazil)

***María Adelaida Gómez***

International Medical Training and Research Center (CIDEIM), Cali (Valle, Colombia); ICESI University, Cali (Valle, Colombia)

***Carlos Arturo Hernández***

Federico Lleras Acosta Dermatology Center, Bogotá (Colombia); National Institute of Health, Bogotá (Colombia)

***Ana Maria Jansen***

Trypanosomatidae Biology Laboratory, Oswaldo Cruz Institute, Oswaldo Cruz Foundation (Fiocruz), Rio de Janeiro (Rio de Janeiro, Brazil)

***José Angelo Lauletta Lindoso***

Emílio Ribas Institute of Infectious Diseases, São Paulo (São Paulo, Brazil)

***Alejandro Llanos-Cuentas***

Alexander von Humboldt Institute of Tropical Medicine, Cayetano Heredia Peruvian University, Lima (Peru); Carlos Vidal Layseca School of Public Health and Administration, Cayetano Heredia Peruvian University, Lima (Peru)

***Paulo Roberto Lima Machado***

Professor Edgard Santos University Hospital, Immunology Service, Salvador (Bahia, Brazil)

***Ana Nilce Silveira Maia-Elkhoury***

Pan American Health Organization, World Health Organization, CDE-VT, Duque de Caxias (Rio de Janeiro, Brazil)

***Sandra Muvdi-Arenas***

Federico Lleras Acosta Dermatology Center, Bogota (Colombia)

***Clemencia Ovalle-Bracho***

Federico Lleras Acosta Dermatology Center, Bogota (Colombia); Javieriana Pontifical University, Bogotá (Colombia)

***Ana Pilar Ramos***

Alexander von Humboldt Institute of Tropical Medicine, Cayetano Heredia Peruvian University, Lima (Peru)

***André Luiz Rodrigues Roque***

Trypanosomatidae Biology Laboratory, Oswaldo Cruz Institute, Oswaldo Cruz Foundation (Fiocruz), Rio de Janeiro (Rio de Janeiro, Brazil)

***Gerzaín Rodríguez***

Federico Lleras Acosta Dermatology Center, Bogota (Colombia)

***Óscar Daniel Salomón***

National Institute of Tropical Medicine of Argentina, Puerto Iguazú (Misiones, Argentina)

***Nancy Gore Saravia***

International Medical Training and Research Center (CIDEIM), Cali (Valle, Colombia); ICESI University, Cali (Valle, Colombia)

*Jeffrey Jon Shaw*

Department of Parasitology, Institute of Biomedical Sciences, University of São Paulo (São Paulo, Brazil)

*Jaime Soto*

National Dermatology Center (Funderma), Santa Cruz de la Sierra (Santa Cruz, Bolivia); Dermatology Hospital of Jorochito, Jorochito (Santa Cruz, Plurinational State of Bolivia)

*Samantha Yuri Oshiro Branco Valadas*

Pan American Health Organization, World Health Organization, CDE-VT, Duque de Caxias (Rio de Janeiro, Brazil)

*Braulio Valencia*

Alexander von Humboldt Institute of Tropical Medicine, Cayetano Heredia Peruvian University, Lima (Peru)

*Dewton De Moraes Vasconcelos*

Institute of Tropical Medicine, University of São Paulo, São Paulo (São Paulo, Brazil)



## Reproductions from Publications

- Rodríguez Bermúdez JC. Contribución al estudio de la leishmaniosis tegumentaria en Colombia. Bogotá: Editorial Minerva; 1929. *Figures: 1.2A, 1.2B, 1.2C*
- Pan American Health Organization. Manual of procedures for surveillance and control of leishmaniasis in the Americas. Washington, D.C.: Pan American Health Organization; 2019. *Figures: 1.5A, 1,17, 1.22, 1.23, 1.24B, 3.46, 3.204A, 3.204B, 4.57A, 4.61A, 5.7B, 5.10B, 5.13A, 5.13B*
- Rodríguez G, Arenas C, Ovalle C, Hernández CA, Camargo C. Las leishmaniasis: atlas y texto. Bogotá: Hospital Universitario Centro Dermatológico Federico Lleras Acosta; 2016. *Figures: 1.6, 1.7D, 1.11, 3.217A, 3.217B, 3.217C, 3.217D, 3.217E, 3.223A, 3.223B, 3.225, 3.226, 3.227A, 3.227B, 3.227C, 3.227D, 3.228A, 3.228B, 3.228C, 3.229A, 3.229B, 3.230C, 3.230D, 3.230E, 3.231A, 3.231B, 3.231C, 3.232A, 3.232B, 3.233A, 3.233B, 3.233C, 3.235A, 3.235B, 3.235C, 3.235D, 3.235E, 3.235F, 3.236A, 3.236B, 3.236C, 3.237A, 3.237B, 3.237C, 3.237D, 3.237E, 3.237F, 3.238A, 3.238B, 3.238C, 3.239A, 3.239B, 3.240A, 3.240B, 3.241A, 3.241B, 3.241C, 3.241D, 3.246B, 3.246C, 3.246D, 3.246I, 3.246J, 3.247A, 3.247B, 3.247C, 3.247D, 3.248A, 3.248B, 3.248C, 3.248D, 3.248E, 3.249C, 3.249D, 3.249E, 3.249F, 3.249G, 3.249H, 3.249I, 3.250A, 3.250B, 3.250C, 3.251A, 3.251B, 3.251C, 3.251D, 3.251E, 3.252A, 3.252B, 3.252C, 3.253A, 3.253B, 3.254A, 3.254B, 3.254C, 3.254D, 3.254E, 3.255A, 3.255B, 3.255C, 3.256A, 3.256B, 3.256C, 3.256D, 3.256E, 3.256F, 3.257, 3.258, 3.259, 3.260, 3.261, 3.262A, 3.262B, 3.262C, 3.262D, 3.262E, 3.263A, 3.263B, 3.263C, 3.263D, 3.264A, 3.264B, 3.265A, 3.265B, 3.266A, 3.266B, 3.266C, 3.266D, 3.267A, 3.267B, 3.267C, 3.267D, 3.268A, 3.268B, 3.287A, 3.287B, 3.287C, 3.288, 3.290B, 3.291A, 3.291B, 3.292A, 3.292B, 3.292C, 3.292D, 3.293A, 3.293B, 3.295A, 3.295B, 3.295C, 3.310, 3.311, 3.312, 3.313, 3.314, 3.315, 3.316, 3.318, 3.319A, 3.319B, 3.336, 3.337, 3.338, 3.339, 4.75E, 4.75F, 4.75G, 4.75H, 4.75I, 4.77A, 4.77B, 4.77C, 4.78B, 4.79A, 4.79B, 4.79C, 4.79D, 4.79E, 4.79F, 4.80A, 4.80B, 4.80C, 4.81B, 4.81C, 4.82A, 4.82B, 4.82C, 4.83A, 4.83B, 4.83C, 4.83D, 4.83E, 4.84A, 4.84B, 4.84C, 4.84D, 4.84E, 4.85A, 4.85C, 4.85D, 4.85E, 4.85F, 4.85G, 4.85H, 4.86A, 4.86B, 4.86C, 4.87, 4.88A, 4.88B, 4.88C, 4.88D, 4.88E, 4.89A, 4.89B, 4.90A, 4.90B, 4.90C, 4.90D, 4.90E, 4.95A, 4.95B, 4.95C, 4.95D, 4.95F, 4.96A, 4.96B, 4.96C, 4.100A, 4.100B, 4.100C, 4.100D, 4.100E, 5.2*
- *Biomédica* (journal):
  - Ferro MC. Colonia de *Lutzomyia longipalpis*. 1998;18(4). *Figure: 1.14*
  - Yung JB. Promastigotes de *Leishmania* spp. 2019;39(3). *Figure: 1.5D*
  - Pardo R, Cabrera OL, López R, Suárez MF. Insectos vectores de agentes infecciosos. *Biomédica*. 2017;37(Supl.2):15-26. *Figures: 1.10, 1.13A, 1.13B, 1.15A, 1.15B*

## PHOTOGRAPHS AND ILLUSTRATIONS

COUNTRY	COLLABORATORS	PHOTOGRAPHS AND ILLUSTRATIONS
<p><b>BOLIVIA (PLURINA- TIONAL STATE OF)</b></p>	<p><i>Jaime Soto</i>, National Dermatology Foundation (Funderma), Santa Cruz; Dermatology Hospital of Jorochito, Santa Cruz</p>	<p>3.5, 3.15, 3.17, 3.18, 3.24, 3.25, 3.27A, 3.27B, 3.27C, 3.27D, 3.28, 3.29A, 3.29B, 3.32A, 3.32B, 3.35, 3.38, 3.42, 3.47, 3.50, 3.52, 3.57, 3.58, 3.59, 3.60, 3.63, 3.64, 3.71, 3.72, 3.74, 3.76, 3.84A, 3.84B, 3.84C, 3.92, 3.95, 3.96, 3.100, 3.101, 3.103, 3.107, 3.108, 3.110, 3.112A, 3.112B, 3.115A, 3.115B, 3.116, 3.118, 3.119, 3.120, 3.123A, 3.123B, 3.125, 3.126A, 3.126B, 3.126C, 3.130, 3.131A, 3.131B, 3.131C, 3.135, 3.137A, 3.137B, 3.138, 3.142, 3.146, 3.148, 3.150, 3.151, 3.152, 3.153A, 3.153B, 3.154, 3.158, 3.159, 3.160, 3.162, 3.163, 3.164A, 3.164B, 3.165, 3.166, 3.169, 3.171, 3.174, 3.175, 3.176, 3.177, 3.178, 3.180, 3.181, 3.182, 3.184, 3.205A, 3.205B, 3.205C, 3.205D, 3.205E, 3.205F, 3.205G, 3.205H, 3.206A, 3.206B, 3.206C, 3.206D, 3.207A, 3.207B, 3.207C, 3.207D, 3.208A, 3.208B, 3.208C, 3.208D, 3.208E, 3.208F, 3.208G, 3.208H, 3.208I, 3.208J, 3.208K, 3.208L, 3.209A, 3.209B, 3.209C, 3.209D, 3.209E, 3.209F, 3.210A, 3.210B, 3.210C, 3.210D, 3.210E, 3.210F, 3.211A, 3.211B, 3.211C, 3.212A, 3.212B, 3.213A, 3.213B, 3.213C, 3.213D, 3.213E, 3.214A, 3.214B, 3.214C, 3.214D, 3.215A, 3.215B, 3.216A, 3.216B, 3.216C, 3.218, 3.219A, 3.219B, 3.220, 3.221, 3.222A, 3.222B, 3.222C, 3.224, 3.230A, 3.230B, 3.234A,</p>

COUNTRY	COLLABORATORS	PHOTOGRAPHS AND ILLUSTRATIONS
BOLIVIA (PLURINA- TIONAL STATE OF)	<i>Jaime Soto</i> , National Dermatology Foundation (Funderma), Santa Cruz; Dermatology Hospital of Jorochito, Santa Cruz	3.234B, 3.242A, 3.242B, 3.243, 3.244A, 3.244B, 3.245A, 3.245B, 3.246A, 3.246E, 3.246F, 3.246G, 3.246H, 3.249A, 3.249B, 3.265C, 3.269A, 3.269B, 3.269C, 3.270A, 3.270B, 3.270C, 3.271A, 3.271B, 3.271C, 3.272A, 3.272B, 3.272C, 3.272D, 3.272E, 3.273A, 3.273B, 3.273C, 3.273D, 3.273E, 3.273F, 3.273G, 3.274A, 3.274B, 3.274C, 3.274D, 3.275A, 3.275B, 3.275C, 3.275D, 3.275E, 3.275F, 3.276A, 3.276B, 3.277A, 3.277B, 3.277C, 3.277D, 3.277E, 3.277F, 3.277G, 3.277H, 3.278A, 3.278B, 3.278C, 3.279A, 3.279B, 3.280A, 3.280B, 3.281A, 3.281B, 3.281C, 3.282, 3.283, 3.284, 3.285A, 3.285B, 3.286, 3.289A, 3.289B, 3.290A, 3.292E, 3.296, 3.297, 3.298, 3.299A, 3.299B, 3.300A, 3.300B, 3.301, 3.302A, 3.302B, 3.303, 3.304, 3.305A, 3.305B, 3.306, 3.307, 3.308, 3.309A, 3.309B, 3.317A, 3.317B, 3.320A, 3.320B, 3.320C, 3.321A, 3.321B, 3.322, 3.323A, 3.323B, 3.323C, 3.324, 3.325, 3.326A, 3.326B, 3.327, 3.328, 3.329A, 3.329B, 3.330A, 3.330B, 3.331, 3.332A, 3.332B, 3.333, 3.334A, 3.334B, 3.334C, 3.335A, 3.335B, 3.340, 3.341, 4.3A, 4.3B, 4.3C, 4.4A, 4.4B, 4.4C, 4.6A, 4.6B, 4.7A, 4.7B, 4.8, 4.11, 4.14A, 4.14B, 4.15, 4.20A, 4.21, 4.22, 4.24, 4.26A, 4.26B, 4.28A, 4.28B, 4.29A, 4.29B, 4.30A, 4.30B, 4.30C, 4.30D, 4.30E, 4.30F, 4.32A, 4.32B, 4.33A, 4.33B, 4.35A, 4.35B, 4.35C, 4.36A, 4.36B, 4.36C,

COUNTRY	COLLABORATORS	PHOTOGRAPHS AND ILLUSTRATIONS
BOLIVIA (PLURINA- TIONAL STATE OF)	<i>Jaime Soto</i> , National Dermatology Foundation (Funderma), Santa Cruz; Dermatology Hospital of Jorochito, Santa Cruz	4.36D, 4.38, 4.39, 4.40, 4.41A, 4.41B, 4.41C, 4.42, 4.43A, 4.43B, 4.43C, 4.43D, 4.43E, 4.43F, 4.43G, 4.44A, 4.44B, 4.45A, 4.45B, 4.45C, 4.45D, 4.45E, 4.46, 4.47A, 4.47B, 4.47C, 4.48A, 4.48B, 4.53, 4.54, 4.55A, 4.55B, 4.55C, 4.56A, 4.56B, 4.56C, 4.56D, 4.58A, 4.58B, 4.59A, 4.59B, 4.59C, 4.59D, 4.59G, 4.59H, 4.59I, 4.59J, 4.59K, 4.59L, 4.59M, 4.59N, 4.59O, 4.59P, 4.59Q, 4.59R, 4.59S, 4.59T, 4.60A, 4.60B, 4.60C, 4.60D, 4.60E, 4.60F, 4.60G, 4.60H, 4.60I, 4.60J, 4.60L, 4.60M, 4.60N, 4.60O, 4.60P, 4.60Q, 4.61B, 4.61C, 4.61D, 4.61E, 4.61F, 4.61G, 4.61H, 4.61I, 4.61J, 4.61K, 4.61L, 4.61M, 4.61N, 4.64, 4.65A, 4.65B, 4.65C, 4.65D, 4.65E, 4.66A, 4.66B, 4.66C, 4.66D, 4.66E, 4.67A, 4.67B, 4.67C, 4.67D, 4.67E, 4.68A, 4.68B, 4.68C, 4.69, 4.70A, 4.70B, 4.70C, 4.71A, 4.71B, 4.71C, 4.71D, 4.71E, 4.74A, 4.74B, 4.91, 4.92C, 4.92D, 4.93A, 4.93B, 4.94A, 4.94B, 4.94C
	<i>Valdir Sabbaga Amato</i> , School of Medicine, University of São Paulo, São Paulo, São Paulo	4.59U, 4.60K
BRAZIL	<i>Leônidas Lopes Braga Júnior</i> , Infectious Disease Service, University Hospital, Federal University of Maranhão, São Luís, Maranhão	5.15, 5.16A, 5.16B, 5.17A, 5.17B

COUNTRY	COLLABORATORS	PHOTOGRAPHS AND ILLUSTRATIONS
	<p><i>Dorcas Lamounier Costa</i>, Federal University of Piauí, Teresina, Piauí</p> <p><i>Jackson Mauricio Lopes Costa</i>, Gonçalo Moniz Institute, Oswaldo Cruz Foundation, Salvador, Bahia</p> <p><i>Carlos Henrique Nery Costa</i>, Federal University of Piauí, Teresina, Piauí</p>	<p>5.3A, 5.3B, 5.4, 5.6A, 5.6B, 5.6C, 5.7A, 5.7C, 5.8A, 5.8B, 5.8C, 5.8D, 5.9A, 5.9B, 5.9C, 5.9D, 5.9E, 5.9F, 5.9G, 5.9H, 5.10A, 5.10C, 5.10D, 5.11A, 5.11B, 5.11C, 5.11D, 5.11E, 5.11F, 5.11G, 5.12A, 5.12B, 5.12C, 5.12D</p> <p>3.190, 3.191A, 3.191B, 3.192, 3.193, 3.194, 3.195, 3.198A, 3.198B, 3.199, 3.200, 3.201</p> <p>5.3A, 5.3B, 5.4, 5.6A, 5.6B, 5.6C, 5.7A, 5.7C, 5.8A, 5.8B, 5.8C, 5.8D, 5.9A, 5.9B, 5.9C, 5.9D, 5.9E, 5.9F, 5.9G, 5.9H, 5.10A, 5.10C, 5.10D, 5.11A, 5.11B, 5.11C, 5.11D, 5.11E, 5.11F, 5.11G, 5.12A, 5.12B, 5.12C, 5.12D</p>
BRAZIL	<p><i>Elisa Cupolillo</i>, Leishmaniasis Research Laboratory, Oswaldo Cruz Institute, Oswaldo Cruz Foundation, Rio de Janeiro, Rio de Janeiro</p> <p><i>Jorge Augusto De Oliveira Guerra</i>, Dr. Heitor Vieira Dourado Tropical Medicine Foundation, Manaus, Amazonas</p>	<p>1.9A, 1.9B, 1.9C</p> <p>3.6, 3.26, 3.81, 3.145, 3.173, 3.179, 3.188, 4.2A</p>

COUNTRY	COLLABORATORS	PHOTOGRAPHS AND ILLUSTRATIONS
BRAZIL	<i>Marcia Hueb</i> , Julio Muller University Hospital, Federal University of Mato Grosso, Cuiabá, Mato Grosso	3.20, 3.33, 3.40, 3.41, 3.77A, 3.77B, 3.78, 3.89, 3.109, 3.156, 3.183, 3.185, 4.5A, 4.5B, 4.52, 4.75A, 4.75B
	<i>Oswaldo Cruz Institute, Oswaldo Cruz Foundation</i> , Leishmania Collection, Rio de Janeiro, Rio de Janeiro	1.5B
	<i>Oswaldo Cruz House</i> , Historical archive, Rio de Janeiro, Rio de Janeiro	1.3A, 1.3B, 1.3C, 1.4
	<i>Luisa Keiko Oyafuso</i> , Emílio Ribas Institute of Infectious Disease, São Paulo, São Paulo	3.73, 3.127
	<i>José Angelo Lauletta Lindoso</i> , Emílio Ribas Institute of Infectious Disease, São Paulo, São Paulo	3.73, 3.127, 3.294, 4.34B, 4.50, 4.97
	<i>Marcelo Rosandinski Lyra</i> , Evandro Chagas National Institute of Infectious Disease, Oswaldo Cruz Foundation, Rio de Janeiro	3.189A, 3.189B, 3.189C, 3.189D

COUNTRY	COLLABORATORS	PHOTOGRAPHS AND ILLUSTRATIONS
	<i>Paulo Roberto Lima Machado</i> , Professor Edgard Santos University Hospital, Immunology Service, Salvador, Bahia	3.186A, 3.186B, 3.187A, 3.187B
	<i>Ana Nilce Silveira Maia-Elkhoury</i> , Pan American Health Organization, World Health Organization, CDE-VT, Duque de Caxias, Rio de Janeiro	3.204A, 3.204B
BRAZIL	<i>Pan American Health Organization/World Health Organization</i> , Duque de Caxias, Rio de Janeiro	1.29, 1.30, 1.31, 1.32, 1.33, 1.34, 1.35, 1.36, 5.5A, 5.5B, 5.5C, 5.5D
	<i>Rita De Cassia Soler</i> , Emilio Ribas Infectious Disease Teaching Hospital, São Paulo, São Paulo	3.294, 4.34B, 4.50, 4.97
	<i>Claudia Batista Câmara Suleiman</i> , Regional Hospital of Araguaína, Araguaína, Tocantins	5.14A, 5.14B, 5.14C

COUNTRY	COLLABORATORS	PHOTOGRAPHS AND ILLUSTRATIONS
COLOMBIA	<i>María Claudia Barrera</i> , Research Group on Rheumatology, Autoimmunity, and Translational Medicine, ICESI University, Cali	2.1
	<i>Jorge Ramiro Barrero-Sánchez (R.I.P)</i> , Medical School, National University of Colombia, Bogota, D.C.	4.99
	<i>Sergio Córdoba-Córdoba</i> , University of Applied and Environmental Sciences (U.D.C.A.), Bogota, D.C.	1.1, 1.16, 1.18, 1.19, 1.20, 1.21, 1.25, 1.26
	<i>Entomology Group</i> , National Institute of Health, Bogota, D.C.	1.12A, 1.12B
	<i>Parasitology Group</i> , National Institute of Health, Bogota, D.C.	1.5C, 1.7A, 1.7B, 1.7C, 5.1
	<i>Carlos Arturo Hernández</i> , National Institute of Health, Bogotá, D.C.	1.8, 4.19
	<i>Astrid Johanna Sabogal-Rico</i> , Gaia Environmental Consultants, S.A.S. Bogotá, D.C.	1.24A



COUNTRY	COLLABORATORS	PHOTOGRAPHS AND ILLUSTRATIONS
COLOMBIA	<i>Clinical Research Unit</i> , International Medical Training and Research Center (CIDEIM), Cali	2.2A, 2.2B, 2.2C, 2.2D, 2.2E, 2.2F, 2.2G
	<i>José B. Yung</i> , Clinical Research Laboratory, Department of Biological Sciences, University of the Andes, Bogotá, D.C.	1.7E, 1.7F, 1.7G
GUATEMALA	<i>Erick Antonio Durán-Bayer</i> , Leishmaniasis Subprogram, Ministry of Public Health and Social Welfare, Guatemala	3.3, 3.9, 3.10, 3.21, 3.30, 3.22, 3.39, 3.91, 3.134
MEXICO	<i>Elizabeth Castro-Adame</i> , Health Jurisdiction #1 Chetumal, State Ministry of Health, Quintana Roo	3.2, 3.23, 3.51, 3.102, 3.117, 3.133, 3.136, 3.140, 3.147
	<i>Josefina Grisel Gómez-Pérez</i> , Veracruz	3.14A, 3.14B, 3.139
	<i>Marco Ramano Quintanilla-Cedillo</i> , General Hospital, National Autonomous University of Mexico, Mexico City	3.8, 3.61, 3.85, 3.87, 3.111, 3.141, 3.149, 3.157, 3.196A, 3.196B, 3.197A, 3.197B
	<i>Emmanuel Alejandro Rivera-Pérez</i> , Veracruz	3.14A, 3.14B, 3.139

COUNTRY	COLLABORATORS	PHOTOGRAPHS AND ILLUSTRATIONS
MEXICO	<i>Laura Del Carmen Sánchez-García</i> , National Autonomous University of Mexico, Mexico City, Mexico	3.8, 3.61, 3.85, 3.87, 3.111, 3.141, 3.149, 3.157, 3.196A, 3.196B, 3.197A, 3.197B
	<i>Russel Alain Solís-Marrufo</i> , National Autonomous University of Mexico, Mexico City, Mexico	3.8, 3.61, 3.85, 3.87, 3.111, 3.141, 3.149, 3.157, 3.196A, 3.196B, 3.197A, 3.197B
	<i>Jimmy Raymundo Torres-Castro</i> , head of the Leishmaniasis Program, State Ministry of Health, Yucatán	3.1, 3.4, 3.11, 3.12, 3.13, 3.16, 3.36, 3.88, 3.93, 3.94, 3.114, 3.124, 3.143A, 3.143B, 3.144, 3.155, 4.37
PARAGUAY	<i>Olga María Aldama-Olmedo</i> , Center for Dermatological Specialties, Asunción	3.34, 3.54, 3.65, 3.66, 3.86, 3.167, 3.172
	<i>Héctor Luis Benítez-Noguera</i> , National Program for the Control of Leishmaniasis (SENEPA), Ministry of Public Health and Social Welfare, Asunción	3.132
	<i>José Guillermo Pereira-Brunelli</i> , Center for Dermatological Specialties, Asunción	3.31, 3.34, 3.37, 3.55, 3.56, 3.68, 3.98, 3.168, 4.23, 4.24, 4.49, 4.92A, 4.92B, 4.92E, 4.93C

COUNTRY	COLLABORATORS	PHOTOGRAPHS AND ILLUSTRATIONS
	<i>María Soledad Silva-Guerín,</i> National Program for the Control of Leishmaniasis (SENEPA), Ministry of Public Health and Social Welfare, Asunción	3.19
PARAGUAY	<i>Lourdes Zárate de Caballero,</i> National Program for the Control of Leishmaniasis (SENEPA), Ministry of Public Health and Social Welfare, Asunción	4.23
	<i>Alejandro Llanos-Cuentas,</i> Alexander von Humboldt Institute of Tropical Medicine, Cayetano Heredia Peruvian University	4.1, 4.7C, 4.7D, 4.9, 4.10, 4.12A, 4.12B, 4.13, 4.16A, 4.16B, 4.16C, 4.16D, 4.16E, 4.17A, 4.17B, 4.17C, 4.17D, 4.17E, 4.17F, 4.18A, 4.18B, 4.18C, 4.18D, 4.20B, 4.25, 4.27A, 4.27B, 4.59E, 4.59F, 4.62, 4.63, 4.72A, 4.72B, 4.72C, 4.72D, 4.73A, 4.73B, 4.73C, 4.73D, 4.75C, 4.75D, 4.76, 4.78A, 4.81A, 4.85B, 4.92F, 4.92G, 4.92H, 4.92I, 4.95E, 4.98
PERU	<i>Aidé Clorinda Sandoval-Juárez,</i> Leishmaniasis Laboratory, National Public Health Center, National Institute of Health, Ministry of Health, Lima	3.44, 3.49, 3.67, 3.69, 3.90, 3.105, 3.106, 3.128, 3.161, 4.2B, 4.2C, 4.31, 4.51, 4.56C

COUNTRY	COLLABORATORS	PHOTOGRAPHS AND ILLUSTRATIONS
PERU	<p><i>Ana Pilar Ramos</i>, Alexander von Humboldt Institute of Tropical Medicine, Cayetano Heredia Peruvian University, Lima</p>	<p>4.1, 4.7C, 4.7D, 4.9, 4.10, 4.12A, 4.12B, 4.13, 4.16A, 4.16B, 4.16C, 4.16D, 4.16E, 4.17A, 4.17B, 4.17C, 4.17D, 4.17E, 4.17F, 4.18A, 4.18B, 4.18C, 4.18D, 4.20B, 4.25, 4.27A, 4.27B, 4.59E, 4.59F 4.62, 4.63, 4.72A, 4.72B, 4.72C, 4.72D, 4.73A, 4.73B, 4.73C, 4.73D, 4.75C, 4.75D, 4.76A, 4.78A, 4.81A, 4.85B, 4.92F, 4.92G, 4.92H, 4.92I, 4.95E, 4.98</p>
	<p><i>Alfredo Rodríguez-Cuadrado</i>, Bureau for the Prevention and Control of Vector-borne Diseases and Zoonoses, Ministry of Health, Lima</p>	<p>3.43, 3.53, 3.70, 3.75, 3.82, 3.83, 3.99, 3.104, 3.113, 3.129, 4.57B, 4.92J, 4.92K</p>
	<p><i>Braulio Valencia</i>, Alexander von Humboldt Institute of Tropical Medicine, Cayetano Heredia Peruvian University, Lima</p>	<p>4.1, 4.7C, 4.7D, 4.9, 4.10, 4.12A, 4.12B, 4.13, 4.16A, 4.16B, 4.16C, 4.16D, 4.16E, 4.17A, 4.17B, 4.17C, 4.17D, 4.17E, 4.17F, 4.18A, 4.18B, 4.18C, 4.18D, 4.20B, 4.25, 4.27A, 4.27B, 4.59E, 4.59F 4.62, 4.63, 4.72A, 4.72B, 4.72C, 4.72D, 4.73A, 4.73B, 4.73C, 4.73D, 4.75C, 4.75D, 4.76A, 4.78A, 4.79F, 4.79G, 4.81A, 4.85B, 4.92F, 4.92G, 4.92H, 4.92I, 4.95E, 4.98</p>

COUNTRY	COLLABORATORS	PHOTOGRAPHS AND ILLUSTRATIONS
SWITZERLAND	<i>World Health Organization,</i> Geneva	1.27, 1.28
VENEZUELA (BOLIVARIAN REPUBLIC OF)	<i>José Ramón Guevara,</i> Sección Leishmaniasis Section, “Dr. Jacinto Convit” Institute of Biomedicine, Caracas	3.7, 3.80, 3.202A, 3.202B, 3.203A, 3.203B, 3.203C, 4.34A

## ACKNOWLEDGEMENTS

This first edition of the *Interactive Atlas of Leishmaniasis in the Americas: Clinical aspects and differential diagnosis* has been prepared by the Pan American Health Organization with support from the Federico Lleras Acosta University Hospital Dermatology Center of Colombia.

First, we would like to express our most sincere gratitude to all the researchers and collaborators that collaborated on each chapter of the atlas, as well as those responsible for the national leishmaniasis programs or epidemiological surveillance services of Brazil, Bolivia (Plurinational State of), Colombia, Costa Rica, El Salvador, Guatemala, Mexico, Paraguay, Peru, and Venezuela (Bolivarian Republic of), who spared no effort to complete this volume.

Furthermore, on behalf of Dr. Claudia Marcela Rojas Daza, we would like to thank the directors of the Federico Lleras Acosta University Hospital Dermatology Center of Colombia for permission to use parts of the text and figures from Chapter 10 of the publication: Rodríguez G, Arenas C, Ovalle C, Hernández CA, Camargo C. *Las leishmaniasis: atlas y texto*. Bogotá: Hospital Universitario Centro Dermatológico Federico Lleras Acosta; 2016. pp. 117-61.

Similarly, we are grateful to the Representative Office of the Pan American Health Organization in Colombia and, especially, to Dr. Jonathan Novoa, for his support in the initial preparation of the proposal for this project and in its implementation.

We are equally grateful to the Editorial Committee of the journal *Biomédica* of the National Institute of Health of Colombia for permission to use illustrations published in the “Medical Entomology” supplement and on two of its covers.

We would also like to express our gratitude to Lia Puppim Buzanovsky of the Epidemiology Department of the Pan American Center for Foot-and-Mouth Disease and Veterinary Public Health of the Pan American Health Organization Duque de Caxias, Rio de Janeiro (Brasil), for preparation of the maps of the Americas in Chapter 1. We are likewise grateful to Dr. David Paz, Director of Jorochito Hospital (Santa Cruz, Bolivia) who generously made it possible for us to photograph patients with leishmaniasis.

Finally, we want to thank Elisa Acevedo Hernández, editor of Pan American Health Organization publications, for her great care and meticulous review of the final texts of the entire document.

The following researchers collaborated by submitting photographs for the final selection of those in the atlas:

***Oswaldo Cruz***

National General Hospital of La Unión, La Unión (El Salvador)

***Maria Cristina De Oliveira Duque***

Evandro Chagas Nacional Institute of Infectious Diseases, Oswaldo Cruz Foundation, Rio de Janeiro, Rio de Janeiro; Municipal Secretariat of Health of Timóteo, Timóteo (Minas Gerais, Brazil)

***Carlos Mata-Somarribas***

Costa Rican Institute of Research and Teaching in Nutrition and Health (INCIENSA), San José (Costa Rica)

***Maria Inês Fernandes Pimentel***

Leishmaniasis Clinical Research Laboratory, Evandro Chagas National Institute of Infectious Diseases, Oswaldo Cruz Foundation, Rio de Janeiro (Rio de Janeiro, Brazil)

***Juana María Rodríguez-Benítez***

Health Jurisdiction #3 Tuxpan, State Ministry of Health, Nayarit (Mexico)

***Cláudia Maria Valete Rosalino***

Evandro Chagas National Institute of Infectious Diseases, Oswaldo Cruz Foundation (Rio de Janeiro, Brazil)

***David Tello-Salgado***

Department of Vectors, State Ministry of Health, Morelos (Mexico)



# CHAPTER 1

## Overview



# Definition



Óscar Daniel Salomón

*Leishmaniases* refers to the group of anthroponosis produced by infection from parasites of the genus *Leishmania* in vertebrate hosts, present mainly in the world's intertropical belt.

This definition involves a broad pathophysiological spectrum of clinical signs (visceral, cutaneous, and mucosal, primary and secondary, laboratory, and immunological), obligate intracellular parasite species in mammals, insect vectors, reservoirs, occasional hosts, and epidemiological scenarios.

Other definitions also include the requirement of transmission of the etiologic agent by female phlebotomine sand flies (subfamily Phlebotominae), but this concept has been questioned because of the cycle in diptera Ceratopogonidae and red kangaroos (*Macropus rufus*) (*Figure 1.1*) in Australia, and the continuity in time of some *Leishmania* species transmitted vertically or horizontally to mammals.

Furthermore, infection without apparent clinical manifestations, a phenomenon reported in most known *Leishmania* species, is excluded from the most stringent definition, which does not diminish its epidemiological importance in transmission mechanisms.



Figure 1.1.  
*Macropus rufus*, red kangaroo

# A Brief History of Leishmaniases in the Americas



Jeffrey Jon Shaw

The history of cutaneous leishmaniasis in the Americas goes back millions of years in wild animals, long before the presence of humans. However, this was not the case with visceral leishmaniasis, which seems to have been imported from the Iberian Peninsula in the 16<sup>th</sup> century by the Spanish and Portuguese. The exact date of the arrival of humans in the Americas is unknown, but it is believed to have been at least 15,000 years ago. The habits of these first immigrants undoubtedly put them in contact with phlebotomine sand flies (subfamily Phlebotominae) while they gathered food and hunted. However, the leishmaniasis are zoonotic diseases, which means that, even though humans have probably suffered from the disease for many thousands of years in Latin America, we have never been a host in which the parasite evolves; this occurs in the vector and in wild mammals.

The first records of the disease come from pieces of Peruvian, Ecuadorian, and Colombian pottery dating back to 400 to 900 CE (*Figures 1.2*). These ceramic figures show extreme disfigurement of the nasal region, similar to that produced by mucosal lesions currently observed in patients.

REPUBLICA DE COLOMBIA  
UNIVERSIDAD NACIONAL - FACULTAD DE MEDICINA Y CIENCIAS NATURALES

# CONTRIBUCION AL ESTUDIO DE LA LEISHMANIOSIS TEGU- MENTARIA EN COLOMBIA (Bubón de Vélez - Marranas - Espundia)

ESTUDIO PARA EL DOCTORADO PRESENTADO

*por*

JOSE DEL CARMEN RODRIGUEZ BERMUDEZ

Monitor, por concurso, del Laboratorio de Histología. 1922.—Preparador del Laboratorio de Histología, por concurso. 1923 y 1924.—Jefe del Laboratorio de Histología y embriología, por concurso. 1925, 26, 27 y 28.—Jefe del Laboratorio de Anatomía Patológica del Hospital de San José, 1927. Interno de la Clínica Dermatológica, por concurso. 1924.—Médico ayudante del "Centro de protección infantil".—Interno ayudante de la Clínica Quirúrgica, servicio del doctor Pompilio Martínez. 1928. Interno del Pabellón La Pola, servicio de Cirugía del Hospital San José. Profesores Corpas y Buendía. Interno del Pabellón Sáenz Pinzón del Hospital San José. Servicio de los doctores Hipólito Machado y Roberto Franco. 1927.—Interno del Pabellón Juan de los Barrios.—Médico del Ferrocarril del Carate. 1927.—Médico ayudante del Ferrocarril del Norte. 1928.—Médico ayudante del Ferrocarril del Sur. 1929.—Delegado por la Facultad de Medicina a la Federación Nacional de Estudiantes. 1923 y 24. Miembro del Tribunal de Honor de la Federación. Delegado extraordinario de la Federación de estudiantes al Centenario de la Universidad de Boyacá. 1924.—Profesor de Histología en el Colegio Dental. 1927.—Miembro de Número de la Sociedad de Ciencias Naturales.—Primer premio en el concurso de Anatomía patológica, abierto por la Academia Nacional de Medicina en 1927.

MCMXXIX

EDITORIAL MINERVA

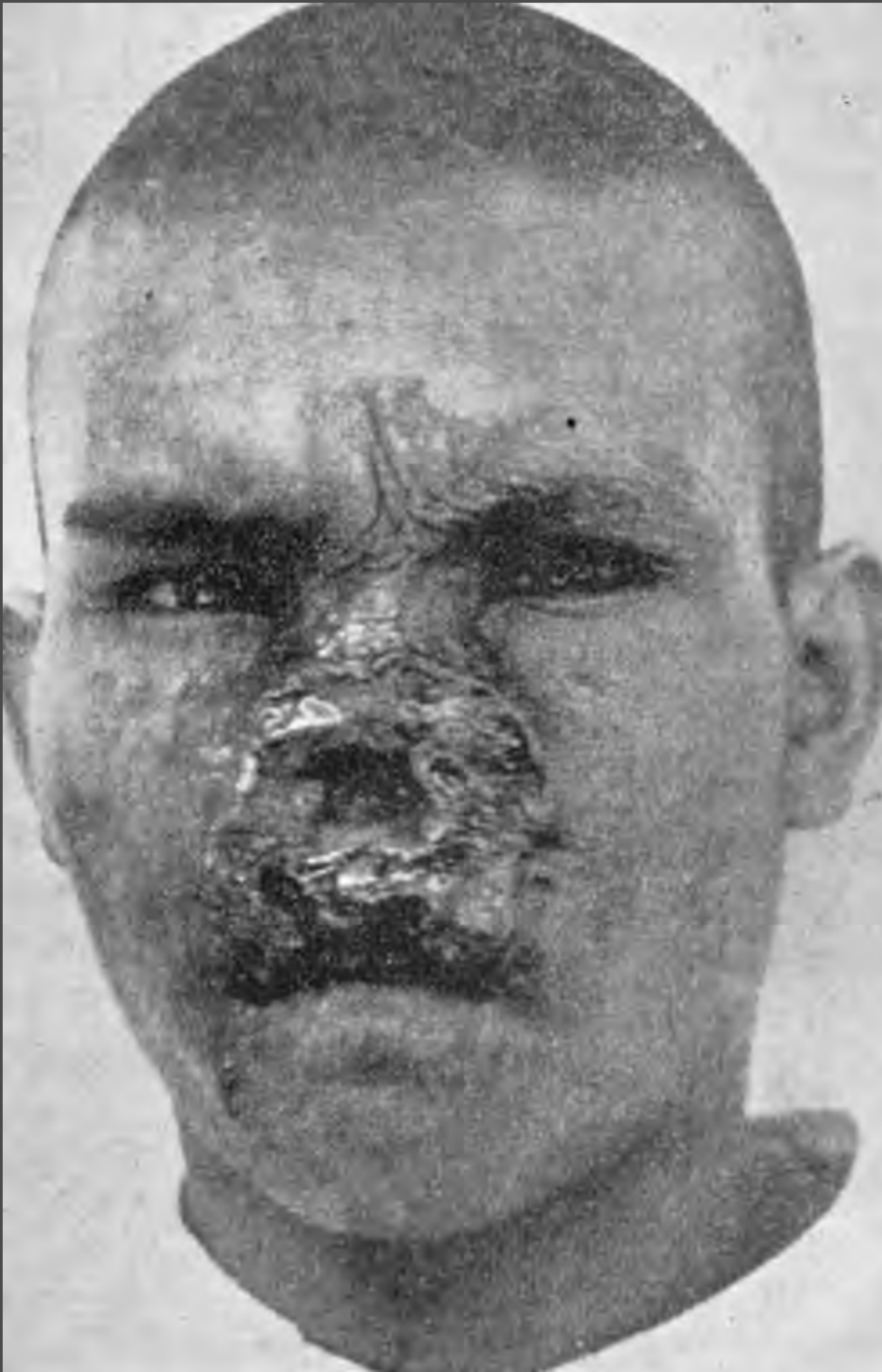BOGOTA

Figure 1.2A.  
*Contribution to the study of tegumentary leishmaniosis in Colombia*, a book by José del Carmen Rodríguez Bermúdez, published in Bogotá in 1929 by Minerva Publishers



**Figure 1.2B.**  
A ceramic piece showing destruction  
of the nose and damage to the lips.





**Figure 1.2C.**  
Patient with lesions similar to those  
represented on the ceramics of the  
previous Figure.

The first references to the disease come from the writings of Jesuit priests and Spanish adventurers from the late 16th century, who described nasal and cutaneous lesions in people associated with coca plantations on the low-lying slopes of the eastern Andes. Given what we know today, they were most likely related to *Leishmania (Viannia) braziliensis*. Lesions were also observed on the skin of potato growers in the colder highlands where, instead of stigmatizing them, they were the mark of a good farmer. It is likely that these highland cases were associated with *L. (V.) peruviana*. *Uta* was the name given by indigenous Peruvians to the disease that occurs in the highlands.

Various cutaneous and visceral clinical manifestations in the Old World had different local names, but, in the late 19<sup>th</sup> and early 20<sup>th</sup> centuries, it was discovered that a small rounded intracellular parasite was responsible for all of them. This parasite was given the generic name *Leishmania* in 1903 and, as more diseases became associated with it, these were known generically as *leishmaniasis*.

During the same period in the Americas—the early 20<sup>th</sup> century—immigrant loggers were being severely affected by cutaneous ulcers. In the Old World, skin diseases were known by the places where they occurred, such as the Aleppo button or boil in Syria. In some cases, in the Western Hemisphere, the same standard was followed; for example, in São Paulo, Brazil, it was known as Bauru's ulcer and, in French Guiana, as *pian-bois* or forest yaws, from the indigenous term *pian*, meaning 'ulcer' and the French *bois* or "forest," referring to the location where it was

contracted. In other places, its name indicates the product being gathered, such as chiclero's ulcer in the Yucatán peninsula, contracted by forest workers who harvested chicle from native trees. With time, the cutaneous disease was progressively diagnosed in all the countries of Central and South America, except Chile.

In 1909, Lindenberg, on the one hand, and Carini and Paranhos, on the other, independently, were the first ones to associate the cutaneous diseases acquired in New World forests with the *Leishmania* parasite observed in Europe. But it was not until 1911 that Splendore demonstrated the parasite in the nasal lesion of an Italian immigrant who had returned to Italy from Brazil.

In these descriptions, the authors refrained from naming the parasites. However, in 1911, Gaspar de Oliveira Vianna (*Figures 1.3*) used the name *Leishmania brazilienses*—then corrected to *braziliensis* by Matta in 1916—for the parasite found in the lesions of a patient with disseminated cutaneous leishmaniasis from Além Paraíba (Minas Gerais, Brazil). Gaspar de Oliveira Vianna also introduced trivalent antimony to treat the disease in 1913, a primary chemotherapy that is still used today in many countries (*Figure 1.4*). Subsequently, other authors started naming the parasites responsible for different forms of the disease: *L. peruviana* for *uta* (Vélez, 1913), *L. tropica guyanensis* for *pian-bois* (Floch, 1954), *L. tropica mexicana* for chiclero's ulcer (Biagi, 1953), and *L. braziliensis pifanoi* for diffuse cutaneous leishmaniasis (Medina and Romero, 1959).



Figure 1.3A.  
Gaspar de Oliveira Vianna at age 18 years

EM MANGUINHOS



*Dr Gaspar de Oliveira Vianna*

Figure 1.3B.  
Gaspar de Oliveira Vianna in his laboratory in  
Manguinhos, Fiocruz (Rio de Janeiro, Brazil)

N. 15622

Photographia tirada em 11 de Dezembro de 1913

A presente carteira de identidade pertence a  
 D. Gaspar de Oliveira Vianna  
 filho de D. Manoel Gomes Vianna  
 e de D. Leonora de Oliveira Vianna  
 nacionalidade Natural do Brasil nascido em 11 de Maio de  
 1885 estado civil solteiro profissão Médico  
 instrução Superior estatuto 1.º Estatuto.

NOTAS CHROMATICAS

cor da pele amarelada olhos castanhos cabelos pretos  
 dentes brancos nariz e orelhas normais

Marcas e sinais particulares visíveis na vida ordinaria

legatura de camisa permanente de 1913  
 no 1112 - 1113 - 1114 - 1115 - 1116 - 1117 - 1118 - 1119

Fls de Janeiro 11 de Dezembro de 1913

Pelo Director do Gabinete de Identificação e de Estatística

Assinatura do portador D. Gaspar de Oliveira Vianna



COLLETAZ DIREITA



I. D. Série E. 1339  
 Seção 3.3122

Observação: A presente carteira valerá como prova de identidade e folha  
 comida, e terá fé publica (Decreto n. 6440, de 30 de março de 1907)

(TIPO) RETRATO

Figure 1.3C.  
Gaspar de Oliveira Vianna's identity card, issued  
on 11 December 1913

## TRATAMENTO DA LEISHMANIOSE TEGUMENTAR POR INJEÇÕES INTRAVENOSAS DE TARTARO EMETICO

DR. GASPAR VIANNA: - Já é necessário de observar varios casos de leishmaniose cutanea, sendo em um doente apresentava tambem lesões na mucosa nasal e bucal.

Nas lesões antigas, por-vezes é muito difficil o diagnostico microscopico, devido á pequena quantidade dos parasitas.

O diagnostico clinico feito com base scientifica, como o fez o illustre professor Terra, julgamos-o do maximo valor, principalmente para o tratamento.

N'este doente foi o diagnostico confirmado pela verificação parasitologica, mas sem esta, como acaba de mostrar o professor Terra, era impossivel classificar as lesões observadas em outra moléstia.

Ultimamente observei em um doente desta moléstia o apparecimento de uma lesão na mucosa bucal, sendo então nos esfregaços muito elevado o numero dos parasitas.

Algum tempo após a abertura da lesão, apesar de pesquisas repetidas, não conseguimos mais verificar leishmanias.

Com o aggravamento d'esta lesão, novos pontos da mucosa foram lesados, observando ali os parasitas.

Perante este facto, parece justo acreditar que, á proporção que o processo caminha, ha diminuição muito pronunciada de parasitas na parte que fica ulcerada, sendo mais raras d'elles as zonas recém-atacadas.

Os côrtes do caso que o meu illustre collega Dr. Rabelin apresentou nitidamente elucidam o facto.

A parte ainda não ulcerada, a portadora do epithelio pouco alterado, apresenta abaixo d'elle um numero prodigioso de leishmanias.

Os esfregaços da mesma lesão revelam pobreza notavel do parasita em questão.

Preoccupou-me tambem o tratamento d'esta moléstia.

(\*) Comunicação ao VII Congresso Brasileiro de Medicina e Cirurgia — Seção da Sociedade Brasileira de Dermatologia, reunida em Belo-Horizonte de 24 a 26 de Abril de 1912 (An. do 7.º Congr. Bras. Med. Cirurg. 4 (31) 426-428).

Figure 1.4.

Abstract of the presentation by Gaspar Vianna at the *VII Brazilian Congress of Medicine and Surgery* on the use of the intravenous injections of emetic tartar for treatment of cutaneous leishmaniasis, published in the *Archives of Brazilian Medicine* of 1912

In 1963, it was observed in Panama that *Leishmania* developed in the hindgut of Phlebotominae and, in 1970, it was found that strains from Guatemala did not travel to the hindgut to develop. The taxonomic importance of this difference led to the creation of the subgenus *L. (Viannia)* in 1987 and to understanding that there were two different phylogenetic groups: *L. (Viannia)*, limited to the Americas, and *L. (Leishmania)* in the Old and New World. There are other basic differences among the parasites belonging to the two subgenera, which include different reactions to drugs and specific histopathological findings. The taxonomy of *Leishmania* spp. continues to evolve and other genera and subgenera have been created to make room for new and historically enigmatic parasites. It became evident that more than one species of *Leishmania* was causing American cutaneous leishmaniasis and 17 different parasite species have been associated with different terrestrial and arboreal mammals, although not all are found in humans.

In 1913, Migone described in Paraguay what is possibly the first case of American visceral leishmaniasis. Nevertheless, it was later, in 1934, that Penna found definitive evidence of the existence of the disease when he saw amastigotes in liver biopsies of Brazilian patients who had been suspected of dying of yellow fever. In total, 47 cases were diagnosed in individuals who had lived in northern and northeastern Brazil. In 1936, Evandro Chagas reported the first case in a live individual: a child residing in Abaetetuba (Pará, Brazil). Chagas' team considered that the disease was being transmitted near and around living quarters by an insect they identified as *Phlebotomus longipalpis*. Later, American visceral leishmaniasis was reported in other countries. The importance of



the dog as a reservoir gradually became apparent in Brazil, Argentina, and Venezuela, after Chagas' team discovered infections in dogs.

The disease had a rural origin, although cases began to appear in city dwellers. Leishmaniasis has become more and more urbanized and, unfortunately, is now well established in many cities throughout the Americas. It took much longer to discover the reservoirs of cutaneous leishmaniasis parasites. Infections in rodents were seen for the first time by Forattini in the 1960s. It was not until 1962 that Lainson and Strangways-Dixon positively identified *L. mexicana* infections in rodents captured in Belize. Leishmaniasis cases have been reported in a growing list of animals, and infections have been found in practically all major orders of mammals.

Following Old World traditions, the generic name for sand flies (*Phlebotomus*) was used for Western Hemisphere vectors up to 1962, when Barreto accepted the generic name *Lutzomyia* for most species in the subfamily Phlebotominae in the Americas. These small diptera are found in great abundance in forests where the disease is contracted.

In 1922, Henrique Aragão, one of the brilliant young scientists from the Federal Serotherapy Institute (the present-day Oswaldo Cruz Institute), successfully infected *Lutzomyia intermedia* by allowing them to feed on patients with American cutaneous leishmaniasis, and then inoculated a dog with the content of the insects, producing a lesion on the dog. This was the first experimental evidence that Phlebotominae were potential vectors of *Leishmania* spp.

The first natural infection of a Phlebotominae was found in *Migonemyia migonei* by Pessôa and Pestana in 1940; although the flagellates were not identified, their morphology left few doubts that they belonged to the genus *Leishmania*.

As more circumstantial evidence accumulated, it became clear that phlebotomines were vectors of different forms of American leishmaniasis. The *L. mexicana* species was the only one that Strangways-Dixon and Lainson successfully transmitted experimentally in 1962. Following this, experimental transmissions were achieved and species of *Leishmania* were progressively identified by more sophisticated methods in many species of Phlebotominae, but the epidemiological importance of many of them is still to be determined.

The history of the leishmaniass has progressed from recognizing the disease to seeking its causes and treatment, identifying its transmission patterns and where it comes from, and understanding the development of the parasite. It has been categorically demonstrated that both cutaneous and American visceral leishmaniasis are zoonotic diseases and that their enzootic cycles involve a mosaic of mammal species; nevertheless, the picture is far from complete. The complexities of the dynamics of these infections are only starting to be investigated. It is hoped that this will lead to more effective and sustainable control measures.

## Recommended Reading

- Deane LM. Leishmaniose visceral no Brasil. Rio de Janeiro (Brazil): Serviço Nacional de Educação Sanitária; 1956. pp. 1-162.
- Espinosa OA, Serrano MG, Camargo EP, Teixeira, MM, Shaw JJ. An appraisal of the taxonomy and nomenclature of trypanosomatids presently classified as *Leishmania* and *Endotrypanum*. *Parasitology*. 2016;ePub:1-13.
- Lainson R. The Neotropical *Leishmania* species: a brief historical review of their discovery, ecology and taxonomy. *Revista Pan-Amazônica de Saúde*. 2010;1(2):13-32.
- Lainson R, Shaw JJ. Evolution, classification and geographical distribution. In: Peters W, Killick-Kendrick R, editors. *The leishmaniasis in biology and medicine*. London: Academic Press; 1987. pp. 112-120.
- Le Moine G, Raymond JC. Leishmaniasis and Inca settlement in the Peruvian jungle. *J Hist Geog*. 1987;13:113-29.
- Rodríguez Bermúdez JC. *Contribución al estudio de la leishmaniosis tegumentaria en Colombia*. Bogotá: Editorial Minerva; 1929.

# Parasites

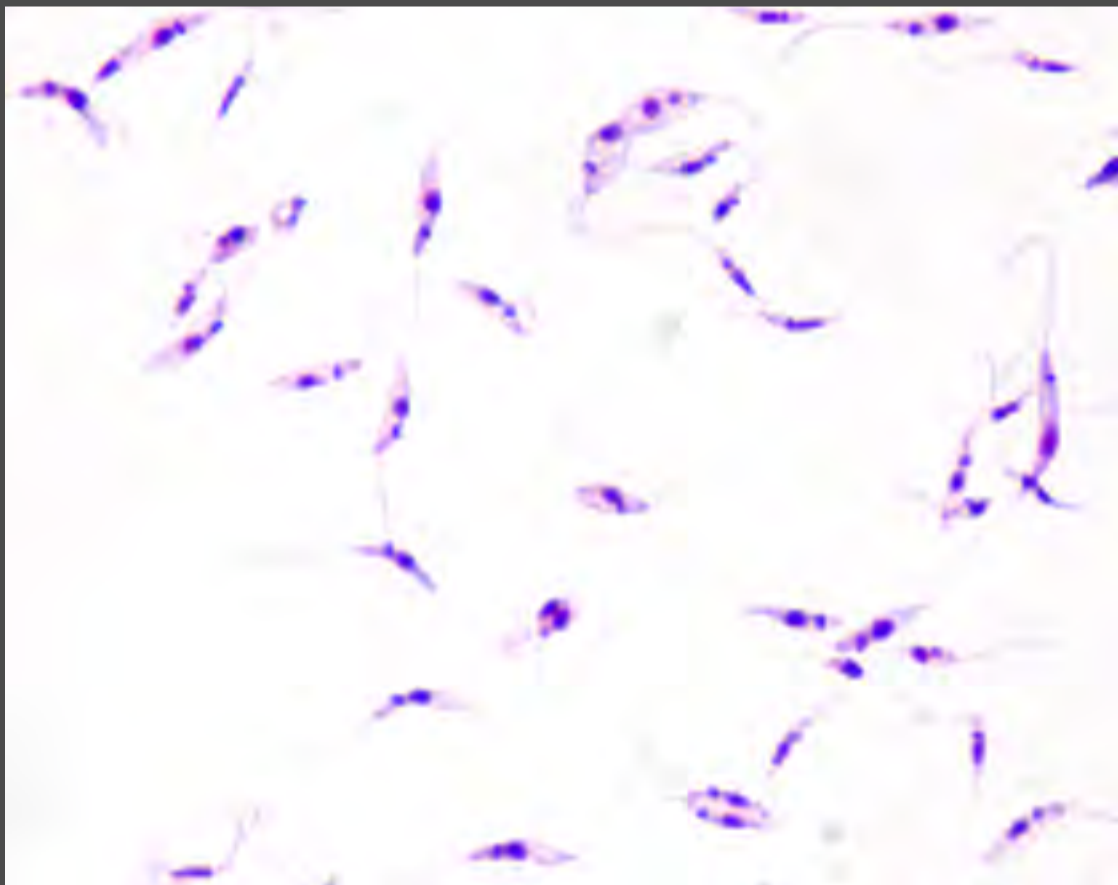
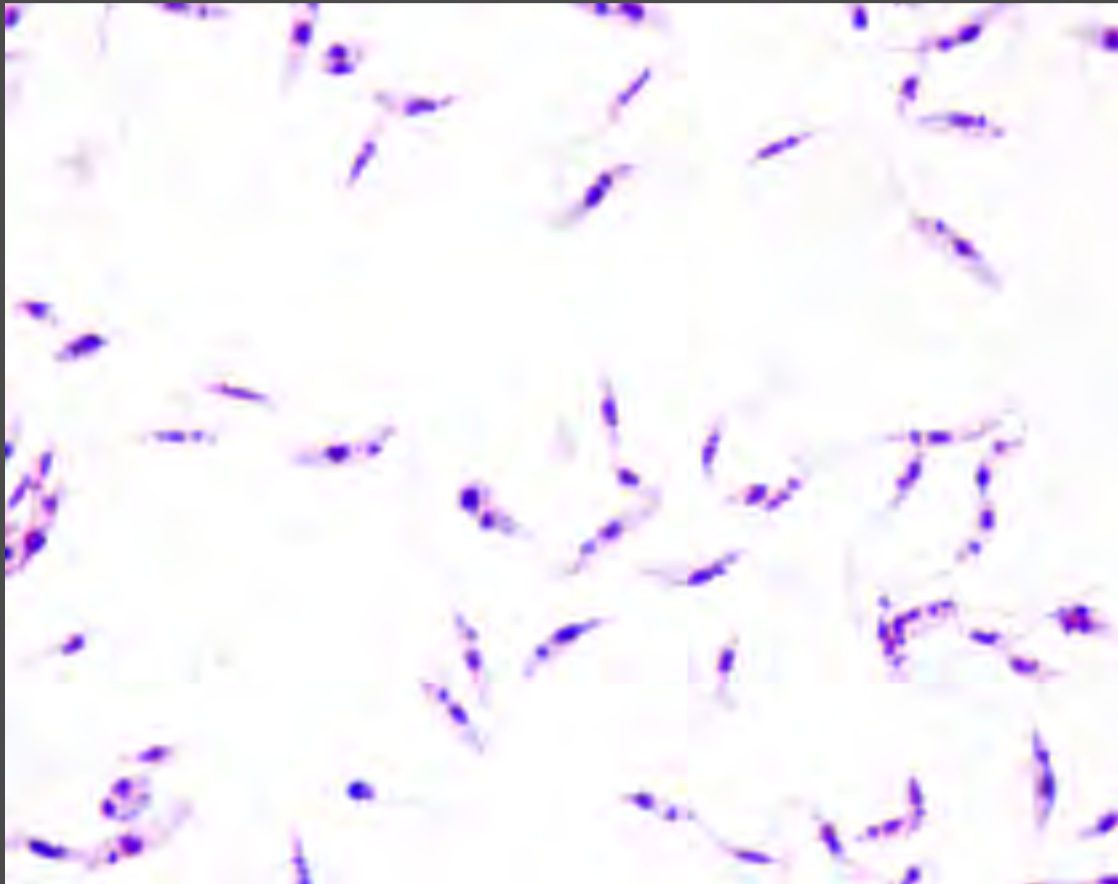


Elisa Cupolillo

The genus of protozoan organisms *Leishmania* is notable for the large number of species described. The species *Leishmania donovani* (Laveran and Mesnil, 1903) belongs to the genus *Leishmania* (Ross, 1908), class Kinetoplastea (Honigber, 1963), and family Trypanosomatidae (Doflein, 1901). From its original description, new species of *Leishmania* were characterized and several classification systems were adopted, using taxonomic categories such as subspecies, complexes and subgenera.

All members of the genus *Leishmania* are heteroxenous parasites. The invertebrate hosts of these parasites are phlebotomines and the vertebrate hosts are various reptiles and mammals. The leishmanias have a single mitochondrion, known as the kinetoplast, which contains a massive network of thousands of interconnected circles of DNA (mini-circles and maxi-circles) that are mitochondrial DNA. These parasites have two main stages in their life cycle: as promastigotes and as amastigotes. The elongated promastigote, with a mobile flagellum, lives extracellularly within the phlebotomine digestive tract (*Figures 1.5 and 1.6*). The oval amastigote, with no apparent flagellum and non-motile, lives inside vertebrate-host macrophages (*Figures 1.7*).

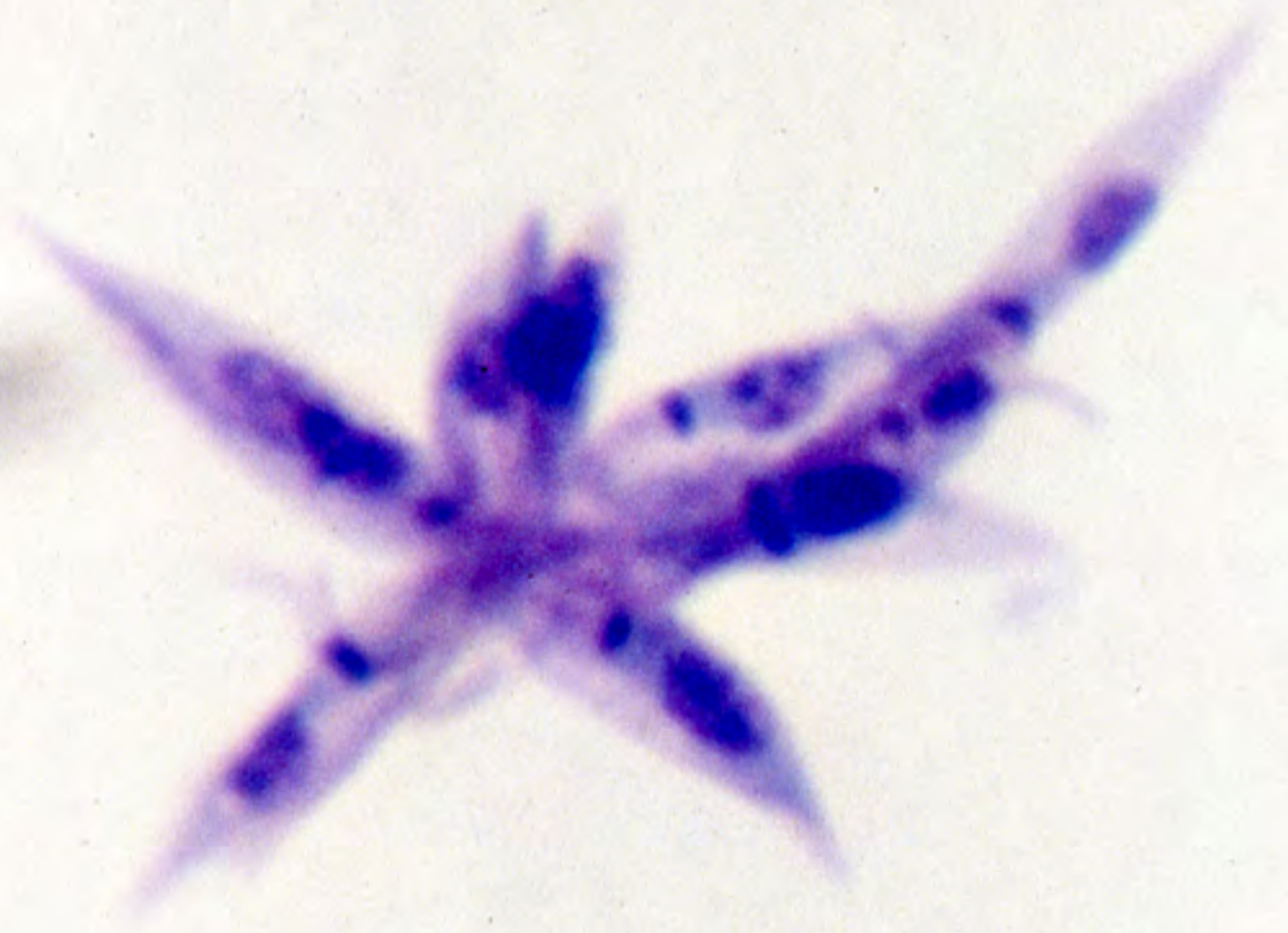
The genus is currently organized into three subgenera: *L. (Sauroleishmania)*, *L. (Leishmania)*, and *L. (Viania)*. The first subgenus includes only reptile parasites and the other two include mammal parasites.



Figures 1.5A and B.  
Promastigotes of *Leishmania* spp. with Giemsa stain

**Figure 1.5C.**

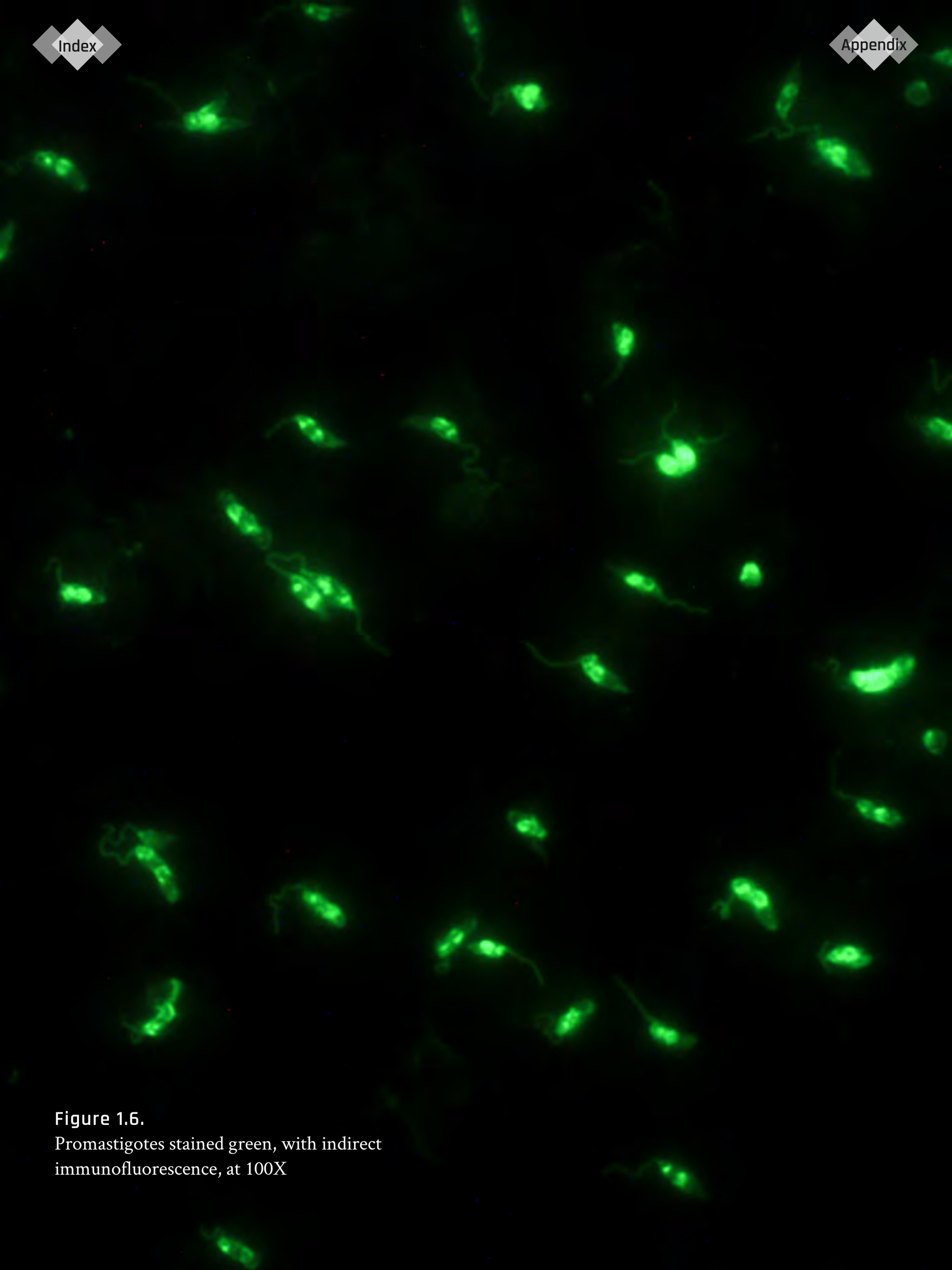
Using light microscopy and Giemsa stain, the oval shape of the promastigotes can be seen, with their mobile flagellum at the anterior pole; they are extracellular organisms mainly found in the lumen of the phlebotomine digestive system.



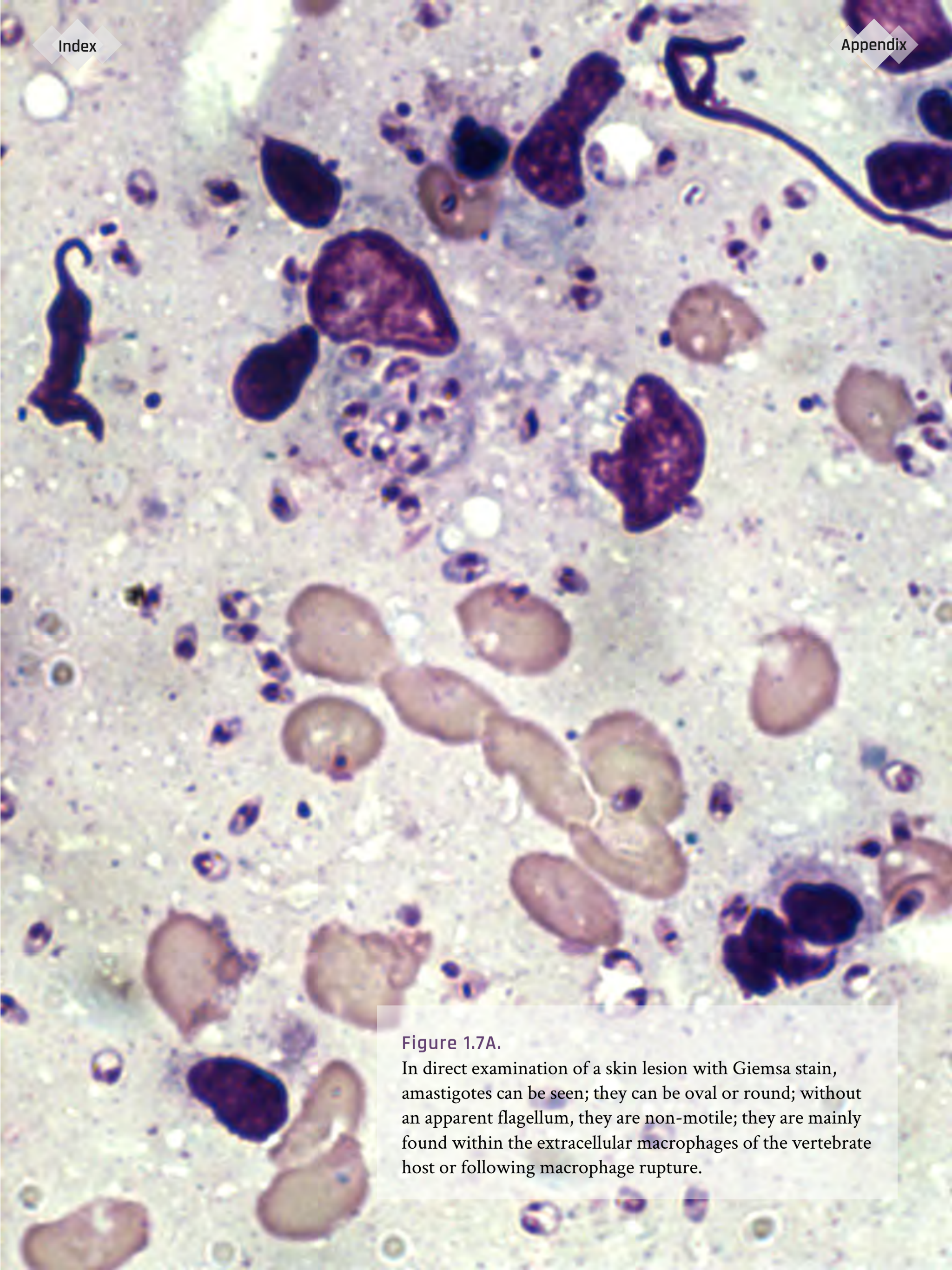
**Figure 1.5D.**  
Image of a *Leishmania*  
spp. culture in a  
scanning electronic  
microscope








**Figure 1.6.**  
Promastigotes stained green, with indirect immunofluorescence, at 100X



**Figure 1.7A.**

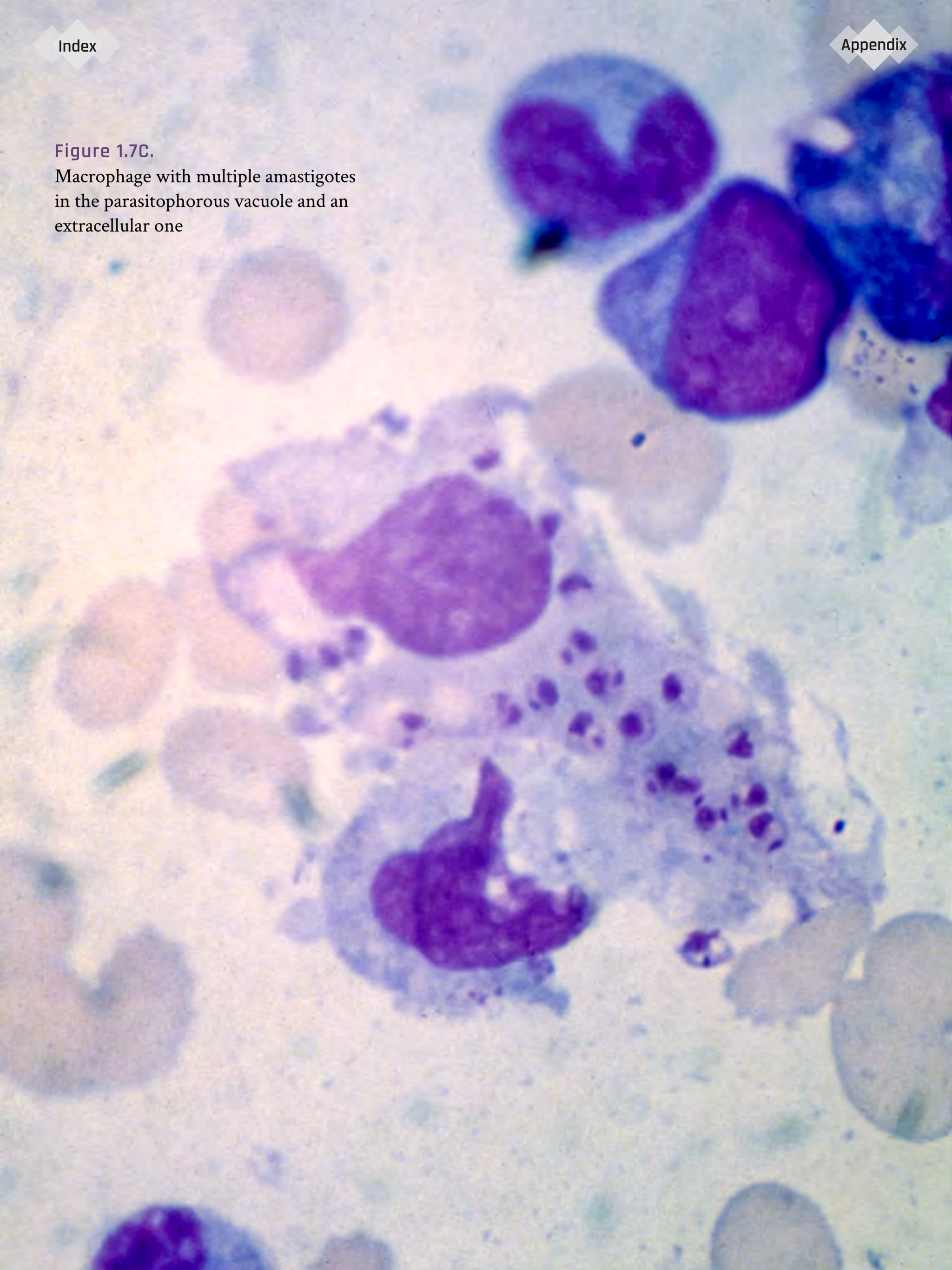
In direct examination of a skin lesion with Giemsa stain, amastigotes can be seen; they can be oval or round; without an apparent flagellum, they are non-motile; they are mainly found within the extracellular macrophages of the vertebrate host or following macrophage rupture.



**Figure 1.7B.**  
The same thing is seen here in a bone marrow aspirate smear from a patient with suspected visceral leishmaniasis.

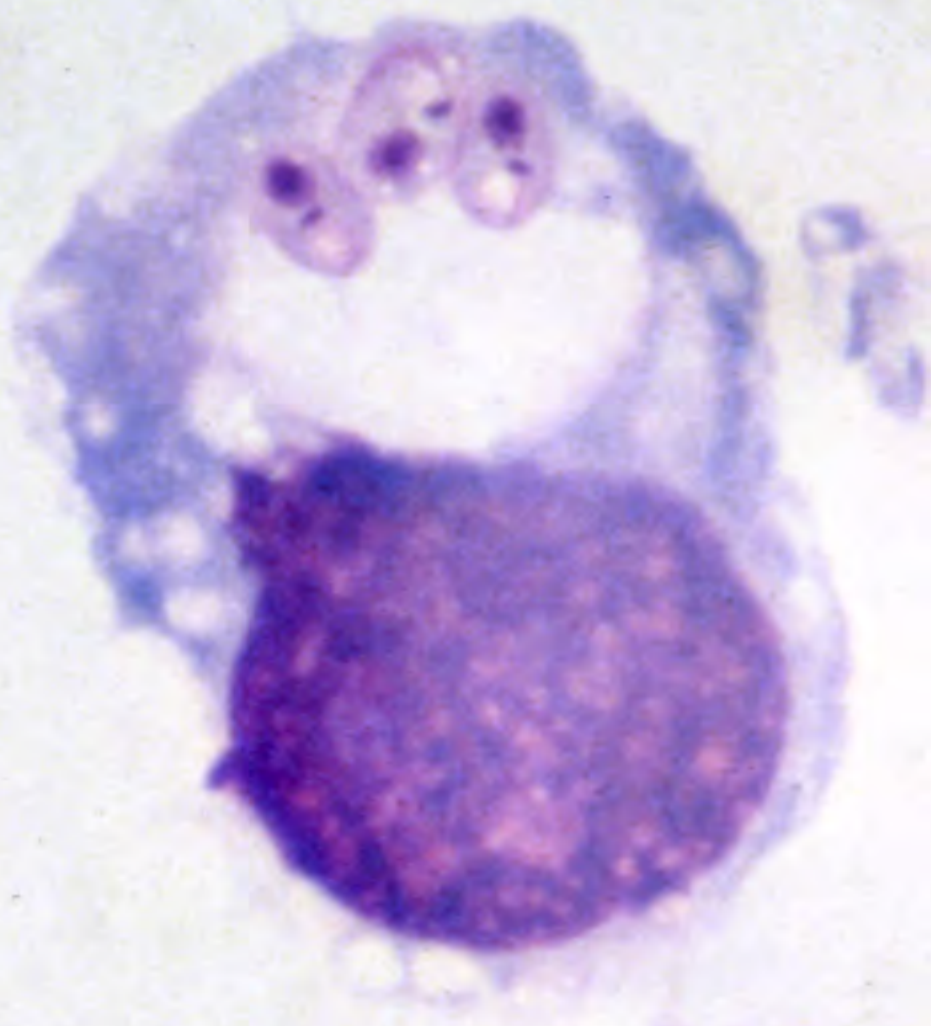
**Figure 1.7C.**

Macrophage with multiple amastigotes in the parasitophorous vacuole and an extracellular one

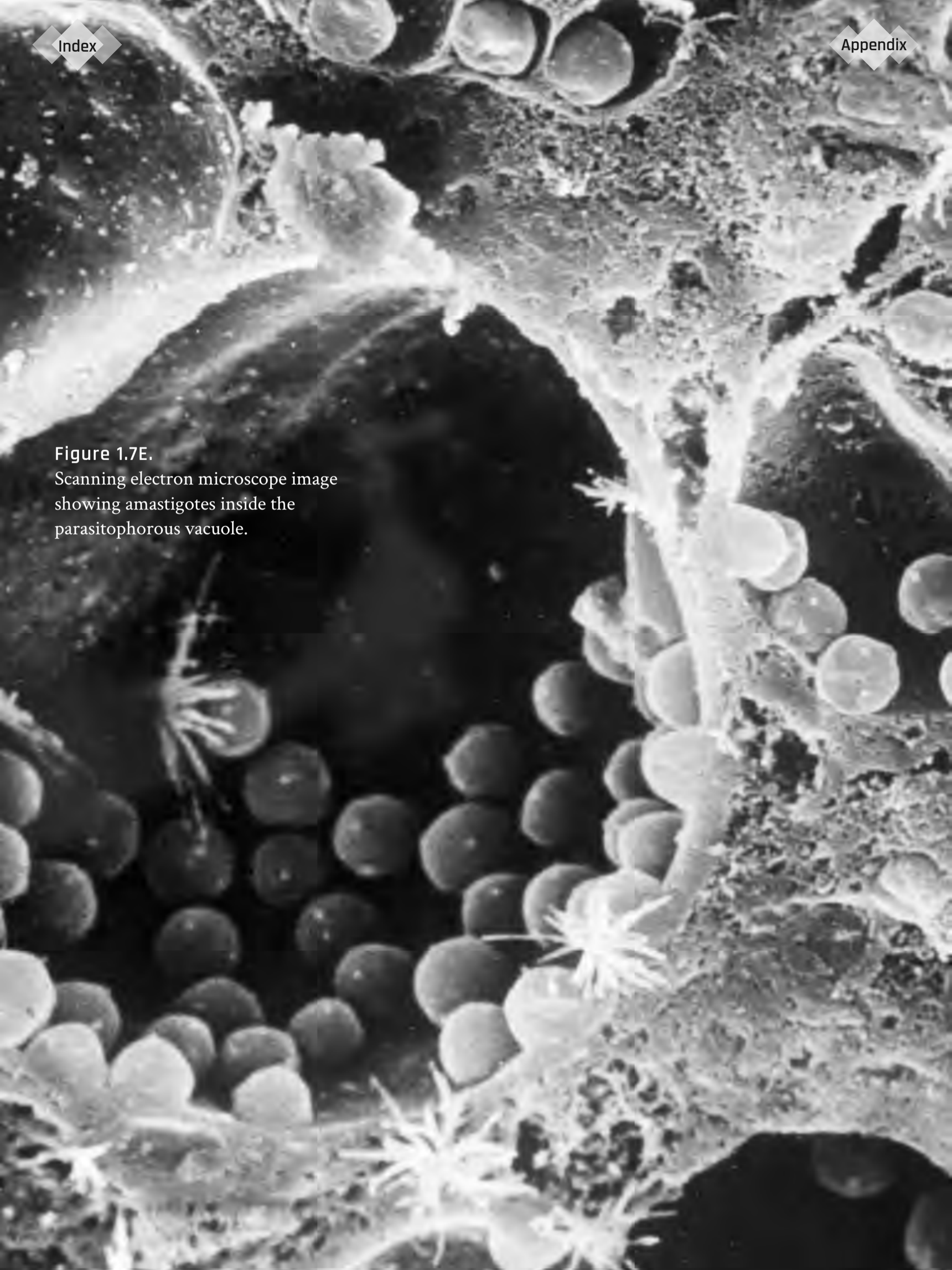

**Figure 1.7D.**

Intact macrophage with prominent nucleus and three amastigotes attached to the parasitophorous vacuole wall

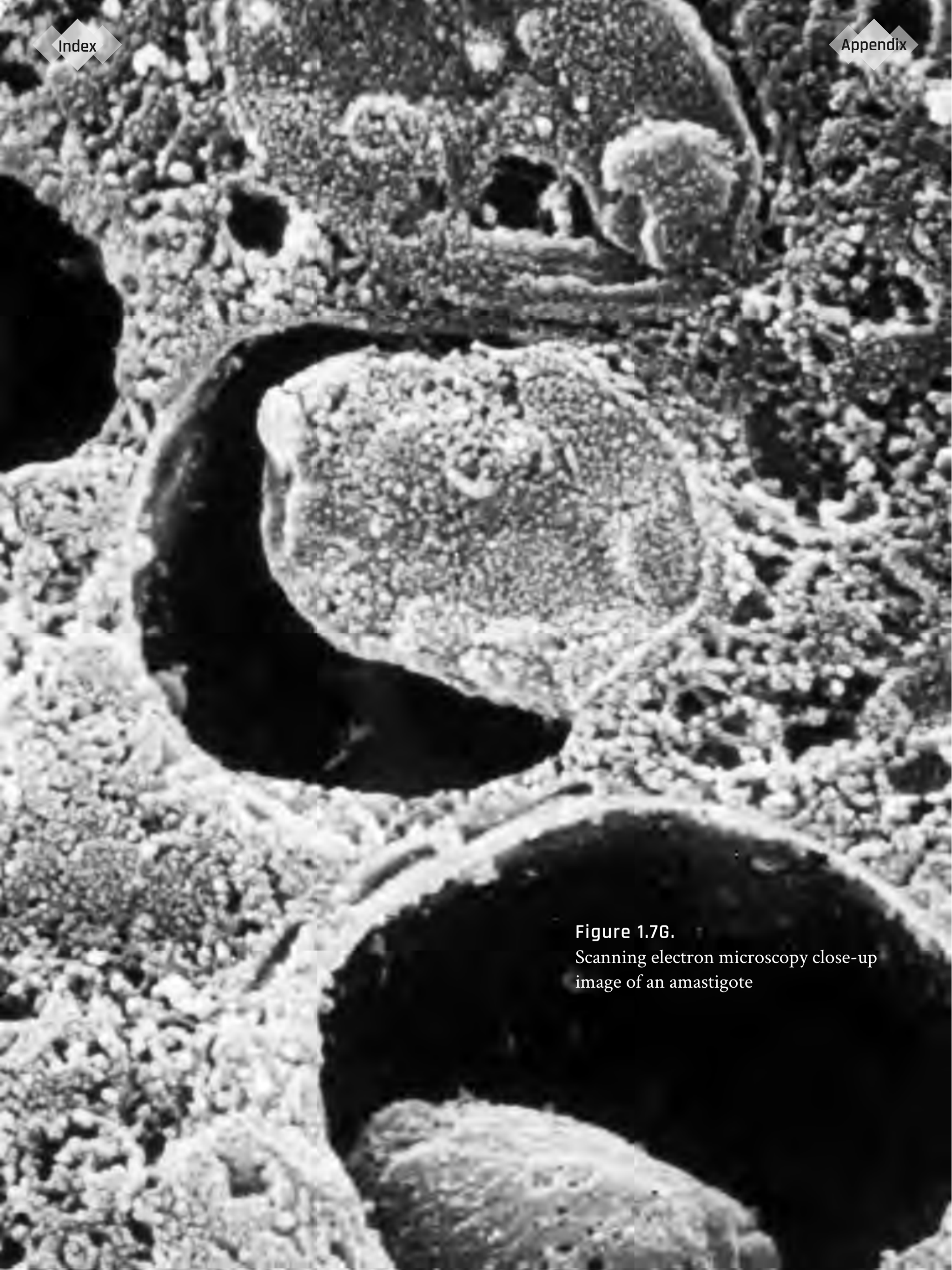


**Figure 1.7E.**  
Scanning electron microscope image  
showing amastigotes inside the  
parasitophorous vacuole.



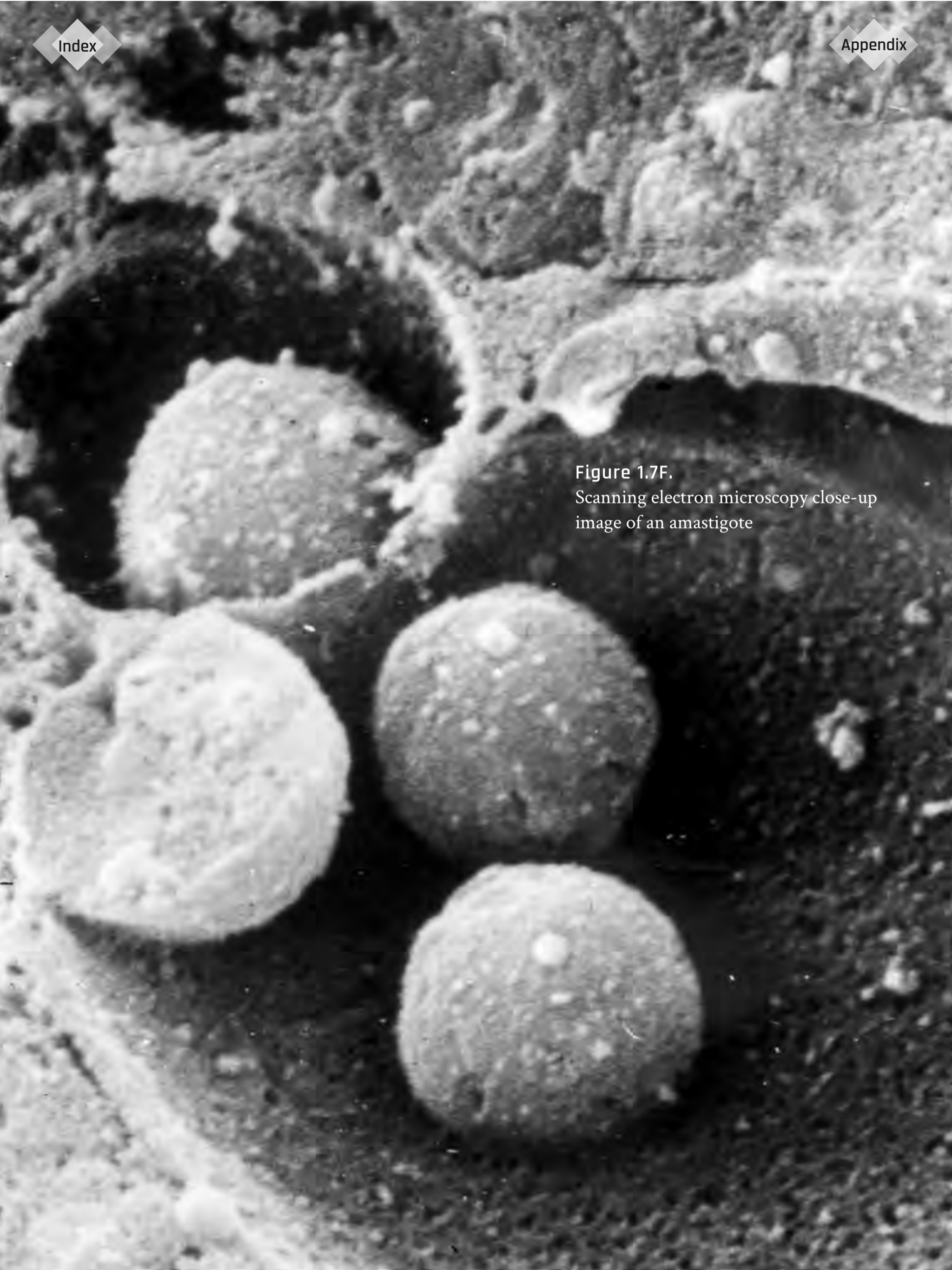

Figure 1.7F.  
Scanning electron microscopy close-up  
image of an amastigote



**Figure 1.7G.**  
Scanning electron microscopy close-up  
image of an amastigote



The species in subgenus *L.* (*Viannia*) generally grow poorly in culture media and slowly in experimentally infected hamsters (*Mesocricetus auratus*) (*Figure 1.8*); these species develop in the hindgut of phlebotomines, attached to the wall of the pylorus. This group includes only species in the Americas and for this reason they correspond to most of the neotropical species.

Commonly, the species in subgenus *L.* (*Leishmania*) grow easily in culture media, cause large nodular lesions with spread to the extremities in experimentally infected hamsters, and develop in the midgut and foregut of phlebotomines. This group includes species that circulate in the Americas, Africa, Asia, and Europe, which justifies referring to them as New World and Old World, depending on the geographical region where they are found.

To date, in the American continent, circulation has been confirmed for 12 *Leishmania* species, considered etiologic agents of human leishmaniasis; however, other species have been subject to discussion or taxonomic review.



Figure 1.8.  
*Mesocricetus auratus*, hamster

The main agent of American visceral leishmaniasis is *L. infantum*, of the *L. donovani* complex, although other species can also cause it. In 1937, Cunha and Chagas described *L. chagasi* as being responsible for American visceral leishmaniasis; although there is now solid evidence to consider *L. chagasi* to be a synonym for *L. infantum*, some authors still use the prior name. In some countries, such as Costa Rica, El Salvador, Honduras, Nicaragua, and Venezuela, this species has also been considered the cause of atypical cutaneous leishmaniasis.

Cutaneous leishmaniasis is associated with several *Leishmania* species, of the subgenera *L.* (*Leishmania*) and *L.* (*Viannia*). The subgenus *L.* (*Leishmania*) includes *L. mexicana*, *L. amazonensis*, and *L. venezuelensis*; *L. pifanoi* and *L. garnhami* are considered synonymous to *L. mexicana* and *L. amazonensis*, respectively, however, this is under discussion. The species of subgenus *L.* (*Viannia*) are more numerous in the Americas and are scattered in all the countries with reported cutaneous leishmaniasis; some, such as *L. braziliensis*, are very widely distributed geographically, while others, such as *L. lindenbergi*, have only been reported in specific regions so far.

The main types of *Leishmania* recognized as etiologic agents of leishmaniasis in humans in the Americas are listed in *Table 1.1*.

**Table 1.1.** Main species of *Leishmania* recognized as etiologic agents of human leishmaniasis in the American continent

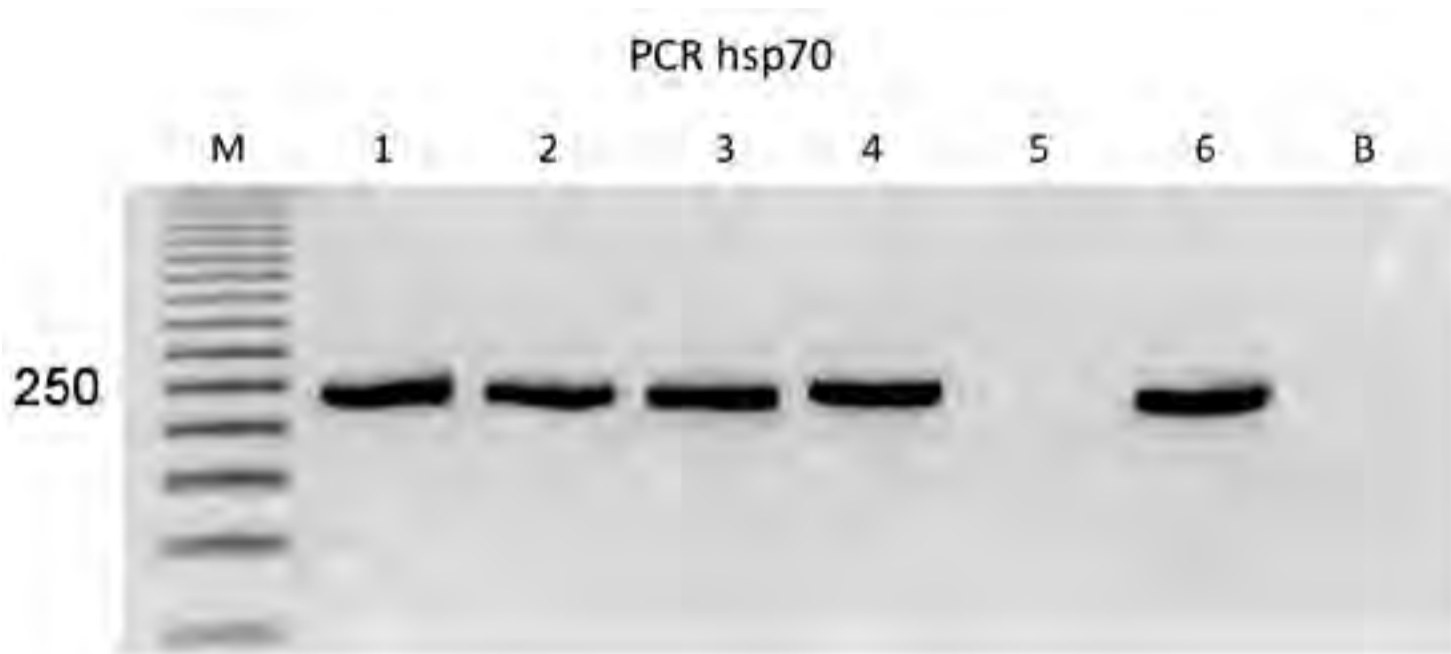
Subgenus	Species	Description	Countries where the species have been reported
<i>Leishmania</i> ( <i>Leishmania</i> ) Safjanova, 1982	<i>Leishmania infantum</i>	Nicolle, 1908 (sin. <i>Leishmania chagasi</i> Cunha and Chagas, 1937)	All countries with reported cases of human or canine visceral leishmaniasis
	<i>Leishmania mexicana</i>	Biagi, 1953 (sin. <i>Leishmania pifanoi</i> Medina and Romero, 1959)	Belize, Colombia, Costa Rica, Dominican Republic, Ecuador, Guatemala, Honduras, Mexico, Panama, and Venezuela
	<i>Leishmania amazonensis</i>	Lainson and Shaw, 1972 (sin. <i>Leishmania garnhami</i> Scorza, et al., 1979)	Bolivia, Brazil, Colombia, Costa Rica, Ecuador, French Guiana, Panama, Peru, Suriname, and Venezuela
	<i>Leishmania venezuelensis</i>	Bonfante-Garrido, 1980	Venezuela
<i>Leishmania</i> ( <i>Viannia</i> ) Lainson and Shaw, 1987	<i>Leishmania braziliensis</i>	Vianna, 1911	Argentina, Belize, Bolivia, Brazil, Colombia, Costa Rica, Ecuador, Guatemala, Honduras, Nicaragua, Panama, Paraguay, Peru, and Venezuela
	<i>Leishmania peruviana</i>	Vélez, 1913	Peru
	<i>Leishmania guyanensis</i>	Floch, 1954	Brazil, Bolivia, Colombia, Ecuador, French Guiana, Guyana, Peru, Suriname, and Venezuela
	<i>Leishmania panamensis</i>	Lainson and Shaw, 1972	Colombia, Costa Rica, Ecuador, Honduras, Nicaragua, Panama, and Venezuela

Subgenus	Species	Description	Countries where the species have been reported
<i>Leishmania</i> ( <i>Viannia</i> ) Lainson and Shaw, 1987	<i>Leishmania lainsoni</i>	Silveira, Shaw, Braga and Ishikawa, 1987	Brazil (mainly in the Amazon region), Bolivia, Colombia, Ecuador, French Guiana, and Suriname
	<i>Leishmania shawi</i>	Lainson, Braga, de Souza, Pôvoa, Ishikawa and Silveira, 1989	Brazil (mainly in the Amazon region), and Ecuador
	<i>Leishmania naiffi</i>	Lainson and Shaw, 1989	Brazil, Ecuador, French Guiana, and Suriname
	<i>Leishmania lindenbergi</i>	Silveira, <i>et al.</i> , 2002	Pará State (Brazil)

In addition to these species, *L. colombiensis* (Kreutzer, Corredor, Grimaldi, Grogl, Rowton, Young, *et al.*, 1991) was described as being associated with canine and human infections in Colombia and Venezuela; following taxonomic review it was classified in another genus. Furthermore, *L. waltoni* (Shaw, Pratlong, Floeter-Invierno, Ishikawa, El Baidouri, Ravel, *et al.*, 2015) was recently implicated as an etiologic agent for diffuse cutaneous leishmaniasis in the Dominican Republic.

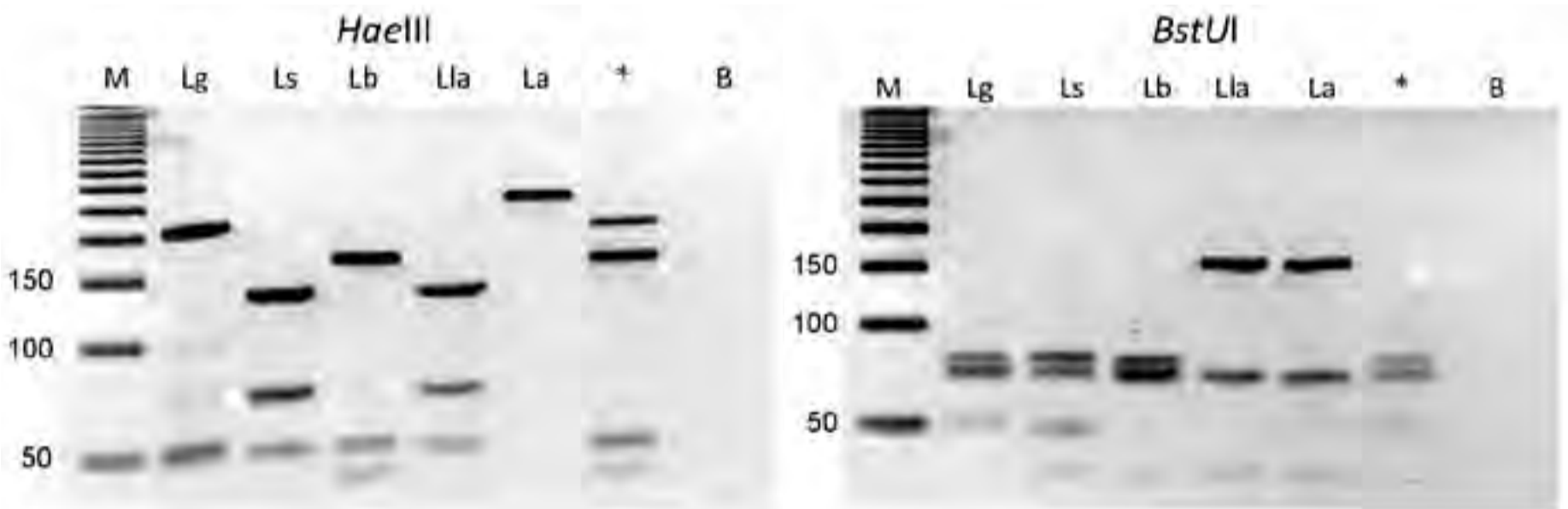
Many methods have been proposed for identifying *Leishmania* species. Isoenzyme electrophoresis continues to be the best method, with the disadvantage that it requires in vitro isolation and culture of the parasite. Among molecular methods for neotropical species, analysis of the heat shock protein 70 (HSP70) gene, through polymerase chain reaction (PCR) followed by restriction fragment length polymorphism (RFLP) or sequencing has demonstrated the best results (*Figures 1.9*).

Molecular tools associated with data interpretation using phylogenetic and population analysis methods have been quite valuable for understanding the means of reproduction of *Leishmania*. Classically, these organisms are considered to have a clonal mode of propagation. However, in addition to enzyme electrophoresis and other methods for observing hybrids among *Leishmania* species, some of them have shown to have frequent genetic exchange. All indications are that, after recombination, these hybrids are propagated by clones. Hybrid lineages are the possible result of genetic exchange within the same species or between species that are quite similar phylogenetically.



**Figure 1.9A.**

HSP70 PCR gel. M: 50bp (base pair) molecular weight marker; 1 to 4: positive clinical samples; 5: negative control; 6: positive control; and B: blank



**Figures 1.9B and C.**

Lg: *Leishmania (V.) guyanensis*; Ls: *Leishmania (V.) shawi*; Lb: *Leishmania (V.) braziliensis*; Lla: *Leishmania (V.) lainsoni*; La: *Leishmania (L.) amazonensis*; \*inconclusive sample; and B: blank

The genus *Leishmania* is characterized by great interspecific and intraspecific genetic diversity. The species included in subgenus *L. (Viannia)* are known to be highly diverse; e.g., *L. braziliensis* and *L. naiffi* present a high degree of intraspecific isozyme polymorphism—i.e., various zymodemes—while *L. guyanensis* is notably uniform. Based on knowledge of several *Leishmania* species, Old World species have 36 chromosomes, while New World ones have 34 or 35; in the *L. mexicana* group, chromosomes 8 and 29 are fused, as are 20 and 36, and the same is true in *L. braziliensis* for chromosomes 20 and 34. Gene organization is known to be preserved among *Leishmania* species, although there are many polymorphisms in DNA sequences.

Regardless of the *Leishmania* species, infection by this parasite in humans can be asymptomatic or produce a wide spectrum of clinical manifestations. Different species can cause similar clinical manifestations, although it is possible to relate some of them to certain species; e.g., the mucosal form is common in infections by *L. (Viannia)* spp., and is even more frequent in infections by *L. braziliensis*, a species that is also strongly associated with the disseminated form characterized clinically by the presence of multiple lesions. In certain neotropical regions, an endosymbiont RNA virus, the Leishmaniavirus 1 (LRV1), is present in some circulating parasites of the subgenus *L. (Viannia)*, which may influence the clinical outcome. In the case of the diffuse form, infections are caused by the species *L. mexicana* and *L. amazonensis*.



Circulation of some *Leishmania* species is more restricted to the wild. However, many species have already adapted to secondary or peridomestic cycles, as is the case with *L. infantum* and *L. braziliensis* in some endemic areas of early human colonization.

One of the characteristics of the *Leishmania* spp. transmission cycle is its association with several ecotopes. Despite a lack of direct evidence of a strict association between a species and a specific environment, some species were described in regions of the Amazon rainforest, such as *L. lainsoni* and *L. naiffi*. The species *L. infantum*, *L. braziliensis*, and *L. guyanensis* have been observed in various environments and, as a result, may be transmitted by different phlebotomine species, although there may be restrictions related to the conduciveness of the environment to the vector.

The presence of different *Leishmania* species should be treated as dynamic and should not be restricted to existing information on some isolates. Several studies indicate that *Leishmania* spp. are parasites with environmental plasticity, and that the observed geographical distribution is more related to adaptation by the vectors and hosts present in the local environment than to the biome.

## Recommended Reading

- Cunha AM, Chagas E. Nova espécie de protozoário do genero *Leishmania* pathogenico para o homem, *Leishmania chagasi*, n.sp. Hospital (Rio de Janeiro). 1937;11:3-9.
- ICD-11 for Mortality and Morbidity Statistics (ICD11 MMS), 2018. Available at: <https://icd.who.int/browse11/l-m/en> (1F54/54.0/54.1/54.2).
- Lainson R, Shaw JJ. Leishmaniasis of the New World: Taxonomic problems. Brit Med Bull. 1972;28:44-8.
- Pessoa SB. Classificação das leishmanioses e das espécies do gênero *Leishmania*. Arq Hig Saude Publica. 1961;26:41-50.

# Vectors



Óscar Daniel Salomón

By 2017, approximately 1,000 species of the subfamily Phlebotominae had been described (order: Diptera; suborder: Nematocera; family: Psychodidae). Its greatest diversity is found between both subtropics—except for New Zealand and the islands of Oceania—although there are species that colonize up to the 50<sup>th</sup> parallel north in Canada and 40<sup>th</sup> parallel south in Argentina, and there are stable populations in areas below sea level, such as the Dead Sea, and at over 3,000 meters above sea level.

In the Americas, 536 species have been recognized, grouped into three genera. The species that pose a health risk belong to the genus *Lutzomyia*, according to the classification by Lewis, revised by Young, the one most commonly used programmatically; the most recent classification by Galati, most used in academia, recognizes 23 genera.

Adult phlebotomines are small sand flies, usually up to 3 mm in length. The body and wings have dense pilosity and a hairy appearance (*Figure 1.10*); the thorax is humped, hiding the head in the dorsal view; the antennae have a connected flagellum; wings are oval or lanceolate and, at rest, are held at a 45° angle or “V” (*Figure 1.11*).



**Figure 1.10.**

Adult phlebotomines are small sand flies, usually up to 3 mm in length. The body and wings have dense pilosity and a hairy appearance.



**Figure 1.11.**

Phlebotomine wings are oval or lanceolate and, at rest, are held at a 45° angle or a “V”.

The main diagnostic structures of adults, used to identify species, are the female's spermathecae and cibarial teeth, the male's external genitalia and genital pump, and the relative size of the palpomeres and wing veins.

Morphological characters, useful in most cases, are not sufficient to differentiate some species and species complexes such as *Lu. longipalpis* (Figures 1.12), the main vector of *L. infantum* in the Americas. In the latter, populations with behavioral ("love songs"), physicochemical (pheromones), biochemical (cuticular hydrocarbons), and genetic differences have been described, which can produce reproductive barriers and be associated with different vector capacities.

However, for correct determination, still using morphological taxonomy, microscopy of clarified specimens and species sympatry require entomological laboratories with trained technicians and quality control, a challenge for programmatic transfer.



**Figures 1.12A and B.**

Adult specimens of *Lutzomyia longipalpis*, the main vector of *Leishmania infantum* in the Americas

Phlebotomines are insects that undergo complete metamorphosis. Their life cycle starts as an egg (0.3 to 0.5 mm long and 0.1 to 0.15 mm wide); continues with four larval instars, with a maggot-shape and head capsule (*Figures 1.13*), that progressively increase in morphological complexity and size (from less than 1 mm up to 4 mm); and turns into the relatively immobile pupa that then transforms into the adult.

Development time depends on the species and on nutritional and climatic conditions, especially temperature and relative humidity. In general, the literature notes average times under fixed experimental conditions, although they serve as a reference for guidance. These periods are from the female's blood meal to oviposition, 6 to 10 days; embryonic development, 6 to 10 days; larval development, 17 to 32 days (three weeks), and pupal development, 7 to 10 days. Thus, from feeding to emergence of the adult, five to six weeks pass. The longevity of the adult is from three to four weeks (14 to 60 days) and the female lays from 30 to 70 eggs up to 200.



**Figures 1.13A and B.**

Larval instar of *Lutzomyia* spp., maggot-shaped with head capsule

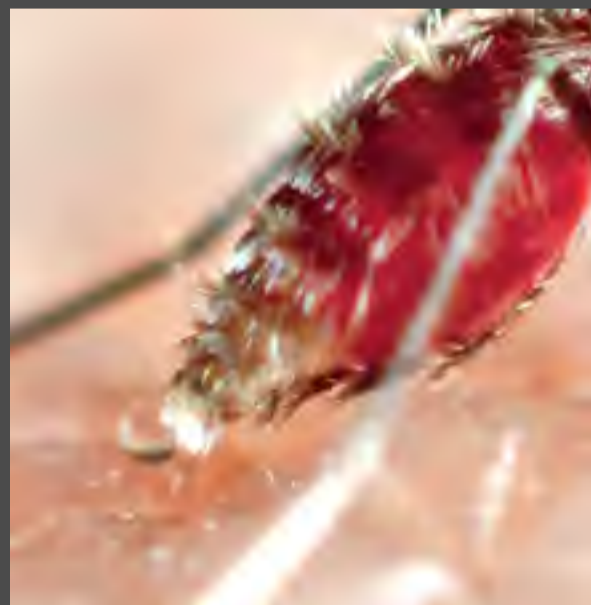
In some species, and in some latitudes, seasonally or under adverse conditions, development can undergo a diapause, usually as a fourth-instar larva. Larvae are terrestrial, saprophagous and, in general, develop in temperate microenvironments that are humid and rich in organic matter, with good canopy cover. Thus far, the natural breeding sites of many species of health interest have not been identified; furthermore, few larvae are collected with regard to the adult population. Due to these circumstances, it has not yet been possible to develop antivectorial interventions directed against the pre-adult stages.

In general, adults are active in the evening or at night and rest during the day in dark places, with relatively stable climatic conditions. Their flight capacity is limited and, in many species is inhibited by the wind; the mode of its dispersion radius, determined by capture-recapture, usually does not exceed 100 to 200 m, and is less when released from a food source, although there are records of specimens found up to 2 km from the release site.

Adult males and females feed on sugary solutions from plants (*Figure 1.14*) or aphids for their metabolism. Females need blood to complete their ovarian cycle (*Figure 1.15*), although autogeny has been described in some species. Although not hematophagous, males tend to reach the host first and attract the females and copulate with them once the females have ingested blood, which guarantees the presence of fertilizable ovocytes.



**Figure 1.14.**  
Adult males and females feed on sugary solutions from plants.



**Figures 1.15A and B.**  
*Lutzomyia* spp. adult female, ingesting blood on human skin



Bioecological and behavioral aspects vary among species, giving them different epidemiological importance and opportunities to control the different species. These aspects include range of tolerance of variables and resiliency to environmental changes; hourly and seasonal activity peaks; rest outside (exophily) or inside (endofily) of human homes during blood feeding; endofily or exophily during egg maturation after the blood meal; restricted or broad host preference, according to host availability; and adaptability and dispersion in rural or urban anthropic environments.

Vectors do not rest inside houses (endofily), nor do they bite preferentially or exclusively indoors (endophagy).

Thus far, only 10% of described Phlebotominae species have been associated with transmission of parasites from the genus *Leishmania* to vertebrates by regurgitation during ingestion of blood, with the exception of the cycle in the *L. enriettii* complex by the family Ceratopogonidae and possible alternate modes of transmission by subgenus *Sauroleishmania*.

*Leishmania* subgenera were characterized according to the site of the parasite's attachment and development in the vector, taking as reference the pylorus region (region anterior to the proctodeum where the Malpighian tubules end), as peripylarian (*Viannia*), suprapylarian (*Leishmania*), and hypopylarian (*Sauroleishmania*), corresponding to different histological or functional structures of different embryological origin.

Duration of the extrinsic cycle of the parasite varies with each combination of vector and parasite species and developmental conditions. In controlled conditions, *L. infantum* has metacyclic forms in three to four days in its New World vectors and *L. braziliensis*, in four to six days, although successive ingestions can alter both times and parasitic cycles.

Due to generalization of molecular analyses in high-prevalence transmission foci, many blood-sucking insects are found with fragments of parasitic DNA in their food content, which does not incriminate them as vectors (except for mechanical transmission) until their vector competence and capability are demonstrated.

According to different authors, the criteria for incriminating a Phlebotominae species as a vector, and specifically as a vector of transmission to humans, include:

- a. association in time, space, environment, and source of blood feeding, between the vector, reservoirs (zoophilia), and humans (anthropophilism);
- b. in repeatedly isolated parasites, identification of vectors without recent blood meals, of reservoirs, and of human cases;
- c. association in time, space, and environment between the infection in host mammals and the vector, with consistent parasite density and infection rate;

- d. growth and amplification of the parasite in the vector until metacyclic promastigotes are present in the stomodeal valve or the mid-foregut (nature or experimental infection); and
- e. the vector is infected and, during the blood meal, can transmit the parasite to the reservoir or to the equivalent experimental model.

Phlebotominae with vector competence can be classified as species-specific or as permissive, while vector capacity is defined by intrinsic and extrinsic factors. Intrinsic factors include digestion, the enzyme cycle and the peritrophic matrix, anchorage of the parasite to the intestinal wall, magnitude of amplification, previous migration, meta-cyclogenesis and “exit” mechanisms, and multiple bites.

Ones that stand out are the composition of vector saliva injected during feeding, which may have protective functions in the case of previous non-infective bites; however, in the case of the vasodilator maxadilan of *Lu. longipalpis*, it is a facilitator of the infection even with few parasites.

Extrinsic factors depend on the bioecological and behavioral aspects of the aforementioned vector, and of the characteristics of the vector-reservoir complex, as cultural factors that modulate the probability of contact between the infected vector and the host. To determine the importance of a vector species in the establishment of foci and the consequent prioritization of public health interventions, it has been proposed to calculate the entomological inoculation rate and the mathematical model of transmission.

## Recommended Reading

- Akhoundi M, Kuhls K, Cannet A, Votýpka J, Marty P, Delaunay P, Sereno D. A historical overview of the classification, evolution, and dispersion of *Leishmania* parasites and sandflies. PLoS Negl Trop Dis. 2016;10:e0004349. doi:10.1371/journal.pntd.0004770.
- Galati EAB, Galvis-Ovallos F, Lawyer P, Léger N, Depaquit J. An illustrated guide for characters and terminology used in descriptions of Phlebotominae (Diptera, Psychodidae). Parasite. 2017;24:26. doi: 10.1051/parasite/2017027.
- Lawyer P, Killick-Kendrick M, Rowland T, Rowton E, Volf P. Laboratory colonization and mass rearing of phlebotomine sand flies (Diptera, Psychodidae). Parasite. 2017;24:42. doi: 10.1051/parasite/2017041.
- Maroli M, Feliciangeli MD, Bichaud L, Charrel RN, Gradoni L. Phlebotomine sandflies and the spreading of leishmaniasis and other diseases of public health concern. Med Vet Entomol. 2013;27:123-47. doi: 10.1111/j.1365-2915.2012.01034.x.
- Shimabukuro PHF, de Andrade AJ, Galati EAB. Checklist of American sand flies (Diptera, Psychodidae, Phlebotominae): Genera, species, and their distribution. Zookeys. 2017;660:67-106. doi: 10.3897/zookeys.660.10508.

# Reservoirs



André Luiz Rodrigues Roque and  
Ana María Jansen

In the Americas, species of the genus *Leishmania* are parasitic of multiple zoonotic hosts, maintained in nature by a great diversity of mammal species. Although infection by *Leishmania* spp. in wild mammals has been studied since the early 20<sup>th</sup> century, transmission of these parasites in their natural cycle is still a major puzzle.

Among the many concepts proposed for what a *reservoir* is, we understand that this attribute is not necessarily restricted to a single species, but to a set of species responsible for maintaining the parasite in nature, which constitutes a system that we call a *reservoir system*. This system is dynamic and can include different species in different times and spaces.

It is important to emphasize that the attributes of pathogenic capacity, virulence, and resiliency are not considered in defining reservoirs. However, studies on wild transmission cycles of *Leishmania* spp. should include a multidisciplinary approach, because:

- a. with the exception of *L. infantum*, the other *Leishmania* species cause long-standing enzootic diseases, which have included numerous mammal species in their transmission cycle during millions of years, before humans arrived in the American continent;
- b. the different *Leishmania* species that circulate in the Americas are scattered in different habitats and biomes, and they exhibit major genetic, intraspecific, and interspecific diversity;

- c. these parasites remain and are transmitted in their natural cycle, despite the low rates of infection reported, generally in wild mammals and Phlebotominae; and
- d. there is enormous overlap in areas in the circulation of different *Leishmania* species and it is highly probable that some host mammals are exposed to mixed or multiple *Leishmania* spp. infections

Although dozens of mammal species have already been found to be naturally infected by different *Leishmania* species and can be considered hosts of these parasites, the reservoir system is made up of only a minority of them. In fact, the different diagnostic methods used, the capacity to maintain the infection, and the ecosystems in which the infected wild mammals were detected all indicate that only a minority of those host species can be considered potential reservoirs; i.e., they present favorable characteristics for infecting the vector.

To be considered a potential reservoir—as opposed to simple hosts—it is essential that individual persistence of the infection or infectious capacity be demonstrated; i.e., the potential to transmit the parasite to vectors, demonstrated by positive xenodiagnosis, positive skin or blood cultures, or both. Only local studies that include ecological and parasitological analyses can confirm one or more species as reservoirs of *Leishmania* spp. in a given environment.

Figure 1.16.  
*Didelphis  
marsupialis*,  
opossum



In the Americas, *Leishmania* spp. have been found infecting wild mammals from seven orders: Didelphimorphia, Cingulata, Pilosa, Rodentia, Primata, Carnivora, and Chiroptera. Didelphimorphia is an autochthonous order of mammals, and species of the genus are among the most investigated in field studies due to their great abundance in environments transformed by humans. In fact, *Didelphis* spp. is considered a synanthropic mammal indicative of disturbed areas. Field and experimental studies suggest that, at the least, *D. marsupialis* (Figure 1.16) and *D. albiventris* (Figure 1.17) are potential reservoirs of *L. infantum*, *L. braziliensis*, *L. amazonensis*, *L. guyanensis*, and *L. panamensis*.



Figure 1.17.  
*Didelphis albiventris*, opossum



A species of armadillo, *Dasypus novemcinctus* (order Cingulata) (Figure 1.18), is the only nonhuman host from which *L. naiffi* was isolated and is considered a potential reservoir of that parasite species.

The order Pilosa includes anteaters and sloths; *Tamandua tetradactyla* (Figure 1.19) is the only species of anteater found with natural infections by *L. amazonensis*, *L. guyanensis*, and *L. infantum*. The sloth species *Choloepus didactylus* (Figure 1.20) is a potential reservoir for *L. guyanensis*, while other sloth species (Figure 1.21) are hosts to different *Leishmania* species, especially those most closely related to *Endotrypanum* sp., such as *L. colombiensis* and *L. ecuatorensis*.



Figure 1.18.

*Dasypus novemcinctus* (order Cingulata), armadillo, potential reservoir of *Leishmania naiffi*



Figure 1.19.

*Tamandua tetradactyla*, anteater



**Figure 1.20.**

*Bradypus tridactyla*, other sloth species are hosts of different *Leishmania* species.



**Figure 1.21.**

*Choloepus didactylus*, anteater

Rodents are included in the most diverse and widespread order of mammals in the Americas: Rodentia. Infections by the greatest diversity of *Leishmania* species were reported in this order. Caviomorph rodents (suborder Hystricognathi) include *Proechimys* sp. and *Thrichomys* sp. species (Figure 1.22), already demonstrated as potential reservoirs of different *Leishmania* species.

Furthermore, despite countless studies that imply that rodents are reservoirs of *L. braziliensis*, *L. amazonensis*, and *L. mexicana*, only some rodent species, especially those of the suborder Hystricognathi, can currently be considered their potential reservoirs. When considering, in particular, the diversity of rodent species, certainly such generalizations are far from describing reality.

With regard to nonhuman primates, studies of *Leishmania* spp. are rare and only some species have been investigated and found to be infected by *L. amazonensis*, *L. shawi*, and *L. infantum*, which demonstrates that these mammals are also exposed to the transmission cycle of *Leishmania* spp. in nature.



**Figure 1.22.** *Thrichomys pachyurus*, caviomorph rodent, species considered a potential reservoir of *Leishmania* spp.



**Figure 1.23.**

Domestic dog (*Canis lupus familiaris*) with skin abnormalities suggestive of *Leishmania infantum* infection

In the order Carnivora, domestic dogs (*Figure 1.23*) are important reservoirs of *L. infantum*, as they are infective for the vector and responsible for maintaining transmission in urban environments. Their role as a reservoir for other *Leishmania* species, as well as the role of domestic cats as reservoirs, has not yet been fully clarified.

Wild canids are usually implicated as wild reservoirs of *L. infantum*. However, of the most abundant wild canid species in the Americas, only *Cerdocyon thous* (*Figures 1.24*) and *Speothos venaticus* (*Figure 1.25*), the prior more frequently, are considered potential reservoirs of *L. infantum*, while the persistence of the infection or its potential to infect vectors, have been never demonstrated for the fox *Pseudalopex vetulus*, for example.



Figures 1.24A and B.  
*Cerdocyon thous*, crab-eating fox (Spanish: *zorro de monte*; Portuguese: *cachorro do mato*), a wild canid species most frequently found infected by *Leishmania infantum*.





Figures 1.25.  
*Speothos venaticus*, bush dog

Bats (order Chiroptera) (*Figure 1.26*) are long-lived animals and the only mammals that fly, but only recently were investigated with regard to *Leishmania* spp. infections. The few records suggest that their importance was perhaps underestimated; both wild and urban bats have already been found to be infected by several species, such as *L. infantum*, *L. braziliensis*, *L. amazonensis*, and *L. mexicana*.



**Figure 1.26.**  
Adult specimens of *Chiroptera*, bats

The magnitude of the health problems caused by the leishmaniasis and their complex epidemiology points to the need to identify all the links in their network of transmission in a “One Health” approach, to implement effective control strategies.

In general, control measures for *L. infantum* concentrate on dogs, without considering the possibility that wild mammals, synanthropes, or both, can be involved in the cycle of transmission, serving as a source of infection for vectors in peridomestic areas. Furthermore, studies with wild mammals require biosafety measures to manage them and, in addition, there are no interventions to carry out.

With respect to *Leishmania* species responsible for the cutaneous and mucosal forms of the human disease, it has been posed that not only one host or one reservoir is involved in maintaining these parasites, but probably, several key species, with major transmission competition, are the ones responsible for the maintenance and transmission of these species in nature.

The factors involved in the amplification of enzootic foci—and the consequent risk of infections in humans—are specific to time and location, and it is essential to understand each focus of transmission in order to support effective and sustainable strategies for surveillance of leishmaniasis.



## Recommended Reading

- Ashford RW. What it takes to be a reservoir host. *Belg J Zool.* 1997;127:85-90.
- Quinnell RJ, Courtenay O. Transmission, reservoir hosts and control of zoonotic visceral leishmaniasis. *Parasitology.* 2009;136:1915-34. doi: 10.1017/S0031182009991156.
- Roque ALR, Jansen AM. Wild and synanthropic reservoirs of *Leishmania* species in the Americas. *Int J Parasitol Parasites Wildl.* 2014;3:251-62. doi: 10.1016/j.ijppaw.2014.08.004.
- Shaw J. The leishmaniases—survival and expansion in a changing world. A mini-review. *Mem Inst Oswaldo Cruz.* 2007;102:541-7.

# Epidemiological Situation of the Leishmaniases



Ana Nilce Silveira Maia-Elkhoury and  
Samantha Yuri Oshiro Branco Valadas

Leishmaniasis are geographically widespread diseases, present in 102 countries, regions, and territories, and distributed throughout the six regions of the World Health Organization (WHO) (*Figures 1.27 and 1.28*).

In the Eastern Mediterranean Region, 82% of countries are endemic for cutaneous leishmaniasis, followed by the Region of the Americas with 58%. For visceral leishmaniasis, the proportion is 82% of countries in the Eastern Mediterranean Region, followed by 51% in the European Region.

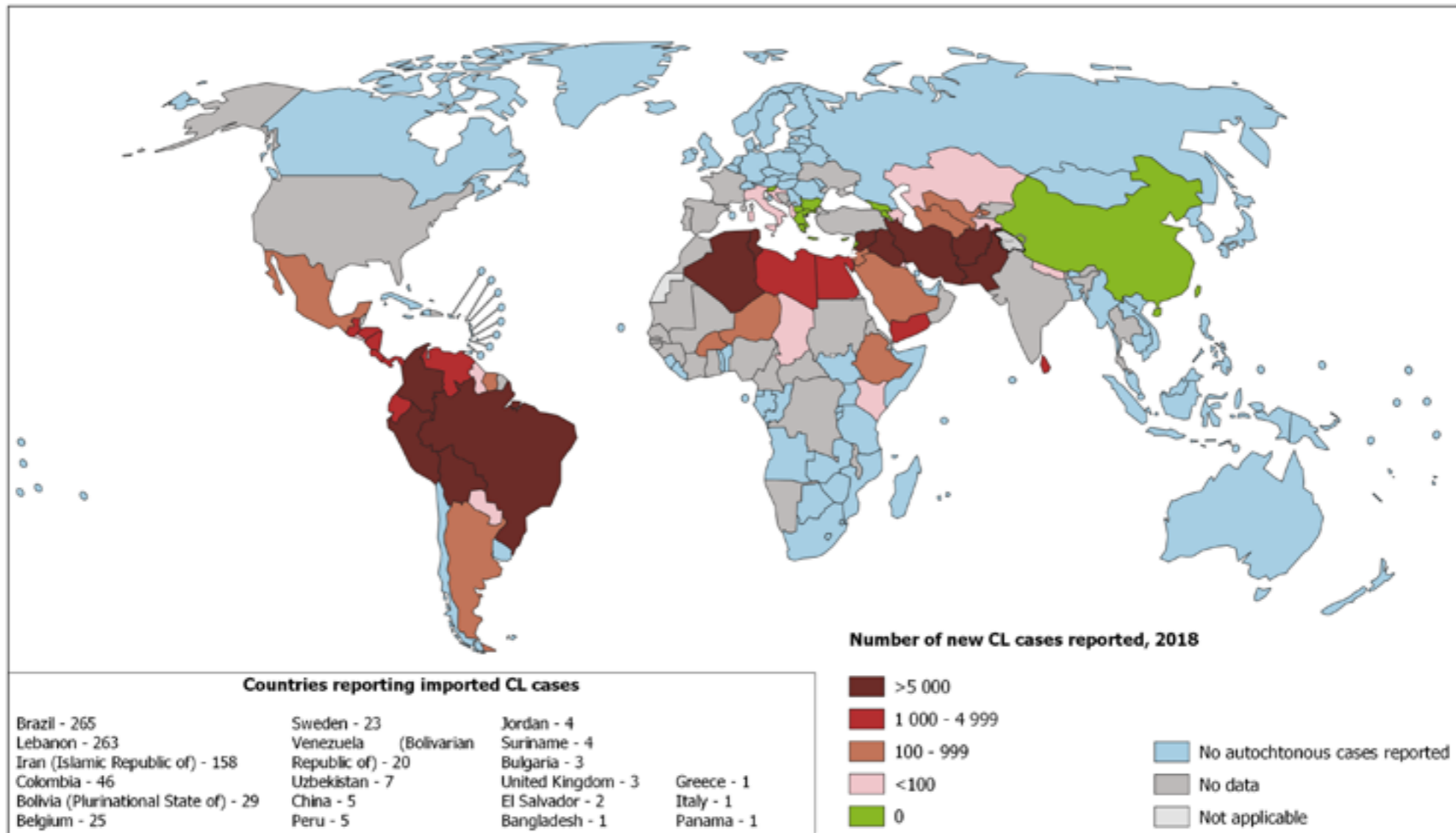
According to WHO, among the 87 countries endemic for leishmaniasis, 25 are considered to have a high disease burden: 14 with visceral leishmaniasis and 12 with cutaneous leishmaniasis; it is noteworthy that Brazil belongs to both groups.

In the Americas, leishmaniasis continues to be a public health problem due to its magnitude, importance, and geographical spread. The clinical forms in the Region are visceral, cutaneous, and mucosal leishmaniasis. However, in recent years, some cases of post kala-azar dermal leishmaniasis are being reported, in areas with visceral leishmaniasis transmission.

In the Region of the Americas, the leishmaniasis are zoonotic diseases, with cycles of sylvatic, domestic-rural, and domestic-urban transmission.

In the sylvatic cycle, infection occurs when humans penetrate the rainforest and are bitten by vectors infected from wild reservoirs; this is the main cycle of cutaneous leishmaniasis.

### Status of endemicity of cutaneous leishmaniasis worldwide, 2018



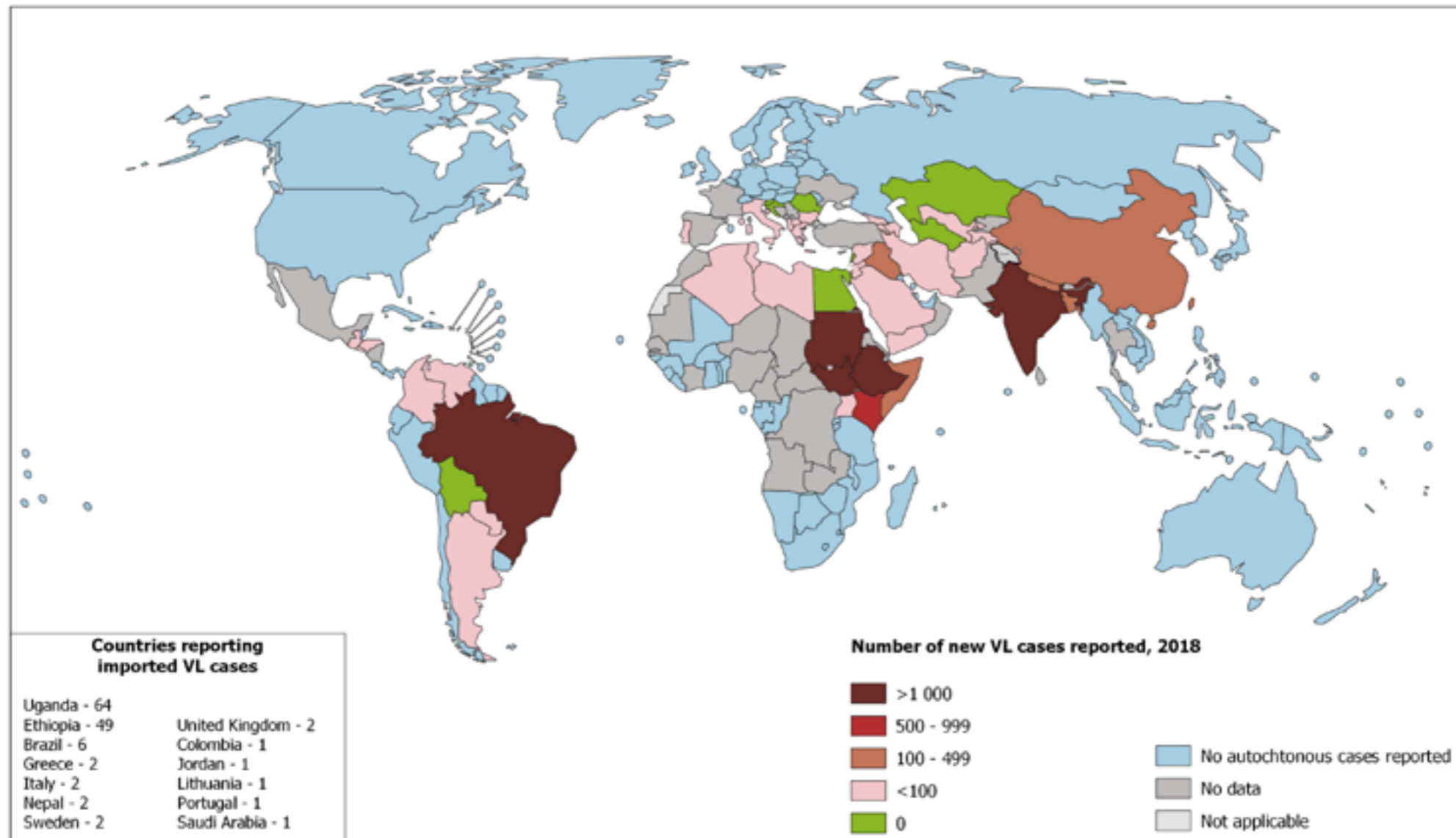
The boundaries and names shown and the designations used on this map do not imply the expression of any opinion whatsoever on the part of the World Health Organization concerning the legal status of any country, territory, city or area or of its authorities, or concerning the delimitation of its frontiers or boundaries. Dotted lines on maps represent approximate border lines for which there may not yet be full agreement. © WHO 2019. All rights reserved

Data Source: World Health Organization  
Map Production: Control of Neglected Tropical Diseases (NTD)  
World Health Organization



Figure 1.27. EState of endemic cutaneous leishmaniasis in the world, 2018  
Source: World Health Organization, 2018

### Status of endemicity of visceral leishmaniasis worldwide, 2018



The boundaries and names shown and the designations used on this map do not imply the expression of any opinion whatsoever on the part of the World Health Organization concerning the legal status of any country, territory, city or area or of its authorities, or concerning the delimitation of its frontiers or boundaries. Dotted lines on maps represent approximate border lines for which there may not yet be full agreement. © WHO 2019. All rights reserved

Data Source: World Health Organization  
 Map Production: Control of Neglected Tropical Diseases (NTD)  
 World Health Organization



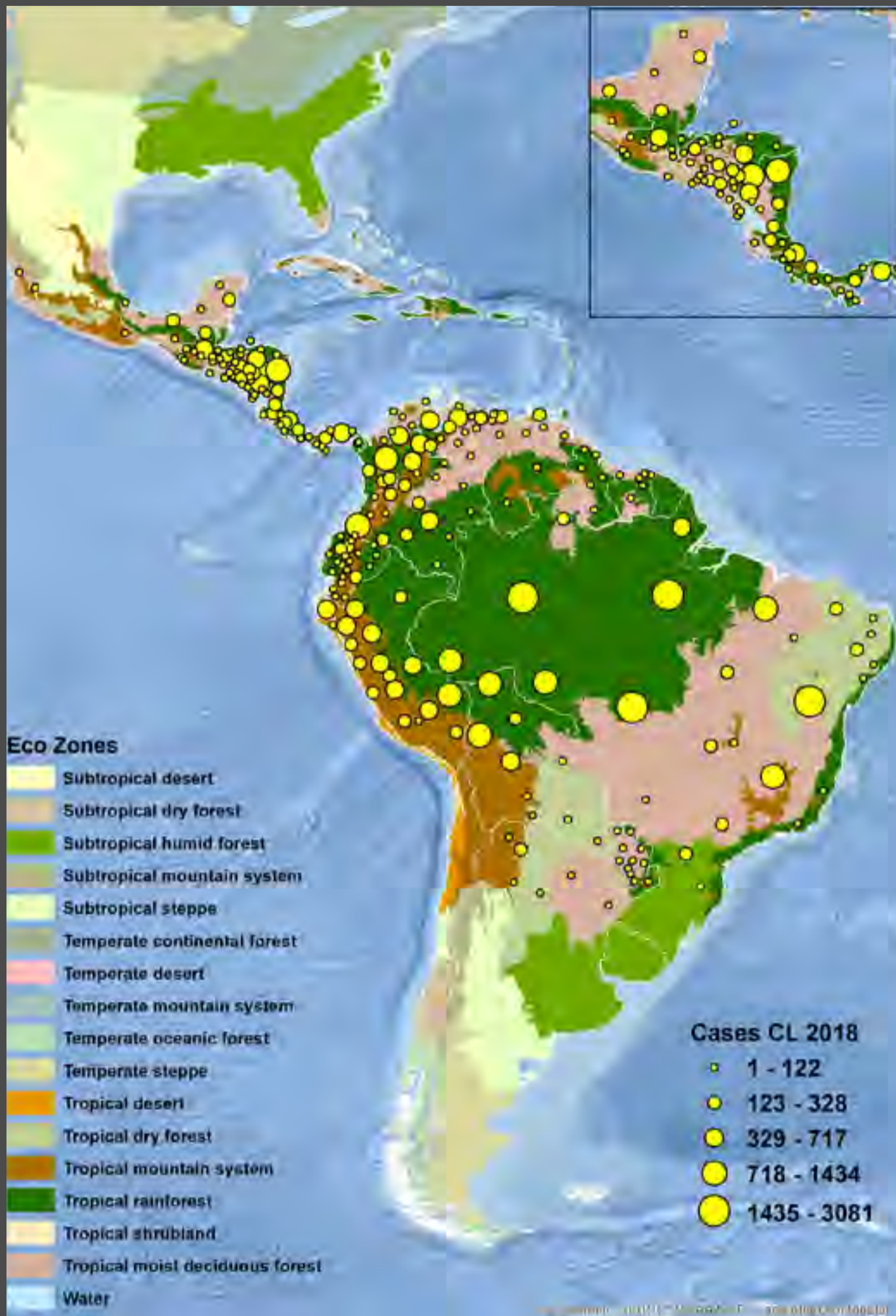Figure 1.28. State of endemic visceral leishmaniasis in the world, 2018

Source: World Health Organization, 2018

In the domestic-rural and domestic-urban cycles, vectors are present in the peridomiciliary area, enter dwellings, and transmit the infection in the domestic environment, where it also affects children.

These cycles, especially the domestic-rural one, include cutaneous leishmaniasis, but are most important in the transmission of visceral leishmaniasis. Thus, in places with transmission of visceral leishmaniasis, such as the countries of Central America, Colombia, Venezuela, and part of northeastern Brazil, the main cycle of transmission is domestic-rural.

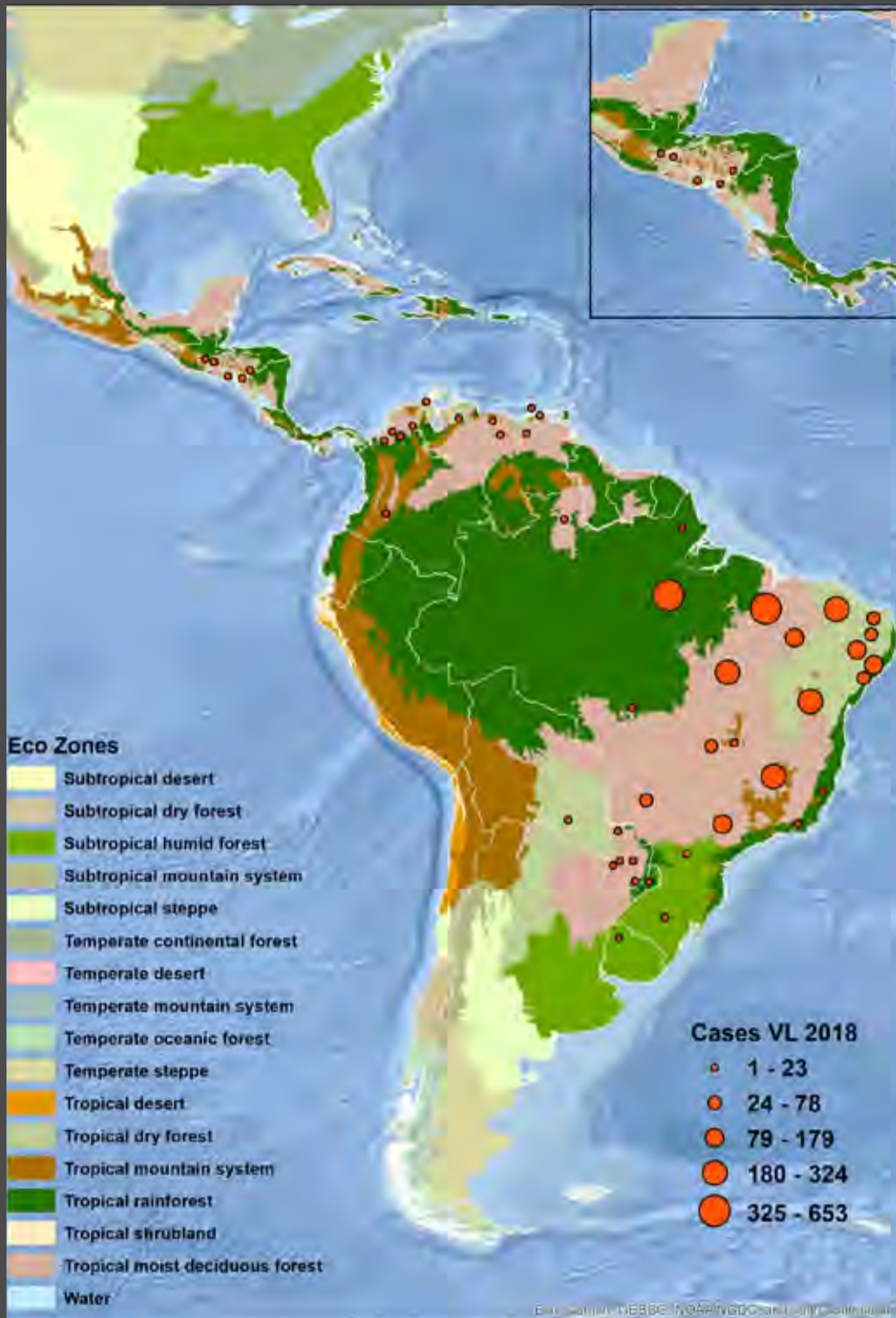
However, with adaptation of the main visceral leishmaniasis vector to the urban environment, in the other areas of Argentina, Bolivia, Brazil, Paraguay, and Uruguay, the main cycle is domestic-urban. The maps in *Figures 1.29 and 1.30*, characterize ecozones and the occurrence of cutaneous leishmaniasis, mainly in areas of tropical rainforest, and of visceral leishmaniasis in areas of subtropical forest and tropical dry forest.



**Figure 1.29.**

Cutaneous leishmaniasis cases, at the second national administrative level and by ecozones, Region of the Americas, 2018

Source: SisLeish-PAHO/WHO, data reported by national leishmaniases and surveillance programs, as of 1 October 2019



**Figure 1.30.**

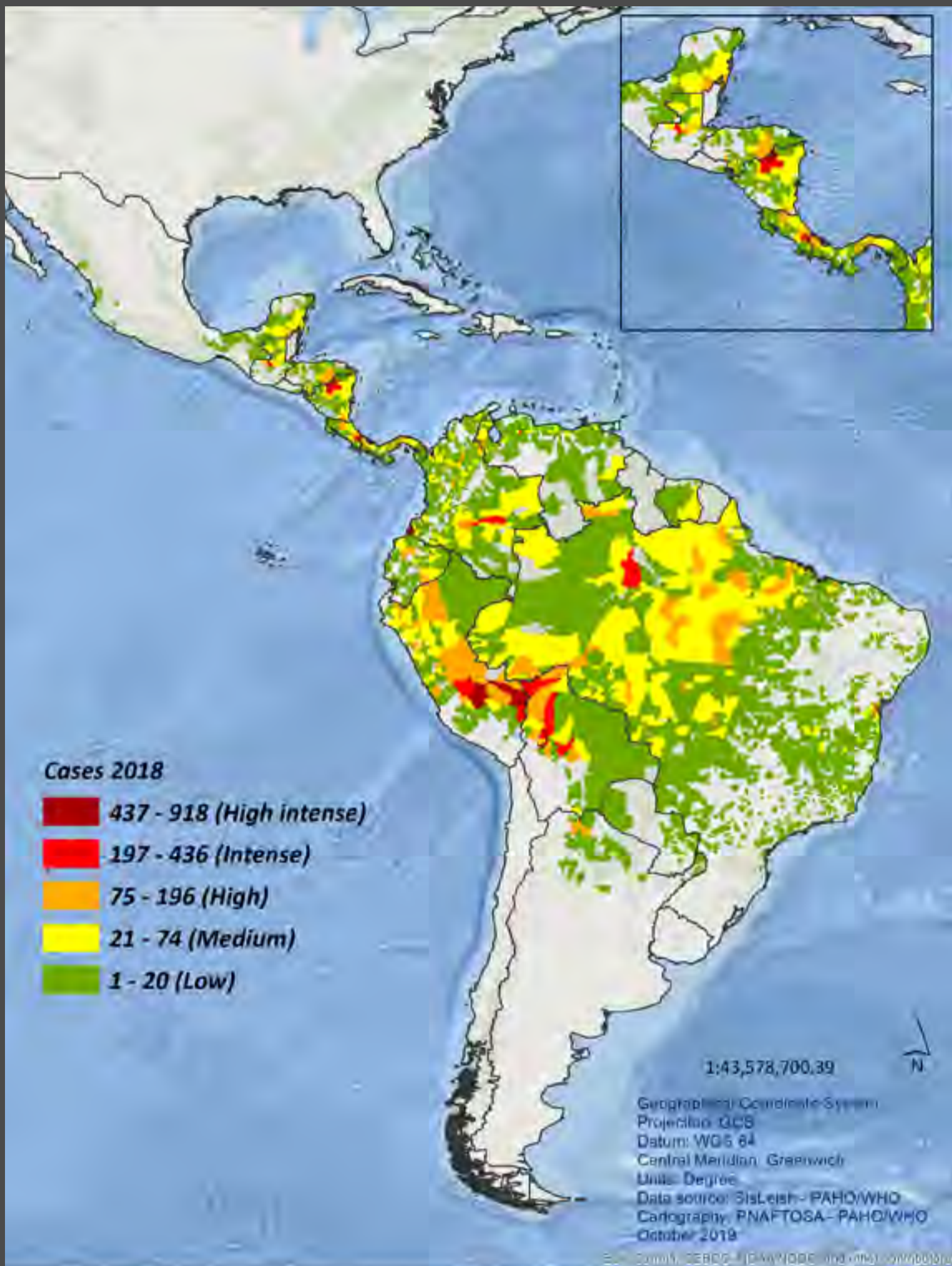
Visceral leishmaniasis cases, at the second national administrative level and by ecozones, Region of the Americas, 2018

Source: SisLeish-PAHO/WHO, data reported by national leishmaniases and surveillance programs, as of 1 October 2019



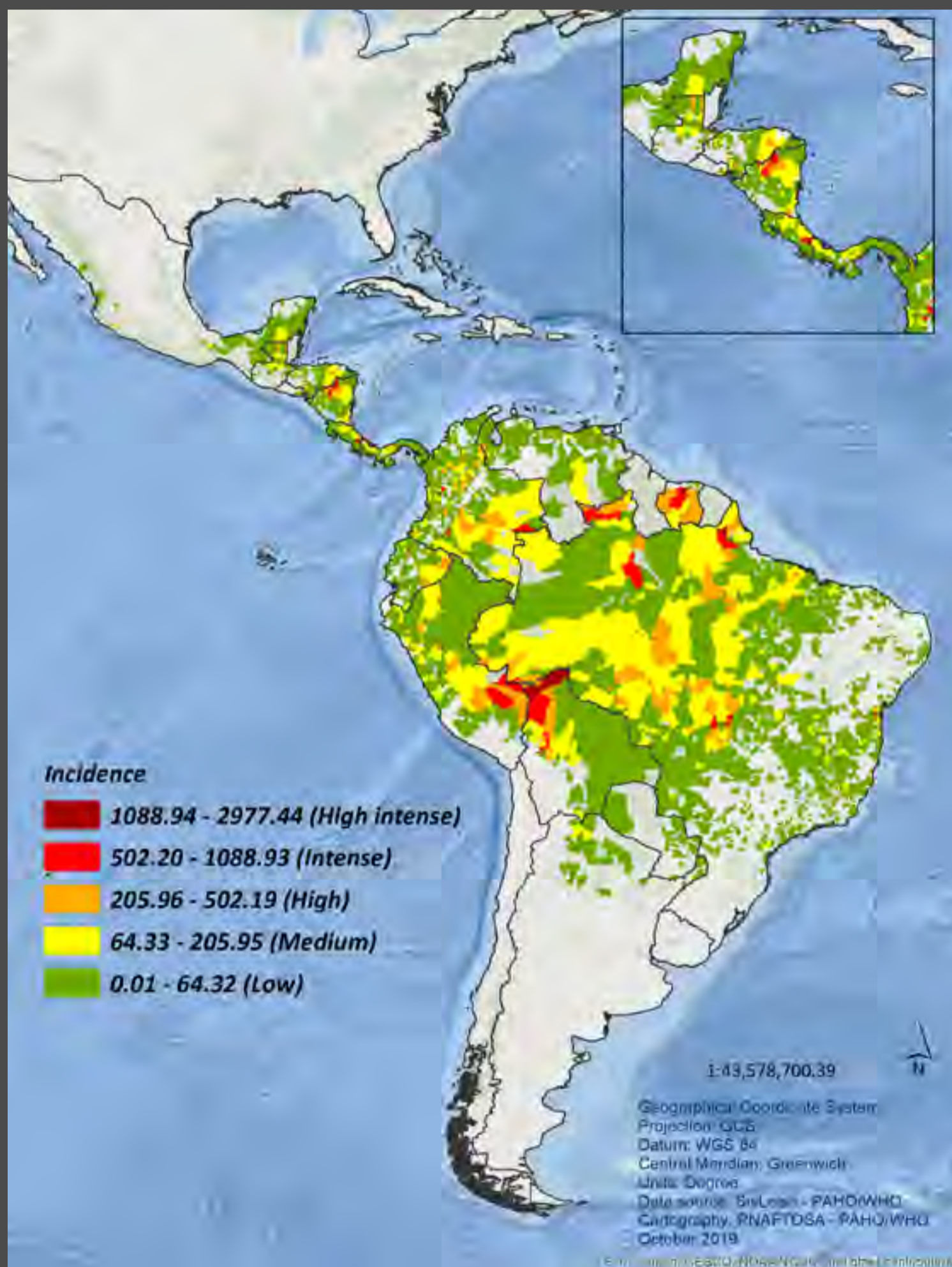
Cutaneous and mucosal leishmaniasis are endemic in 18 countries of the Region; from 2001 to 2018, 989,096 new cases were reported in 17 countries, excluding French Guiana whose data are reported to France. In 2018, the countries reported 46,041 cases, with the greatest number of records from Brazil (16,432), Colombia (6,362), Peru (6,321), and Nicaragua (3,722), together representing 71.3% of the Region's cases (*Figure 1.31*). The annual incidence rate in the Americas was 18.91 cases per 100,000 population, and the countries with the highest rates were Bolivia (54.71 per 100,000 population), Nicaragua (82.14 per 100,000 population), and Suriname (137.1 per 100,000 population) (*Figure 1.32*).

Nearly 69.6% of cases occurred in males and 86.6% in persons over 10 years of age. In 44,383 (92.2%) cases, the clinical form was reported; 1,942 (4.2%) cases were the mucosal form, which is more severe because it causes clinical complications, disabilities, and disfigurement.



**Figure 1.31.**

Cases of cutaneous leishmaniasis, at the second national administrative level, Region of the Americas, 2018  
 Source: SisLeish-PAHO/WHO, data reported by national leishmaniasis and surveillance programs, as of 1 October 2019

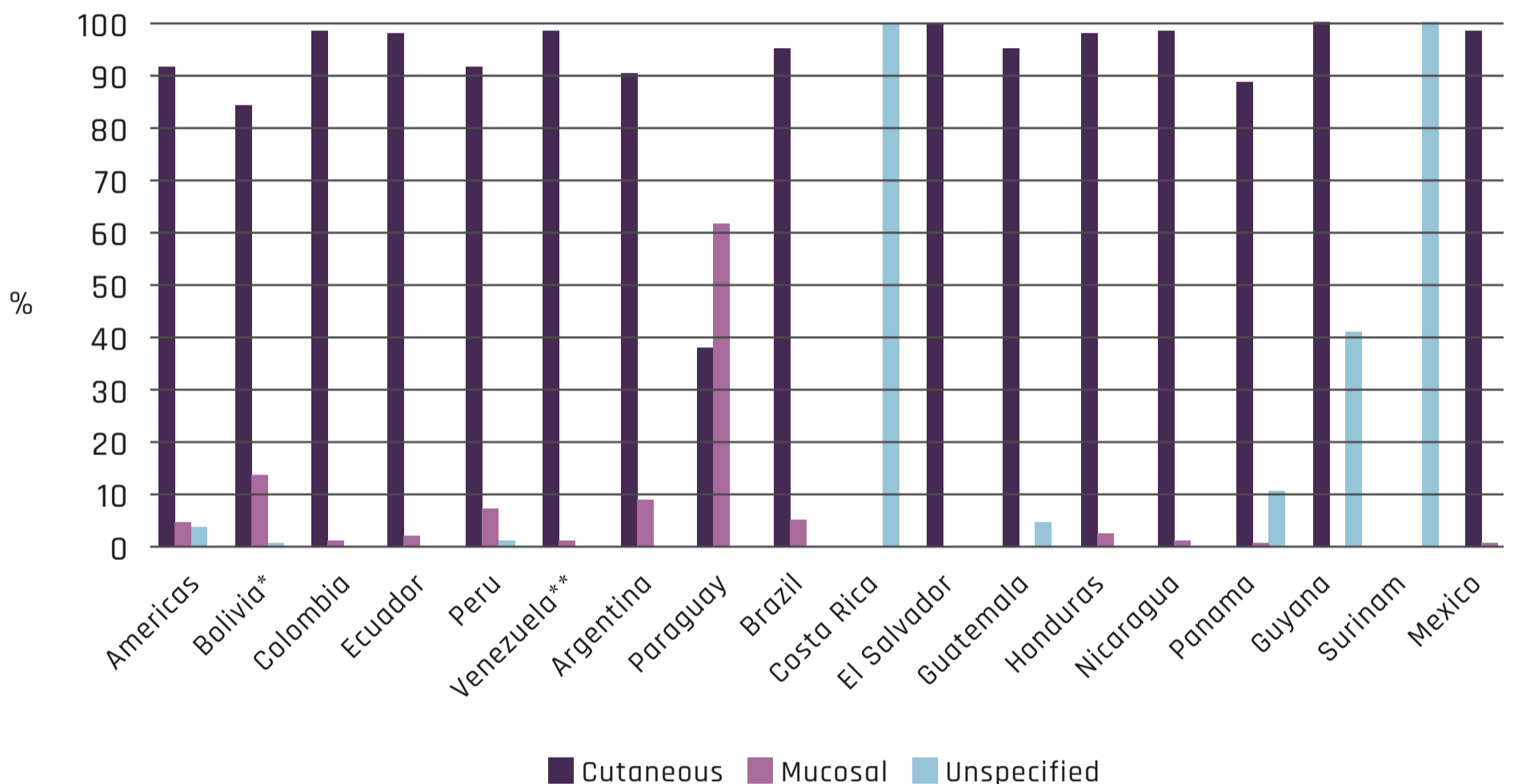


**Figure 1.32.**

Incidence of cutaneous leishmaniasis per 100,000 population, at the second national administrative level, Region of the Americas, 2018

Source: SisLeish-PAHO/WHO, data reported by national leishmaniases and surveillance programs, as of 1 October 2019

The countries that reported 92% of mucosal leishmaniasis cases were Bolivia (428), Brazil (800), Colombia (89), Paraguay (52), and Peru (417). Paraguay had the highest proportion (62%) of the mucosal form (*Figure 1.33*).



**Figure 1.33.**

Proportion of cutaneous and mucosal leishmaniasis cases, Region of the Americas, 2018. \*Bolivia (Plurinational State of); \*\*Venezuela, Bolivarian Republic of  
Source: SisLeish-PAHO/WHO, data reported by national leishmaniasis and surveillance programs, as of 1 October 2019

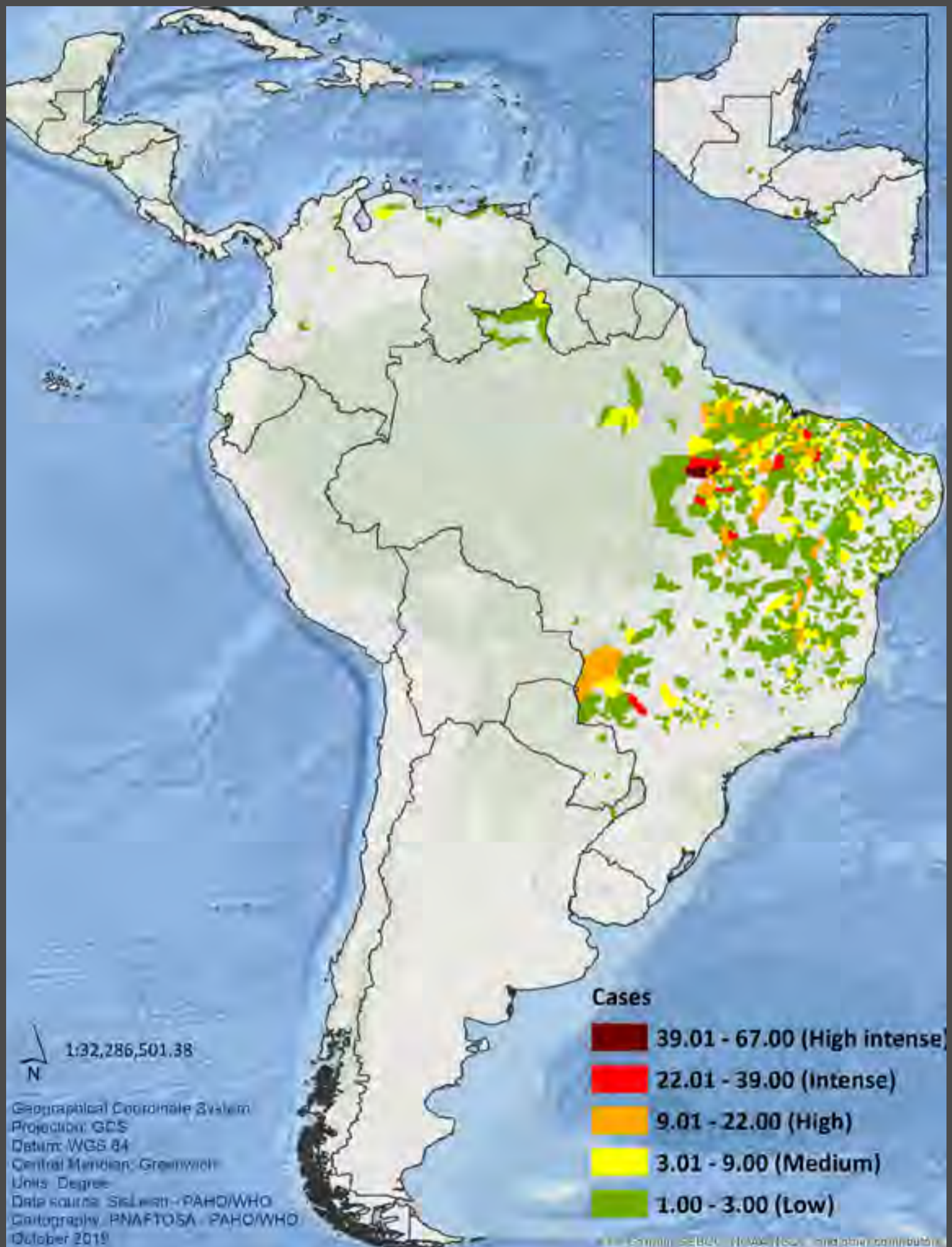
There were 812 cases of atypical cutaneous forms, distributed in El Salvador (6.2%), Honduras (86.4%), and Nicaragua (7.4%). A total of 38,511 (83.65%) cases were confirmed by laboratory diagnosis.

Coinfection by *Leishmania* and HIV occurred in 247 (0.53%) cases with different cutaneous and mucosal forms, with 7 records in Bolivia, 168 in Brazil, 57 in Colombia, 1 in Guyana, 1 in Nicaragua, and 2 in Mexico and in Peru.

Of the total of 46,041 cases, 66% were cured, 11 deaths were reported, and in 33.8%, the course of the disease was not reported in the leishmaniasis regional information system (SisLeish).

Visceral leishmaniasis is endemic in 12 countries of the Americas, although 96% of cases are reported in Brazil. In the period 2001 to 2018, 63,331 human cases of visceral leishmaniasis were reported, with an average of 3,518 cases per year. In 2018, 3,466 cases of visceral leishmaniasis were reported, with an incidence rate of 5.05 per 100,000 population, when considering the population of the areas of transmission (*Figures 1.34 and 1.35*).

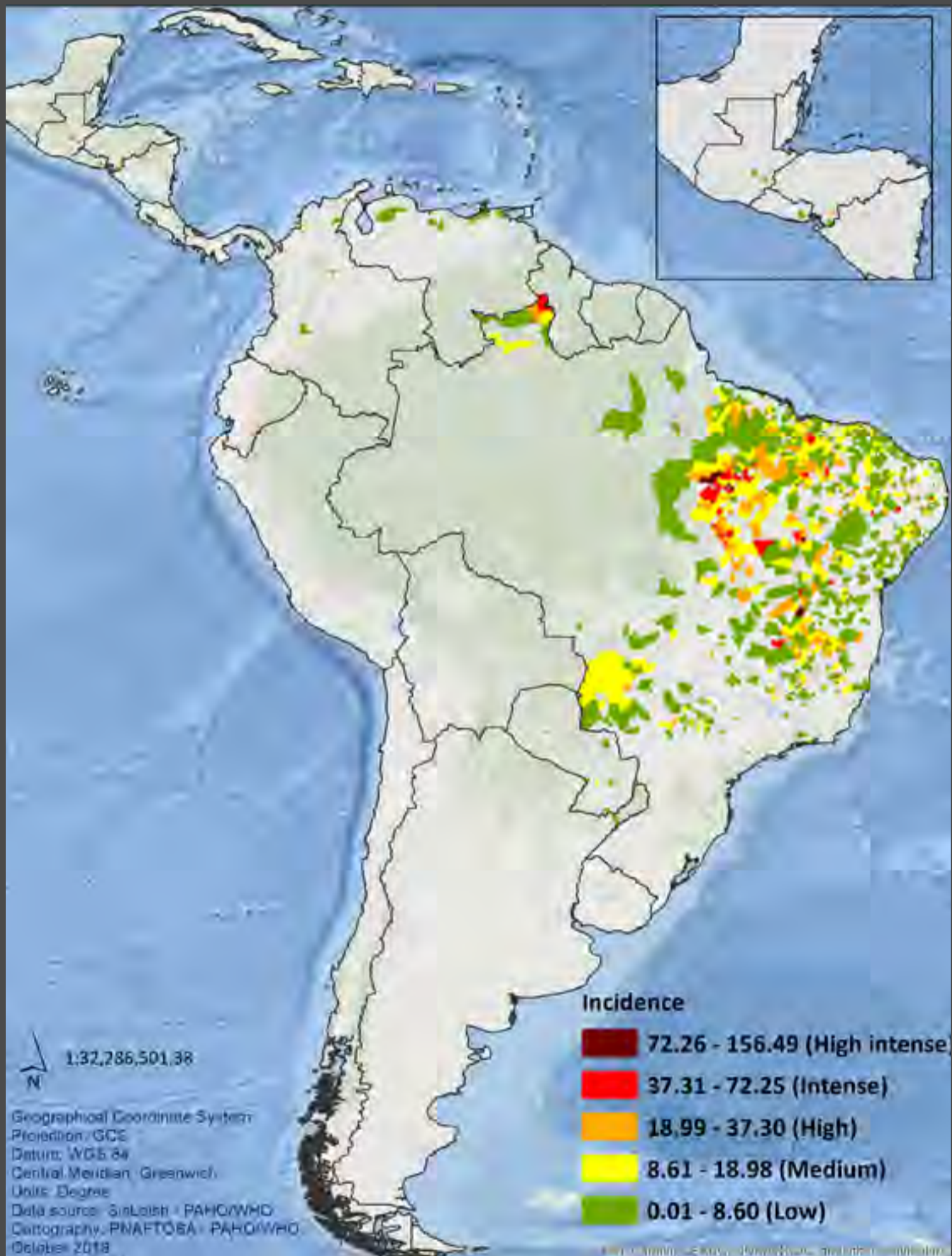
Cases of visceral leishmaniasis were reported in nine countries and, in 2018, there was a notable reduction of nearly 16% in cases reported in the Americas compared to 2017. The reduction occurred in Argentina, Brazil, Colombia, and Paraguay, while El Salvador, Guatemala, and Venezuela had an increase in visceral leishmaniasis cases. Sixty-seven percent of cases were male, and children aged <10 years were the most affected, with 41.2% of reports. In Colombia and Venezuela, children aged <5 years represented 75% of cases, and in El Salvador, Guatemala, and Honduras, they were 100% of reported cases.



**Figure 1.34.**

Visceral leishmaniasis cases, at the second national administrative level, Region of the Americas, 2018

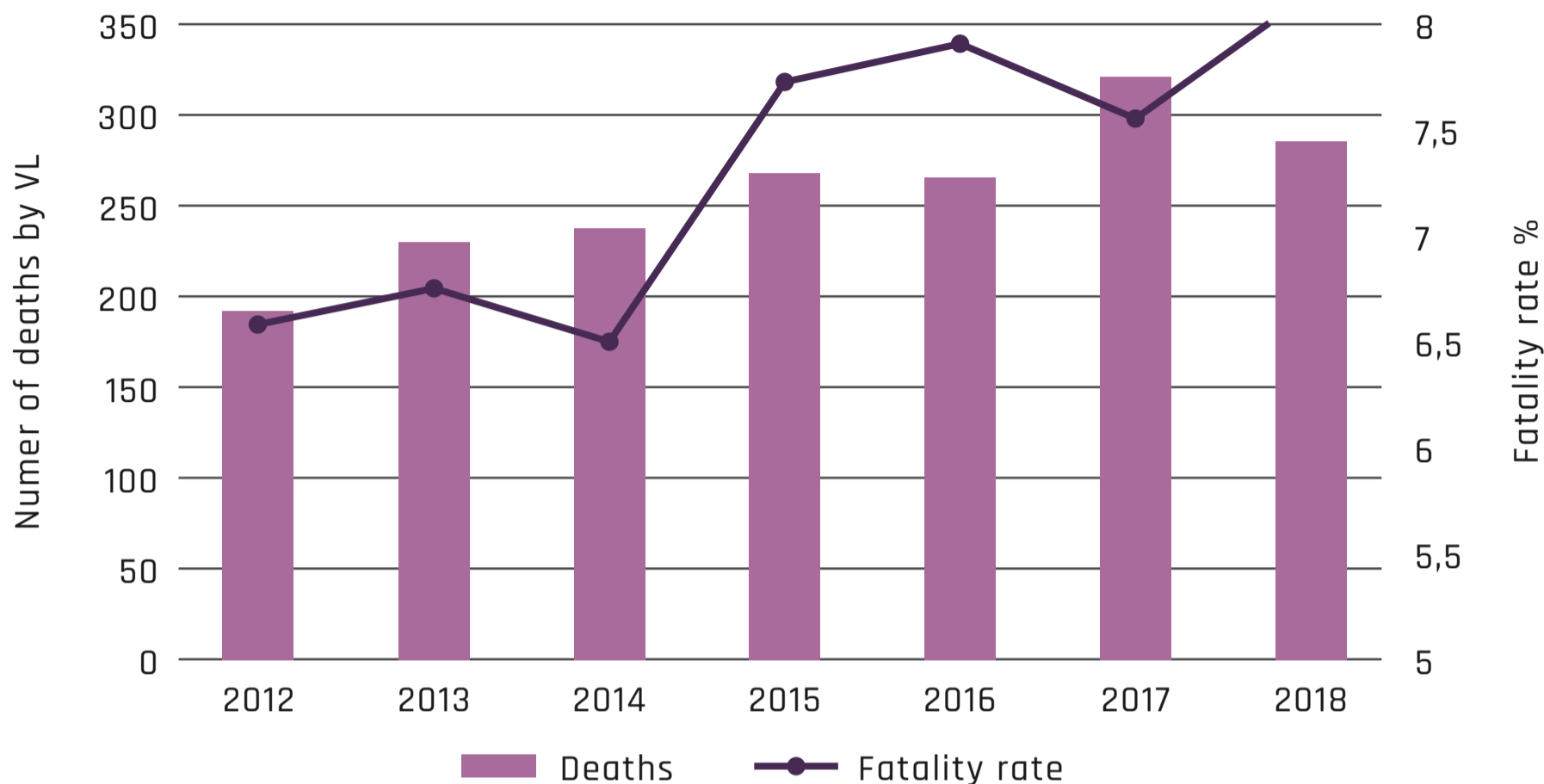
Source: SisLeish-PAHO/WHO, data reported by national leishmaniasis and surveillance programs, as of 1 October 2019



**Figure 1.35.**

Incidence of visceral leishmaniasis per 100,000 population, at the second national administrative level, Region of the Americas, 2018

Source: SisLeish-PAHO/WHO, data reported by national leishmaniases and surveillance programs, as of 1 October 2019



**Figure 1.36.**

Visceral leishmaniasis deaths and case-fatality, Region of the Americas, 2012-2018

Source: SisLeish-PAHO/WHO, data reported by national leishmaniasis and surveillance programs, as of 1 October 2019

Coinfection of visceral leishmaniasis and HIV occurred in 7% of cases; in Paraguay, this proportion was 21% of all reported cases. Annual case-fatality in 2018 was 8%. In 87.7% of reports, the criterion for confirmation was laboratory diagnosis.

Leishmaniasis control in the Americas is a commitment of the Member States, as endorsed in the *Plan of Action for the Elimination of Neglected Infectious Diseases, and Post-elimination Actions 2016-2020* (Resolution CD55.R09). However, it remains a great challenge that requires efforts by health services, professionals, health authorities, and the population in general, for surveillance, prevention, and control actions to be sustainably implemented (*Figure 1.36*).



## Recommended Reading

- Salomón OD, Feliciangeli MD, Quintana MG, Afonso MM, Rangel EF. *Lutzomyia longipalpis* urbanisation and control. Mem Inst Oswaldo Cruz. 2015;110:831-46.
- World Health Organization. Control of the leishmaniasis: Report of a meeting of the WHO Expert Committee on the Control of Leishmaniasis. Technical Report Series No. 949. Geneva: WHO; 2010.
- World Health Organization. Global leishmaniasis update, 2006-2015: A turning point in leishmaniasis surveillance. Weekly Epidemiological Record. 2017;92(38):557-72. Accessed on: 29 July 2019. Available at: <http://www.who.int/wer>.
- World Health Organization. Leishmaniasis in high-burden countries: An epidemiological update based on data reported in 2014. Weekly Epidemiological Record. 2016;91(22):285-96. Accessed on: 29 July 2019. Available at: <http://www.who.int/wer>.
- World Health Organization. Leishmaniasis: Informe Epidemiológico en las Américas: Washington: WHO; 2018. Accessed on: 29 July 2019. Available at: <https://iris.paho.org/handle/10665.2/34858>.

# CHAPTER 2

## Immunopathogenesis of Leishmaniases



María Adelaida Gómez, María del Mar  
Castro and Nancy Gore Saravia

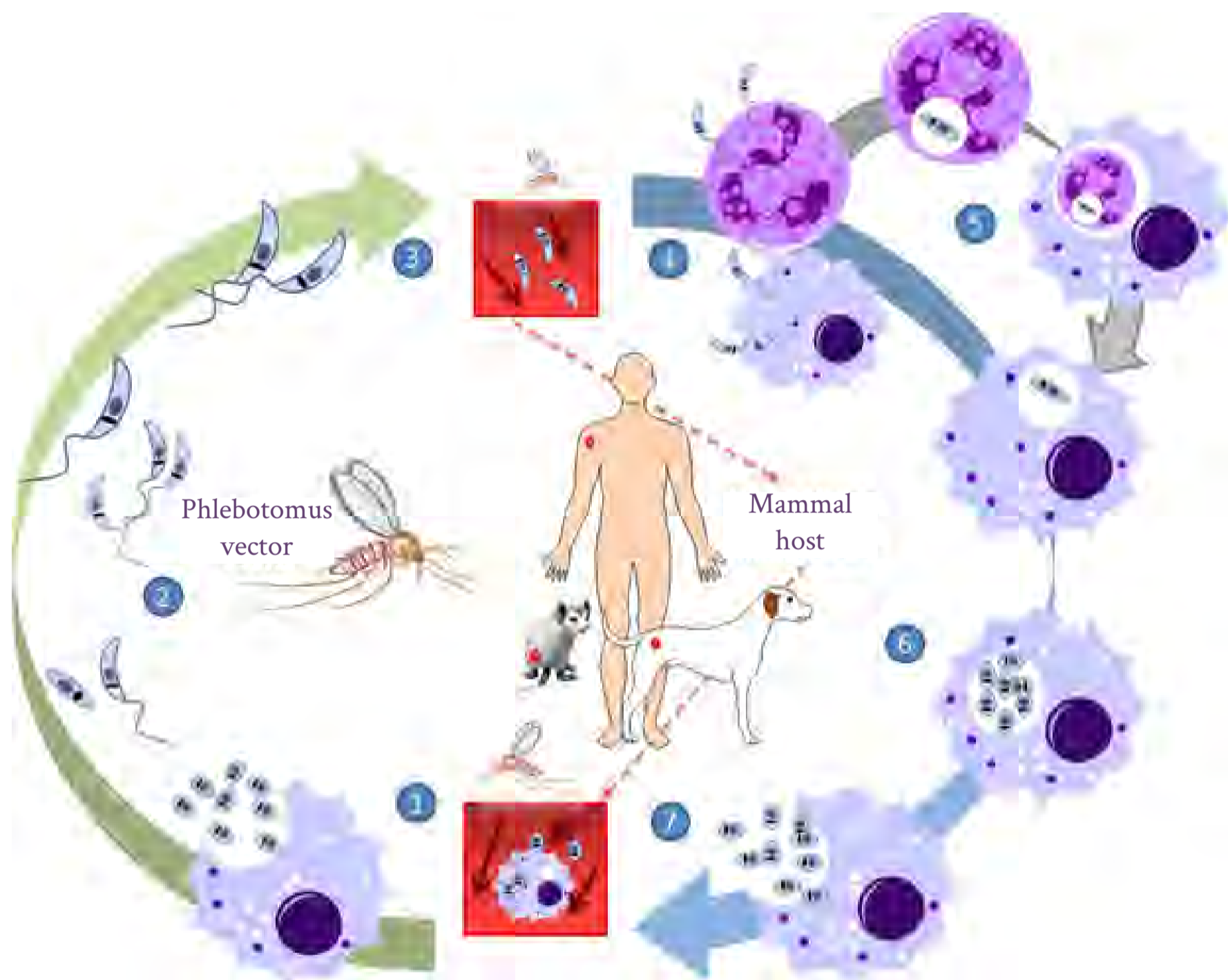
## Microbiology

During its life cycle, the parasitic protozoan *Leishmania* alternates between two stages: one in the insect vector as an extracellular flagellated promastigote and, the second, in the mammal host—including humans, dogs, and rodents—as an obligate intracellular aflagellated amastigote.

The infection is transmitted to the mammal through the bite of phlebotomine sand flies—in the Americas, from the genus *Lutzomyia* spp.—and inoculation with promastigotes, which induces recruitment of different immune cells to the infection site.

A subpopulation of metacyclic promastigotes establishes the infection upon being phagocytized, primarily by monocytes and macrophages, where they differentiate into amastigotes. Although the macrophage is considered the host cell par excellence of *Leishmania* spp., neutrophils, dendritic cells, and fibroblasts can also house the parasite.

In the host cells, amastigotes multiply by binary fission and infect new cells, by rupture and release of amastigotes, or through phagocytosis of infected cells and by membrane fusion. Sand flies acquire the parasite by biting an infected mammal and ingesting infected blood cells, thus maintaining the life cycle of *Leishmania* spp. (*Figure 2.1*).



**Figure 2.1.** Lifecycle of the *Leishmania* spp. parasite

1. The life cycle begins when uninfected female sand flies bite and take a blood meal on a parasitized mammal, acquiring infected cells or free amastigotes.
  2. Amastigotes turn into procyclic promastigotes in the vector's gut and, subsequently become metacyclic promastigotes.
  3. These migrate to the vector's proboscis and then inoculate a host mammal during the bite and blood meal.
  4. The promastigotes are phagocytized in the human host, mainly by macrophages and neutrophils recruited at the lesion site, where they become intracellular amastigotes.
  5. The infected neutrophils are subsequently phagocytized by macrophages and infection is established.
  6. The amastigotes multiply intracellularly by binary fission and the infection spreads to other cells by phagocytosis of free amastigotes or infected cells.
  7. After a subsequent sand fly bite, infected cells or free amastigotes are ingested, thus continuing the life cycle.
- Courtesy of: María Claudia Barrera, M.Sc., Research Group on Rheumatology, Autoimmunity, and Translational Medicine (GIRAT), ICESI University, Cali (Valle, Colombia)

Various species of *Leishmania* spp. from subgenera *L. (Viannia)* and *L. (Leishmania)* are the causative agents of nearly 50,000 leishmaniases cases reported annually in the Americas, where more than 90% correspond to cutaneous leishmaniasis.

*Leishmania (Viannia) braziliensis*, *L. (V.) guyanensis*, *L. (V.) panamensis*, and *L. (Leishmania) mexicana* are the principal causative agents of the disease. In some regions of Central America, *L. (L.) infantum* is the causative agent of atypical cutaneous leishmaniasis, a non-ulcerative form. In addition to causing cutaneous manifestations, infections by *L. (V.) braziliensis*, *L. (V.) guyanensis*, and *L. (V.) panamensis* may result in mucosal leishmaniasis and account for approximately 4% of reported cases.

*Leishmania (L.) infantum* is the causative agent of visceral leishmaniasis in the Region of the Americas, where there are more than 3,000 cases annually, the vast majority in Brazil.

## Pathogenesis

The specter of infection and disease caused by *Leishmania* spp. in the Americas ranges from inapparent infection, single localized skin lesions, and some that resolve without treatment up to chronic and recurring manifestations, such as those of mucosal leishmaniasis or diffuse cutaneous leishmaniasis, and potentially fatal disorders such as visceral leishmaniasis.

The variability of clinical phenotype during natural infection and the lack of experimental models that could help explain the spectrum of clinical presentations have limited identification of factors, in both the host and parasite, that determine pathogenesis and its association with clinical phenotype.

Clinical presentation is closely related to the presence of *Leishmania* spp. in different tissues or organs. However, virulence factors that trigger and determine its severity have not been totally elucidated.

## Cutaneous and mucosal leishmaniasis

Infected tissue macrophages are the source of infection and starting point for the different types of skin lesions. Those transported by the lymphatic or hematogenic route give rise to staggered, nodular, papular, or ulcerated skin lesions; regional lymphadenitis and adenopathies (common among the early clinical manifestations of cutaneous leishmaniasis); in addition to distal skin lesions and, in some cases, damage to the nasal and buccopharyngeal mucosa (*Figures 2.2*).

The presence of *Leishmania* spp. in mucosal tissues is frequent and detectable from the early stages of symptomatic infection and also during inapparent infection without evident tissue involvement. The parasite can persist in the nasopharyngeal mucosa after clinical cure, which suggests that mucosal leishmaniasis is triggered by an inflammatory reaction or an imbalance in immunological homeostasis.

Figures 2.2. Clinical manifestation of the cutaneous and mucosal or mucocutaneous leishmaniasis in the Americas

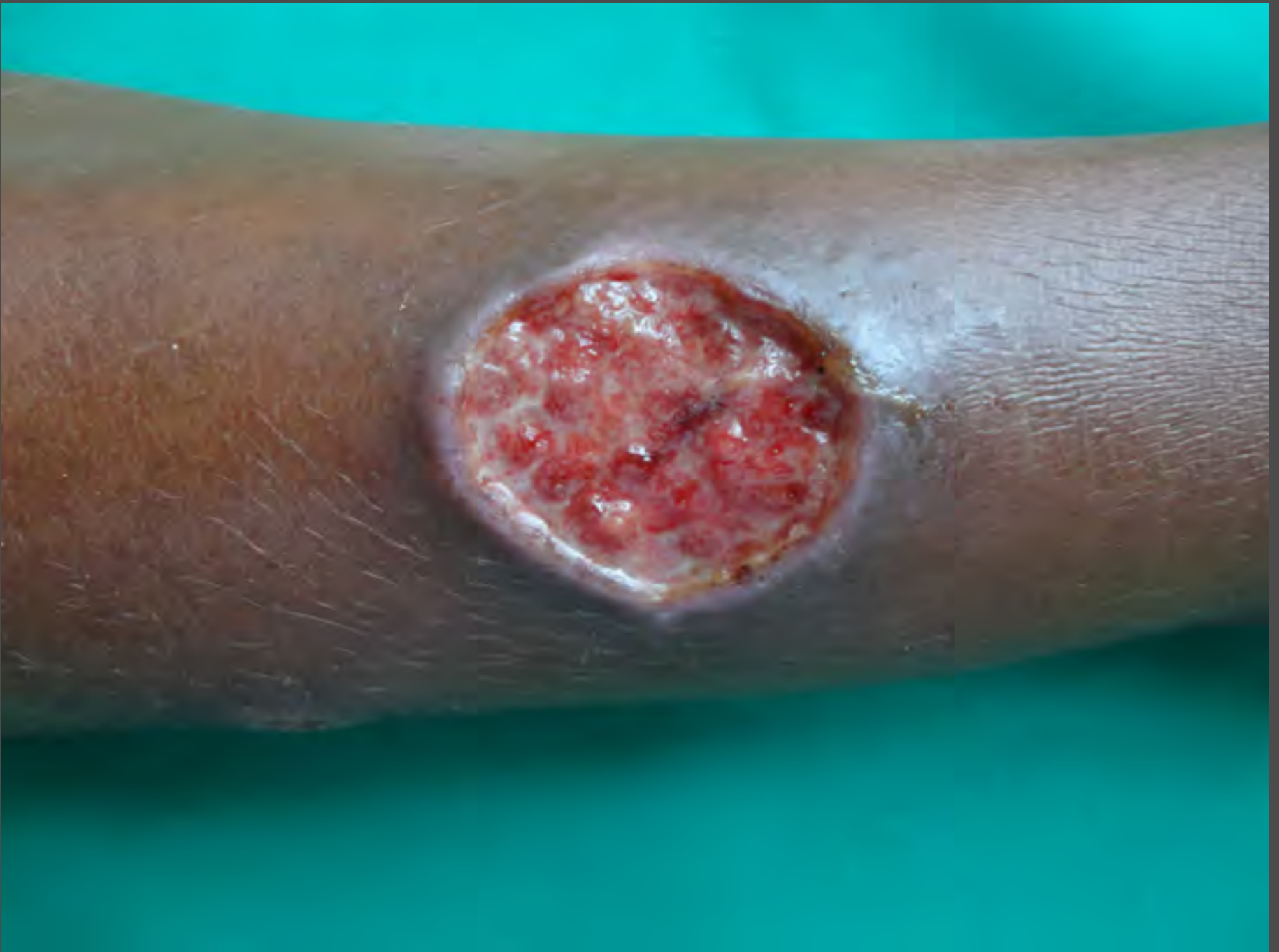
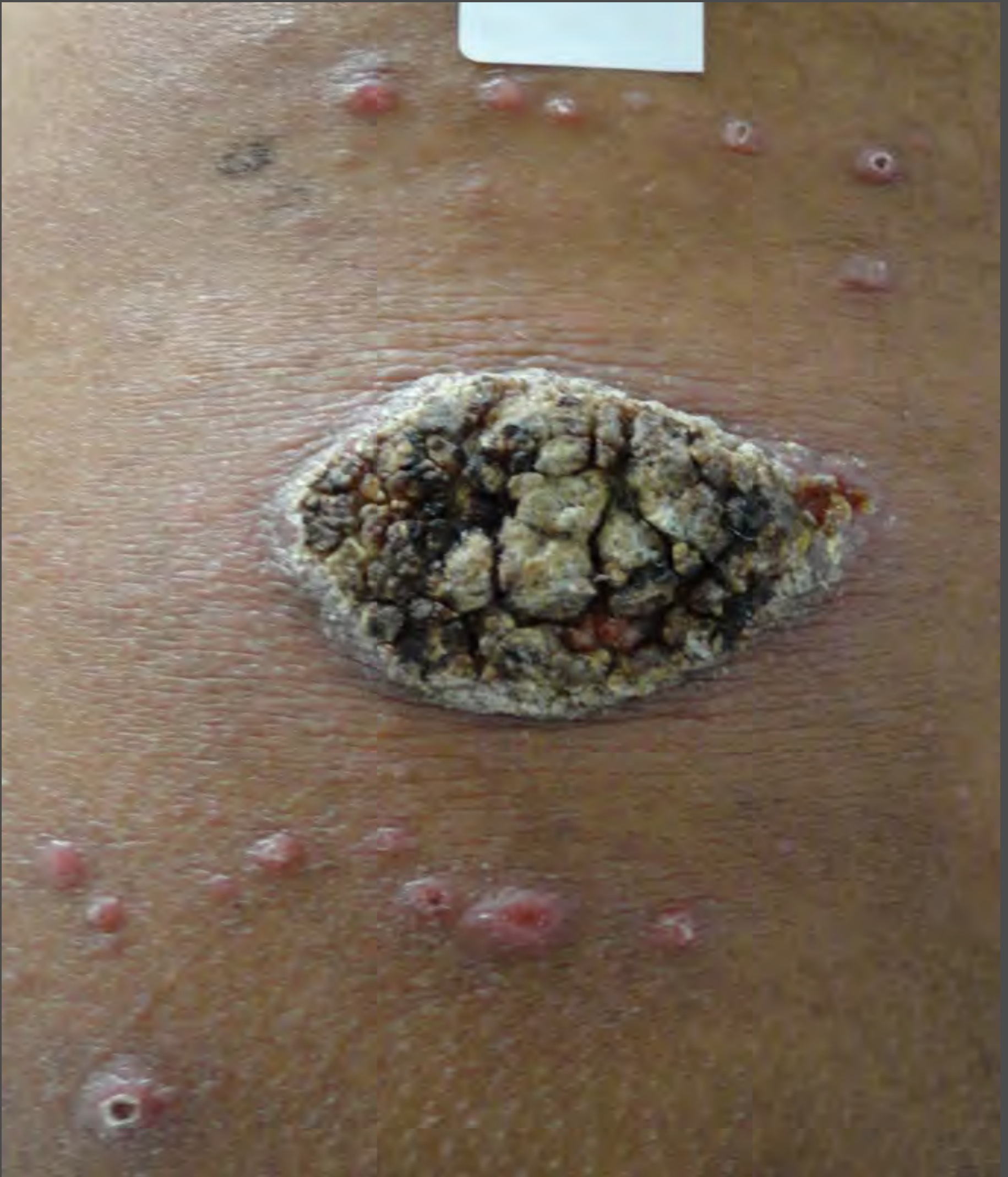
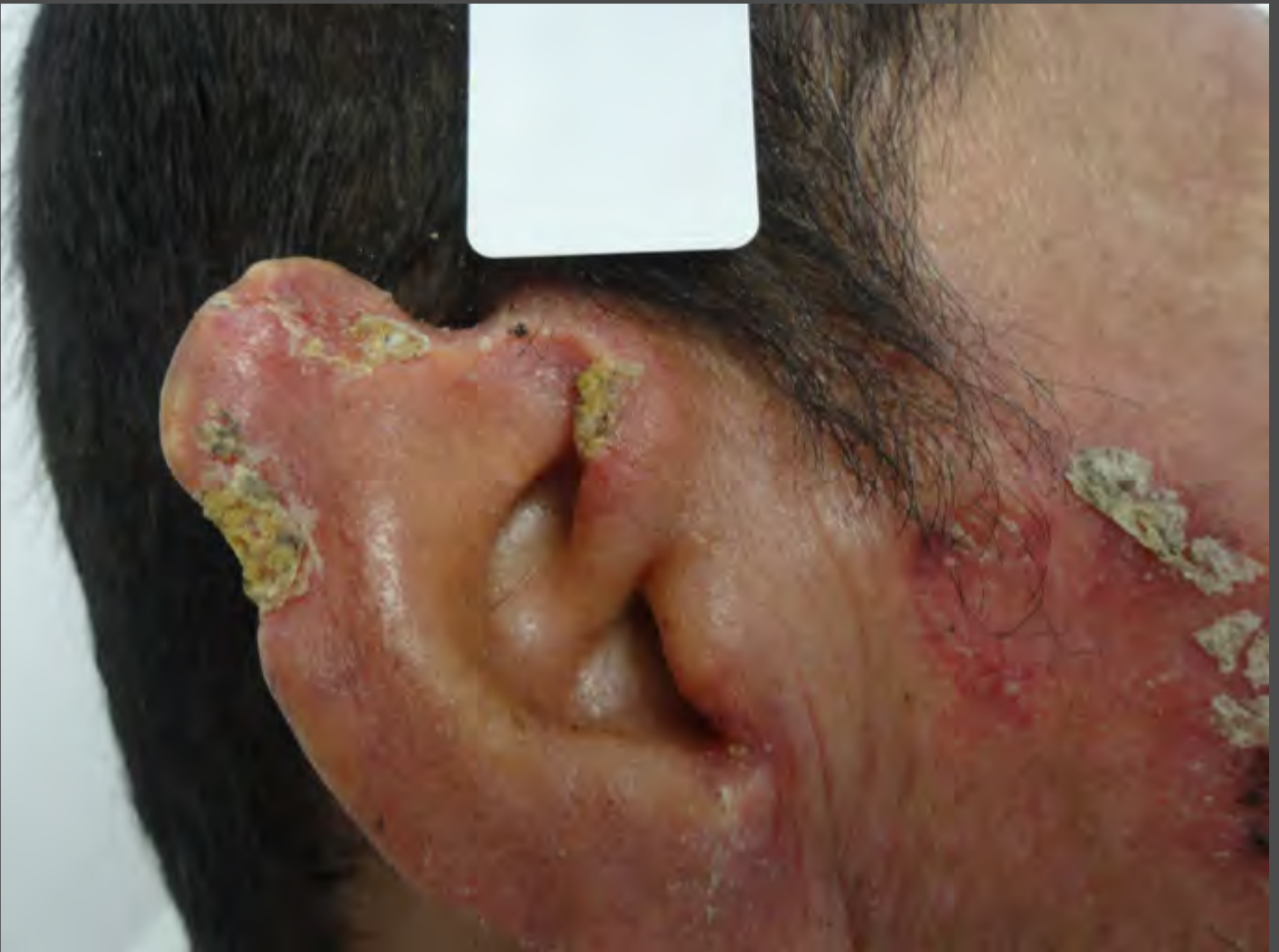Figure 2.2A.  
Cutaneous leishmaniasis: classic lesion

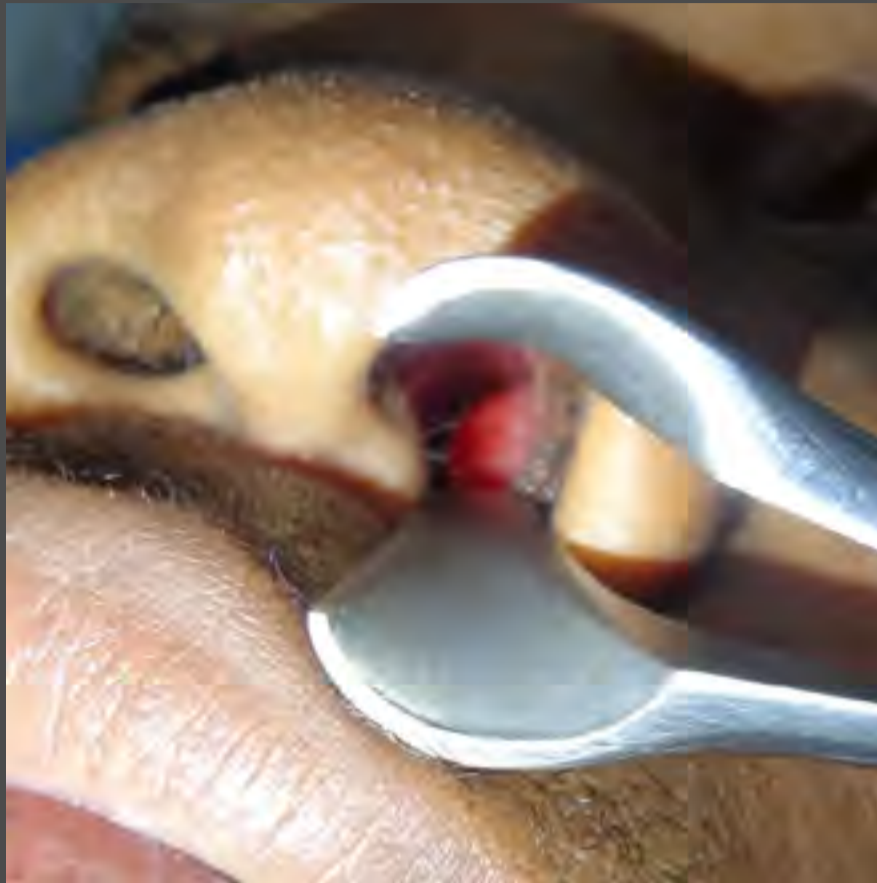



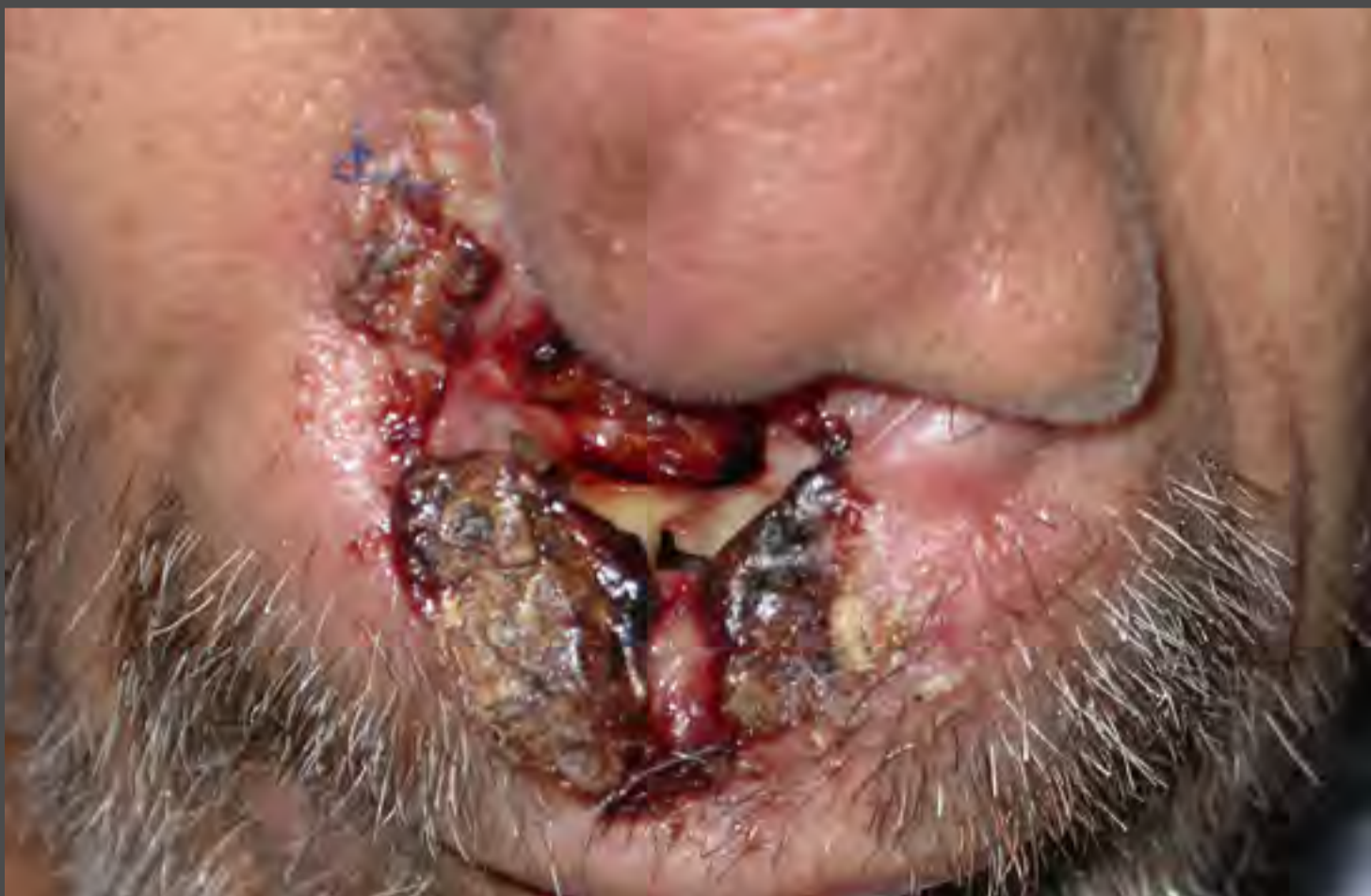**Figure 2.2B.**  
Cutaneous leishmaniasis: crusted lesion with satellite papules



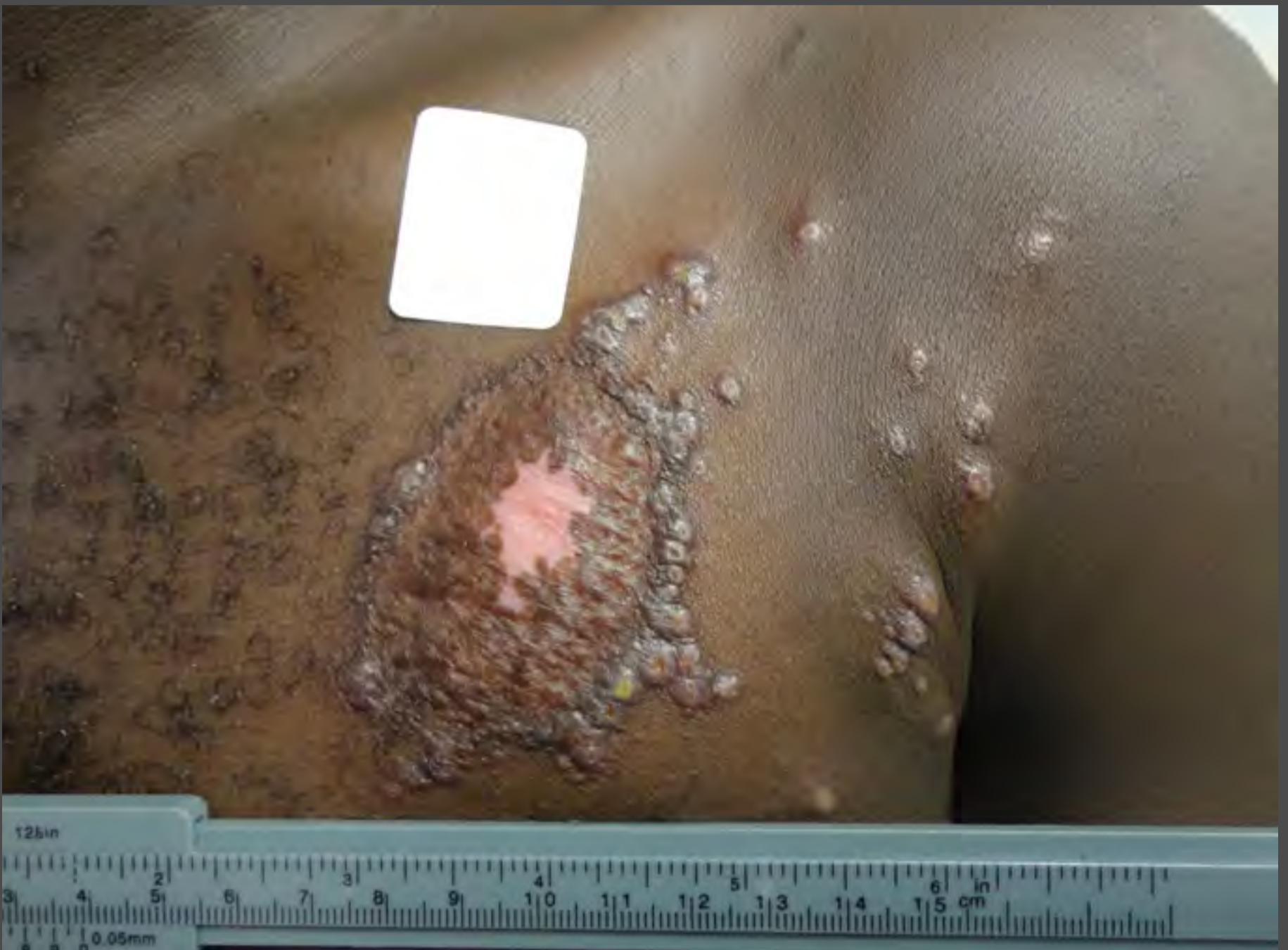**Figure 2.2C.**  
Cutaneous leishmaniasis: destruction of the outer rim of the ear



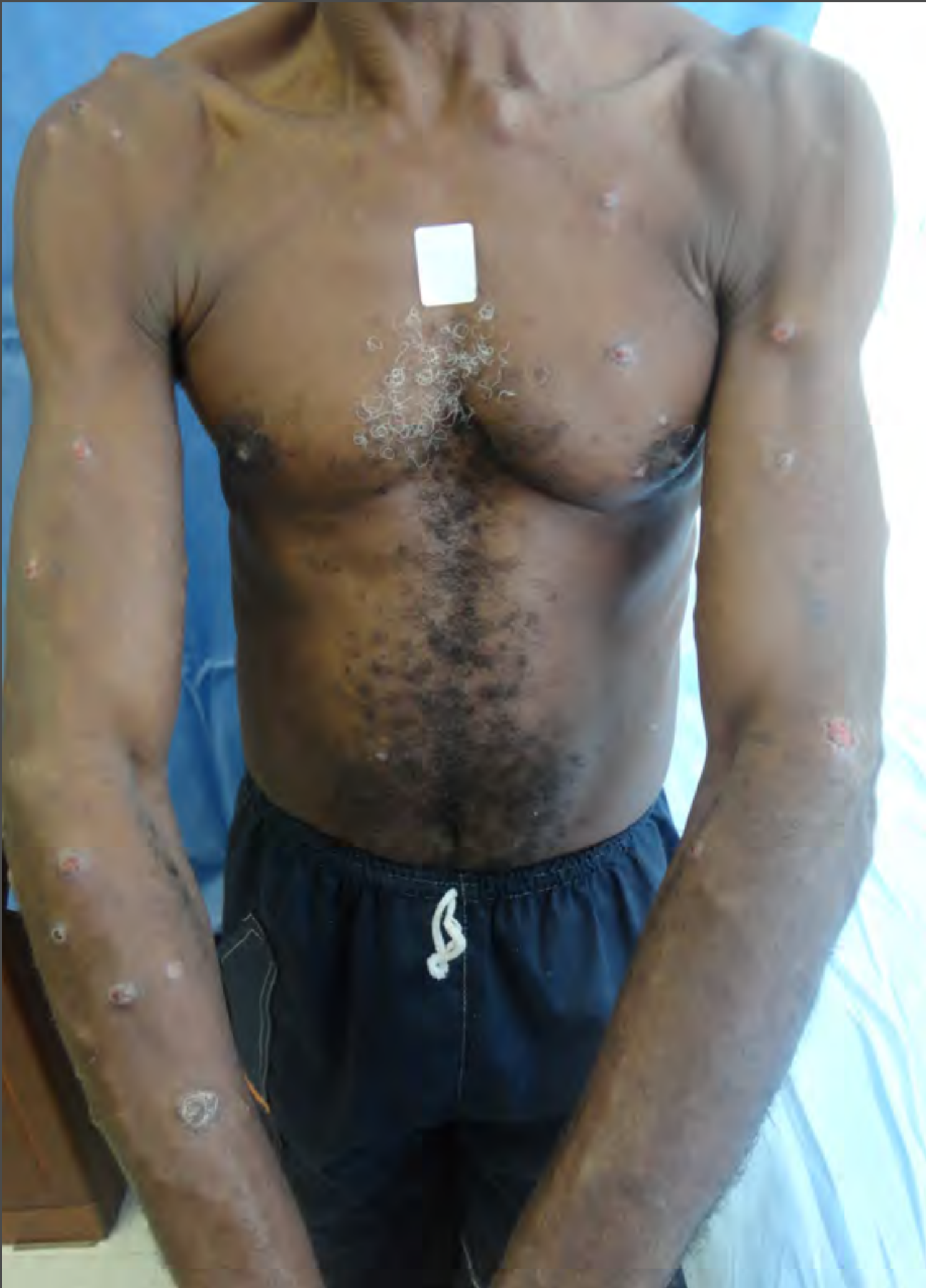**Figure 2.2D.**  
Excoriation and edema in the lower nasal turbinate  
of a patient with mucosal leishmaniasis



**Figure 2.2E.**  
Mucosal leishmaniasis: destruction of the nasal ala, septum,  
columella, and upper lip



**Figure 2.2F.**  
Cutaneous leishmaniasis: recidiva cutis, scar with active edge, and satellite papules



**Figure 2.26.**  
Multiple skin lesions on a patient with disseminated cutaneous leishmaniasis

## Visceral leishmaniasis

In the Americas, *L. (L.) infantum* is the causative species of visceral leishmaniasis. After the infection spreads to spleen and liver histiocytes (“visceralization”), parasite proliferation results in infiltration of the bone marrow, hepatosplenomegaly, and lymphadenopathies.

Reticuloendothelial hyperplasia of the spleen, liver, bone marrow, lymph nodes, and other lymphoid tissues occurs, with the consequent impairment in the production and life span of leukocytes and erythrocytes, which leads to anemia and granulocytopenia.

Symptoms such as fever, fatigue, and weakness, among others, are associated with persistent systemic infection and hematological changes such as anemia and thrombocytopenia. Infections and other concomitant diseases may occur, which may involve complications and even death.

## Asymptomatic infection

The pathogenic capacity of infections caused by different *Leishmania* species, reflected in the proportion of symptomatic and subclinical infections, varies between countries and even between different areas in a single country. Although its frequency is unknown, Brazil has reported Figures from 17% to 91% for subclinical infection in endemic areas for cutaneous leishmaniasis transmission, and more than 80% for visceral leishmaniasis.

The effectiveness of the cellular immunity reaction is essential to controlling the infection, and the immunological inflammatory response determines the pathogenesis of clinical manifestations. Some host factors, such as malnutrition, age, HIV coinfection, bacterial infections, or bleeding, among others, have been associated with greater risk of developing severe disease, which suggests that immunological equilibrium contributes to natural resistance or susceptibility to the disease. Changes in this equilibrium can turn asymptomatic into symptomatic leishmaniasis or reactivate the infection.

## Immunological Response

Characteristics of the parasite and the host, the saliva of the sand fly, and the inoculated parasite load are factors that contribute to different clinical manifestations and disease severity. Either an excessive or deficient immunological reaction can increase the severity of clinical manifestations. An exaggerated cellular immunological response and low parasite loads are common in mucosal leishmaniasis and in chronic skin lesions. In contrast, high parasite load and a limited cellular immunological response with major antibody concentrations are characteristic of diffuse cutaneous leishmaniasis, another serious form of the disease.

Innate immune response, such as the production of reactive oxygen species and nitric oxide, play an important role in initial elimination of the parasite, meaning there can be infection without disease. However, the genus *Leishmania* can evade the early immunological response. As it persists and disseminates, the disease is triggered.

Phagolysosome maturation, inflammatory mediator production, oxidative and nitrous radical synthesis, among other factors, are modulated for the intracellular survival of the parasite. Infection with *Leishmania* spp. modulates early expression of cytokines, chemokines, and their receptors, mediating host cell recruitment and facilitating establishment of the infection.



Studies of cutaneous leishmaniasis caused by *L. major* using mouse models have shown that polarized Th1 responses lead to resistance to infection, and Th2 responses to susceptibility to infection. However, this dichotomy does not determine the clinical outcome of human infection in the Americas.

Spontaneous clinical remission of the disease has been associated with strong, limited, T-cell activation, poor antibody response, and proinflammatory chemokine induction. In contrast, a hyperimmune reaction accompanied by overproduction of proinflammatory and anti-inflammatory cytokines contributes to tissue damage and to progression and chronicity of the mucosal and cutaneous forms of the disease. Although regulatory T cells have been implicated in this uncontrolled inflammatory response, it is not known what mechanisms are involved in cellular recruitment at the site of the lesion and in maintaining hyperimmune activation during the infection.

Recently, the contribution of neutrophils in pathogenesis and persistence of *Leishmania* spp. infection has become evident. Neutrophils are among the first host cells recruited at the site of the bite and infection, which rapidly phagocytize inoculated promastigotes.

Experimental studies suggest that involvement of neutrophils in the clinical course of the infection can help to protect against the disease or facilitate its development and, in addition, that the result of the interaction between parasite and neutrophils varies according to the *Leishmania* species.

Nevertheless, instead of being rapidly destroyed by neutrophils, most *Leishmania* species resist or evade their antimicrobial activity, which facilitates the parasite's silent access to macrophages and favors establishment of the infection in humans.

## Recommended Reading

- Chappuis F, Sundar S, Hailu A, Ghalib H, Rijal S, Peeling RW, *et al.* Visceral leishmaniasis: What are the needs for diagnosis, treatment and control? *Nat Rev Microbiol.* 2007;5:873-82.
- Hurrell BP, Regli IB, Tacchini-Cottier F. Different *Leishmania* species drive distinct neutrophil functions. *Trends Parasitol.* 2016;32:392-401.
- Kaye P, Scott P. Leishmaniasis: Complexity at the host-pathogen interface. *Nat Rev Microbiol.* 2011;9:604-15.
- Martínez-Valencia AJ, Daza-Rivera CF, Rosales-Chilama M, Cossio A, Casadiego EJ, Desai MM, *et al.* Clinical and parasitological factors in parasite persistence after treatment and clinical cure of cutaneous leishmaniasis. *PLoS Negl Trop Dis.* 2017;11:e0005713. doi: 10.1371/journal.pntd.0005713.
- Murray HW, Berman JD, Davies CR, Saravia NG. Advances in leishmaniasis. *Lancet.* 2005;366:1561-77.
- Pan American Health Organization. Leishmaniasis: Epidemiological report of the Americas. Washington, D.C.: PAHO; 2018.
- Scott P, Novais FO. Cutaneous leishmaniasis: Immune responses in protection and pathogenesis. *Nat Rev Immunol.* 2016;16:581-92.
- Weigle K, Saravia NG. Natural history, clinical evolution, and the host-parasite interaction in New World cutaneous leishmaniasis. *Clin Dermatol.* 1996;14:433-50.

# CHAPTER 3

## Cutaneous Leishmaniasis



Clemencia Ovalle-Bracho, Carlos Arturo Hernández, Ana Nilce Silveira Maia-Elkhoury, Sandra Muvdi-Arenas, Claudia Arenas, Gerzaín Rodríguez, Paulo Roberto Lima Machado, Jackson Mauricio Lopes Costa, Carolina Camargo and Jaime Soto

Cutaneous leishmaniasis is an infectious disease that affects the skin. It has a widely varied clinical spectrum that depends on the interaction of several factors: age, nutritional status, immunological response, host genetic susceptibility, infective species, vector, dose, and inoculation site. There are four clinical forms: localized cutaneous leishmaniasis, disseminated cutaneous leishmaniasis, diffuse anergic cutaneous leishmaniasis, and atypical cutaneous leishmaniasis.

Recently, a growing group of patients has been observed with clinical manifestations different from classical descriptions of cutaneous leishmaniasis. In general, the disease begins with multiple lesions of various clinical appearances, which may simultaneously involve the skin and mucous membranes. It has no defined immunological pattern, and response to different drugs is partial; relapse is the norm and it constitutes a clinical form that could be called chronic relapsing cutaneous leishmaniasis.

## Localized Cutaneous Leishmaniasis

### Definition, agents, vectors, and reservoirs

Localized cutaneous leishmaniasis is caused by multiple species of parasites of the genus *Leishmania*. In the Region of the Americas, 15 *Leishmania* species have been described as causative agents of cutaneous leishmaniasis, of which the taxonomic status or position of three is under discussion. Of the species described, the following belong to subgenus *Viannia*: *L. braziliensis*, *L. guyanensis*, *L. panamensis*, *L. shawi*, *L. naiffi*, *L. lainsoni*, *L. lindenbergi* and *L. peruviana* and the following belong to subgenus *Leishmania*: *L. mexicana*, *L. pifanoi*, *L. venezuelensis*, *L. garnhami*, *L. amazonensis* and *L. infantum*. Furthermore, *L. colombiensis* has been described. Some species are more frequently associated with certain clinical manifestations; however, there are no unique associations. The presence of species varies in each country and knowing their distribution is important to surveillance and control of the disease.

In the Americas, the vectors are phlebotomine insects of the order Diptera, family Psychodidae, subfamily Phlebotominae, and genus *Lutzomyia*. Some vectors can be associated with a single type of *Leishmania*; however, a species can be transmitted by different vectors. Nearly 50 species of vectors been implicated in the cycle of transmission of cutaneous leishmaniasis in the Region. The main ones are: *Lu. ayrozai*, *Lu. anduzei*, *Lu. anthophora*, *Lu. ayacuchensis*, *Lu. amazonensis*, *Lu. carrerai carrerai*, *Lu. complexa*, *Lu. columbiana*, *Lu. cruciata*, *Lu. diabolica*, *Lu. edwards*, *Lu. evansi*, *Lu. flaviscutellata*, *Lu. gomezi*, *Lu. hartmani*, *Lu. intermedia*, *Lu. neivai*, *Lu. migonei*, *Lu. nunez tovari*, *Lu.*

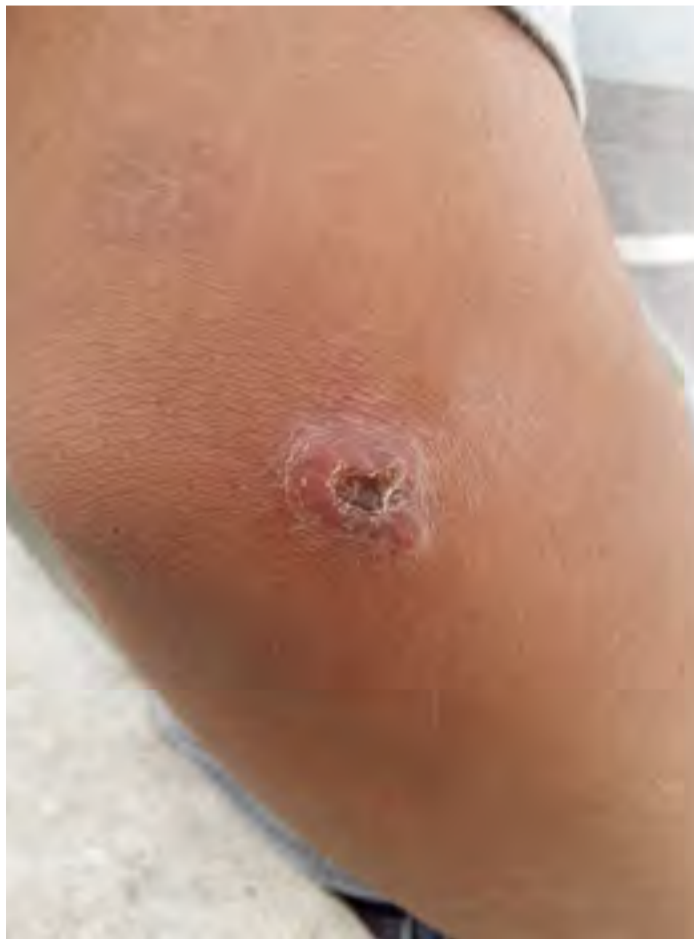*ovallesi*, *Lu. olmeca olmeca*, *Lu. paraensis*, *Lu. pia*, *Lu. panamensis*, *Lu. peruensis*, *Lu. pescei*, *Lu. reducta*, *Lu. shawi*, *Lu. squamiventris*, *Lu. spinicrasa*, *Lu. shannoni*, *Lu. sanguinaria*, *Lu. towsendi*, *Lu. trapidoi*, *Lu. tejadai*, *Lu. trinidadensis*, *Lu. umbratilis*, *Lu. ubiquitalis*, *Lu. verrucarum*, *Lu. wellcomei*, *Lu. whitmani*, *Lu. yucumensis*, *Lu. yuilli*, *Lu. youngi* and *Lu. ylephiletor*.

Multiple reservoirs—confirmed and assumed—have been implicated in the life cycle of the parasite that causes cutaneous leishmaniasis. They can be classified as domestic, peridomestic, and wild. Wild reservoirs are known for maintaining the infection for a long time without suffering from the disease and harbor abundant amounts of parasites in the skin.

The following have been described as wild reservoirs: non-domesticated canids, sloths (*Choloepus didactylus*, *Choloepus hoffmani*, *Bradypus griseus*), anteater (*Tamandua tetradactyla*), opossums (*Didelphis albiventris* and *Didelphis marsupialis*) and rodents (*Oryzomys*, *Nectomys* and *Dasyprocta*, *Proechimys guyanensis*, *Proechimys cuvieri*, *Akodon*, *Bolomys*, *Nectomys* and *Rattus*). In some transmission cycles, dogs may act as a potential reservoir.

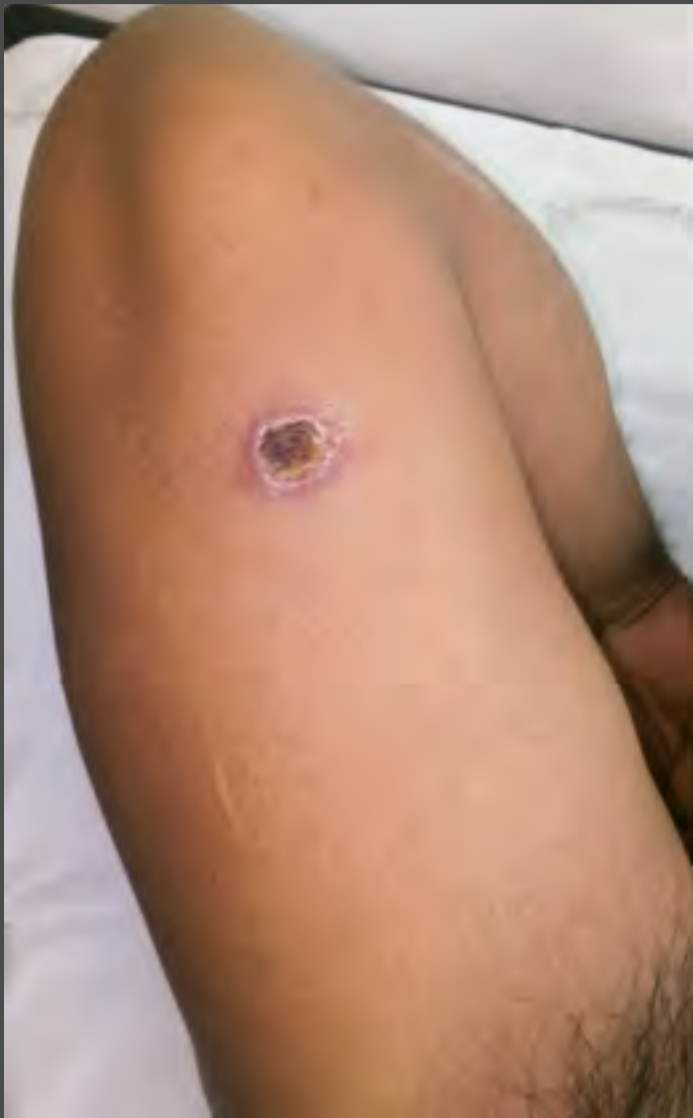## Clinical manifestations

Localized cutaneous leishmaniasis can present as one or multiple skin lesions (in general, up to 10 lesions). Uncovered areas of the skin are the most affected; 70% to 76% of lesions involve the arms (*Figures 3.1 to 3.41*) and legs (*Figures 3.42 to 3.84*), 20% to 22% affect the face and neck (*Figures 3.85 to 3.115*), and the rest affect the trunk (*Figures 3.116 to 3.131*). Lesions are rarely seen on the palms of the hands, soles of the feet, or scalp. Sometimes, lesions may heal spontaneously, but they normally follow their clinical course, making administration of specific treatment necessary. In other cases, they may become a warty plaque, with raised edges covered with scales or crusts.

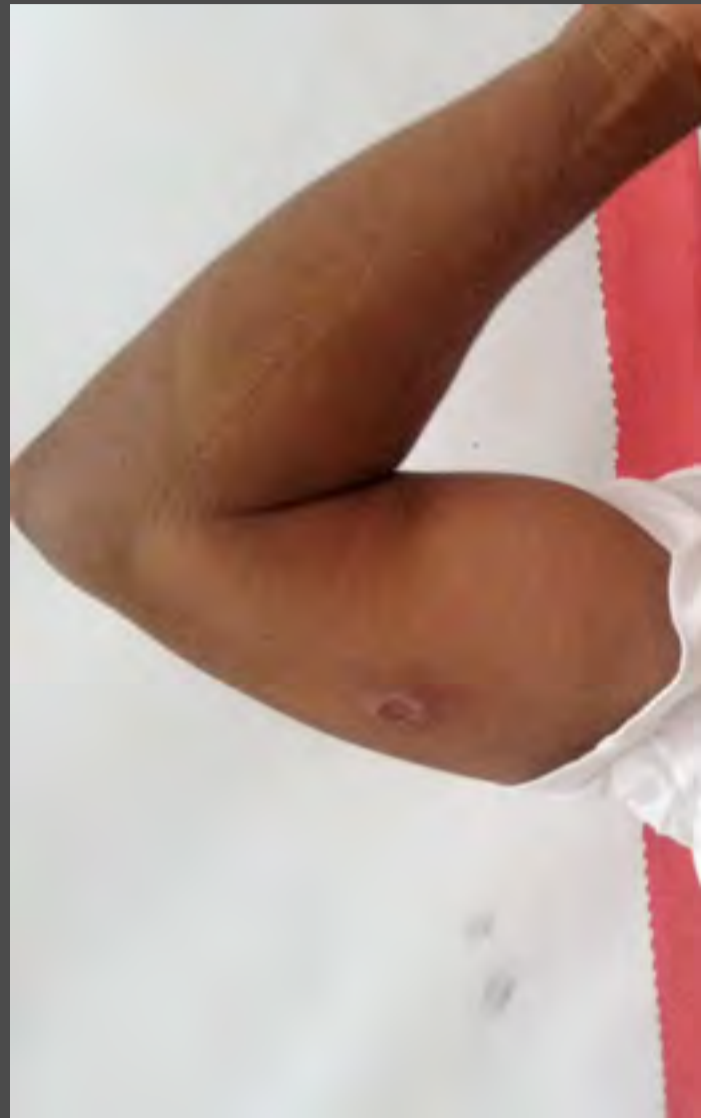

**Figure 3.1.**  
Ulcer 15 mm in diameter with raised edges and considerable perilesional infiltration

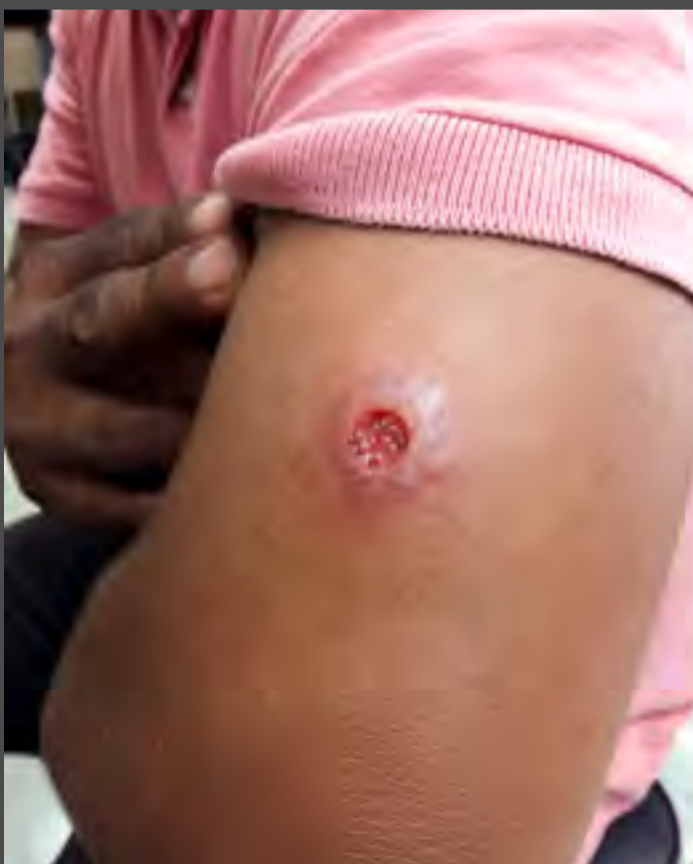



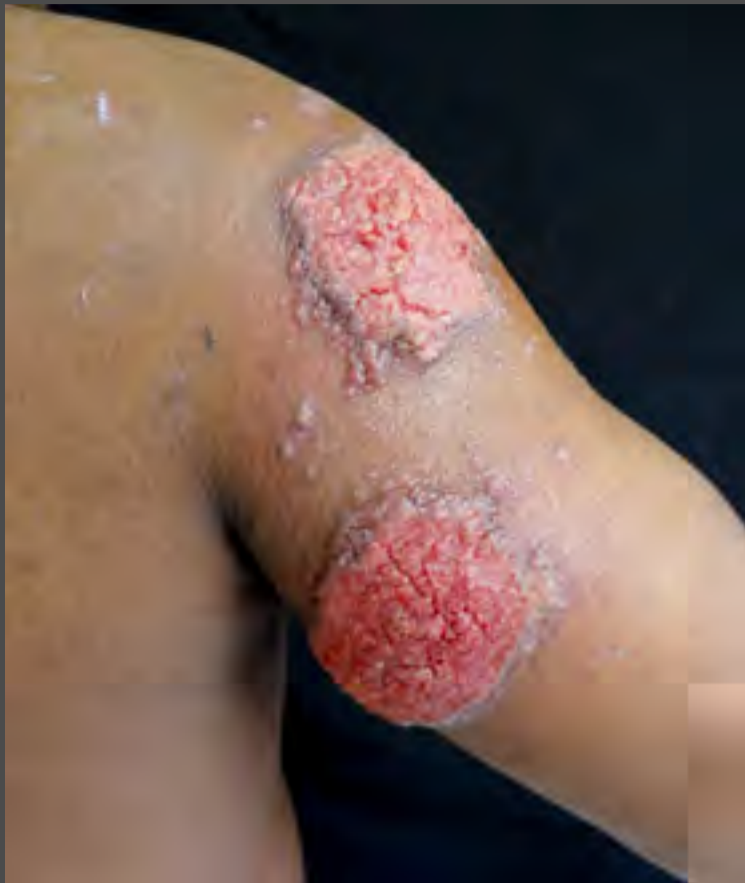**Figure 3.2.**  
Ulcer 25 mm in diameter covered in  
serosanguineous scabs



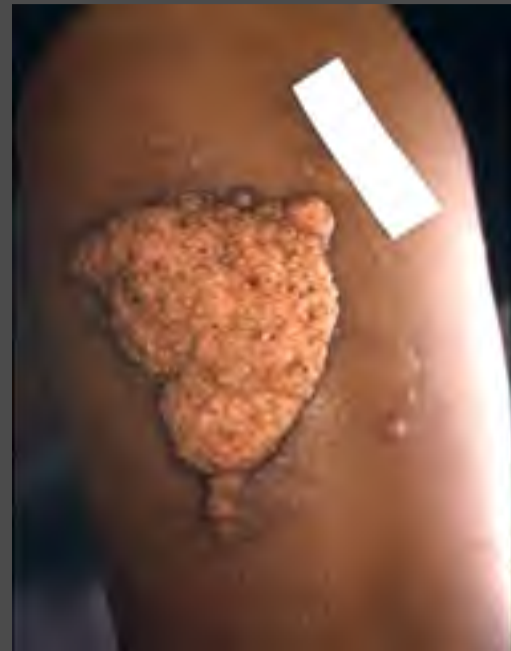**Figure 3.3.**  
Lesion 2 cm on right arm



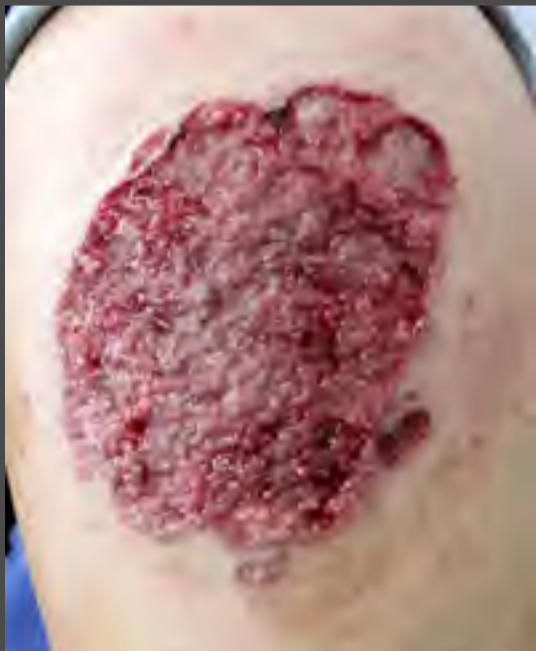**Figure 3.4.**  
Crateriform ulcer 1.5 cm in diameter on  
extensor surface of left arm



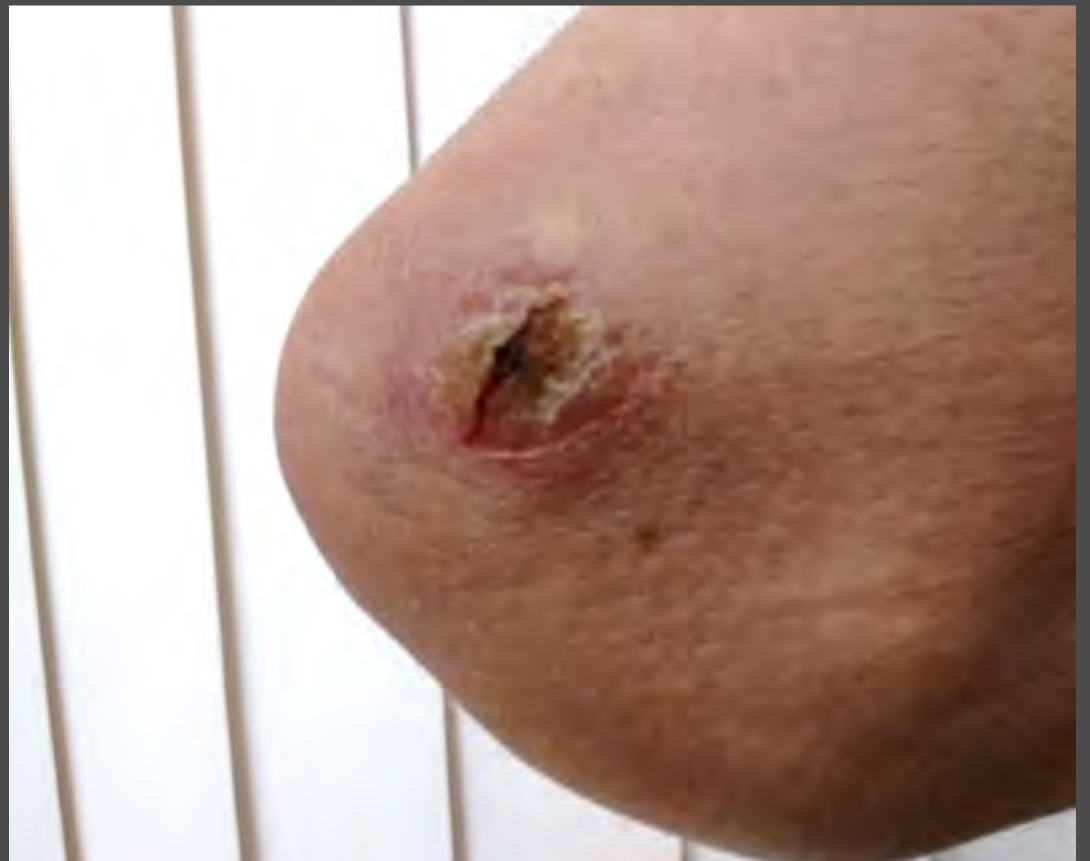**Figure 3.5.**  
Verrucous plaques with exuberant granulation tissue extending above the skin's surface; presence of some nearby satellite papules



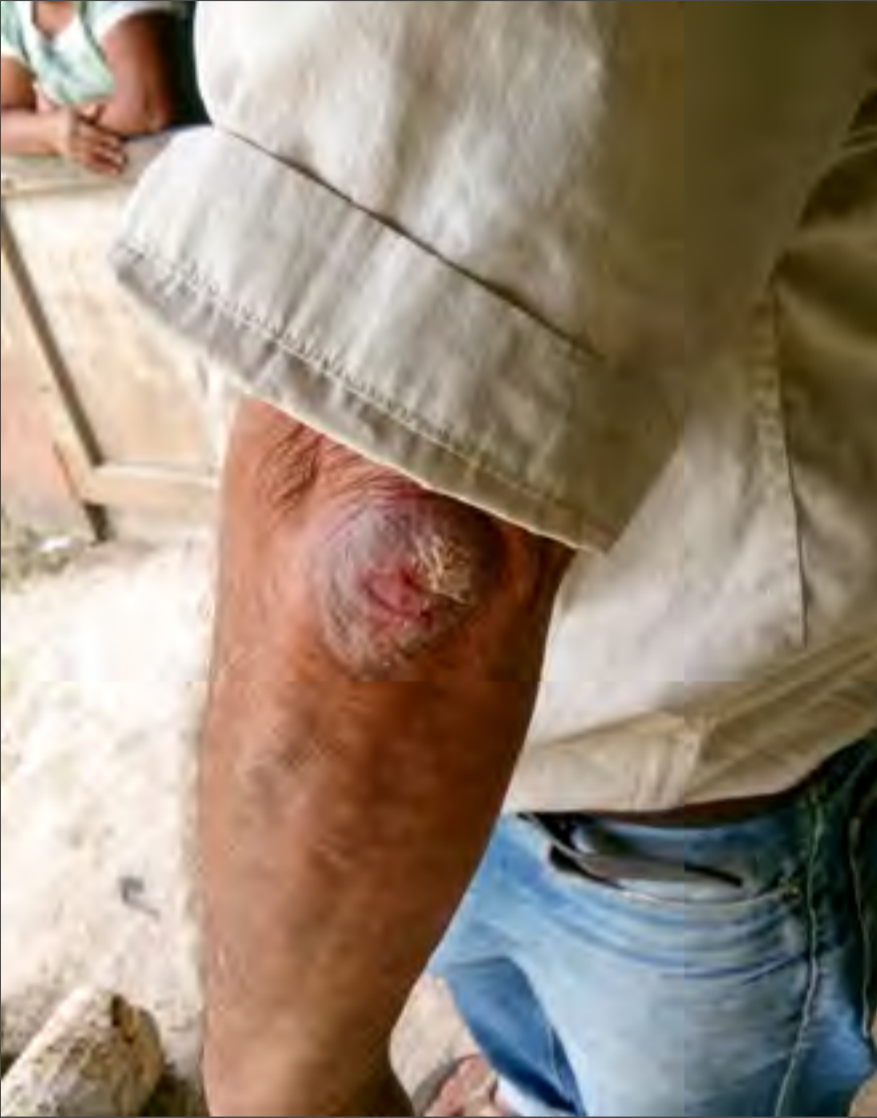**Figure 3.6.**  
Verrucous plaque on the upper arm of a pregnant woman



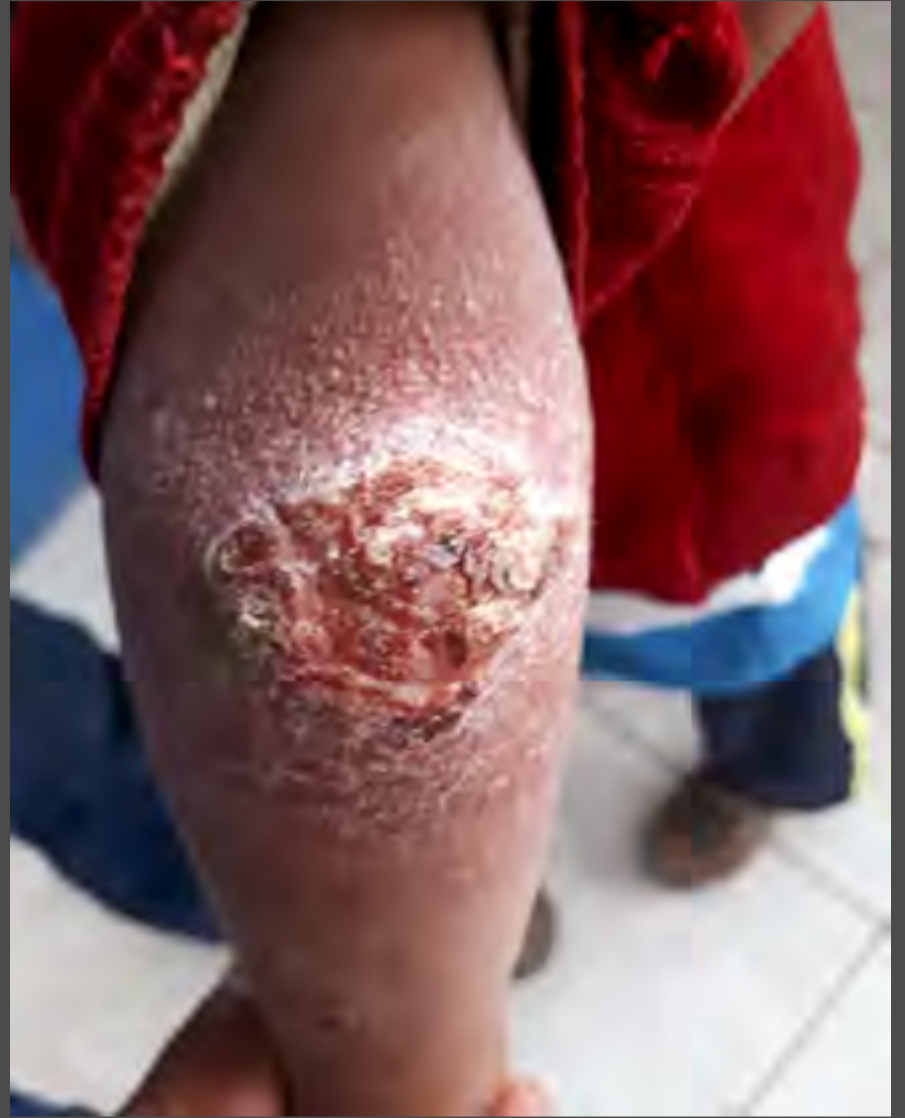**Figure 3.7.**  
Ulcerated verrucous-like lesion on left thigh



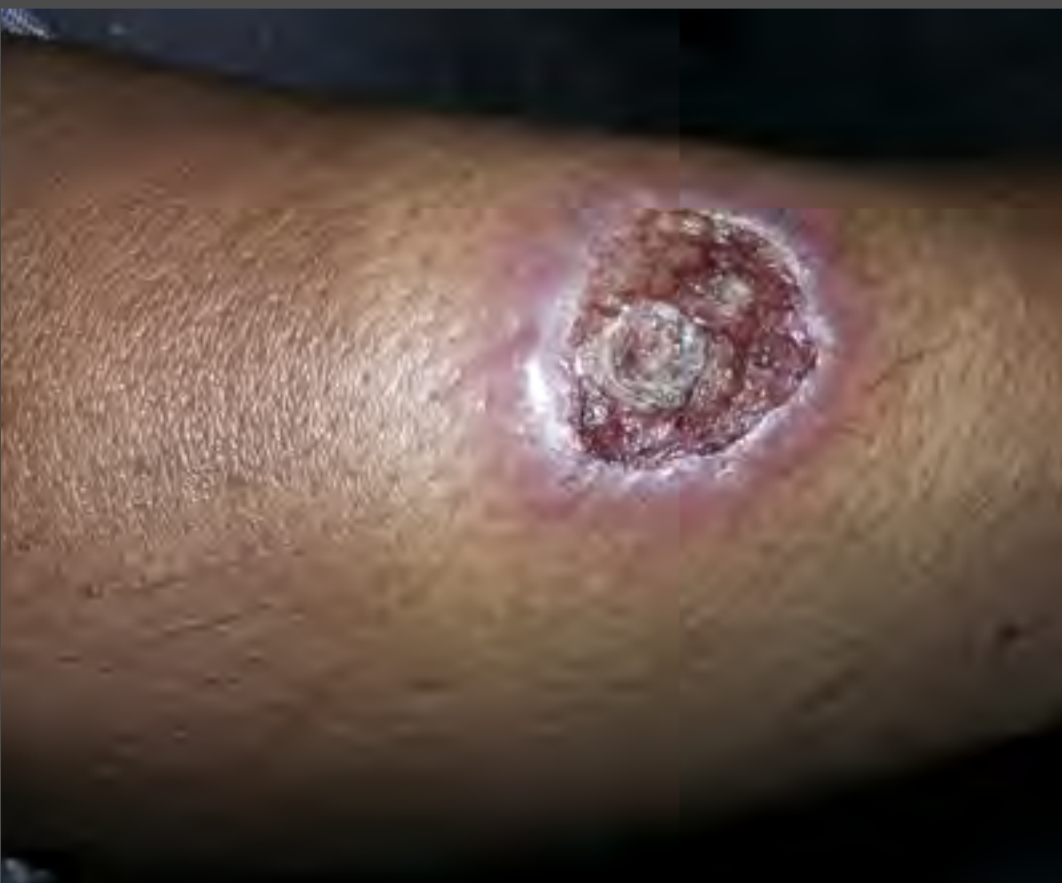**Figure 3.8.**  
Lesion on right elbow following treatment (*Leishmania (L.) mexicana*)



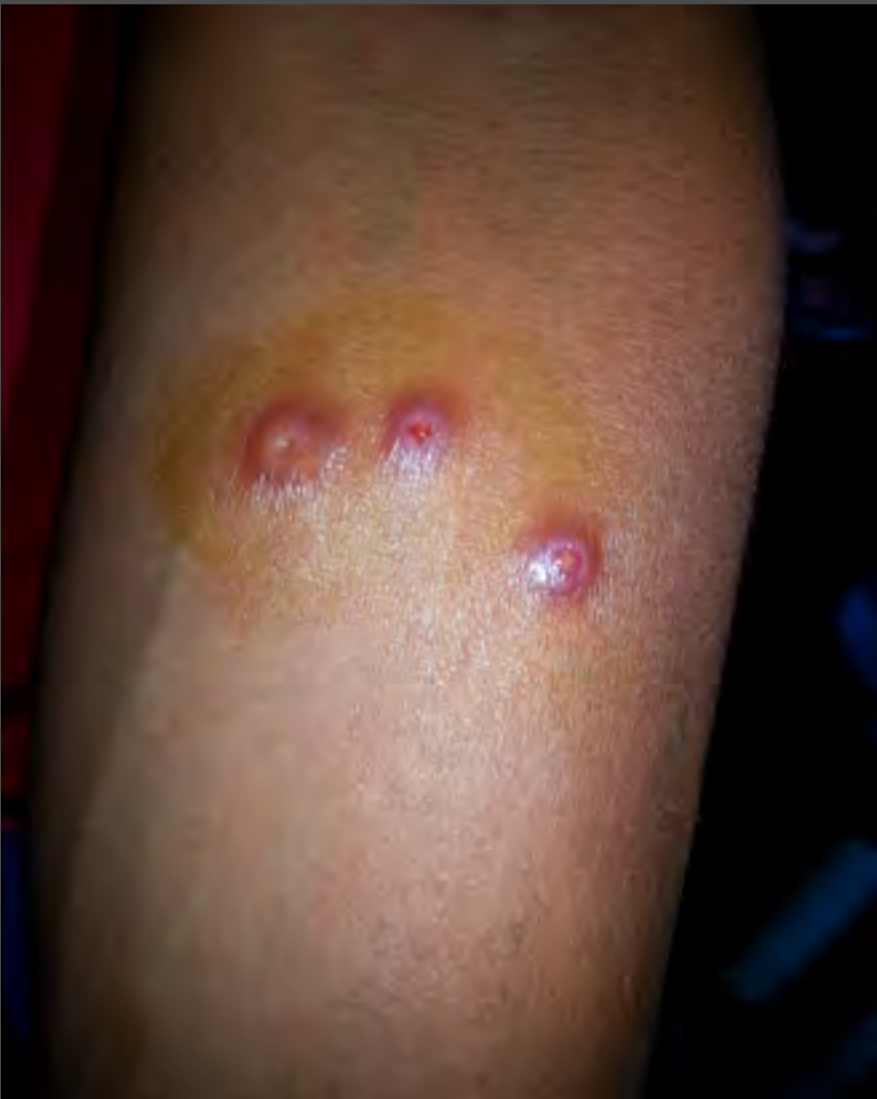**Figure 3.9.**  
Ulcer 4 cm in diameter on left elbow, surrounded by considerable infiltration



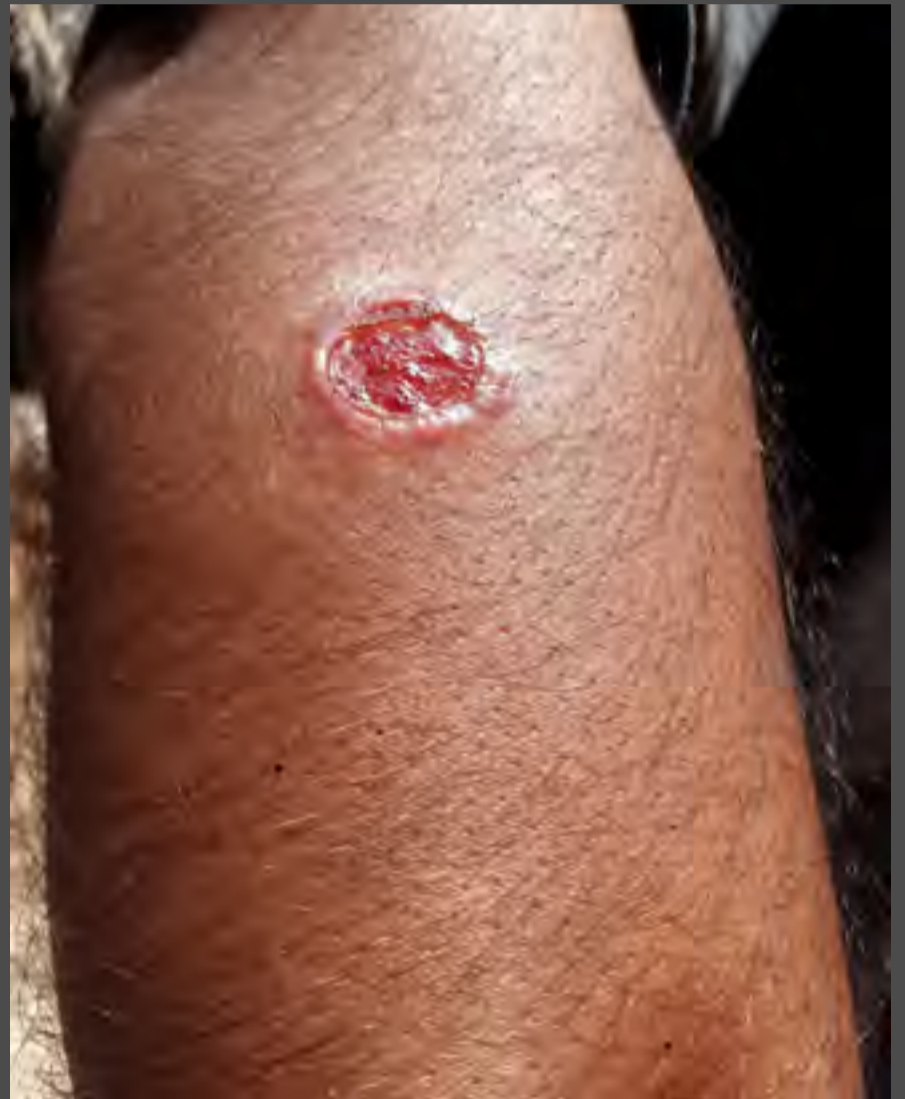**Figure 3.10.**  
Irregularly-shaped ulcer with extensive edema and surrounding infiltration



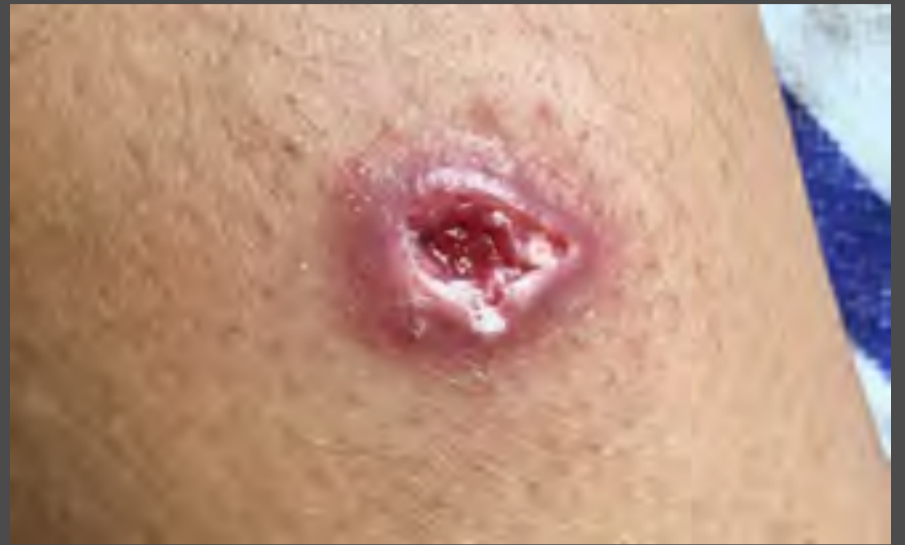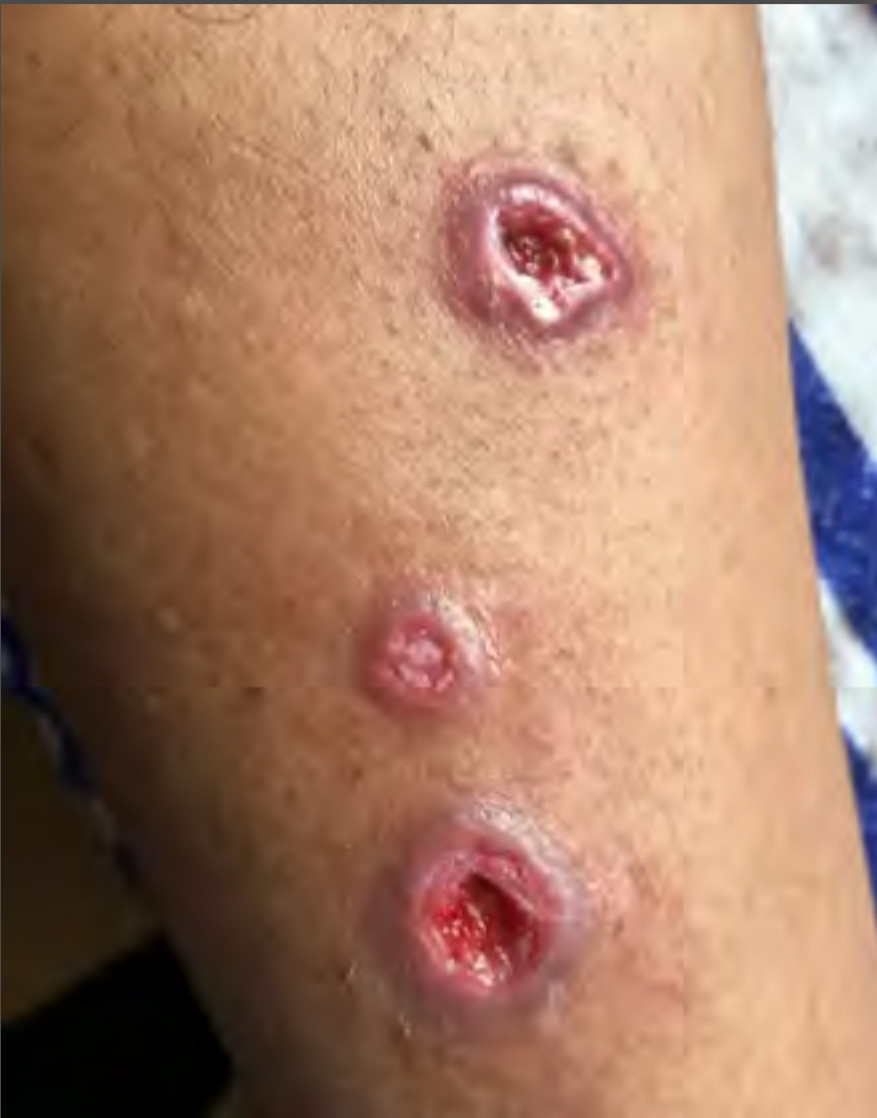**Figure 3.11.**  
Ulcer on forearm 3.5 cm in diameter, covered in serosanguineous scabs, and surrounded by considerable edema and infiltration



**Figure 3.12.**  
Three recent ulcerated papules on forearm

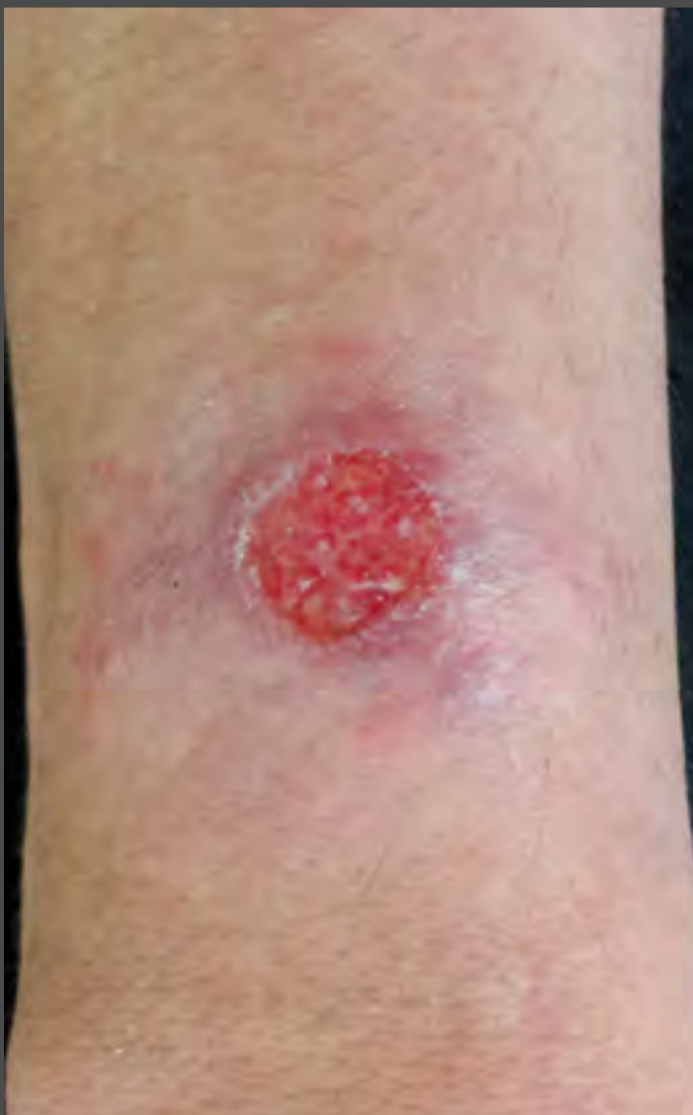

**Figure 3.13.**  
Ulcerated lesion approximately 2.5 cm in diameter  
on posterior external aspect of right forearm



**Figures 3.14A and B.**

Three ulcers approximately 3.5, 3, and 1.8 cm in diameter, rounded, with raised indurated edges, on leg. B is a close-up of the largest lesion.

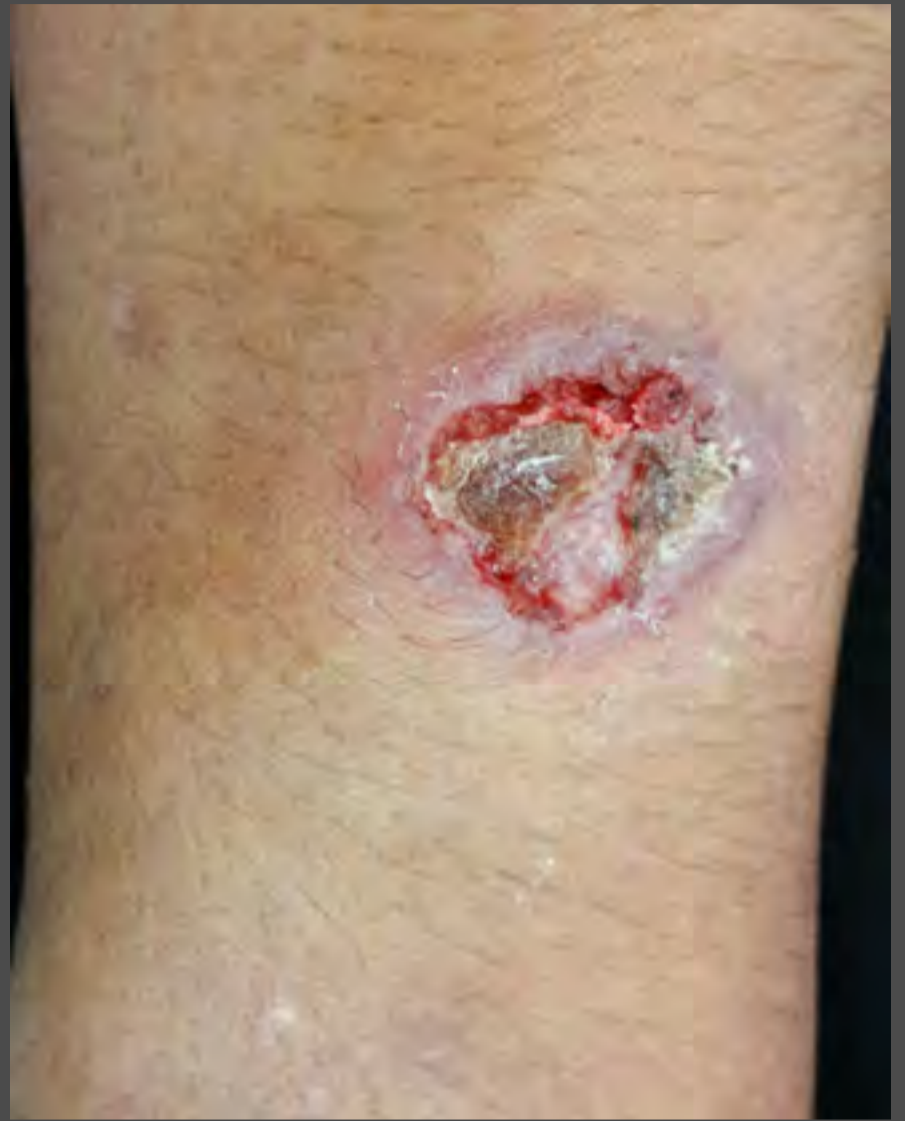

**Figure 3.15.**

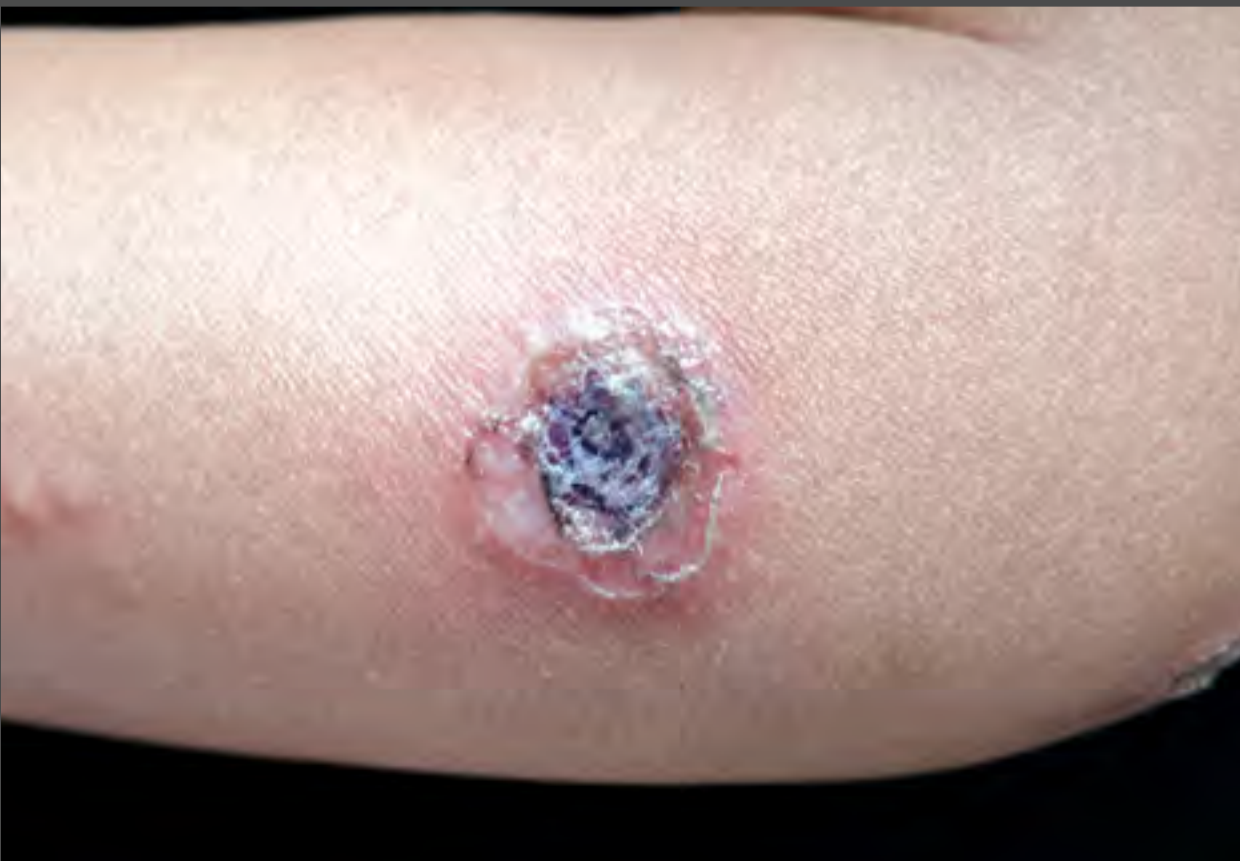Typical peripheral inflammatory infiltration can extend several centimeters around the lesion.



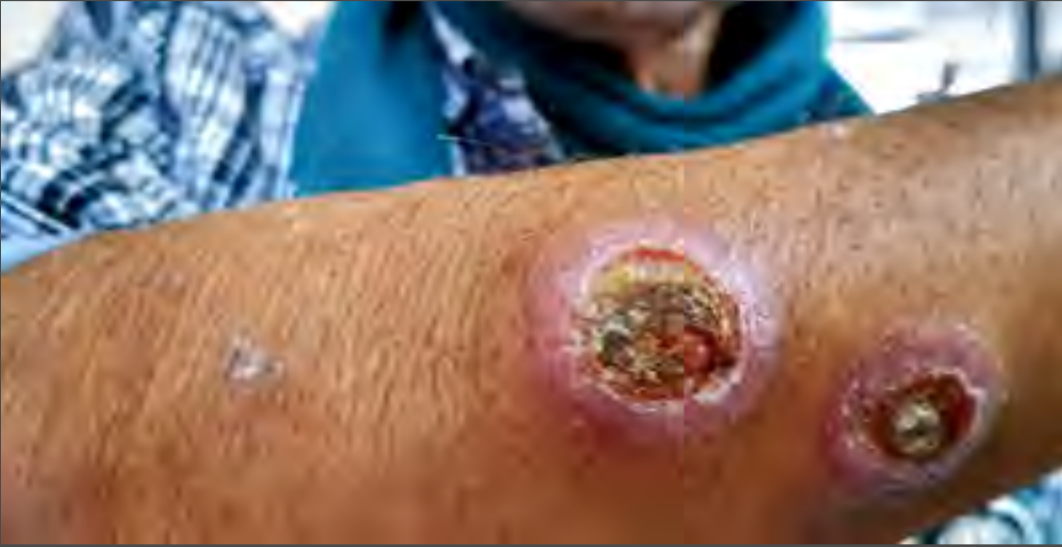**Figure 3.16.**  
Ulcerated lesion approximately 3 cm in diameter, on posterior external aspect of right forearm



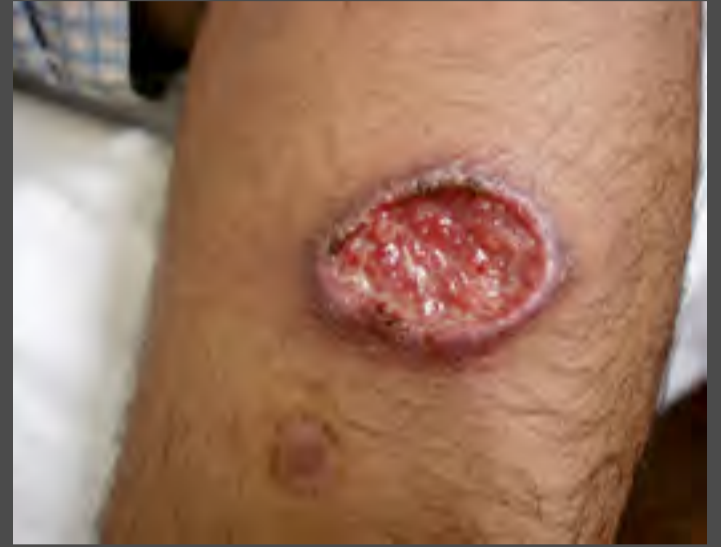**Figure 3.17.**  
Ulcer covered with a dirty scab. Crusts should be removed as part of local management, which is critical to lesion healing.



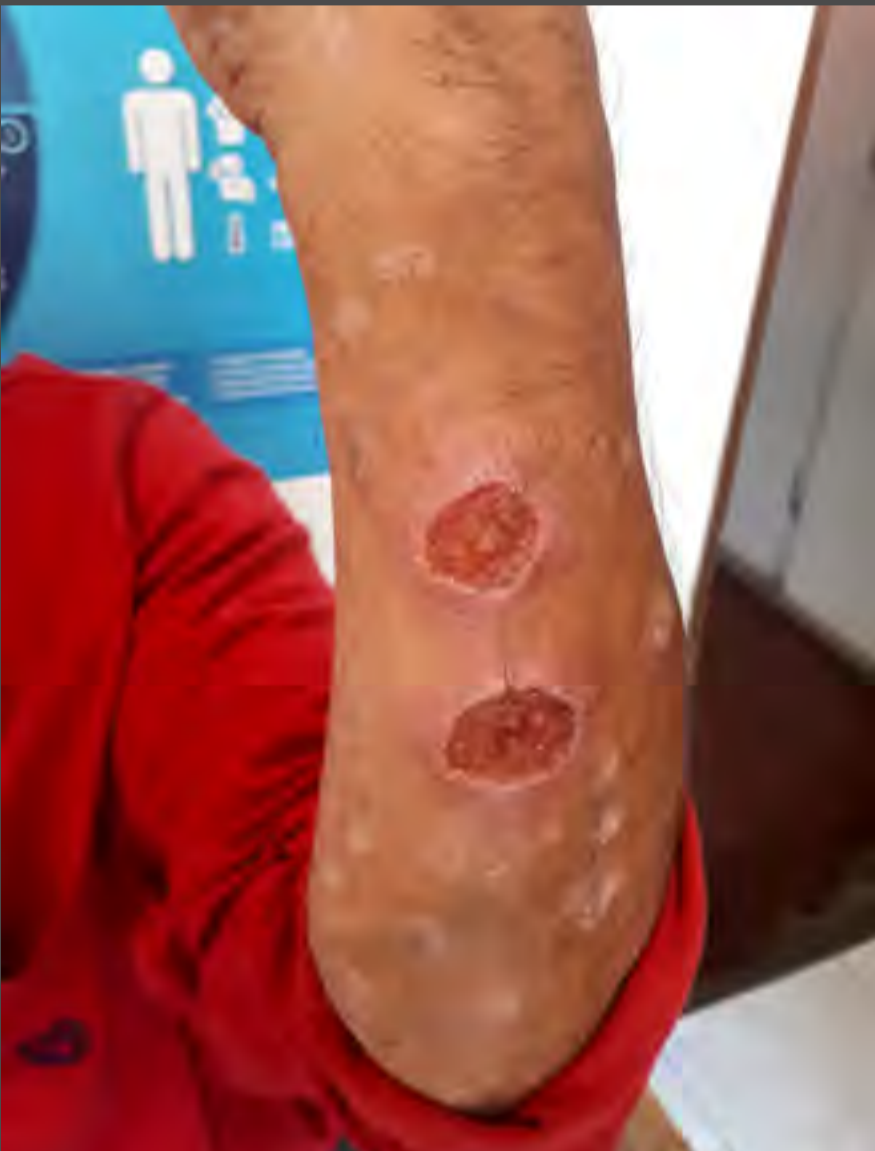**Figure 3.18.**  
Removal of the crust and cleaning the lesion may be enough to prevent development of a concomitant bacterial infection, with greater inflammation and purulent discharge. Sometimes, topical or systemic antibiotics are required.



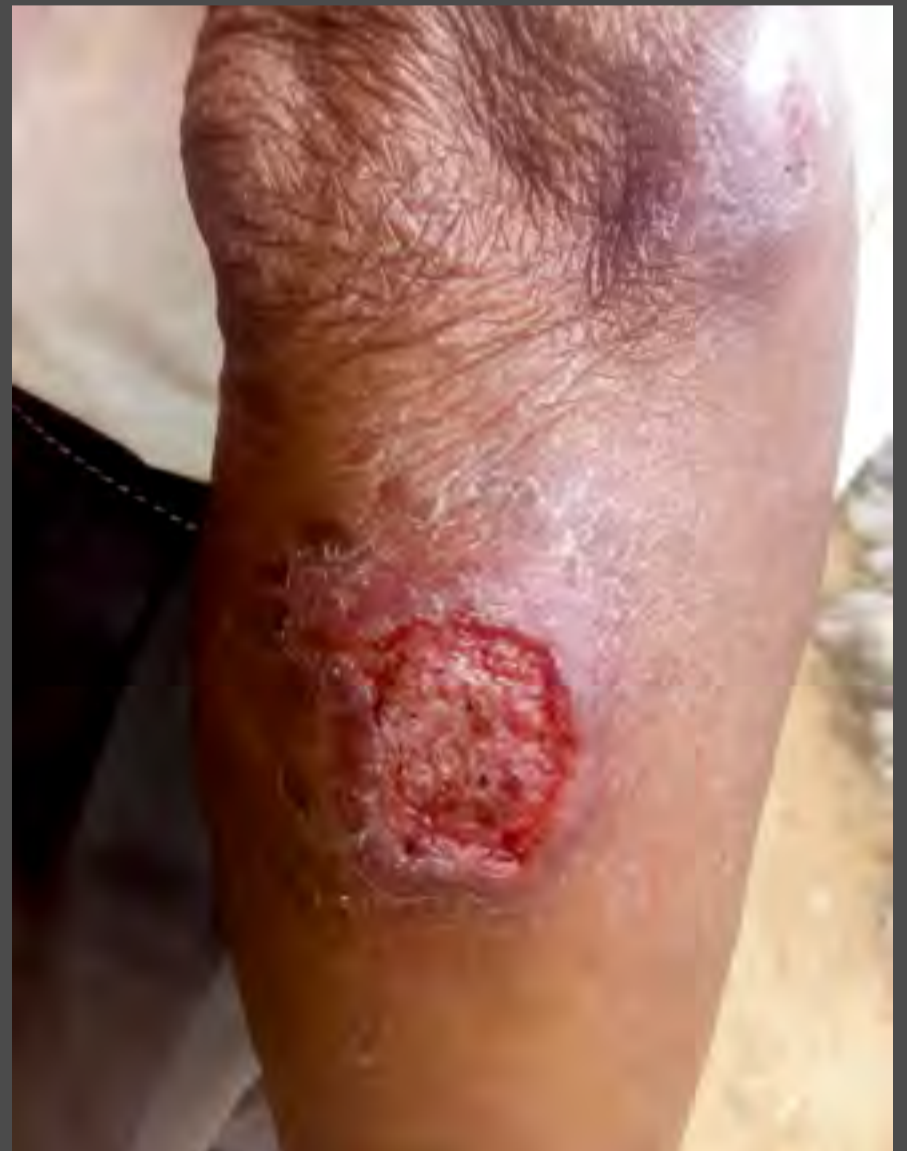**Figure 3.19.**  
Ulcers on right forearm (*Leishmania (V.) braziliensis* complex)



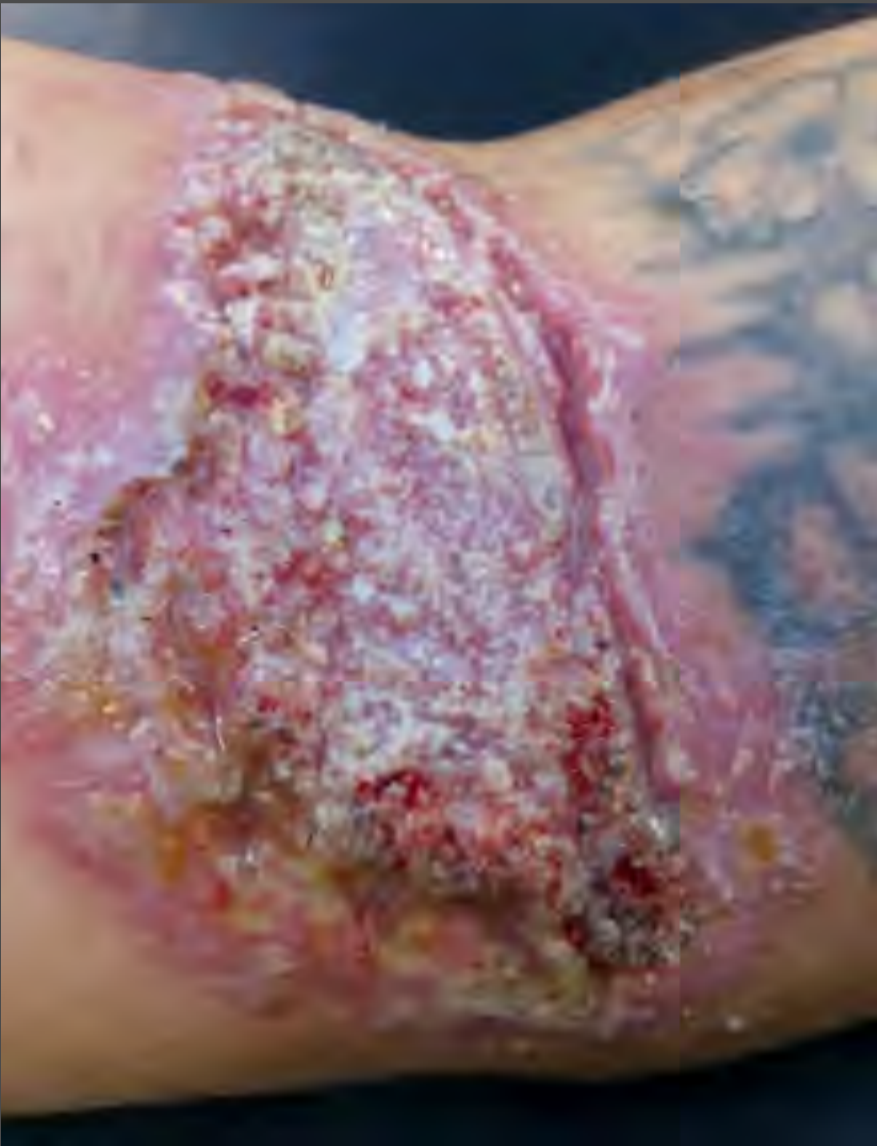**Figure 3.20.**  
Ulcerated lesion on forearm



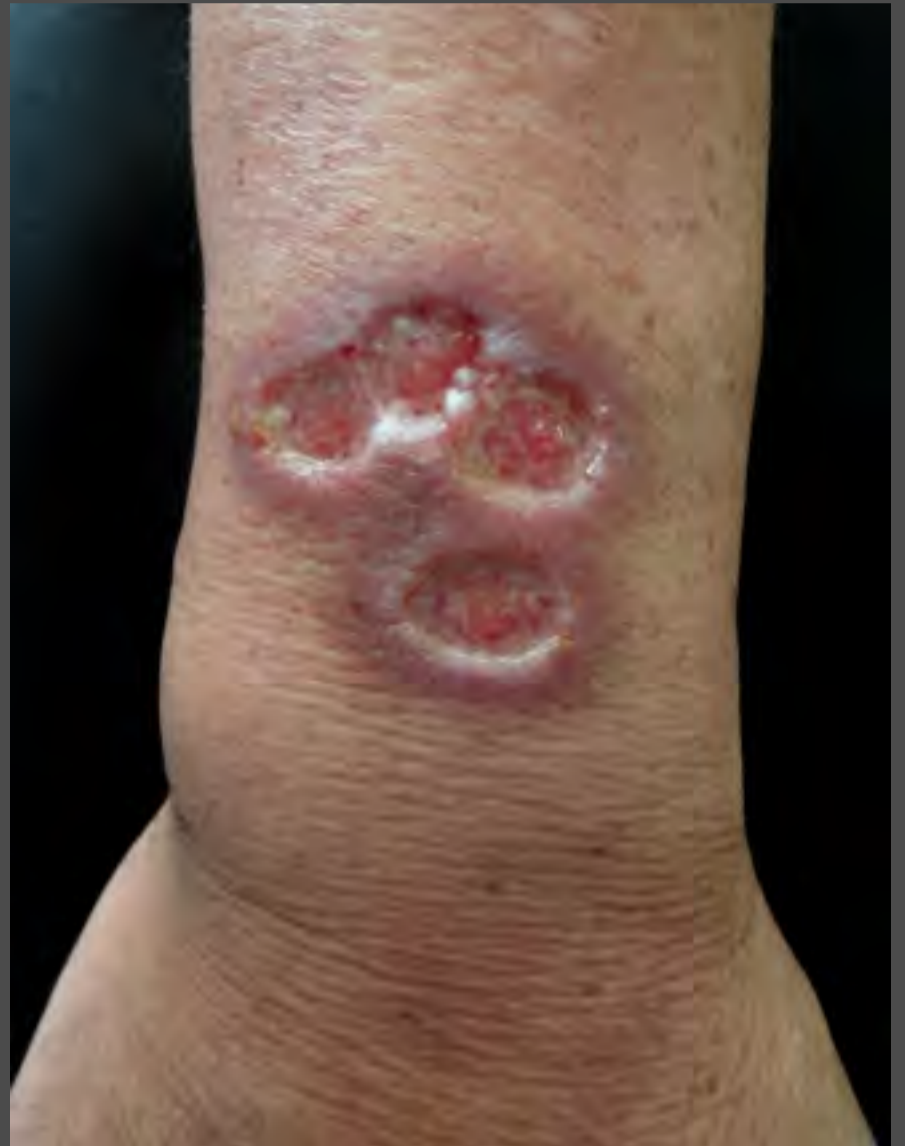**Figure 3.21.**  
Ulcerated lesions on right arm



**Figure 3.22.**  
Lesion 3 cm on right forearm



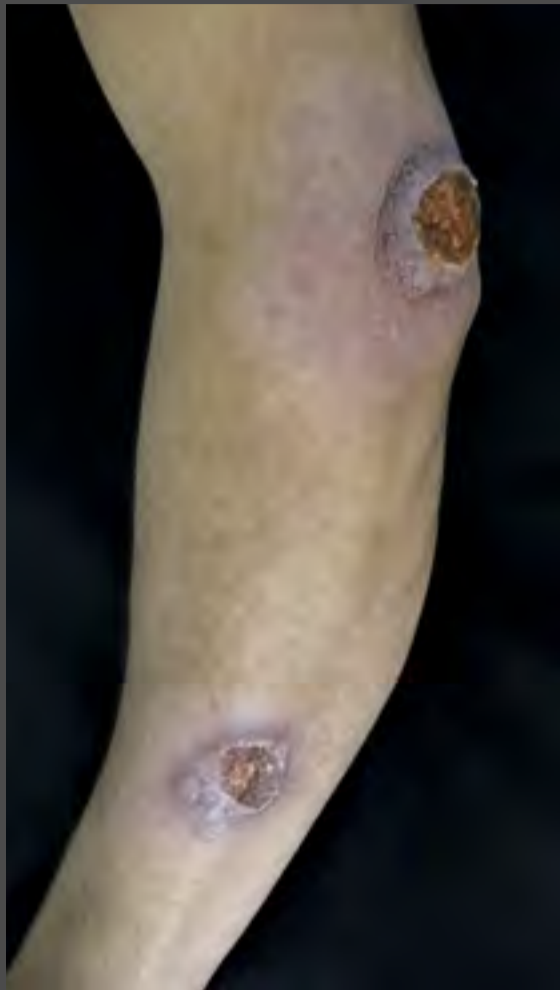**Figure 3.23.**  
Large lesion on left arm with presence of serosanguineous crusts, along with pruritus and a superimposed infection



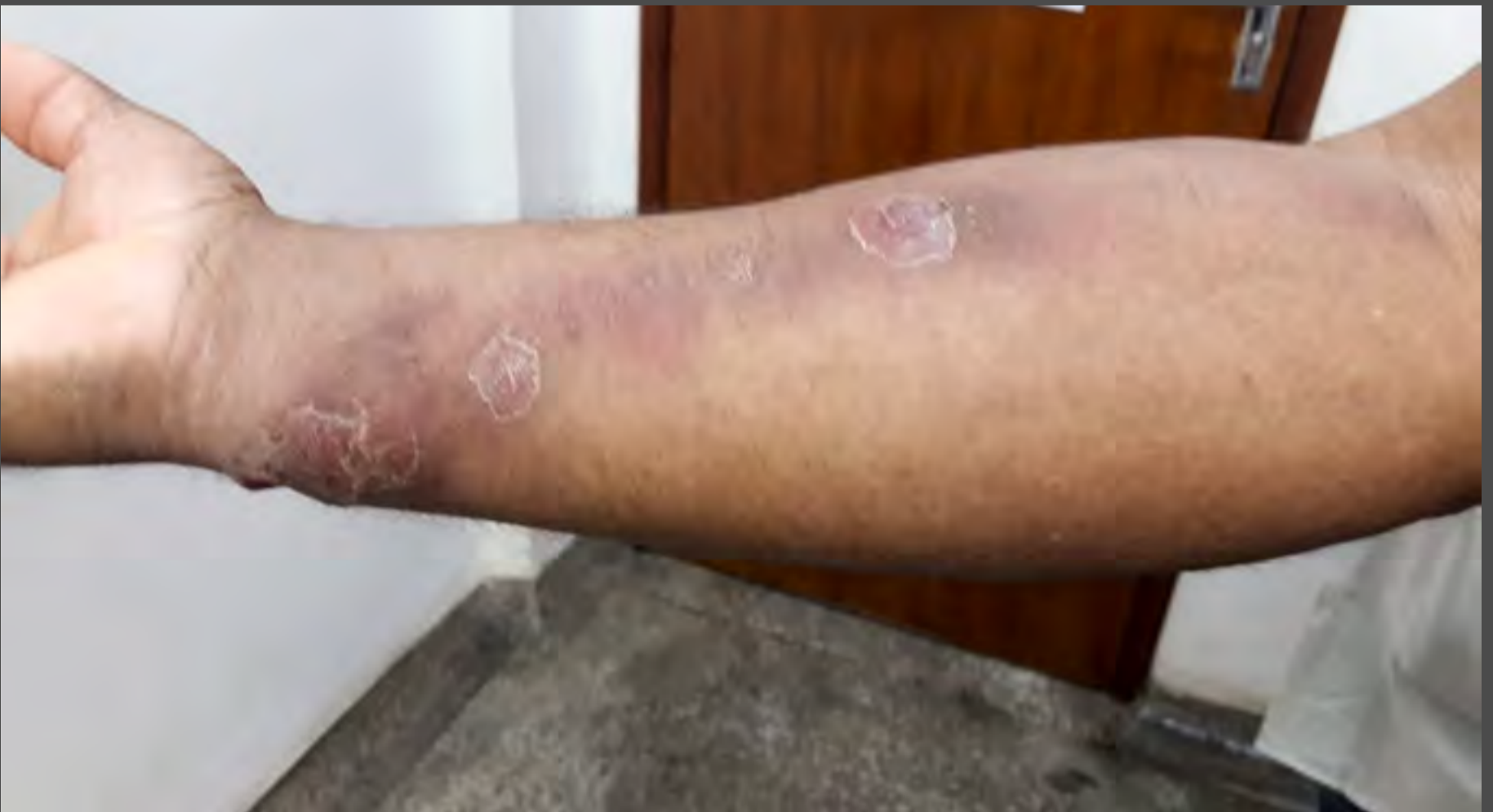**Figure 3.24.**  
Four very close, confluent ulcers. Their development is similar, possibly resulting from a simultaneous bite. The insect vector can bite several times looking for a capillary and inject enough parasites with its saliva to cause clinical lesions in each bite.



## Lymphangitic cutaneous leishmaniasis

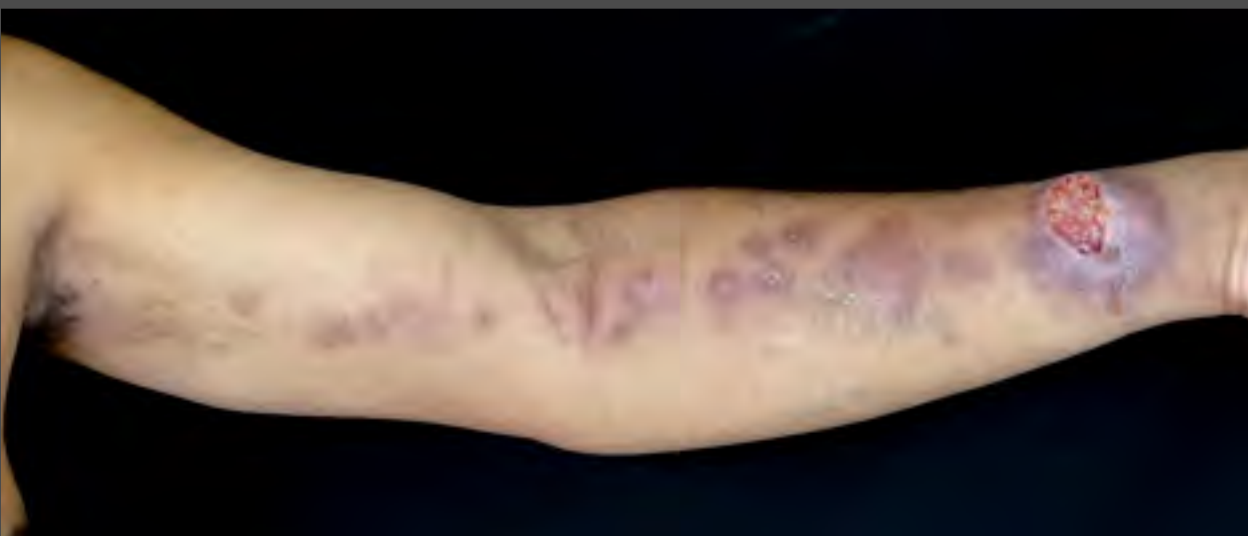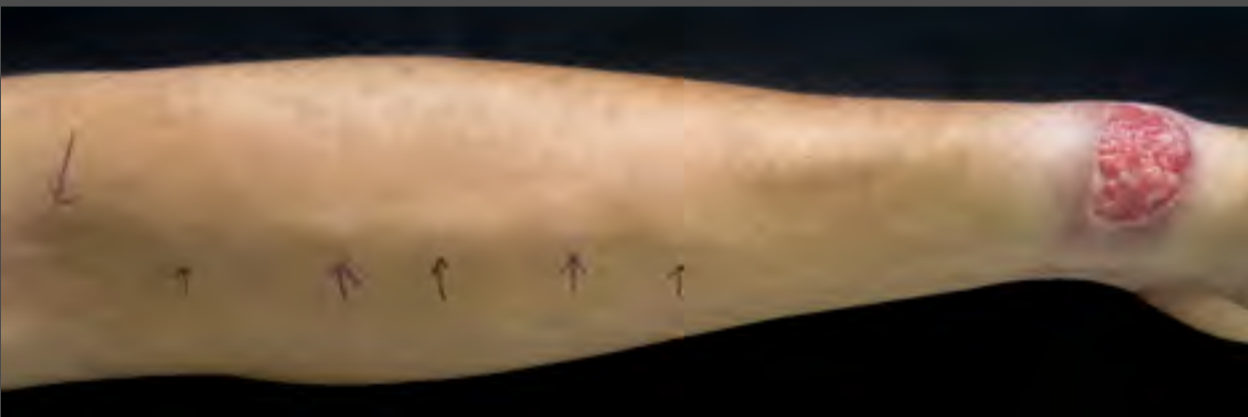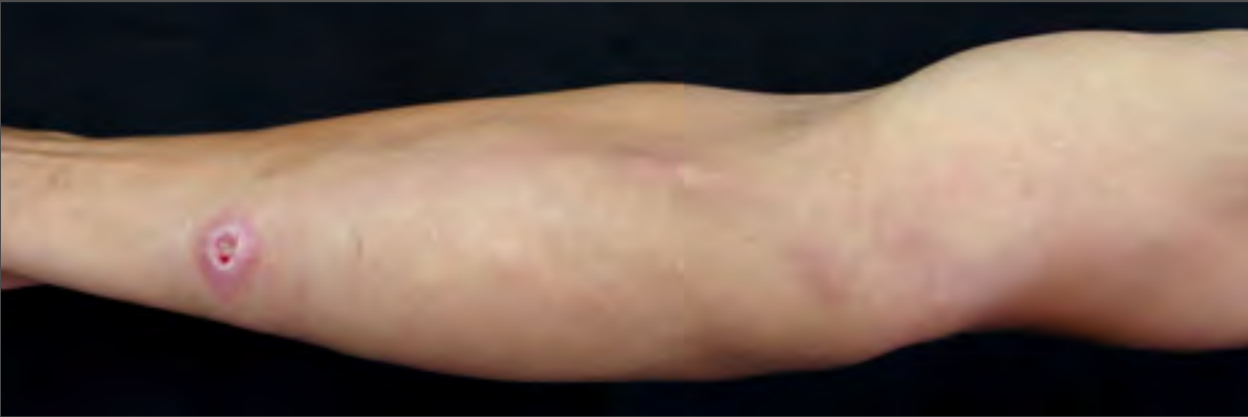**Figure 3.25.**

Close, clinically similar ulcers, with no visible lymphatic cording between them, suggesting two simultaneous bites.

**Figure 3.26.**

Cutaneous leishmaniasis with lymphatic involvement on day 35 since appearance; differential diagnosis from sporotrichosis should be done.

## Lymphangitic cutaneous leishmaniasis

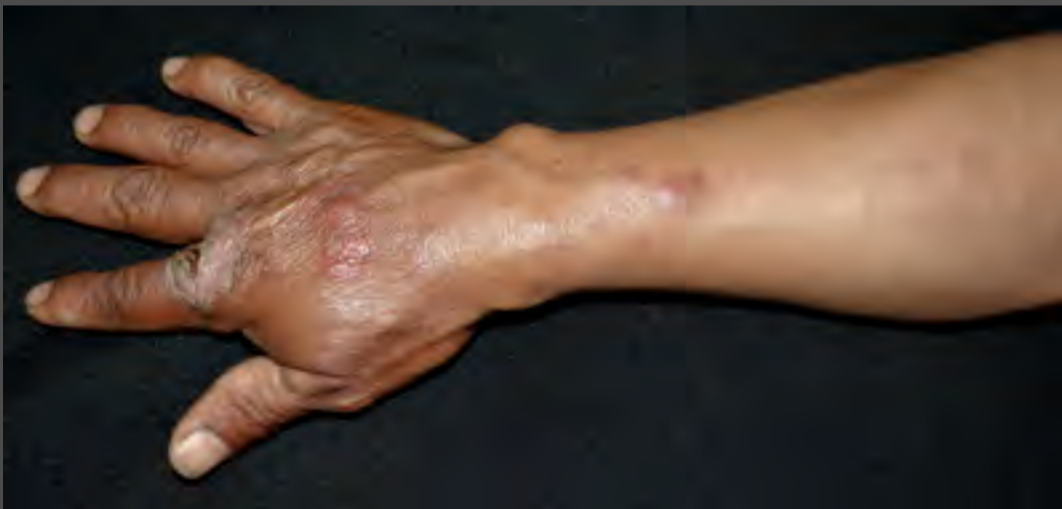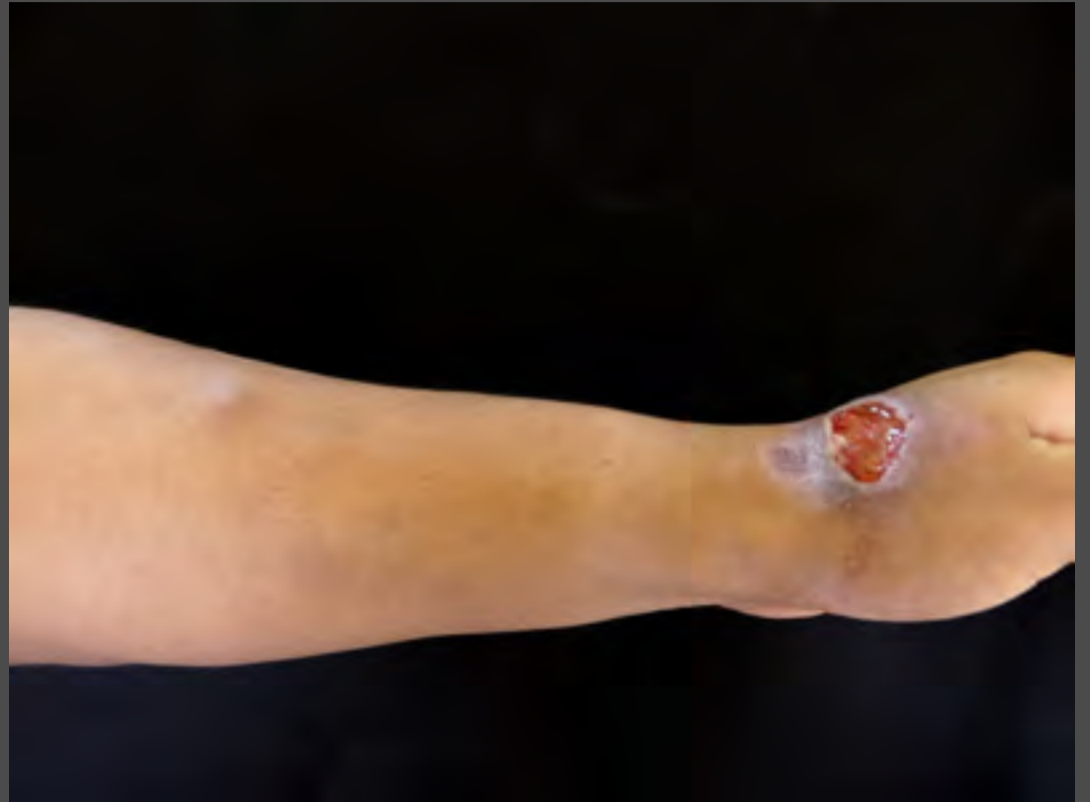


**Figures 3.27A, B, C and D.** Palpation makes it possible to detect regional adenopathies and lymphatic vessel involvement. Initially, the affected vessels produce palpable linear thickening and, subsequently, changes in color, nodules or papules, a track with visible relief and, sometimes, ulcerations.

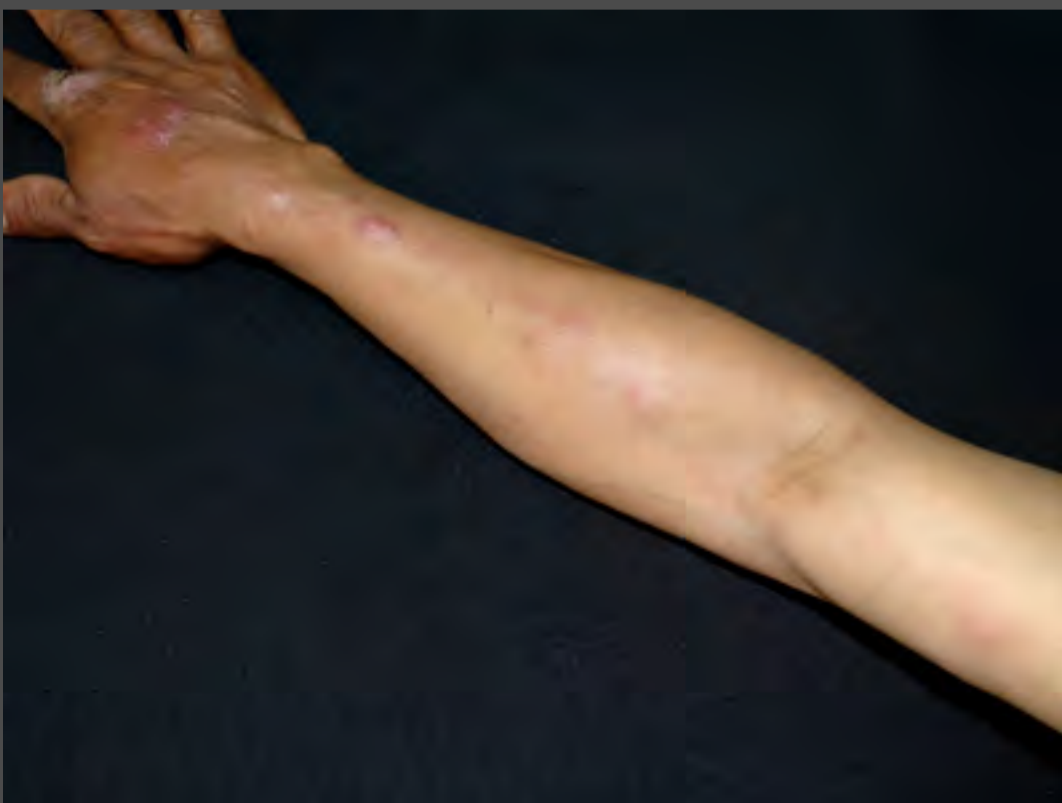## Lymphangitic cutaneous leishmaniasis

**Figure 3.28.**

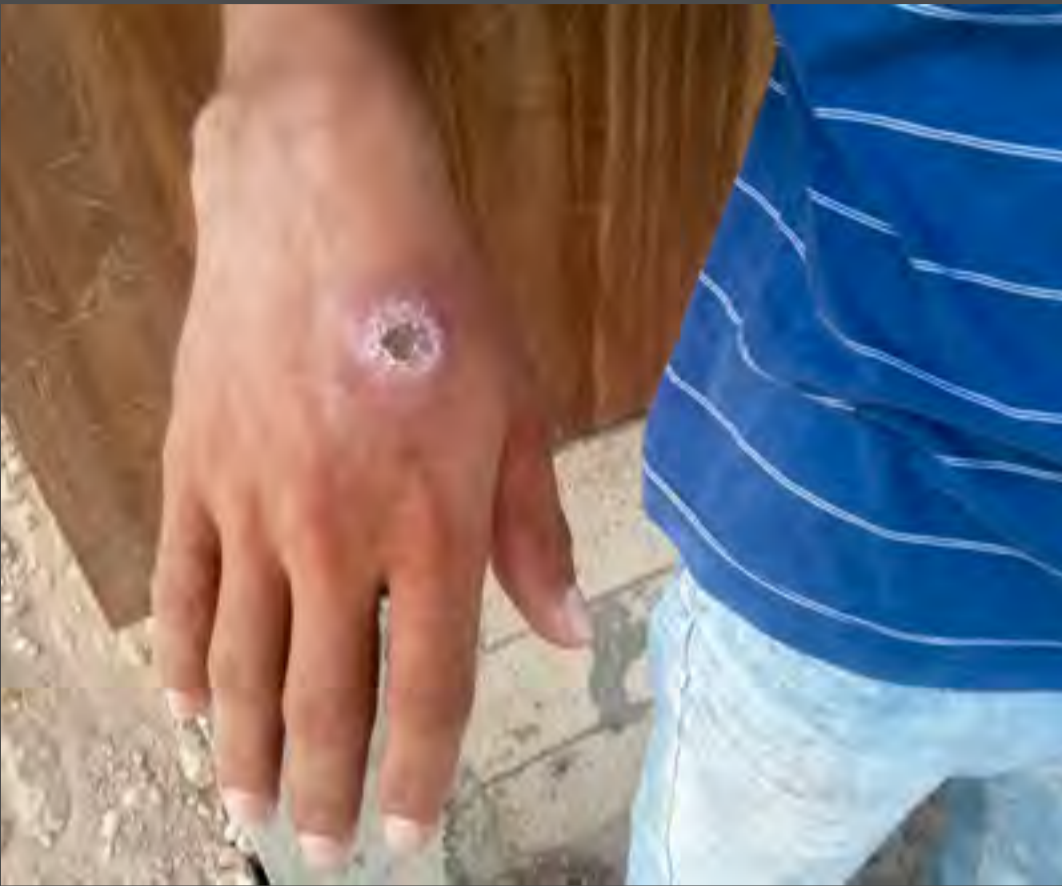Sometimes lesions are more palpable than visible, which is why careful palpation is very important.

**Figure 3.29A.**

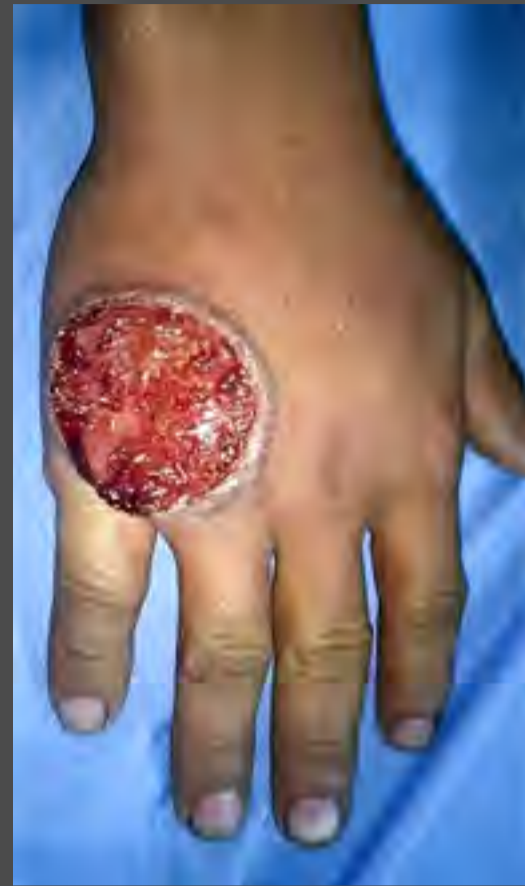Lymphatic involvement started in the ulcer at the base of the index finger and, after two weeks of development, already had numerous gummy ulcerated lesions, almost all at the same stage of development.

**Figure 3.29B.**

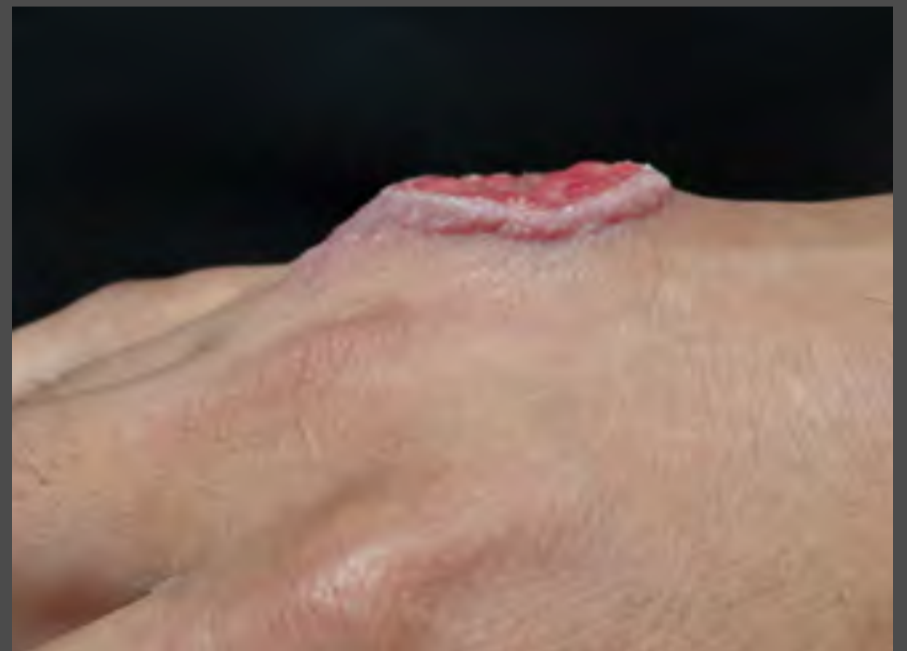By day 40, lesions had ascended and the most proximal was the least developed (nodule, papule, macule).



**Figure 3.30.**  
Ulcerated lesion 2 cm in diameter with scab, on back of right hand

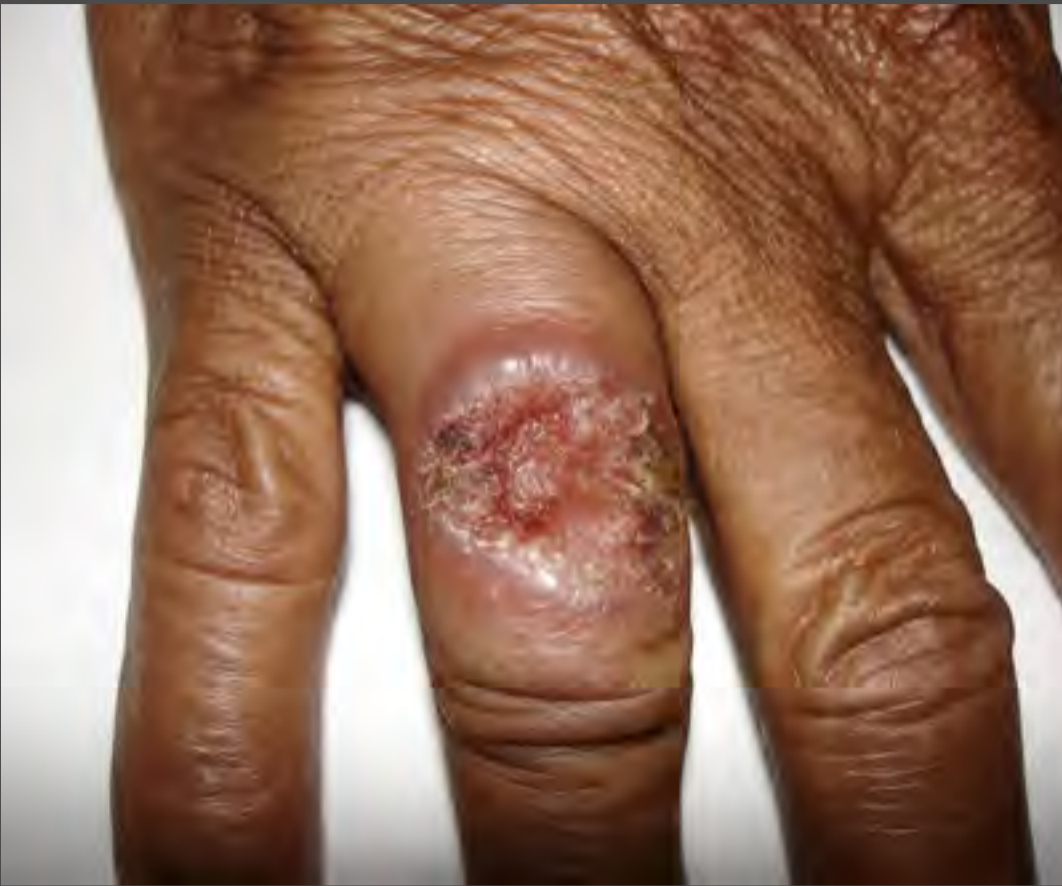

**Figure 3.31.**  
Ulcer with raised edge and center with granular appearance, on back of right hand, before treatment (*Leishmania (V.) braziliensis*)



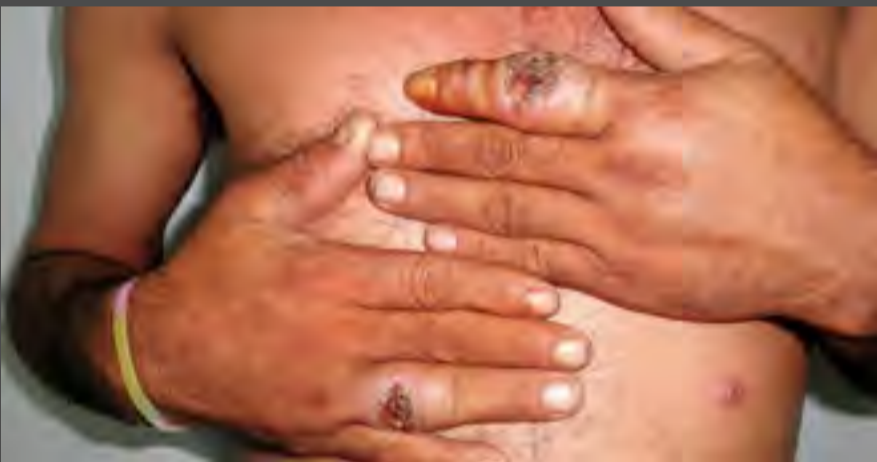**Figures 3.32A and B.**

Characteristic lesion. Round or oval ulcer 2 to 6 cm in diameter, with raised edges, cording, infiltrates, and crateriform center with granulation tissue, in addition to peripheral infiltration and erythema. Frequently located on hands and forearms, from their exposure to bites.



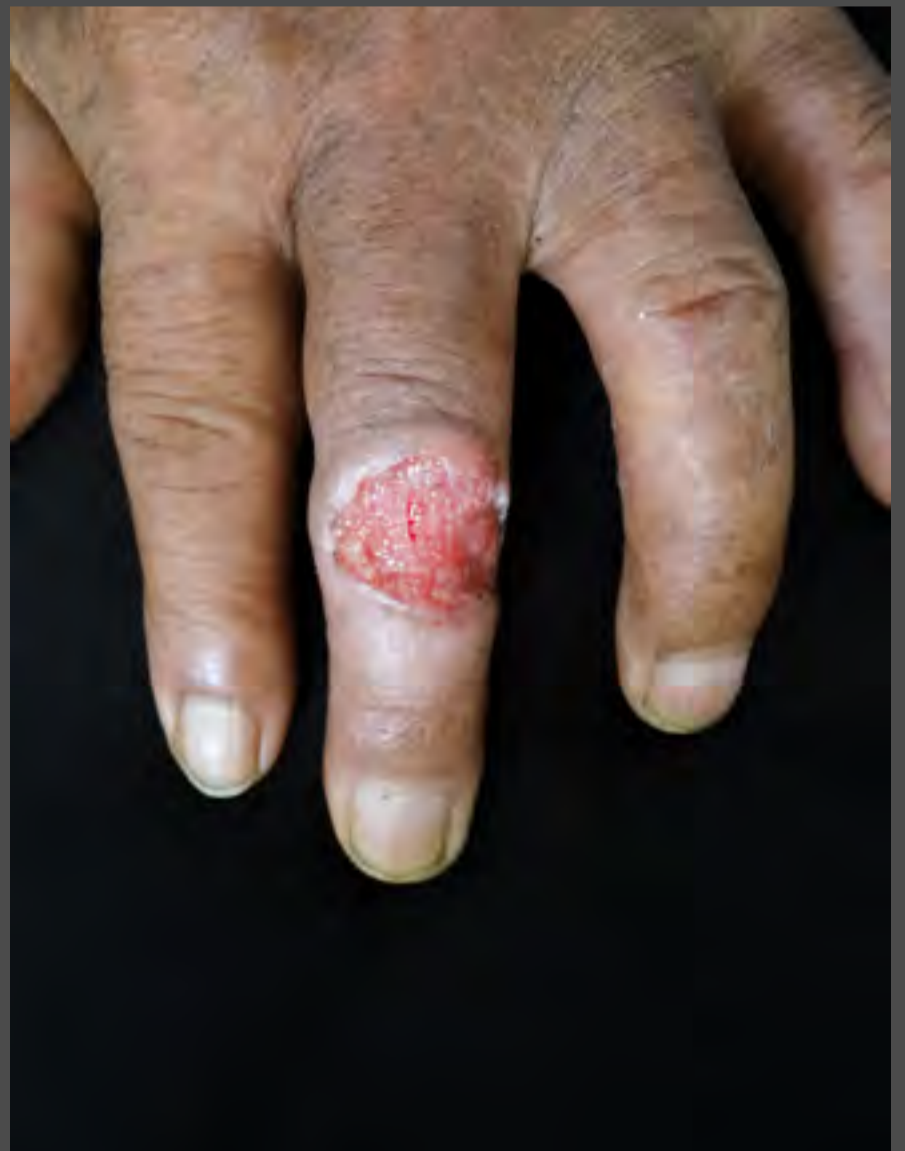**Figure 3.33.**

Ulcer on back of ring finger, well-defined and painless



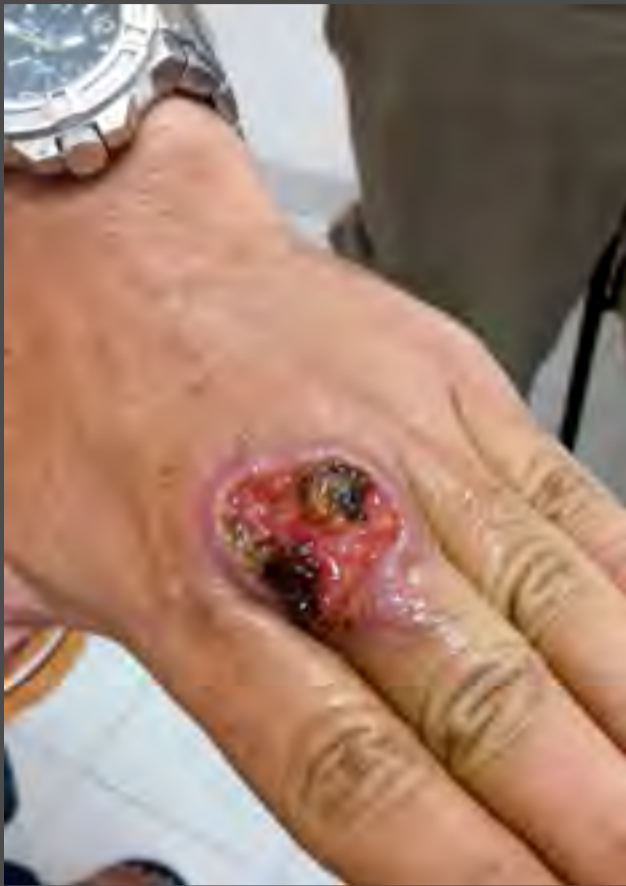**Figure 3.34.**

Ulcer on fingers with raised edges, crusty center, and secretions (*Leishmania (V.) braziliensis* complex)

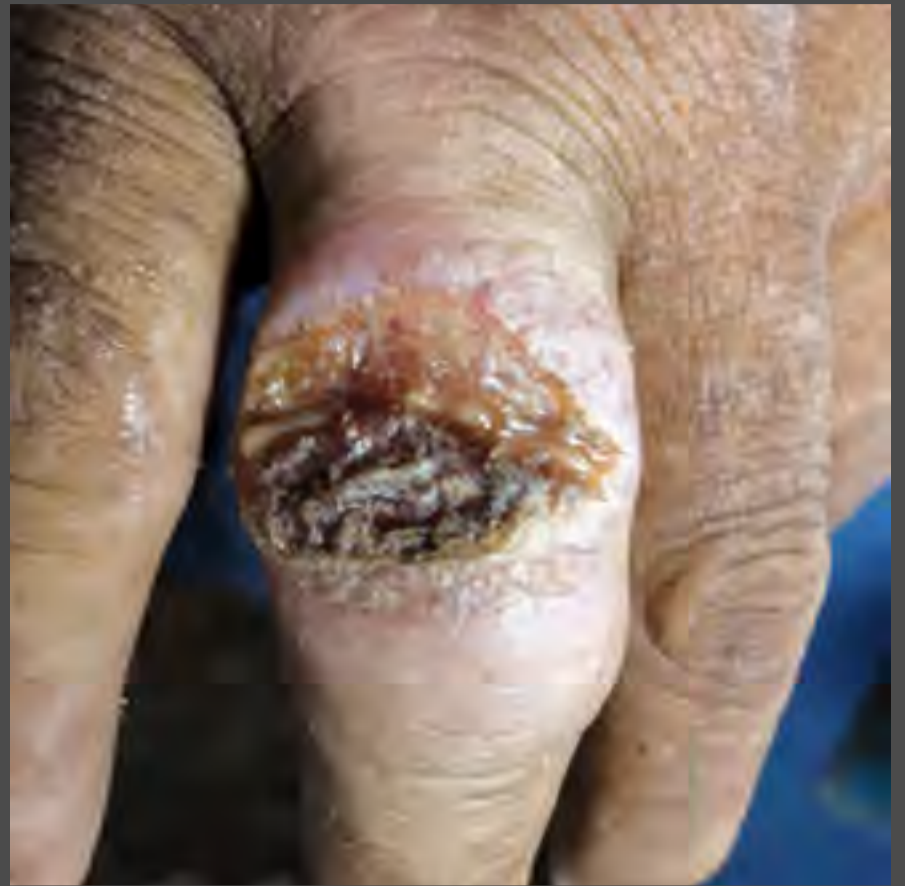

**Figure 3.35.**

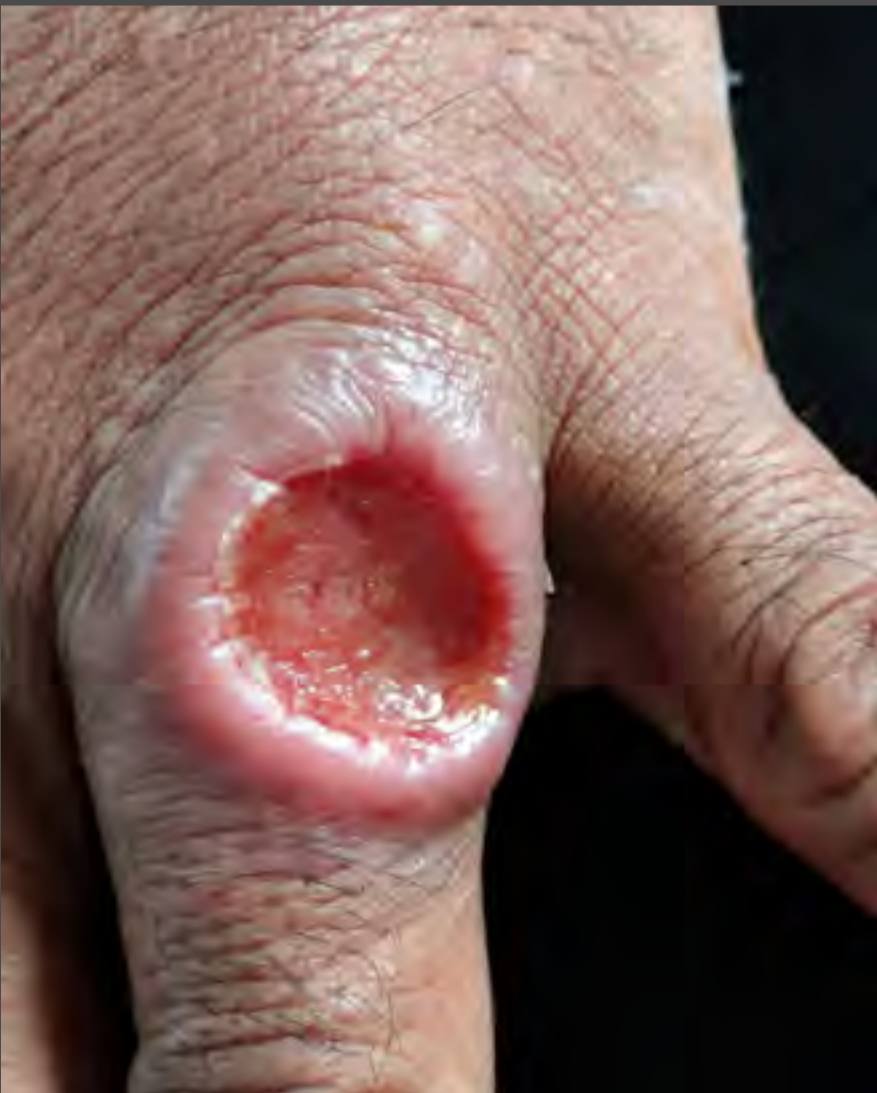Lesions tend to be smaller on the fingers, but otherwise retain the same typical characteristics.



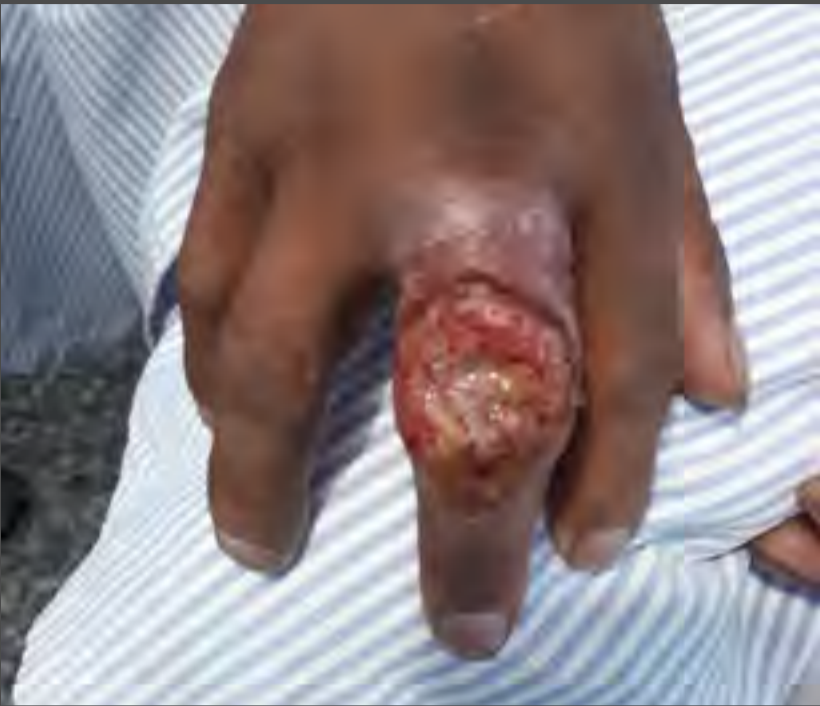**Figure 3.36.**  
Ulcerated lesion approximately 3 cm in diameter, next to knuckle on third finger



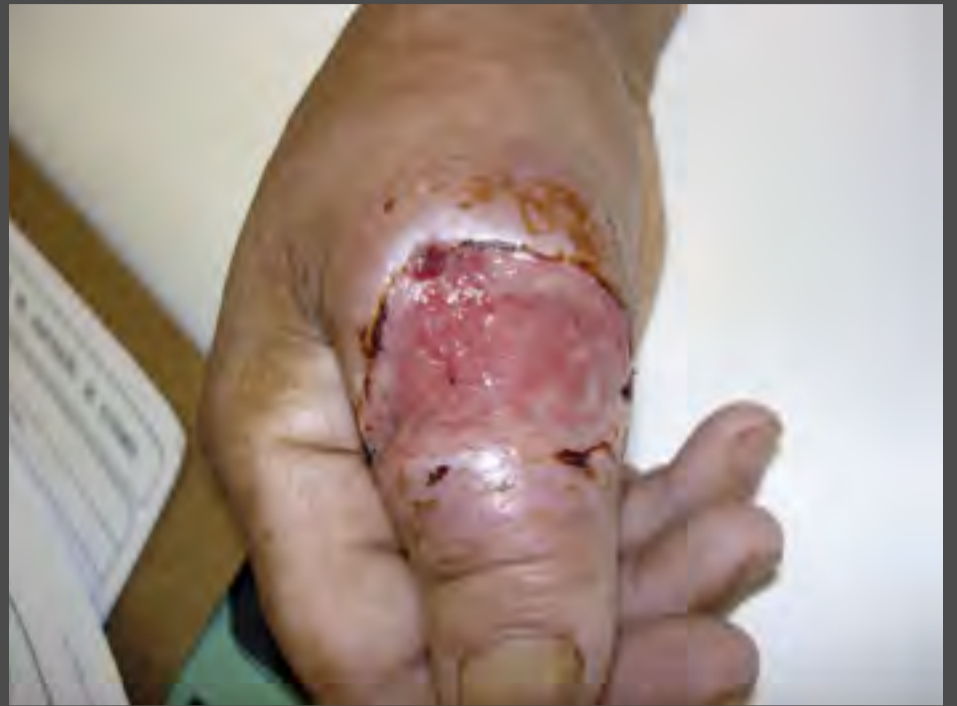**Figure 3.37.**  
Ulcer with raised edge and crusty center with secretions on a finger of the left hand (*Leishmania (V.) braziliensis* complex)



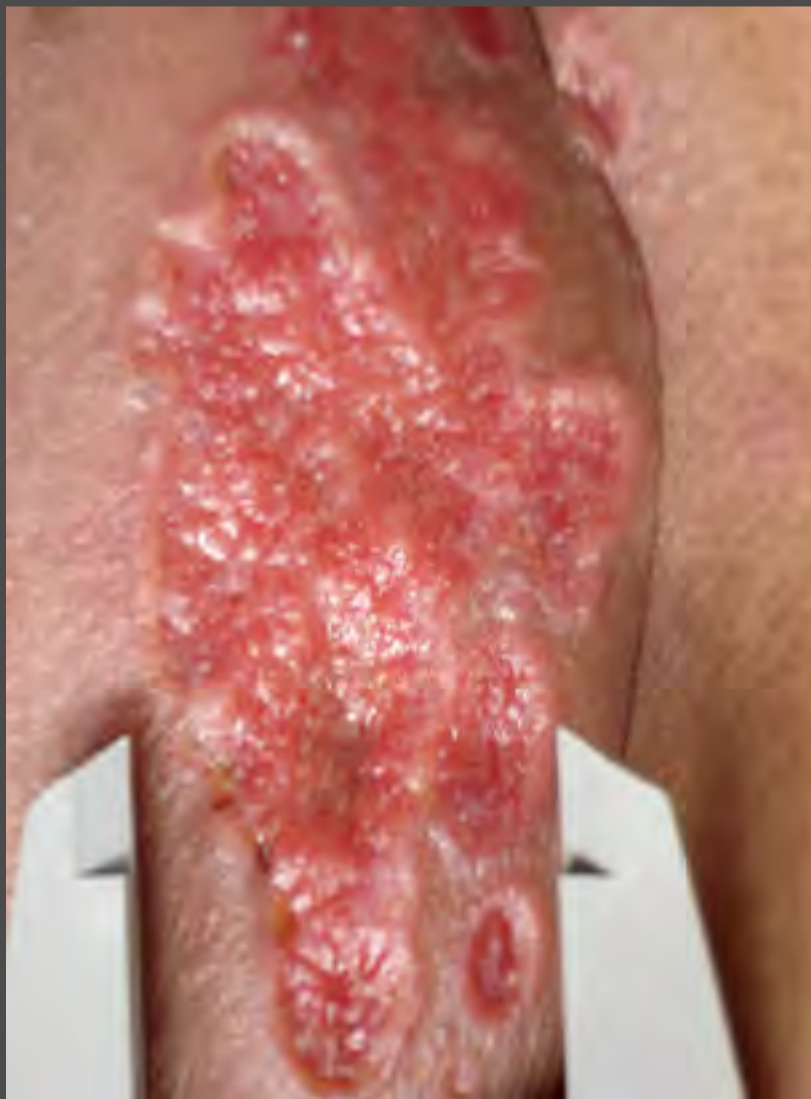**Figure 3.38.**  
Ulcer typical of cutaneous leishmaniasis, round or oval, 2 to 6 cm in diameter, with raised, corded, and infiltrated edges and crateriform center covered by granulation tissue. Hands and forearms are frequently affected because they are uncovered and exposed to bites.



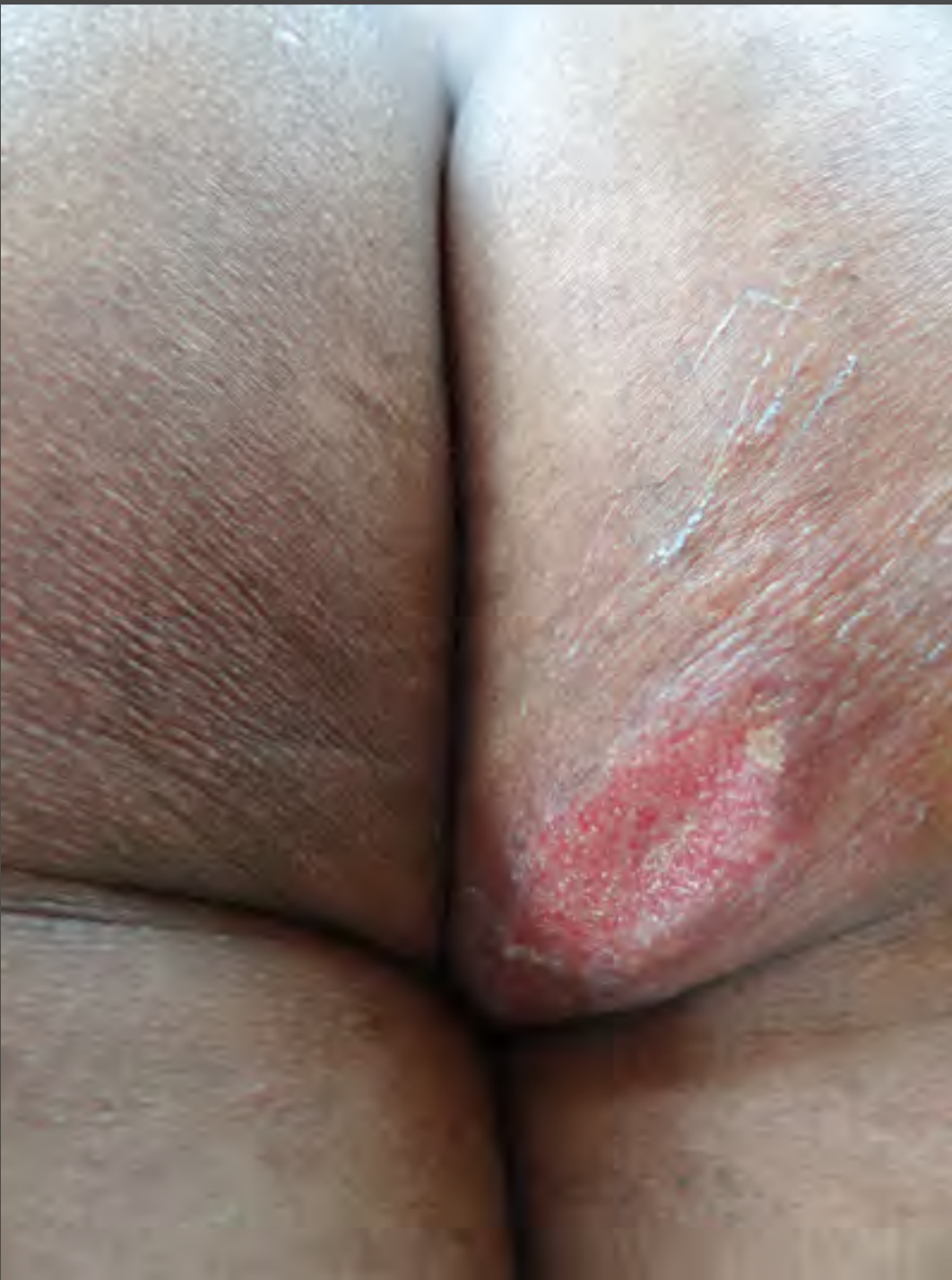**Figure 3.39.**  
Lesion 5 cm in diameter on third finger of left hand



**Figure 3.40.**  
Ulcer on thumb, well-defined and painless

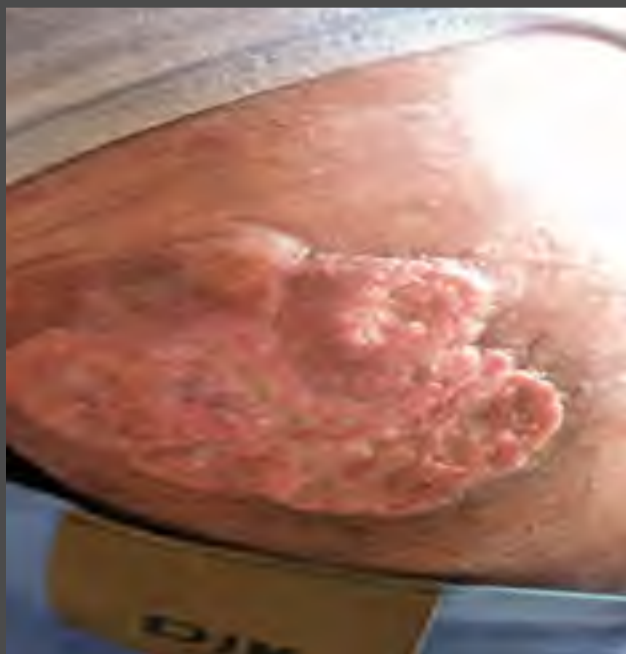

**Figure 3.41.**  
Extensive ulcerated lesion that involves the knuckle and back of the finger.



**Figure 3.42.**

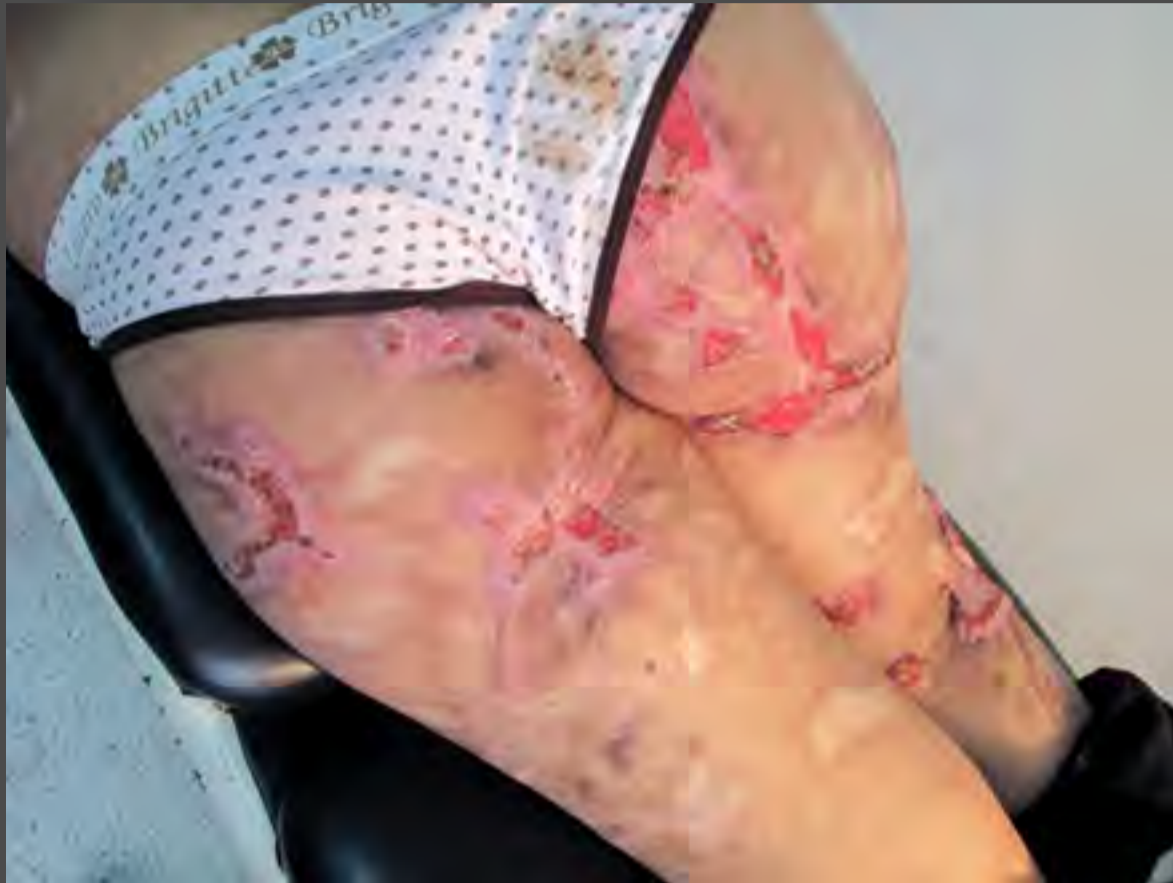Although lesions are more frequent on areas not covered by clothes, they can occur on other sites depending on circumstances, in this case, the buttock.



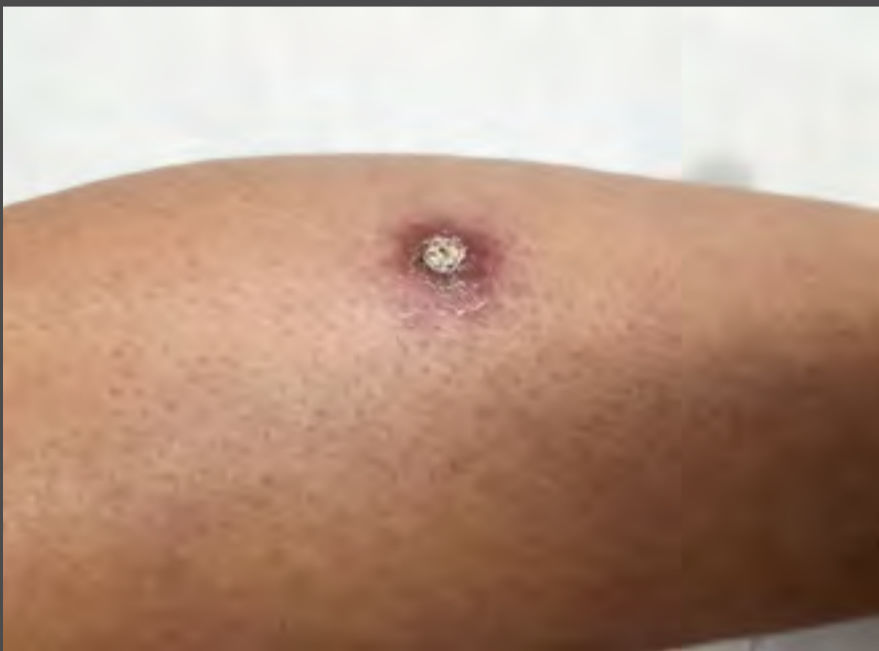**Figure 3.43.**

Lesion with raised, well-defined edges, warty appearance, and granular center with crusts and exudation; not painful or itchy; located on thigh.

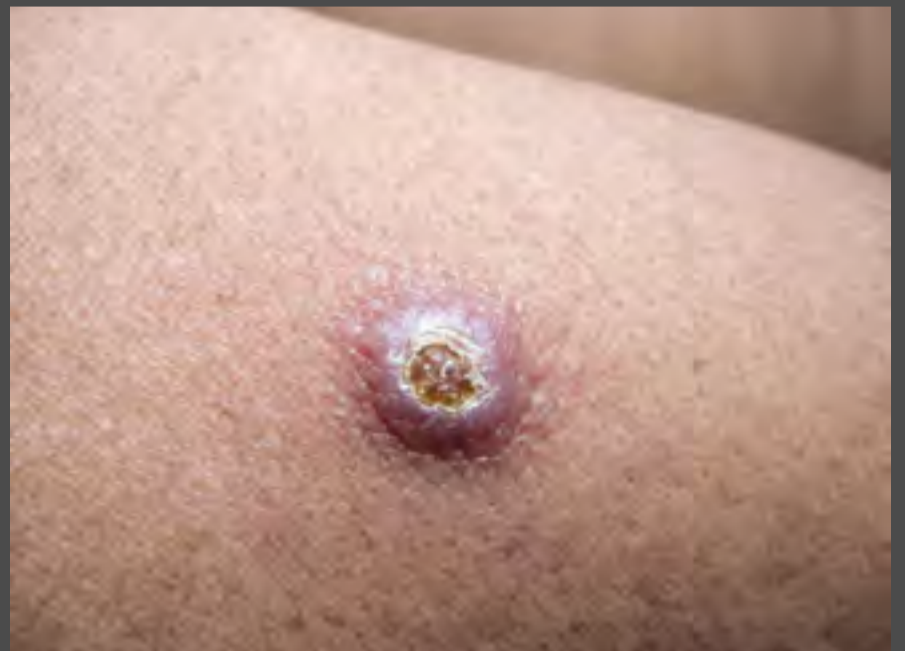



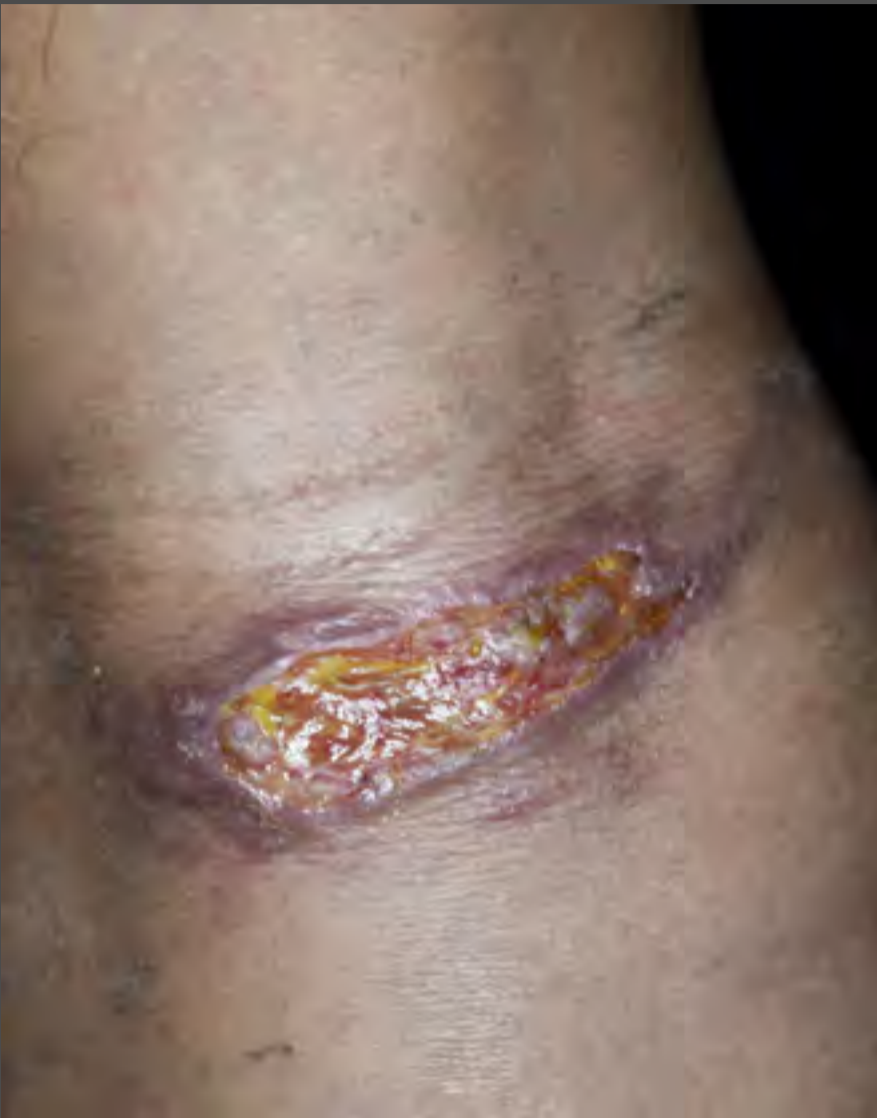**Figure 3.44.**  
Crusty ulcerative lesions and wart-like lesions, involving back of legs.



**Figure 3.45.**  
Crusty ulcer with erythematous edge

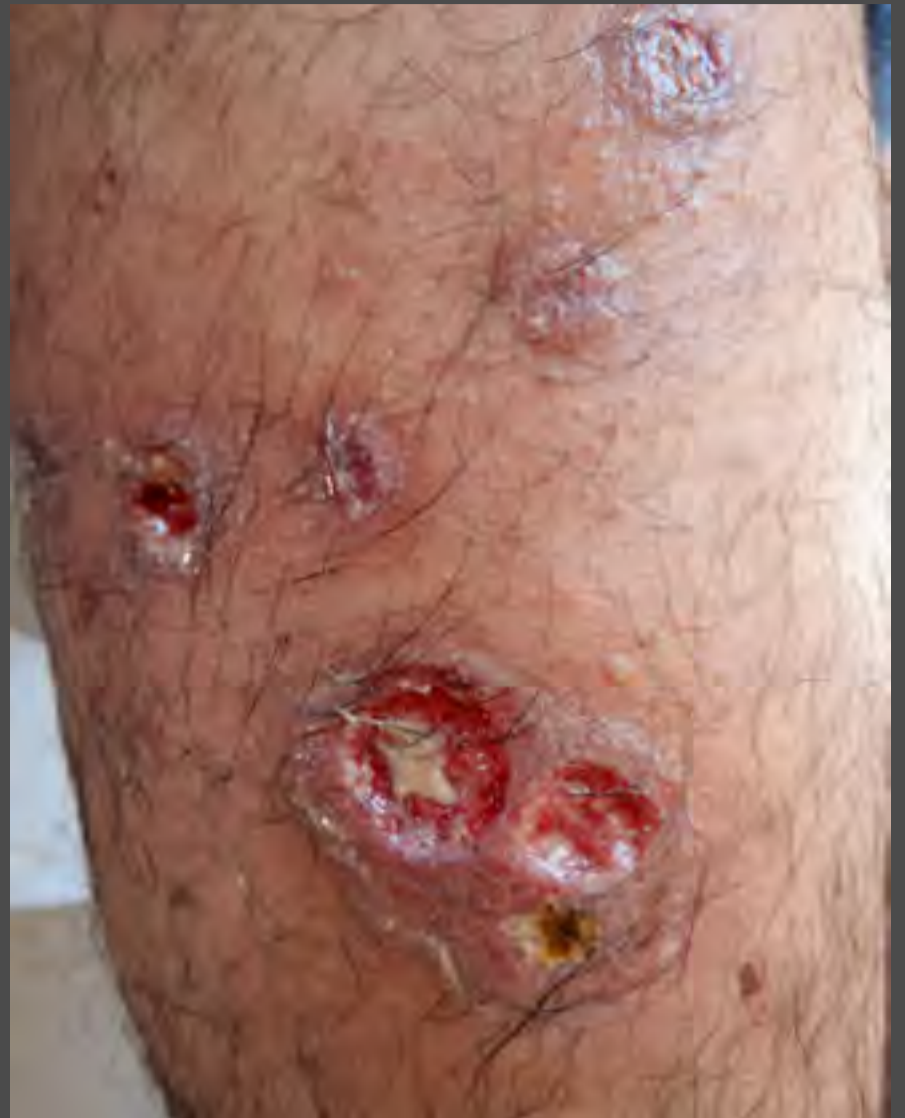

**Figure 3.46.**  
Small papule with ulcerated center



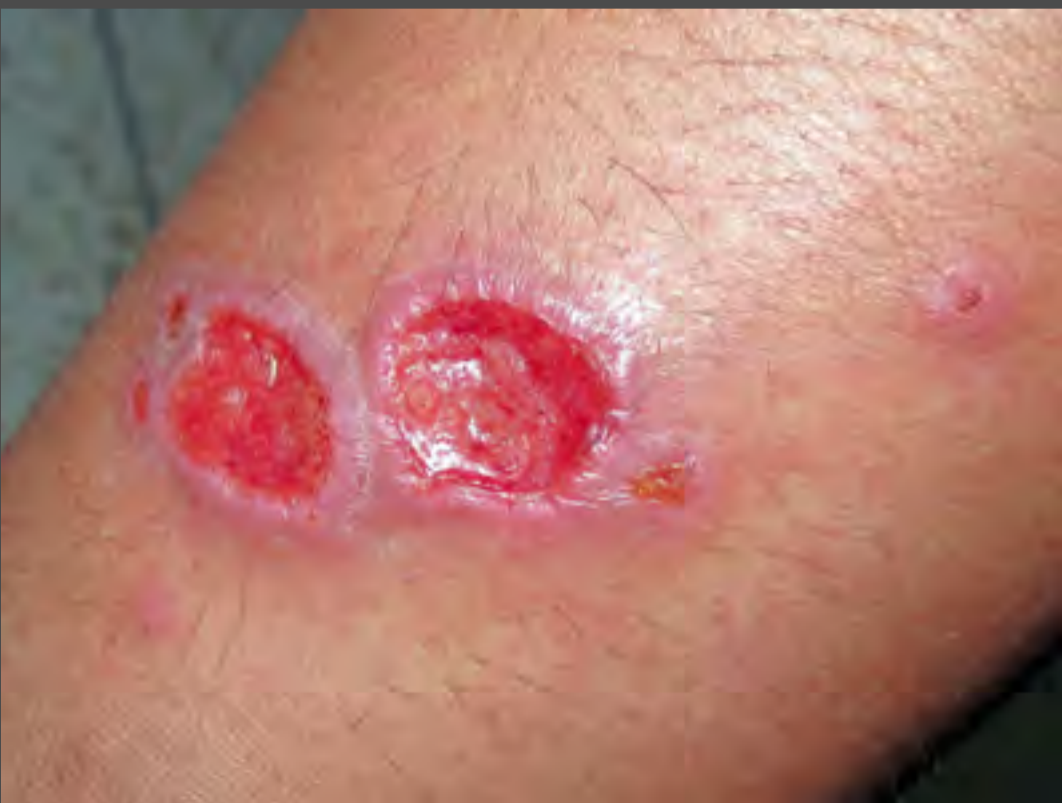**Figure 3.47.**

On areas where the limbs bend, lesions tend to be elongated and oval-shaped, following the direction of the fold. Otherwise, they retain the usual characteristics.



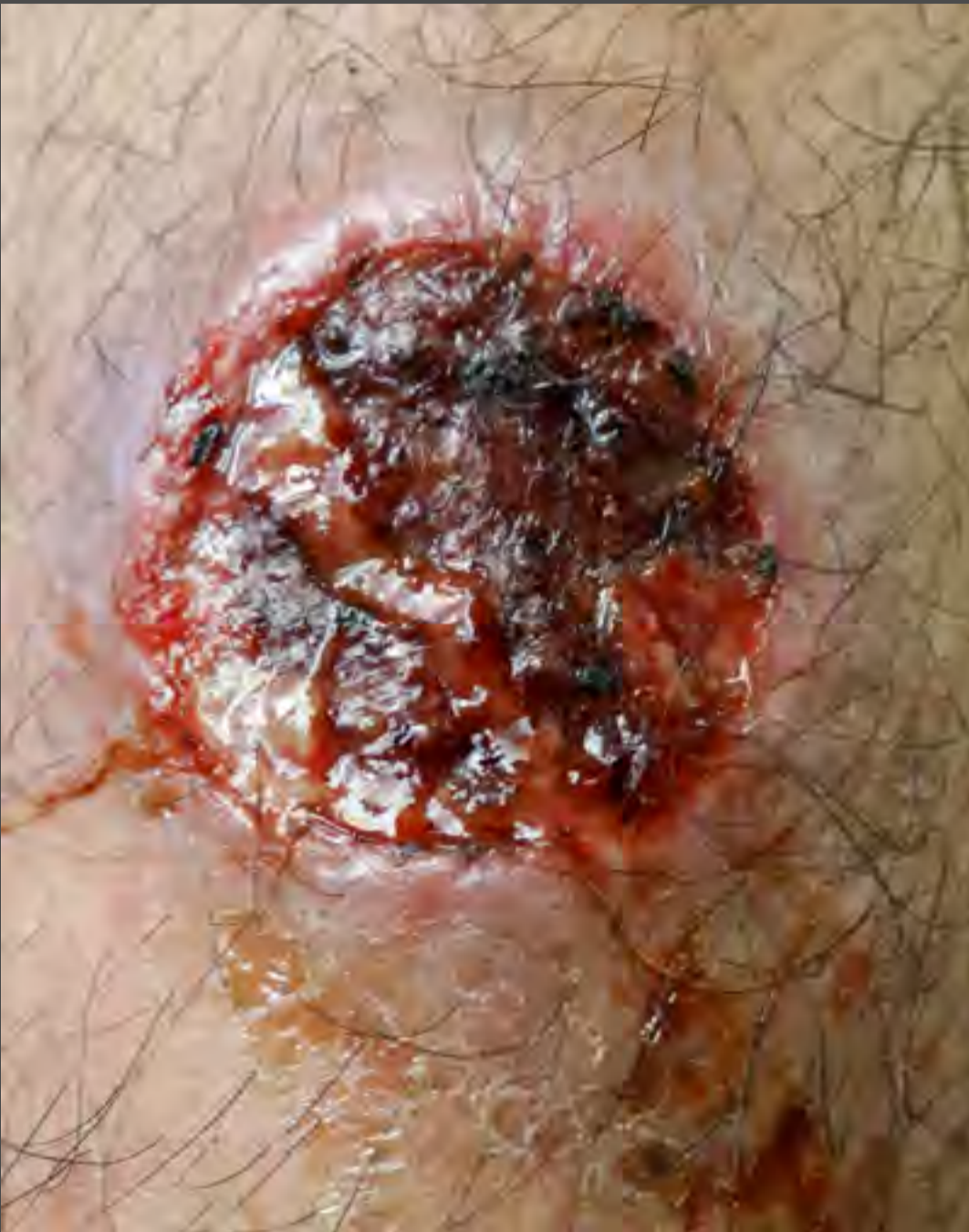**Figure 3.48.**

Several lesions at different stages of development, some quite close to others.

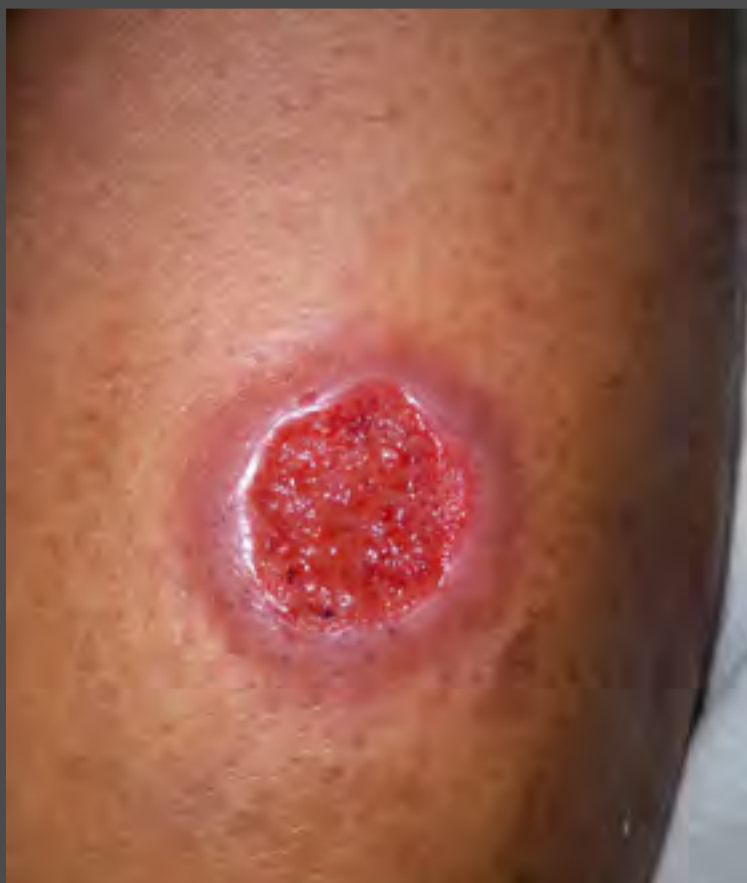

**Figure 3.49.**

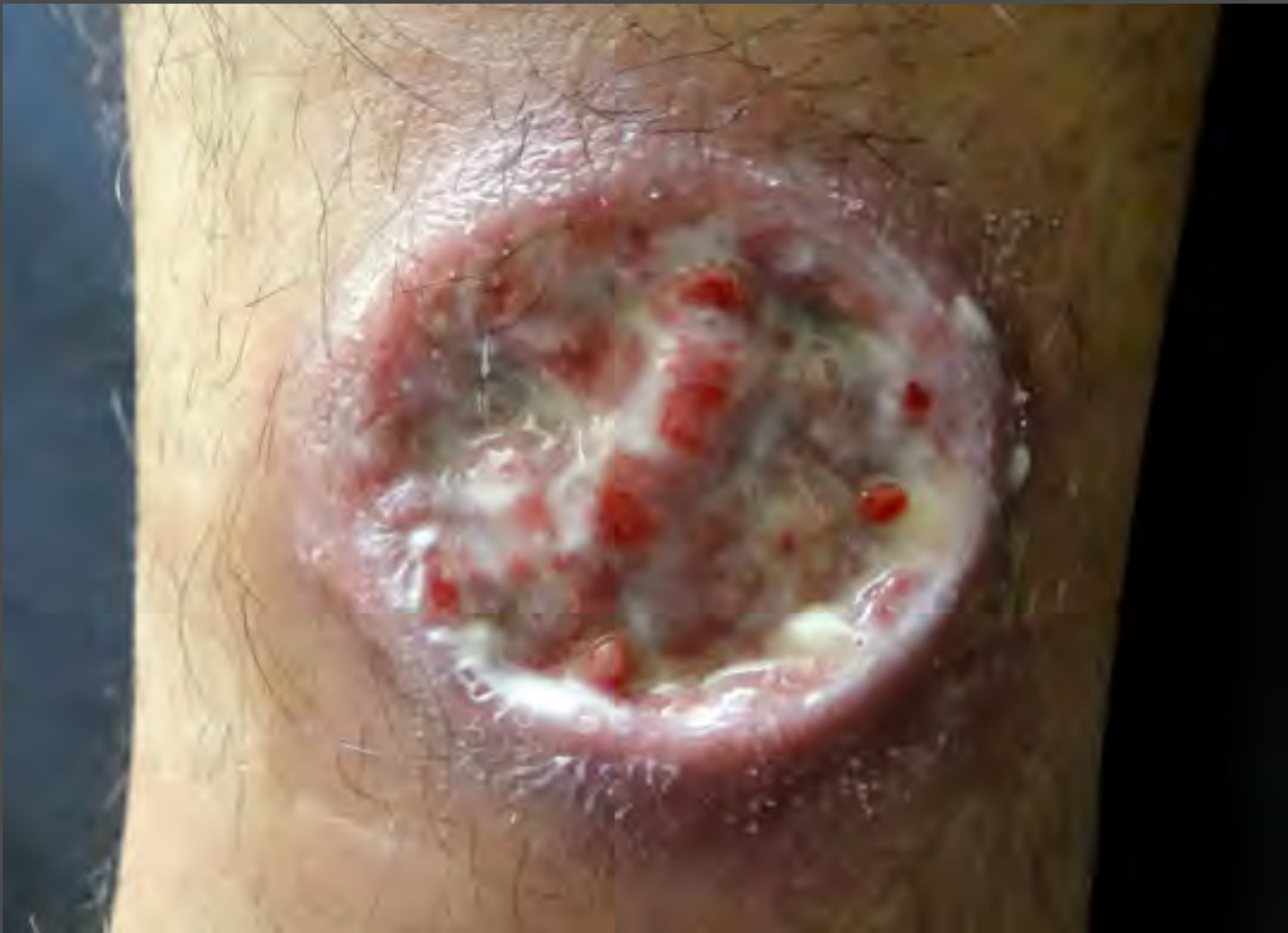Multiple lesions, round ulcers with corded edges, infiltrated base, and granular center



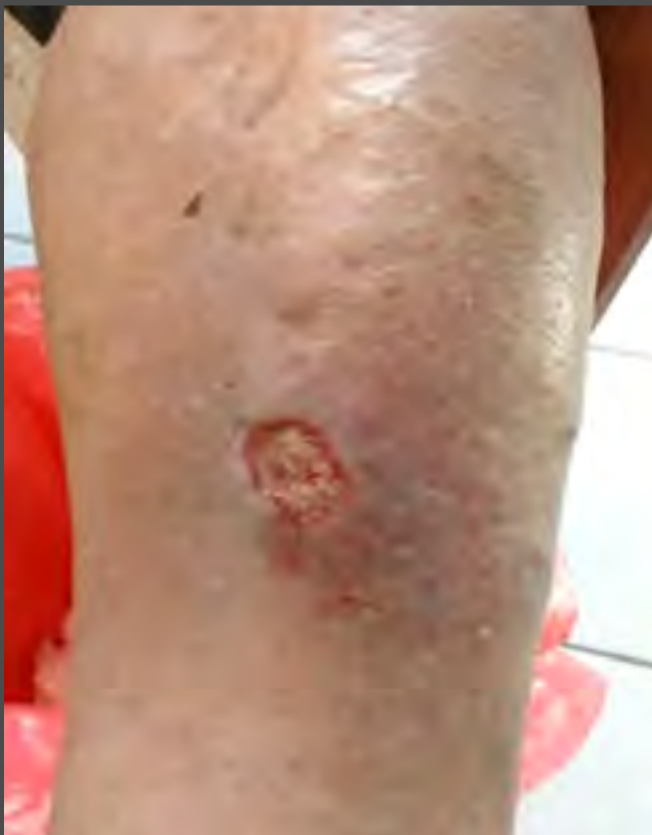**Figure 3.50.**  
Rounded ulcer 4 cm in diameter,  
with distinct edges and discrete  
infiltration, covered by abundant  
serosanguineous crusts



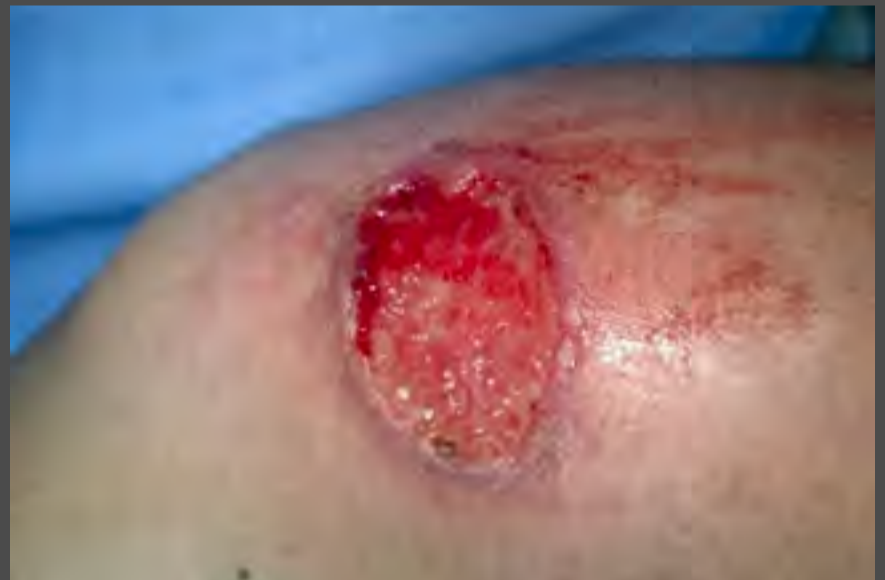**Figure 3.51.**  
Ulcer with raised edges,  
granulomatous floor,  
accompanied by pruritus.



**Figure 3.52.** Cutaneous leishmaniasis with acute bacterial superinfection with erythema, edema, warmth, purulent secretions, and desquamation. This occurs in up to 25% of leishmaniasis ulcers due to failure to remove crusts or perform proper cleansing.

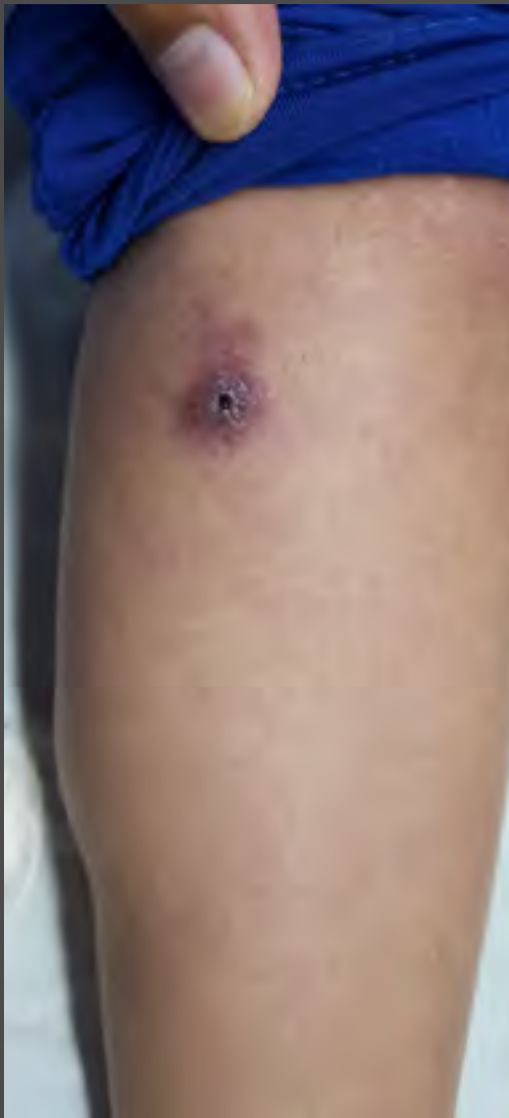

**Figure 3.53.** Multiple lesions around the knee, with defined raised edge, up to 1.5 cm in diameter, granular floor, and moist discharge, surrounded by crusts; not painful or itchy. Visible inflammation and desquamation of the skin around the lesions.

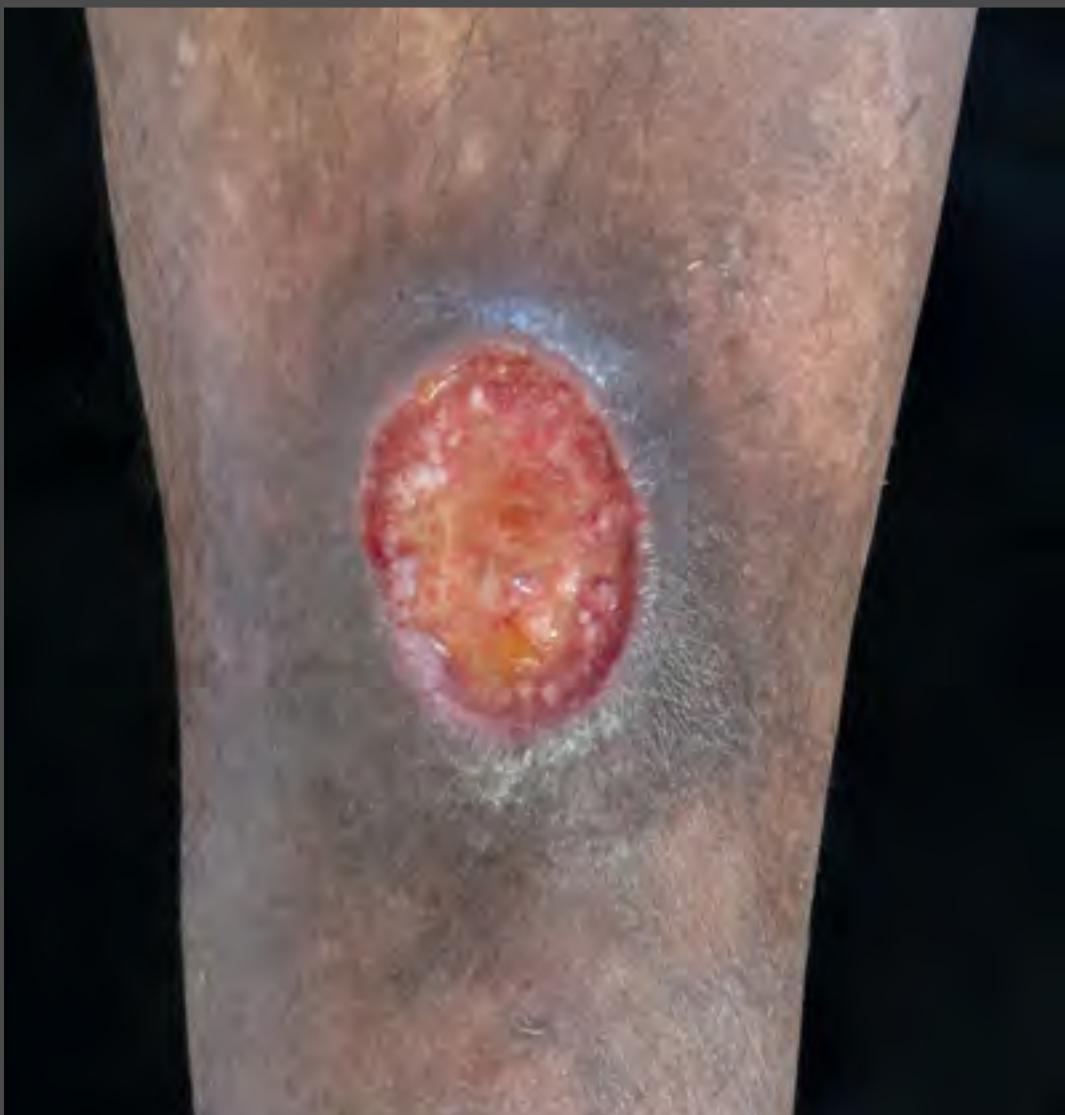
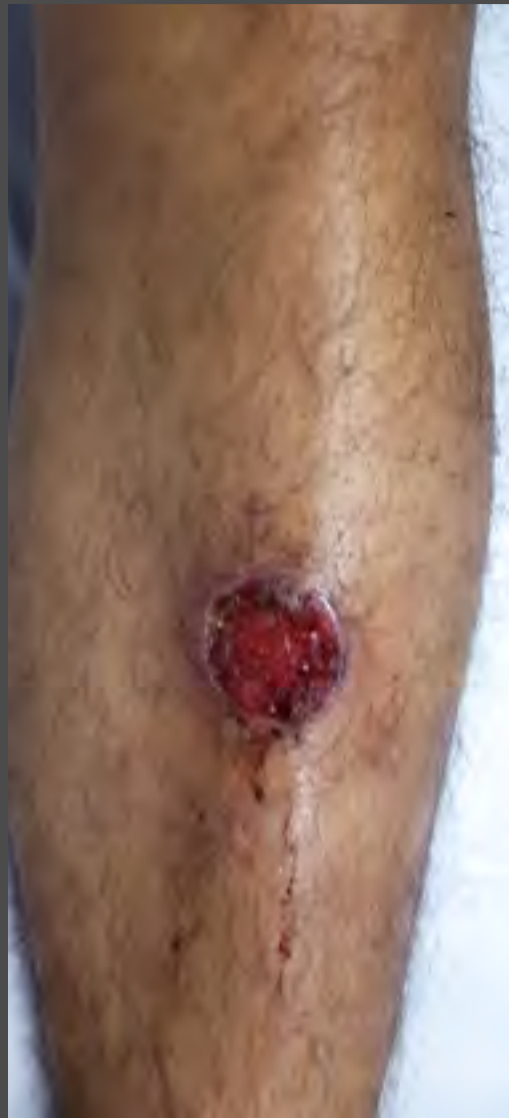
**Figure 3.54.** Ulcer on knee with infiltrated, reddish-purplish edge and bleeding center (*Leishmania* (V.) *braziliensis* complex)

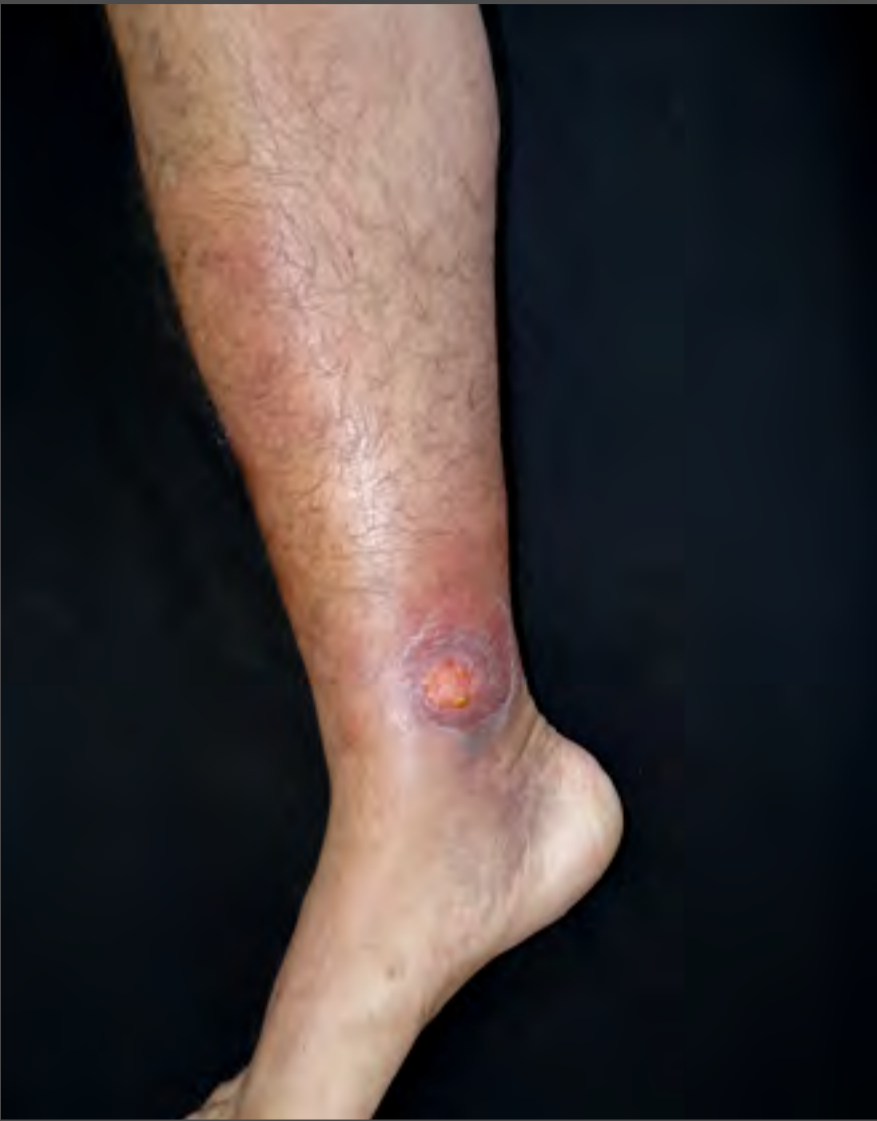**Figure 3.55.**  
Crusty ulcer with erythematous edge on leg (*Leishmania (V.) braziliensis* complex)



**Figure 3.56.**  
Ulcer with infiltrated erythematous edges, and granular and exudative floor, on leg (*Leishmania (V.) braziliensis* complex)

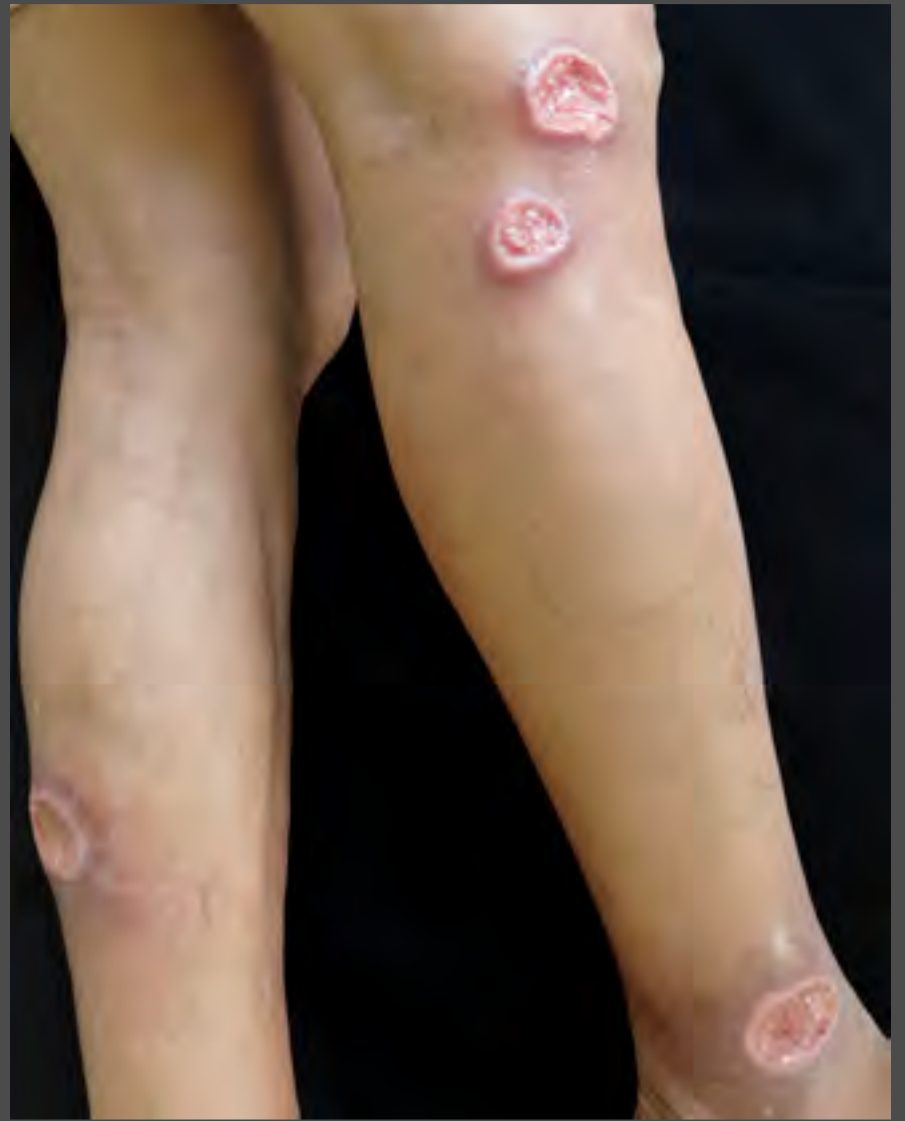

**Figure 3.57.**  
In dark-skinned patients, inflammatory lesions frequently produce residual hyperpigmentation. For this reason, this typical leishmaniasis lesion on the leg makes it essential to differentiate it from a venous ulcer of stasis dermatitis.



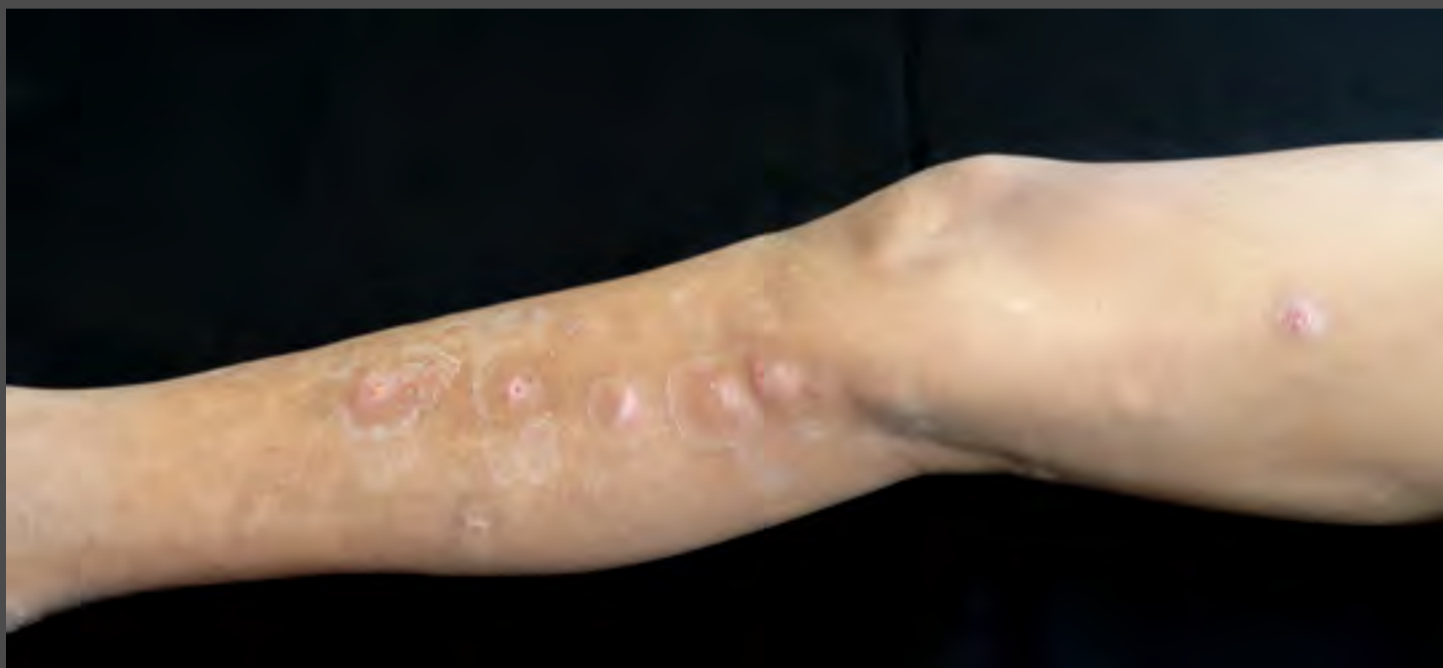**Figure 3.58.**

Hyperpigmentation usually does not occur around the lesion when the skin is lighter.



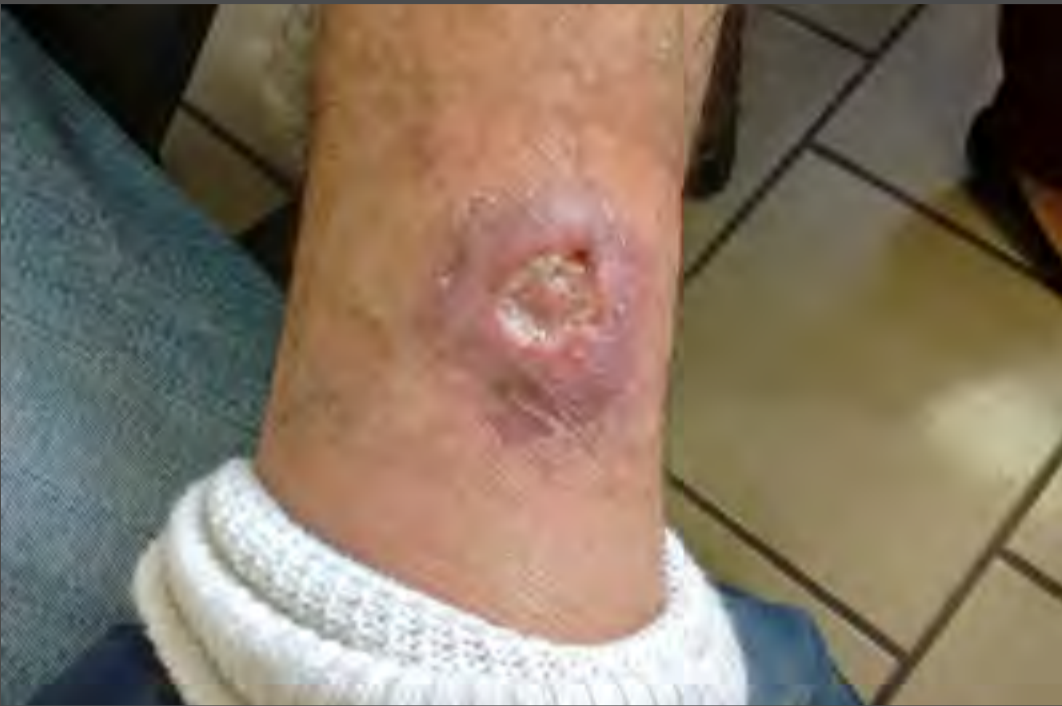**Figure 3.59.**

Lesions that are very characteristic of cutaneous leishmaniasis, at the same stage of development, which suggest their origin from simultaneous bites.

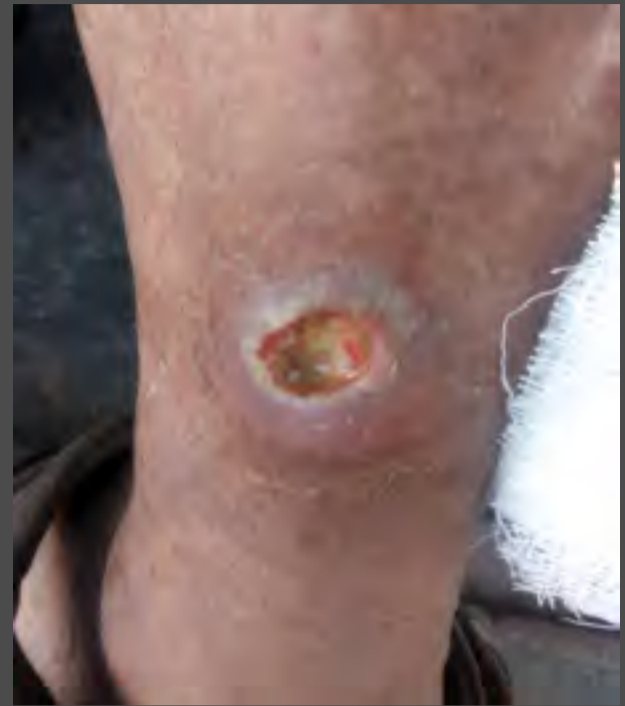

**Figure 3.60.**

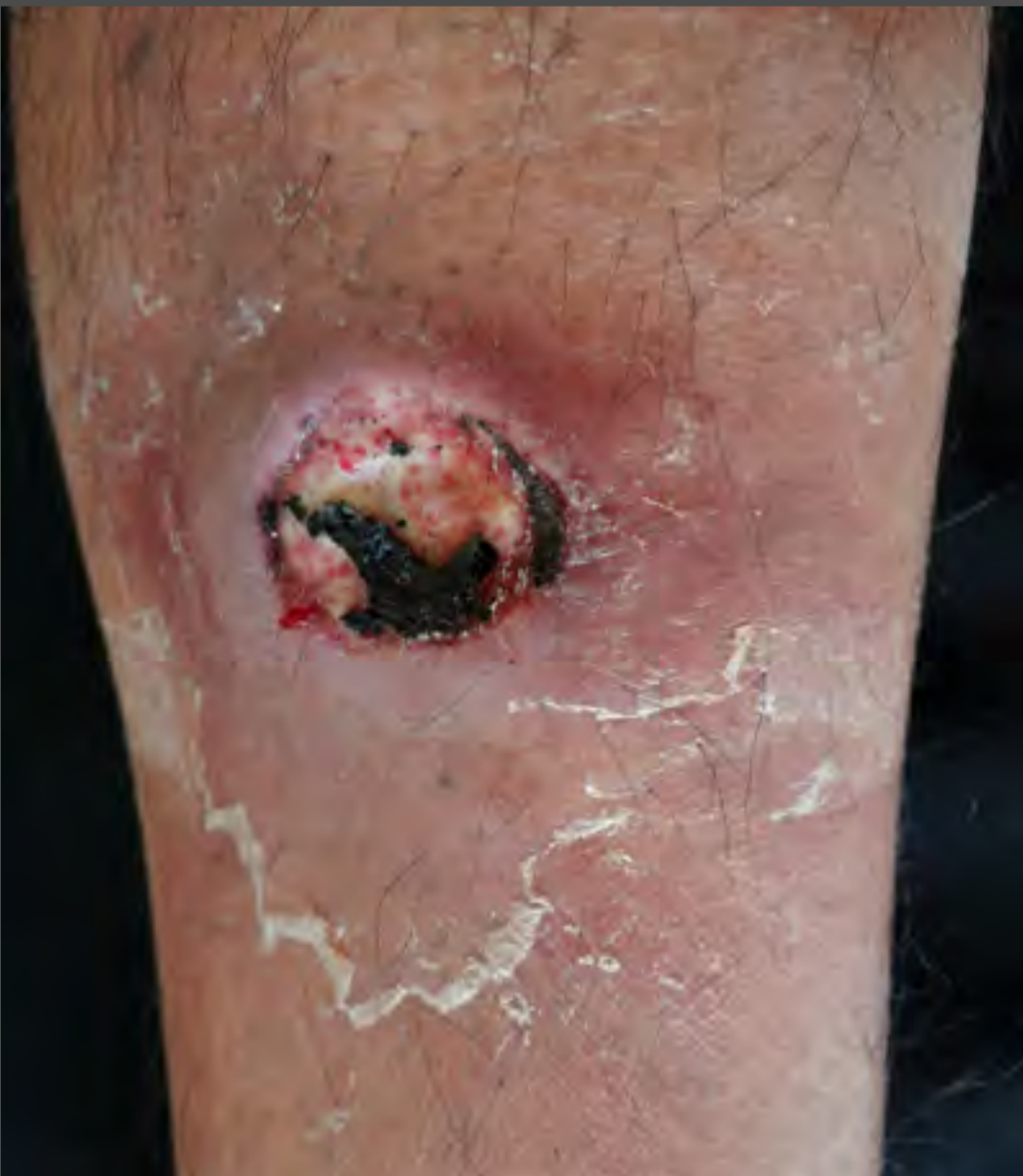Lymphatic dissemination can also occur on the legs. Ascending path with erythematous, papulonodular lesions and perilesional desquamation.



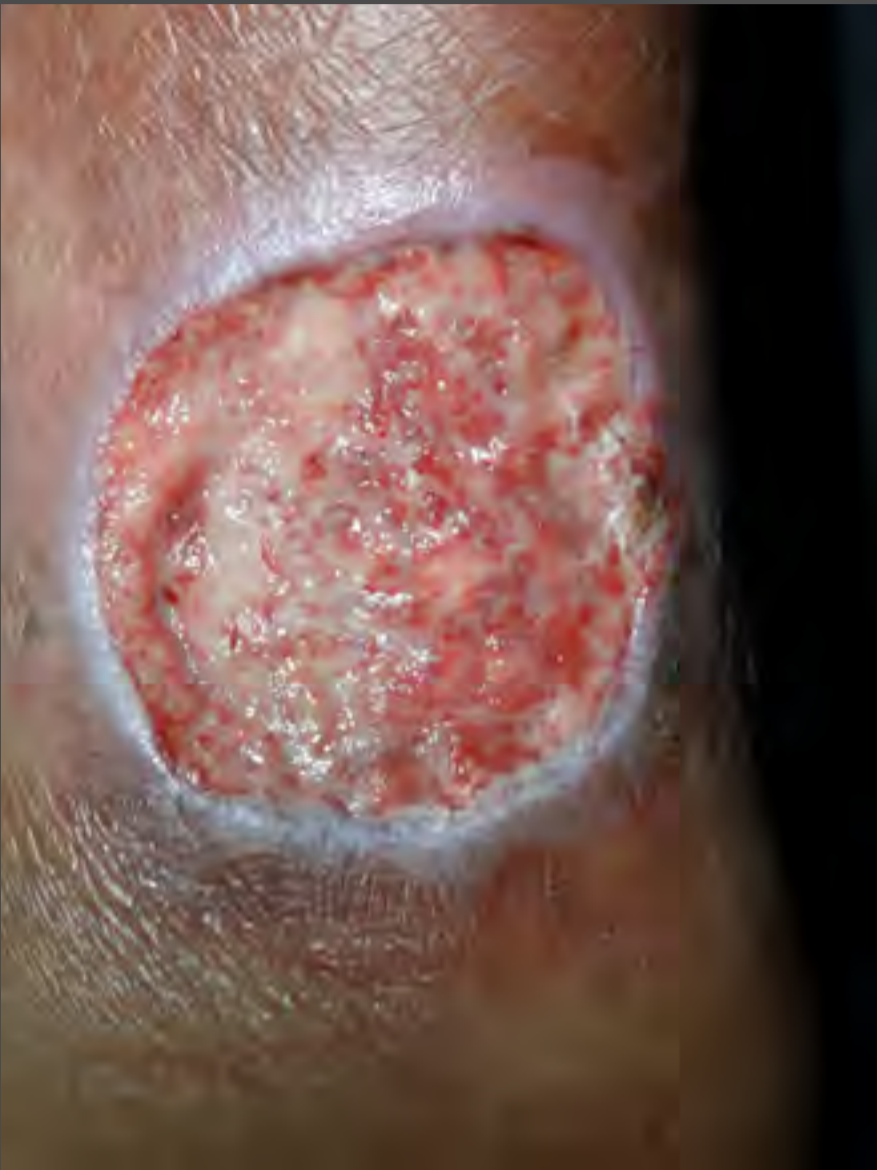**Figure 3.61.**  
Lesion of 2 cm, with seropurulent secretions and crusts, before treatment (*Leishmania (L.) mexicana*)



**Figure 3.62.**  
Asymptomatic punched-out ulcer, 1.5 cm in diameter, with a defined raised edge and granular floor with discharge. Inflammation and crusts on the margins.

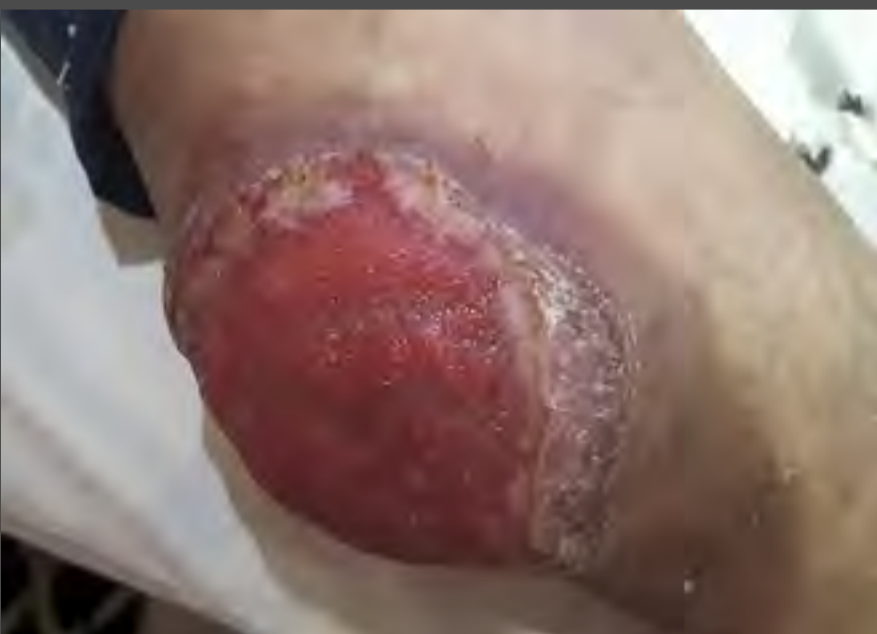

**Figure 3.63.**  
Up to 25% of leishmaniasis ulcers may become superinfected with bacteria if the crust is not removed or if it is not properly cleansed. In this case, signs of acute inflammation extend around the ulcer on the leg.



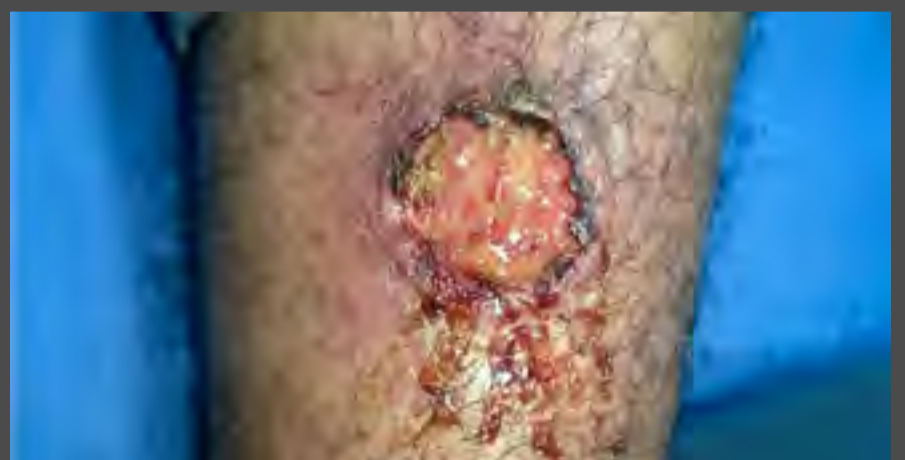**Figure 3.64.**

Characteristic lesion. Round or oval ulcer 2 to 6 cm in diameter, with raised edges, cordoned, infiltrates, and crateriform center with granulation tissue; it also shows peripheral infiltration and erythema.



**Figure 3.65.**

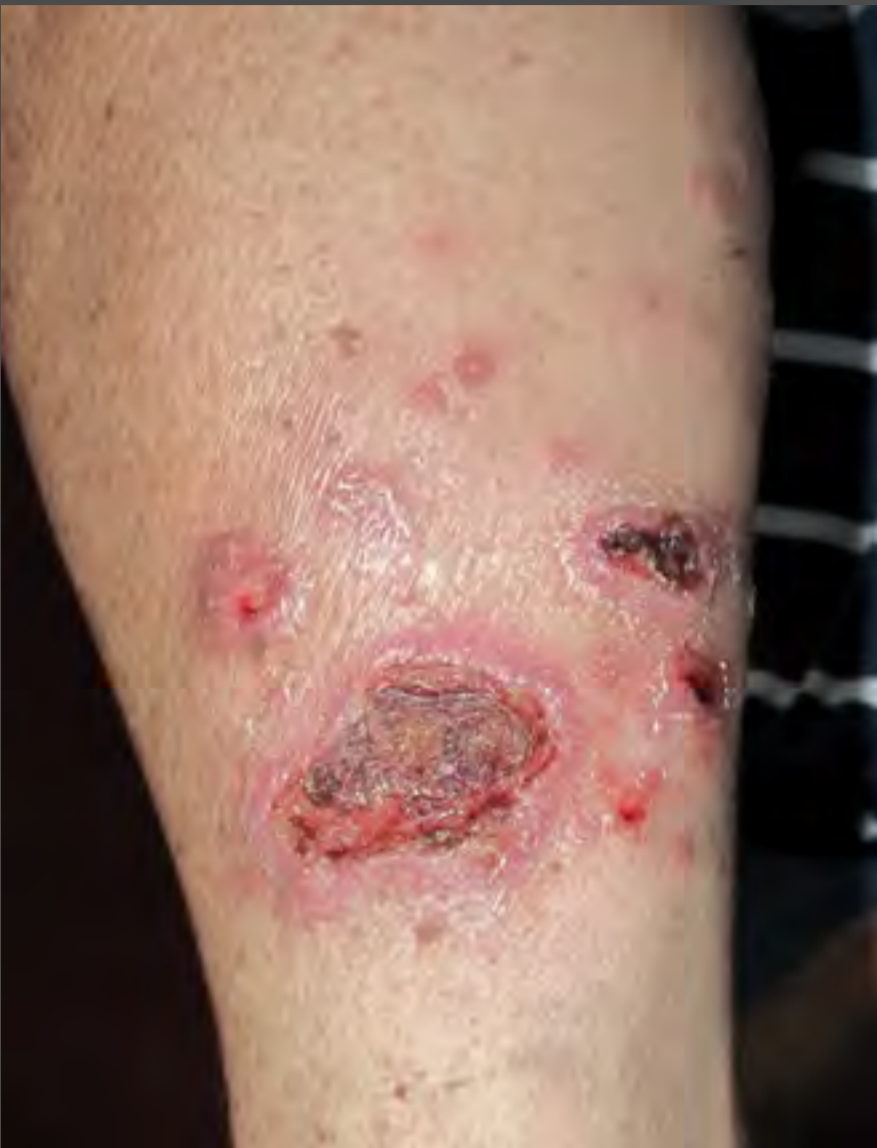Erythematous ulcer on the knee



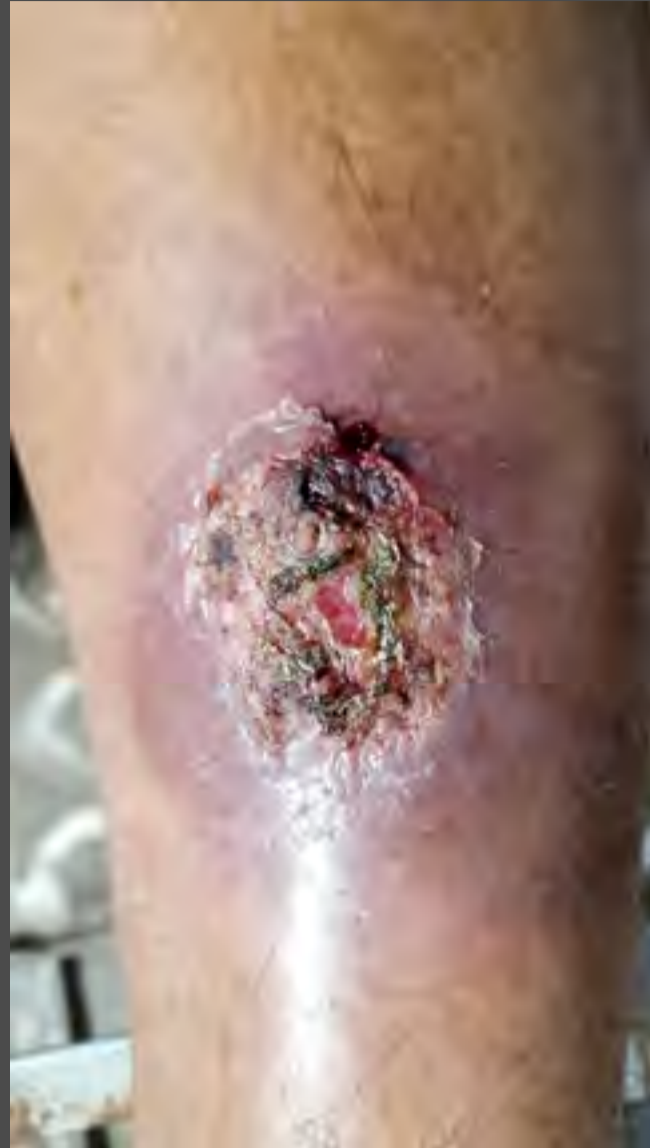**Figure 3.66.**

Ulcer with infiltrated, erythematous edges and secretory, granulomatous floor (*Leishmania (V.) braziliensis* complex)

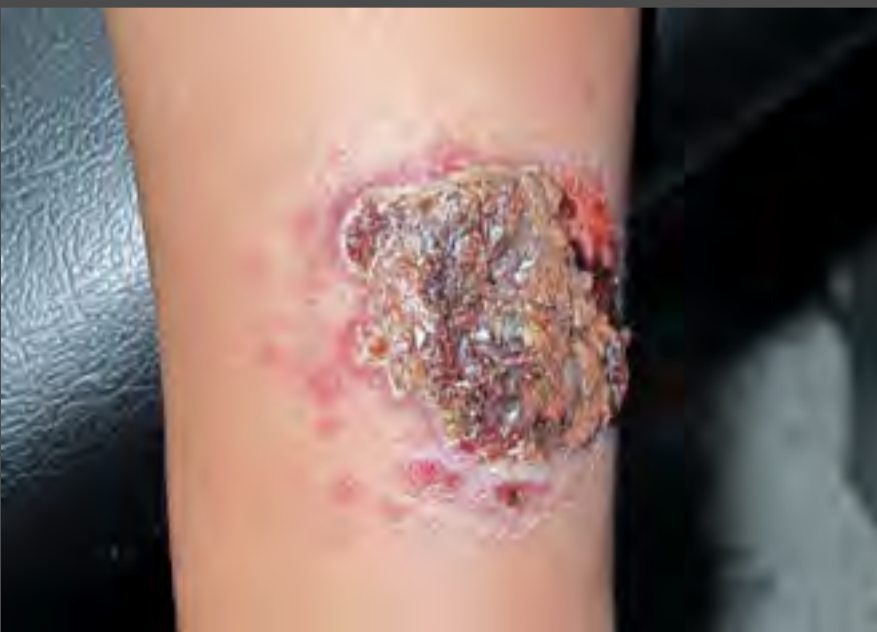



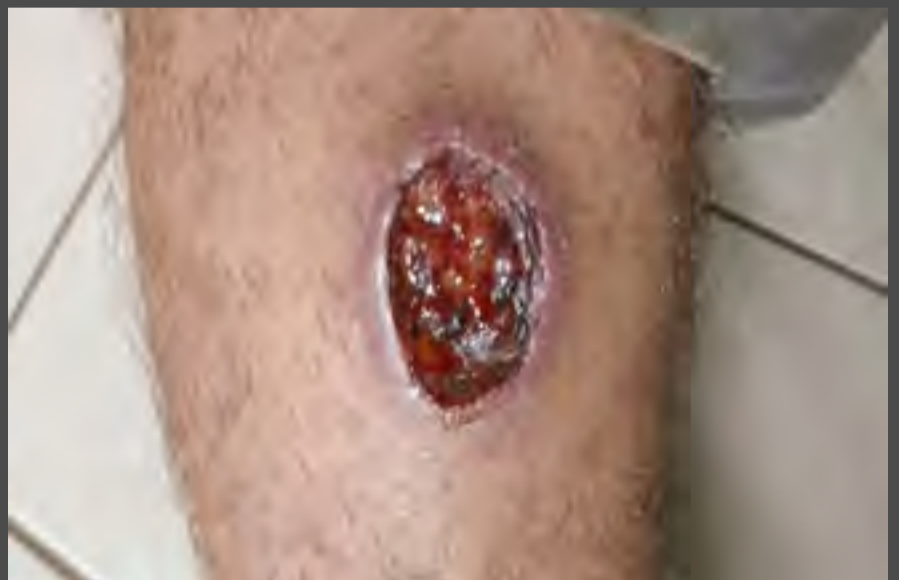**Figure 3.67.**  
Multiple small ulcers around a larger ulcer than may reflect extension by contiguity or by seeding during scratching.



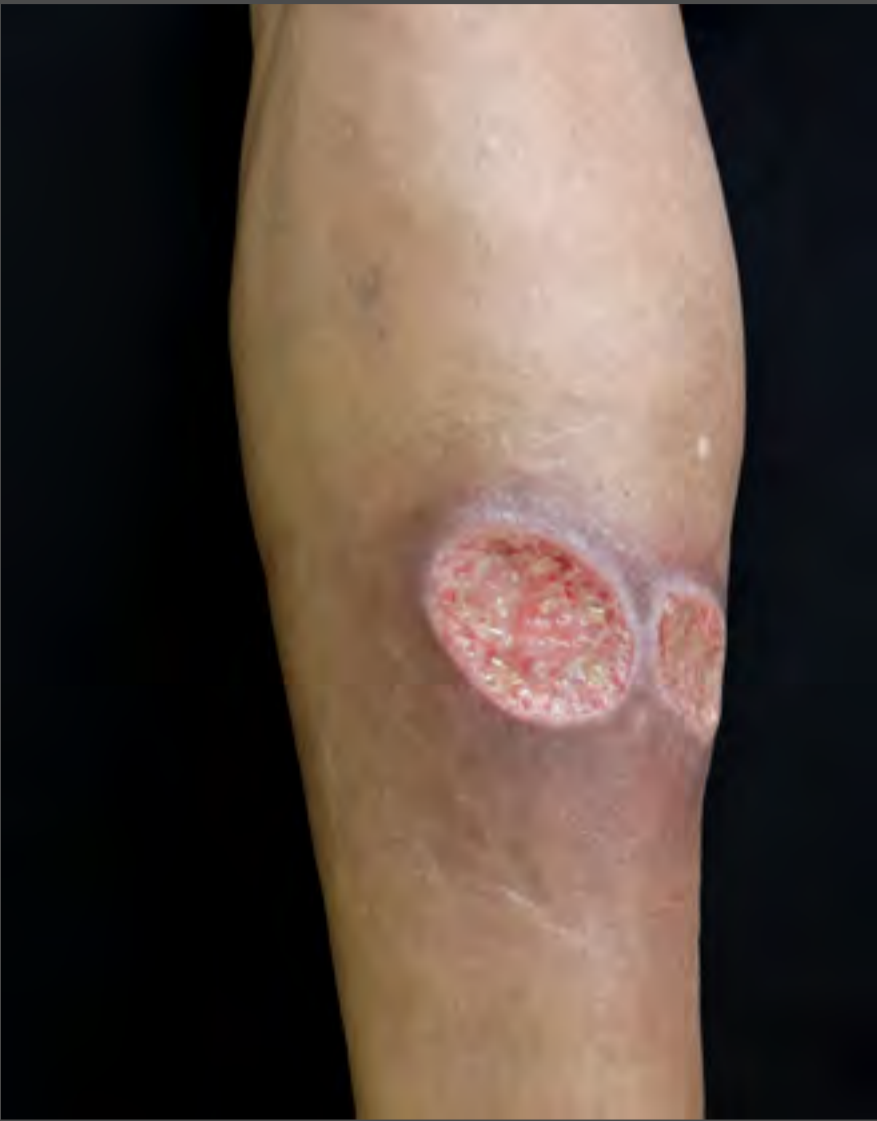**Figure 3.68.**  
Warty, crusty plaque with erythematous edges (*Leishmania (V.) braziliensis* complex)



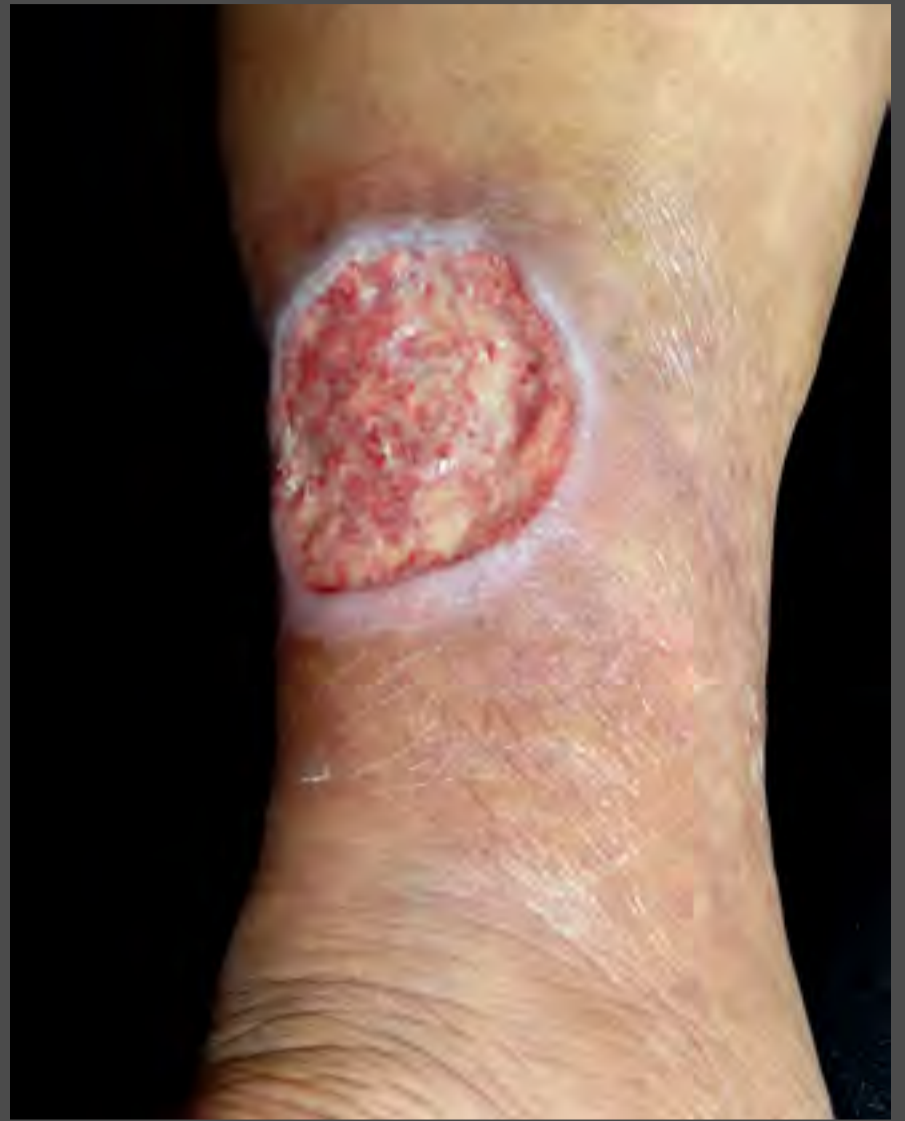**Figure 3.69.**  
Ulcerous-crusty lesion with peripheral satellite lesions on left leg



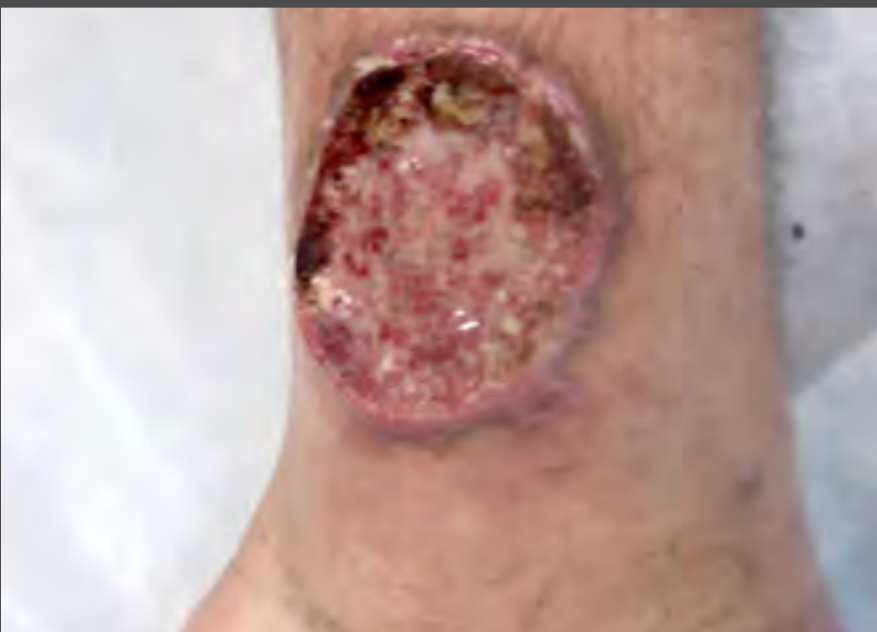**Figure 3.70.**  
Oval, asymptomatic ulcer 3.5 cm in diameter, with a granular floor and covered with some crusts and mild perilesional erythema



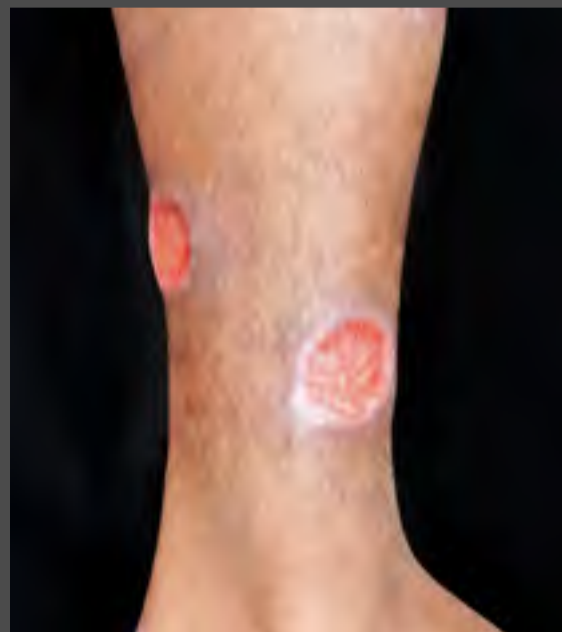**Figure 3.71.**  
Two adjacent ulcers at the same stage of development, with a characteristic appearance and peripheral erythema



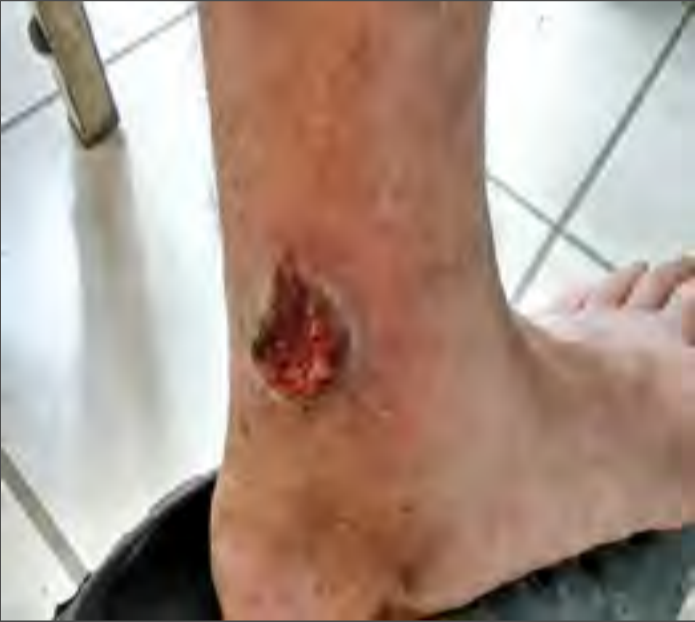**Figure 3.72.**  
Classical ulcer covered with white-yellowish membranes and no bacterial superinfection, on posterior aspect of leg



**Figure 3.73.**  
Cutaneous ulcer almost 4 cm in diameter with abundant fibrinous membranes and exudation

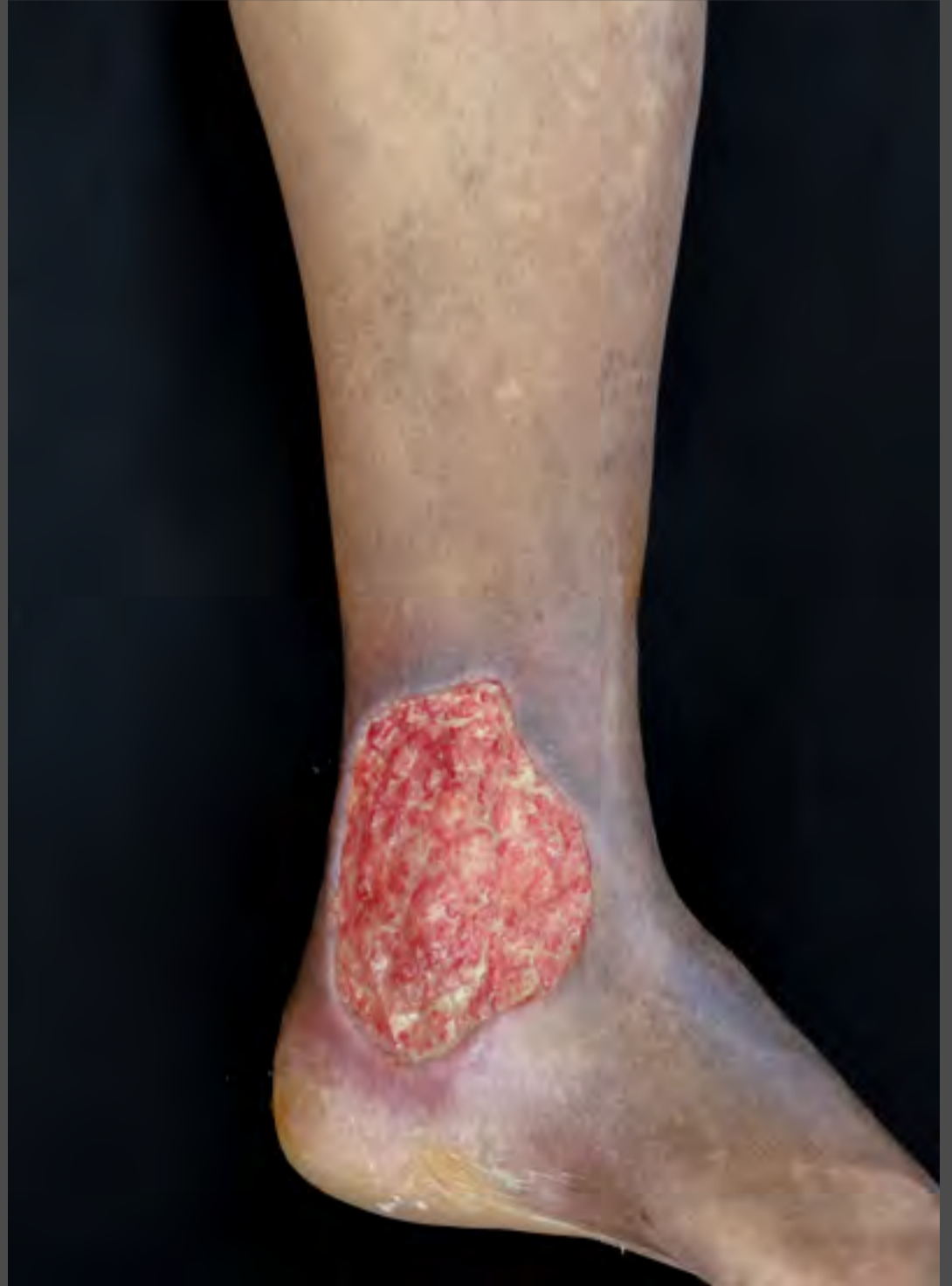

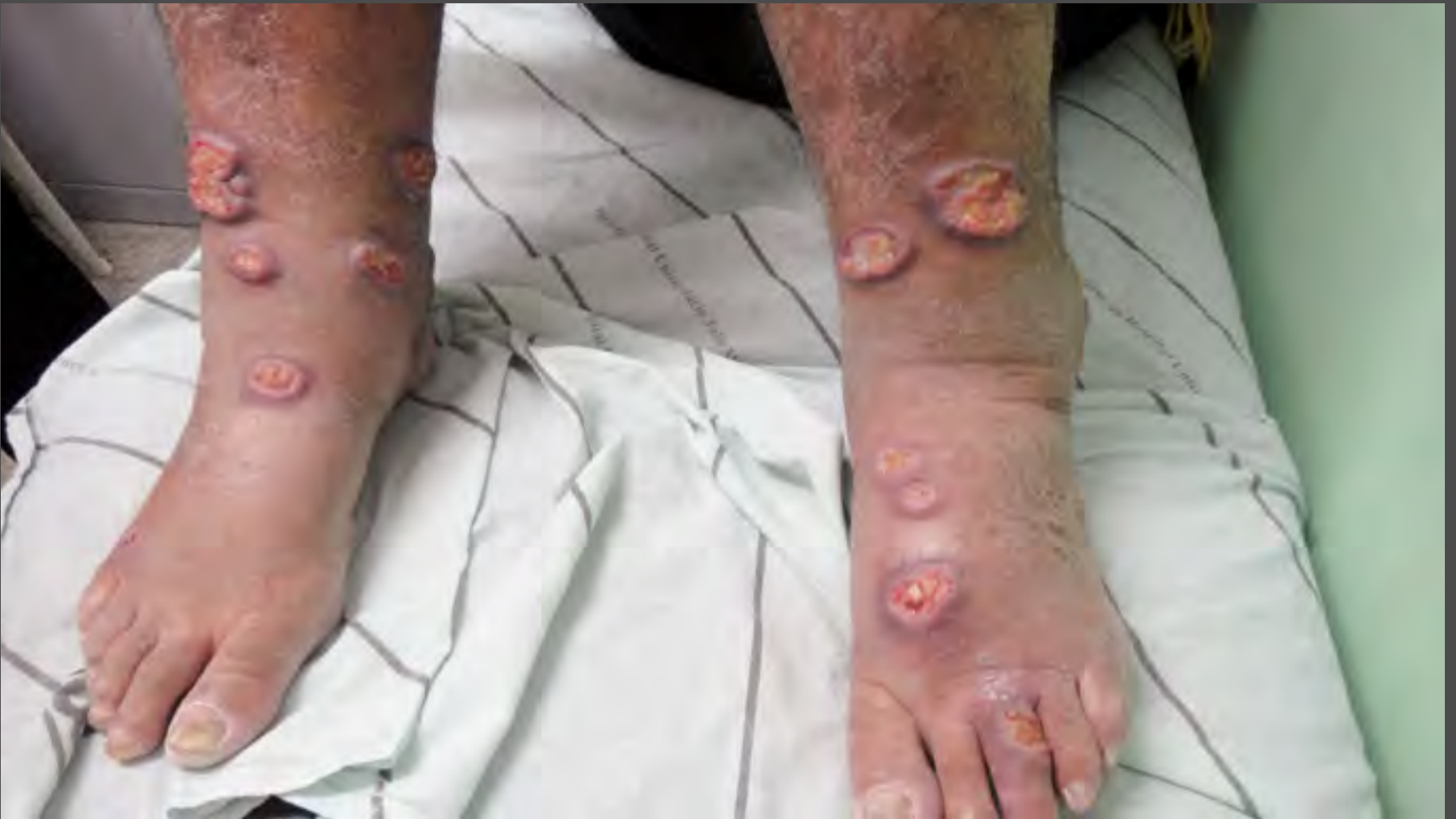**Figure 3.74.**  
Two separate ulcers on the leg at the same stage of development with classical characteristics



**Figure 3.75.**  
Crateriform ulcer 3.5 cm in diameter,  
with granular floor, crusts, and  
perilesional inflammation

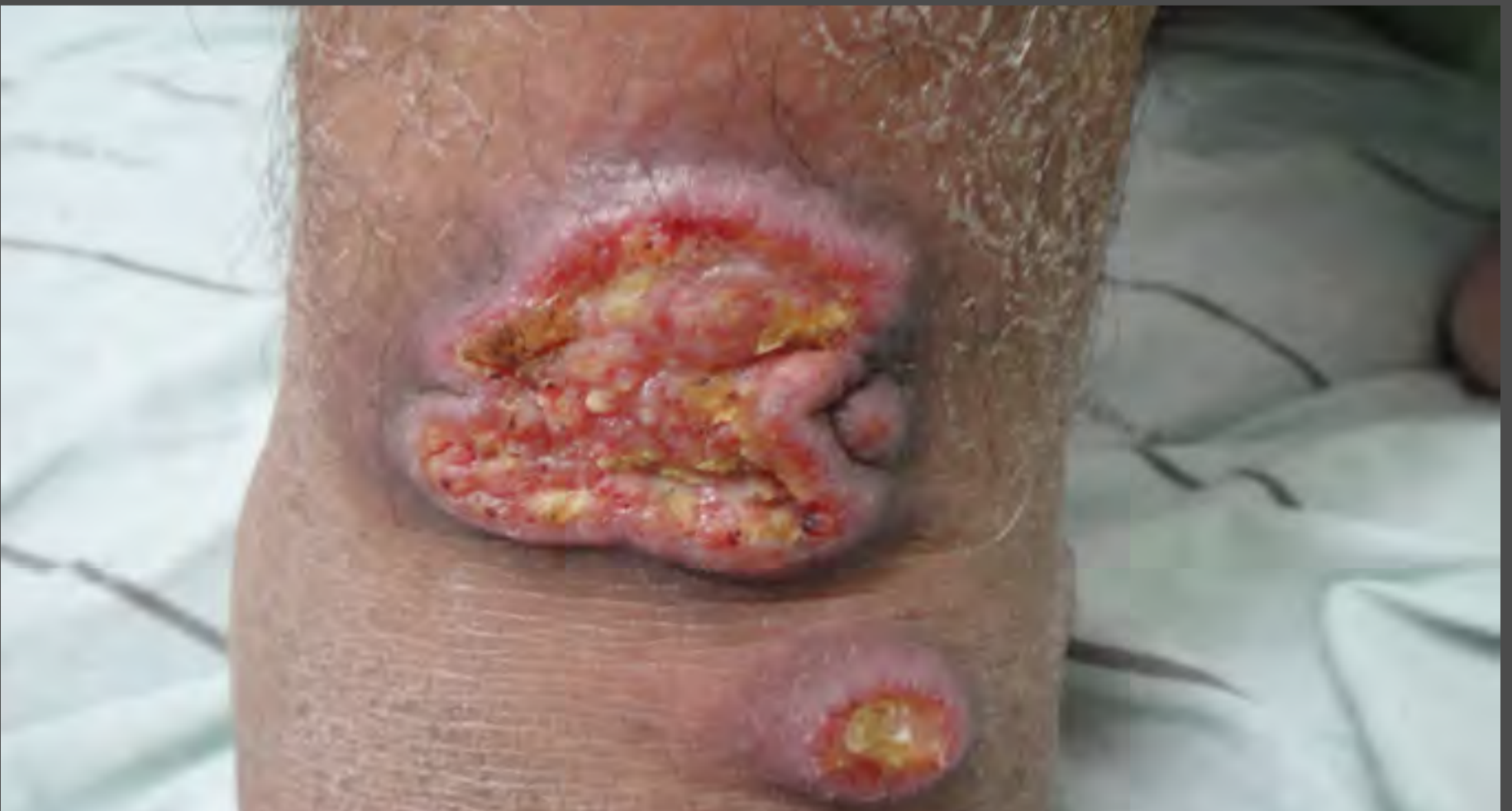**Figure 3.76.**  
On the lower limbs, especially on the  
distal third of the leg or foot, ulcers can be  
very large and slow to heal due to tissue  
hypoxia from the effects of gravity and  
slow blood circulation.

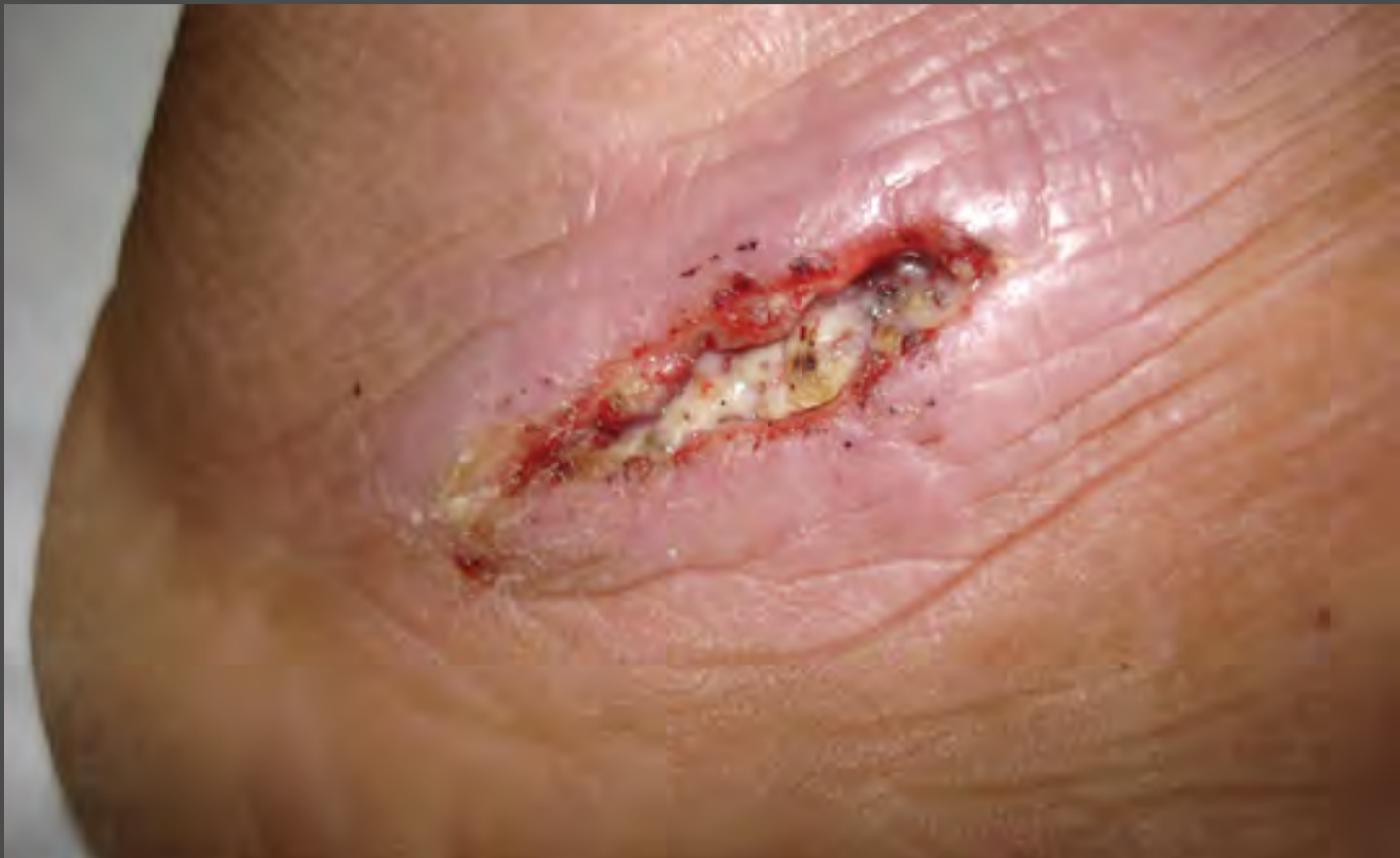



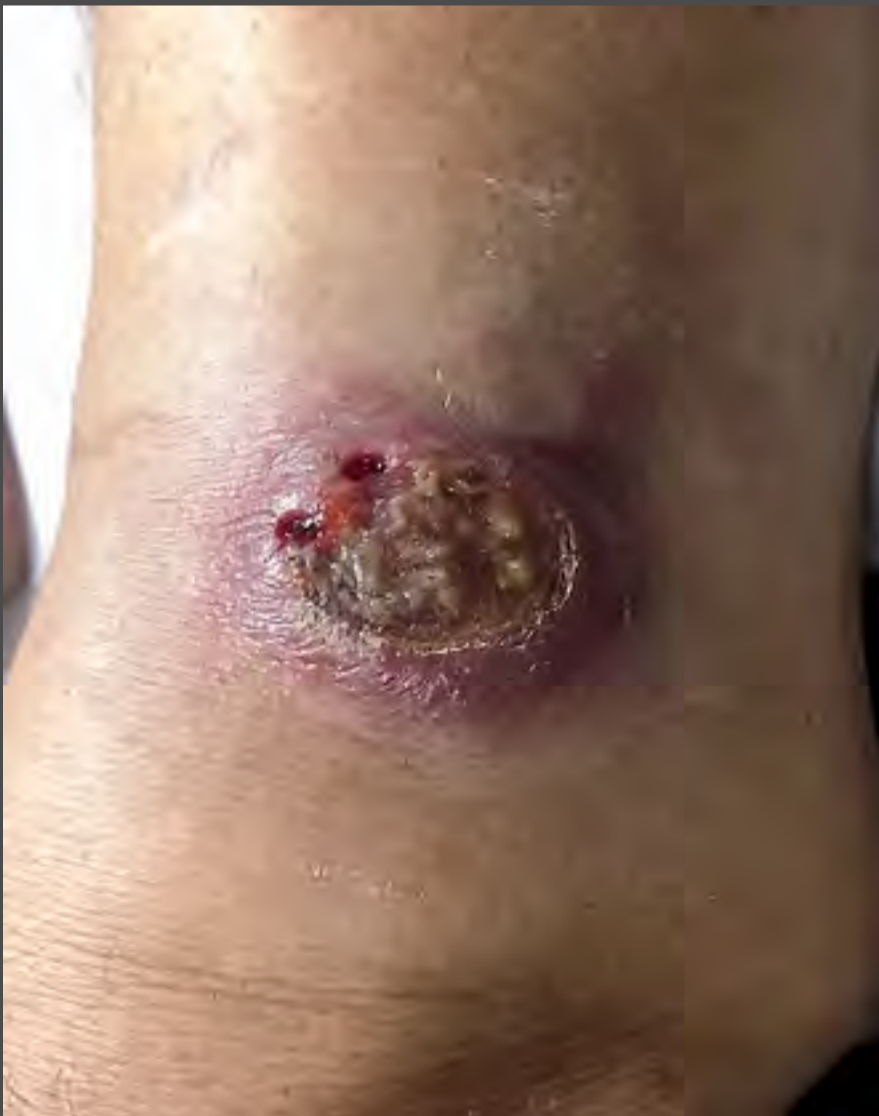**Figure 3.77A.**  
Multiple ulcerous-vegetative lesions on the legs,  
which should be differentiated from sporotrichosis.

**Figure 3.77B.**  
Close-up of a lesion on the right leg



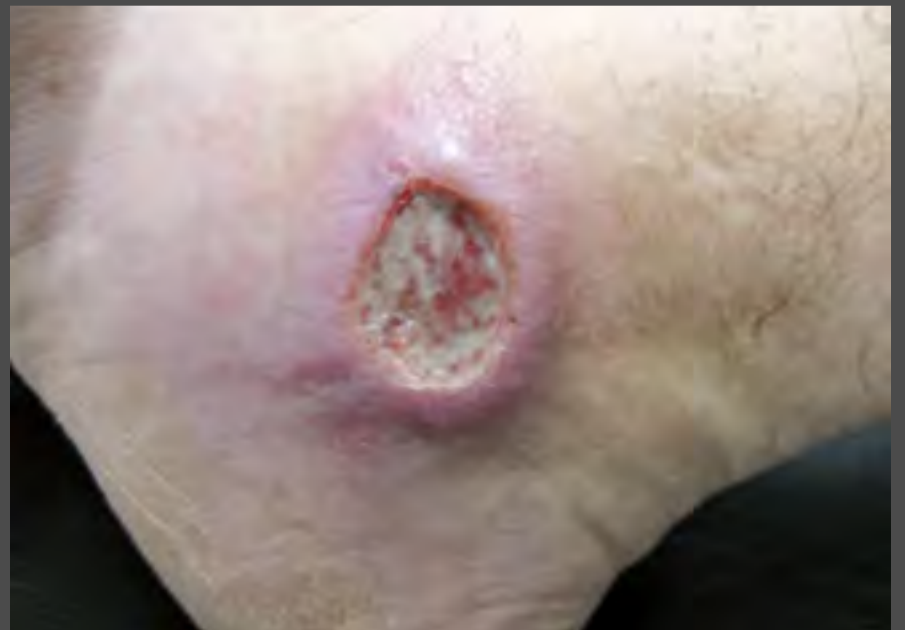

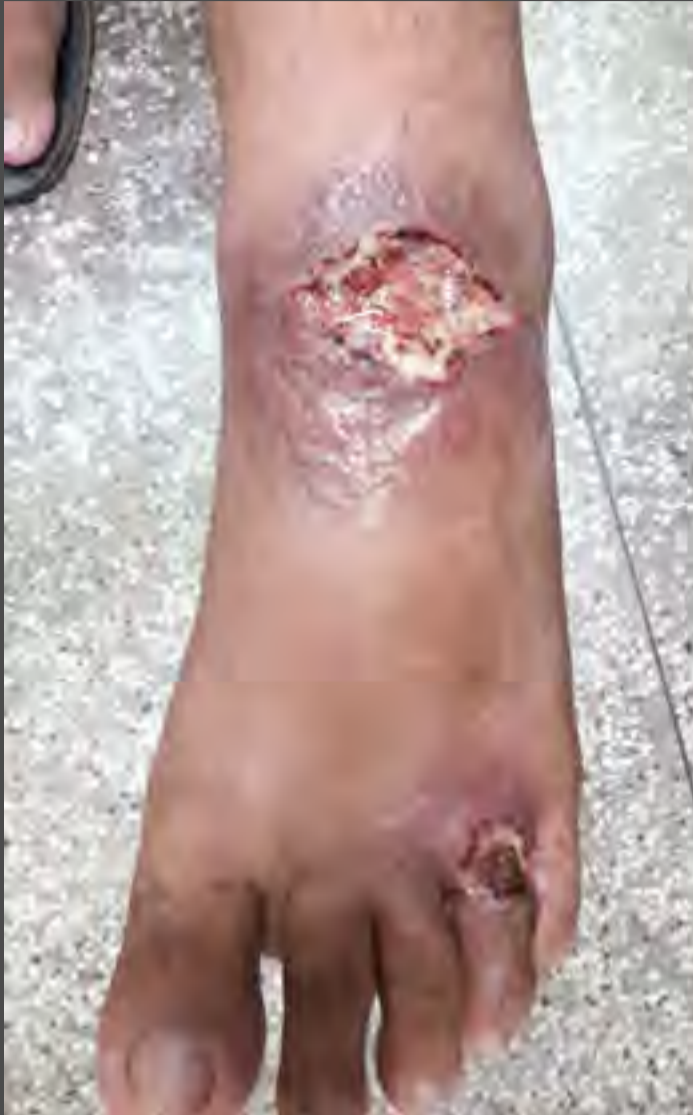**Figure 3.78.**  
Fusiform ulcer located in the inframalleolar region



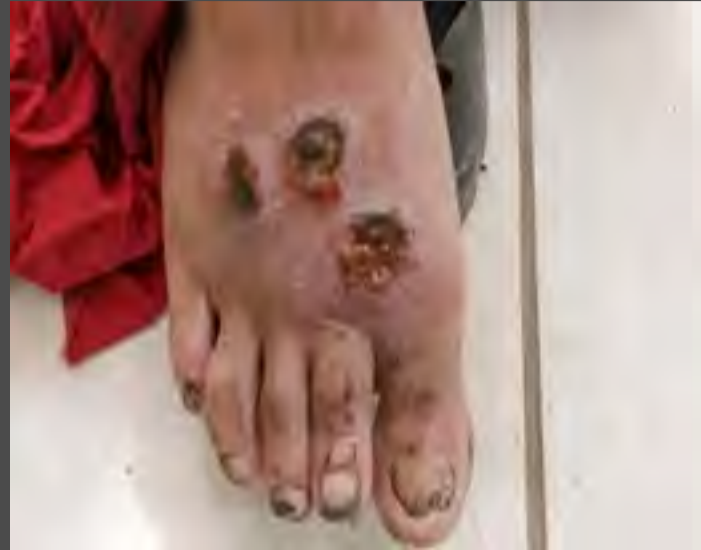**Figure 3.79.**  
Ulcer with bacterial superinfection on right leg  
(*Leishmania (V.) braziliensis* complex)

**Figure 3.80.**  
Ulcer with well-defined, regular, erythematous edges on right malleolar region

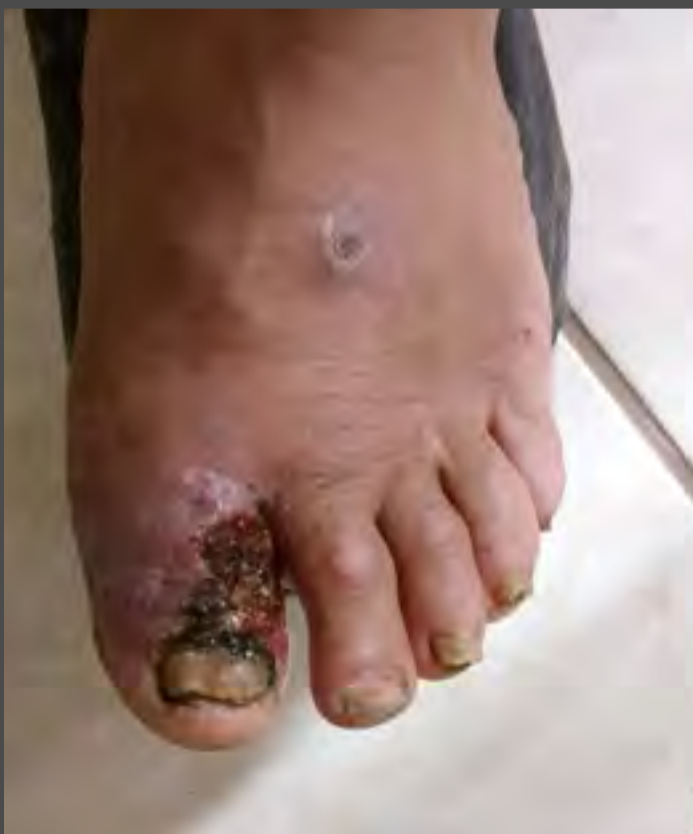



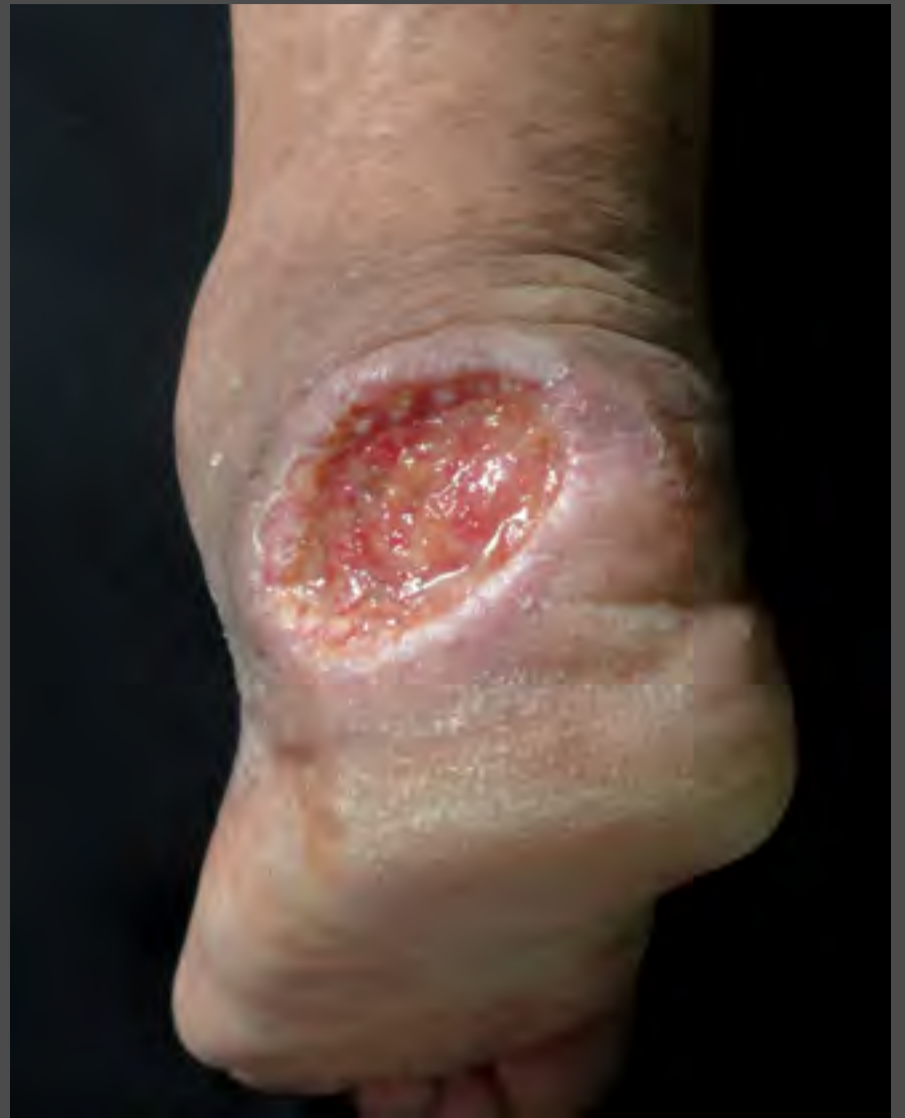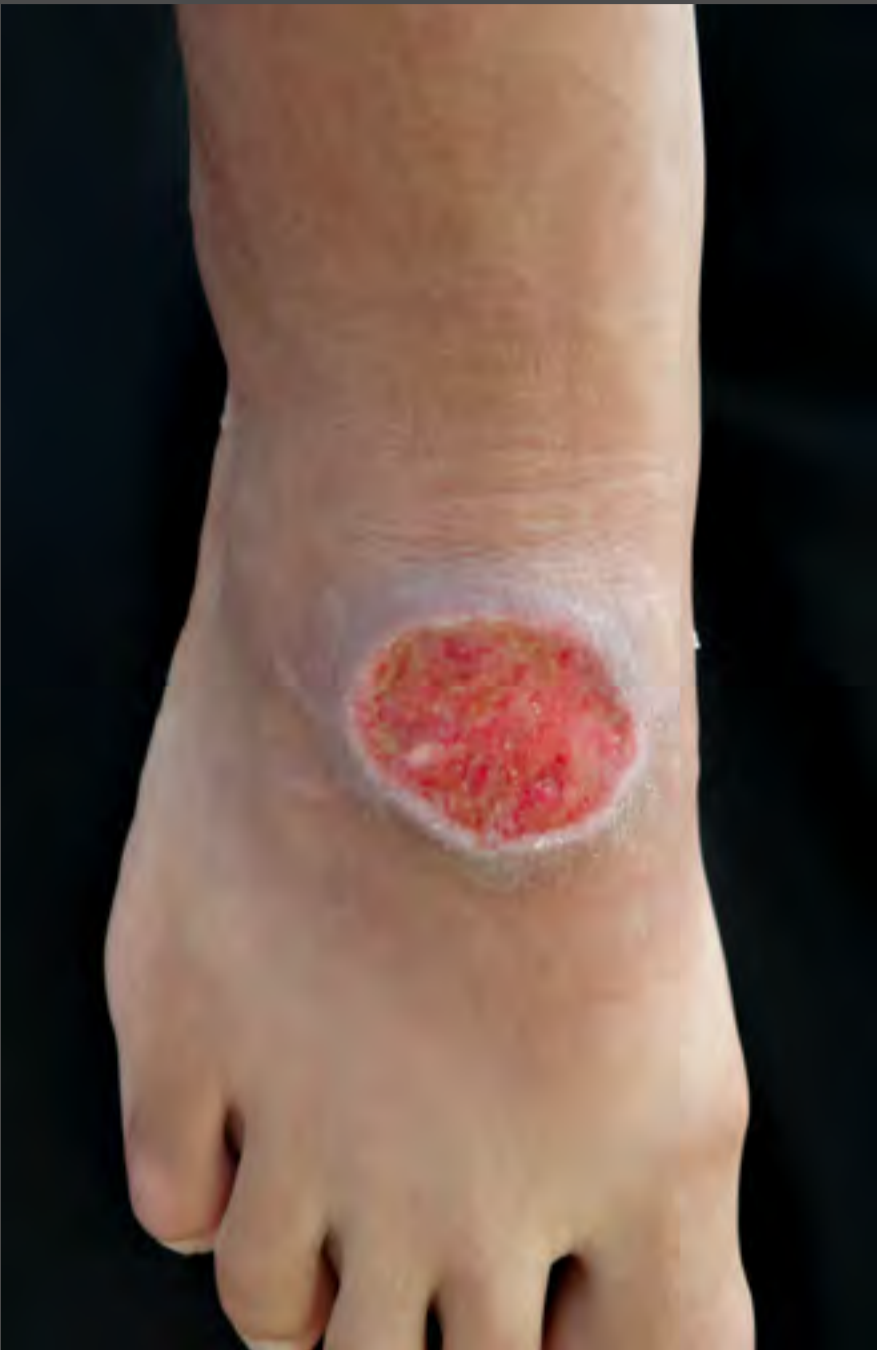**Figure 3.81.**  
Two lesions with bacterial superinfection  
on the foot



**Figure 3.82.**  
Three ulcers covered in dense  
adherent bloody crusts and with  
perilesional inflammation

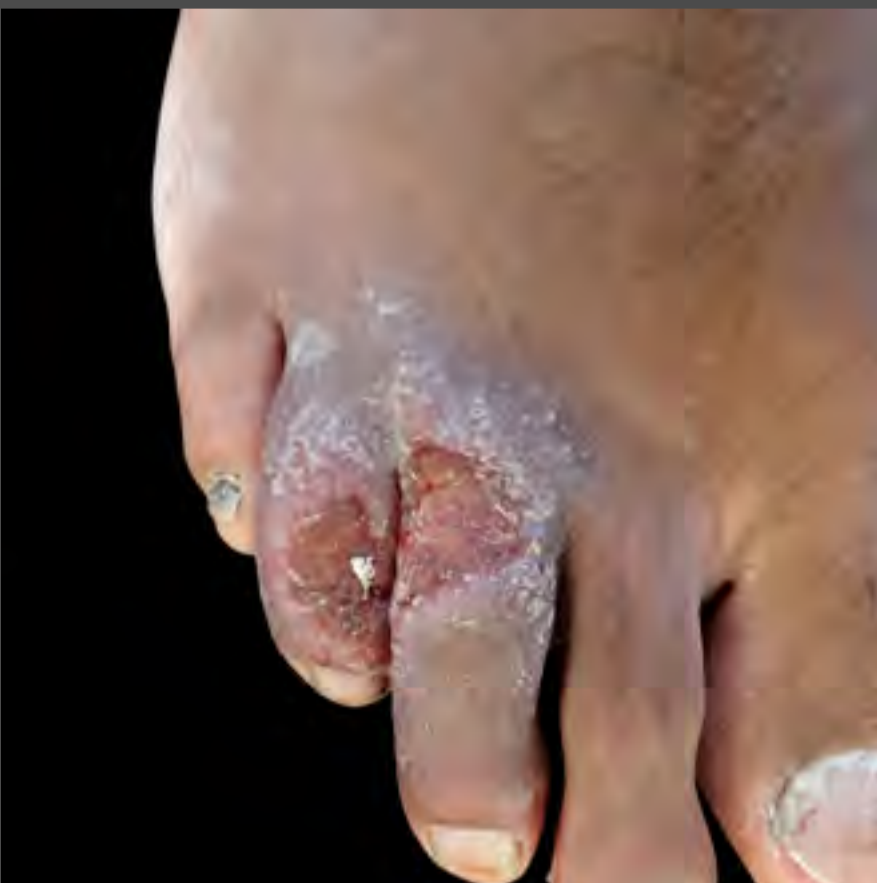

**Figure 3.83.**  
Older ulcer 1.8 cm in diameter, with  
a defined, raised edge extending up to  
the base of the nail of the first toe; not  
painful or itchy. Its floor is granular,  
covered with crusts and exudate. It is  
surrounded by inflammation and crusts.  
There is another small 0.8 cm lesion on  
the top of the foot.



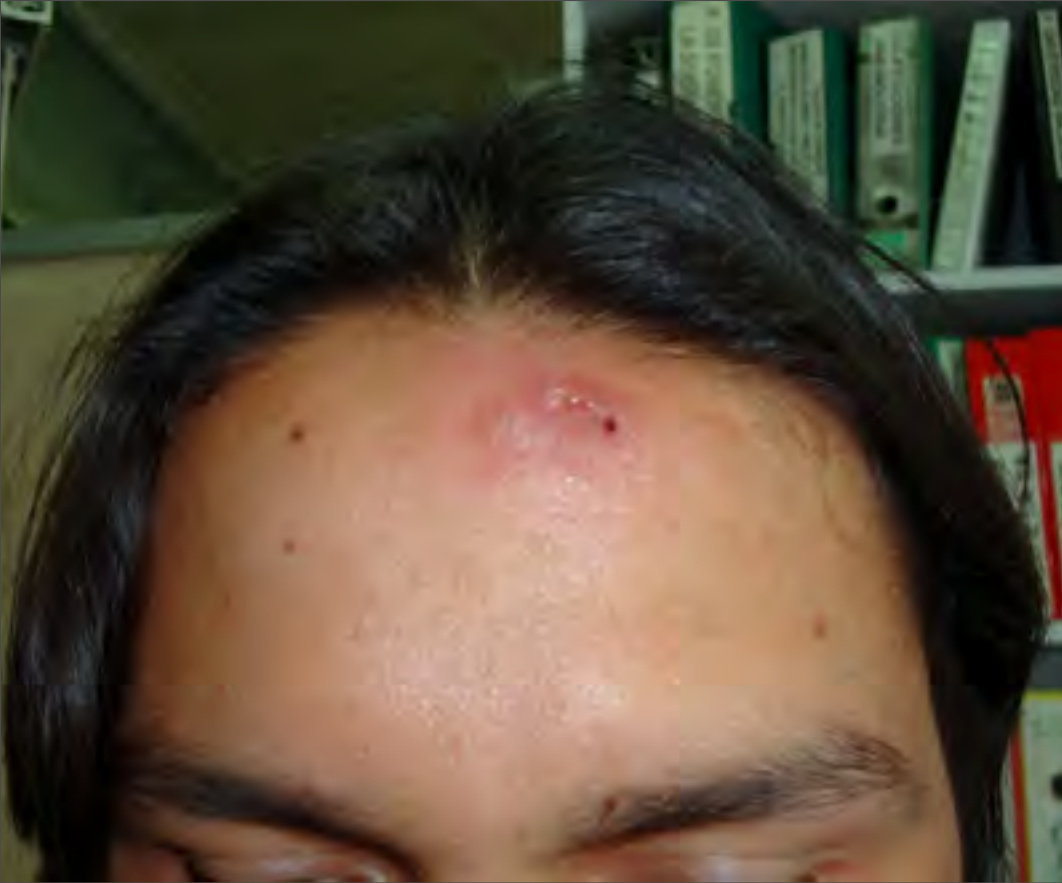**Figures 3.84A and B.**

Characteristic leishmaniasis ulcers on the back of the foot and on the ankle

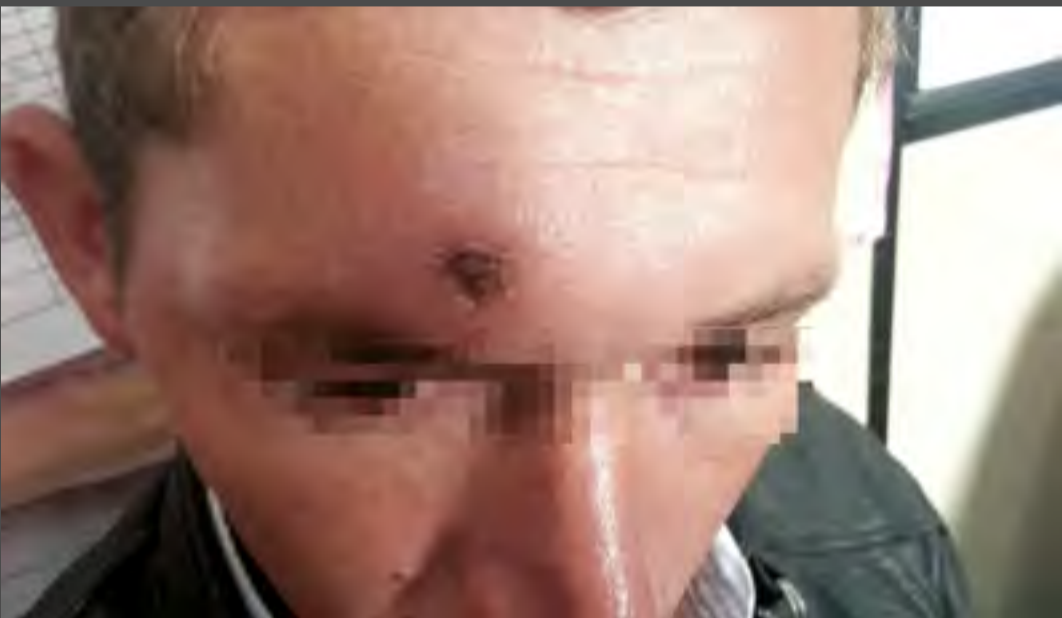

**Figure 3.84C.**

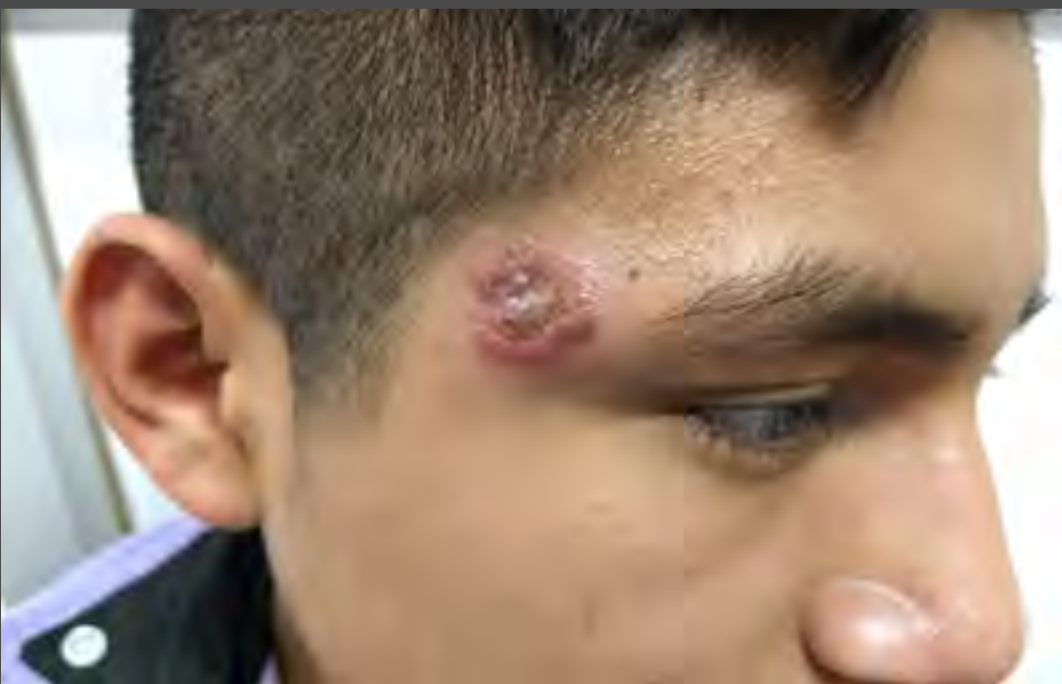Ulcer extends by contiguity over two fingers. Lesions tend to be smaller on the toes, without varying from their typical characteristics. The feet and legs are frequently affected because they are uncovered and exposed to bites.



**Figure 3.85.**  
Small, dry lesion on the upper forehead  
(*Leishmania (L.) mexicana*)

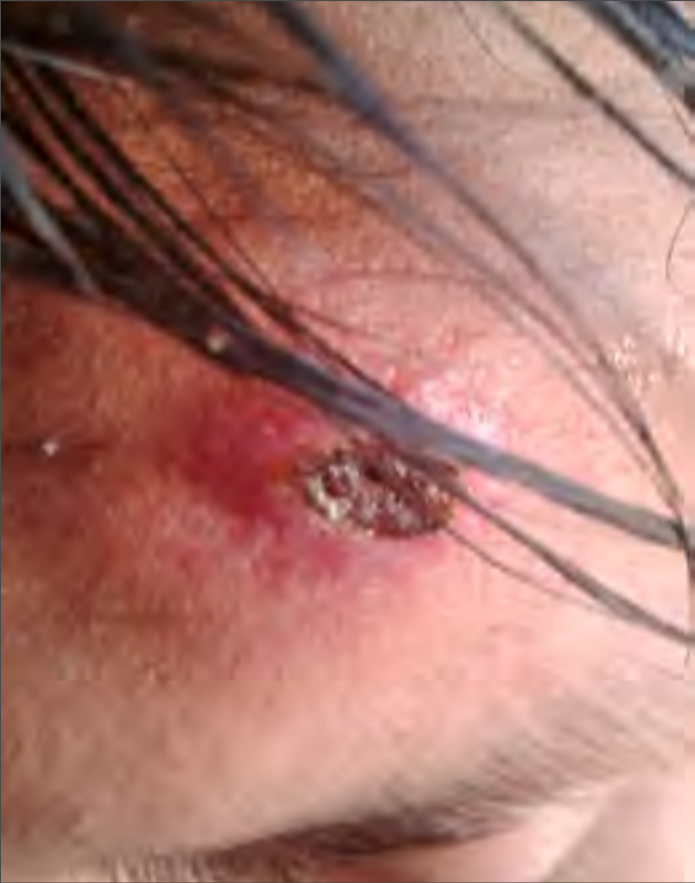

**Figure 3.86.**  
Ulcer on right side of forehead

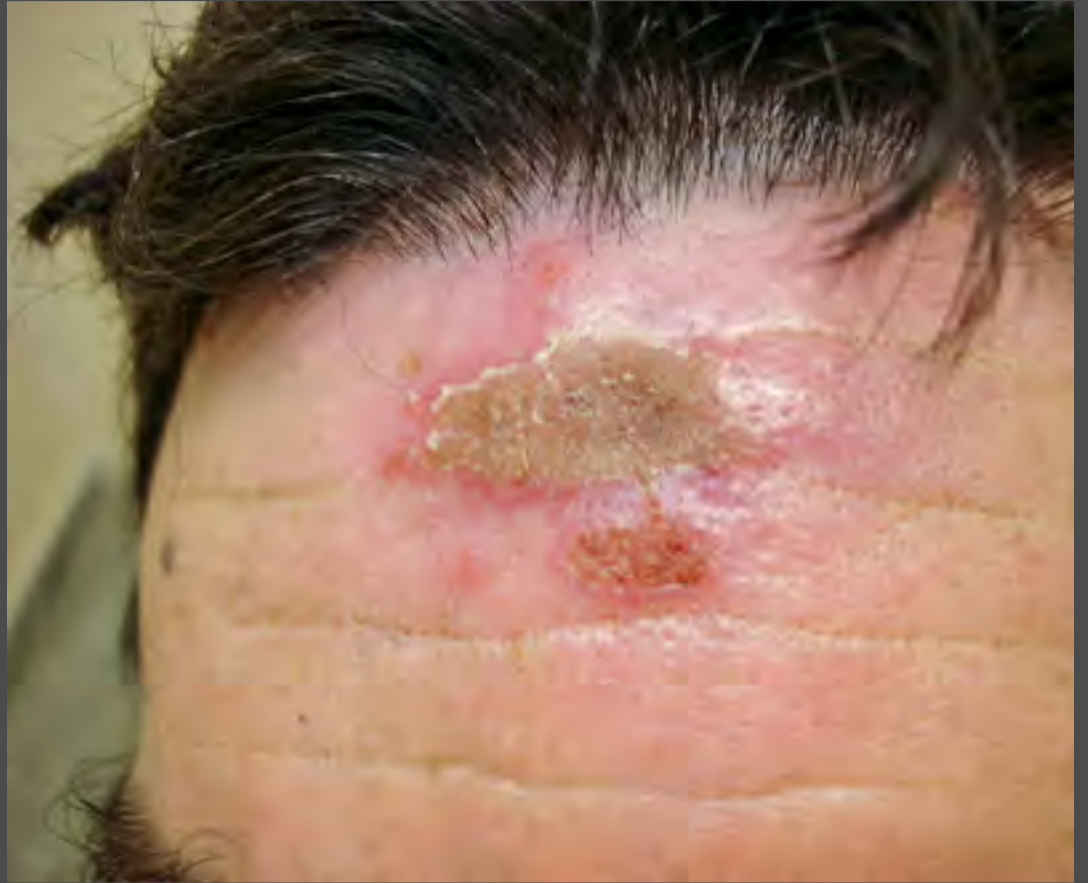

**Figure 3.87.**  
Large, dry lesion with erythematous  
edges on right temple (*Leishmania*  
(*L.*) *mexicana*)

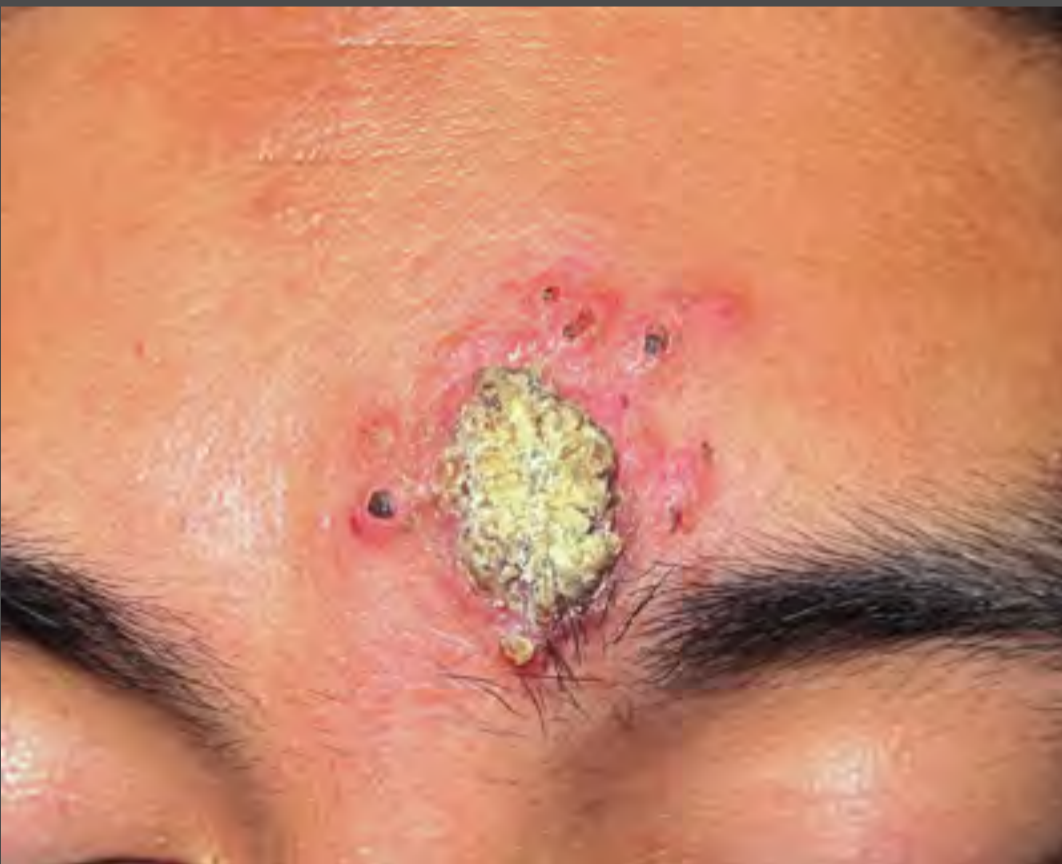



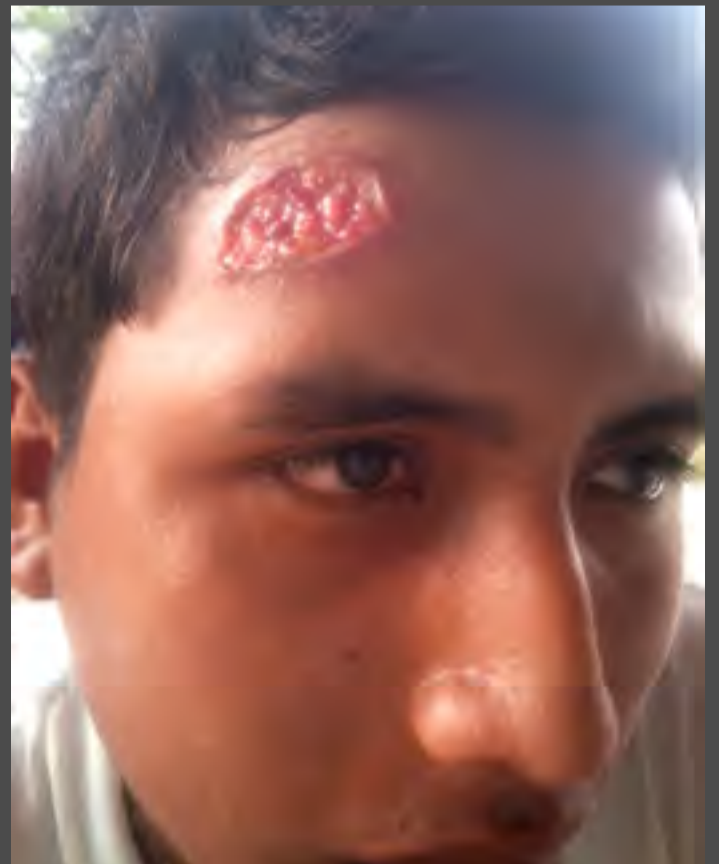**Figure 3.88.**  
Ulcerated lesion approximately 2 cm in diameter on forehead



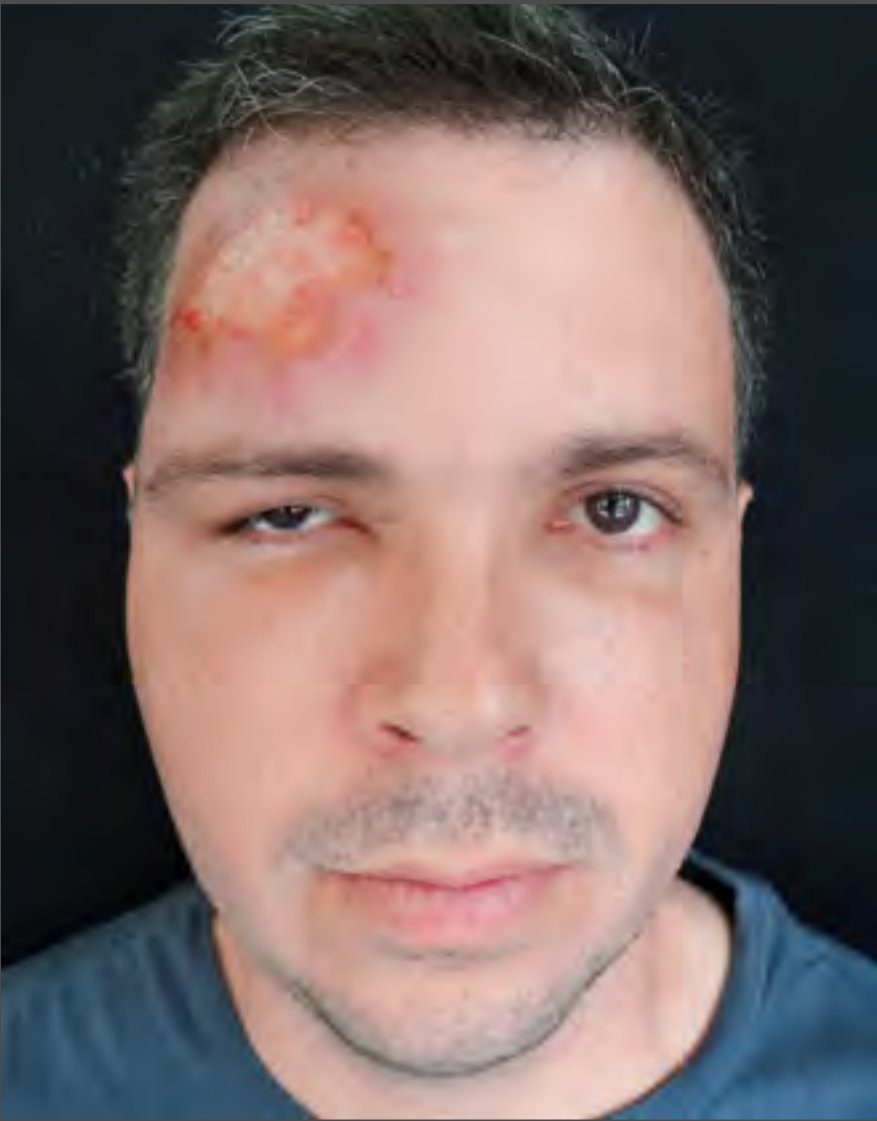**Figure 3.89.**  
Plaque lesion with peripheral inflammation, on forehead



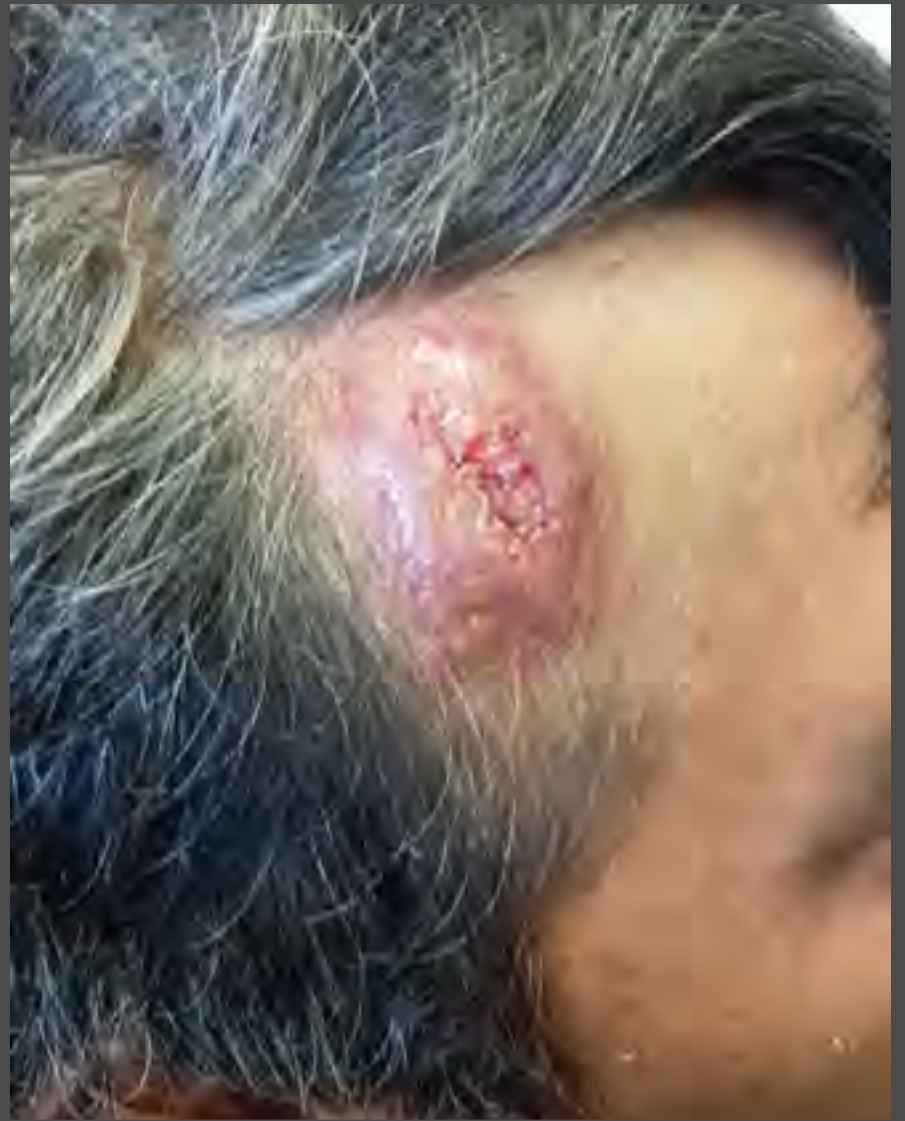**Figure 3.90.**  
Erythematous, warty plaque on forehead with peripheral satellite lesions



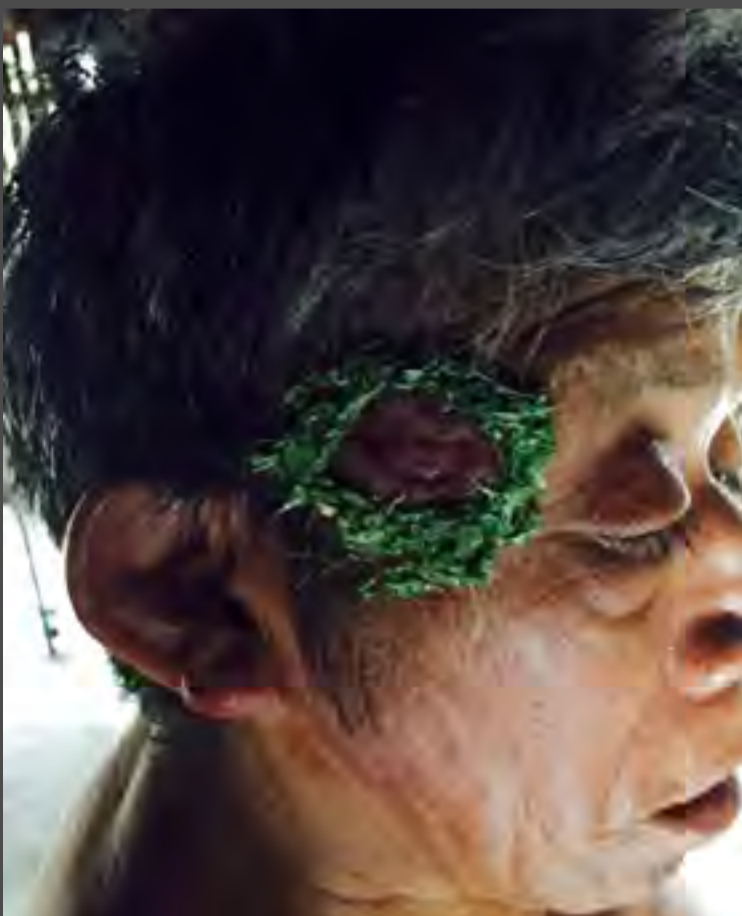**Figure 3.91.**  
Lesion approximately 6 cm in diameter, on right side of forehead



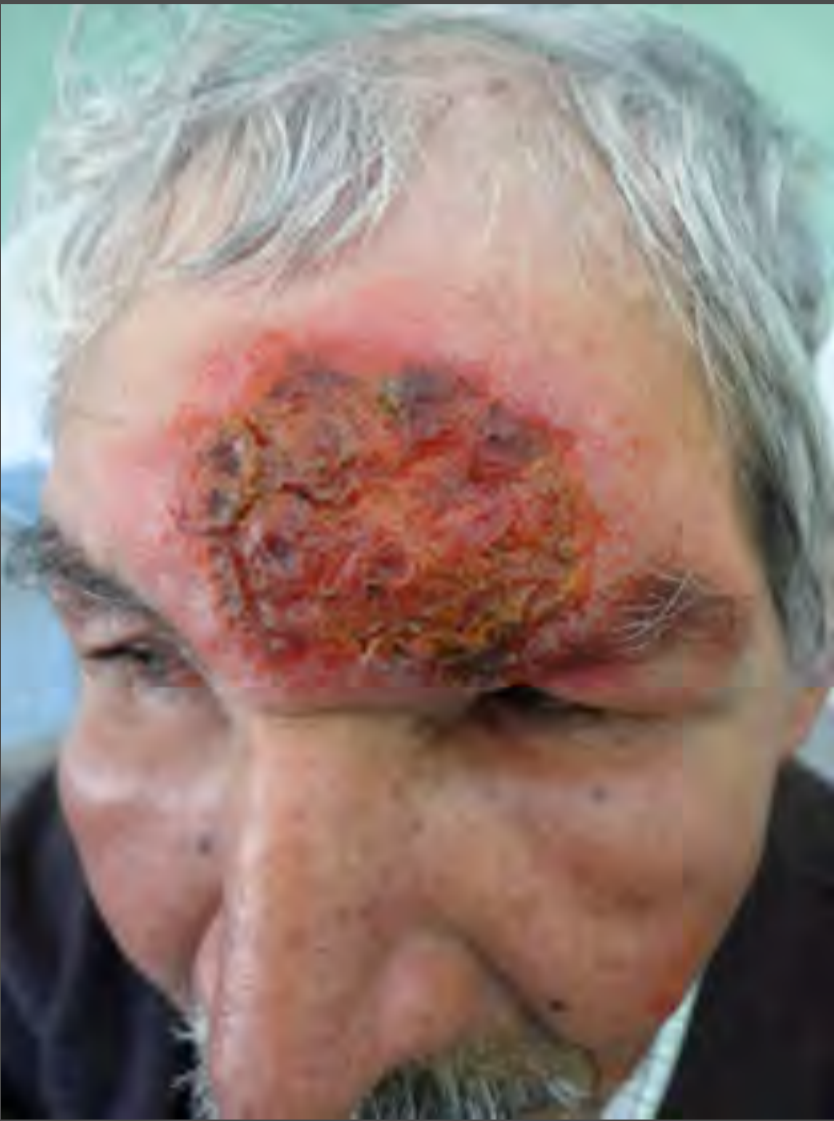**Figure 3.92.**  
Extensive infiltrated, ulcerated 3.5-month-old plaque, with soft edema extending to the eyelids.



**Figure 3.93.**  
Ulcerated lesion approximately 3.5 cm in diameter, on right part of forehead

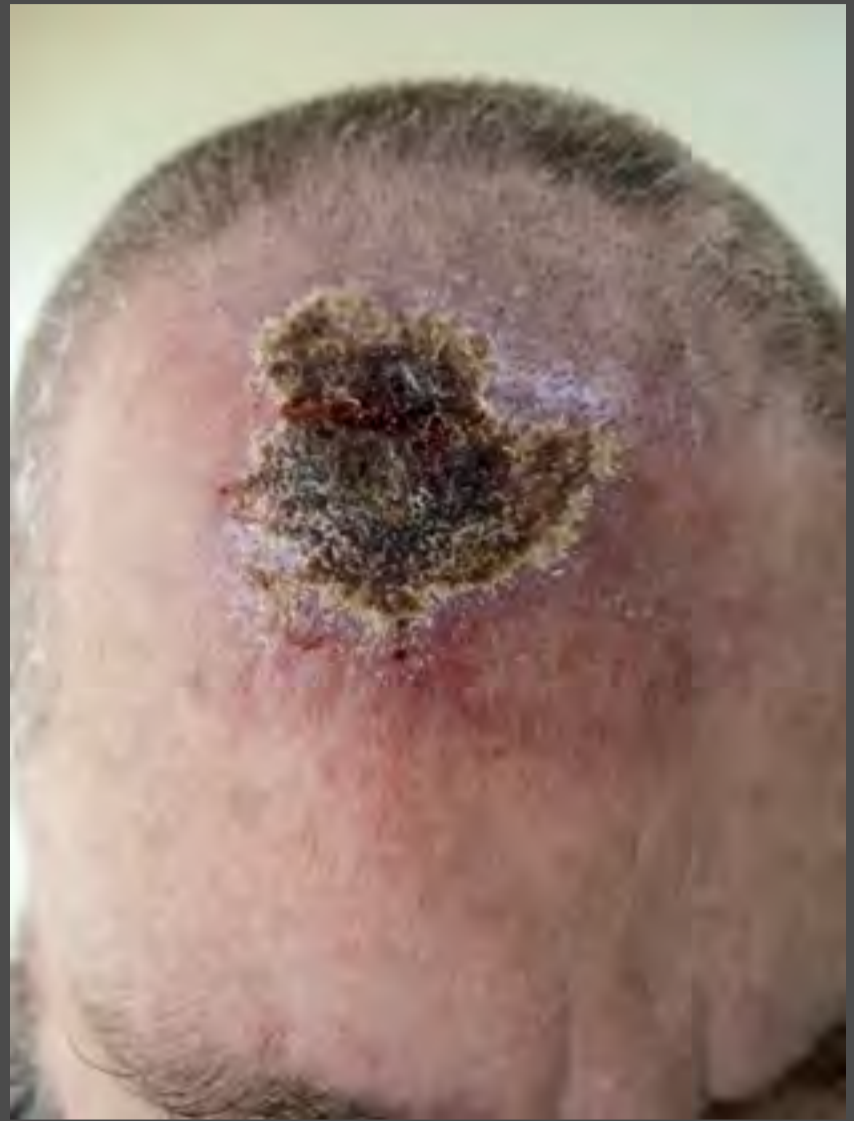

**Figure 3.94.**  
Ulcerated lesion 4 cm in diameter on right temple, being treated at home with herbs



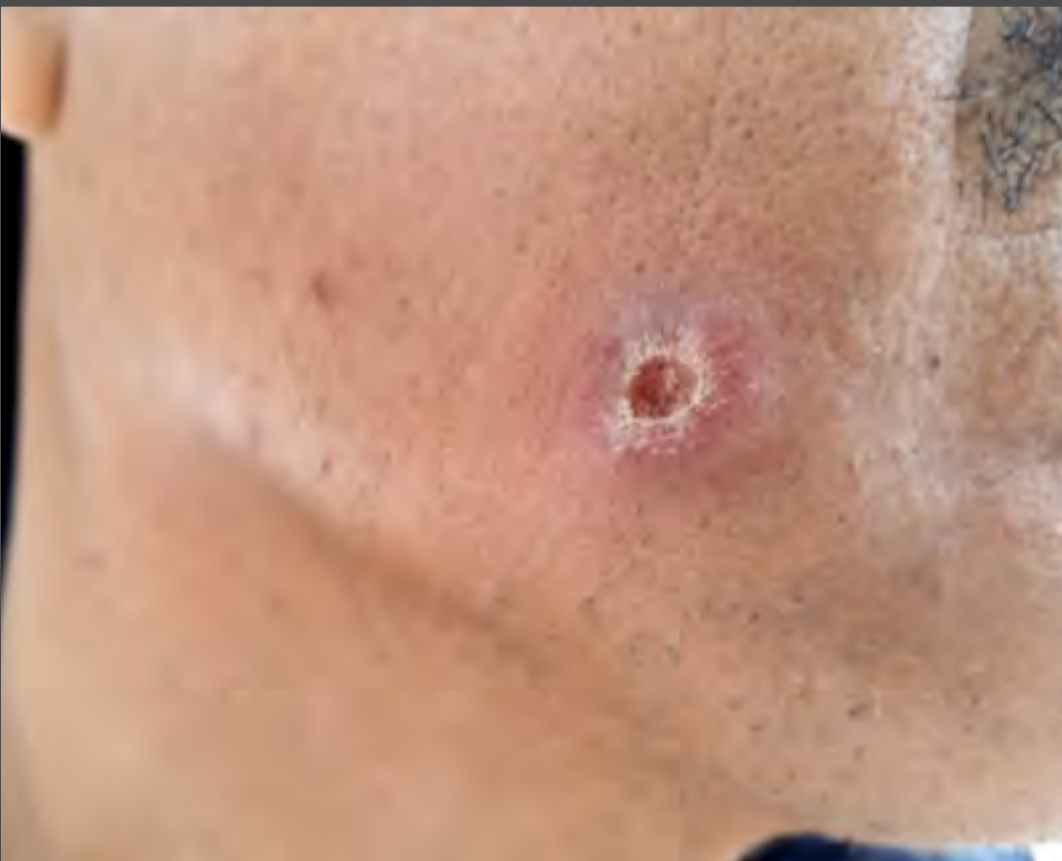**Figure 3.95.**

Leishmaniasis in plaque that resembles impetigo vulgaris, barely infiltrated, not ulcerated, and heavily exudative, which is why it covered over with crusts.



**Figure 3.96.**

Erythematous, infiltrated, and irregular plaque, covered by a thick adherent serosanguineous crust, located on a bald area unprotected by hair.

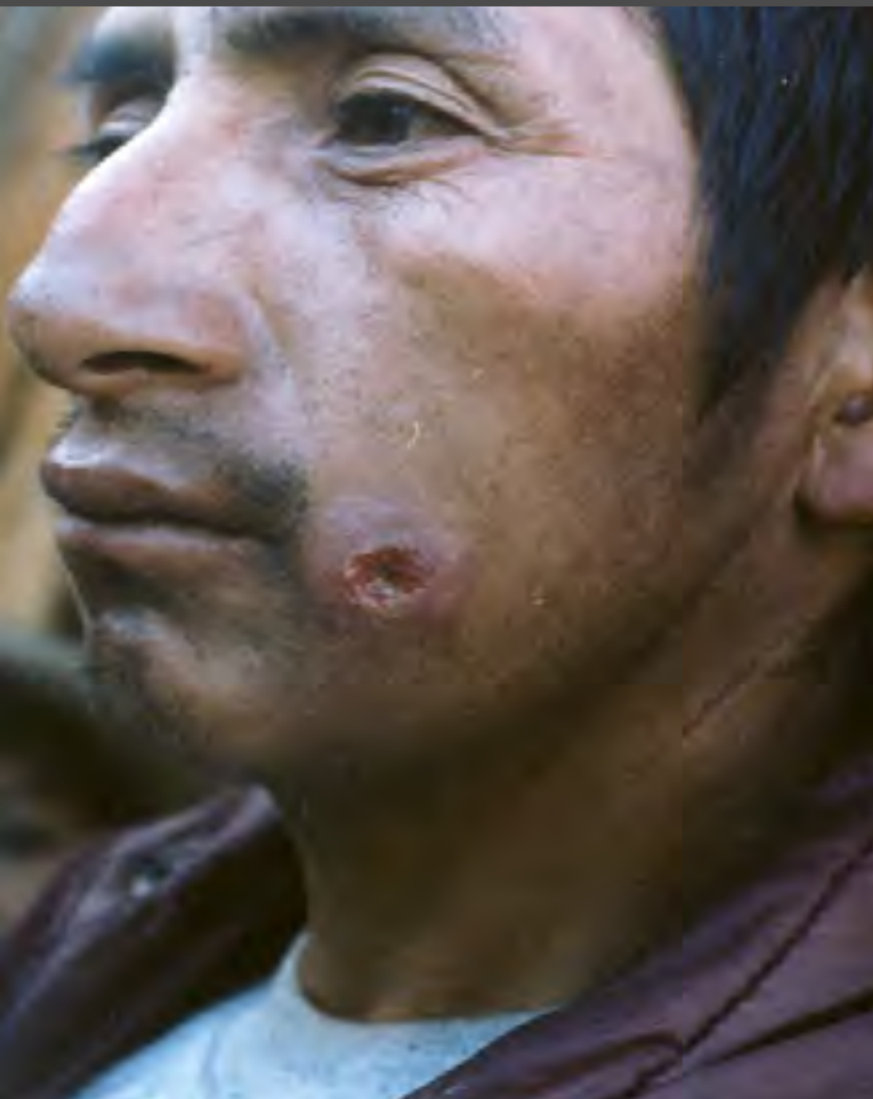

**Figure 3.97.**

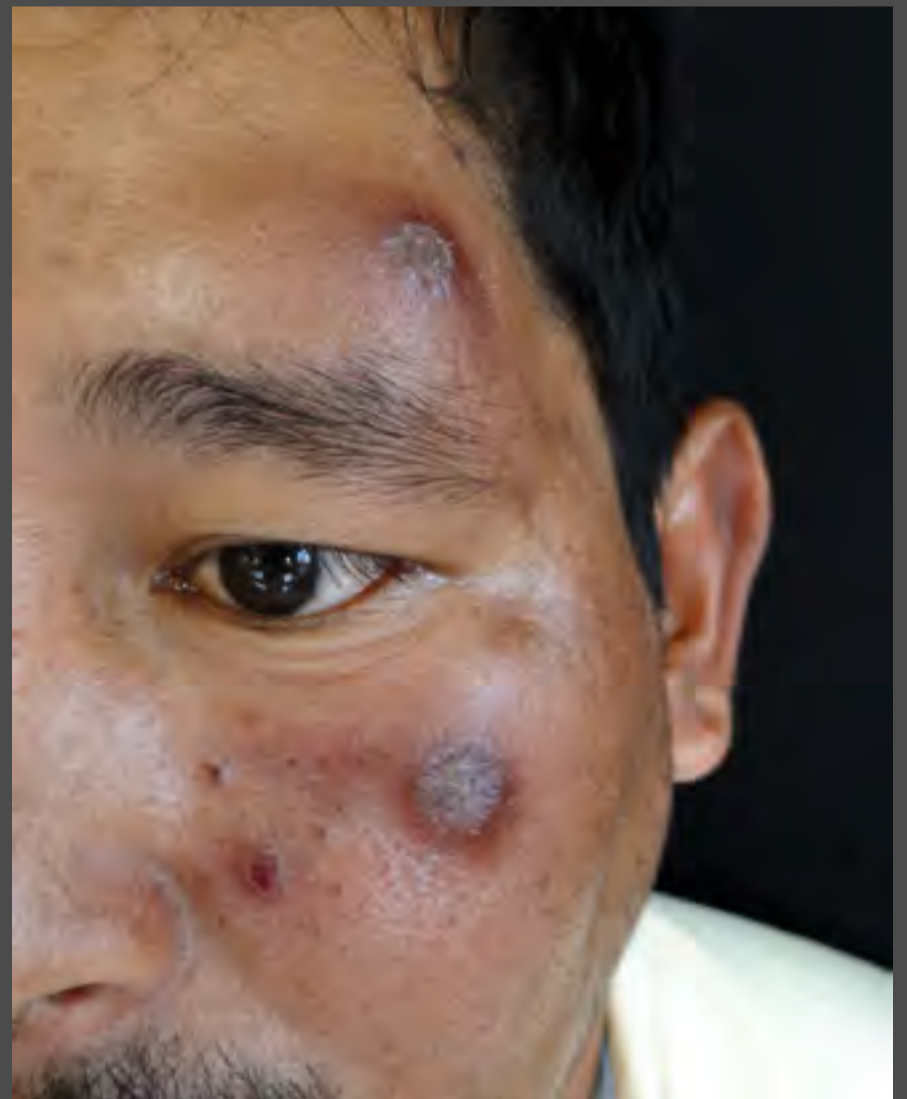Ulcerated lesion approximately 1 cm in diameter, on right cheek



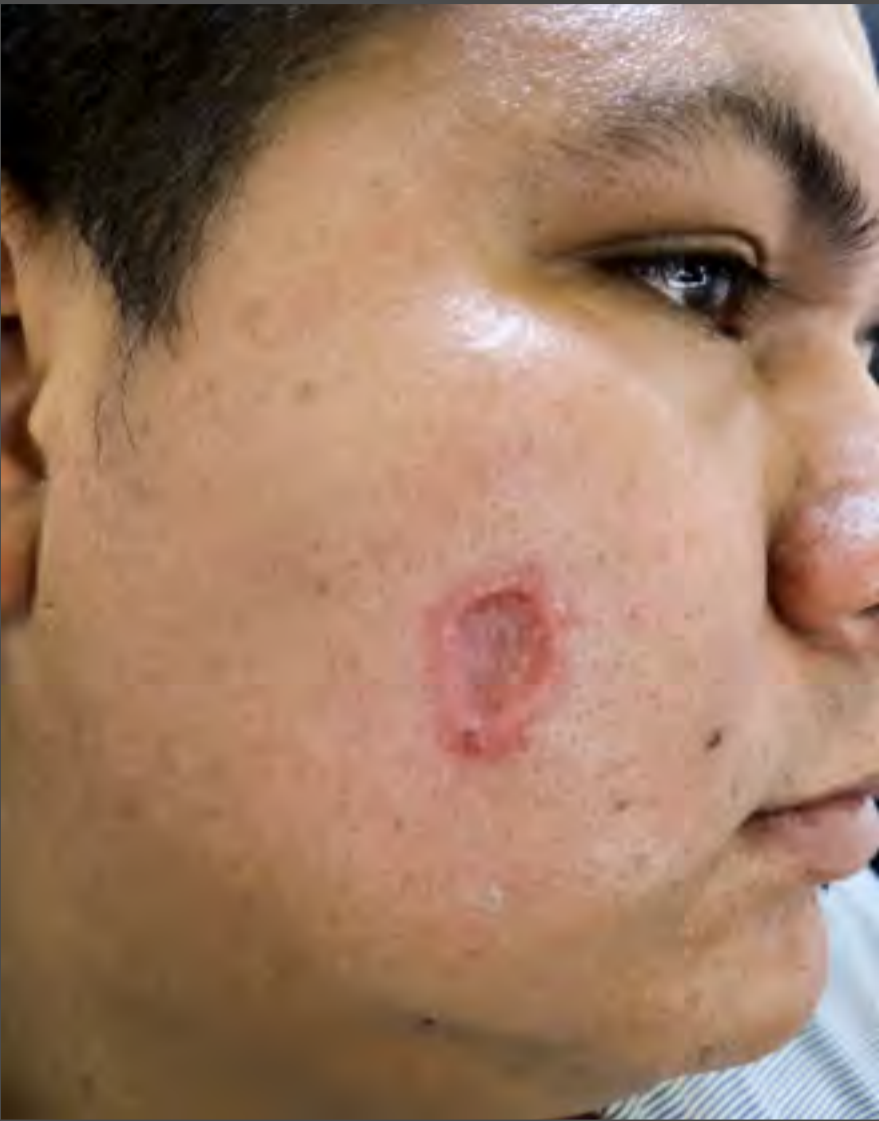**Figure 3.98.**  
Ulcer with infiltrated edge and thick central scab (*Leishmania (V.) braziliensis* complex)



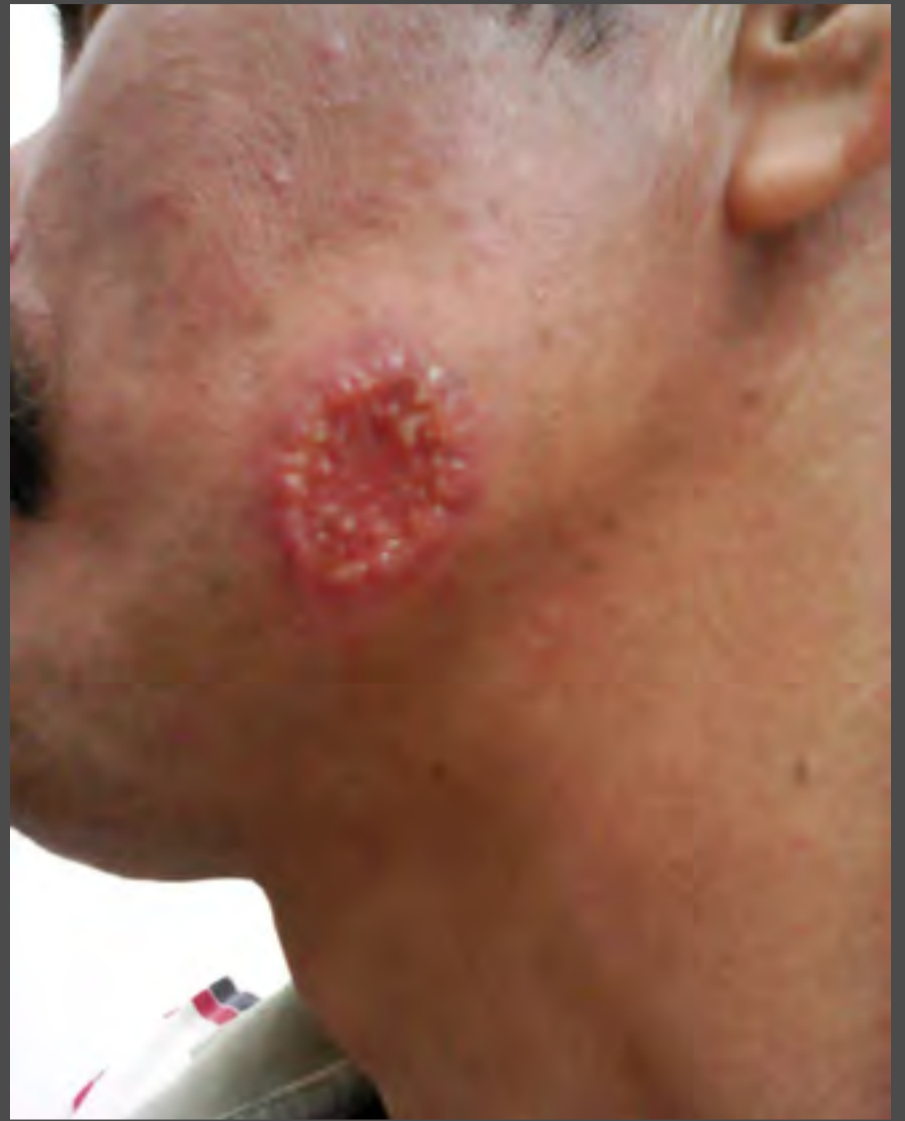**Figure 3.99.**  
Ulcerative lesion 1.4 cm in diameter, with little inflammation, 43 days old, on left side of face



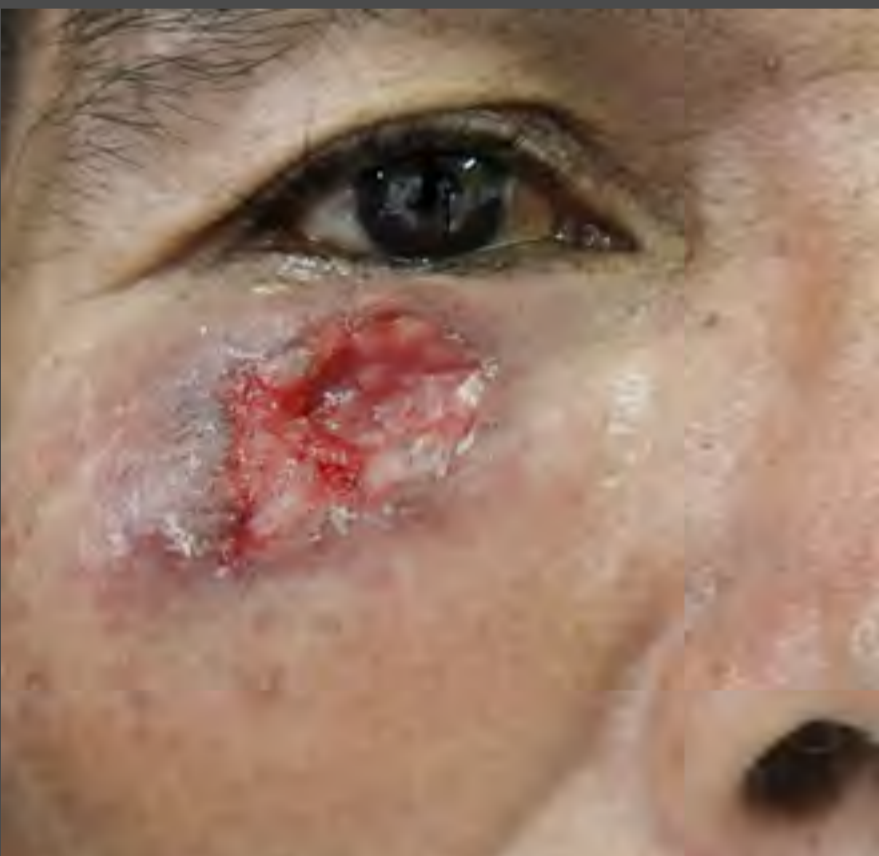**Figure 3.100.**  
Rounded, infiltrated, erythematous, squamous plaques with distinct edges, described as *lupoid* because they resemble discoid lupus lesions



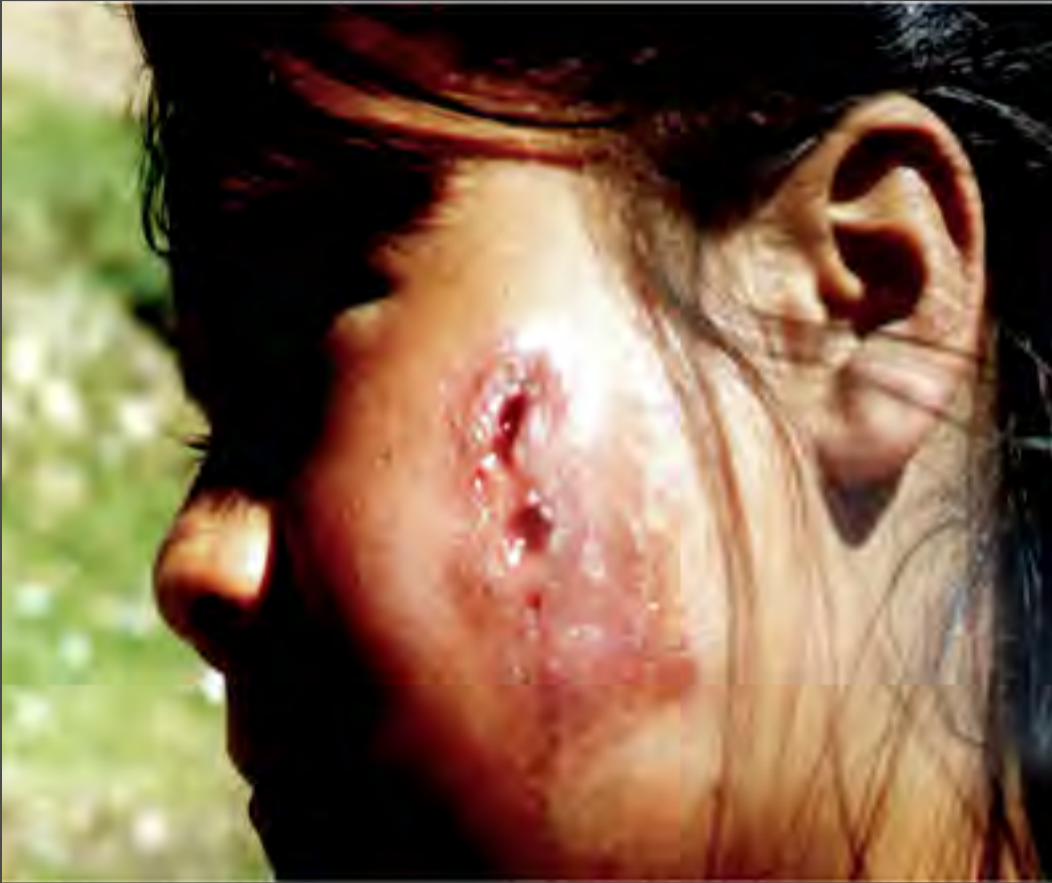**Figure 3.101.**  
Rounded erythematous plaque, with raised cordoned edges, and depressed atrophic center, but no ulceration



**Figure 3.102.**  
Lesion with indurated edge on left side of face, with pruritus

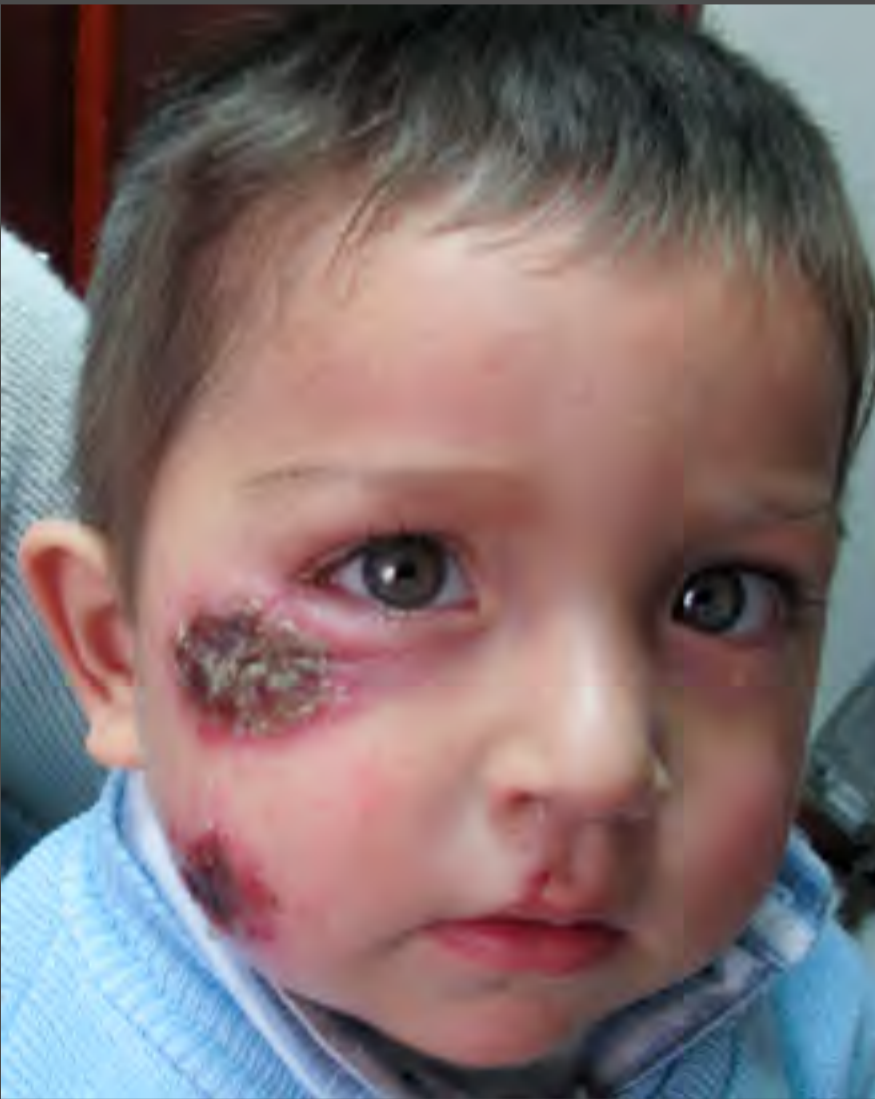

**Figure 3.103.**  
Ulcer with irregular border, infiltrated edges, and granular center, located on the malar region



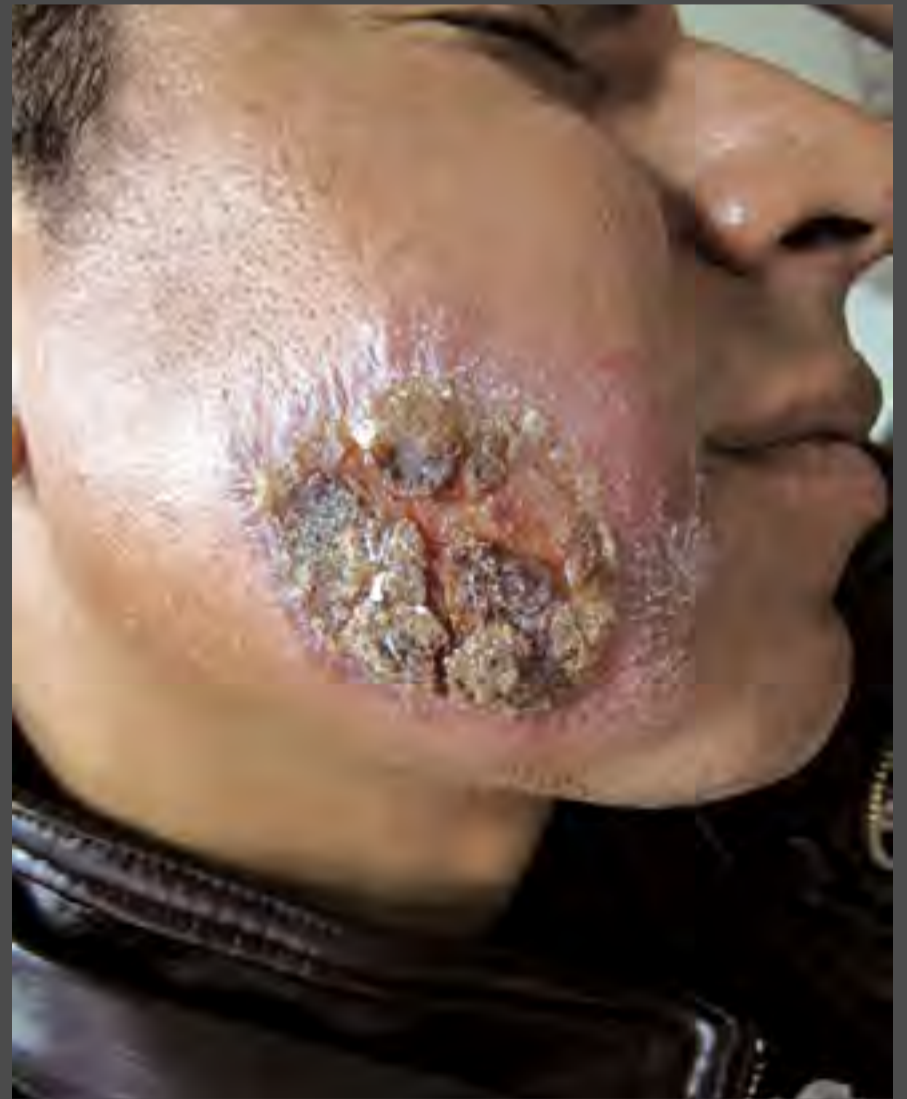**Figure 3.104.**

Crusty, contiguous, 16-day-old ulcers on left side of the face; not painful or itchy. They have raised, defined edges, a granular floor, discharge, and peripheral inflammation.



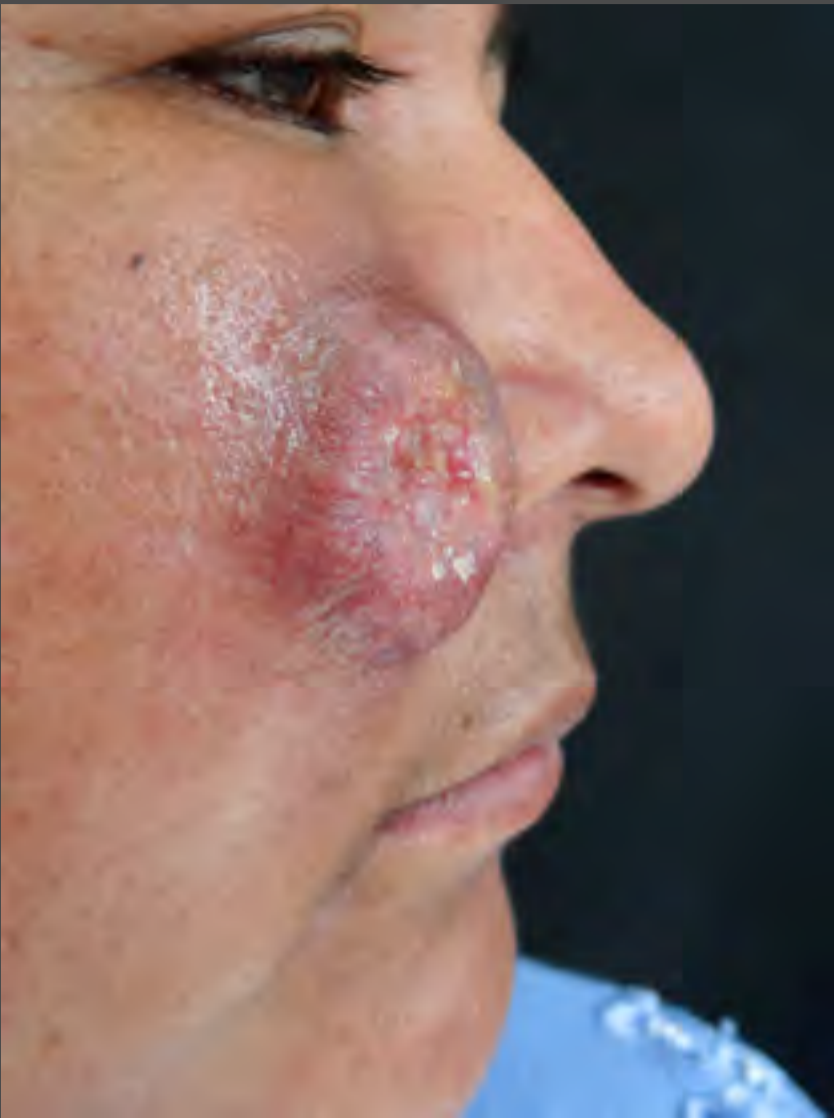**Figure 3.105.**

Crusty lesions with considerable inflammation (*Leishmania (V.) lainsoni*)



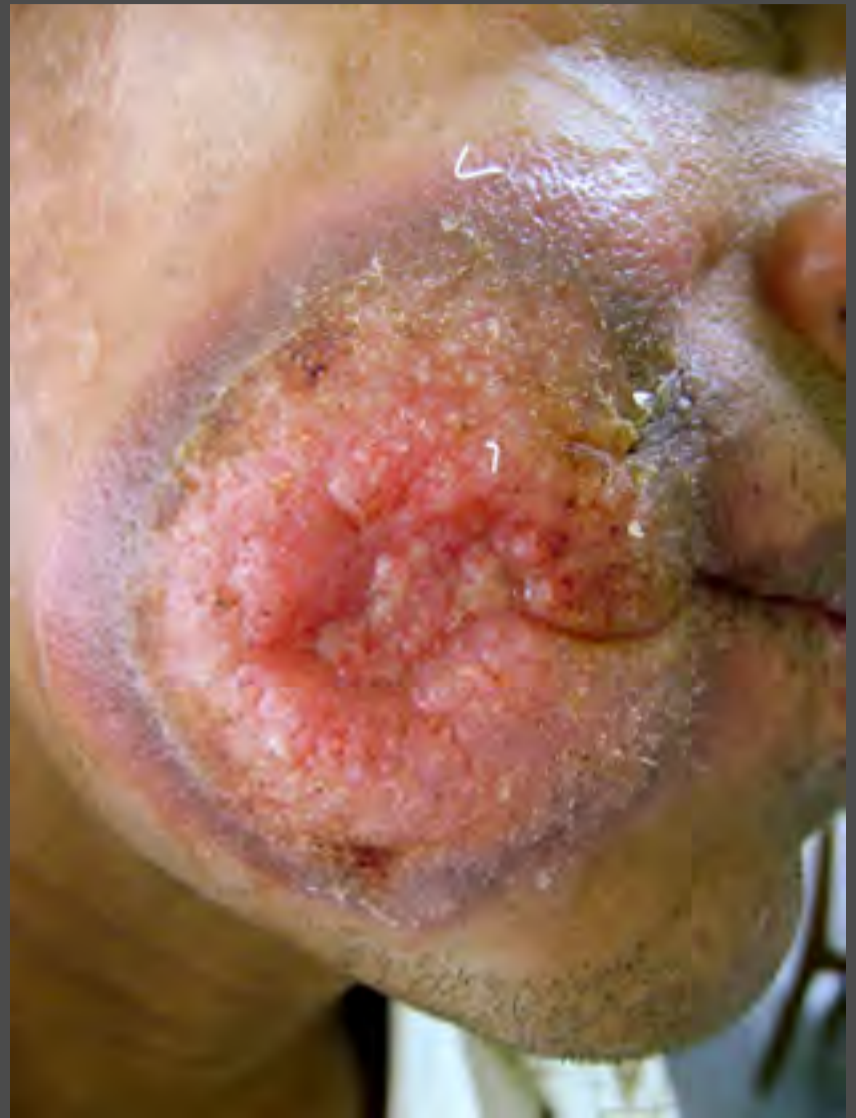**Figure 3.106.**

Erythematous, edematous, infiltrated plaque with a large ulcerated lesion covered by extensive and abundant serosanguineous crusts



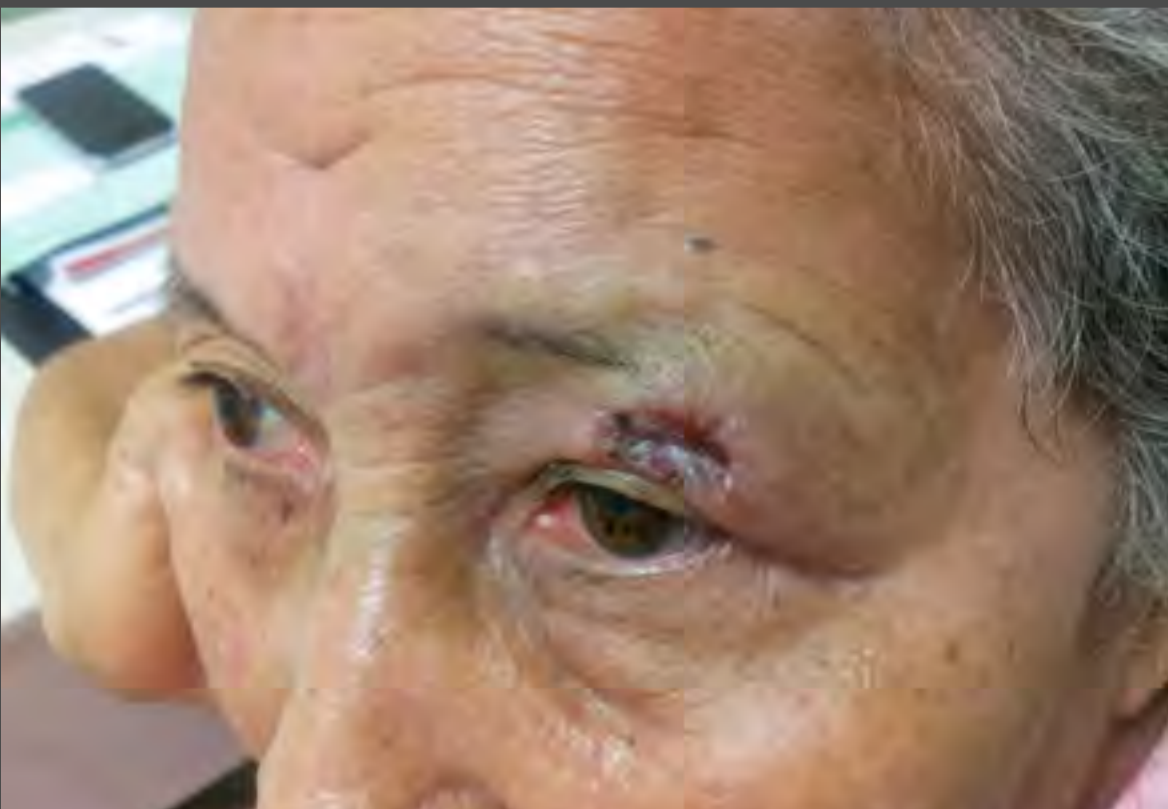**Figure 3.107.**

Erythematous, edematous plaque, raised above the surrounding tissue by intense infiltration, with a depressed, ulcerated, and crusty center. Keratoacanthoma should be discarded.



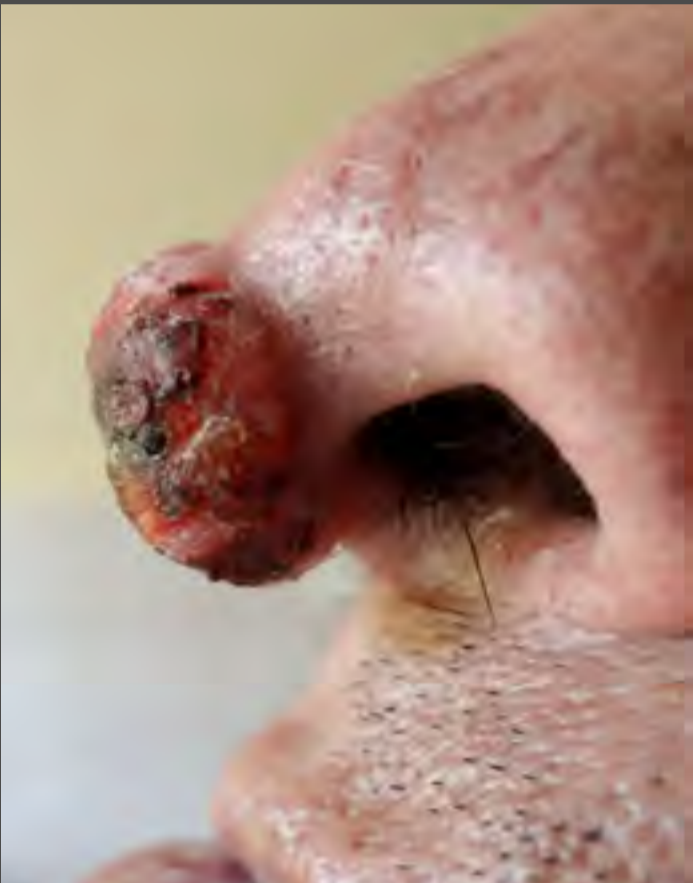**Figure 3.108.**

Erythematous plaque with intense inflammation and infiltration, abundant warty granulation and erosions, with no frank ulceration

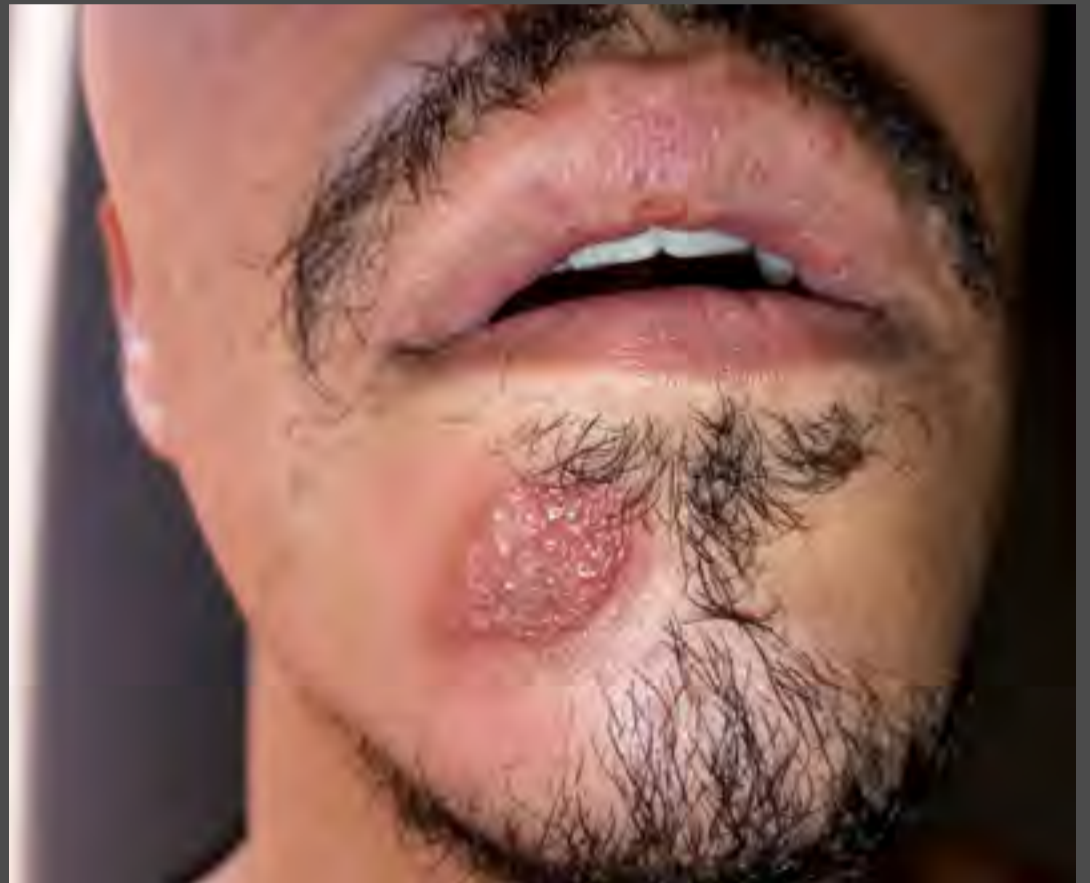

**Figure 3.109.**

Ulcerative lesion with peripheral inflammation, located on upper eyelid

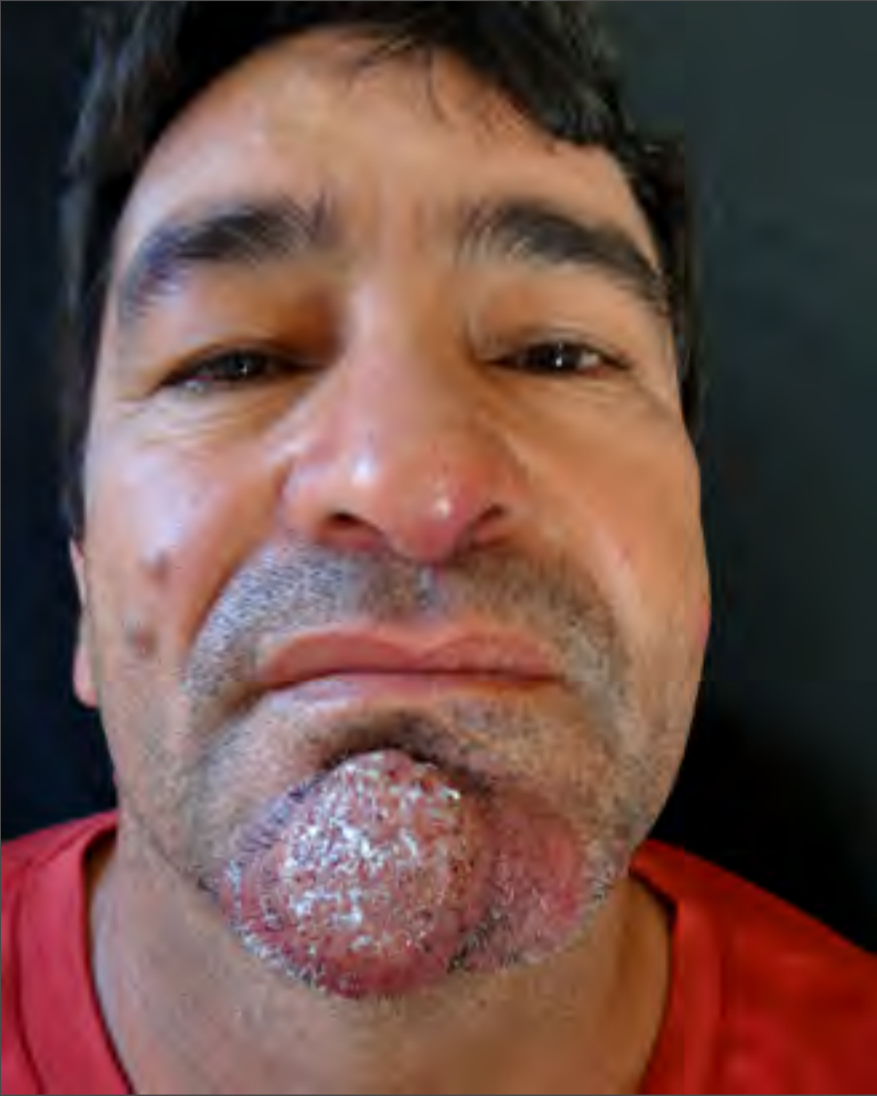

**Figure 3.110.**  
Hemispheric exophytic, erythematous papule covered with serosanguineous crusts, with the appearance of a tumor and rapid growth. Usually, this type of lesion is very rich in amastigotes on direct examination and shows abundant histiocytes full of parasites in the biopsy.



**Figure 3.111.**  
Moist, non-indurated lesion with erythematous edges (*Leishmania (L.) mexicana*)



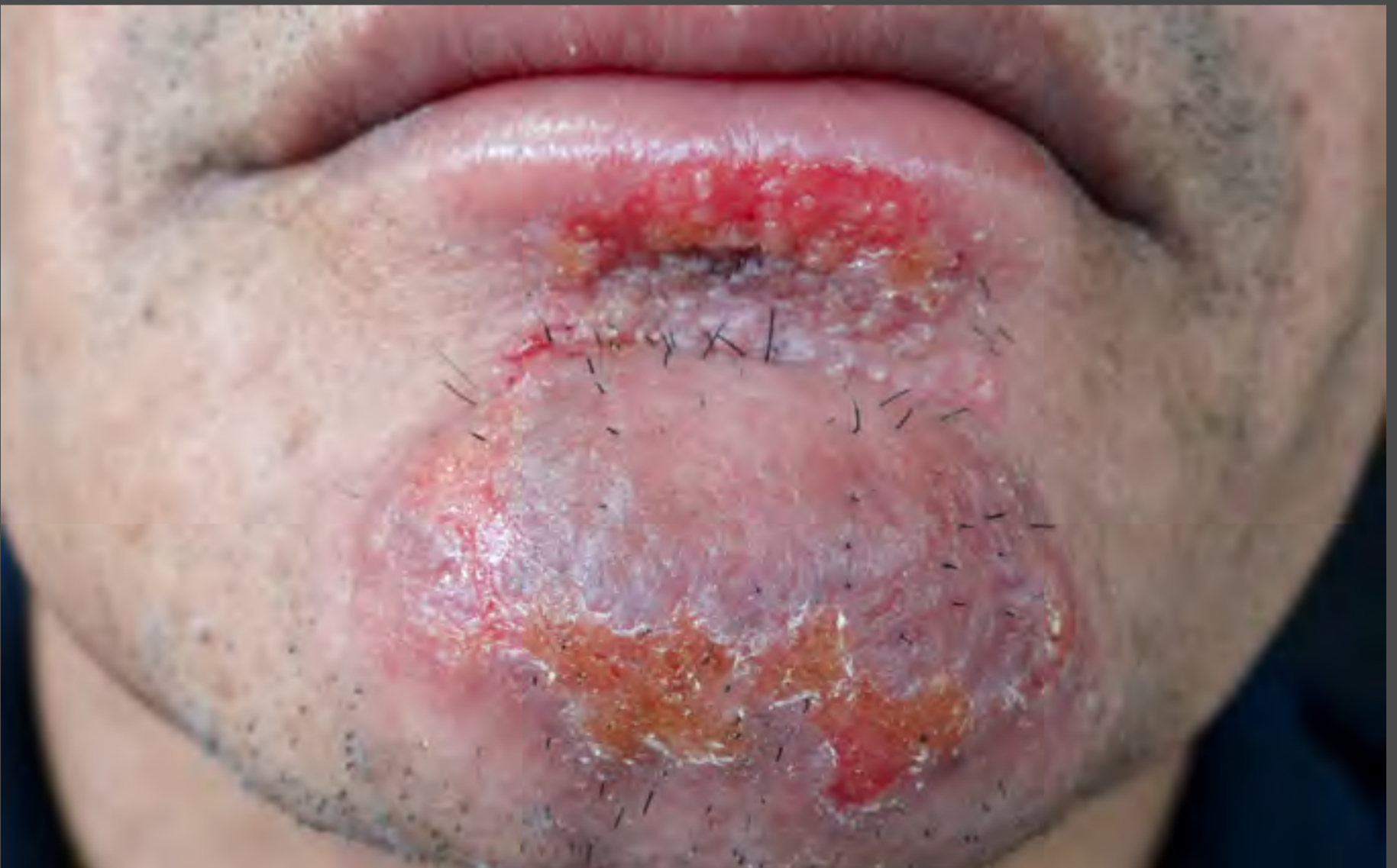

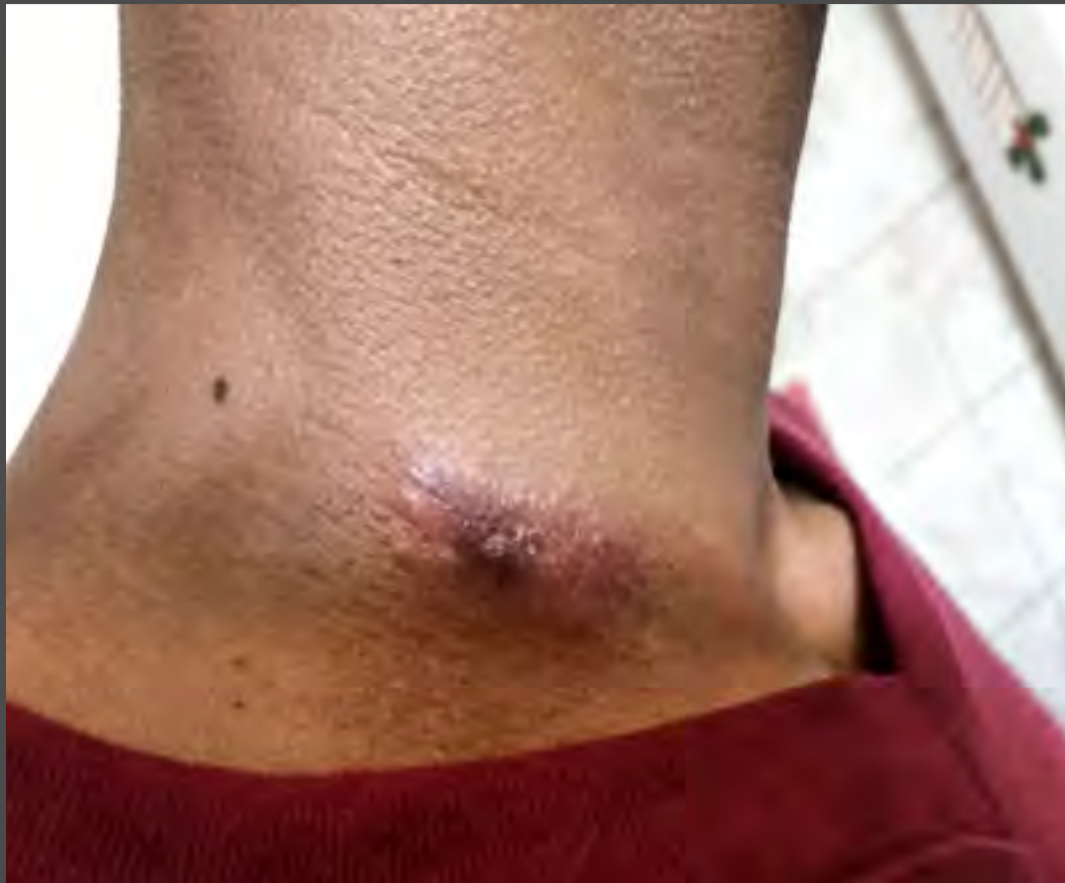**Figure 3.112A.**

Extensive erythematous edematous plaque with a tumorous area draining limited purulent material. The first direct examination was negative. Following antibiotic treatment, direct examination and biopsy found amastigotes.

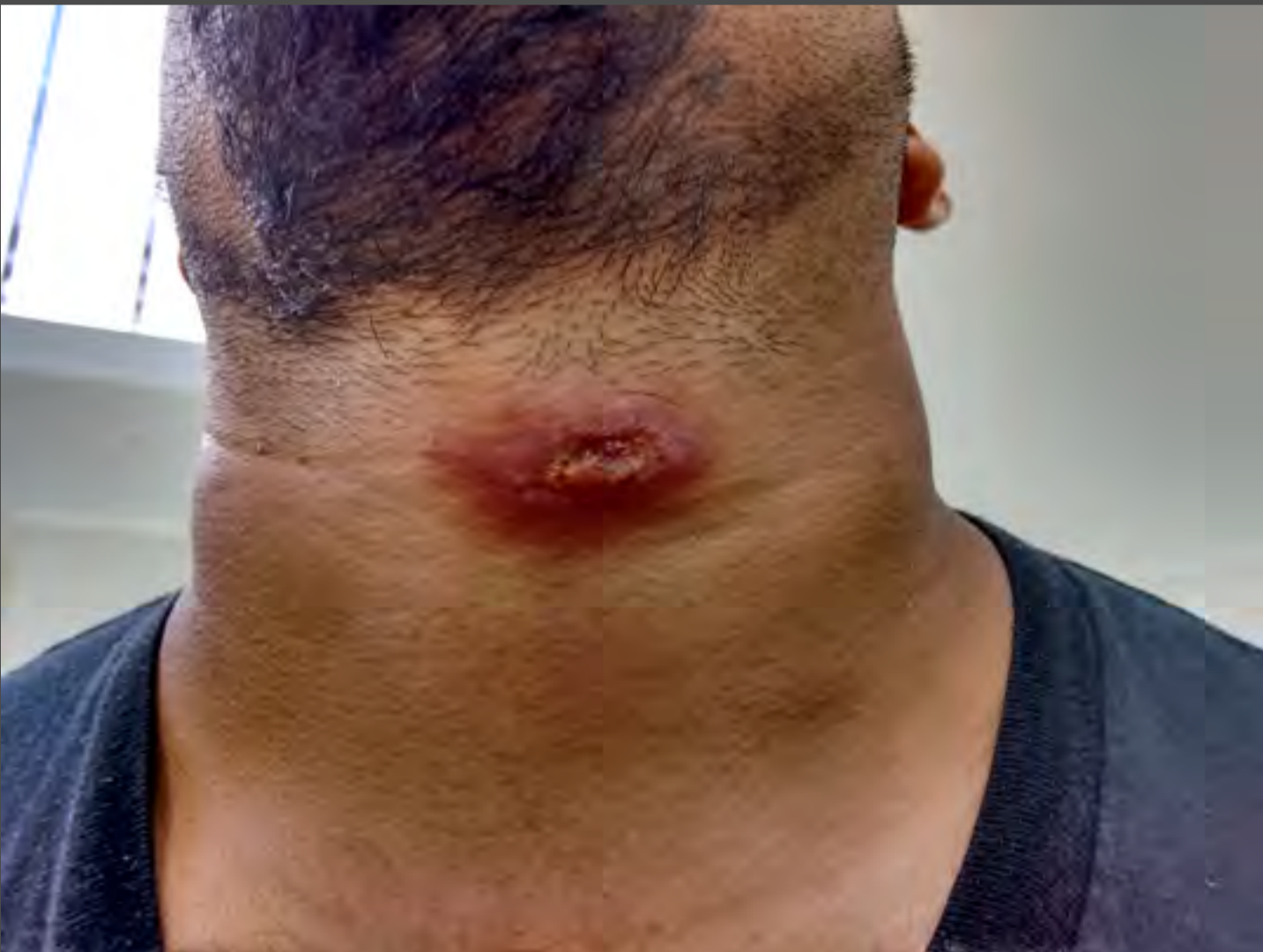**Figure 3.112B.**

Erythematous plaque with excoriations, located on the chin. In hairy areas, such as the chin, lesions are inflammatory and infiltrative, do not ulcerate, and have seropurulent discharge. The hair falls out, although there is partial regrowth once the disease is cured.

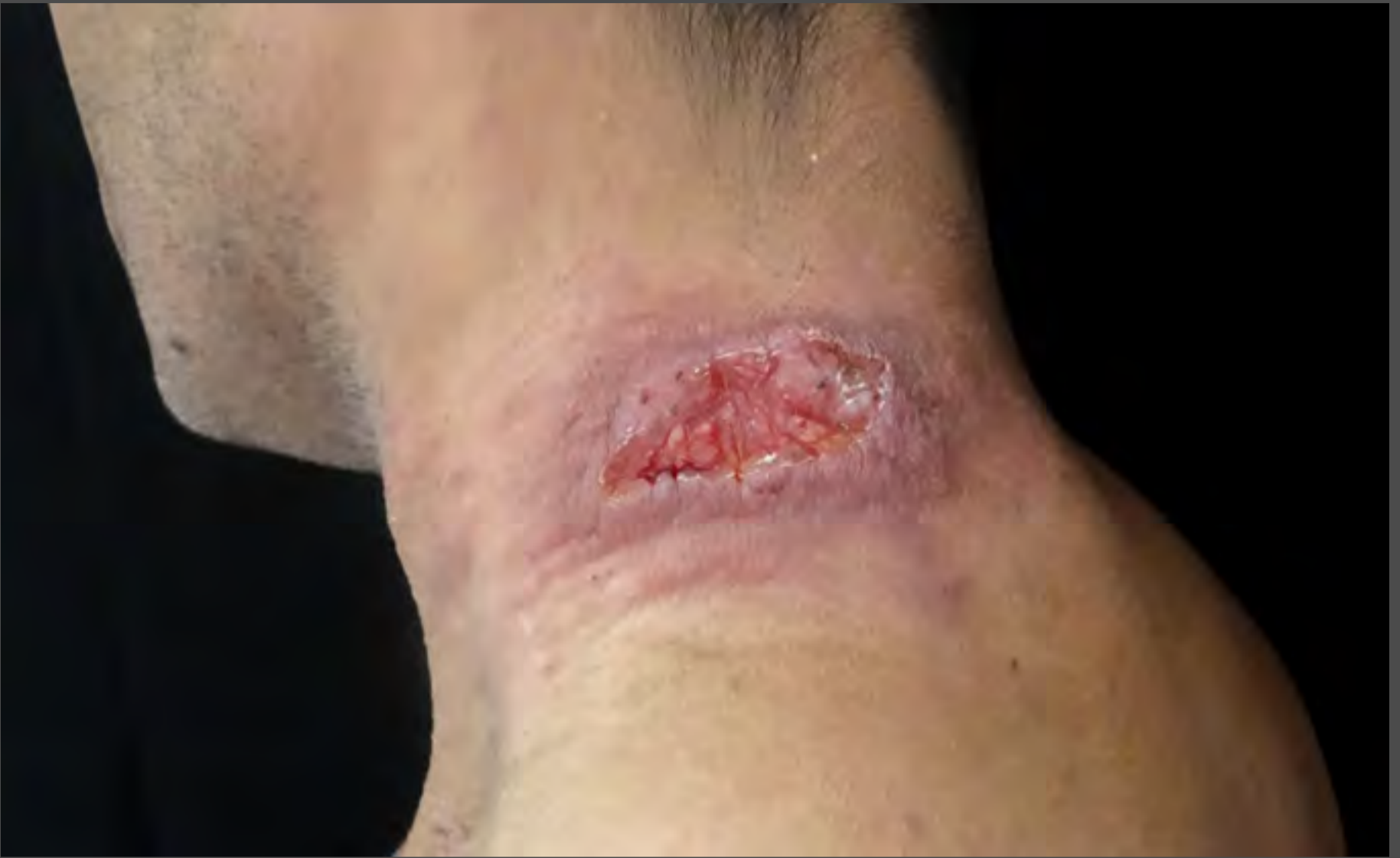



**Figure 3.113.**  
Supraclavicular lesion 1.2 cm in diameter with defined raised edge and granular floor with crusts; not painful or itchy. Lesion surrounded by inflammation and crusts.

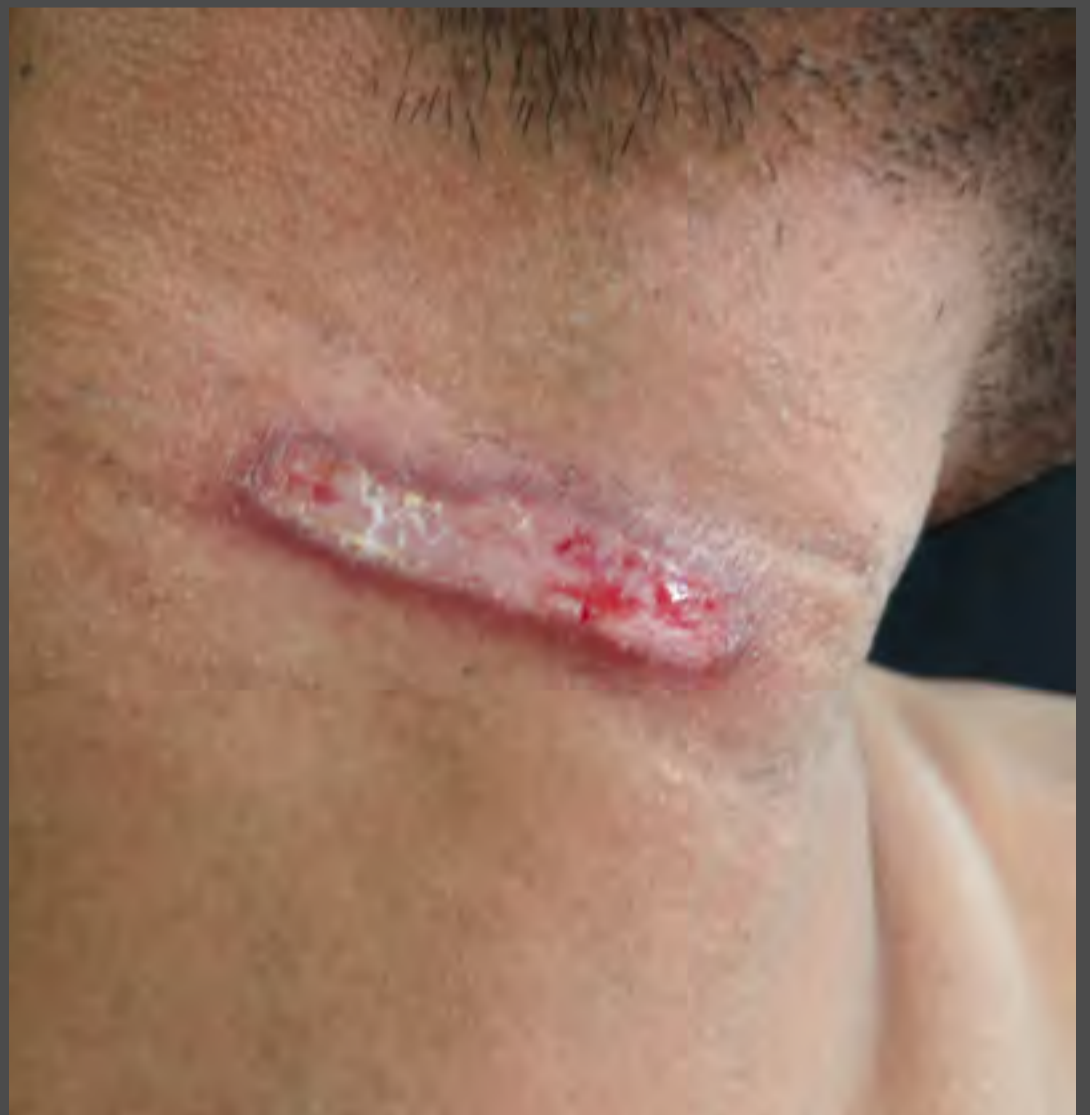

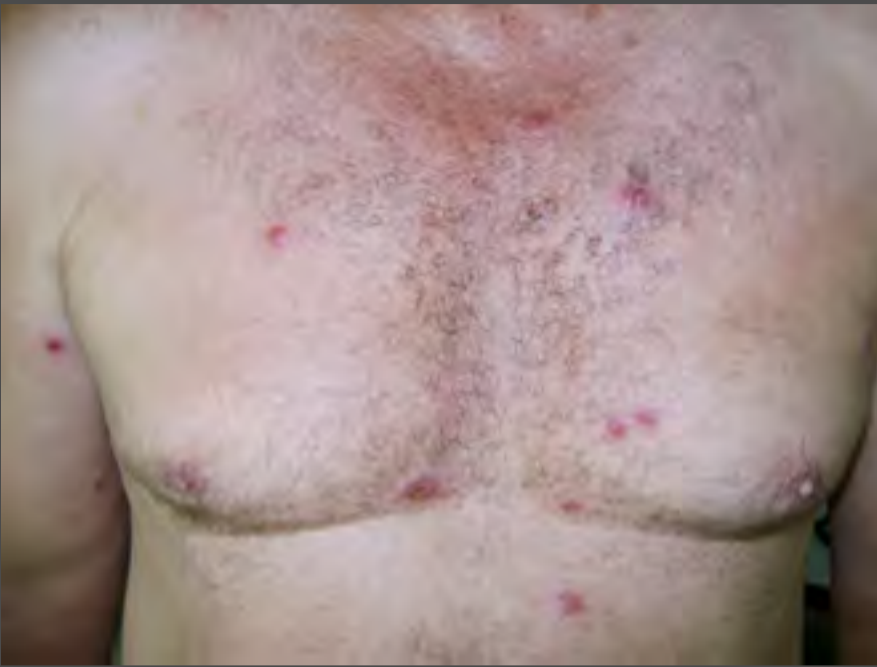**Figure 3.114.**  
Ulcerated lesion approximately 3 x 2 cm, located on front of neck



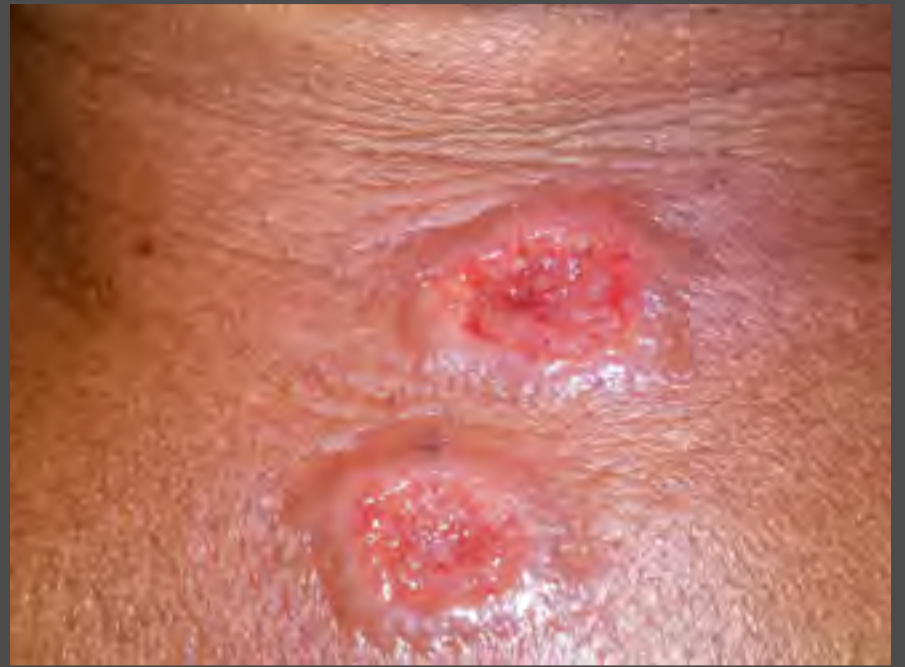**Figures 3.115A and B.**

In folds, lesions tend to take an elongated oval shape, following their direction. Otherwise, they retain the usual characteristics.

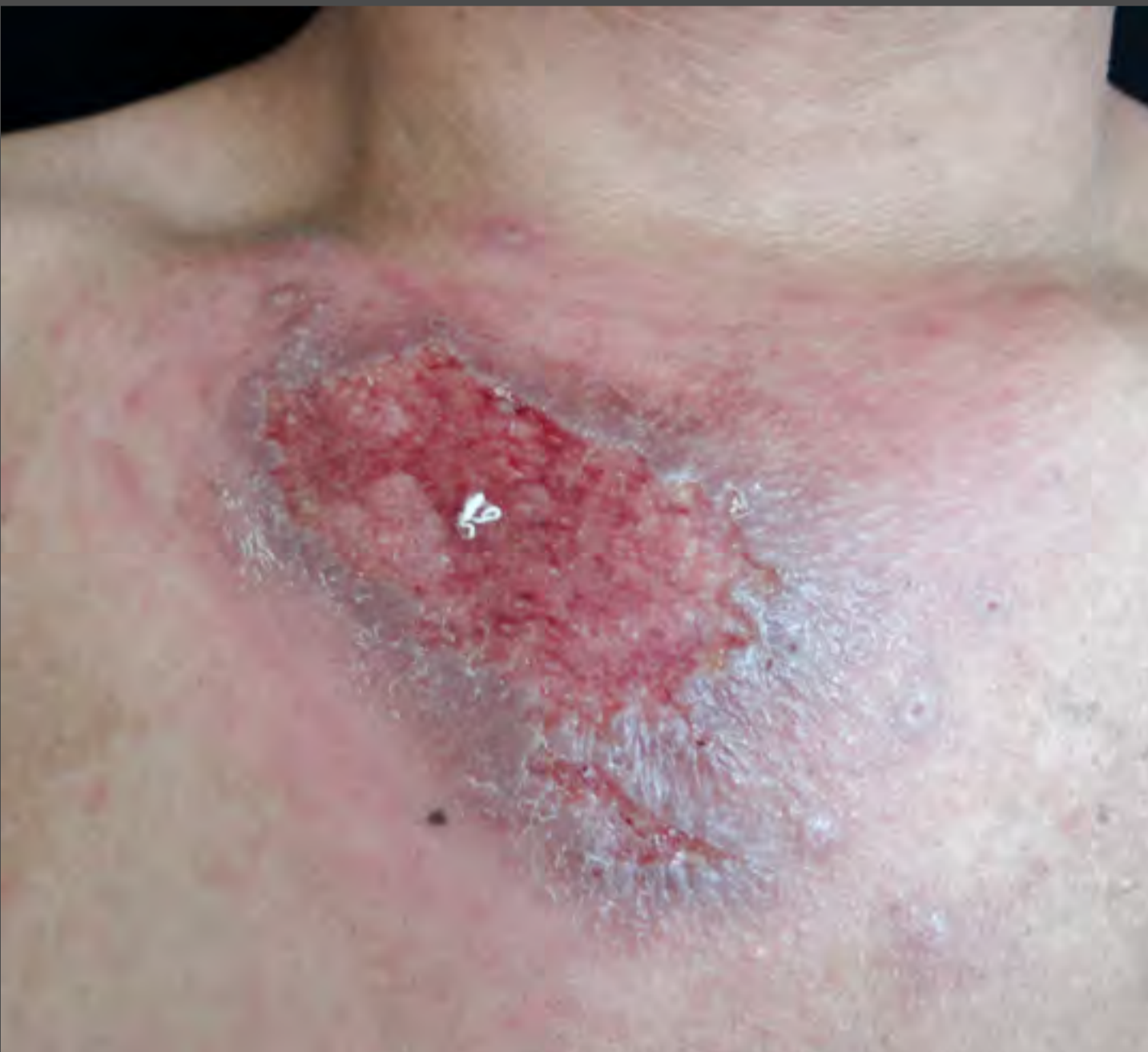



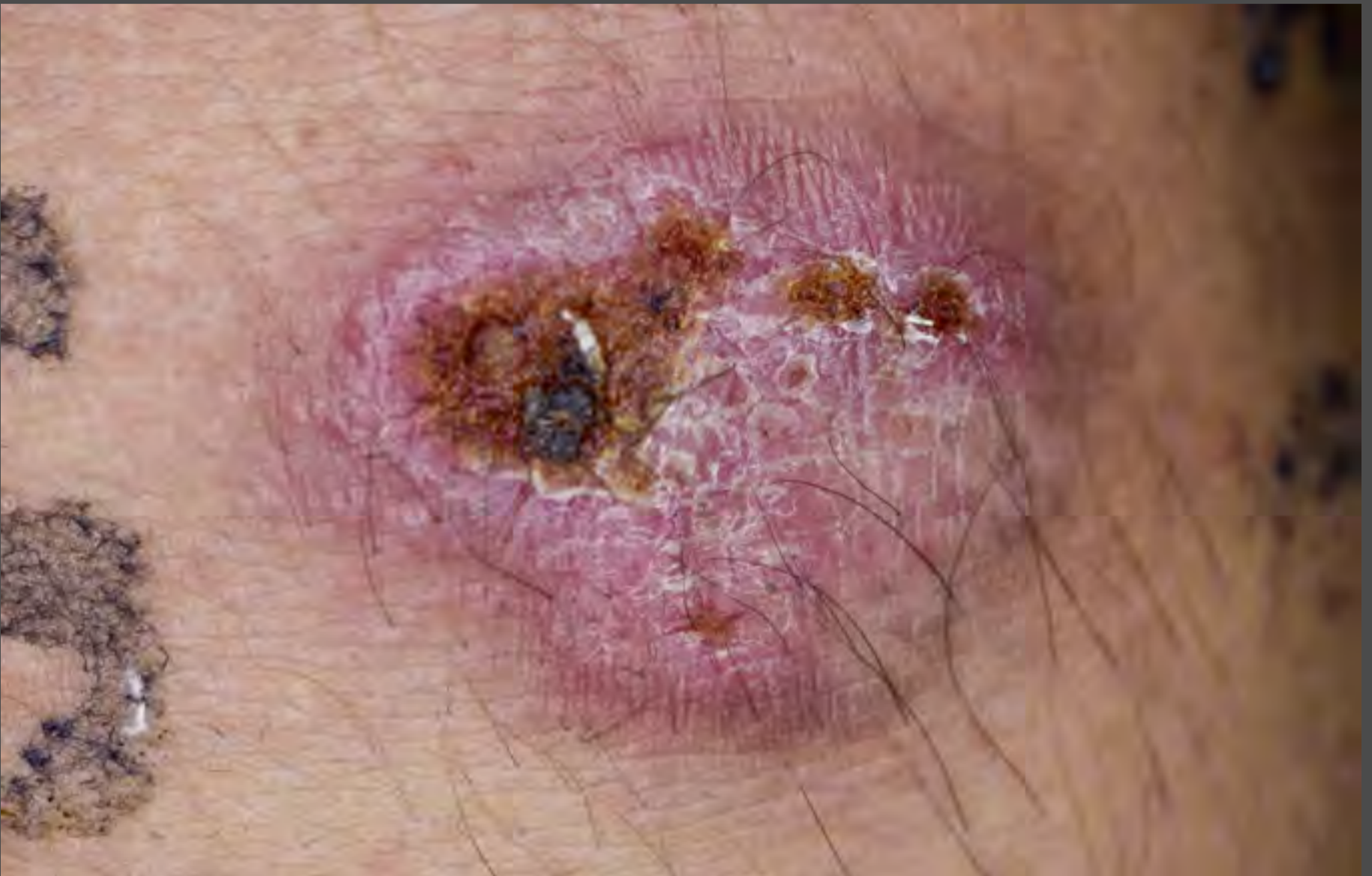**Figure 3.116.**  
 Numerous erythematous, edematous, ulcerated, itchy papules on the upper anterior aspect of the chest. Patient has similar lesions on other parts of the body.



**Figure 3.117.**  
 Ulcer with cordoned edges and granular center

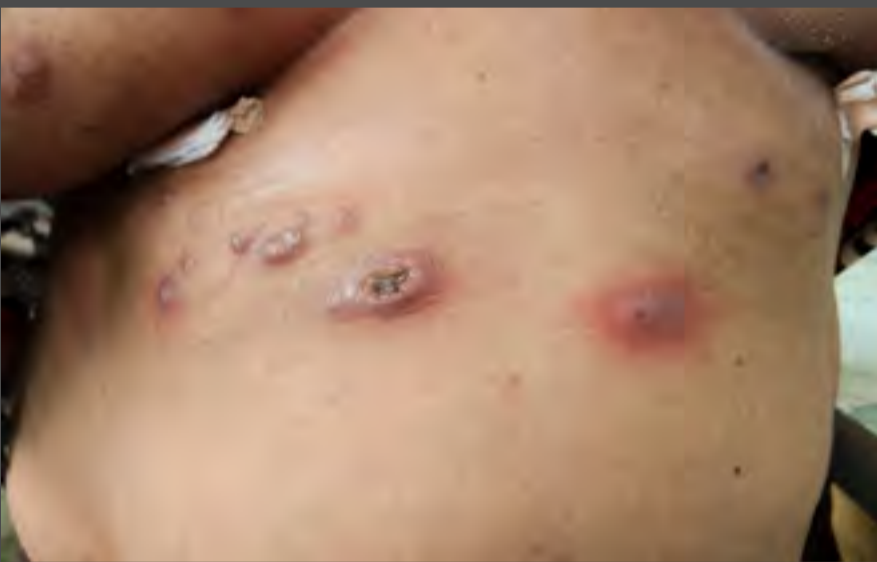

**Figure 3.118.**  
 Large infiltrated plaque with superficial ulcer on the upper presternal region



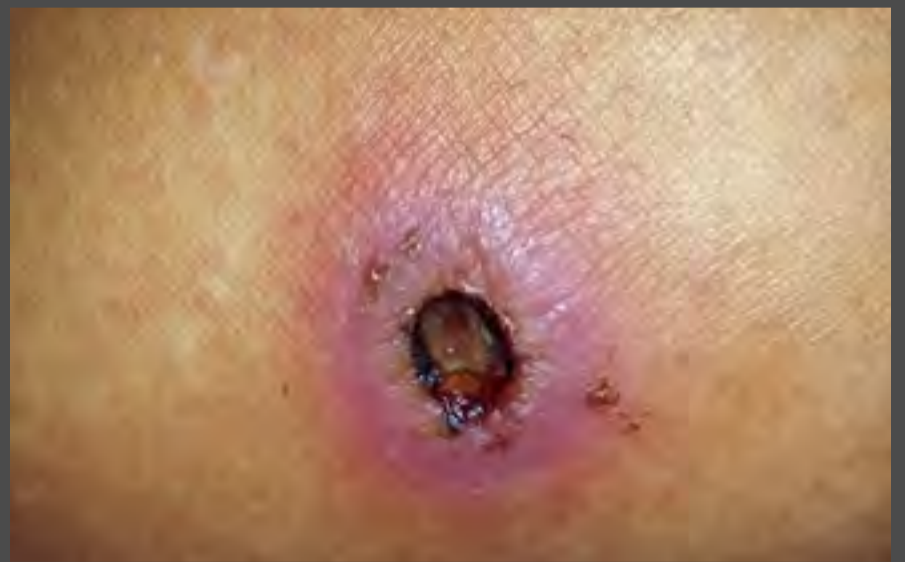**Figure 3.119.**

Erythematous-edematous infiltrated plaque, covered with scales and crusts; irregular, though well-defined edges; with ulcerated peripheral areas covered in serosanguineous crusts



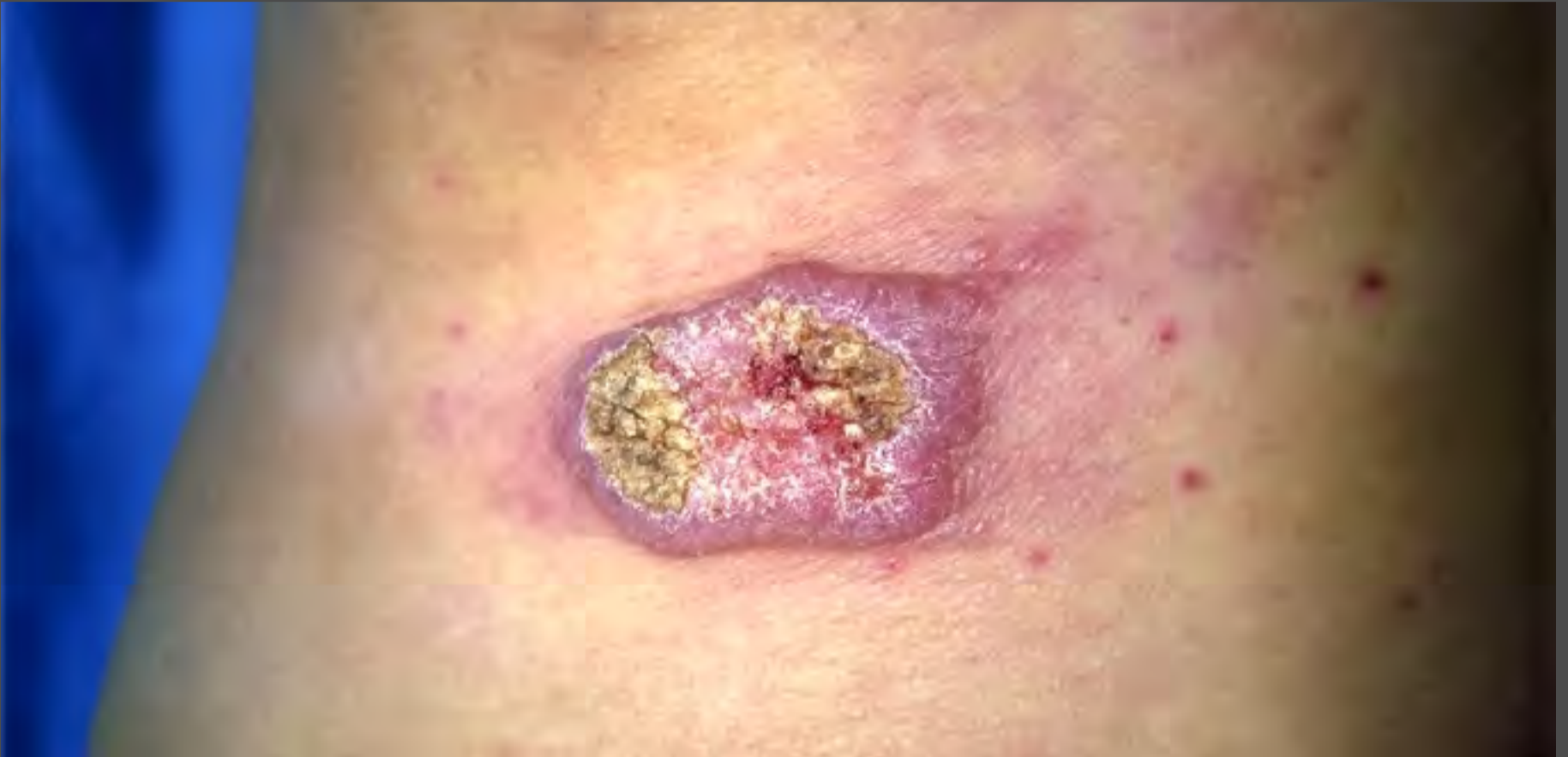**Figure 3.120.**

Rare atypical pattern, usually on the trunk, that mimics the metameric distribution of herpes zoster. Lesions are much more succulent, such as ulcers, nodules, or papules, than common herpes vesicles.

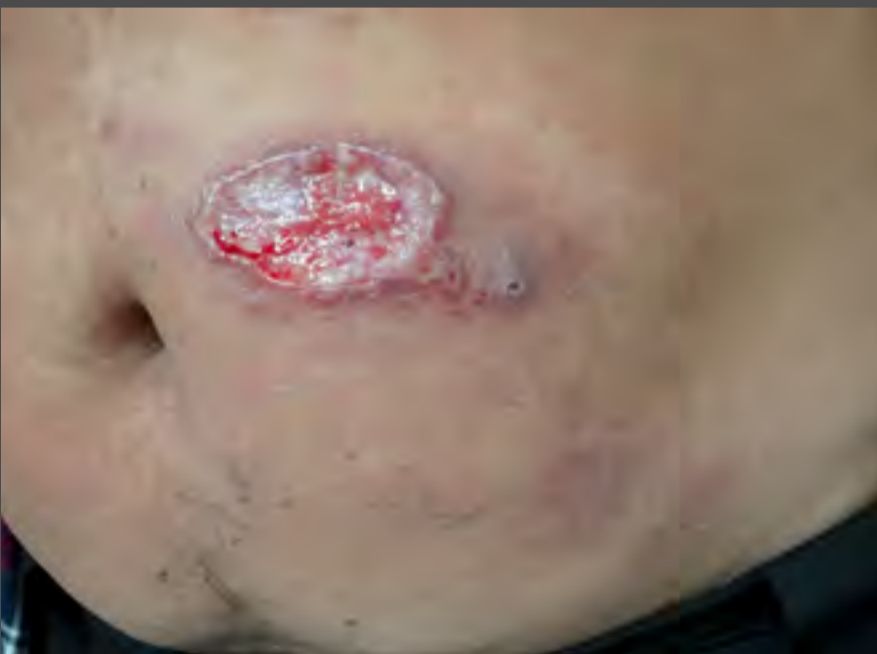

**Figure 3.121.**

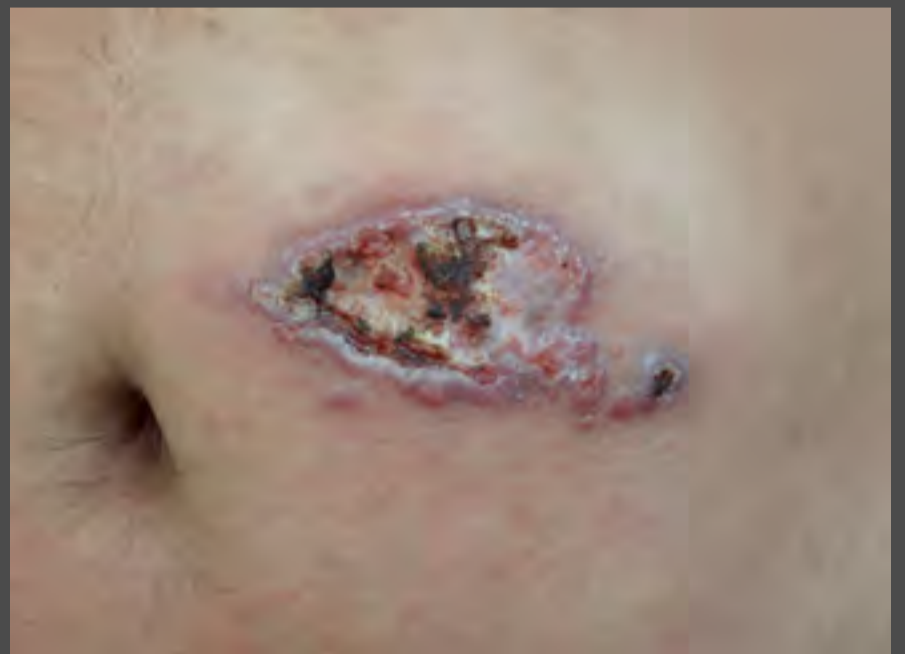Punched-out crateriform ulcer 2.2 cm in diameter, with granular floor, abundant discharge, and visible perilesional inflammation.



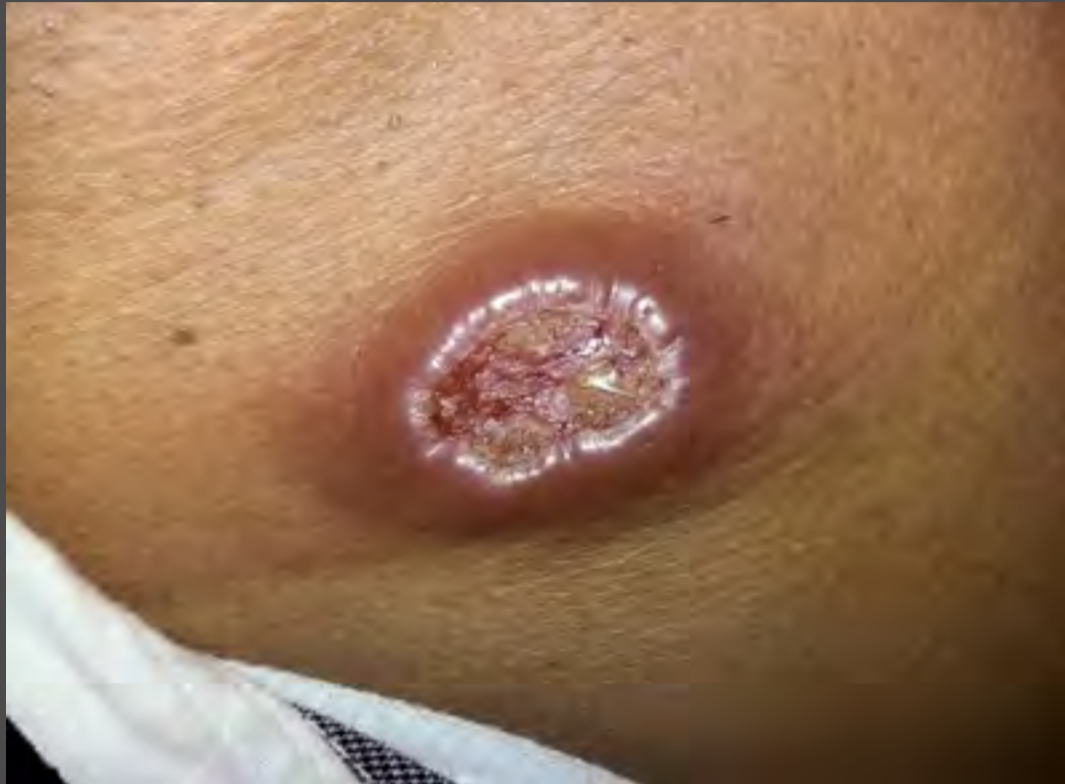**Figure 3.122.**  
Ulcer with reddish-purplish infiltrated edge with crusty center



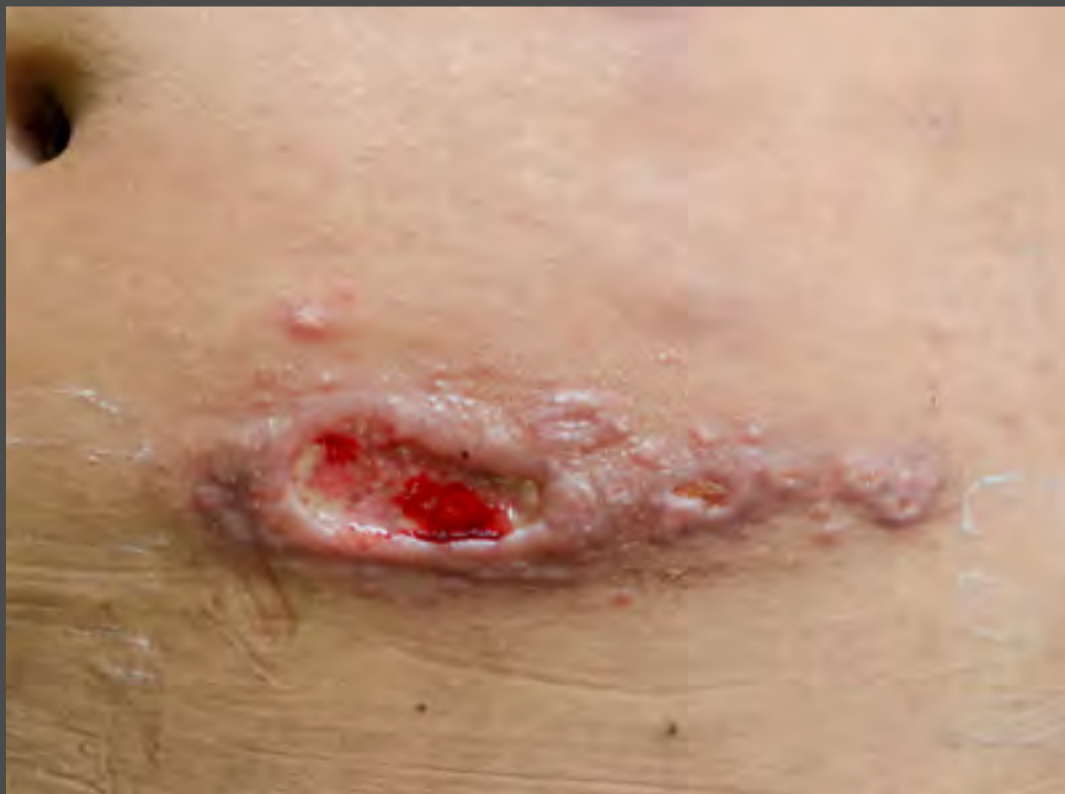**Figure 3.123A.**  
Ulcer with irregular border, cordoned edges, and granulation tissue. With treatment, it improved until closing, though infiltration persists.



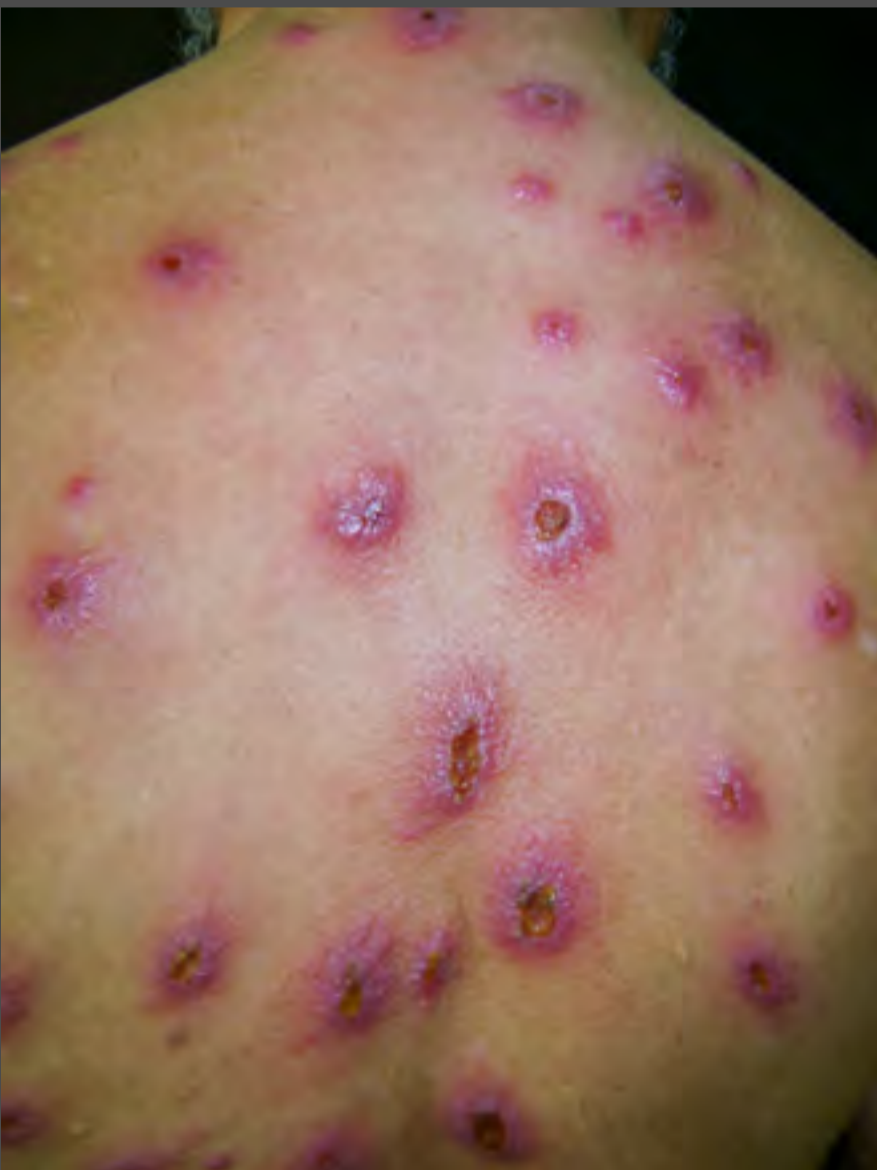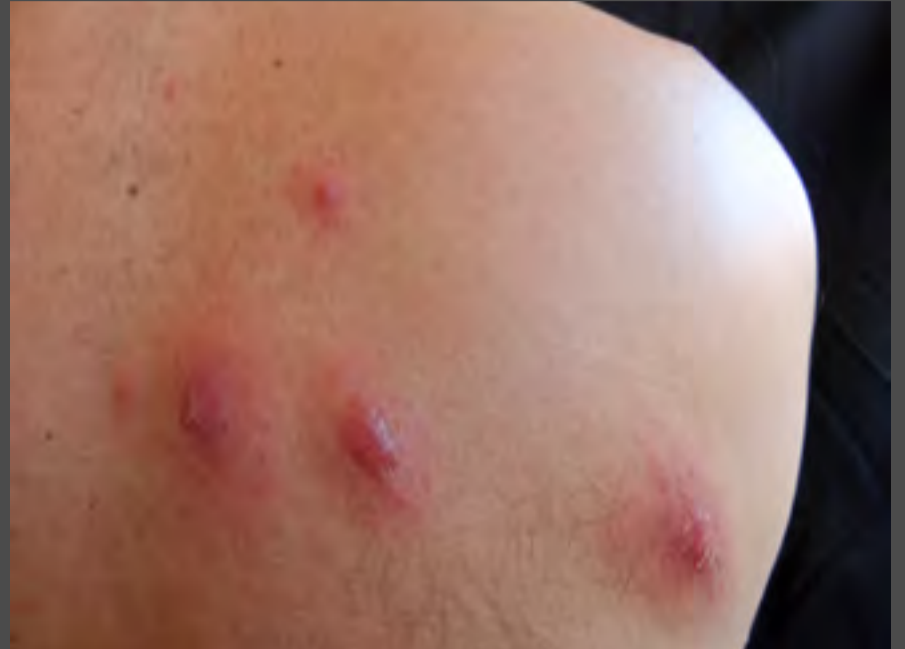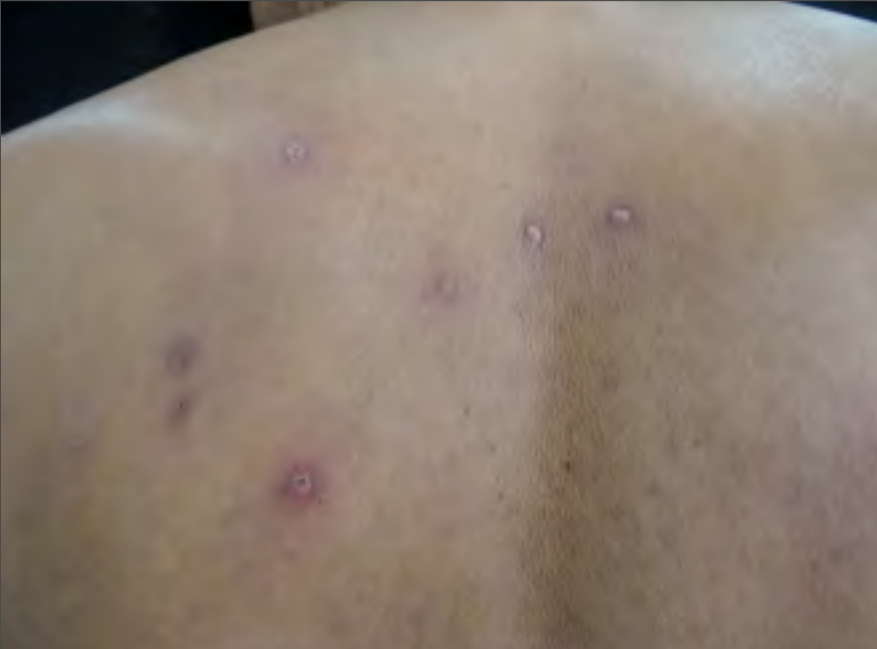**Figure 3.123B.**  
Relapse. An ovoid, infiltrated plaque with thickened and cordoned edge, and center with vegetative active areas and other fibrous areas with a scarred appearance.



**Figure 3.124.**  
Ulcerated lesion 3.5 cm in diameter



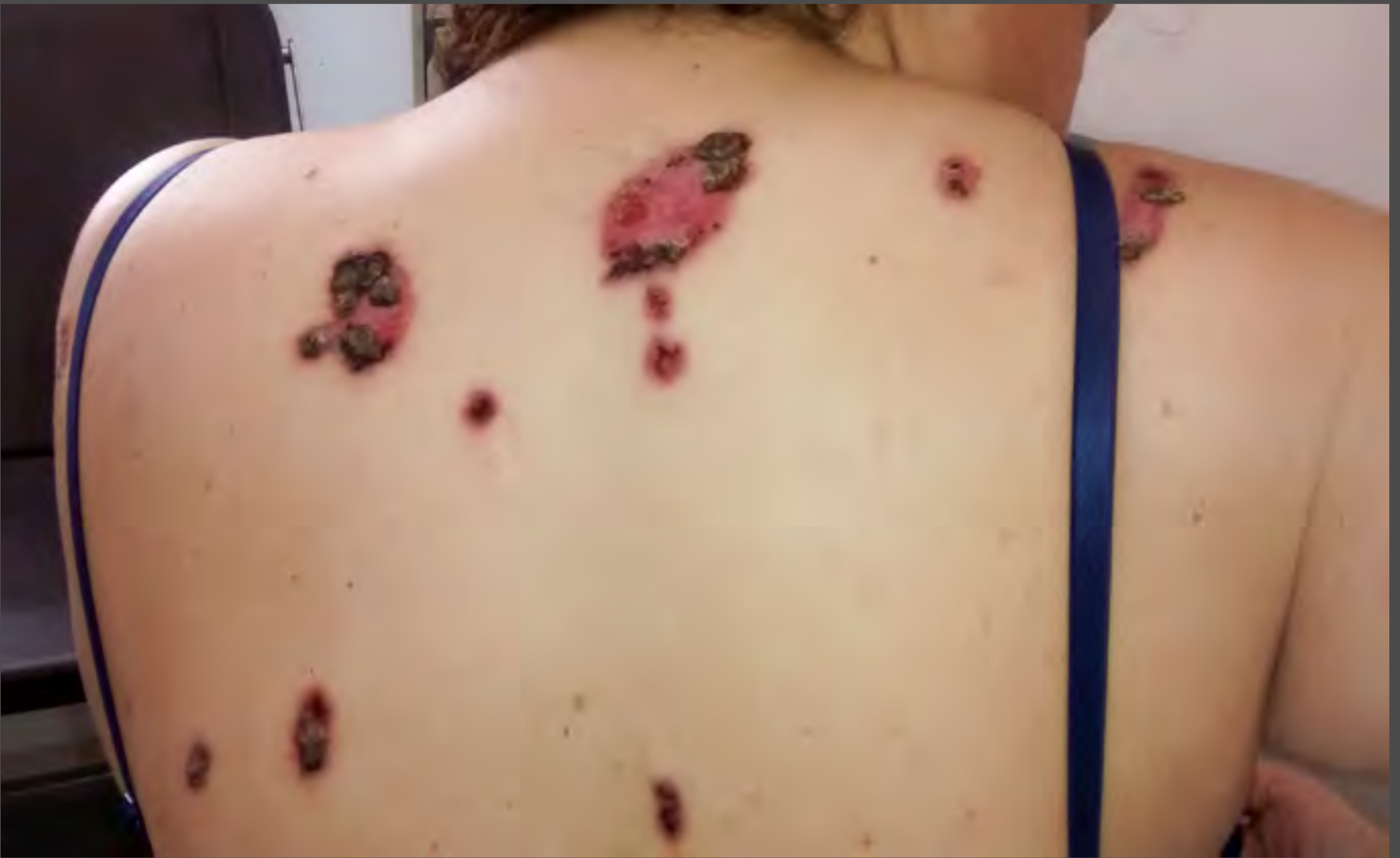**Figure 3.125.**  
Ulcer with cordoned edges and a granular center  
that has a zosteriform linear extension containing  
small ulcers and excoriations.



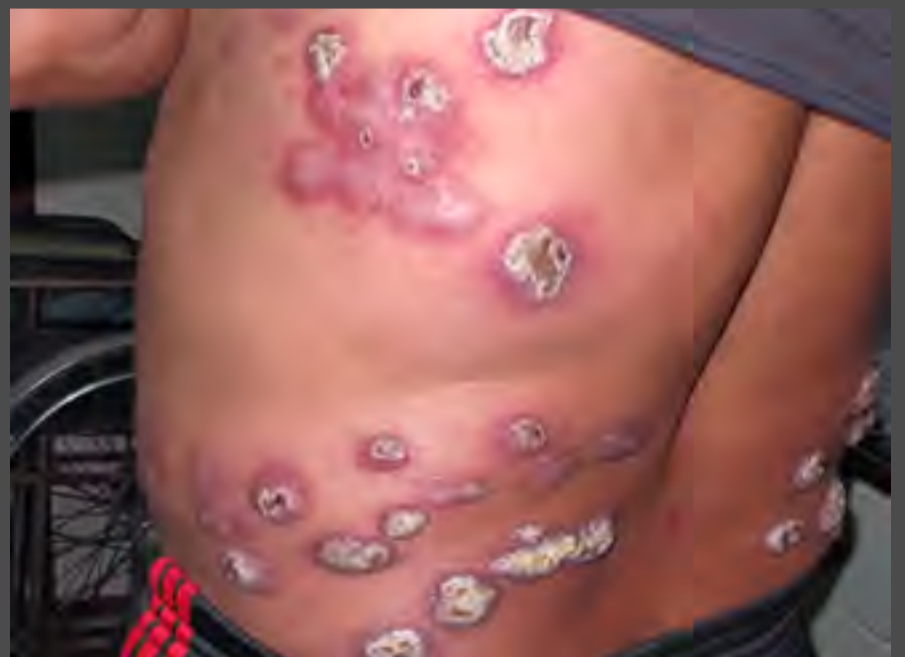**Figures 3.126A, B and C.**

A large number of lesions is infrequent and almost always due to multiple bites at the same time when spending the night without any protection in areas where there is transmission. Characteristically, the lesions are at the same stage of development and are located on areas of the body that are usually unprotected.

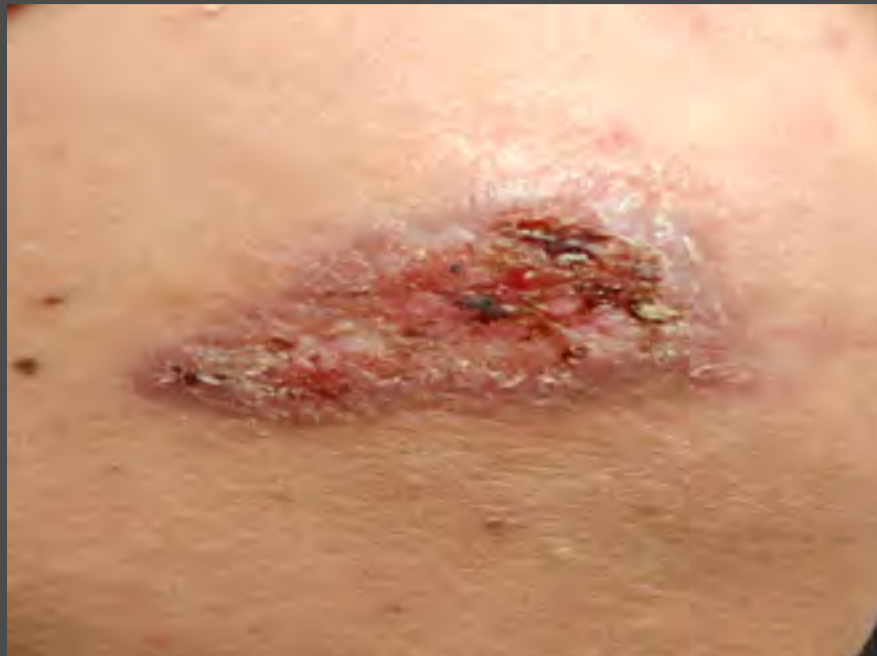



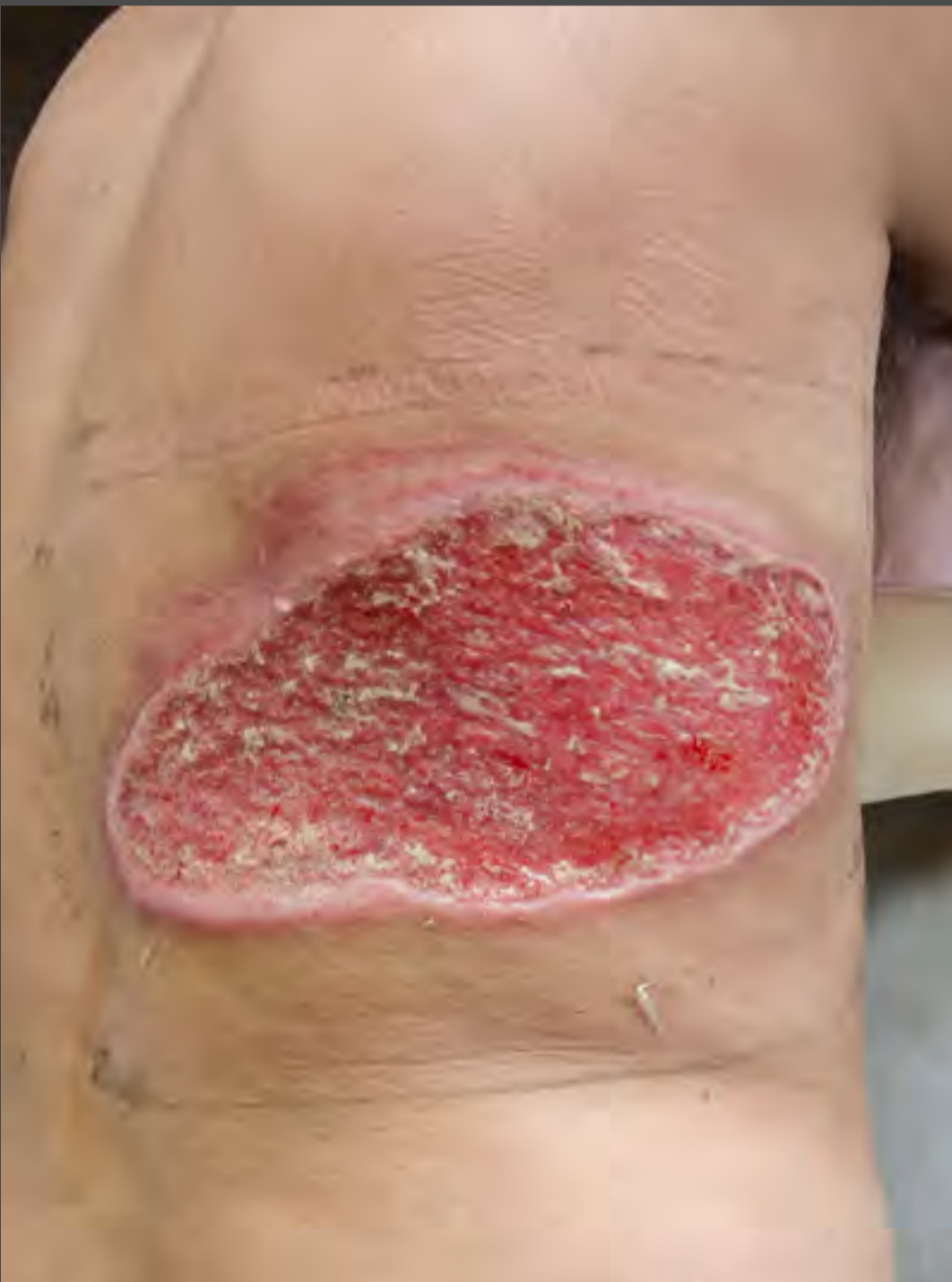**Figure 3.127.**  
Multiple ulcerous, crusty lesions on the back  
(*Leishmania (V.) braziliensis*)



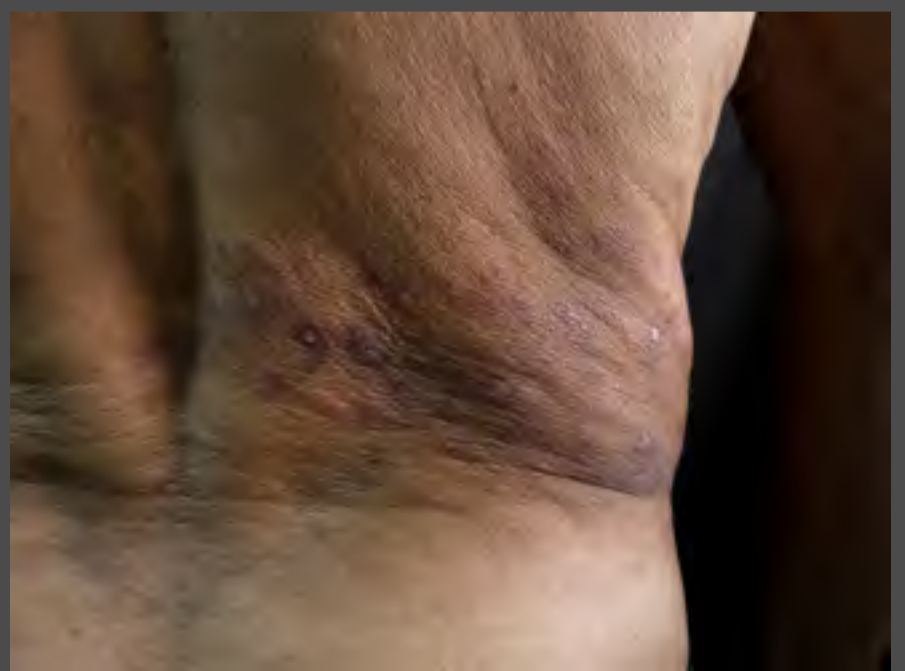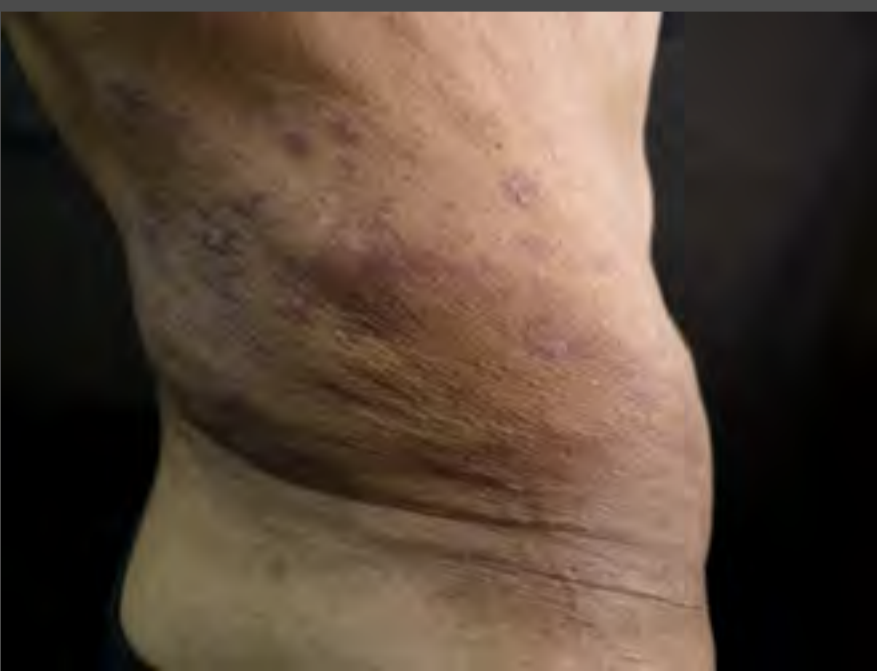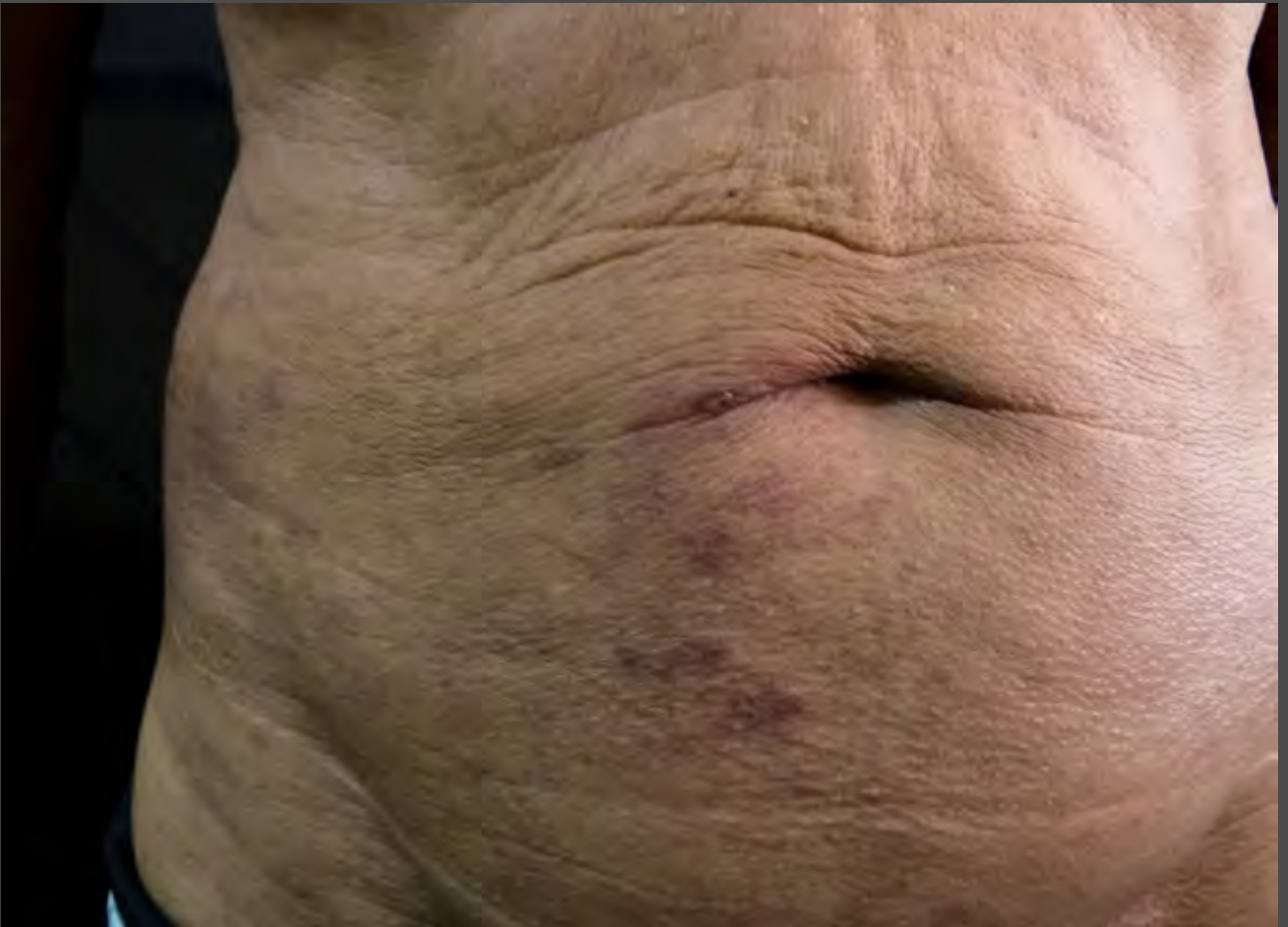**Figure 3.128.**  
Multiple lesions in erythematous plaques with a  
warty surface, which involve almost the entire back  
and mimic chromomycosis.



**Figure 3.129.**  
Crusty ulcer (*Leishmania (V.) braziliensis* complex)



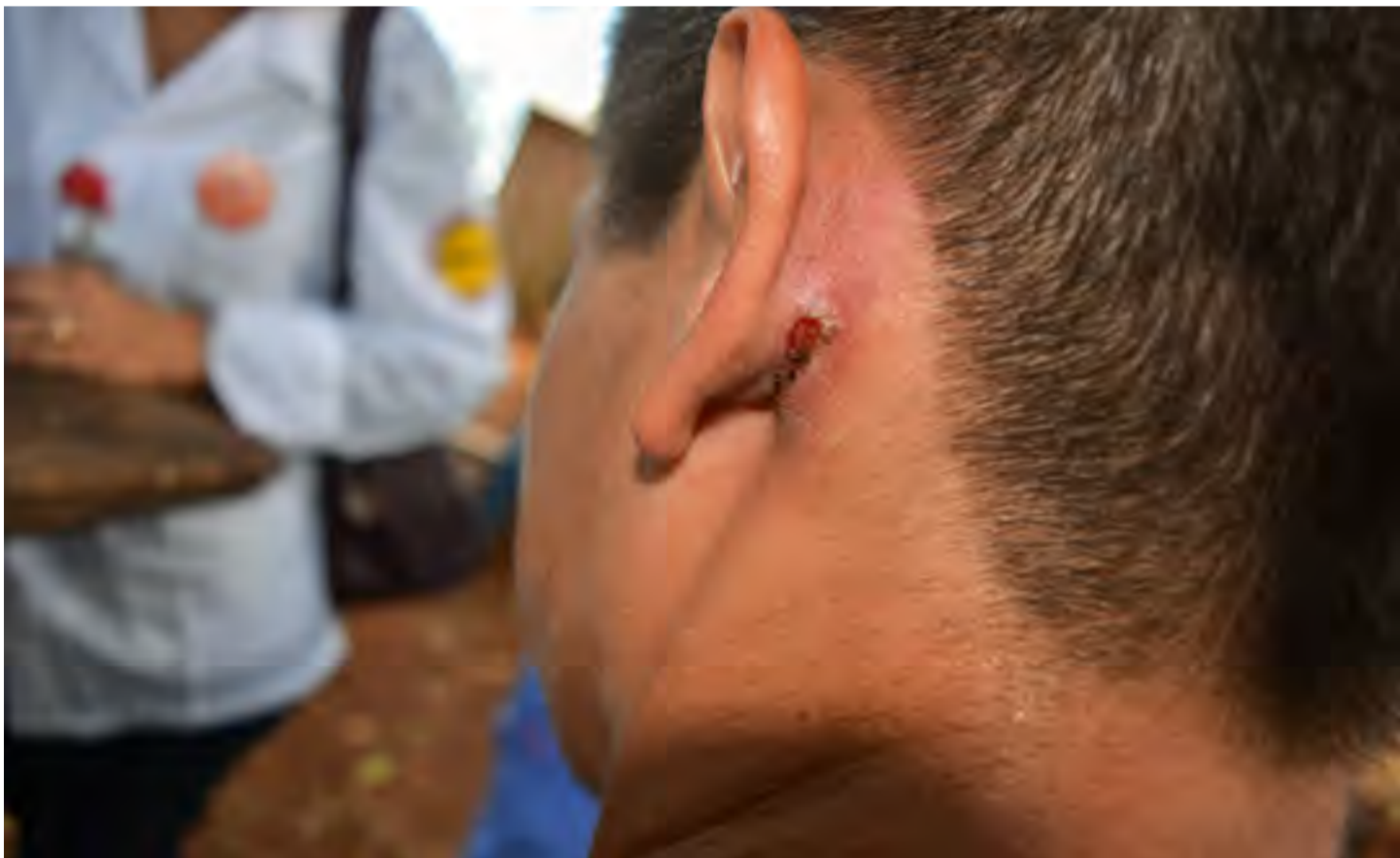**Figure 3.130.**  
Large, six-month-old ulcer (13 x 23 cm)  
on the trunk, which maintains the special  
characteristics of leishmaniasis lesions.



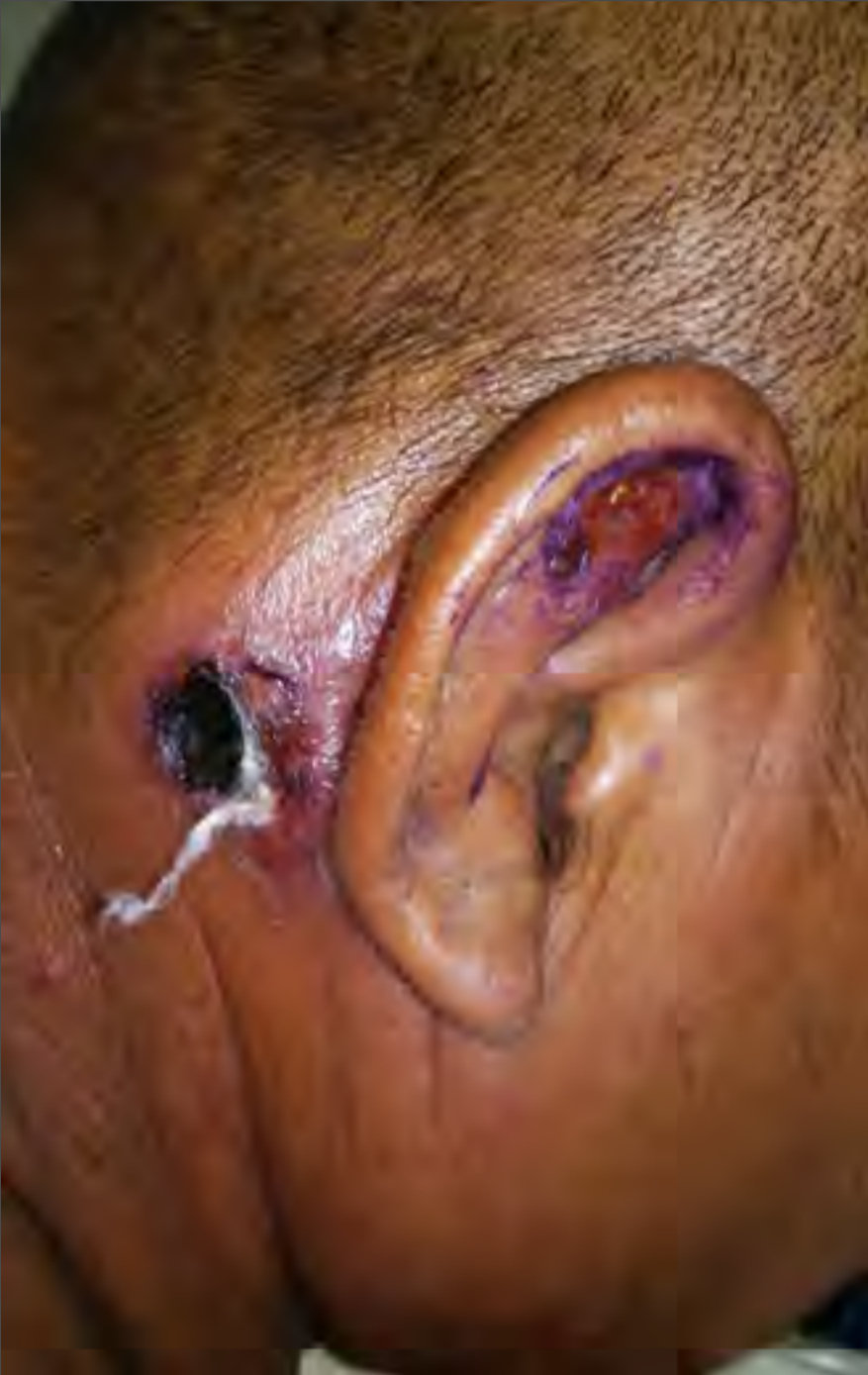**Figures 3.131A, B and C.**

Zosteriform cutaneous leishmaniasis. Lesions may adopt a zosteriform distribution pattern, for no apparent reason. They are multiple, generally superficial, and not very infiltrated, but very inflammatory and have a dermatomal distribution similar to herpes zoster.

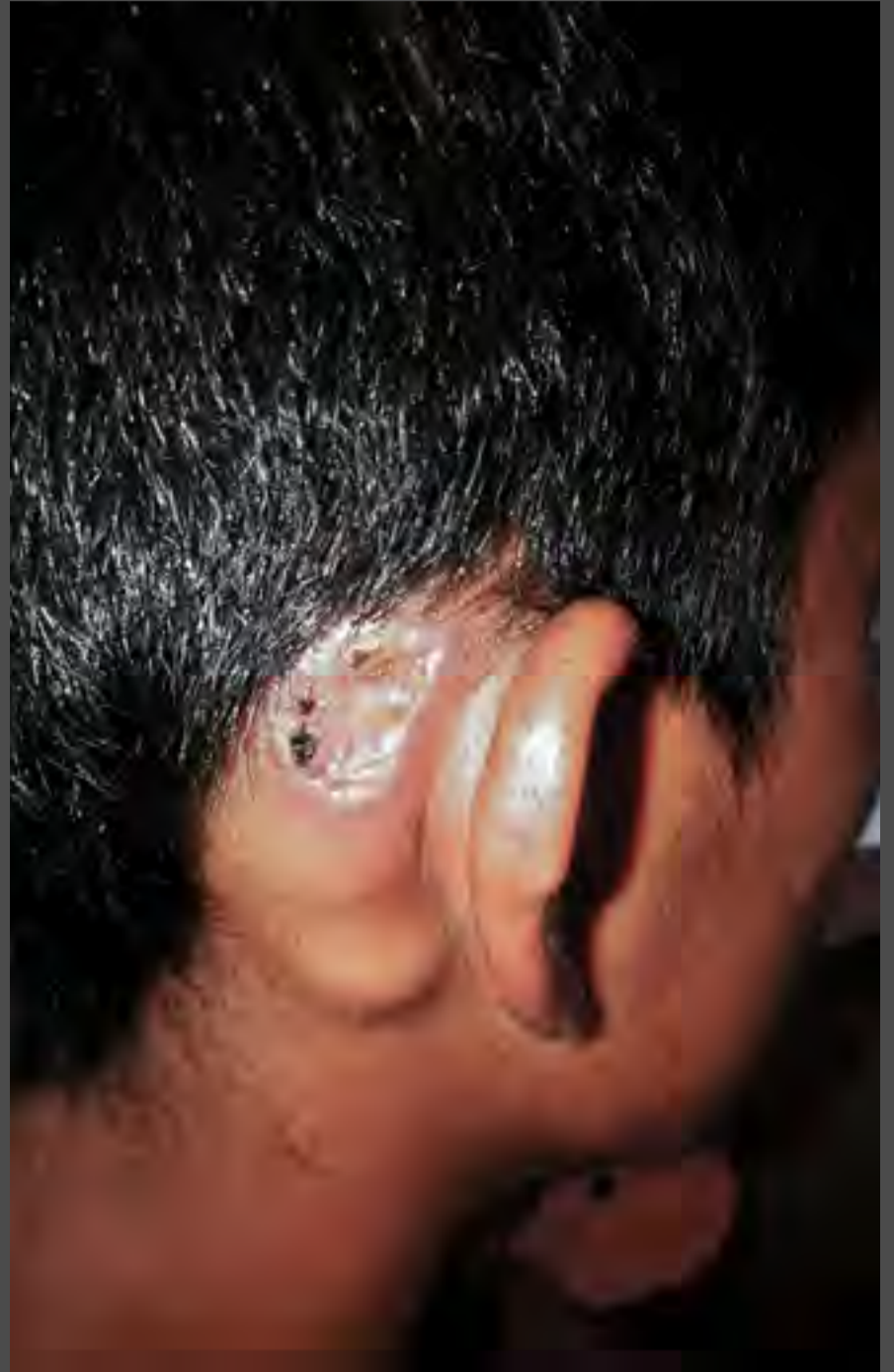When the ulcer is located on the ear (*Figures 3.132 to 3.166*) it is known as a *chiclero* ulcer, because of its high frequency among the chicle collectors of Mexico, where it is caused by *L. (L.) mexicana* and consists of a slow-growing ulcer. In South American countries, lesions have been seen at the same site that are caused by other species of subgenus *Viannia*, which can produce metastases to the mucous membranes (primarily in preschool-age children in Peru), unlike the Mexican form.



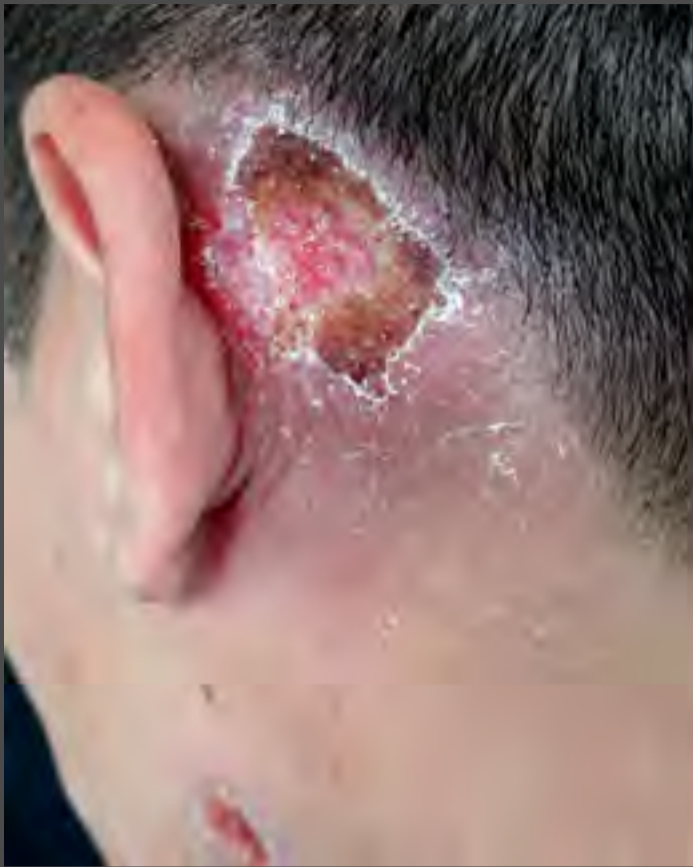**Figure 3.132.**  
Ulcer located behind the ear (*Leishmania (V.) braziliensis* complex)



**Figure 3.133.**  
Lesion on left ear with serosanguineous crusts and pruritus.

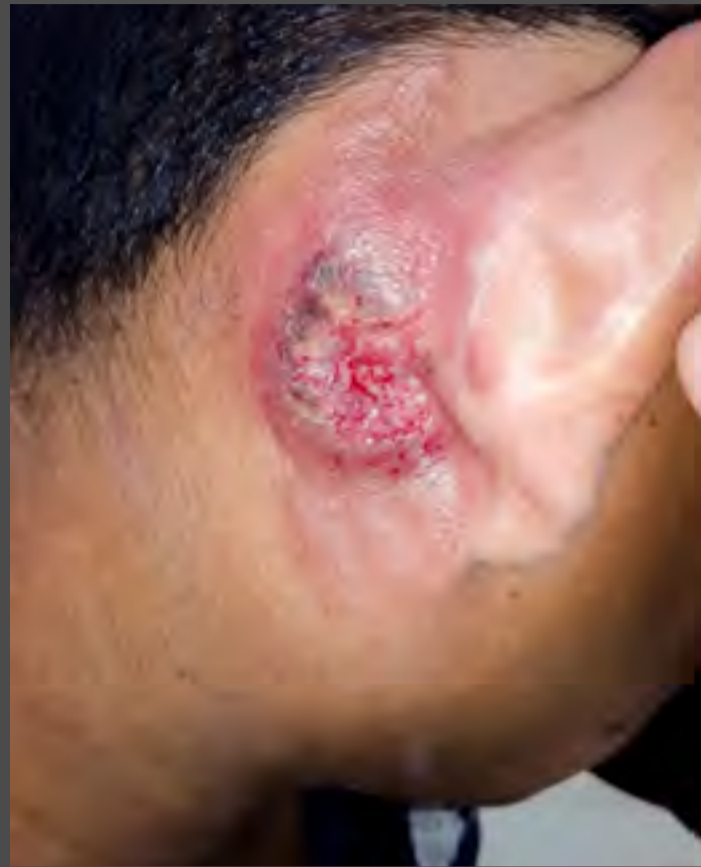

**Figure 3.134.**  
Lesion approximately 2 cm in diameter, located on back of right ear



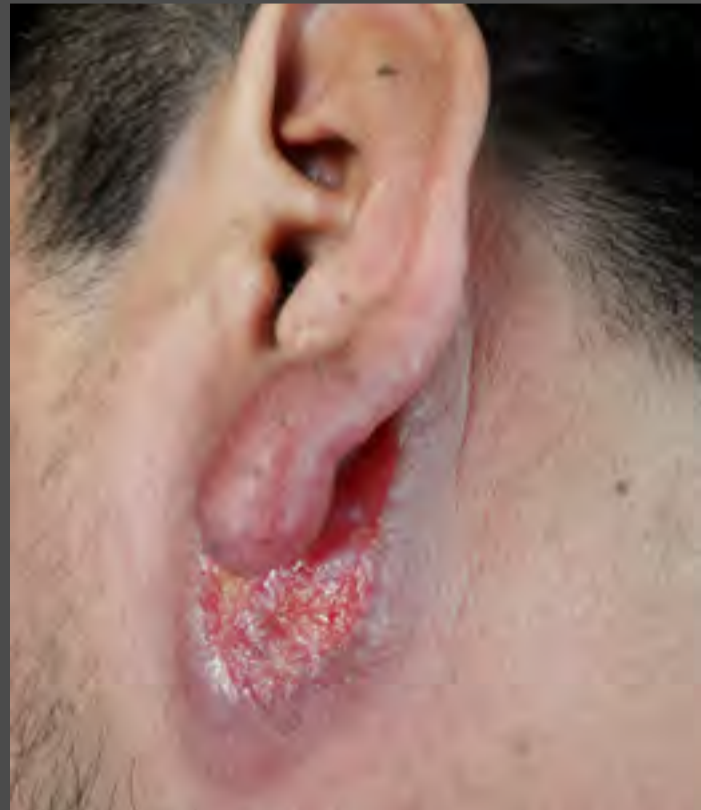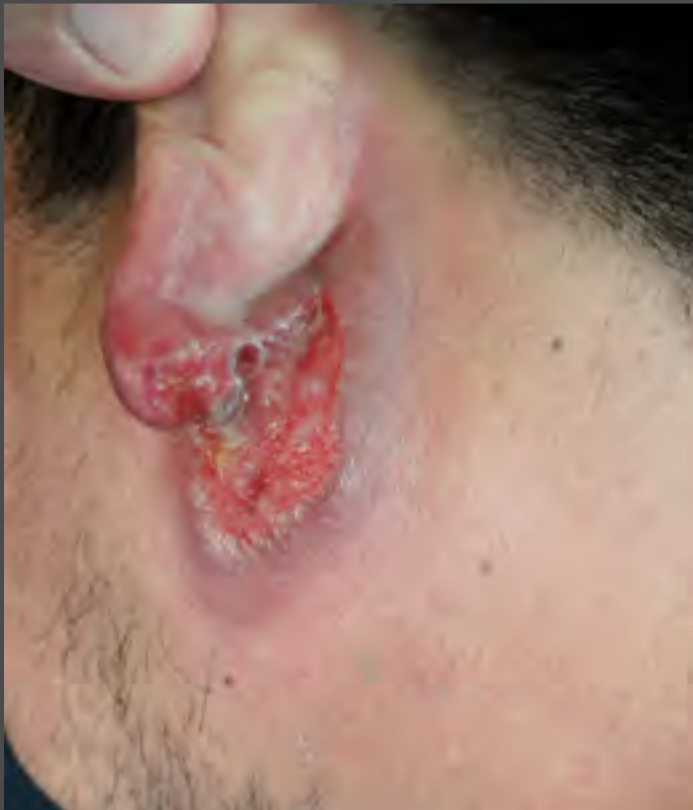**Figure 3.135.**

Superficial, irregular ulcer covered by a very adherent serosanguineous scab, located on the fold and on the retroauricular area. There was a smaller similar lesion on the neck.



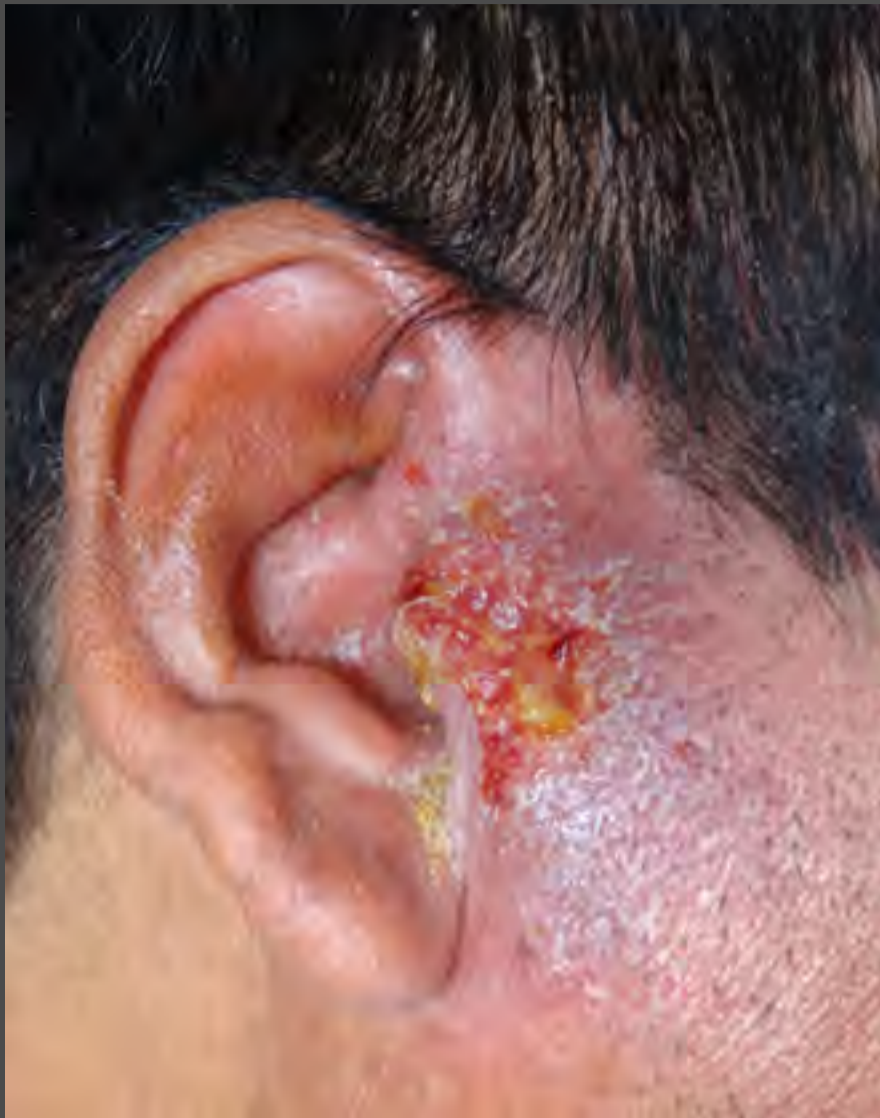**Figure 3.136.**

Lesion with serosanguineous crust and pruritus located on the retroauricular area

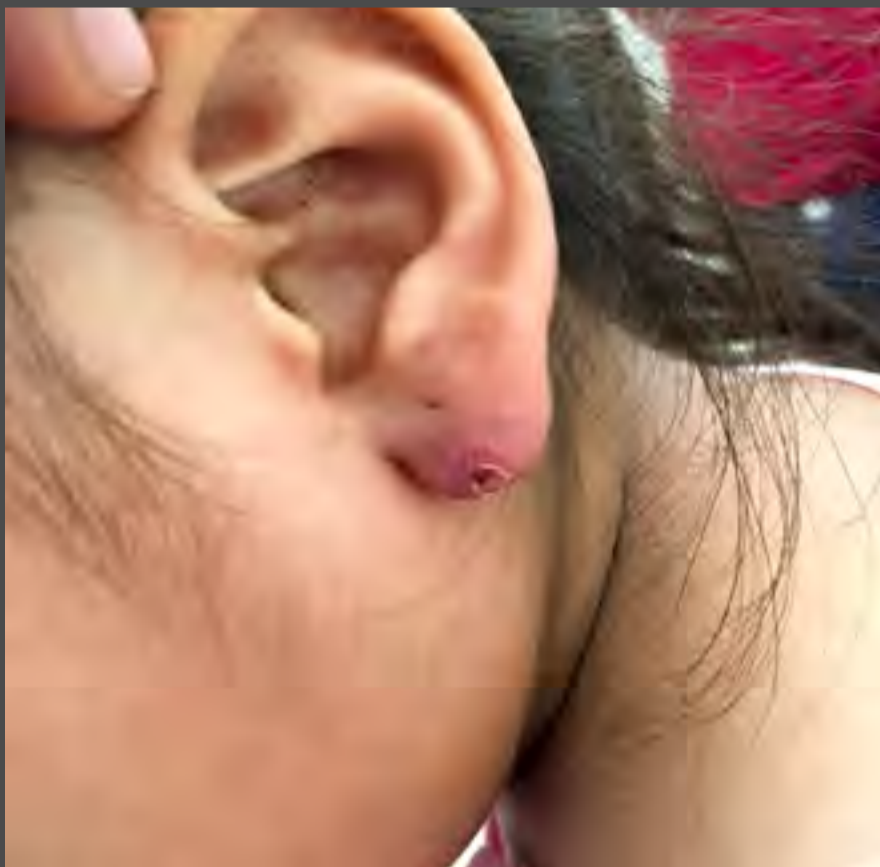

**Figures 3.137A and B.**

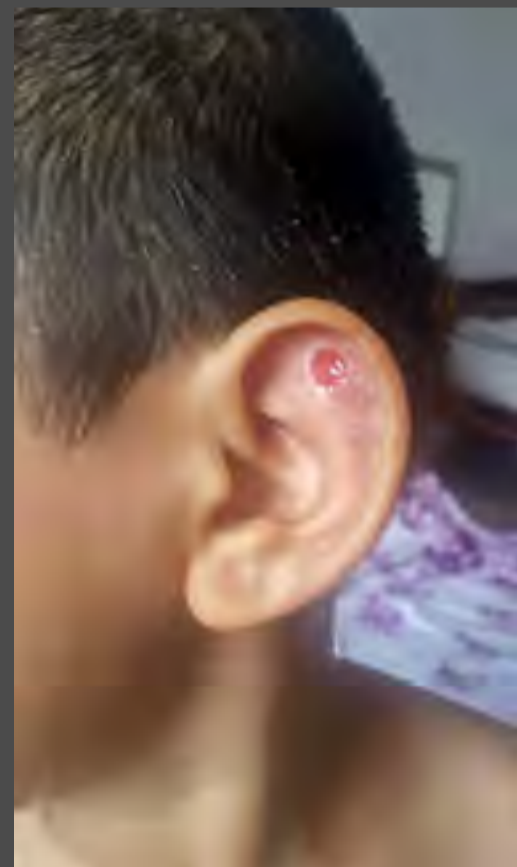Rounded ulcer with reddish-purplish, thickened, raised, and cordoned edges, and a granular center covered by seropurulent secretions. It involves the skin of the neck and the earlobe, from which it detached, and is accompanied by inflammatory adenopathies on the neck.



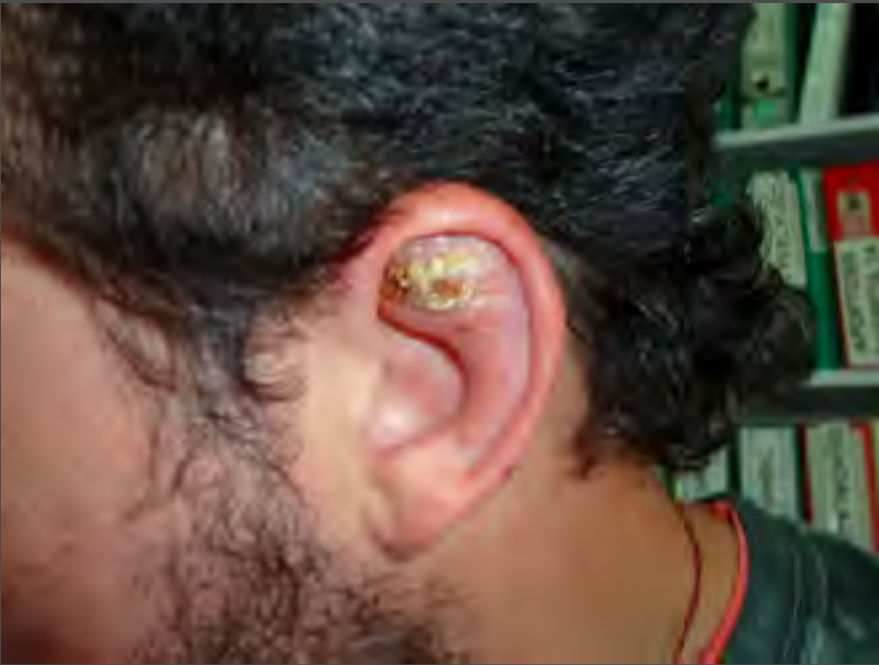**Figure 3.138.**  
Infiltrated plaque with irregularly ulcerated central area covered with honey-colored crusts, located on the preauricular area and tragus, accompanied by adenopathies.



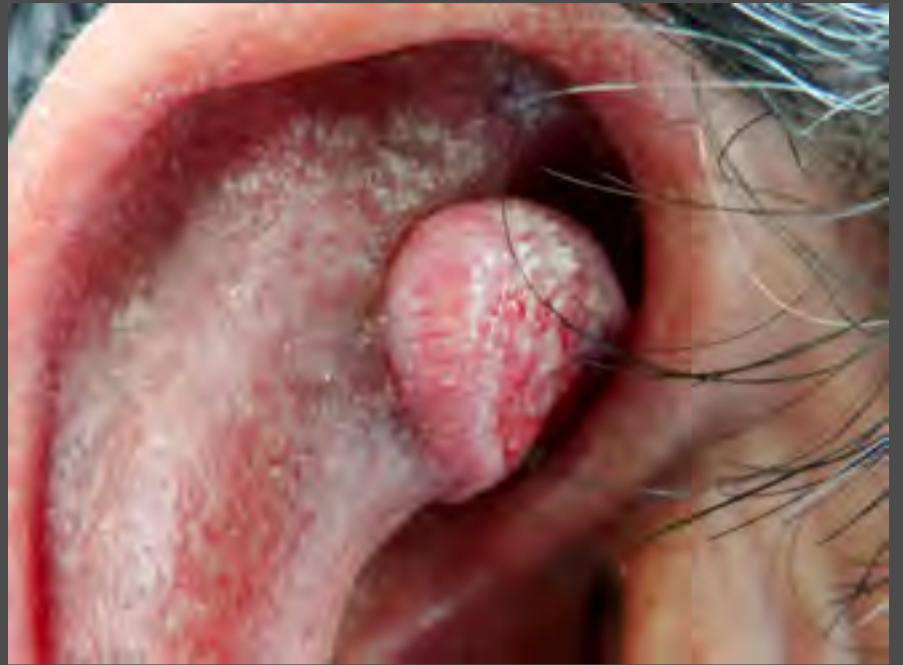**Figure 3.139.**  
Rounded, erythematous ulcer, with serosanguineous crust, painful on palpation, scratch marks on left earlobe



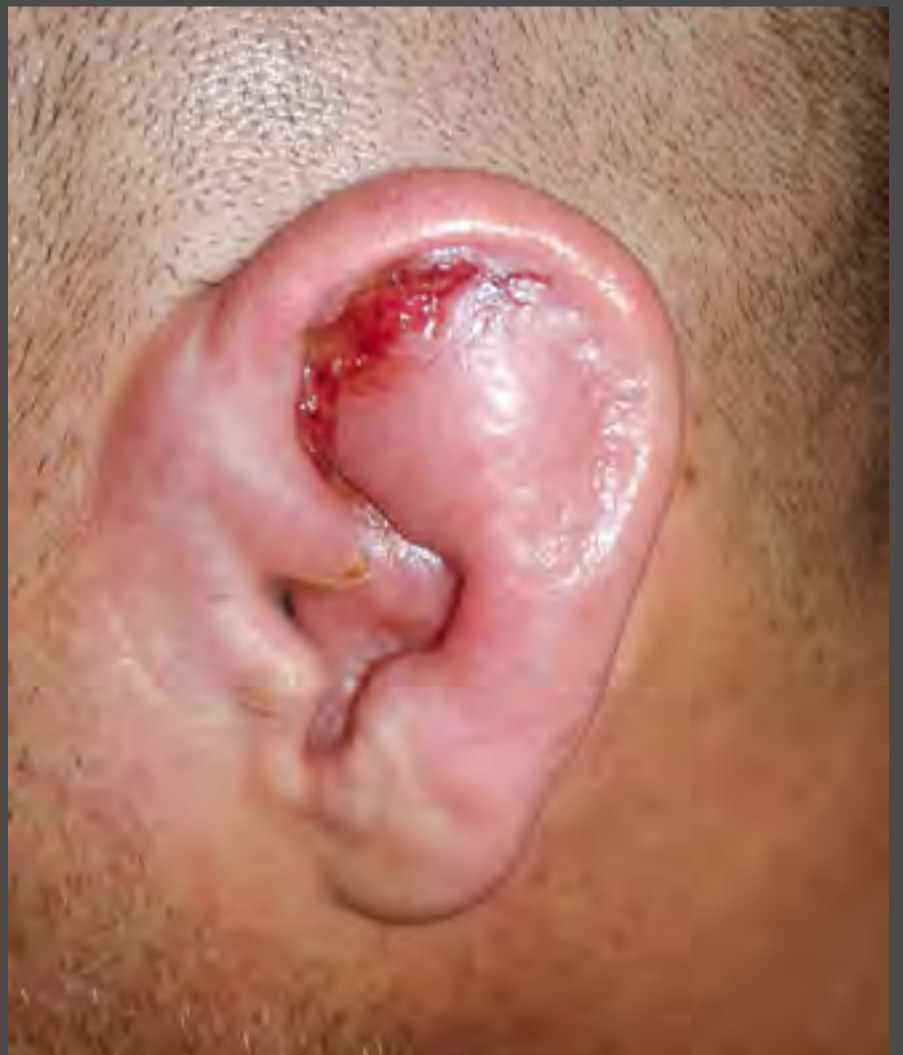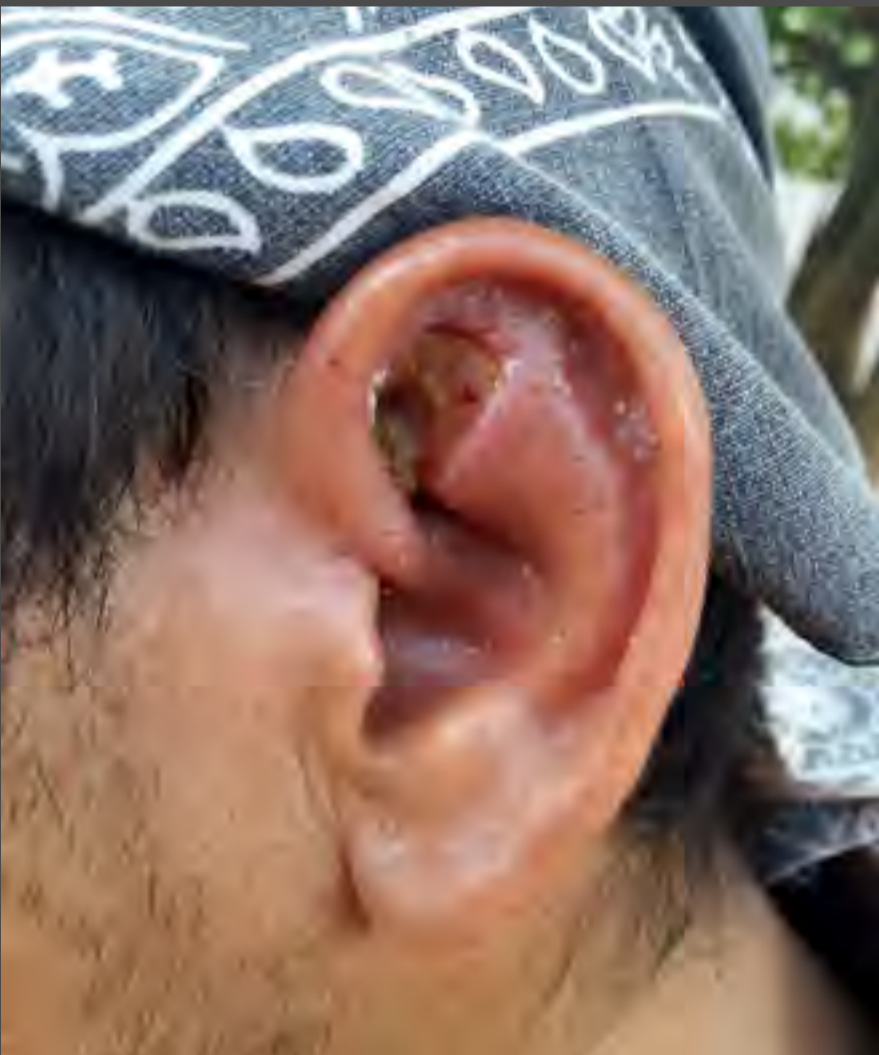**Figure 3.140.**  
Small ulcer with clean floor, distinct edges, and no crusts



**Figure 3.141.**  
Dry squamous lesion on the ear (*Leishmania*  
(*L.*) *mexicana*)

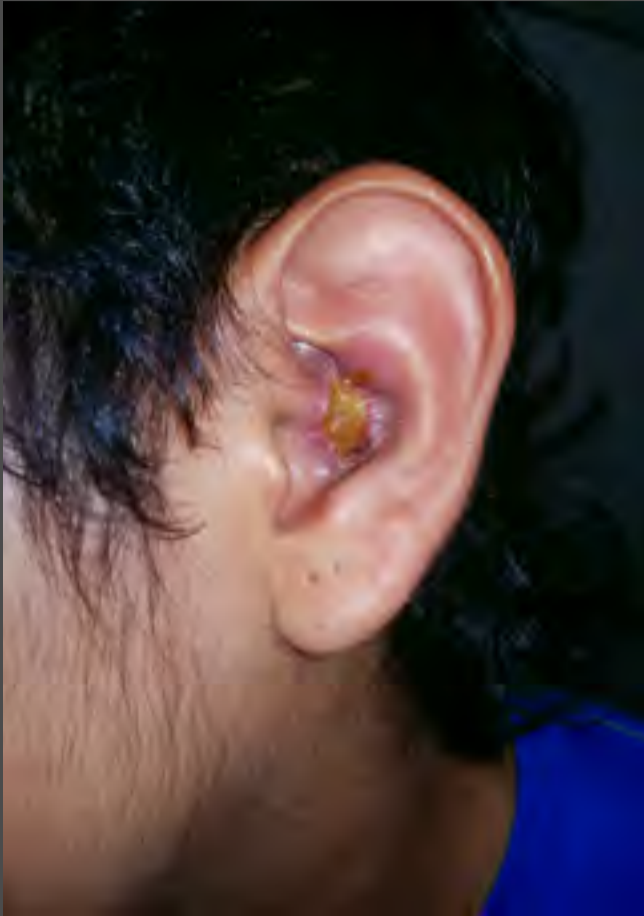

**Figure 3.142.**  
Lesion very typical of cutaneous leishmaniasis,  
sharply demarcated, with raised edges, crateriform  
appearance, and depressed center

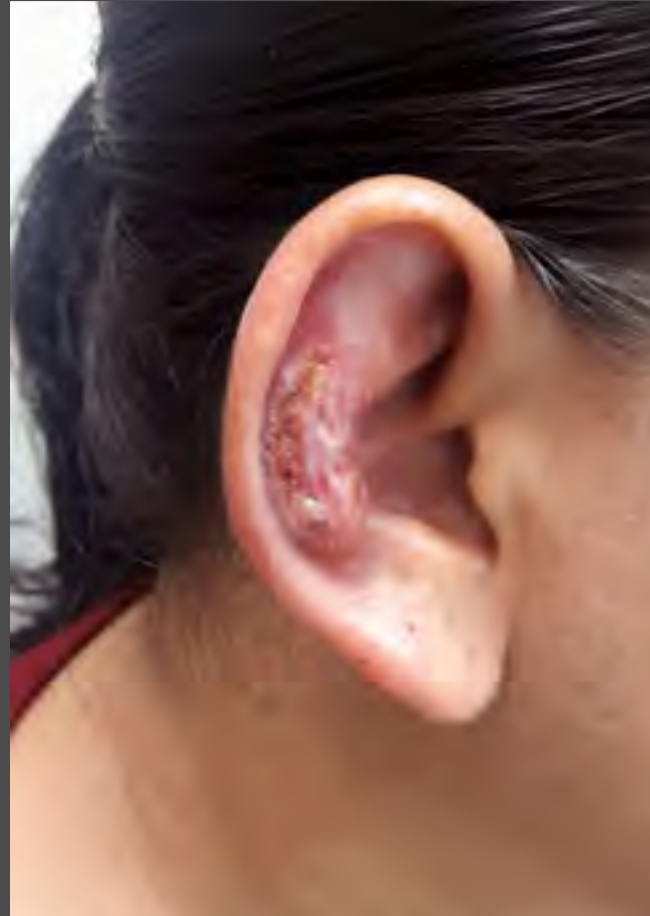

**Figures 3.143A and B.**  
Ulcerated lesion approximately 2 cm in diameter, on left ear

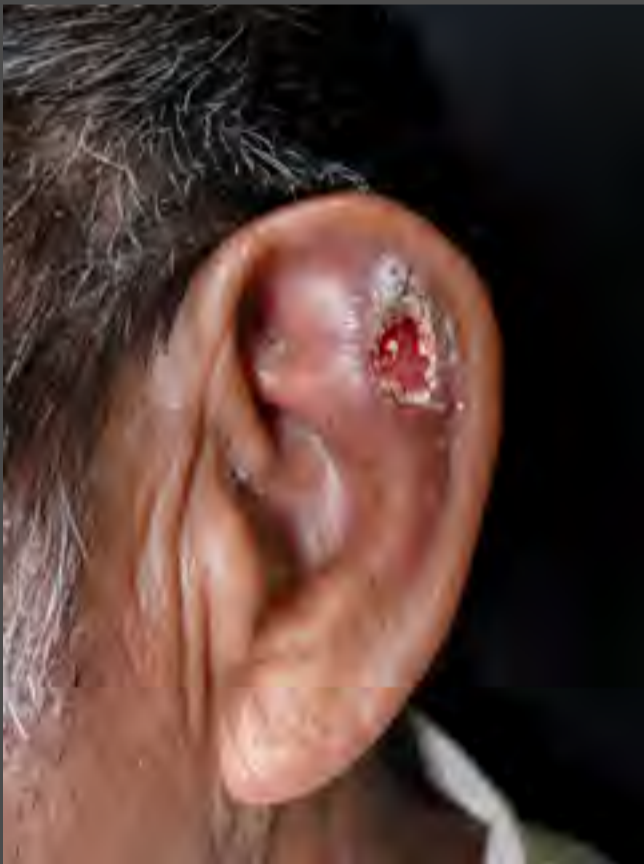



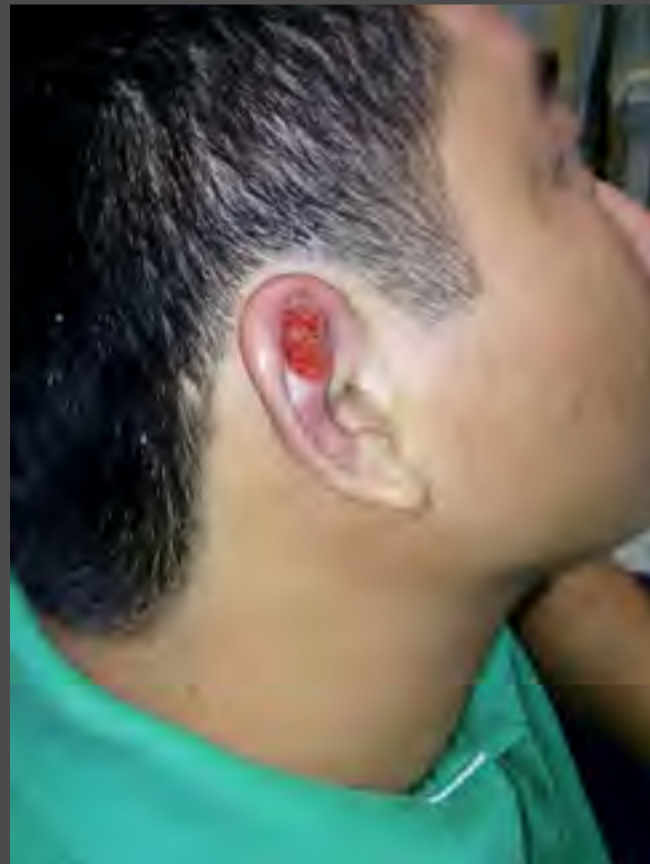**Figure 3.144.**  
Ulcerated lesion approximately 1.5 cm  
in diameter, on left ear



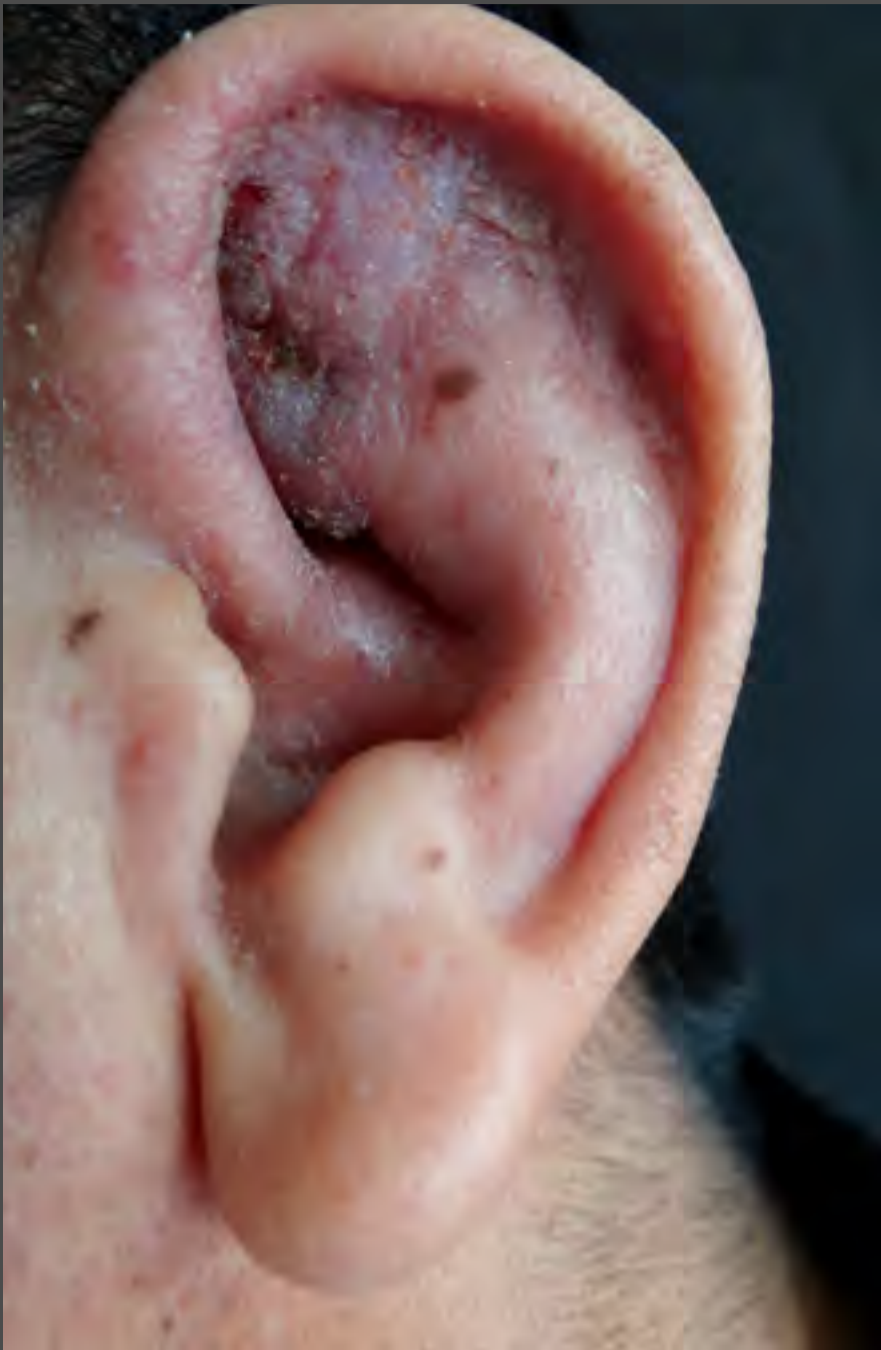**Figure 3.145.**  
Leishmaniasis on right ear



**Figure 3.146.**  
Ulcer on antihelix, 9 months old, that  
shows a warty plaque on its edge after a  
second treatment for leishmaniasis.

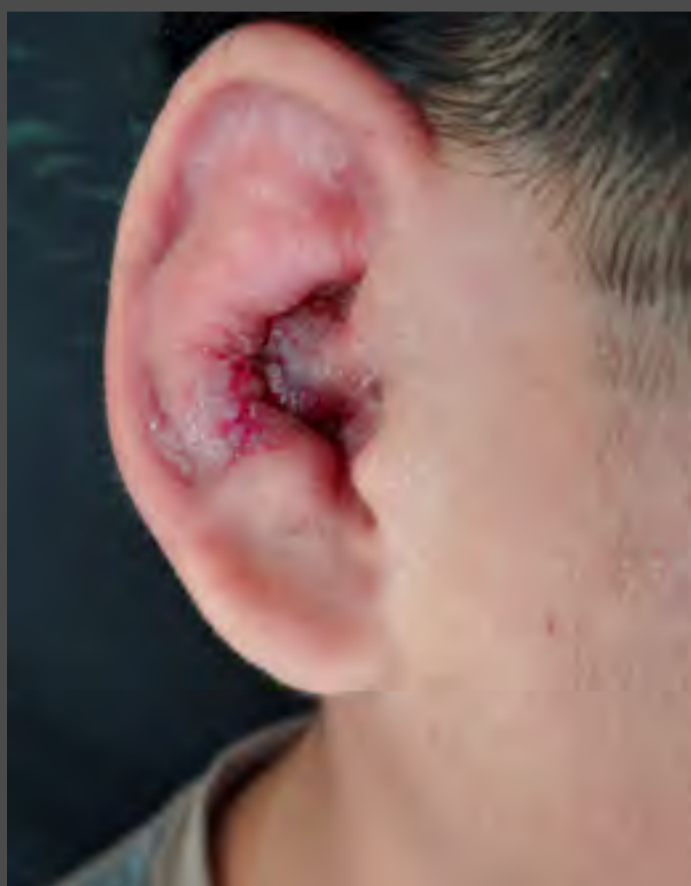
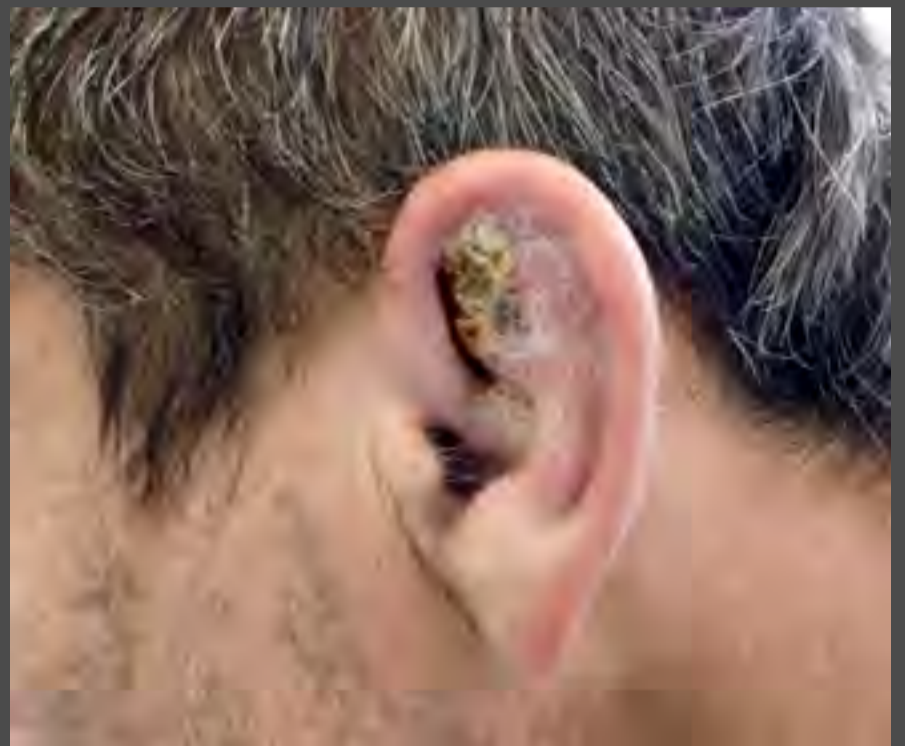
**Figure 3.147.**  
Lesion on right ear, with pruritus

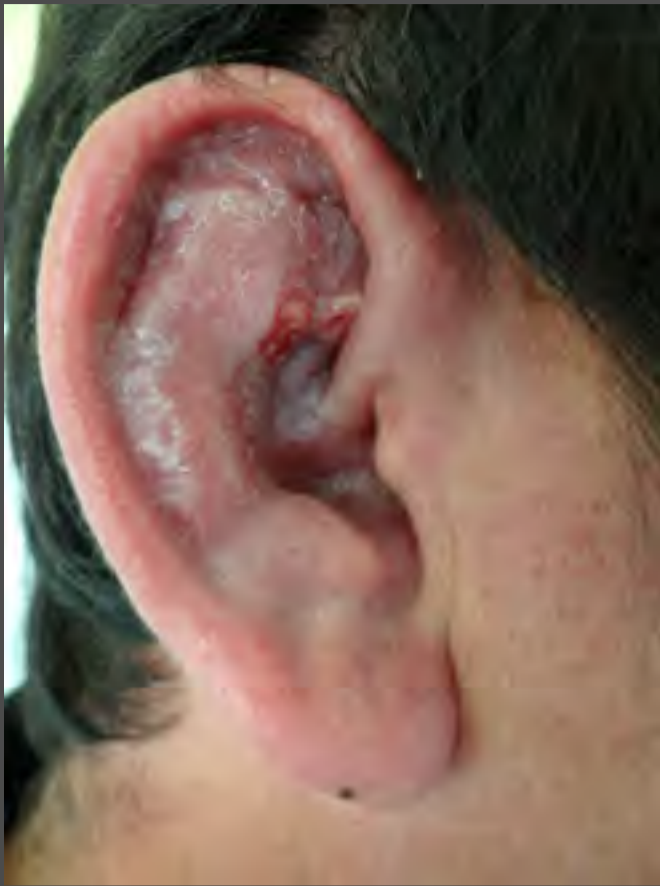

**Figure 3.148.**  
Infiltrated plaque on antihelix, with a warty-looking surface

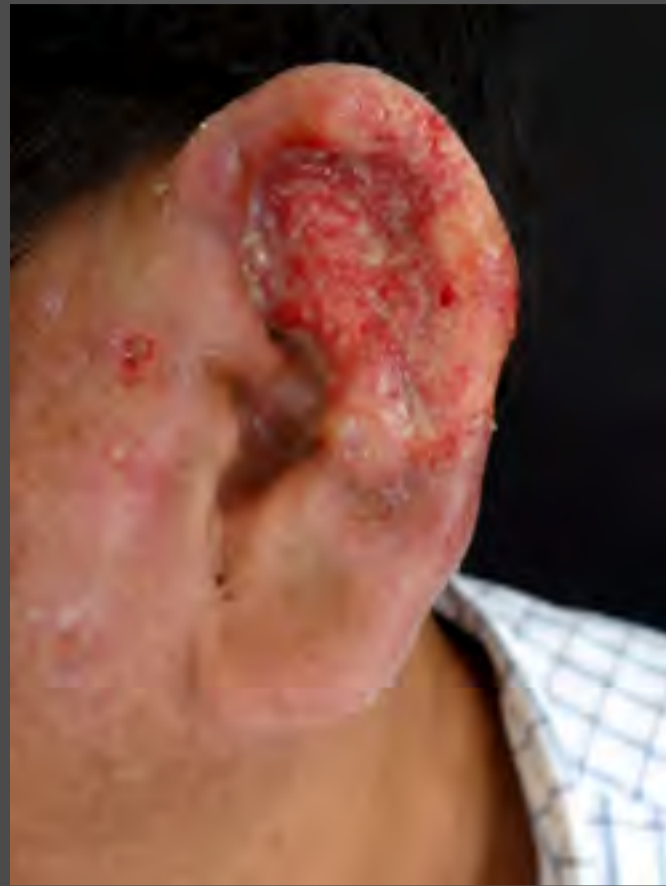**Figure 3.149.**  
Appearance of ear after receiving treatment (*Leishmania (L.) mexicana*)



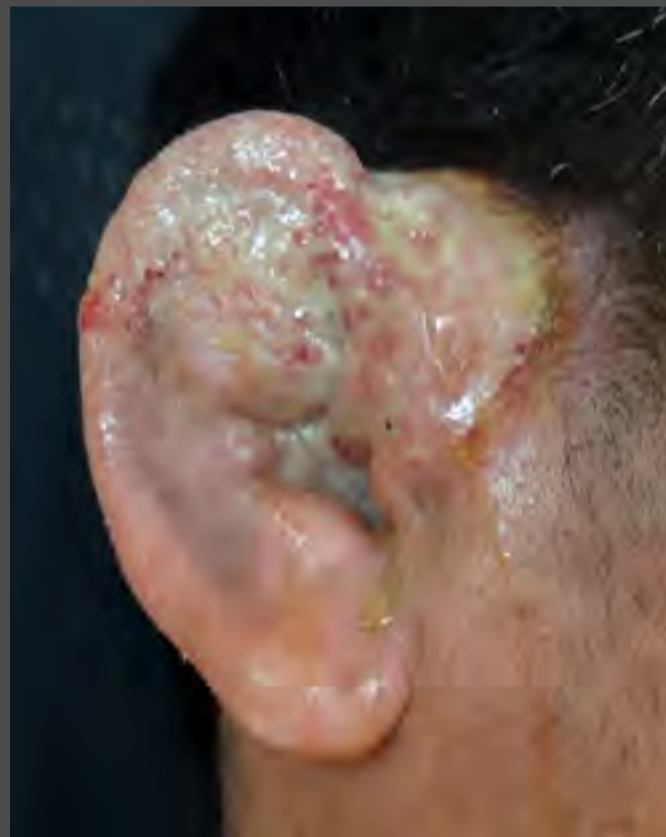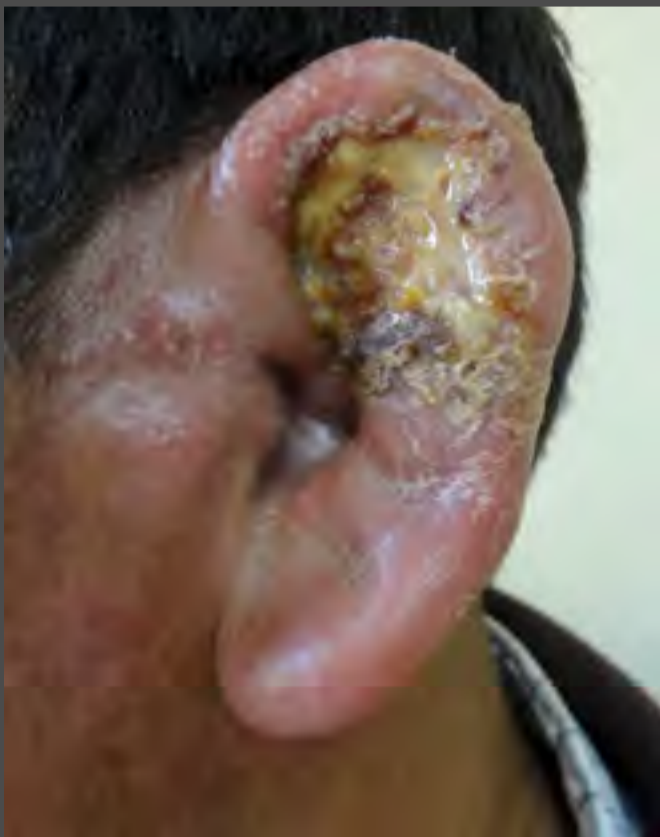**Figure 3.150.**  
Infiltrated plaque with a warty-looking surface, occupying the middle third of the antihelix and the auricular concha.



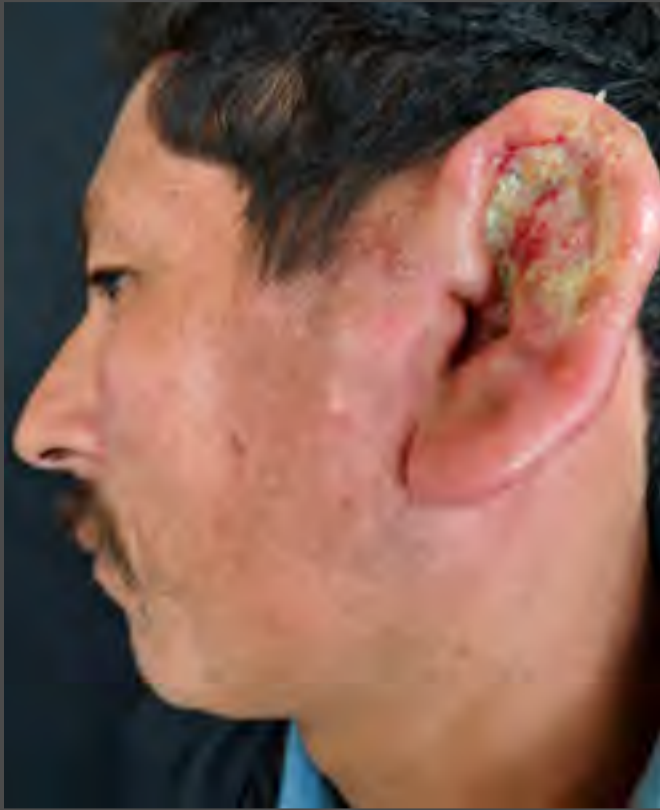**Figure 3.151.**  
Erythematous, infiltrated, dense plaque, with a smooth, shiny surface and a small ulceration, located on the antihelix



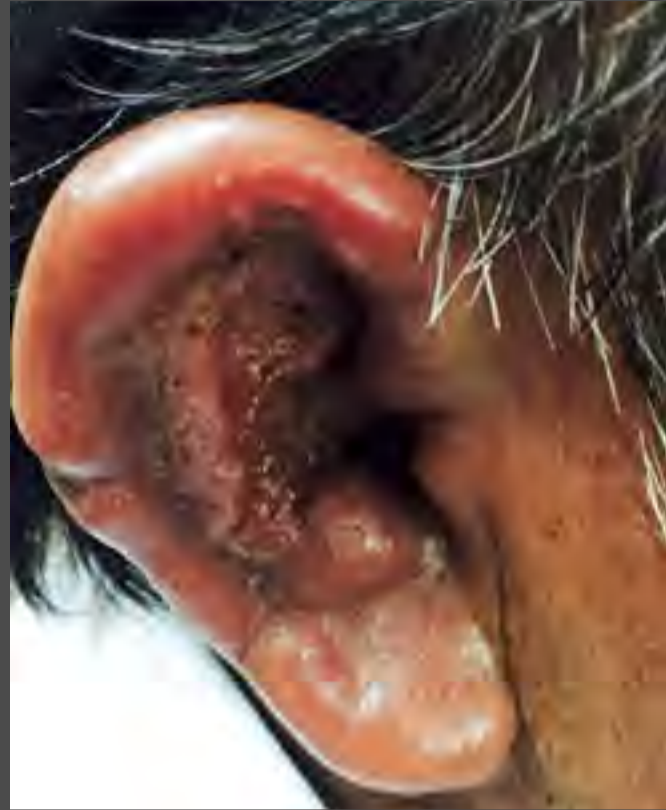**Figure 3.152.**  
Large vegetative ulcer occupying the entire antihelix and extending to the helix and auricular fossa. There are abundant serous secretions with fibrinous purulent areas and a small ulcerated preauricular satellite lesion.



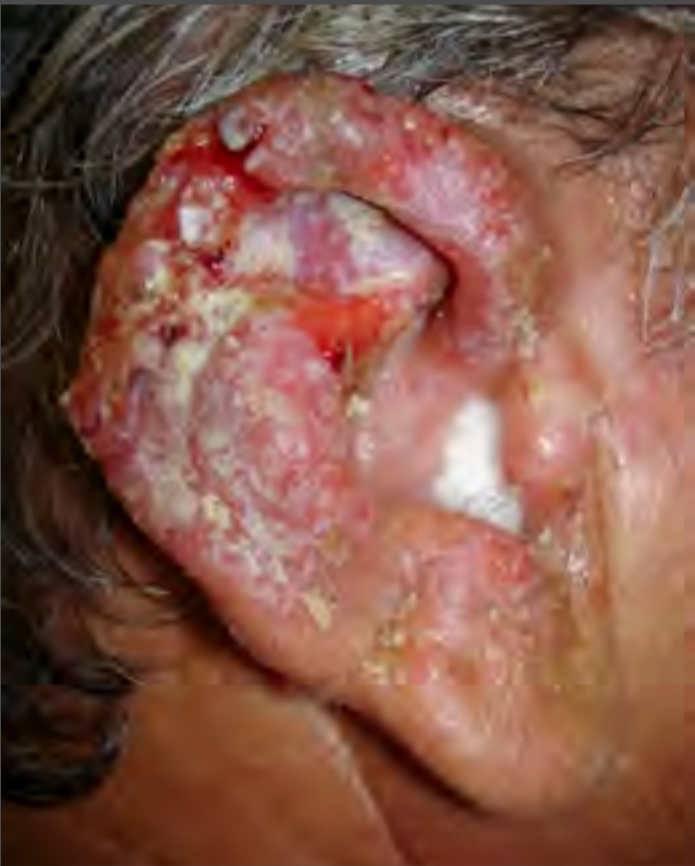**Figure 3.153A and B.**  
Cutaneous leishmaniasis with a significant bacterial superinfection. Abundant purulent secretions and extensive edema of the entire ear.



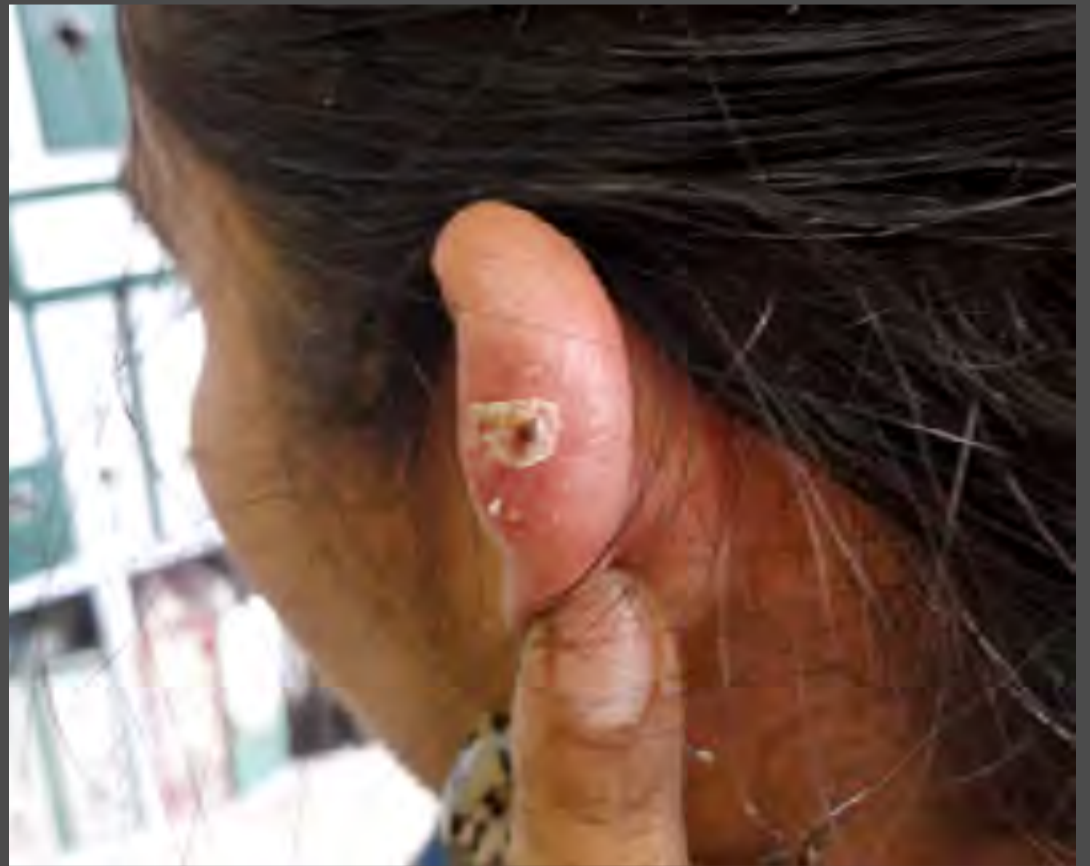**Figure 3.154.**  
Superficial ulcer on the superinfected antihelix, with extensive erythema, edema, and inflammation on the entire ear. Abundant inflammatory adenopathies on the neck.



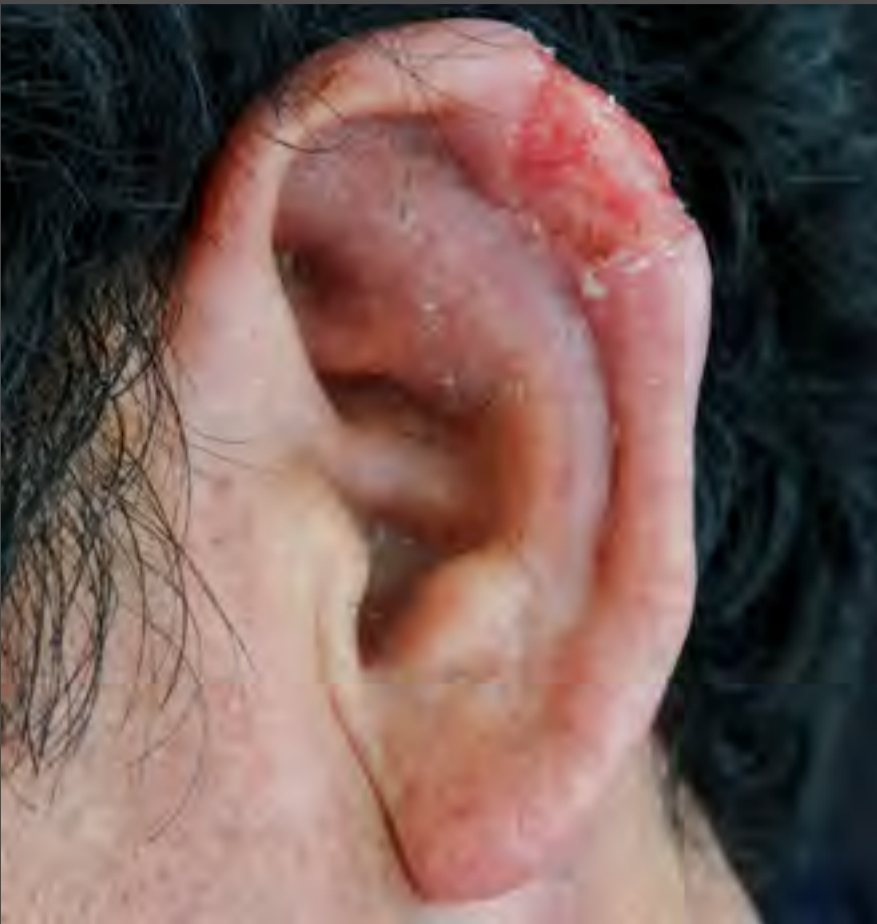**Figure 3.155.**  
Ulcerated lesion 3 x 2 cm on the antihelix and another smaller one on the helix of the right ear



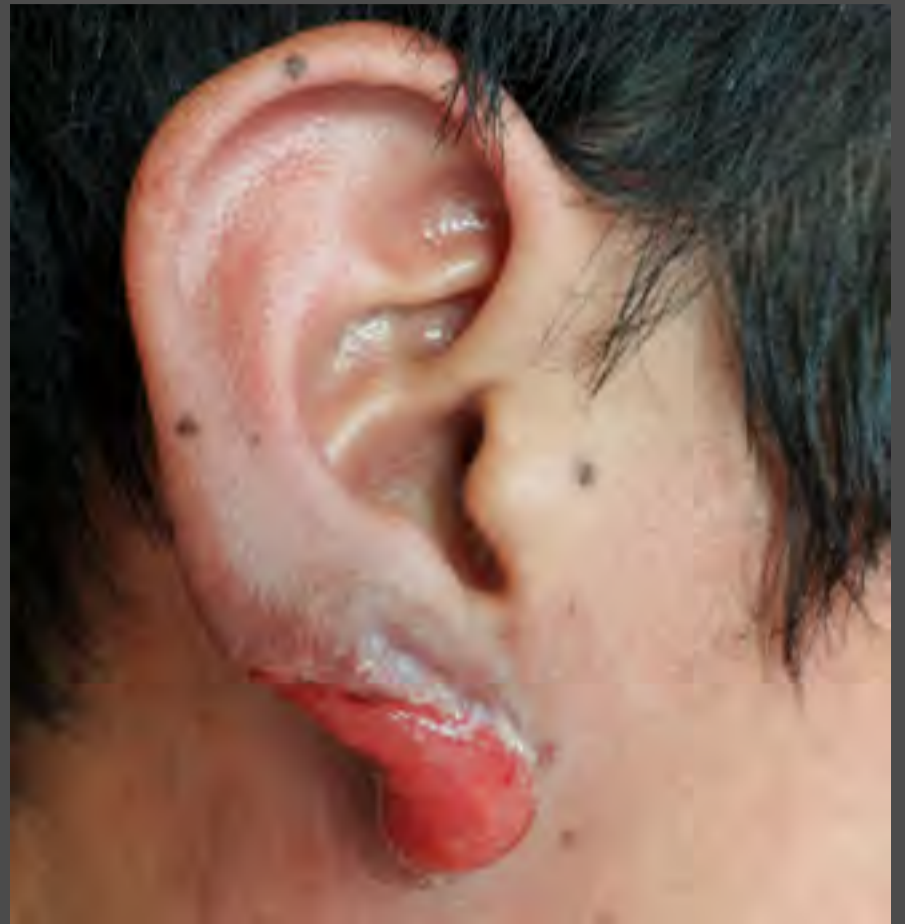**Figure 3.156.**  
Extensive involvement of the entire right ear



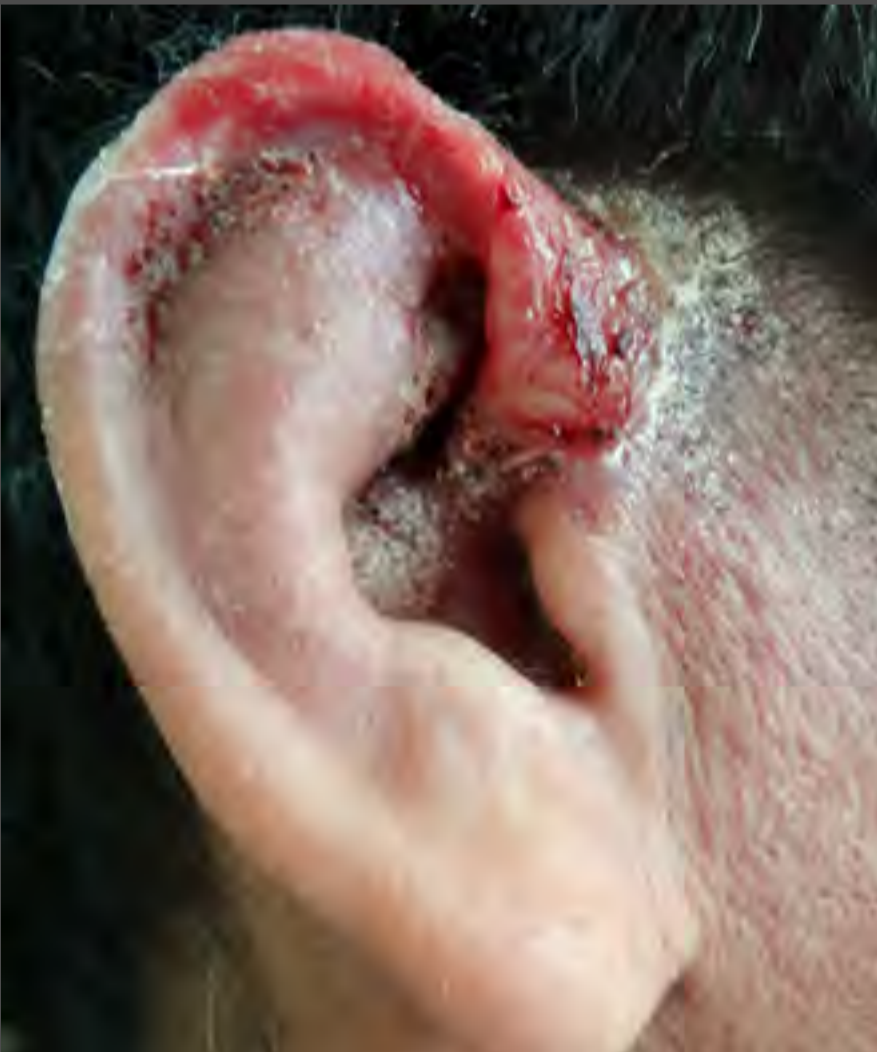**Figure 3.157.**  
Dry squamous lesion on helix of left ear (*Leishmania (L.) mexicana*)



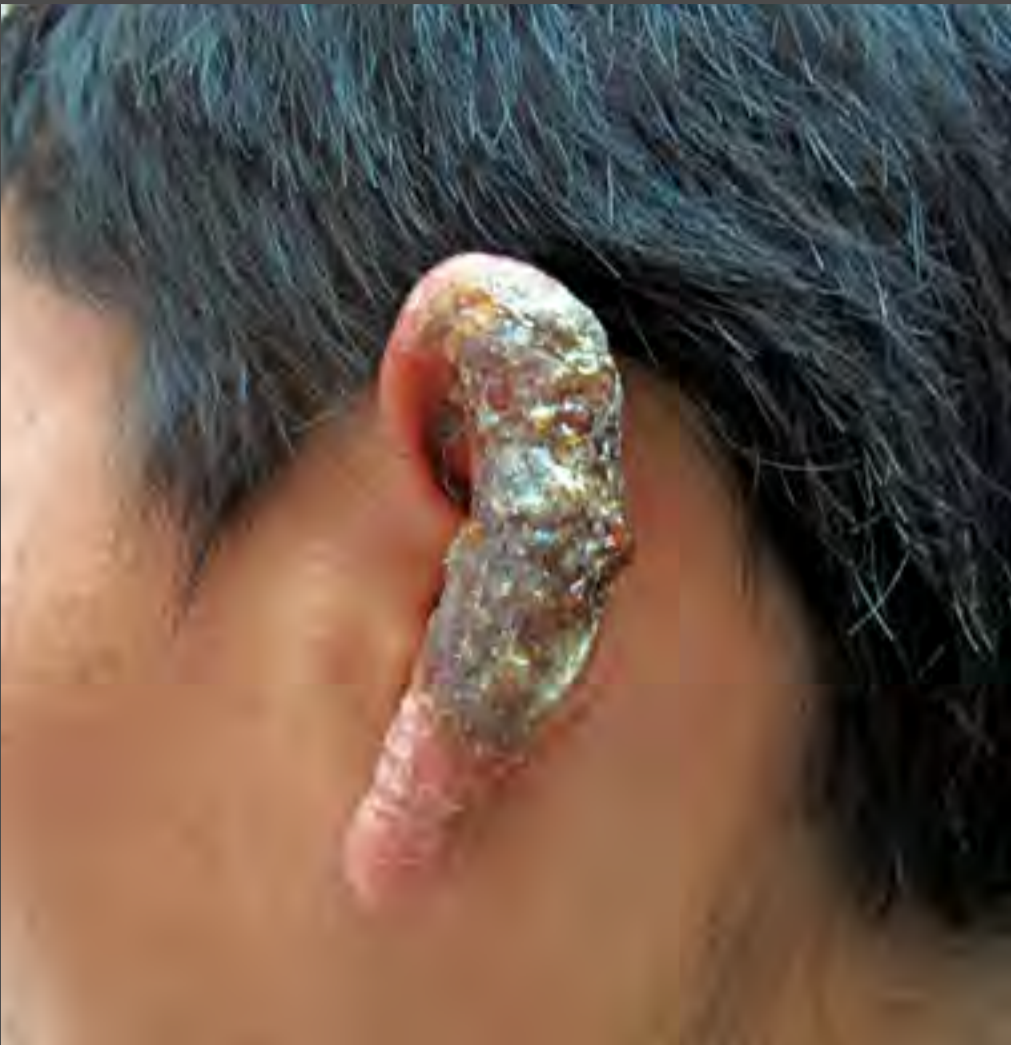**Figure 3.158.**  
Flattened superficial ulcer with well-defined edges and granular center, on the upper helix. This is the most frequent clinical presentation on the ear.



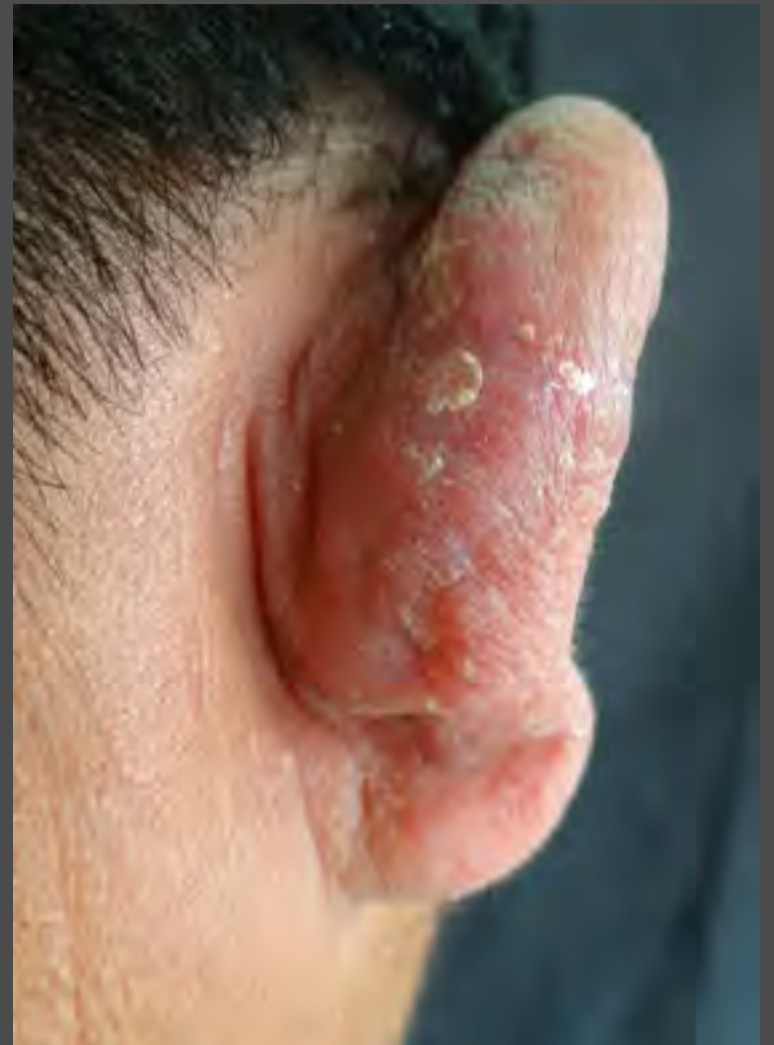**Figure 3.159.**  
Ulcer with distinct well-defined edges and a clean granular center, surrounded by reddish-purple infiltration



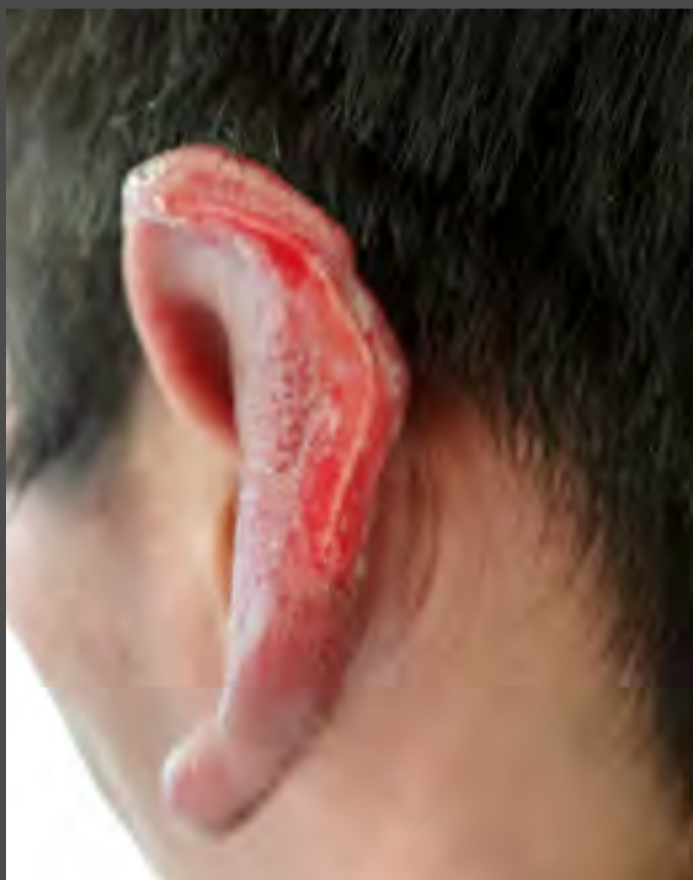**Figure 3.160.**  
A large superficial ulcer on the helix, covered with bloody crusts and surrounded by vegetative crusty plaque extending to the fossa of the antihelix and the auricular concha.



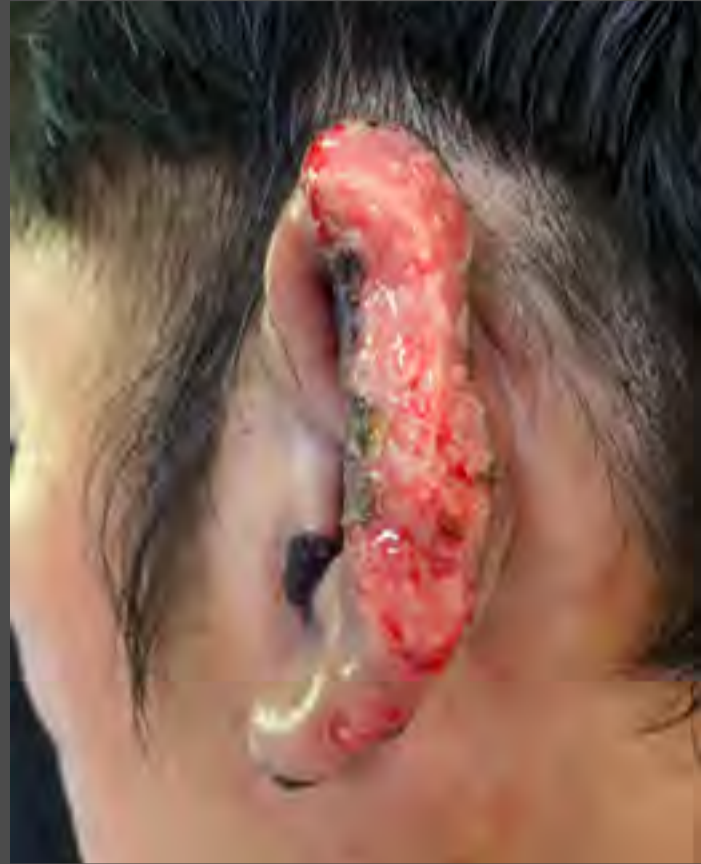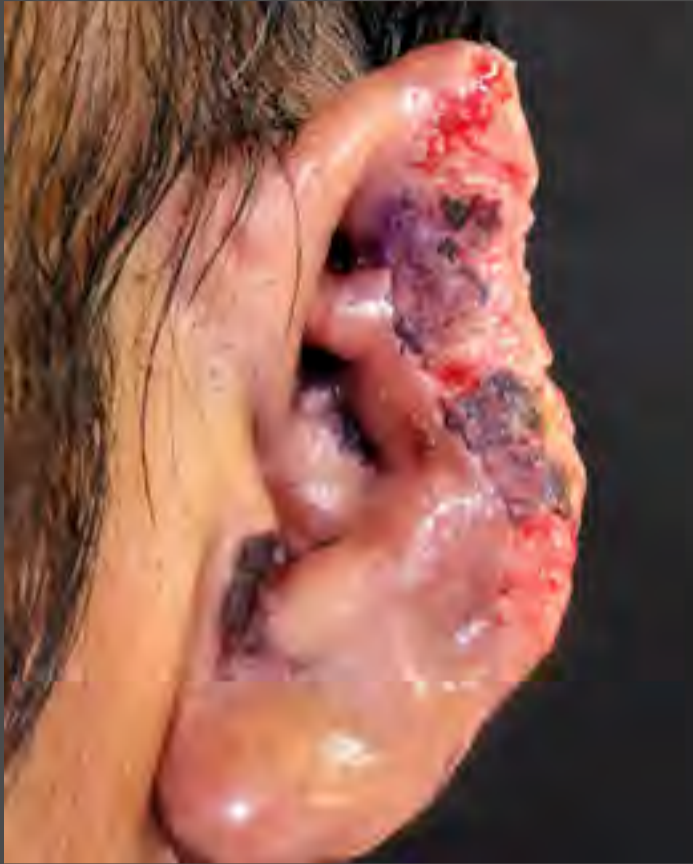**Figure 3.161.**  
Ulcerative lesion with extreme inflammation and accumulation of serosanguineous crusts on left ear



**Figure 3.162.**  
Erythematous, squamous, infiltrated, extensive plaque, with some serous crusts, that involves the helix, the posterior aspect of the ear, and retroauricular skin.

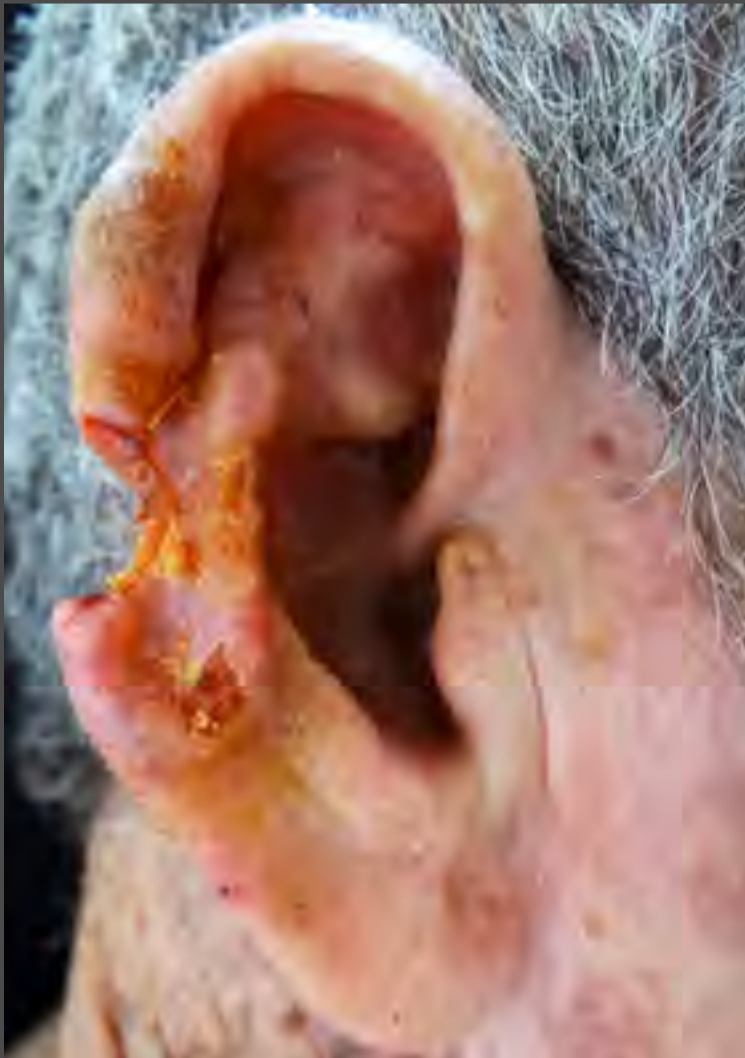

**Figure 3.163.**  
Irregular, infiltrated, ulcerated, crusty plaque on the antihelix. The extent of superficial and deep involvement may expose the cartilage. This can become infected easily and responds poorly to antibiotics.



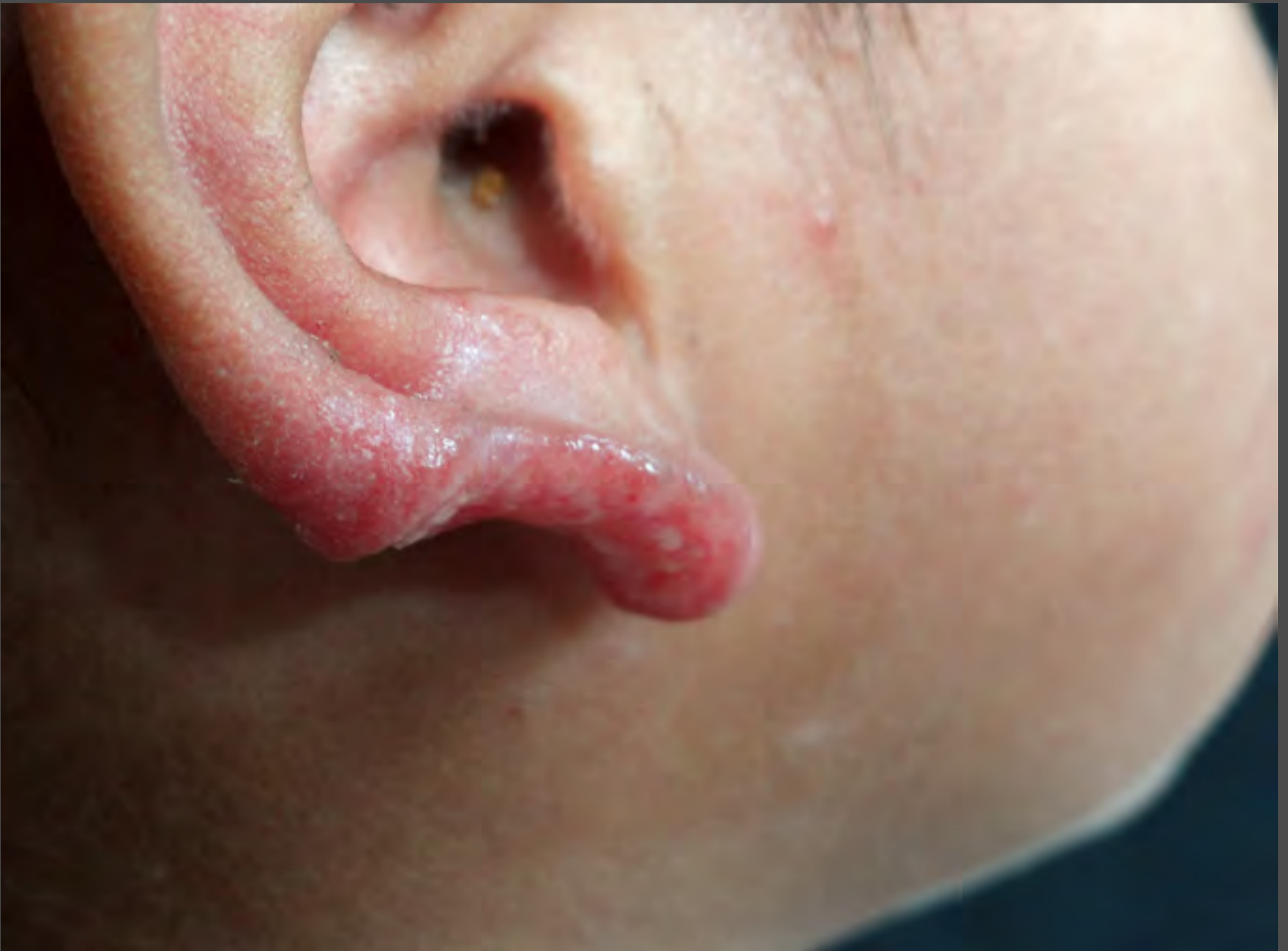**Figures 3.164A and B.**

The extent of superficial and deep involvement may expose the cartilage, which facilitates superinfection and impedes the therapeutic response to antibiotics; more advanced destruction of the cartilage, with presence of crusts and considerable edema of the entire outer ear.



**Figure 3.165.**

A very serious inflammatory process may destroy the cartilage and produce punched-out ulcers.



**Figure 3.166.**

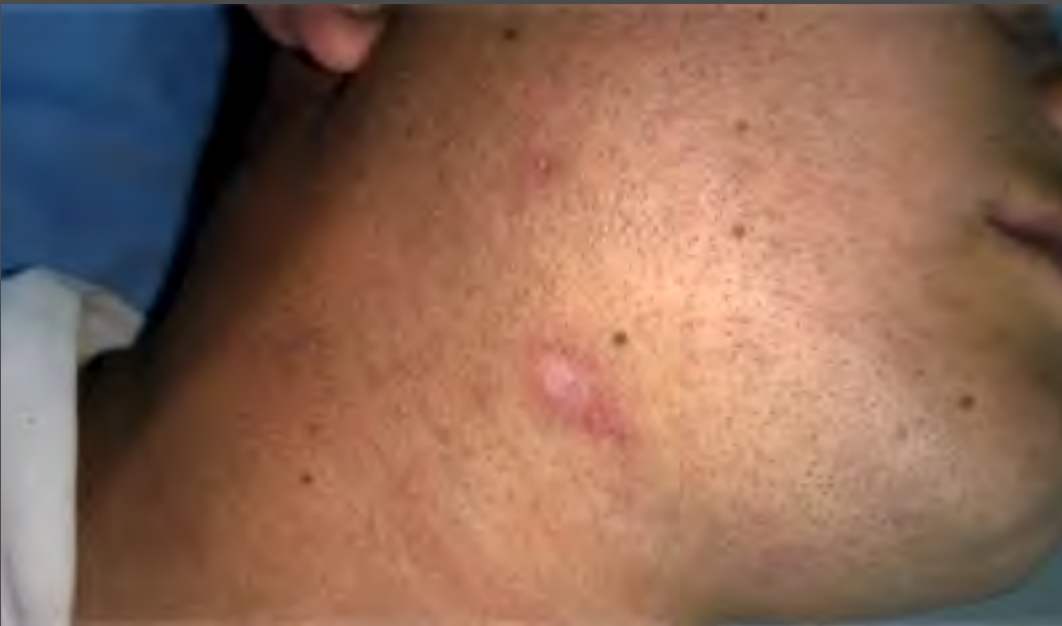Child aged 4 years, bitten two months earlier on the ear. This ulcer has destroyed part of the lobe.



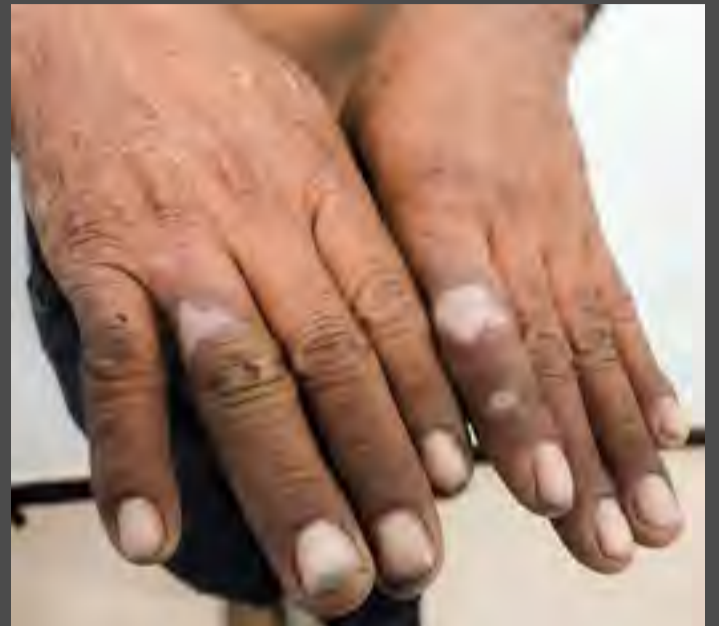Localized leishmaniasis ulcers heal slowly and leave scars (*Figures 3.167 to 3.185*), usually atrophic with a hypopigmented center and hyperpigmented edge, round, lacking hair or any other appendages and, depending on the site, may sometimes cause disfigurement or disabilities.

Some 33% of patients may suffer relapses; one of the clinical variants is known as *lupoid leishmaniasis* or *leishmaniasis recidiva cutis*, so called because new crusty or warty papular lesions appear that resemble lupus vulgaris, usually on the edge of the already-healed lesion. Some of these new lesions may progress to ulceration and others involute spontaneously. This form is the result of the reactivation of a latent infection and may appear from 1 to 15 years after the initial lesion.

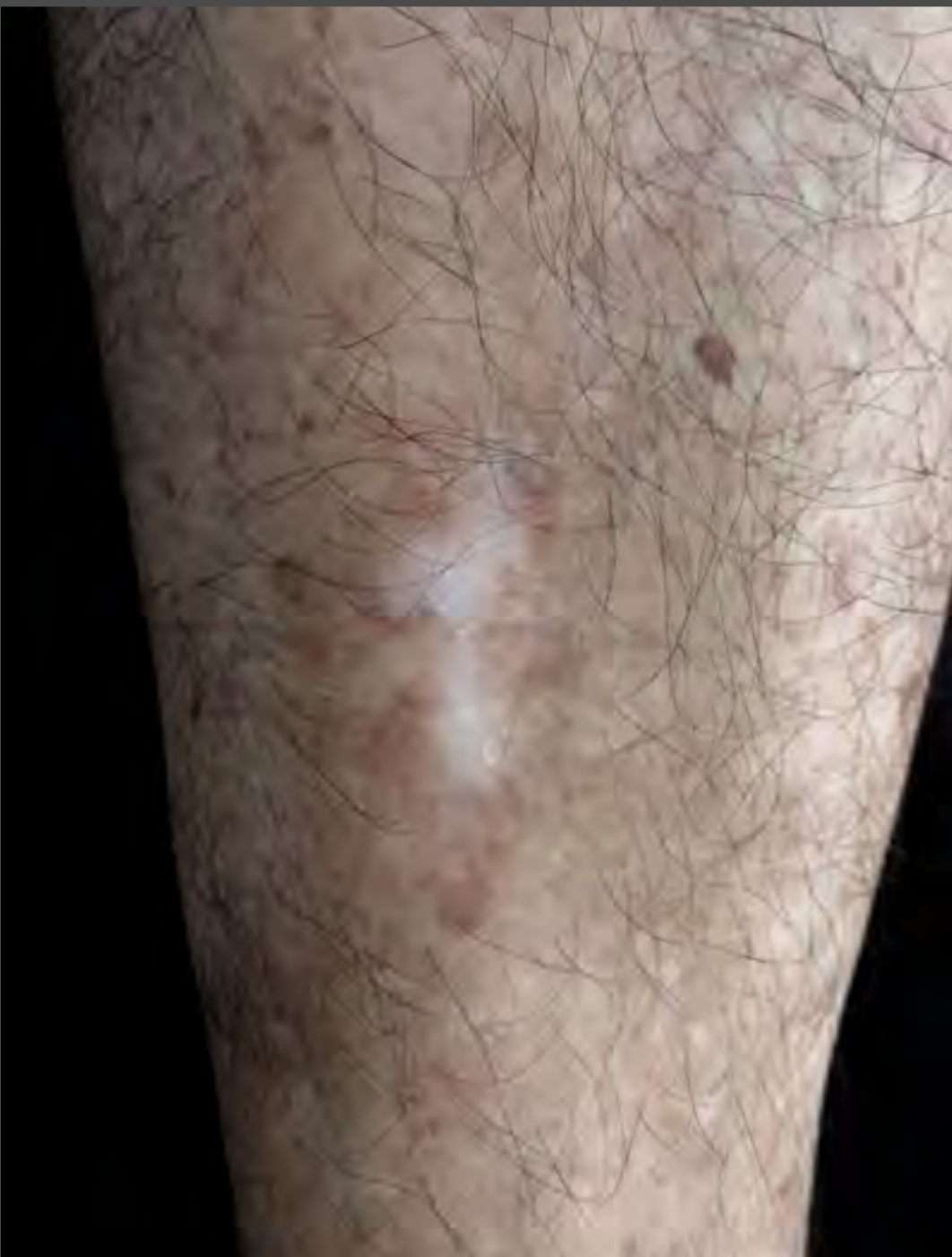
The ulcer is the most frequent clinical presentation, although in up to 20% of cases, lesions may be warty, impetigo-like, annular, keloid-like, nodular, acneiform, erysipeloid, psoriasiform, sporotrichoid, or zosteriform, among others.



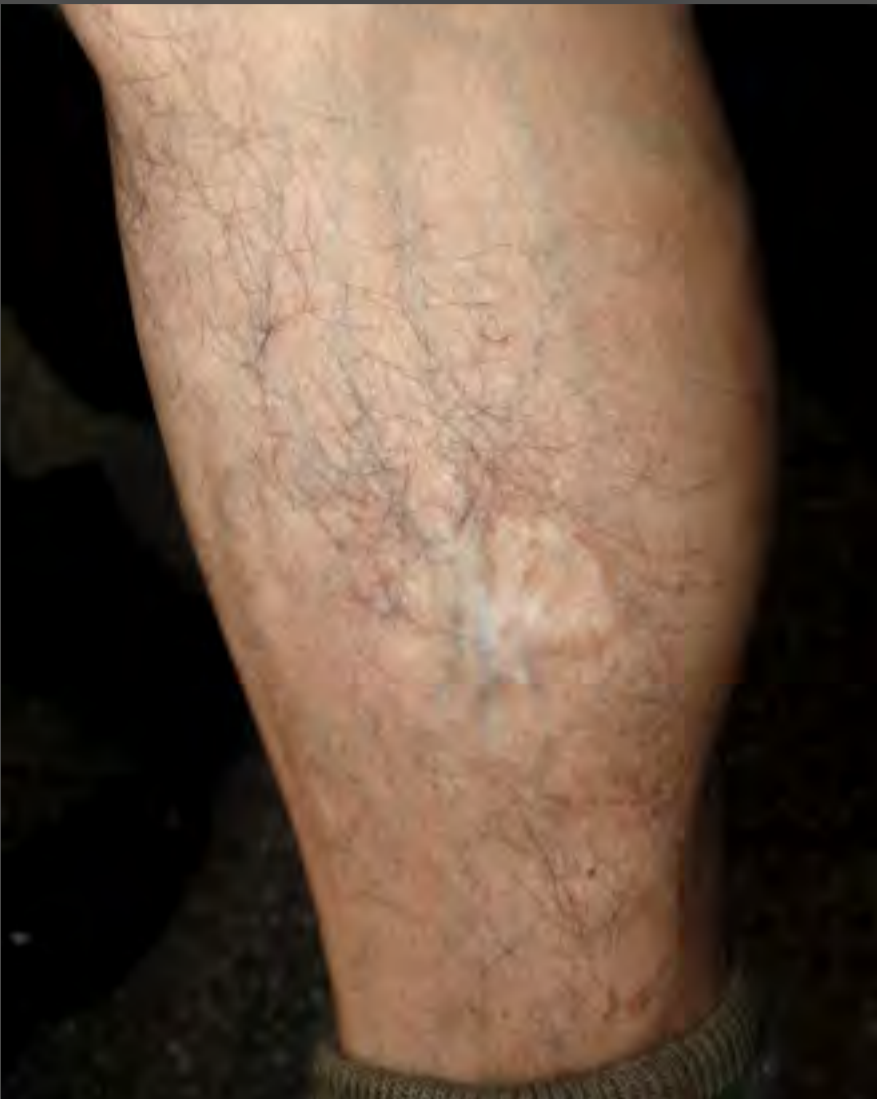**Figure 3.167.**  
Erythematous plaque with infiltrated edges and healing center  
(*Leishmania (V.) braziliensis* complex)



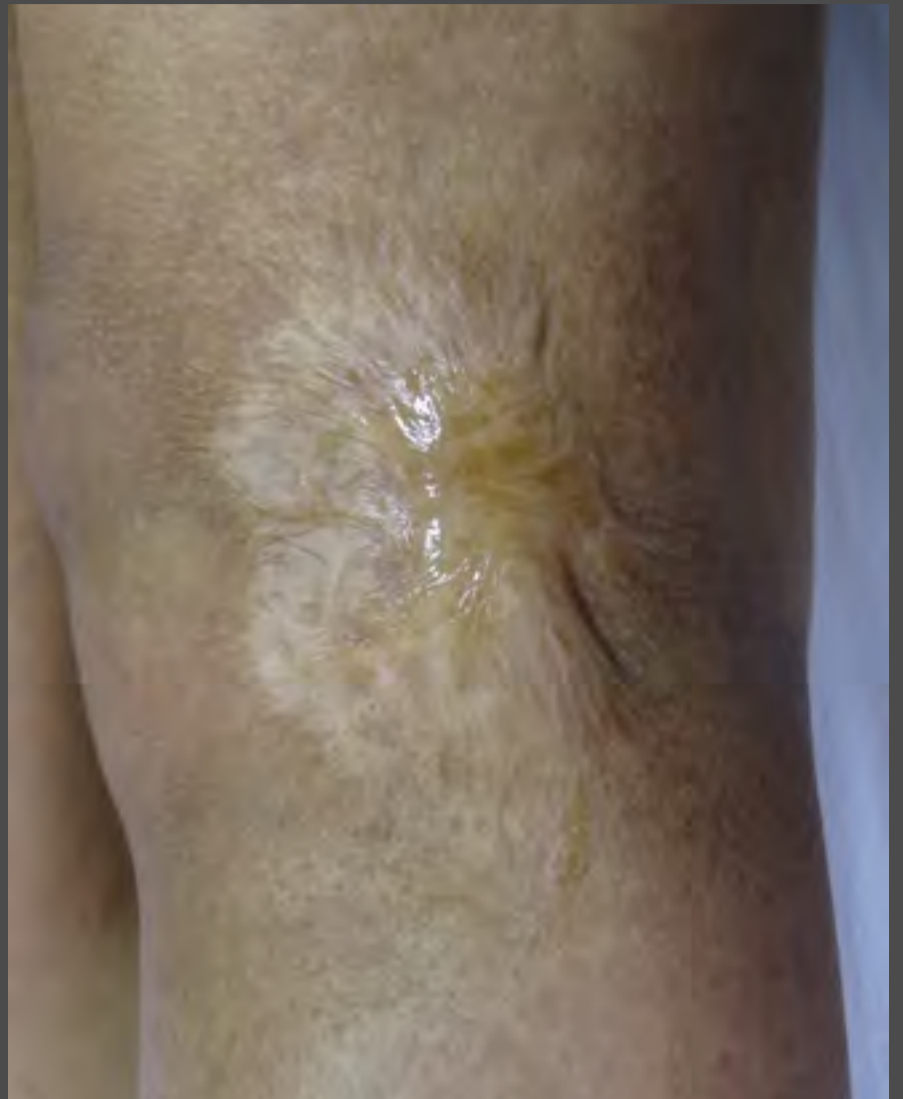**Figure 3.168.**  
Healing lesions on fingers  
following treatment



**Figure 3.169.**  
Oval-shaped scar with atrophic, hairless skin, central hypochromia, and discrete hyperpigmentation on the edges



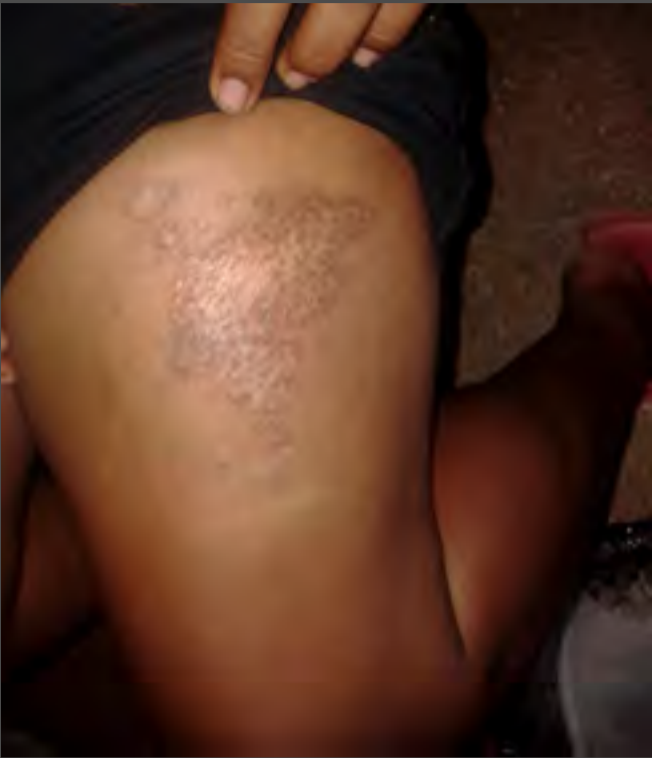**Figure 3.170.**  
Atrophic, hypochromic, rounded, hairless plaque, with “cigarette paper” appearance making the superficial vascular network visible.



**Figure 3.171.**  
Irregular, hypochromic scar with an atrophic area and a hypertrophic area and lacking appendages, located on the outer aspect of arm

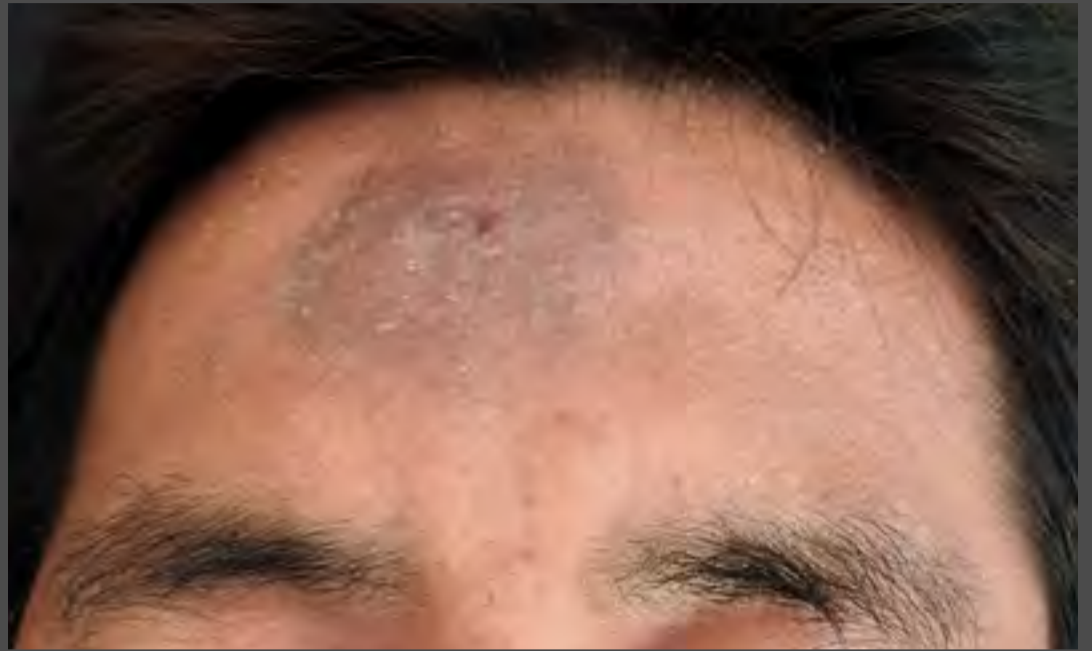

**Figure 3.172.**  
Healing plaque after ulcer healed with treatment



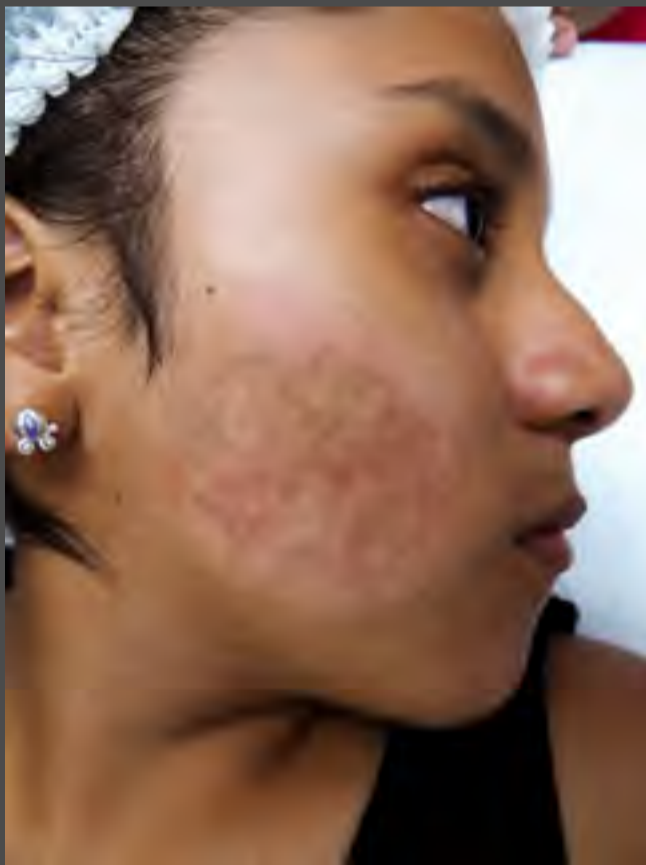**Figure 3.173.**

Pregnant patient who presented a warty form of the lesion that spontaneously healed after 120 days.



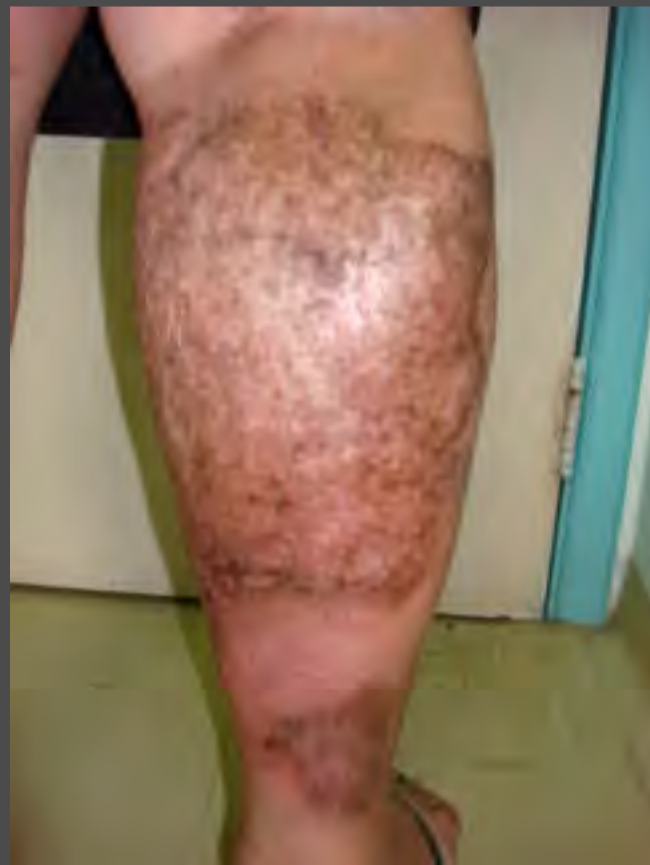**Figure 3.174.**

A month after finishing treatment, ulcers should be almost totally healed, with some erythema, hyperpigmentation and residual postinflammatory desquamation. In this case, a small area of superficial ulceration can still be seen, covering barely 5% of the lesion's pretreatment area.



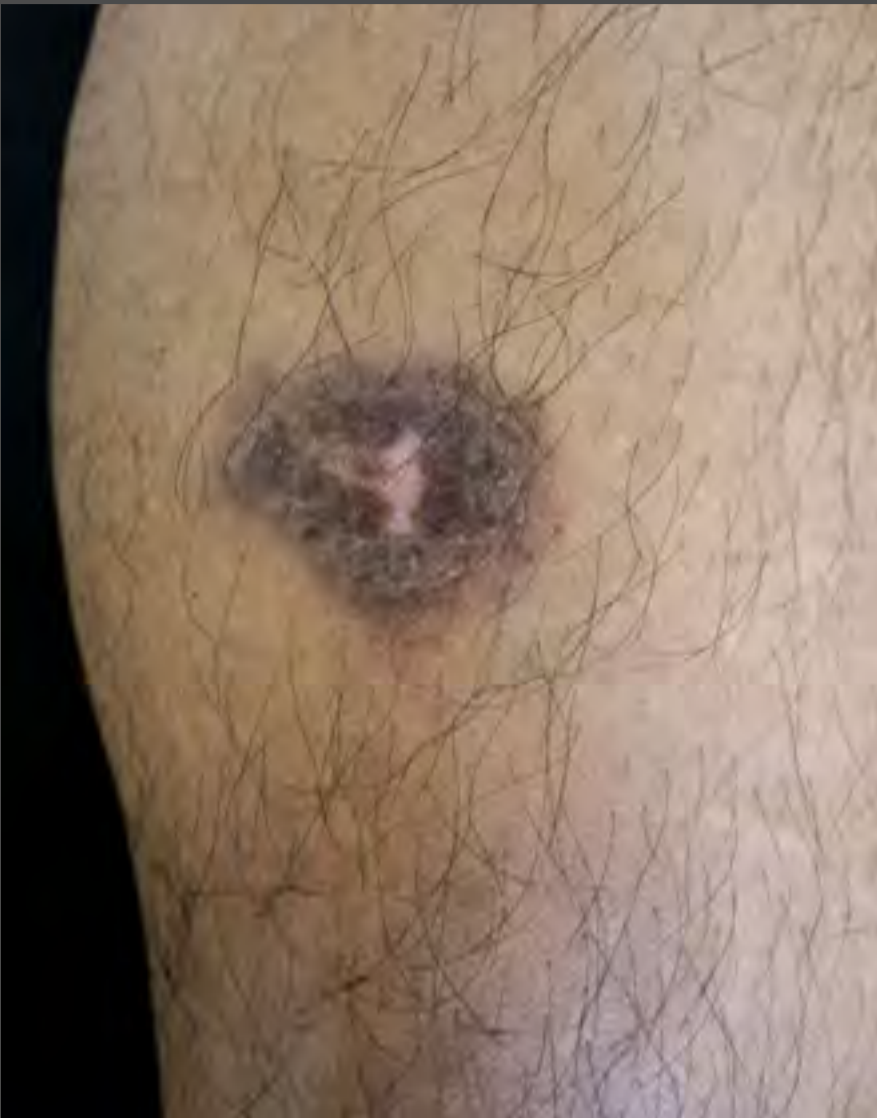**Figure 3.175.**

Rounded scar with atrophic skin showing the superficial vascular network, with hyperpigmented and hypopigmented areas.

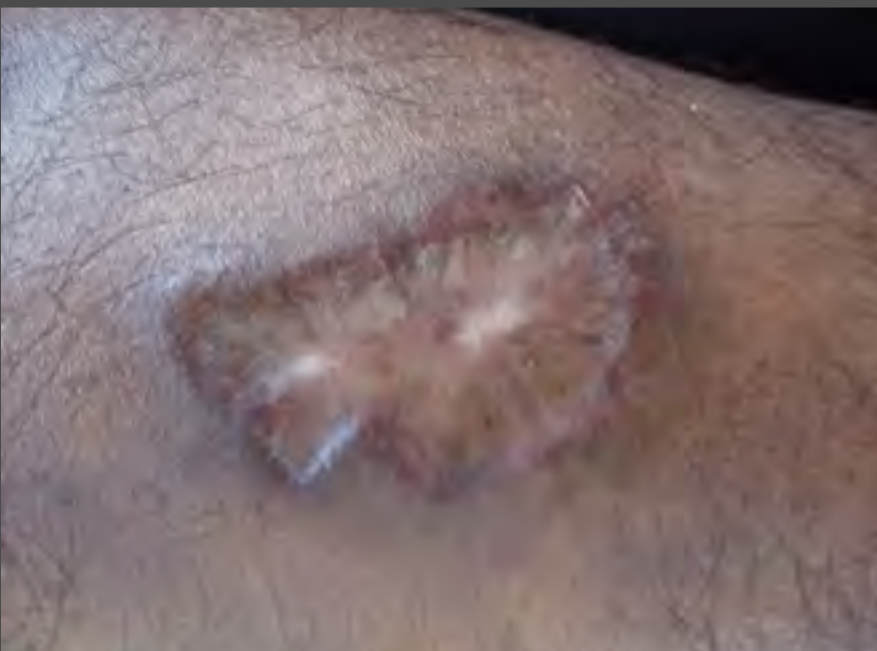

**Figure 3.176.**

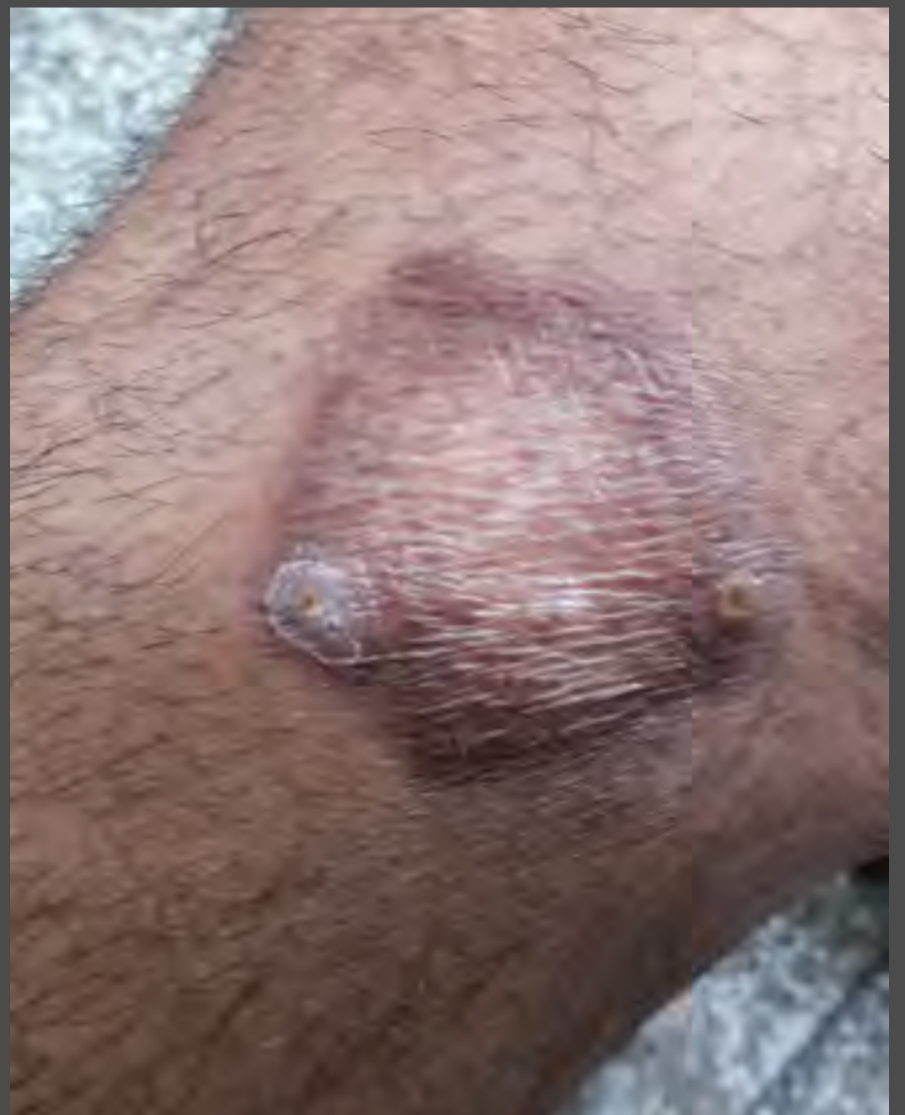Healing lesion on right leg (*Leishmania (V.) braziliensis*)



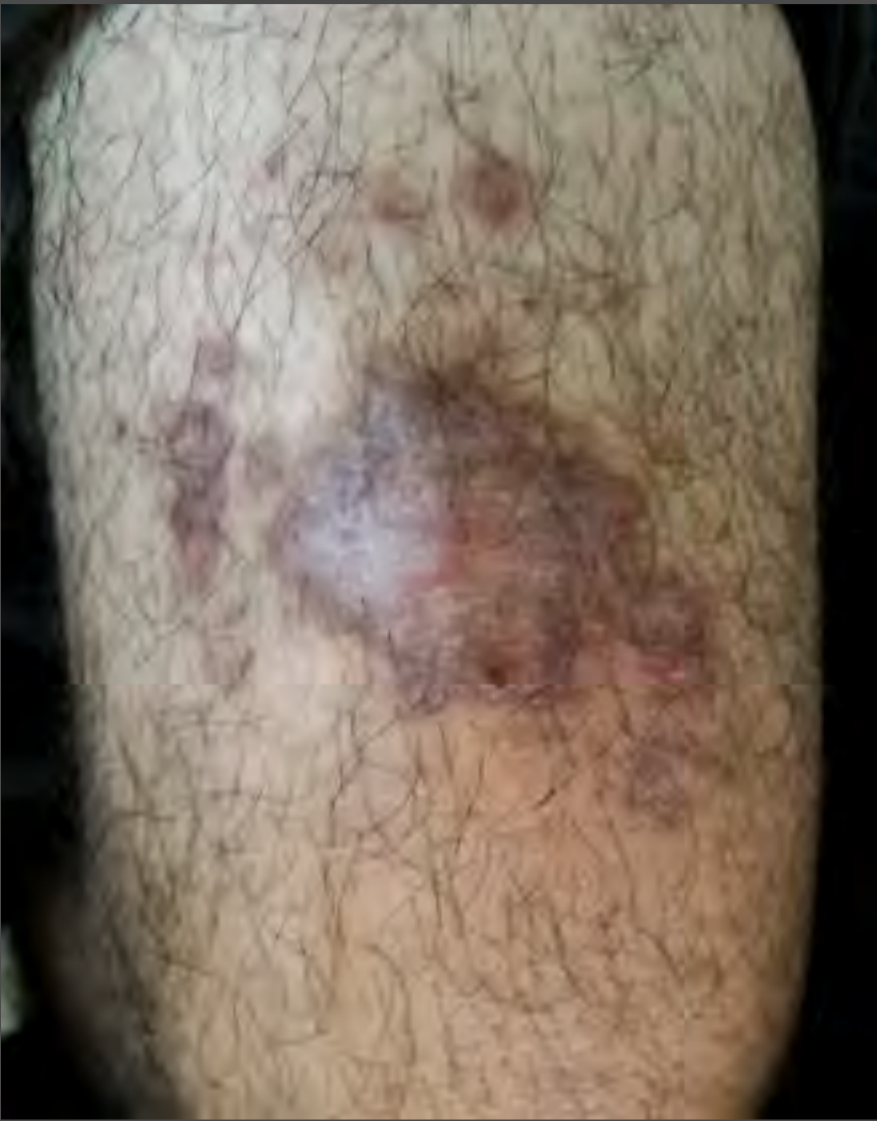**Figure 3.177.**  
Healing lesion on calf; round, atrophic, deeply hyperpigmented, and lacking appendages



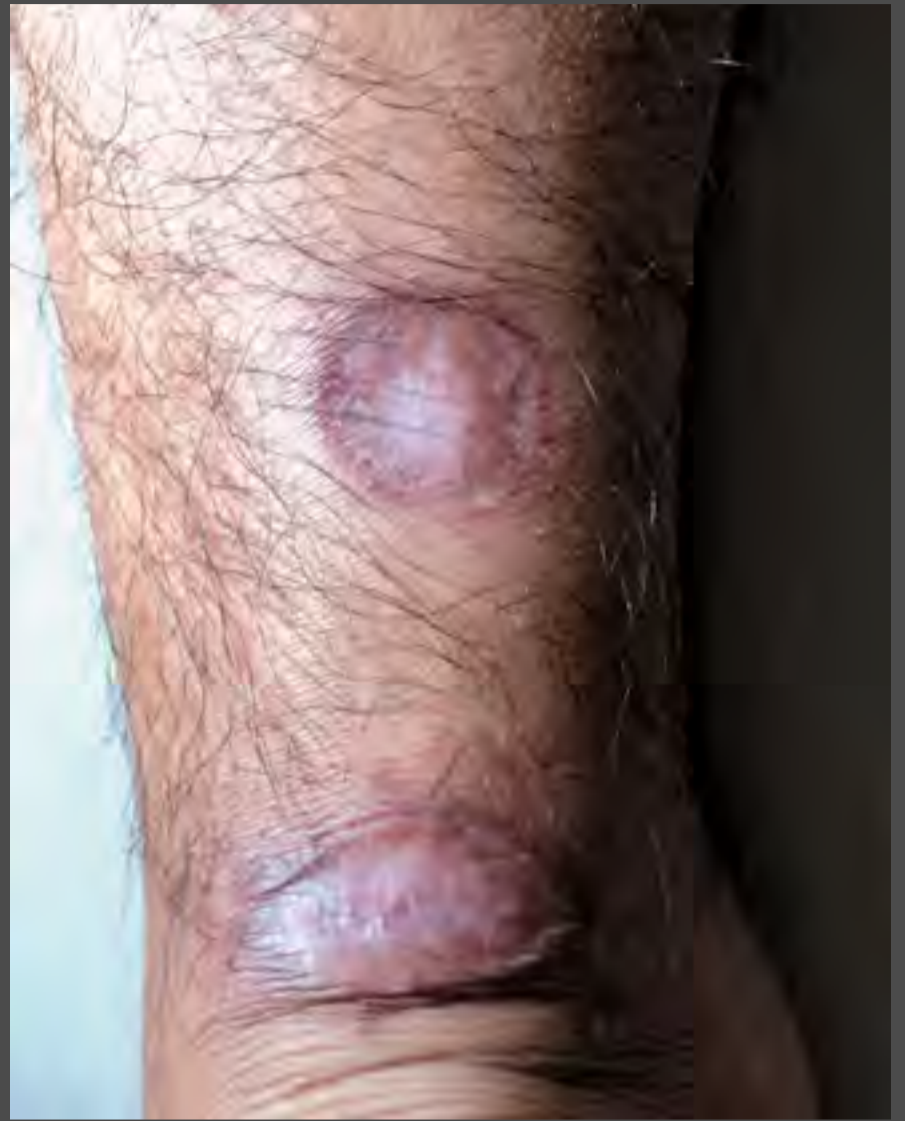**Figure 3.178.**  
Irregular atrophic scar, with hypochromic center, hyperchromic edges, and evident hairlessness and thinning skin



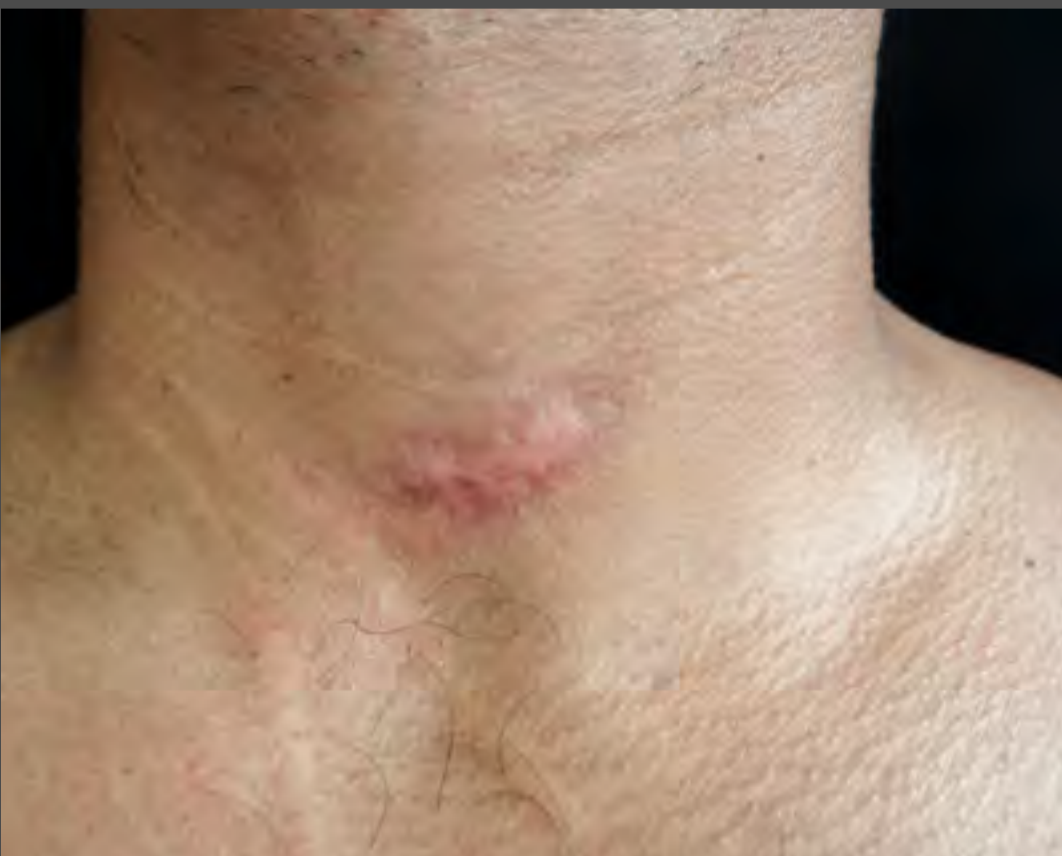**Figure 3.179.**  
*Leishmaniasis recidiva cutis*



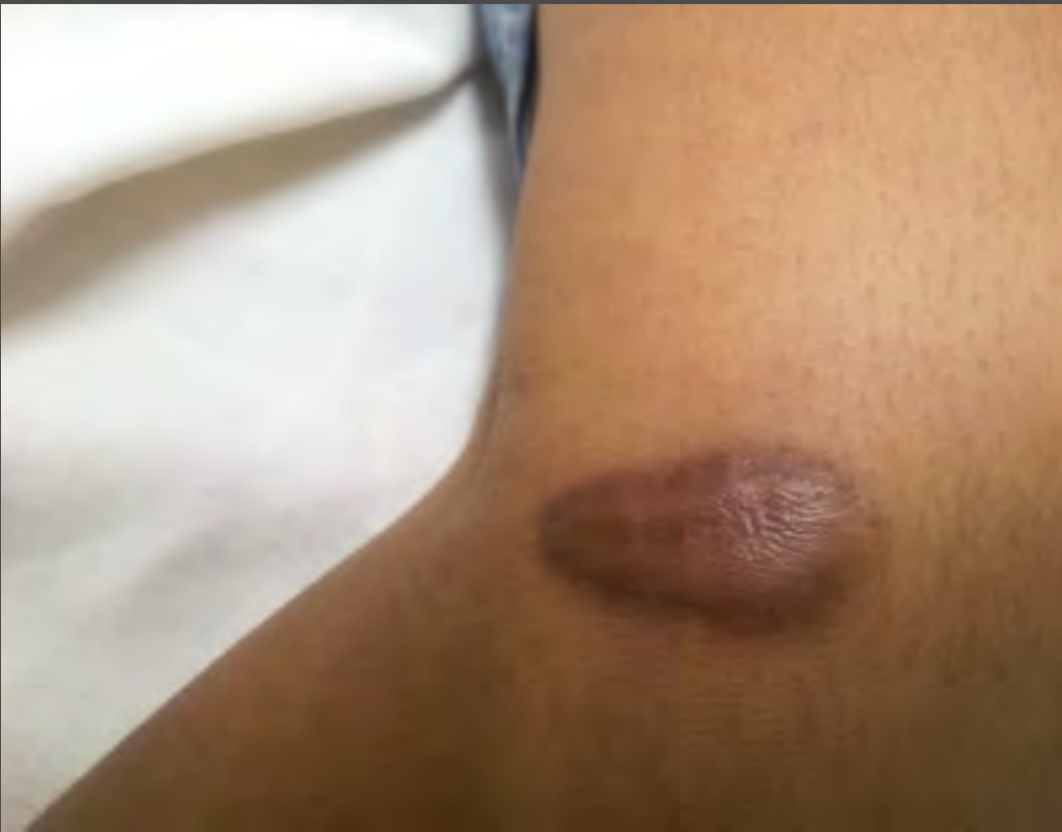**Figure 3.180.**  
Irregular atrophic scar, heavily pigmented, with multiple, similar, small satellite scars



**Figure 3.181.**  
Two rounded atrophic scars, with smooth shiny skin and no appendages, hypochromic center, and hyperpigmented periphery

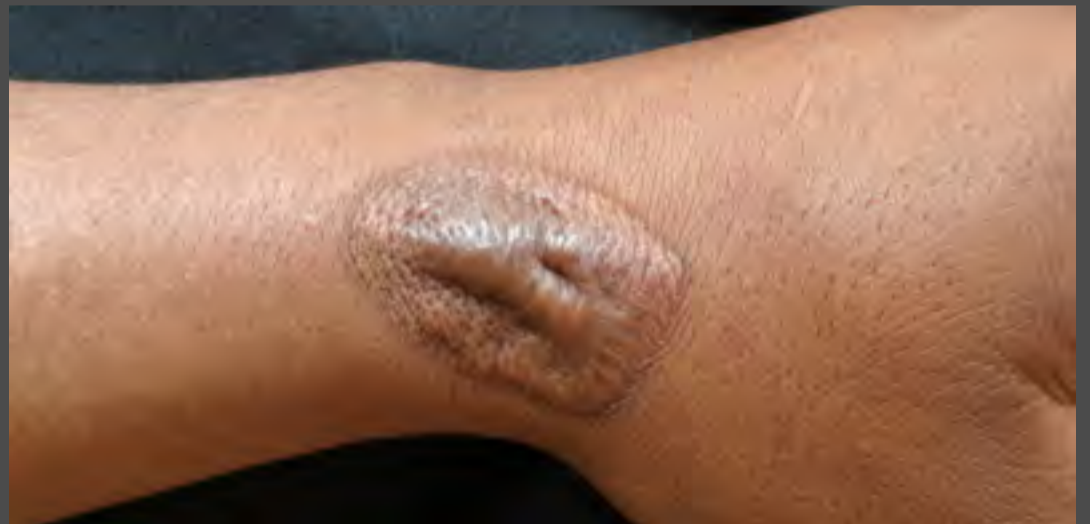

**Figure 3.182.**  
Pink scar with hypertrophic center and flush edges. Active lesions and scars on folds take an elongated shape, following the direction of the fold.

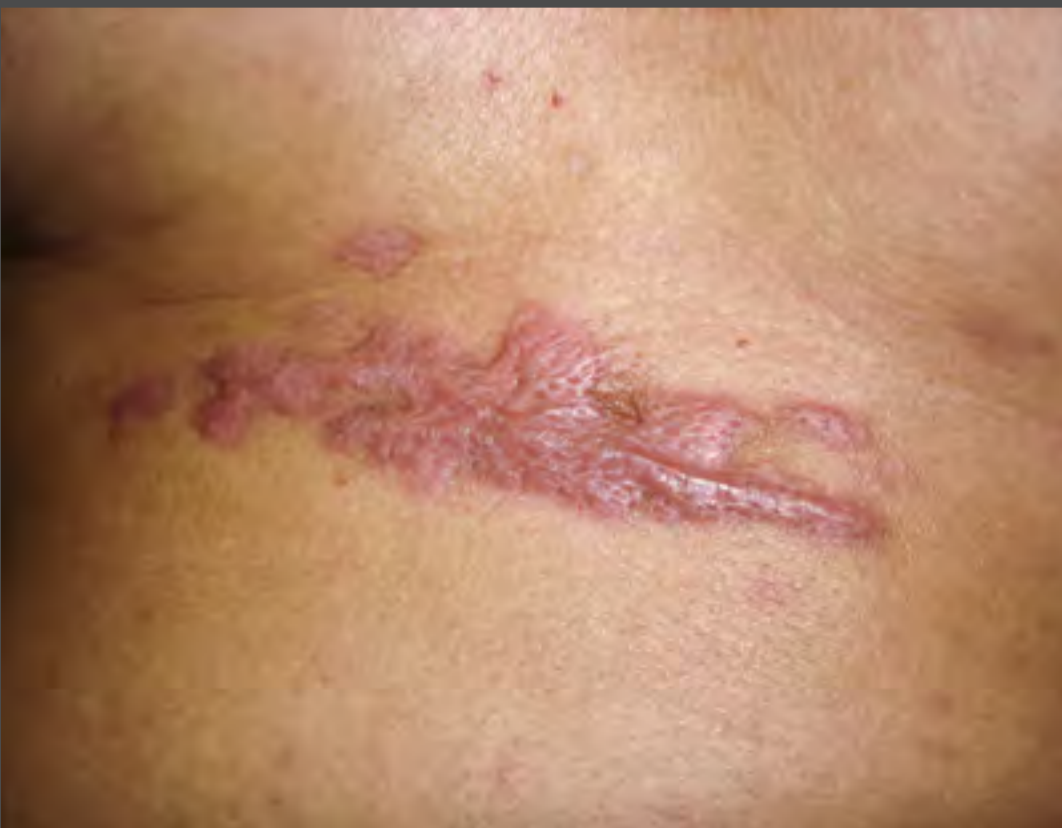

**Figure 3.183.**  
Keloid scar

**Figure 3.184.**  
Oval-shaped, hypertrophic, thick, hard, atypical scar. Its location at the bend in the wrist and the patient's race may be the cause of its characteristics.



**Figure 3.185.**  
Extensive scar



## Laboratory diagnosis

Direct smear is the basis for diagnostic confirmation of cutaneous leishmaniasis when at least one intracellular or extracellular amastigote is seen, from the product of scraping, excision, or aspiration of the ulcer's edge or floor. When the smear is negative and clinical suspicion persists, the examination should be repeated since this result does not rule out the disease, considering that direct smear sensitivity is from 40% to 90%. If the second direct smear examination is negative, other tests should be done such as histopathological study, culture, or polymerase chain reaction (PCR), which also make it possible to confirm presence of the parasite or make a differential diagnosis.

Histopathology can diagnosis leishmaniasis by demonstrating the presence of amastigotes or because it reveals an inflammatory pattern suggestive of leishmaniasis; furthermore, it may be useful in confirming other etiologies. The histological pattern shows variations that depend on the host's immune response, the location of the lesions and how long they have been there, secondary bacterial infection, and treatments received.



The Montenegro skin test is a support method that can determine if the patient has been in contact with the parasite; however, it does not establish if the infection is recent or old. One papule >5 mm indicates a positive result. A negative result indicates that there has been no exposure to the parasite or that the patient is anergic.

Detailed technical procedures for collection, processing, conservation, and shipment of samples for diagnosis of cutaneous leishmaniasis can be consulted in the *Manual of procedures for leishmaniases surveillance and control in the Americas*, Chapter 4 and Annexes 1 to 5 (available at: <https://iris.paho.org/handle/10665.2/51838>).

## Treatment and follow-up

Management of treatment options for the leishmaniasis in the Americas should take into account clinical manifestations, number and location of lesions, the *Leishmania* species causing the lesion, geographical location, the patient's overall condition, and the availability of drugs, among others.

In the Region of the Americas, the drugs commonly used as first-line treatment of the cutaneous leishmaniasis are pentavalent antimonials, which are found in two presentations: meglumine antimonate, widely used by endemic countries, and sodium stibogluconate, used only in Peru. Other drugs have been used, such as liposomal amphotericin B, pentamidine isethionate, deoxycholate amphotericin B, and miltefosine, in cases of treatment failure or contraindication to antimonials, or when they present the same or better therapeutic response and greater safety compared to antimonials. Furthermore, intralesional treatment with antimony and thermotherapy has been recommended to reduce the risk of serious adverse events in patients with single lesions of up to 3 cm in diameter at any location—except on the head and in periarticular areas—in immunocompetent patients who are able to follow up after treatment.

*Leishmaniasis in the Americas: Treatment recommendations* (available at: <https://iris.paho.org/handle/10665.2/7704>) is a guide containing detailed therapeutic recommendations using the GRADE method, with detailed descriptions of leishmaniasis drugs in Annex 1. *Tables 3.1 and 3.2* contain a summary of recommended therapeutic interventions for the Region.

**Table 3.1.**

Local treatments of cutaneous leishmaniasis by quality of the evidence and strength of the recommendation

Intervention	Administration	Regimen
Thermotherapy	Application of localized heat with electromagnetic device generating high-frequency waves	After local anesthesia, electrode is applied at 50 °C for 30-second periods, until the entire area of the lesion is covered, for 1-3 sessions, at 1-week intervals.
Intralesional antimonials	Intradermal injection	1-5 infiltrations of 1-5 ml per session, depending on lesion size (i.e., the quantity used is whatever is necessary to cover the lesion) every 3-7 days.

Adapted with authorization from: Pan American Health Organization. *Leishmaniasis in the Americas: Treatment recommendations*. Washington, D.C.: PAHO; 2018. Available at: <https://iris.paho.org/handle/10665.2/7704>

**Table 3.2.**

Systemic treatments for cutaneous leishmaniasis by quality of the evidence and strength of the recommendation

Intervention	Administration	Regimen
Pentavalent antimonials (Sb <sup>+5</sup> )	Intravenous or intramuscular	10-20 mg Sb <sup>+5</sup> /kg/day in single daily dose for 20 days. Indication for doses (10, 15, or 20 mg of pentavalent antimonials) should be based on local evidence. Maximum dose of 3 ampoules/day to reduce adverse effects.
Miltefosine	Oral	1.5-2.5 mg/kg/day, with maximum dose of 150 mg/day, for 28 days. It is suggested that divided doses be taken after meals to reduce adverse gastrointestinal effects.
Pentamidine isethionate	Intramuscular	3-4 mg/kg/day in 3-4 doses on alternate days
Ketoconazole	Oral	600 mg/day for 28 days
Liposomal amphotericin B	Intravenous	2-3 mg/kg/day up to 20-40 mg/kg total dose
Amphotericin deoxycholate B	Intravenous	0.7 to 1 mg/kg/day up to 25-30 doses.

Adapted with authorization from: Pan American Health Organization. Leishmaniasis in the Americas: Treatment recommendations. Washington, D.C.: PAHO; 2018. Available at: <https://iris.paho.org/handle/10665.2/7704>

During treatment, weekly follow-up of patients is indispensable for clinical evaluation and detection of side effects. When parenteral pentavalent antimonials are administered, follow-up with a weekly electrocardiogram is suggested for persons aged >50 years to monitor possible changes, specifically, prolongation of QTc interval. When any systemic treatment is used, recommended biochemical tests should be requested, based on the main adverse events caused by use of the drug or based on the patient's symptoms. At the conclusion of treatment, periodic clinical checkups should be done, at 45 and 90 days after finishing, with follow-up at least until 6 months after treatment to detect possible cutaneous recurrences and evaluate whether mucous membranes are involved. Patients should be instructed about these clinical events so that if they detect any they will consult immediately.

The criteria for cure of localized cutaneous leishmaniasis after three months of treatment are scarring with complete re-epithelialization and flattening of lesion edges, disappearance of induration at the lesion's base, disappearance of any lymphangitis or adenitis, and absence of new lesions.

## Disseminated Leishmaniasis

### Definition, agents, vectors, and reservoirs

Disseminated leishmaniasis is a serious and emerging form of cutaneous leishmaniasis, present in South America and in several countries of the world.

It is caused by different species of *Leishmania*, although the principal causative agent in the New World is *L. (V.) braziliensis*. According to epidemiological data, adult men and agricultural workers are at greater risk of developing disseminated leishmaniasis compared to patients with localized cutaneous leishmaniasis. Exposure to products on the job or to specific vectors may be related to the risk of disseminated leishmaniasis, although this has not yet been documented. Periodic studies in the endemic area of Corte de Pedra, an area of *L. (V.) braziliensis* transmission in northeast Brazil, have shown a major increase in the frequency of disseminated leishmaniasis cases in recent decades. Disseminated leishmaniasis accounted for 0.2% of all cutaneous leishmaniasis cases identified from 1978 to 1984, increasing to 1.9% from 1992 to 1998, and to 3.9% from 2004 to 2008, with more than 30 cases diagnosed annually.

Although cutaneous leishmaniasis in immunodepressed patients may be associated with multiple lesions, the majority of disseminated leishmaniasis cases are not associated with immunosuppression in endemic regions. Studies have described a reduction in type 1 cytokines in the peripheral blood of patients with disseminated leishmaniasis in comparison with patients with localized cutaneous leishmaniasis, due to the attraction of T cells activated by *Leishmania* spp. to the multiple skin lesions. The development of disseminated leishmaniasis involves a complex network involving the host immune response and the environment, with the polymorphism of *L. (V.) braziliensis* also playing an important role.

As previously described, there are several wild reservoirs and transmitting vectors of cutaneous leishmaniasis. These are the principal Plebotominae species involved: *Lu. whitmani*, *Lu. intermedia*, *Lu. wellcomei*, *Lu. complexa*, *Lu. neivai*, *Lu. edwardsi*, *Lu. migonei*, *Lu. nuneztovari anglesi*, *Lu. carrerai carrerai*, *Lu. spinicrassa*, *Lu. colombiana*, *Lu. pia*, *Lu. tosendi*, *Lu. tejadai* and *Lu. pescei*, among others.

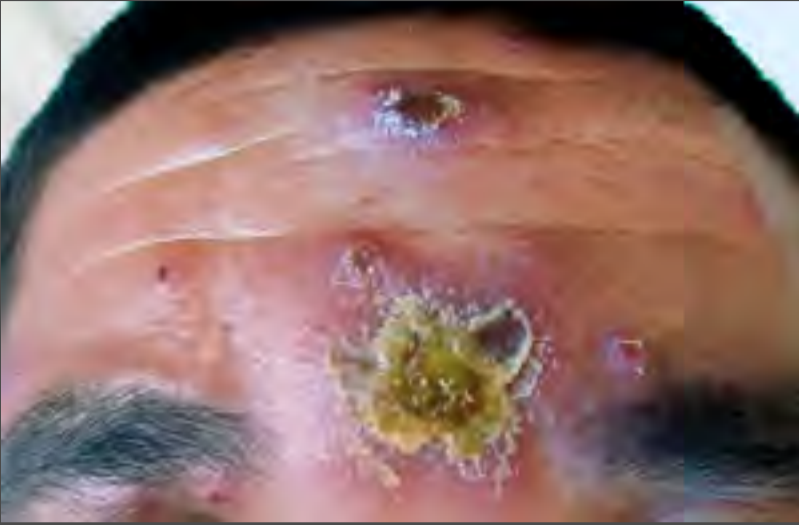## Clinical manifestations

Disseminated leishmaniasis is defined by the presence of 10 or more lesions of different types (e.g., acneiform, papular, nodular, or ulcerated), located in two or more non-contiguous parts of the body (*Figures 3.186 to 3.189*). The number of lesions can vary from ten to hundreds. A single initial ulcer—usually on a limb—is followed, after a period of a few days up to eight weeks, by disseminated lesions on the body.

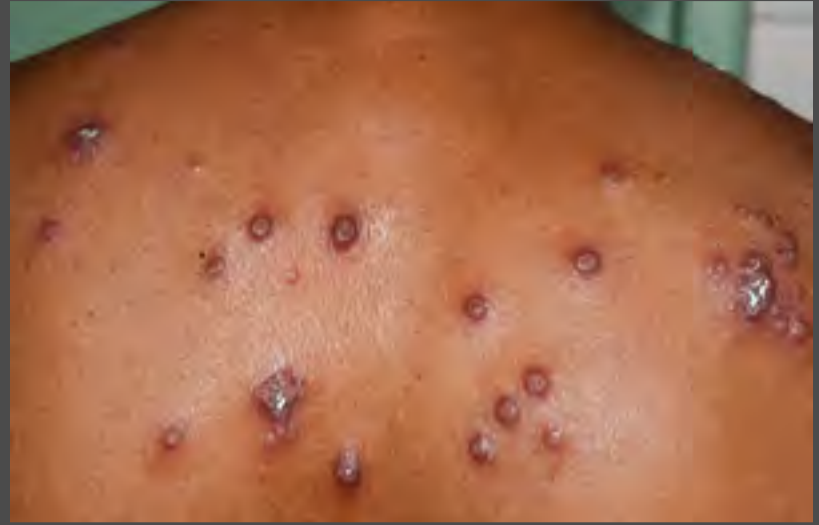Most patients with this type of leishmaniasis present widespread dissemination—legs, arms, trunk, and face—and all cases have lesions above the waist. The rapid spread of lesions with systemic symptoms—fever, chills, and malaise—in up to 75% of cases suggests hematogenic dissemination. Mucosal lesions are described in 25% to 48% of cases, and mainly affect the nasal mucosa, which may lead to perforation of the septum and to involvement of the mucous membranes of other areas, such as the lips, palate, and pharynx.



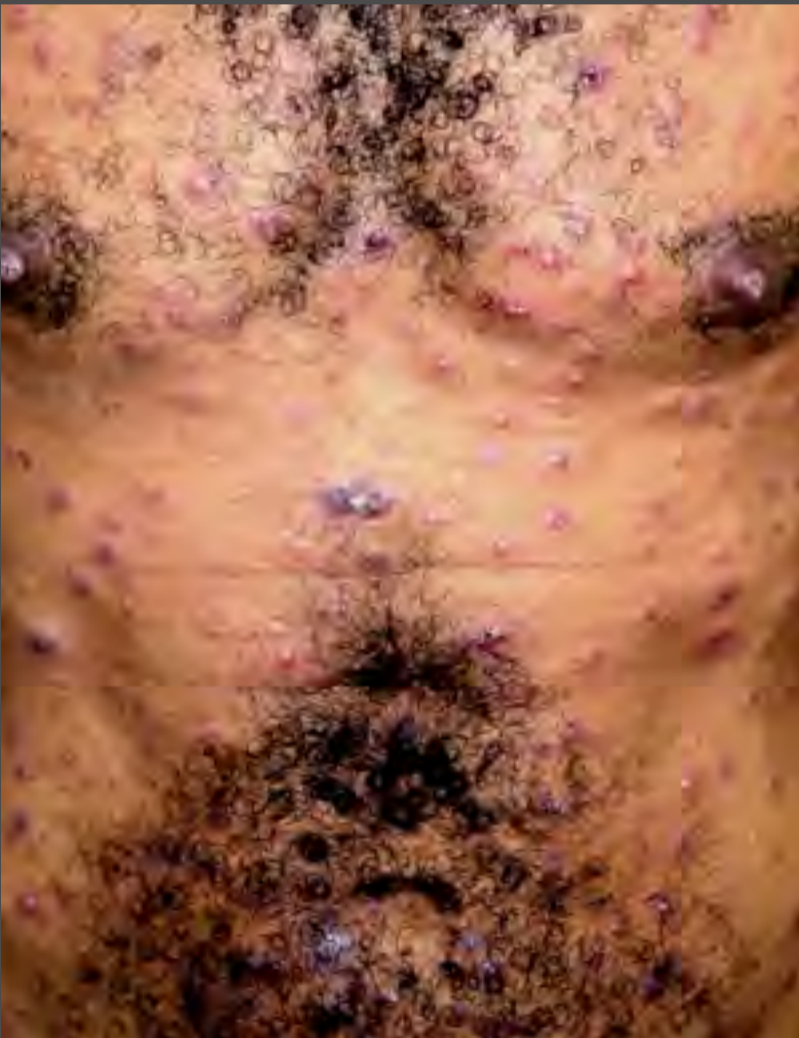## Disseminated leishmaniasis



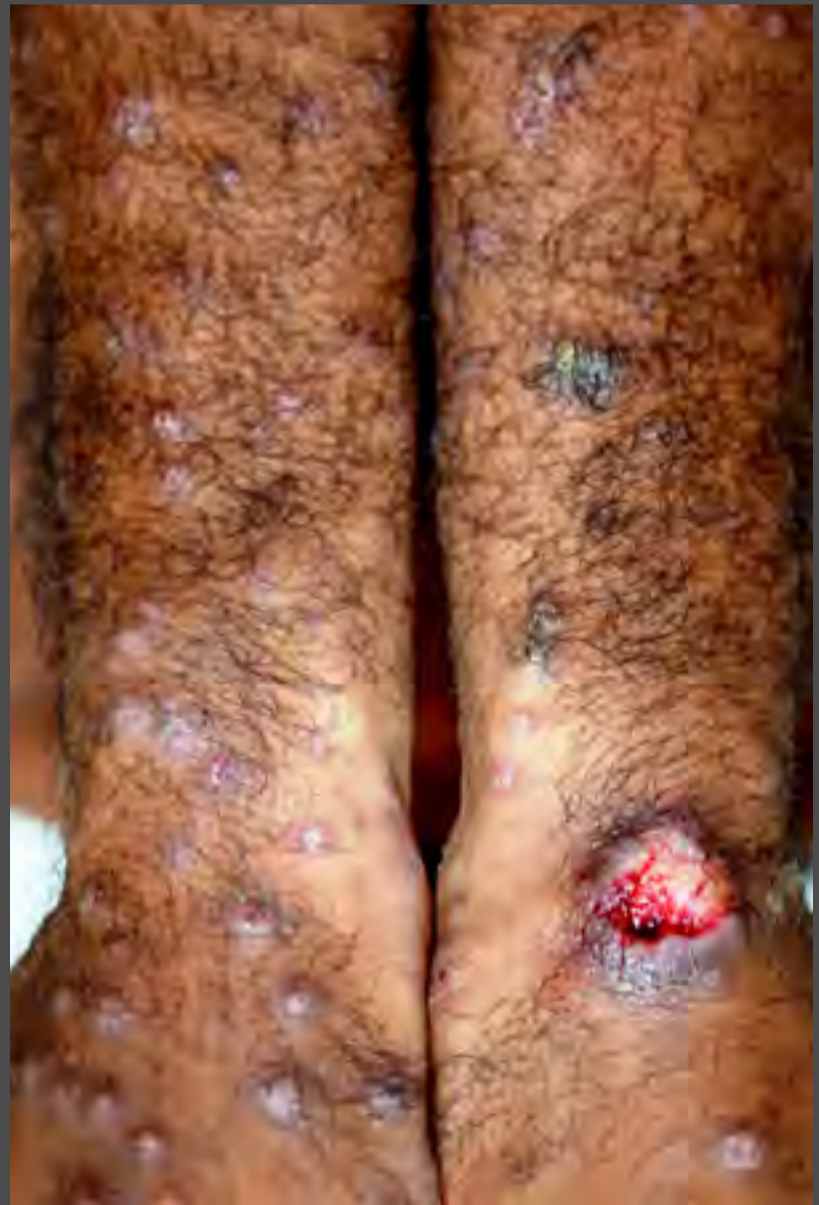**Figure 3.186A.**  
Erythematous, eroded, crusty plaque and inflammatory papules, on forehead (*Leishmania (V.) brasiliensis*)



**Figure 3.186B.**  
Inflammatory papules of several sizes, some with central erosion, on upper dorsal region (*Leishmania (V.) brasiliensis*)



**Figure 3.187A.**  
Inflammatory papules and multiple acneiform lesions on the trunk (*Leishmania (V.) brasiliensis*)



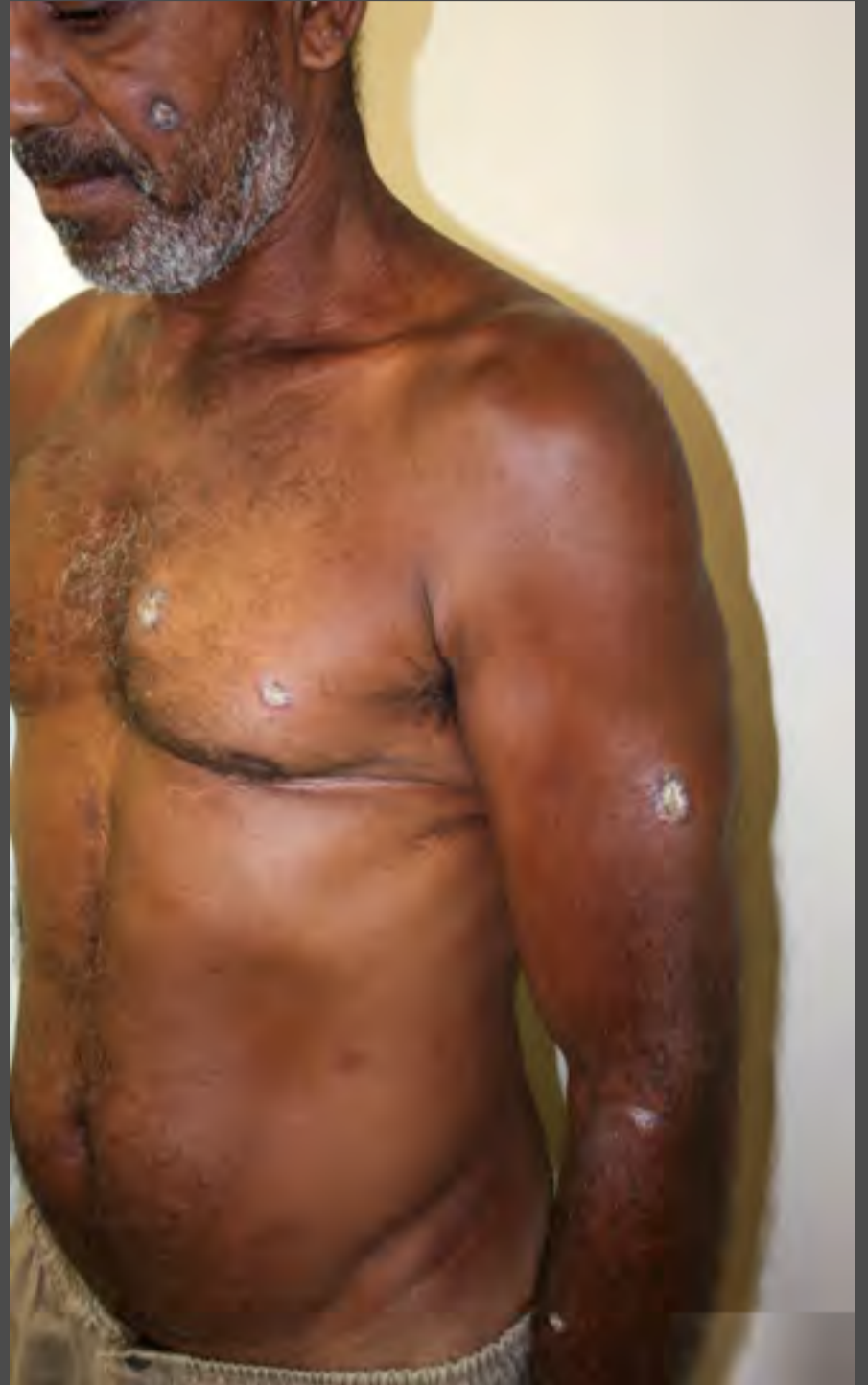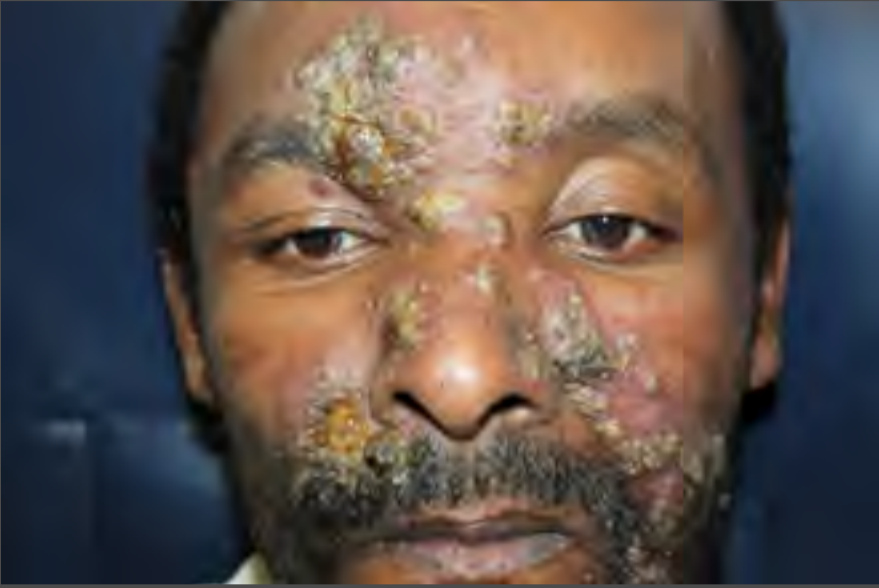**Figure 3.187B.**  
Ulcer on the hand. Initial lesion, erythematous and acneiform papules on the arms (*Leishmania (V.) brasiliensis*)

## Disseminated leishmaniasis

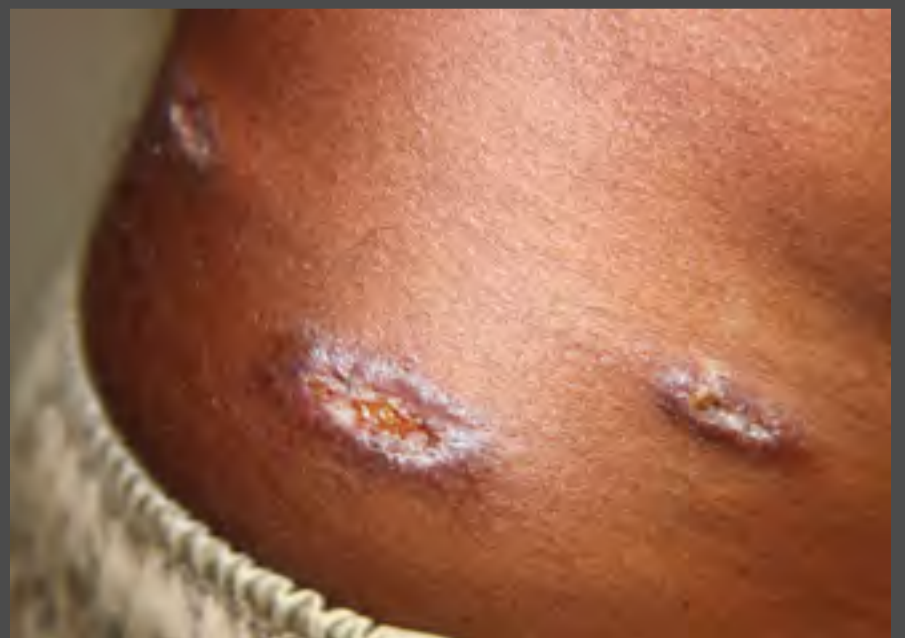
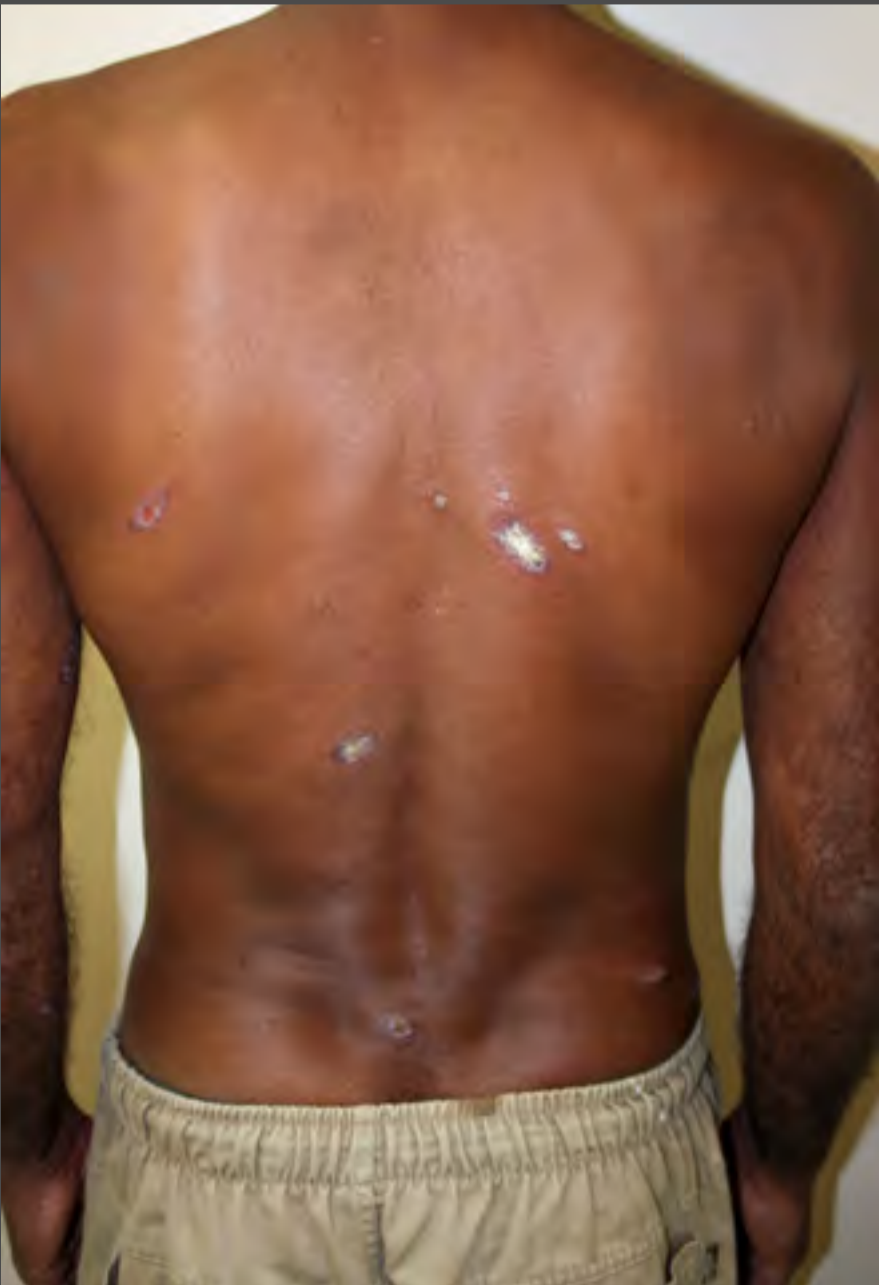
**Figure 3.188.**  
Erythematous plaques and nodular lesions on the trunk and on arms and legs, with several ulcerated lesions

## Disseminated leishmaniasis



Figures 3.189A, B, C and D.  
Crusty, nodular, ulcerated plaque lesions on the face,  
trunk, and limbs (*Leishmania (V.) brasiliensis*)



## Laboratory diagnosis

The Montenegro skin test, histopathology, and parasite identification are important to confirm disseminated leishmaniasis. Immunosuppressed patients with diffuse cutaneous leishmaniasis have negative intradermal skin tests. In disseminated leishmaniasis, the Montenegro test is positive in up to 83% of cases. In histopathology, a mononuclear infiltrate is observed with predominance of plasma cells, a granulomatous reaction, and few amastigotes (*Table 3.3*). Disseminated and diffuse cutaneous leishmaniasis are very easily confused by some clinicians, however, there are several significant differences in their clinical and laboratory manifestations that help to make a better diagnosis and administer more appropriate treatment.

**Table 3.3.**

Clinical picture, histology, parasitological diagnosis, and response to delayed hypersensitivity in disseminated leishmaniasis and in diffuse cutaneous leishmaniasis in the Americas

Characteristics	Disseminated leishmaniasis	Diffuse cutaneous leishmaniasis
Skin lesions	Acneiform and inflammatory papules, and nodules	Infiltrated nodules and plaques that resemble lepromatous leprosy.
Ulcers	Present	Absent
Mucosal involvement	Up to 48% of cases	Absent
Parasite in tissue	Absent or few	Abundant
<i>Leishmania</i> species*	Mainly, <i>Leishmania</i> ( <i>V.</i> ) <i>braziliensis</i>	<i>Leishmania</i> ( <i>L.</i> ) <i>amazonensis</i> and <i>Leishmania</i> ( <i>L.</i> ) <i>mexicana</i>
Montenegro skin test	Positive in 80% of cases	Negative

\* In immunocompetent host

## Treatment and follow-up

Treatment of disseminated leishmaniasis consists of 30 days of 20 mg/kg/day of pentavalent antimonials ( $\text{Sb}^{+5}$ ). Cure rates vary with *Leishmania* type, ranging from 24% in *L. (V.) braziliensis* cases to 86% in *L. (V.) panamensis* cases. Many patients receive several series of  $\text{Sb}^{+5}$  until a definitive cure is achieved, however, toxicity is the primary concern. Pentamidine was used successfully in three *L. (V.) panamensis* cases. In Corte de Pedra (Brazil), liposomal amphotericin B was used in 20 patients with disseminated leishmaniasis, with a total dose of 17 to 37 mg/kg, resulting in a final cure rate of 65%. The greatest cure rate, 75%, was associated with a total dose greater than 30 mg/kg. Use of miltefosine in patients with disseminated leishmaniasis continues to be limited due to its cost and lack of availability in several countries.

Patients with disseminated leishmaniasis should be followed until a complete cure from skin and mucous-membrane lesions is obtained, sometimes for years after the use of several drugs.

At present, disseminated leishmaniasis poses a therapeutic challenge with a high social and economic burden, which is why these patients should be referred to specialized services. Better treatment with lower toxicity is needed for this serious form of cutaneous leishmaniasis.

## Diffuse Cutaneous Leishmaniasis

### Definition, agents, vectors, and reservoirs

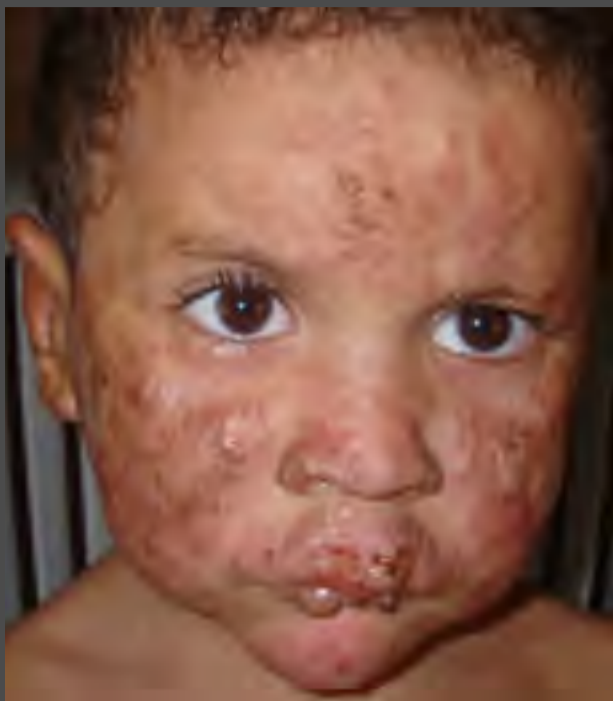Diffuse cutaneous leishmaniasis is considered a rare clinical form of cutaneous leishmaniasis, described in some New World and African countries. In the Americas, it is caused by different species of the parasite of the genus *Leishmania* and has been reported in Brazil, Colombia, Costa Rica, the Dominican Republic, Ecuador, Mexico, Peru, and Venezuela. It is produced mainly by *L. (L.) amazonensis* and *L. (L.) mexicana*; however, in some cases, *L. (L.) venezuelensis* and *L. (V.) braziliensis* were identified. Brazil is the country with the largest number of reported cases in the Region, and *L. (L.) amazonensis* is considered to be the only species that acts as an agent of diffuse cutaneous leishmaniasis. It is transmitted to humans by the bite of insects of the species *Lu. flaviscutellata*.

## Clinical manifestations

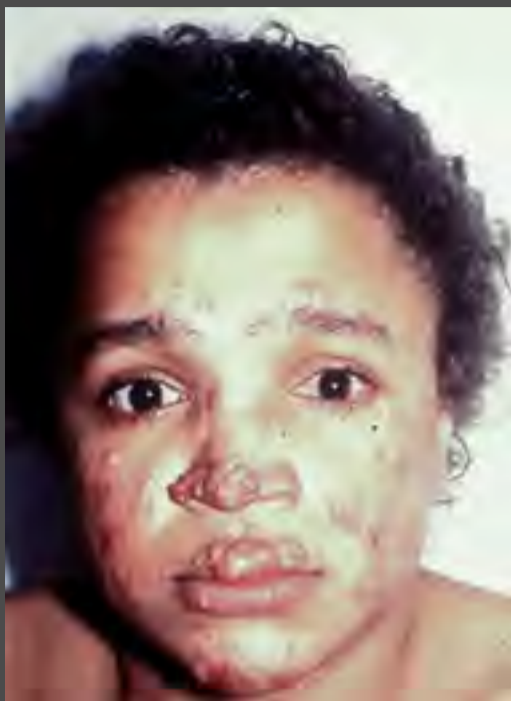Diffuse cutaneous leishmaniasis is clinically characterized by the polymorphism of lesions—papules, nodules, infiltrated plaques, tubercles, and erosions—that may involve extensive areas of the body (*Figures 3.190 to 3.203*).

The disease has a chronic course, with the capacity to produce deformities in the limbs; it appears in patients considered to be anergic, with a specific deficiency in the cellular immune response to *Leishmania* spp. antigens. Lesions start insidiously, with a single papular-nodular lesion that evolves slowly, forming plaques and multiple non-ulcerated nodules. Generally, there is no mucosal involvement.

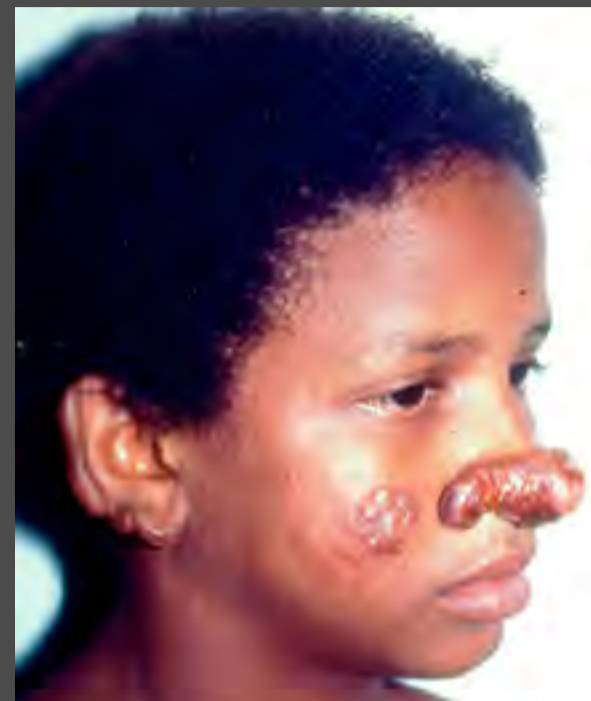## Diffuse cutaneous leishmaniasis



**Figure 3.190.**  
Nodular infiltrating plaques on the face. Note punched-out lesions associated with nodular-tumoral lesions and ulcerations on lips (*Leishmania (L.) amazonensis*)



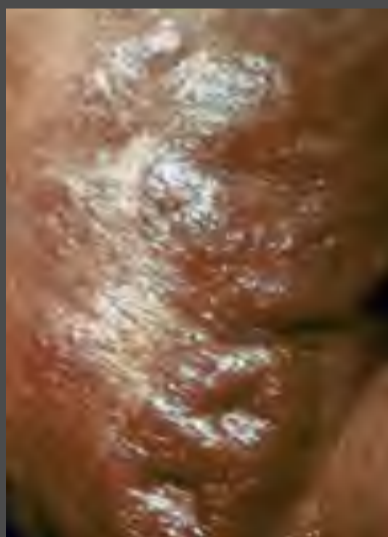**Figure 3.191A.**  
Nodular infiltrating plaques on the face; nodular-tumoral appearance on upper lip and on bridge of the nose (*Leishmania (L.) amazonensis*)



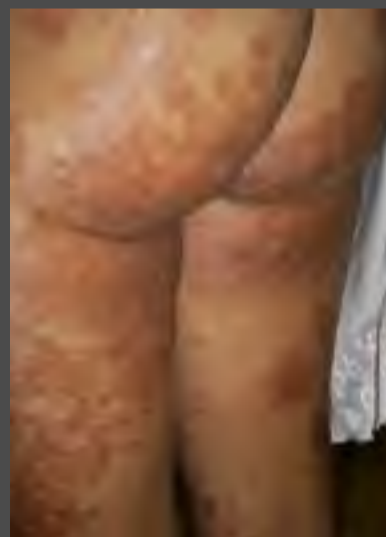**Figure 3.191B.**  
Nodular-tumoral plaque on bridge of the nose, and nodular infiltrating plaques on cheek and right ear (*Leishmania (L.) amazonensis*)



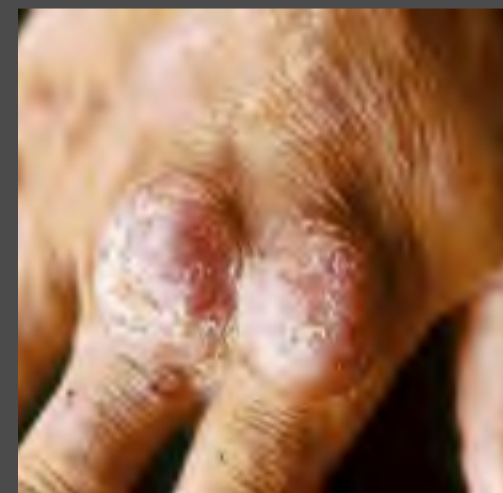**Figure 3.192.**  
Nodular-tumoral plaques on face, ear, and arms (*Leishmania (L.) amazonensis*)



**Figure 3.193.**  
Punched-out lesions



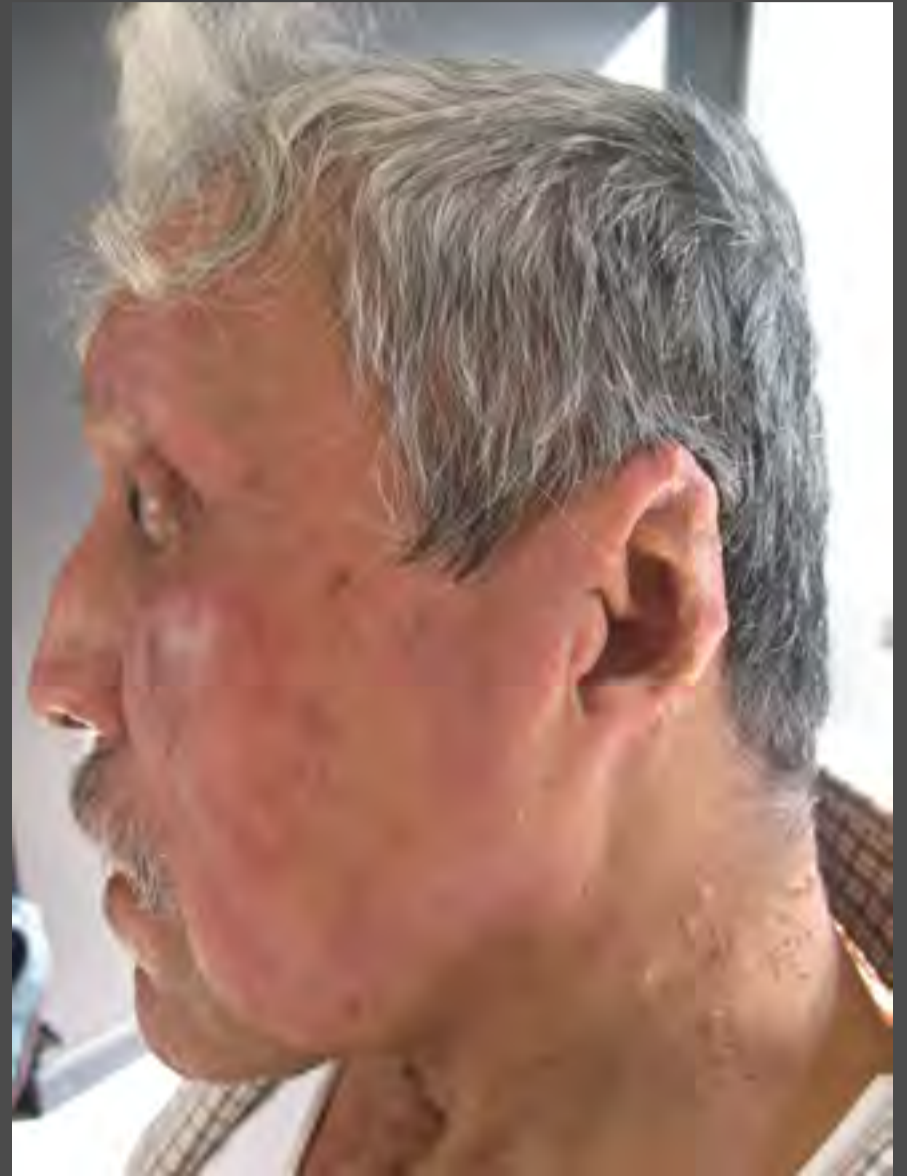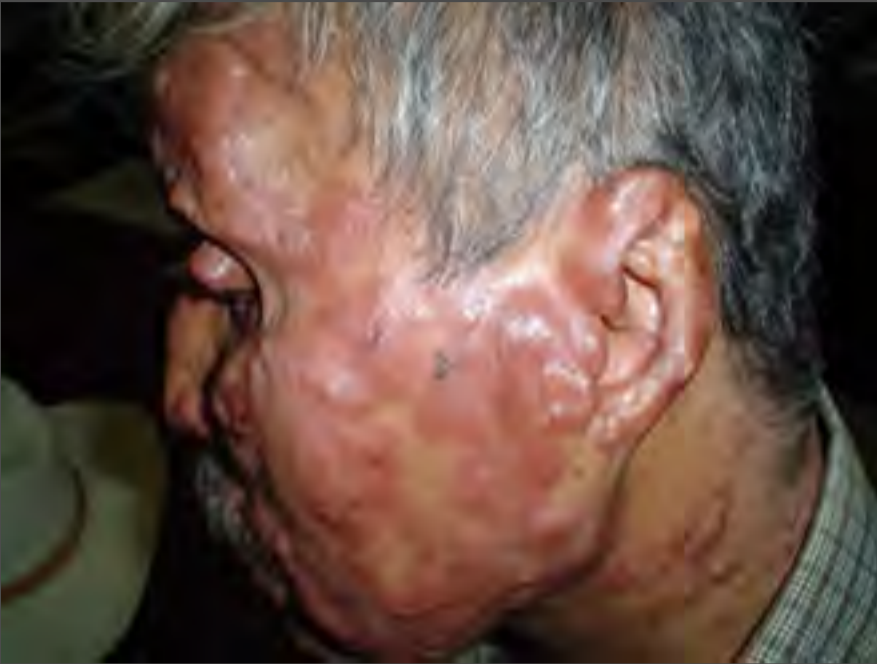**Figure 3.194.**  
Infiltrating plaque lesions on buttocks and thighs



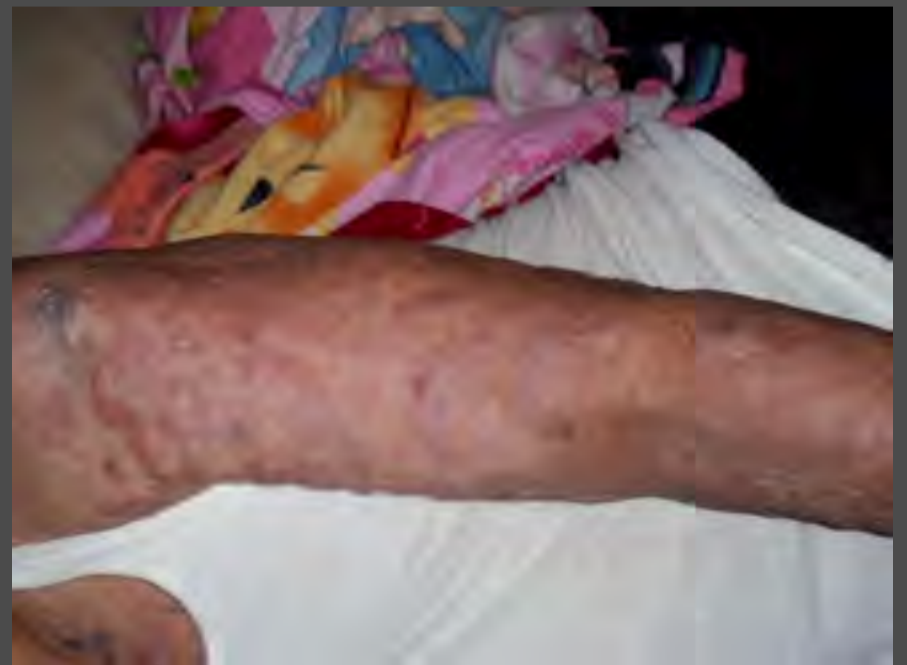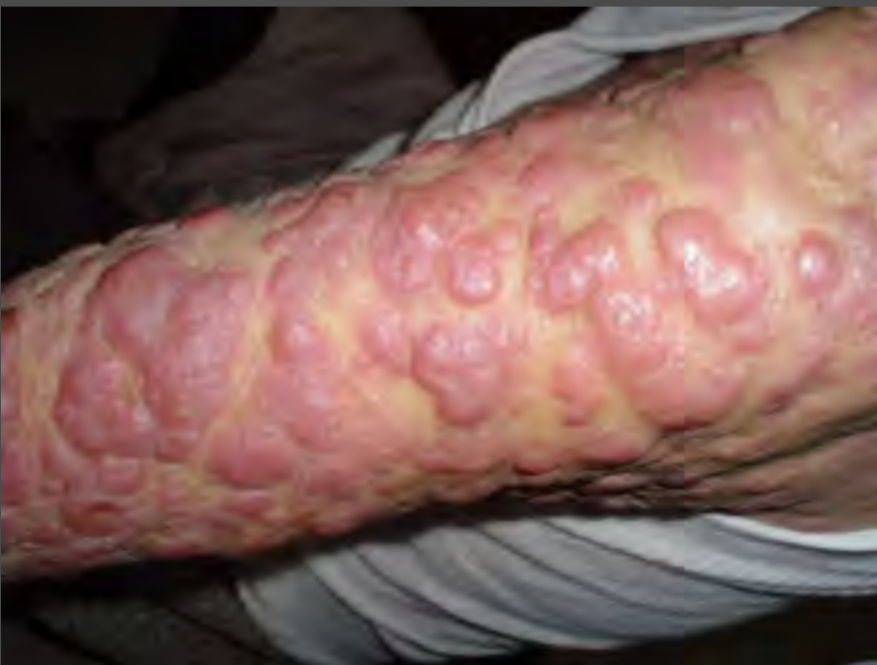**Figure 3.195.**  
Lesions with nodular-tumoral appearance on the knuckles



## Diffuse cutaneous leishmaniasis

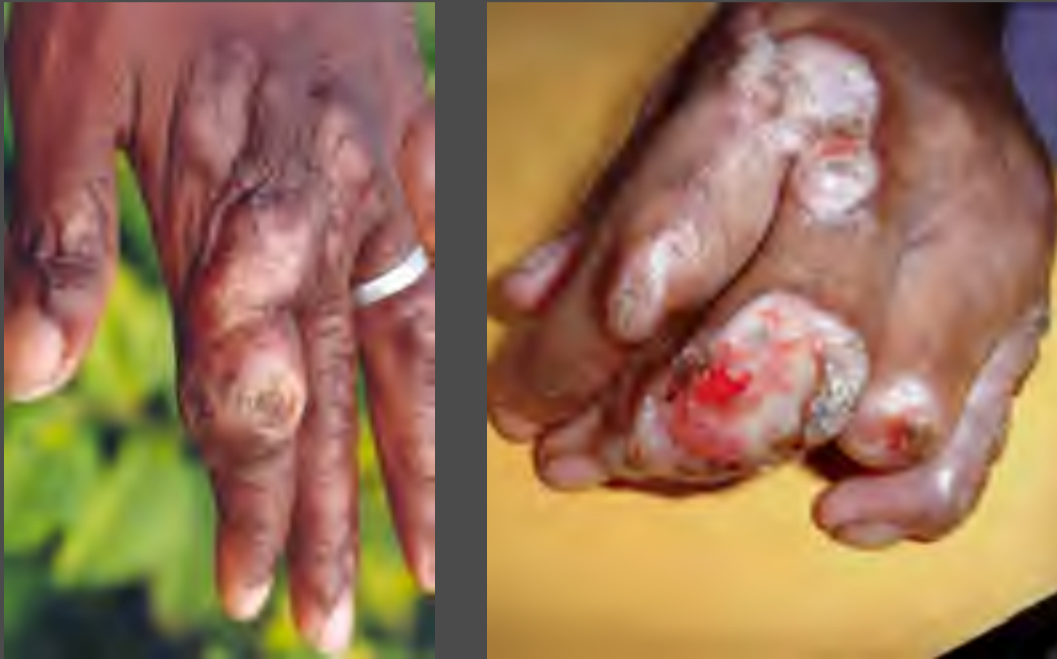

**Figures 3.196A and B.**  
Nodules on the face before and after treatment  
(*Leishmania (L.) mexicana*)



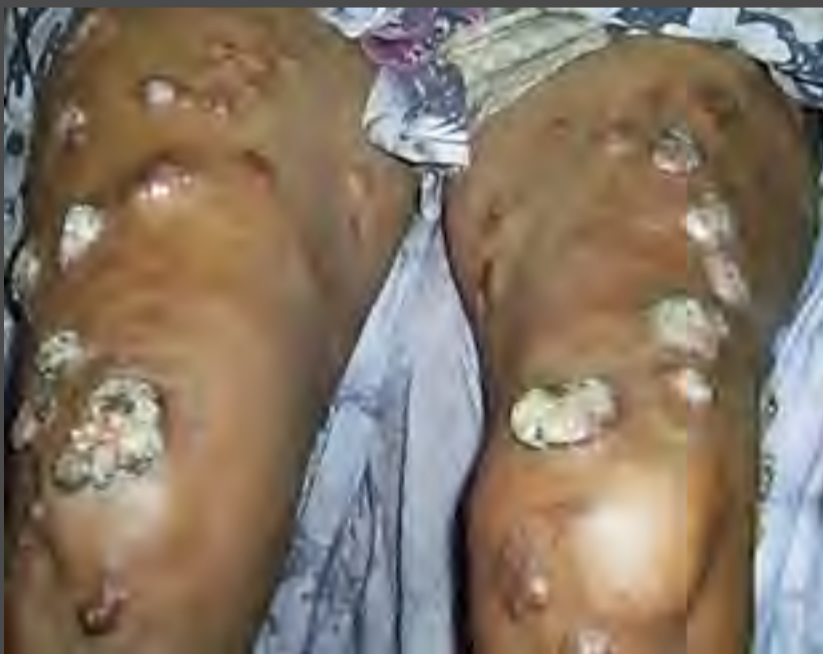**Figures 3.197A and B.**  
Lesions with nodular-tumoral appearance (permanent deformity) on hands (*Leishmania (L.) mexicana*)

## Diffuse cutaneous leishmaniasis



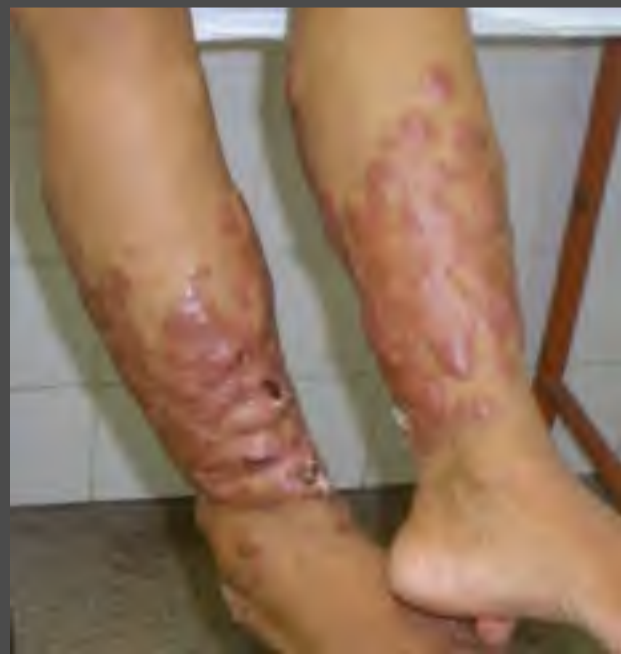**Figures 3.198A and B.**

Lesions with nodular-tumoral appearance (permanent deformity) on hands (*Leishmania (L.) amazonensis*)



**Figure 3.199.**

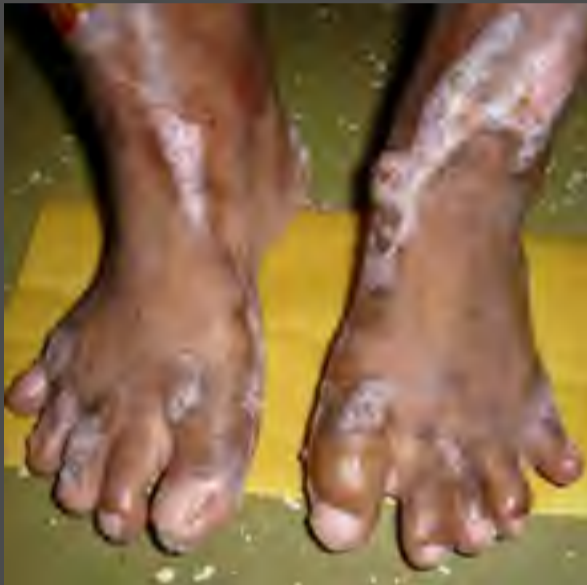Lesions with nodular-tumoral appearance, some warty, on thighs and legs (*Leishmania (L.) amazonensis*)



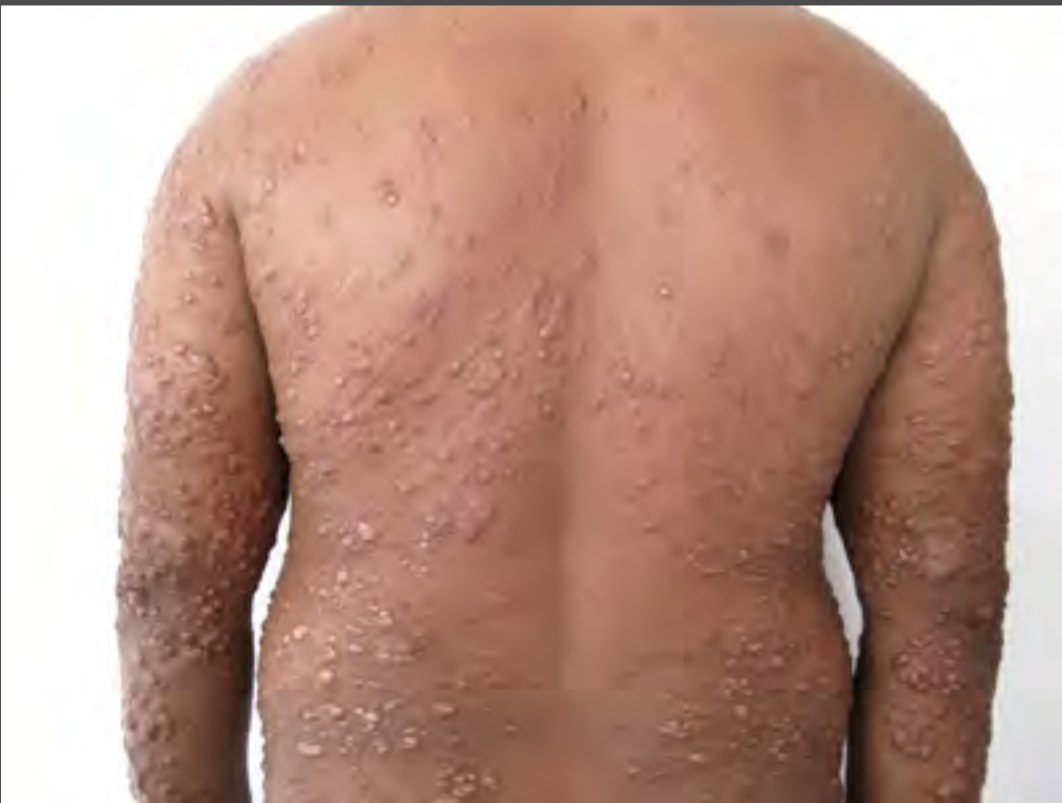**Figure 3.200.**

Lesions with nodular-tumoral appearance, some punched out, on legs (*Leishmania (L.) amazonensis*)

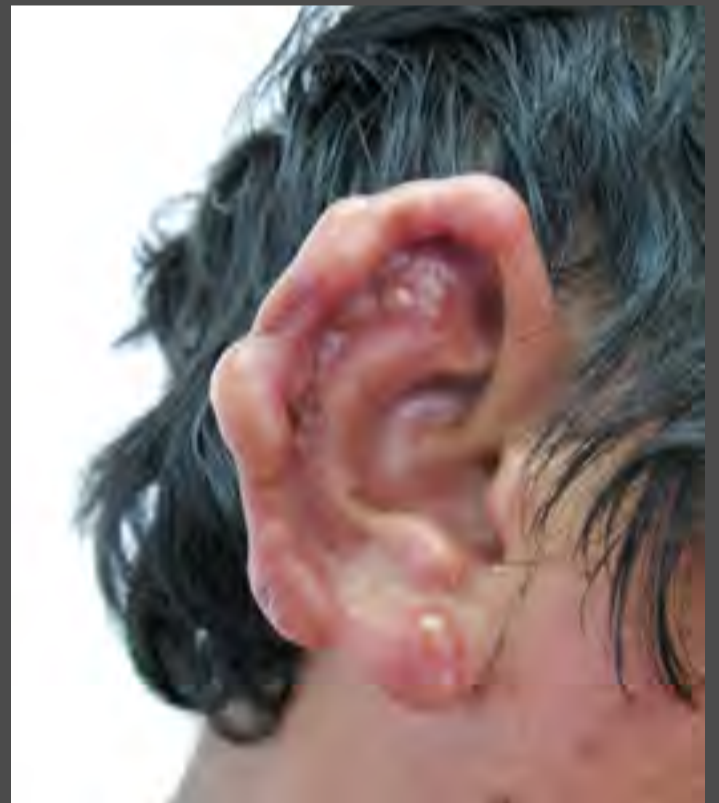## Diffuse cutaneous leishmaniasis



**Figure 3.201.**  
Lesions with nodular-tumoral appearance (permanent deformity) on feet (*Leishmania (L.) amazonensis*)

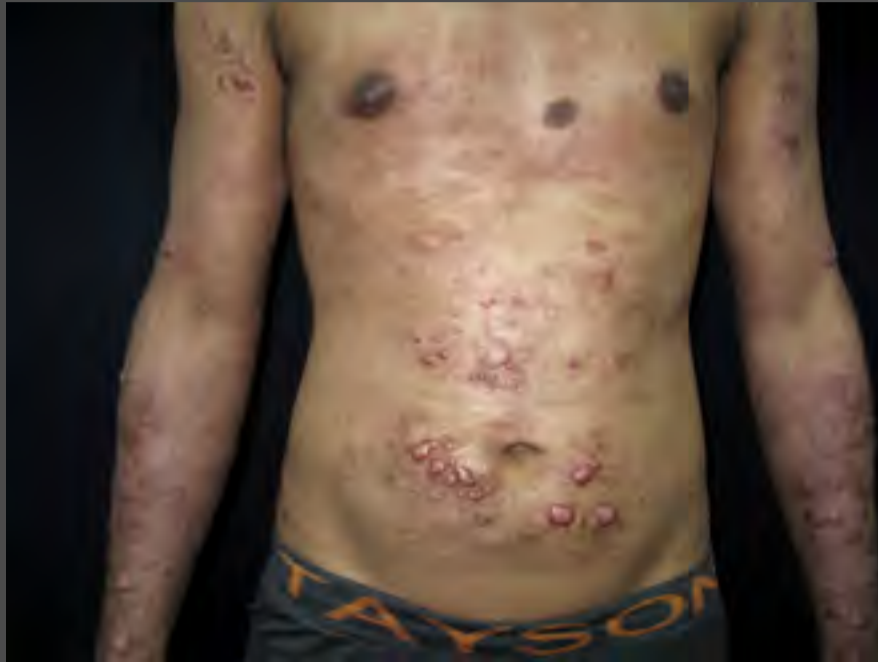

**Figure 3.202A.**  
Nodular lesions disseminated on body surface

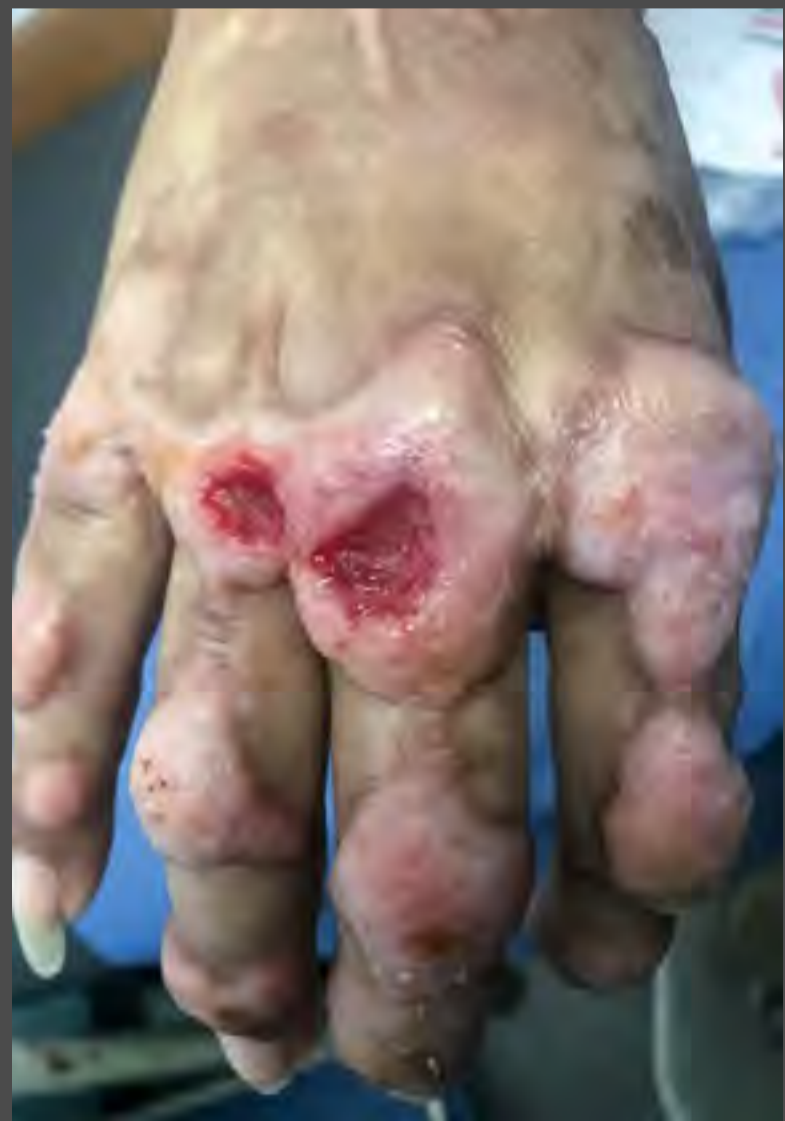
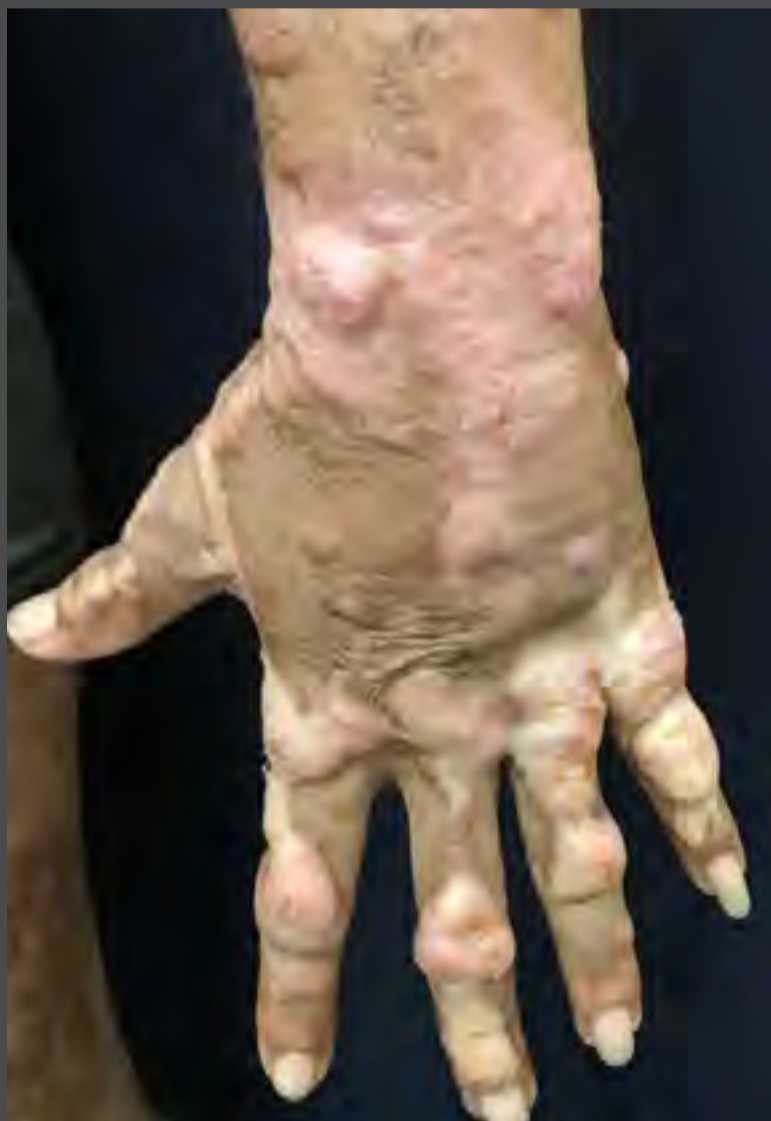
**Figure 3.202B.**  
Infiltrated plaque on the ear

## Diffuse cutaneous leishmaniasis



**Figure 3.203A.**  
Plaques and nodules  
disseminated over  
body surface



**Figures 3.203B and C.**  
Infiltrated plaques with permanent deformity on  
hands. Visible ulceration secondary to trauma in  
the lesions on the left hand.

## Laboratory diagnosis

Diagnosis is confirmed by presence of the parasite on direct examination. The histopathological picture is characterized by a diffuse infiltrate of vacuolated macrophages, full of *Leishmania* spp. amastigotes in the parasitophorous vacuoles, with occasional lymphocytes and plasmocytes, which give it the appearance of a macrophage granuloma. The Montenegro skin test and lymphocyte proliferation are always negative, indicating an almost total and specific blockage of the mechanisms of the cellular immune response for *Leishmania* spp., making it impossible for patients to control the infection in the skin.

## Treatment and follow-up

Poor response to treatment is one of the most salient characteristics of diffuse cutaneous leishmaniasis. This is due to resistance to drugs used for leishmaniasis treatment. The different leishmaniasis drugs produce partial and short-term improvements and the norm is reactivation of lesions. As a result, its characteristic incurability poses a great challenge for clinical management of these patients, which is the reason why diffuse cutaneous leishmaniasis cases should be referred to specialized services.

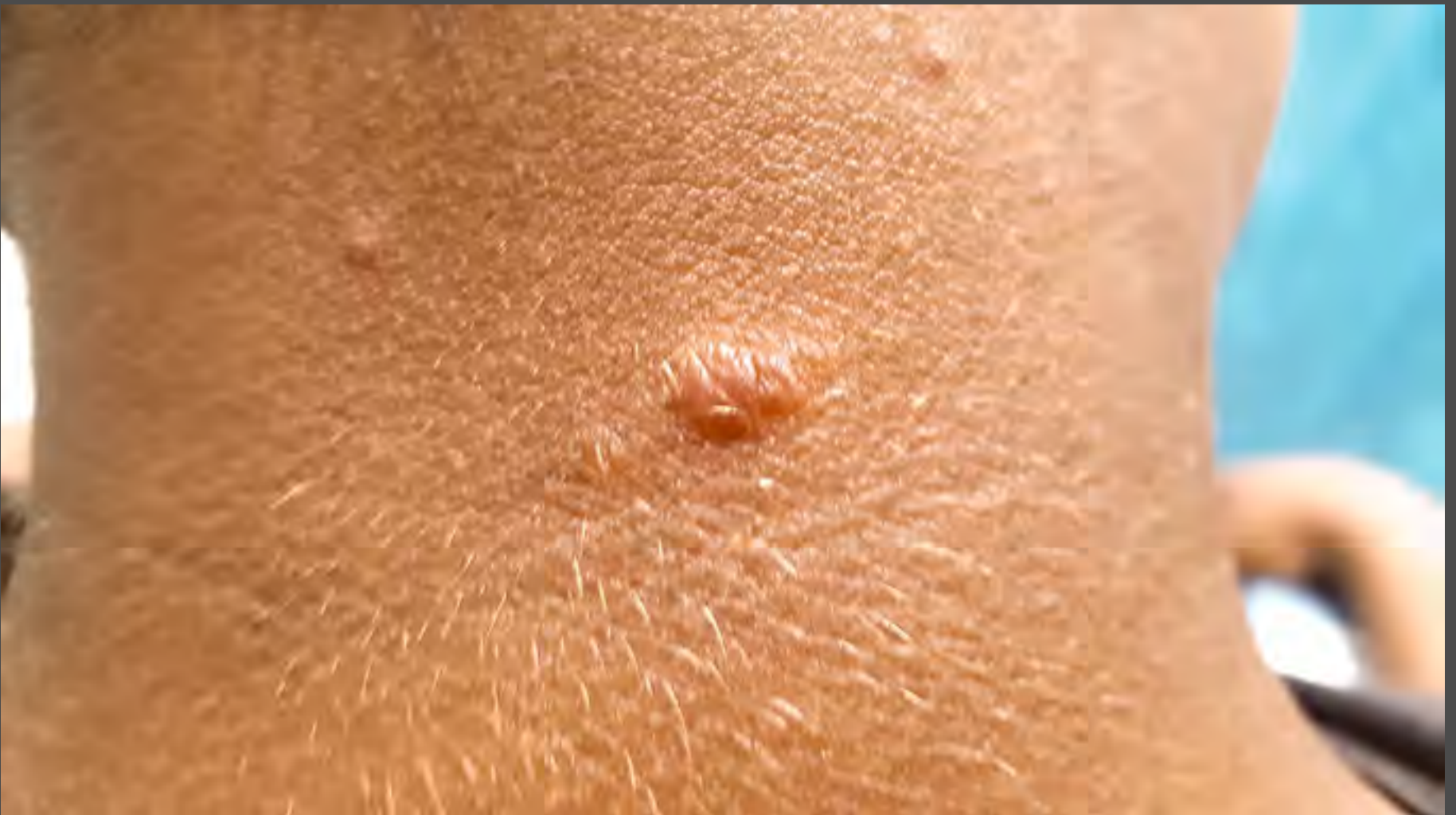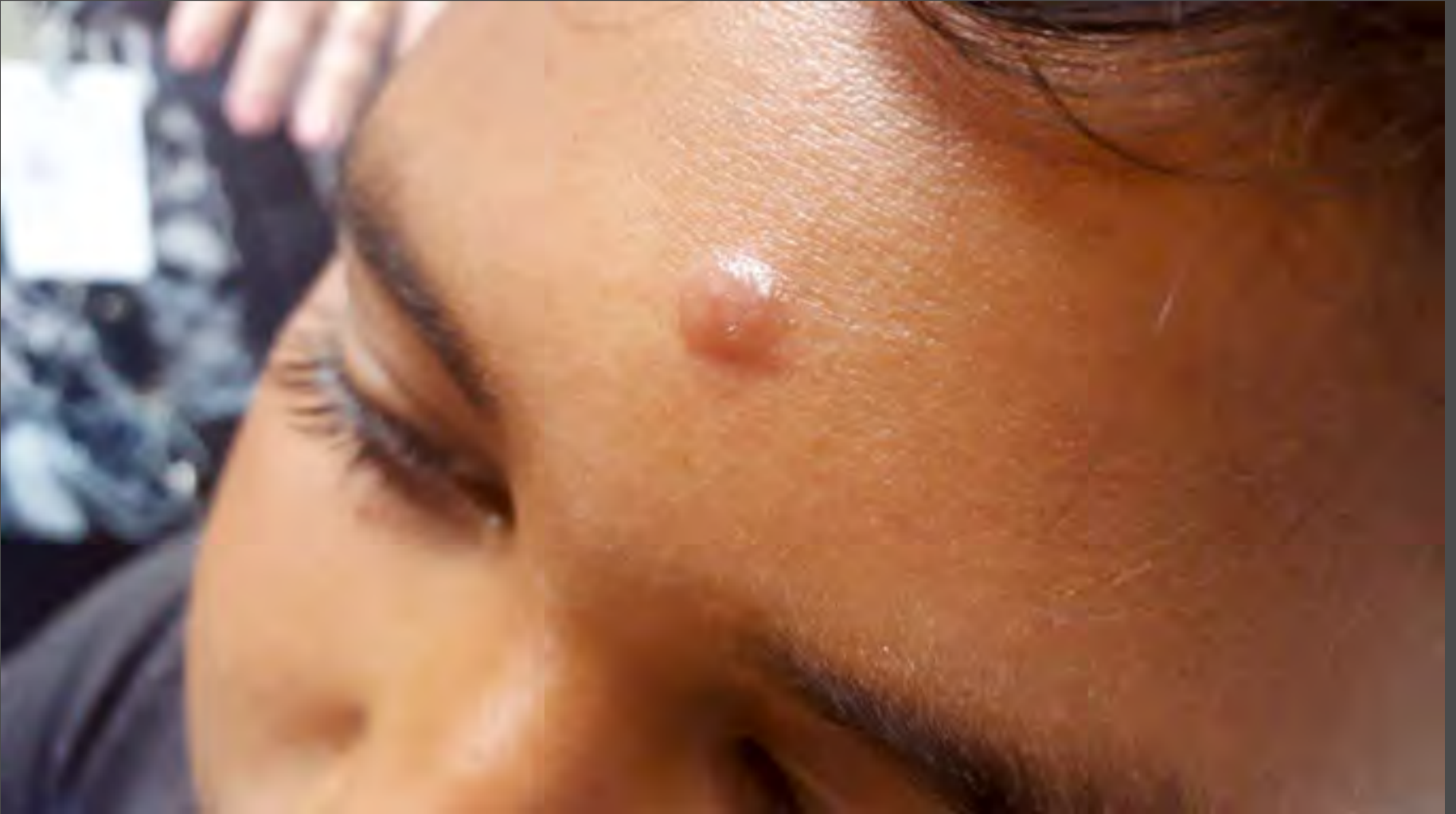## Atypical Cutaneous Leishmaniasis

Atypical cutaneous leishmaniasis has been described in Central America and South America and is produced by *L. (L.) infantum* in the same areas where visceral leishmaniasis appears. The vectors involved in its transmission are *Lu. longipalpis* and *Lu. evansi*.

The most frequent clinical manifestations are characterized by circumscribed lesions, papules, nodules, and non-ulcerated, round, or oval plaques that are reddish-purplish or have mild erythema, with a depigmentation halo (*Figures 3.204*). In general, the greatest frequency of lesions occurs on the face, and neither regional lymphadenopathy nor clinical signs of visceral involvement prior to or concomitant with skin lesions are mentioned. Atypical cutaneous leishmaniasis has been reported in Brazil, Costa Rica, El Salvador, Honduras, Nicaragua, and Venezuela.

Diagnostic confirmation is done with the same methods used for other cutaneous forms, primarily by visual detection of the parasite. Pentavalent antimonials are the first-line drug most commonly used for treatment, administered both systemically and locally and with a favorable therapeutic response. Treatment regimens, case follow-up, and patient management and care are the same as those described above for localized cutaneous leishmaniasis.

Atypical cutaneous leishmaniasis

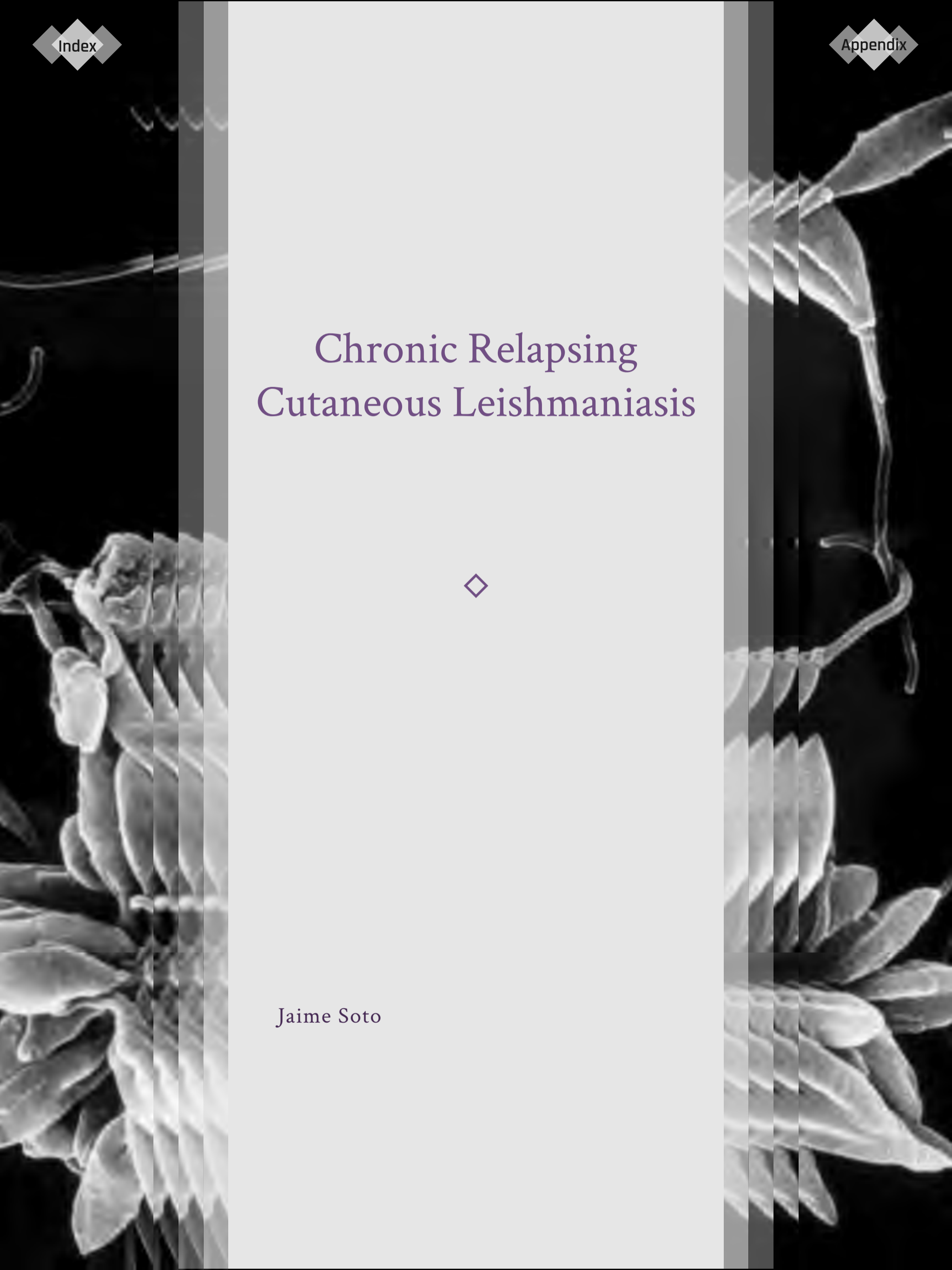


Figures 3.204A and B.  
Non-ulcerated nodular lesion

# Chronic Relapsing Cutaneous Leishmaniasis



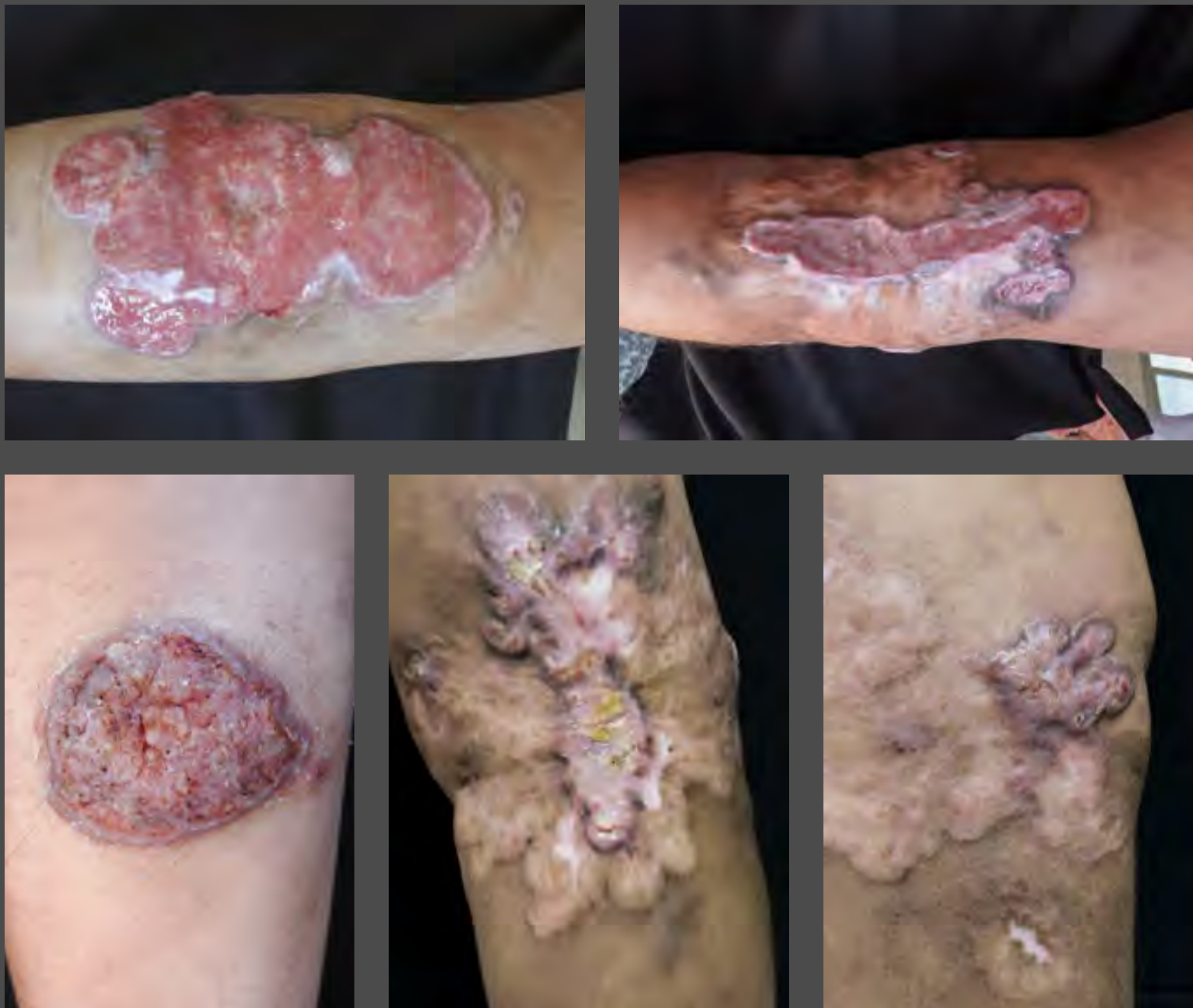Jaime Soto





In those areas where *L. (V.) braziliensis* predominates, a group of patients has been described that increasingly presents clinical manifestations that do not correspond to any of the classical descriptions of chronic relapsing cutaneous leishmaniasis (*Figures 3.205 to 3.216*). Whether these forms are the result of changes in the parasite, in patient immunological status or comorbidity, environmental changes, or a combination of all these factors, is something that has yet to be defined and should be studied.

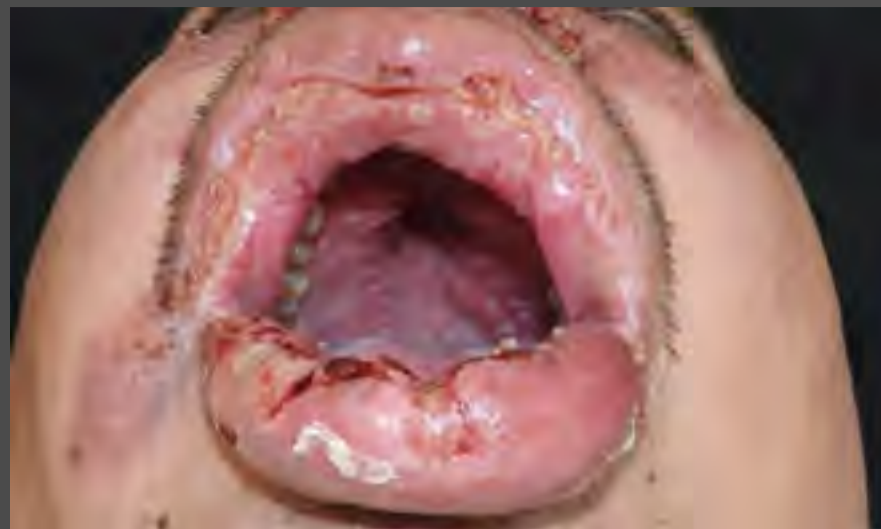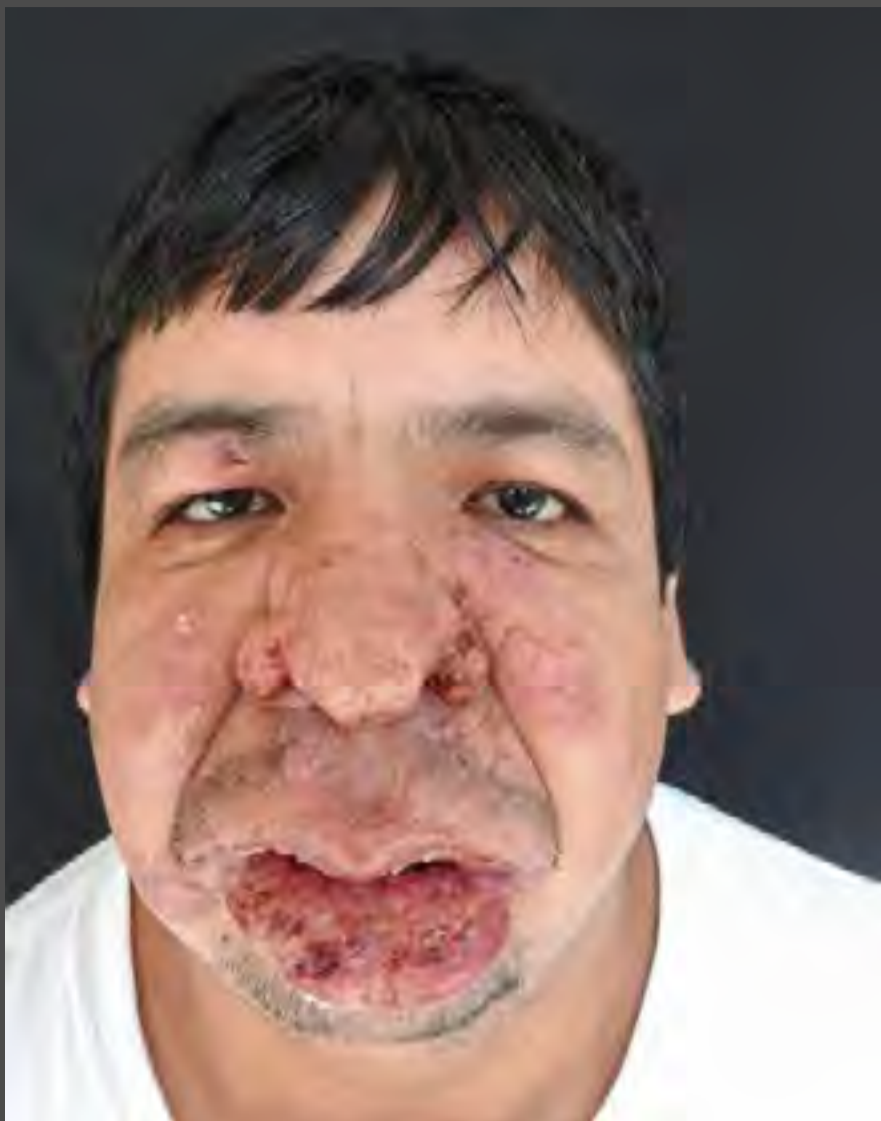## Chronic relapsing cutaneous leishmaniasis



**Figures 3.205A, B, C, D and E.**

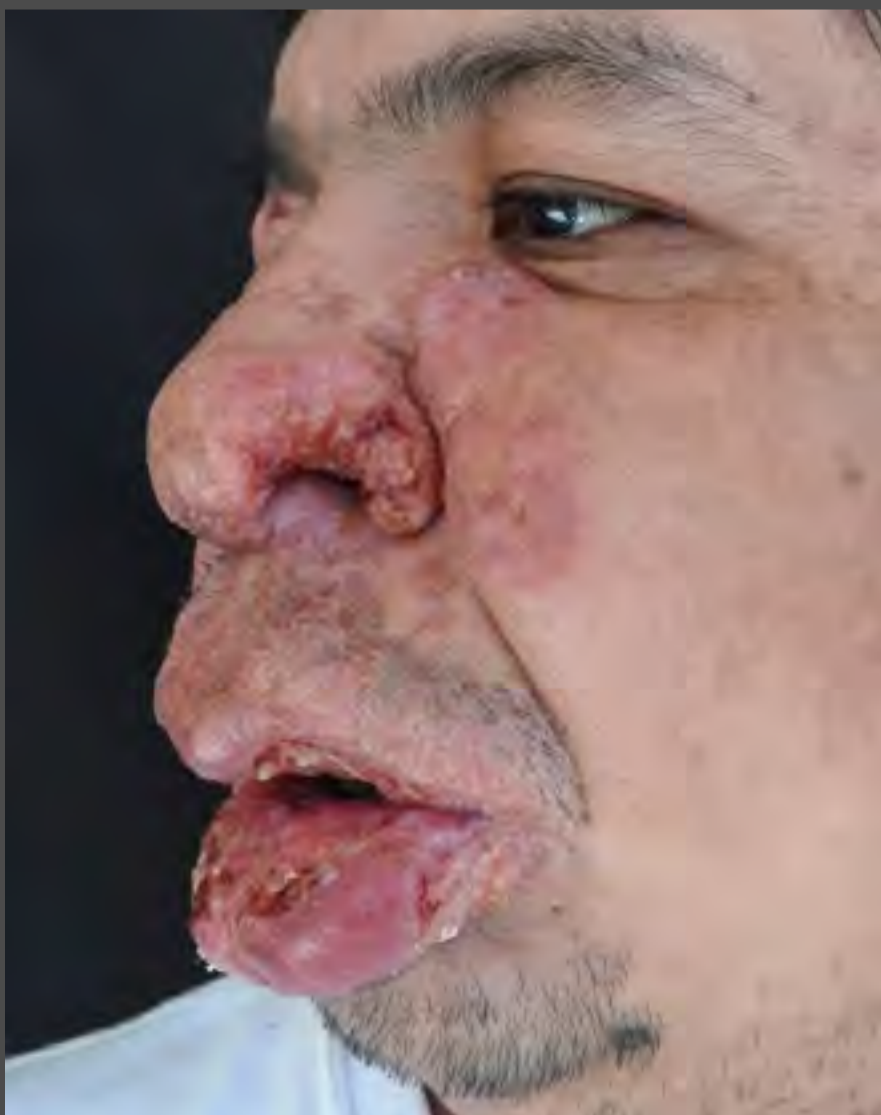Man aged 45 years with cutaneous leishmaniasis on right arm. In 2003, he was treated with meglumine antimonate for 20 days and improved. Seven later years, the initial lesions reactivated and other new ones appeared on the legs, for which he received the same drug for 40 days, with partial resolution of the lesions. In 2015, he returned with extensive involvement of the nasal and oral mucosa, and with lesions on the cheeks, bridge of the nose, and limbs. He received 150 mg of miltefosine daily for 28 days with apparent cure, but rapidly relapsed. Two later years, in 2017, he received amphotericin B deoxycholate, which, due to intolerance to the drug, had to be suspended when his cumulative dose was only 525 mg. In 2018, he received 4 mg/kg of pentamidine every three days in 14 injections, combined with 150 mg of miltefosine daily for 28 days, resulting in an excellent initial therapeutic reaction, with no return for follow-up.

## Chronic relapsing cutaneous leishmaniasis

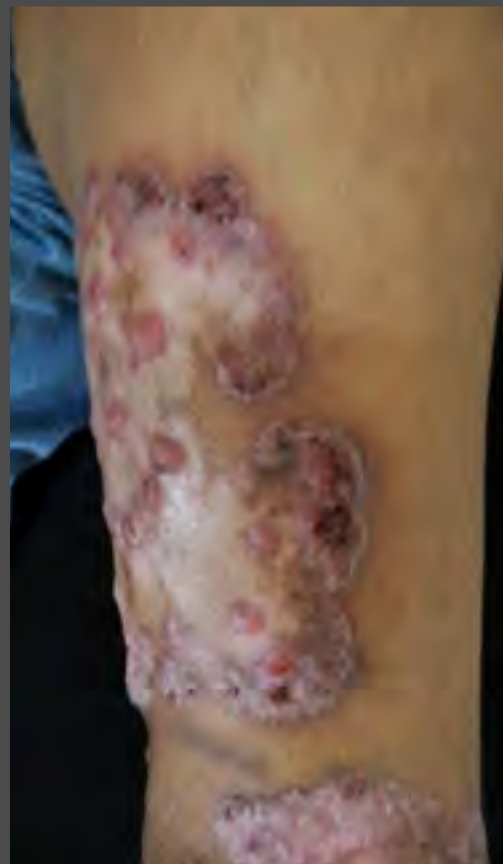
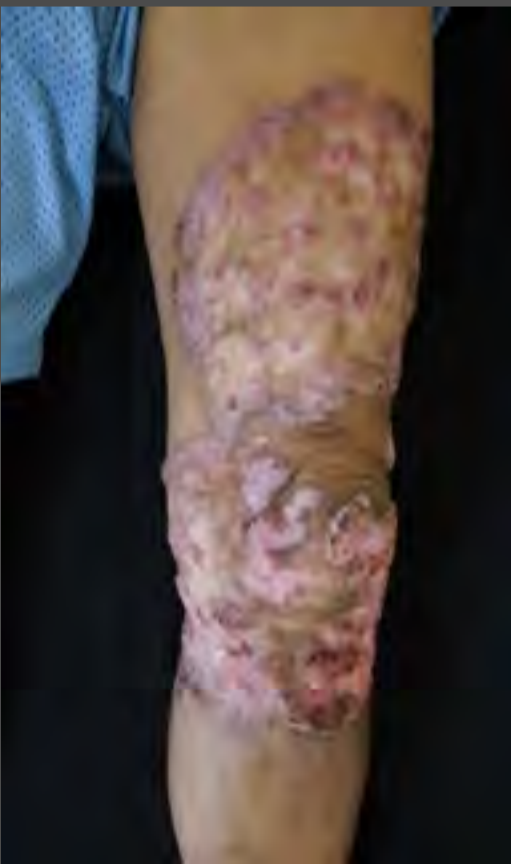
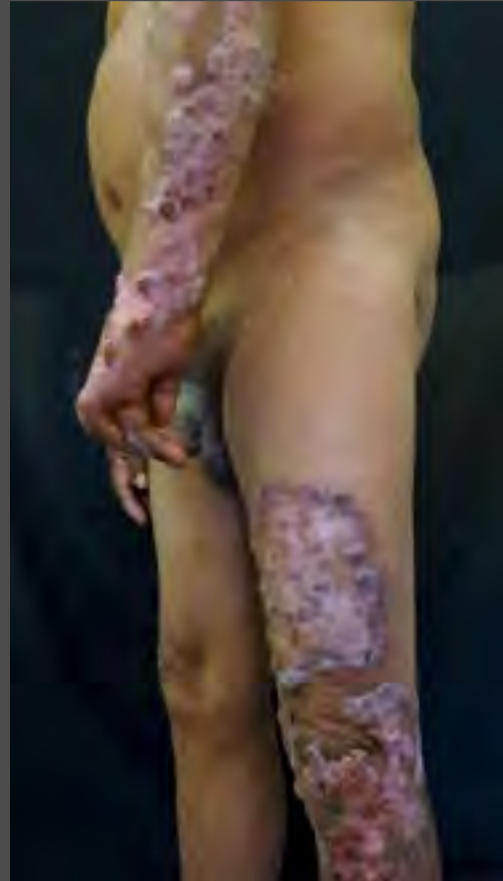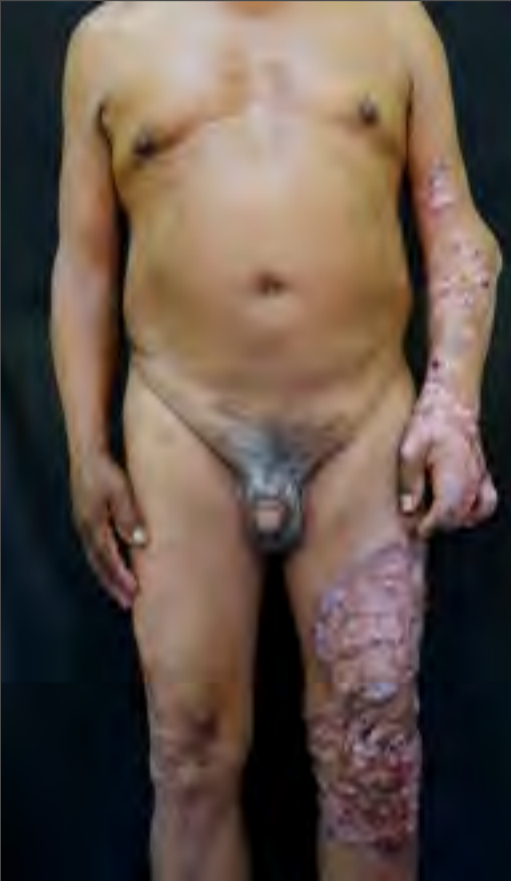**Figures 3.205F, G and H.**

Man aged 45 years with cutaneous leishmaniasis on right arm. In 2003, he was treated with meglumine antimonate for 20 days and improved. Seven later years, the initial lesions reactivated and other new ones appeared on the legs, for which he received the same drug for 40 days, with partial resolution of the lesions. In 2015, he returned with extensive involvement of the nasal and oral mucosa, and with lesions on the cheeks, bridge of the nose, and limbs. He received 150 mg of miltefosine daily for 28 days with apparent cure, but rapidly relapsed. Two later years, in 2017, he received amphotericin B deoxycholate, which, due to intolerance to the drug, had to be suspended when his cumulative dose was only 525 mg. In 2018, he received 4 mg/kg of pentamidine every three days in 14 injections, combined with 150 mg of miltefosine daily for 28 days, resulting in an excellent initial therapeutic reaction, with no return for follow-up.

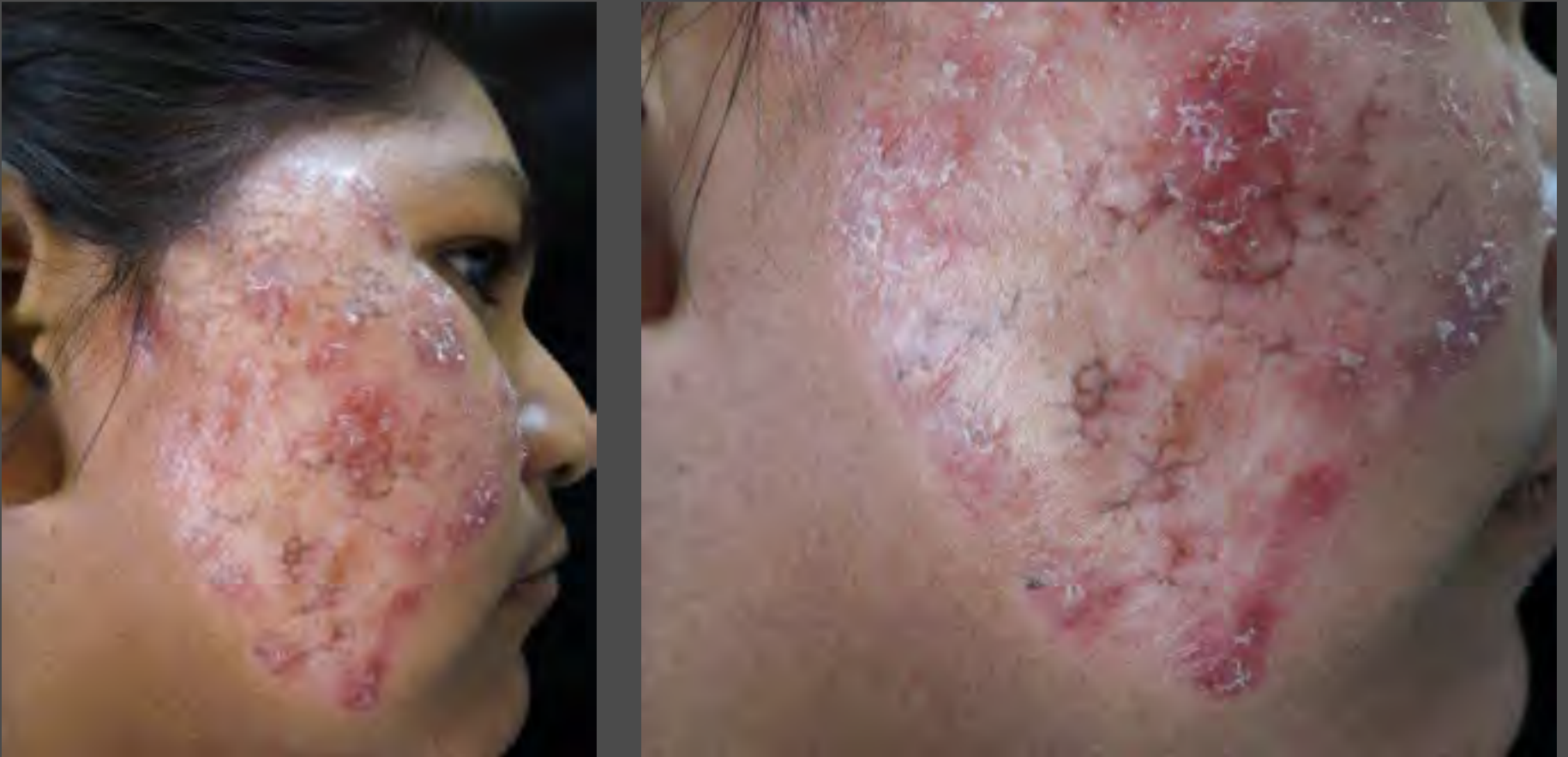

## Chronic relapsing cutaneous leishmaniasis

**Figures 3.206A, B, C and D.**

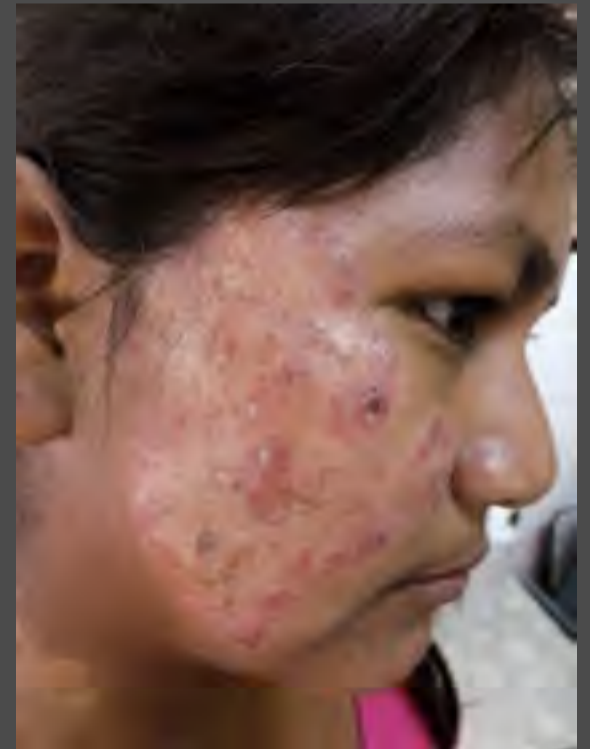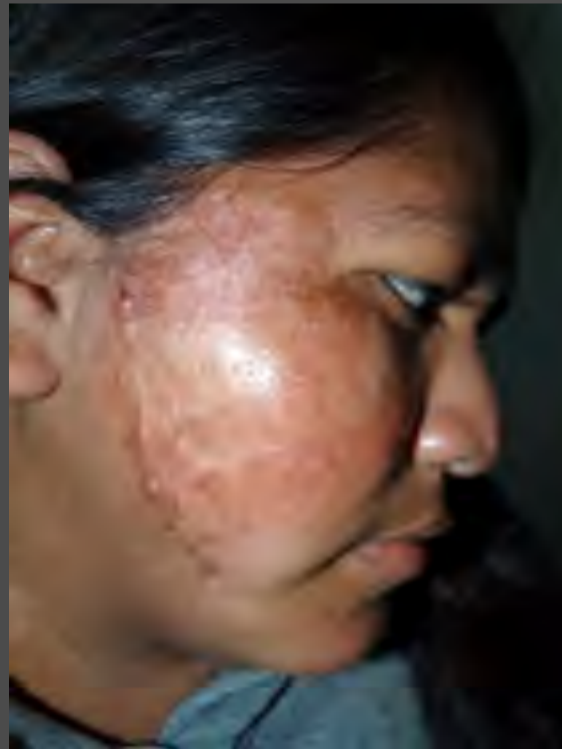Man aged 62 years with two cutaneous leishmaniasis lesions, one on the left arm and the other on the left leg. In 1996, he was treated with meglumine antimonate for 12 days, with partial interruptions due to intolerance or lack of the drug; he improved partially and some small localized lesions persisted. In 2005, lesions began to extend contiguously. Due to a presumptive diagnosis of chromomycosis, he received 400 mg of oral ketoconazole daily for six months, with no improvement. The patient consulted again in 2015; he was diagnosed with poorly controlled type 2 diabetes and leishmaniasis with positive parasitological examination and Montenegro test. He was treated with 150 mg of miltefosine daily for 28 days, with considerable improvement, although without a complete cure. Three later years, in 2018, he consulted again with the involvement illustrated in the photographs. He received 20 mg/kg of meglumine antimonate daily for 30 days, with good tolerance and improvement, but without achieving a cure. He returned a year later with extensive lesions in the same areas.

## Chronic relapsing cutaneous leishmaniasis



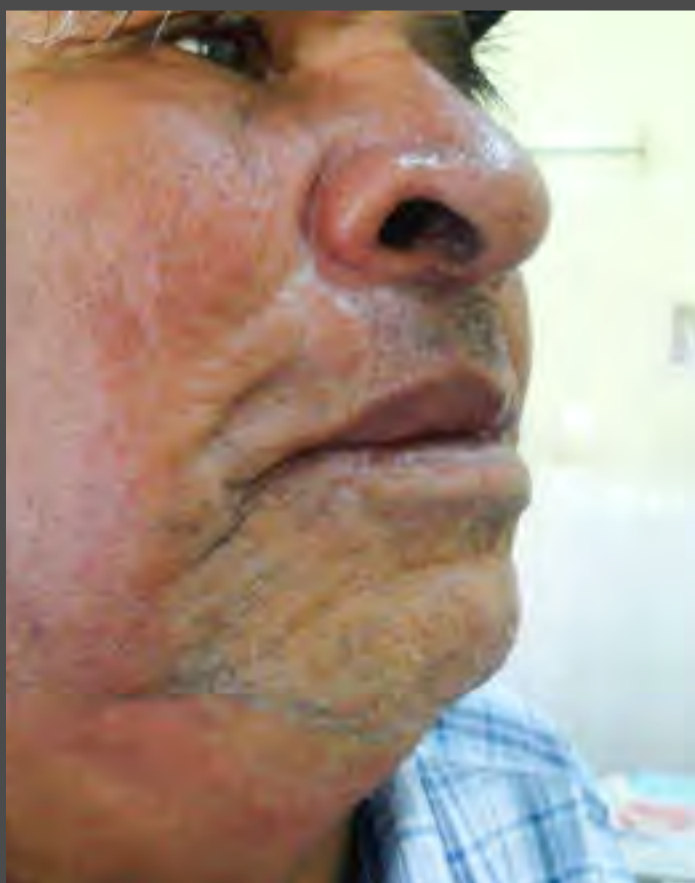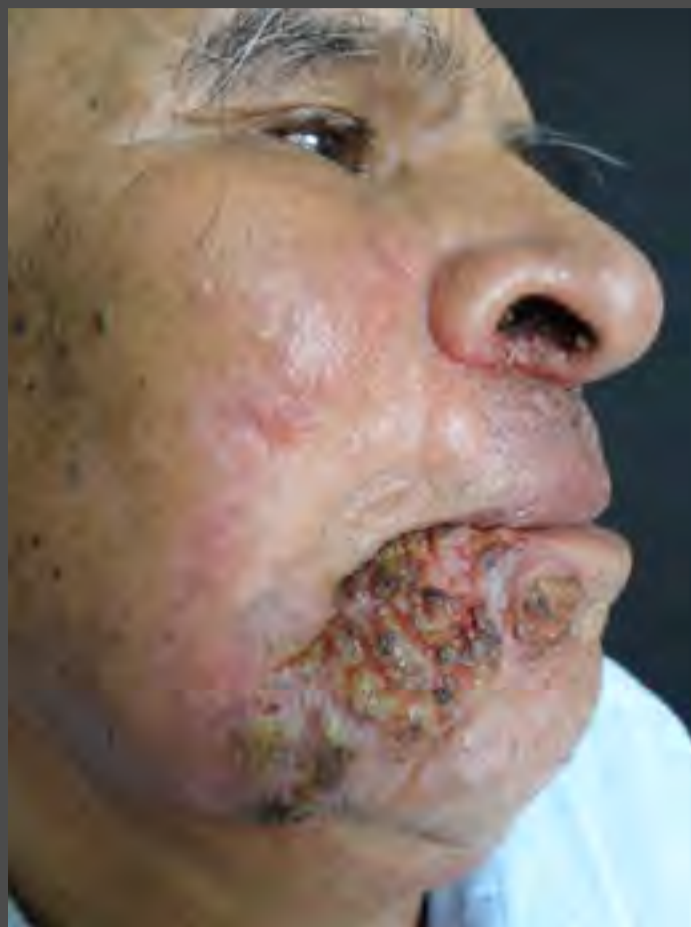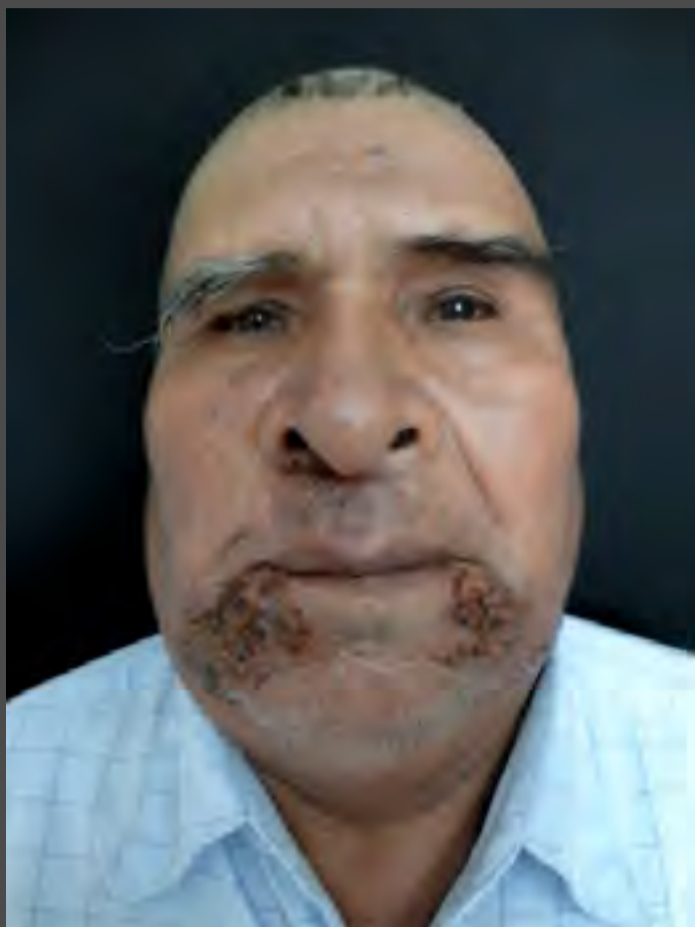
**Figures 3.207A, B, C and D.**

Woman aged 20 years who was treated for cutaneous leishmaniasis on the face at six months of age with 4 mg/kg of pentavalent antimony daily for 20 days, with apparent cure. In 2009, she presented erythematous squamous plaques on the same area of the face. She was given clinical diagnostic tests for lupus vulgaris and received tuberculosis treatment, with no improvement. In 2015, she consulted again with erythematous, squamous, slightly infiltrated plaques on the entire right side of the face.



A new biopsy was done that confirmed cutaneous leishmaniasis and she received 150 mg/kg of miltefosine daily for 28 days, with apparent cure. In 2017, she consulted again for similar, although smaller, lesions again with the presence of *Leishmania* spp., for which she received 14 doses of 4 mg/kg of pentamidine on alternate days, and the lesions disappeared. In 2018, she presented with one small, erosive plaque that had a crusty edge, which disappeared after three 1.5 ml doses of pentamidine, injected into the lesion. A year later she had not had new lesions.

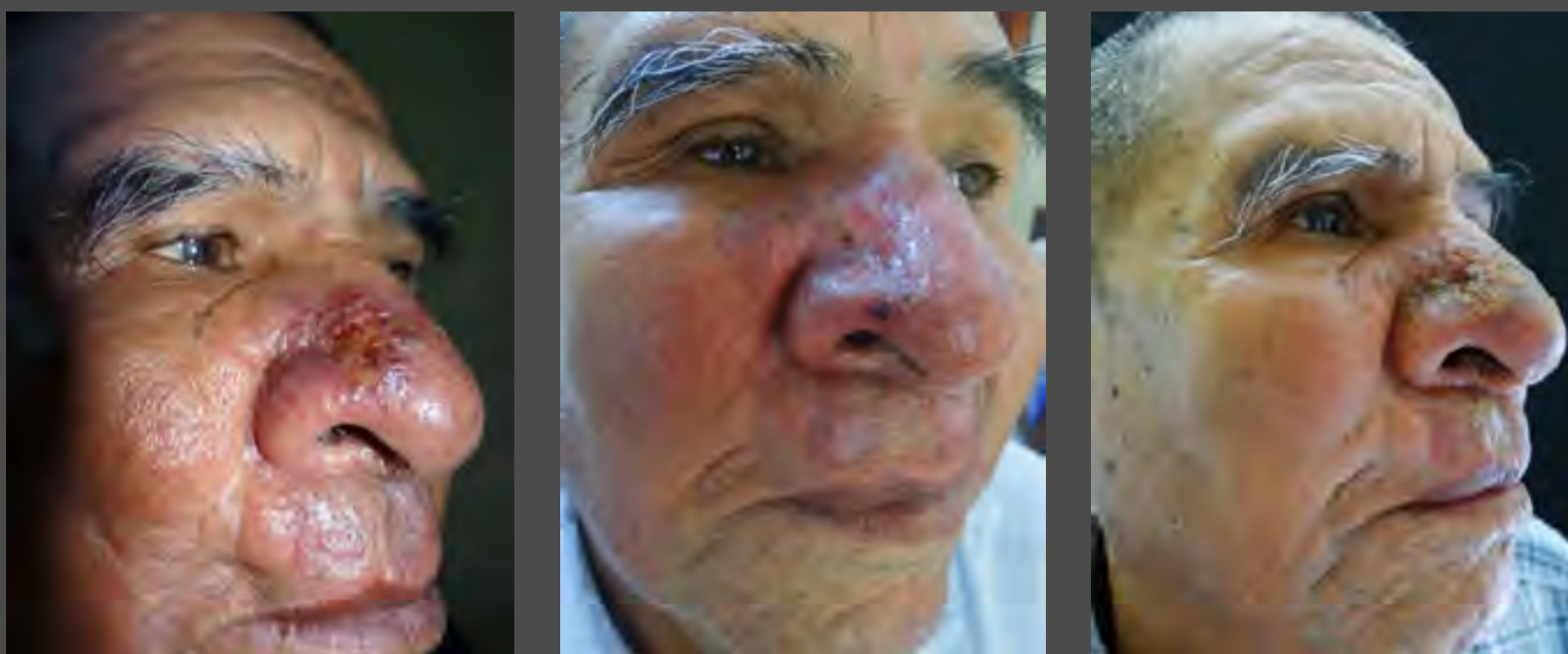
## Chronic relapsing cutaneous leishmaniasis



**Figures 3.208A, B and C.**

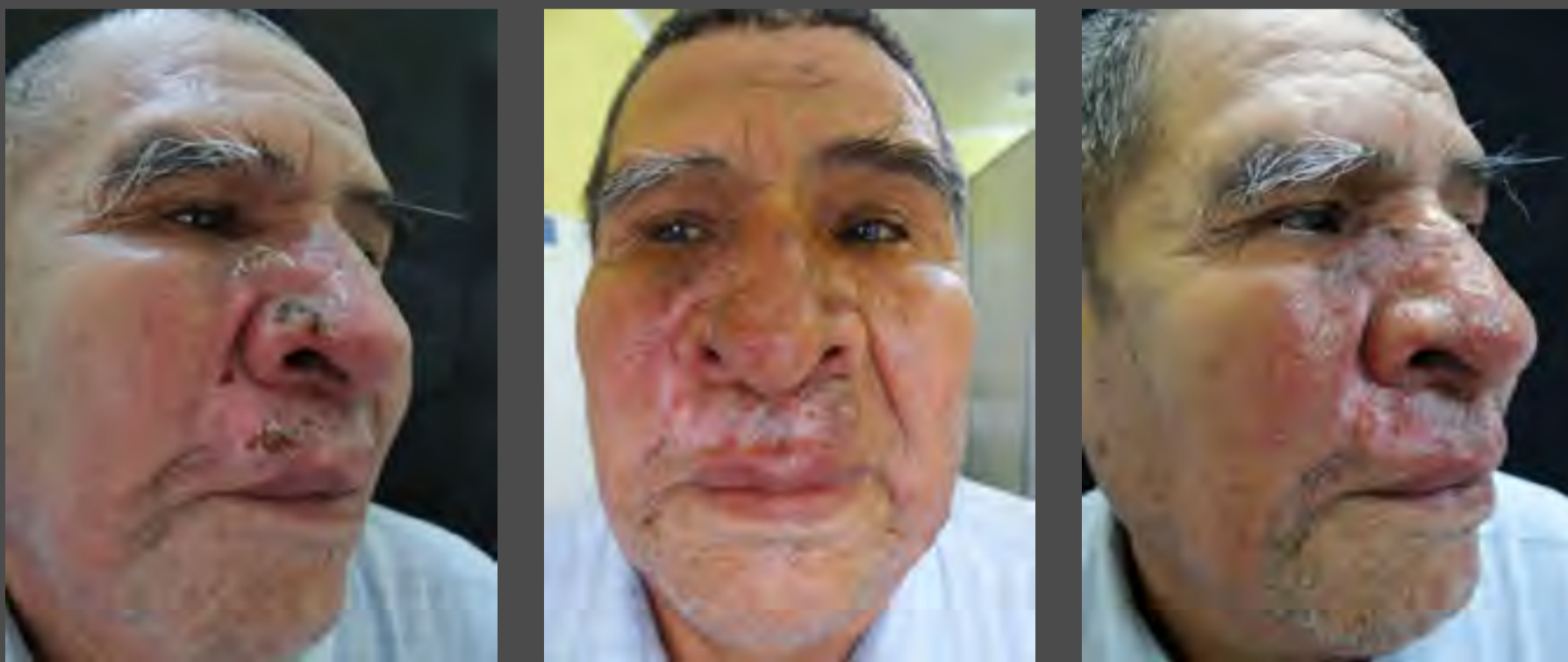
Man aged 72 years, treated in 2011 for cutaneous leishmaniasis on the chin (no photographic record). He received 20 mg/kg of pentavalent antimony per day for 20 days with no maximum dose, with apparent improvement. A year later he returned with crusted infiltrated lesions on his chin and lower cheeks, with no mucous membrane involvement (Figure 3.208A and B). He received 1,250 mg of amphotericin B deoxycholate, which was suspended due to toxicity and, four months later, showed quite substantial improvement (Figure 3.208C).

## Chronic relapsing cutaneous leishmaniasis

**Figures 3.208D, E and F.**

Man aged 72 years, treated in 2011 for cutaneous leishmaniasis on the chin (no photographic record). He received 20 mg/kg of pentavalent antimony per day for 20 days with no maximum dose, with apparent improvement. A year later he returned with crusty infiltrated lesions on his chin and lower cheeks, with no mucous membrane involvement (Figure 3.208A and B). He received 1,250 mg of amphotericin B deoxycholate, which was suspended due to toxicity and, four months later, showed quite substantial improvement (Figure 3.208C). Six months later, lesions appeared on the bridge of the nose (Figure 3.208D) and he received 20 mg/kg of pentavalent antimonials daily for 20 days, with a maximum dose of three ampoules; partial improvement was maintained for four months (Figure 3.208E). Six months later, the lesions had spread to the entire bridge of the nose and to the adjacent area on the cheeks (Figure 3.208F); as before, amastigotes were seen in the direct smear.

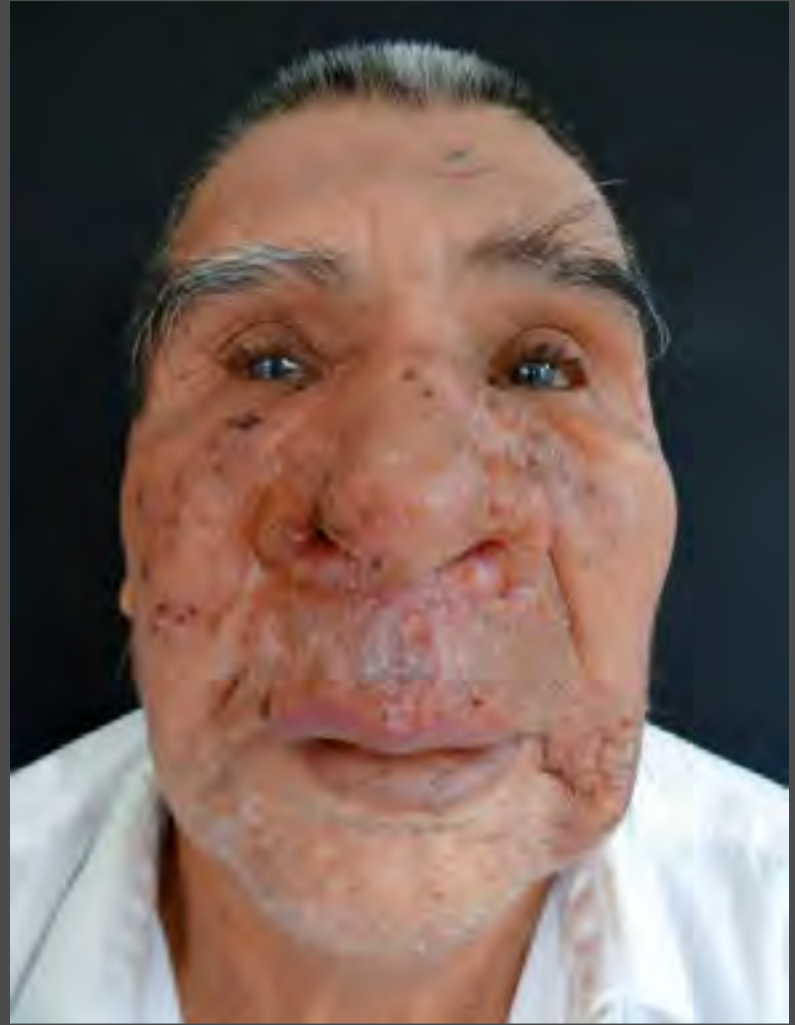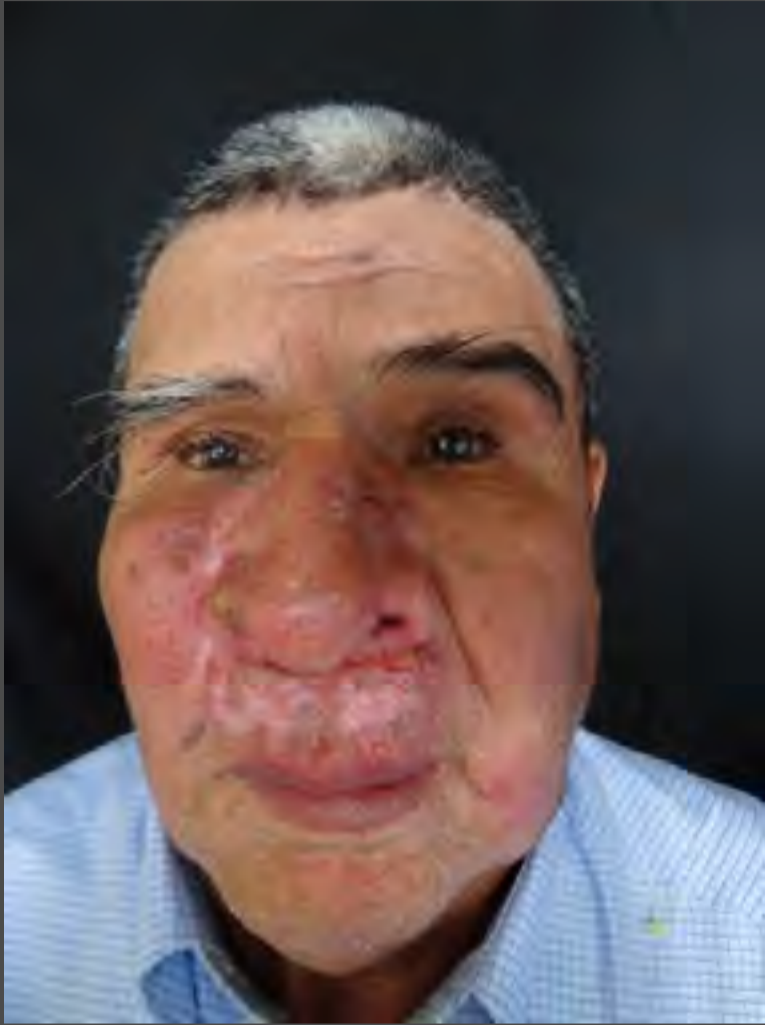## Chronic relapsing cutaneous leishmaniasis

**Figures 3.208G, H e I.**

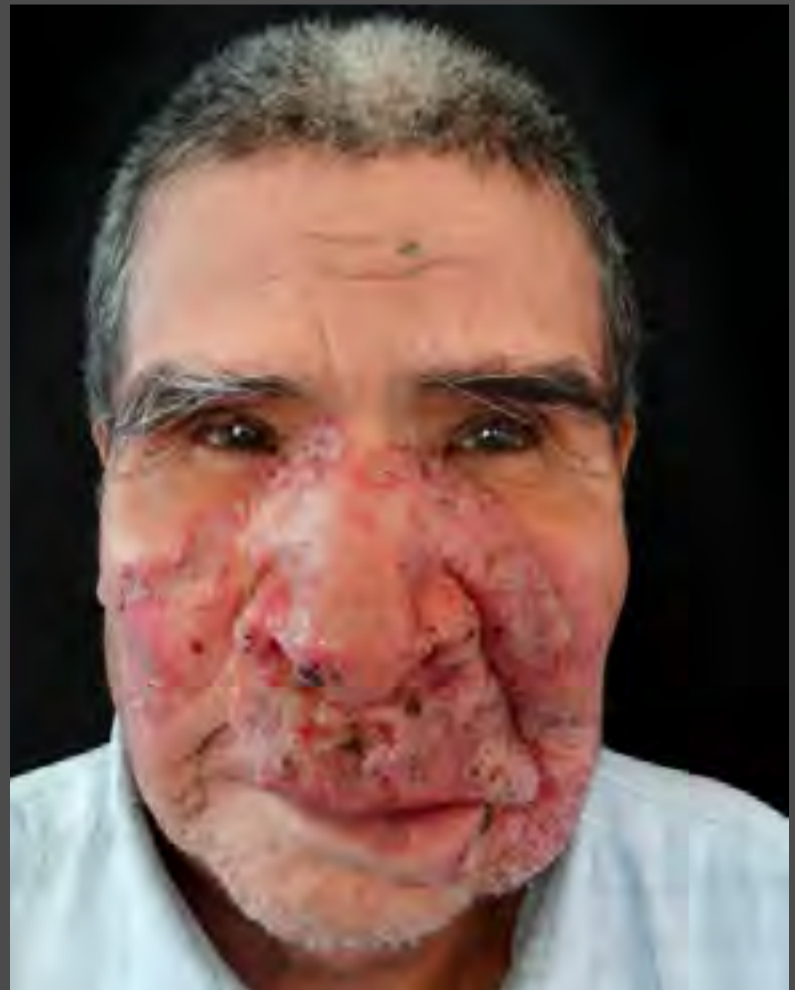Man aged 72 years, treated in 2011 for cutaneous leishmaniasis on the chin (no photographic record). He received 20 mg/kg of pentavalent antimony per day for 20 days with no maximum dose, with apparent improvement. A year later he returned with crusty infiltrated lesions on his chin and lower cheeks, with no mucous membrane involvement (Figure 3.208A and B). He received 1,250 mg of amphotericin B deoxycholate, which was suspended due to toxicity and, four months later, showed quite substantial improvement (Figure 3.208C). Six months later, lesions appeared on the bridge of the nose (Figure 3.208D) and he received 20 mg/kg of pentavalent antimonials daily for 20 days, with a maximum dose of three ampoules; partial improvement was maintained for four months (Figure 3.208E and F). Six months later, the lesions had spread to the entire bridge of the nose and to the adjacent area on the cheeks (Figure 3.208F); as before, amastigotes were seen in the direct smear. He received 150 mg of miltefosine daily for 28 days, five 3.5 ml intralesional injections of pentavalent antimony, and three sessions of aerosol cryotherapy. He had improved significantly and quickly (Figure 3.208G and H) a month after finishing treatment, but three months later the lesions had reactivated and, at a different facility, he received amphotericin B and then pentavalent antimony, apparently with good tolerance and clinical improvement. He returned for follow-up six months later and presented reactivation of the lesions on the bridge of his nose and cheeks (Figure 3.208I).



## Chronic relapsing cutaneous leishmaniasis

**Figures 3.208J. K and L.**

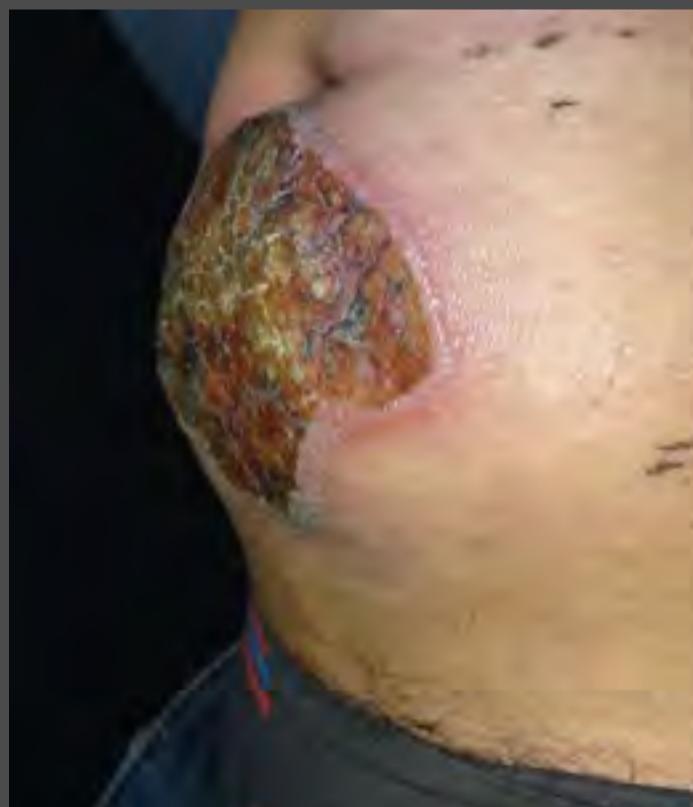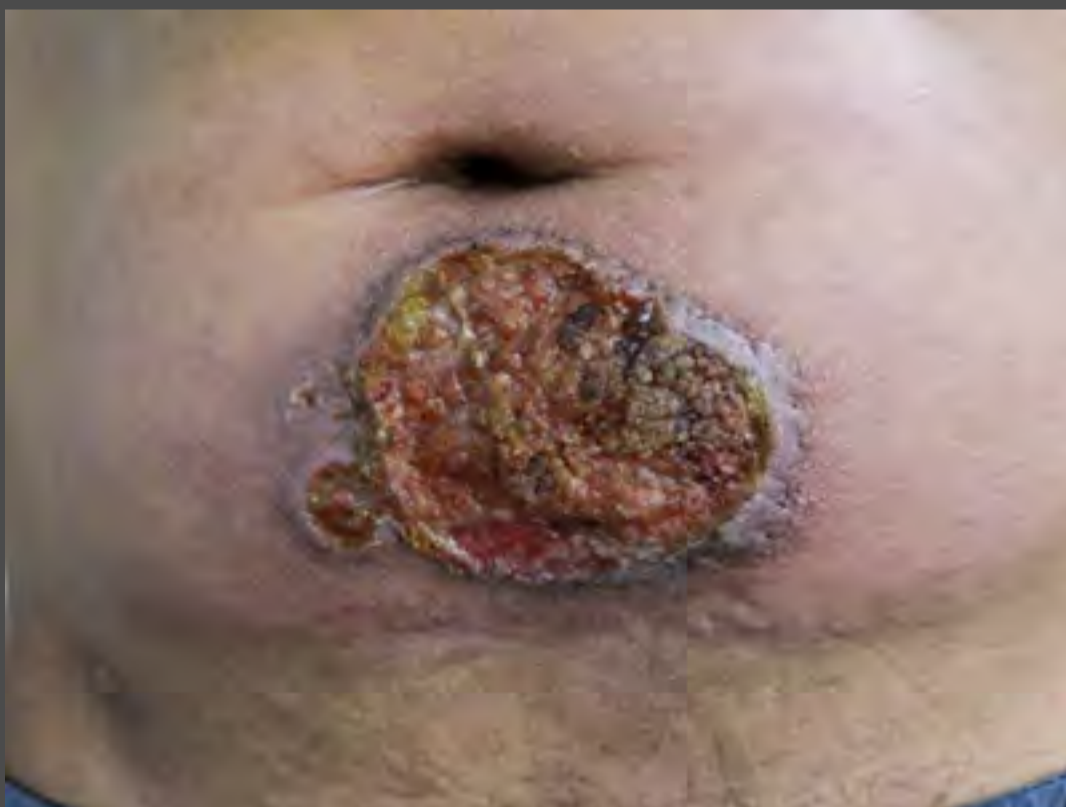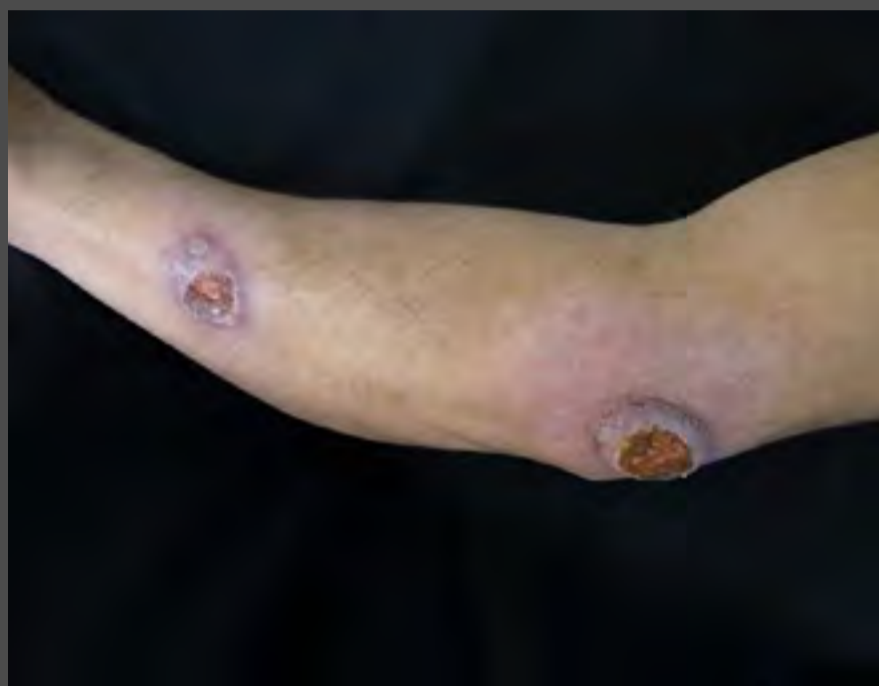The same patient in Figures 3.208 A, B, C, D, E, F, G, H, and I. As the sequence shows, the lesions worsened over the following six months (Figure 3.208J); therefore, 7 doses of pentamidine at 4 mg/kg daily on alternate days was combined with miltefosine, 150 mg daily for 42 days. Improvement was partial (Figure 3.208K) with relapse five months later (Figure 3.208L).



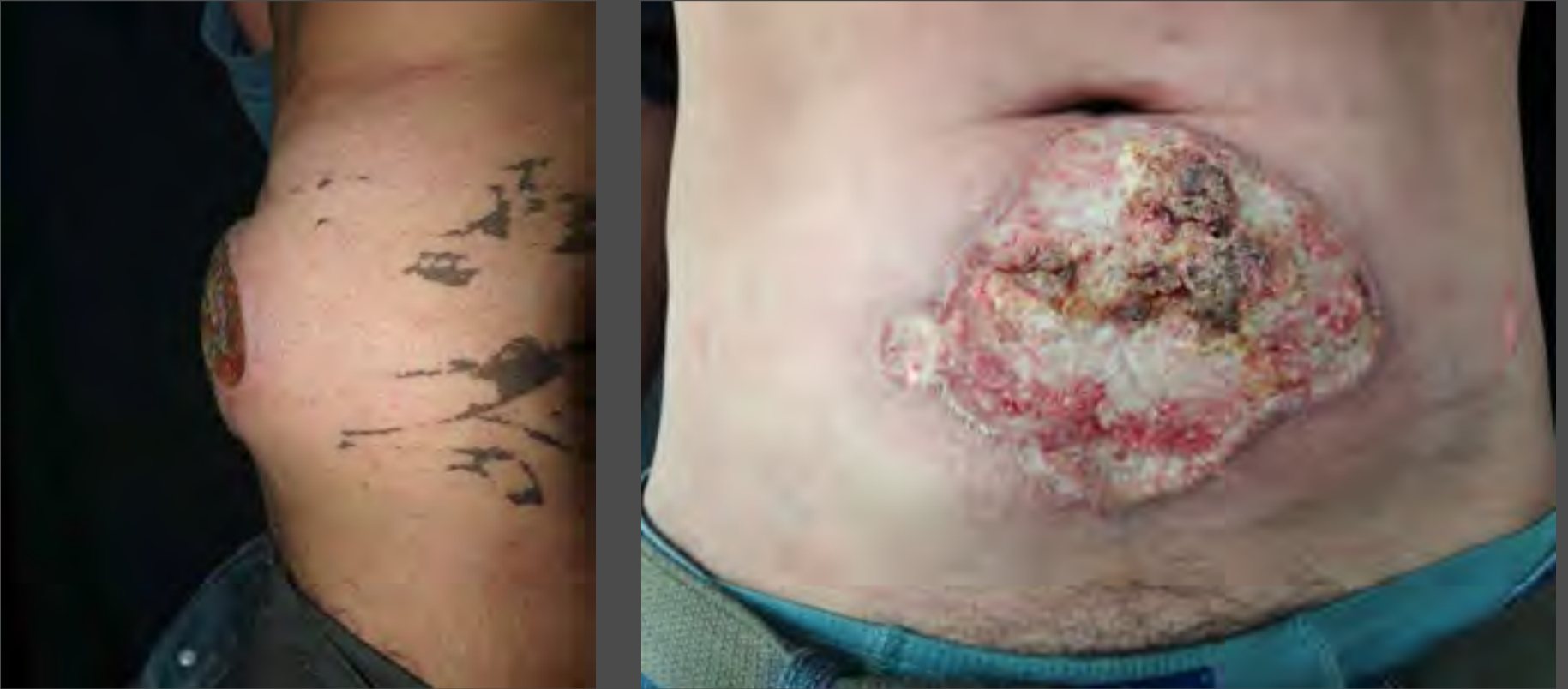## Chronic relapsing cutaneous leishmaniasis

**Figures 3.209A, B and C.**

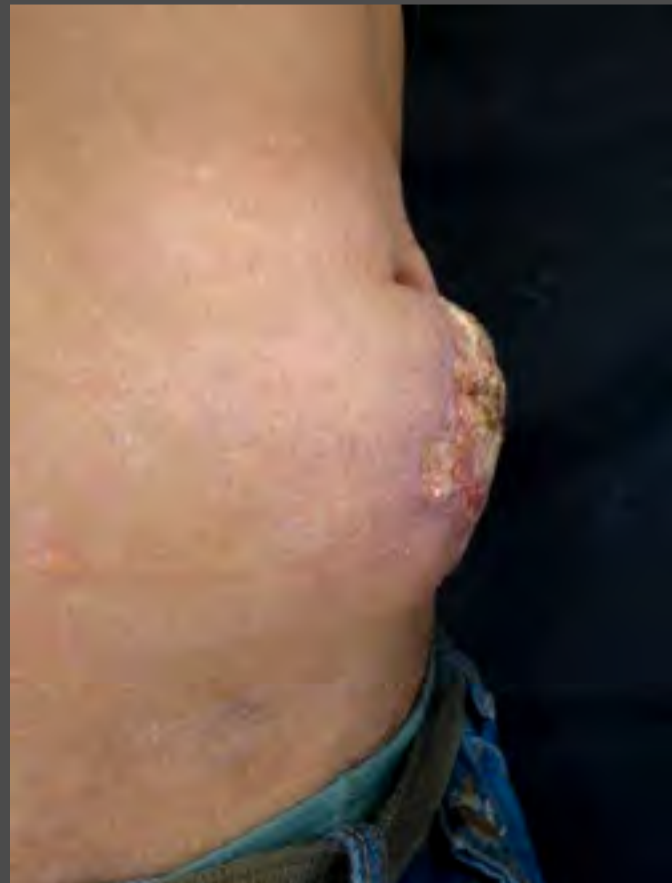Man aged 48 years who consulted in 2015 for two 4-cm ulcers on left arm and one 13 cm in diameter with extensive, intense infiltration that produces bulging of the abdominal wall skin (Figures 3.222A-D). He was treated with 20 mg/kg of a pentavalent antimonial daily for 20 continuous days. At three months, the lesions continued to be active and amastigotes were seen on direct examination of the abdominal lesion, for which he received treatment with 150 mg of miltefosine daily for 28 days, with improvement, but at six months resolution was not complete.



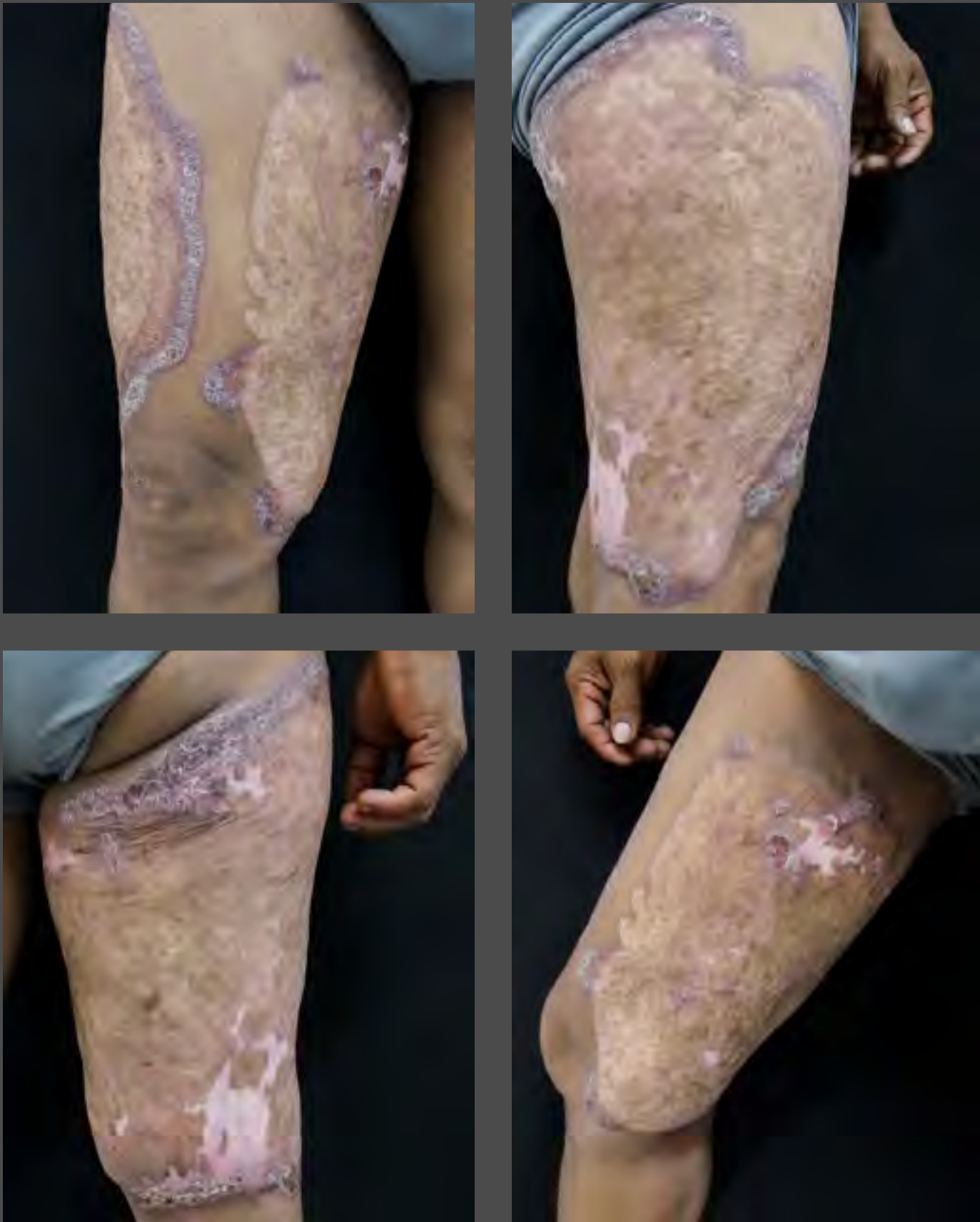## Chronic relapsing cutaneous leishmaniasis

**Figures 3.209D, E and F.**

The same patient in Figures 3.209A, B, and C. Ten months later, the lesions persisted with amastigotes on direct examination, so he received 11 doses of 4 mg/kg of pentamidine on alternate days (Figures 3.222E and F). There was improvement without complete cure, and a year later, he returned with active lesions. He was scheduled for in-hospital combination therapy, but did not return.

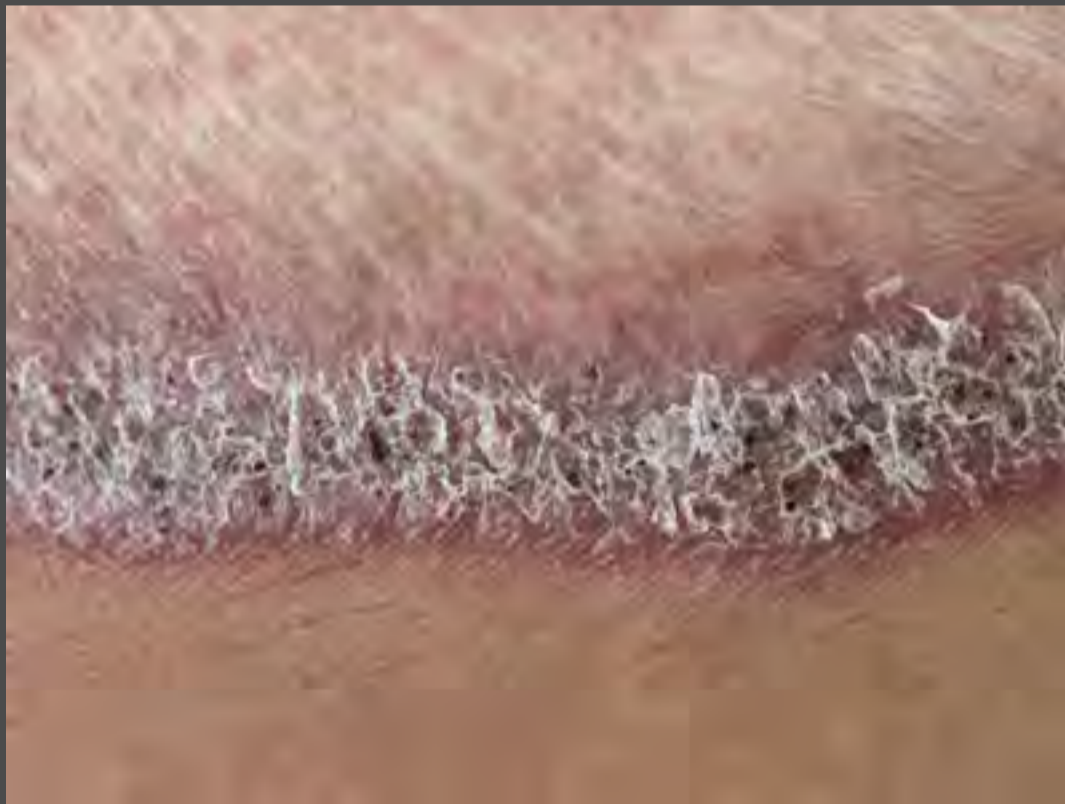
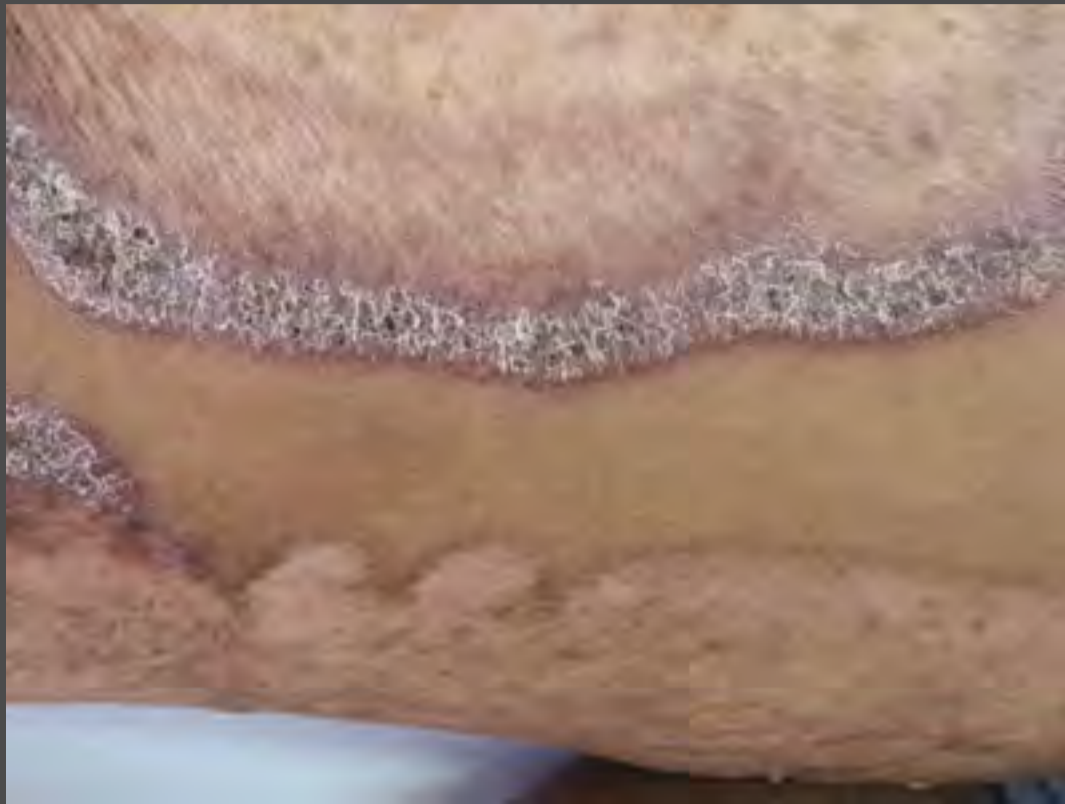
## Chronic relapsing cutaneous leishmaniasis

**Figures 3.210A, B, C and D.**

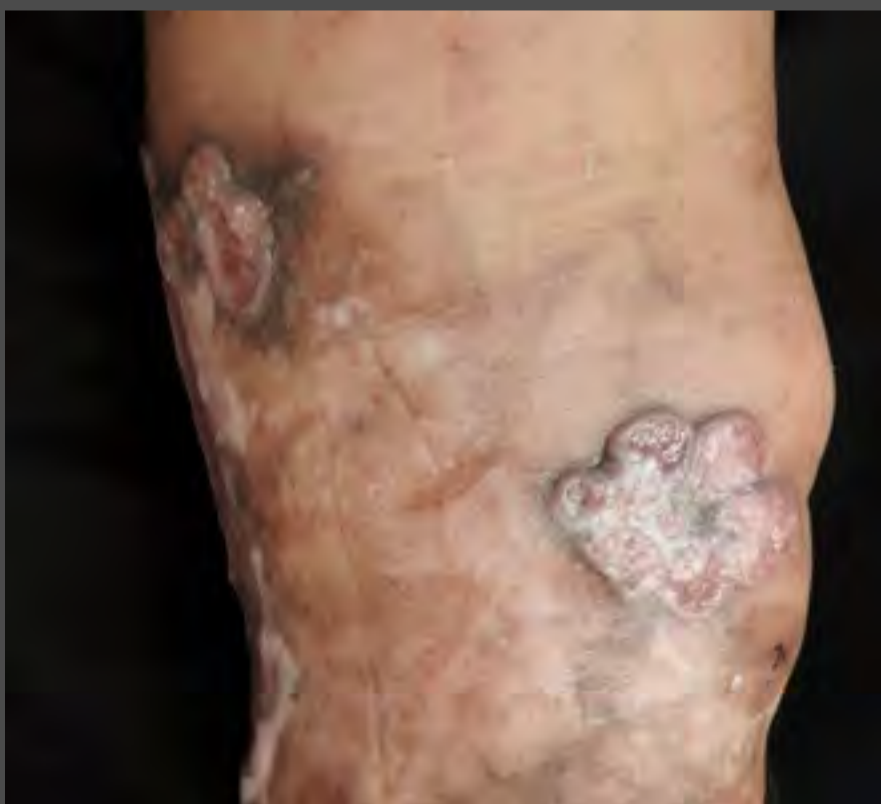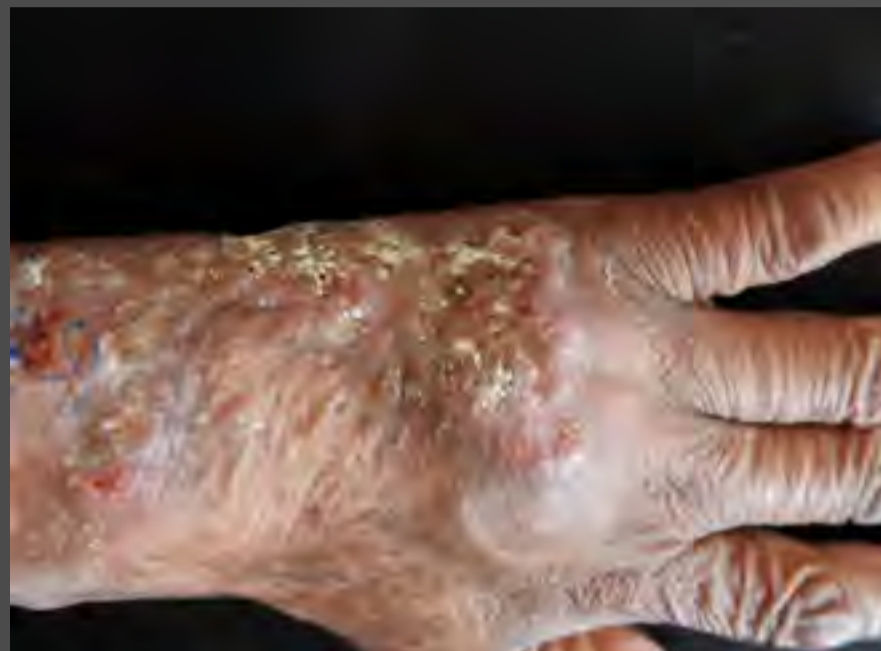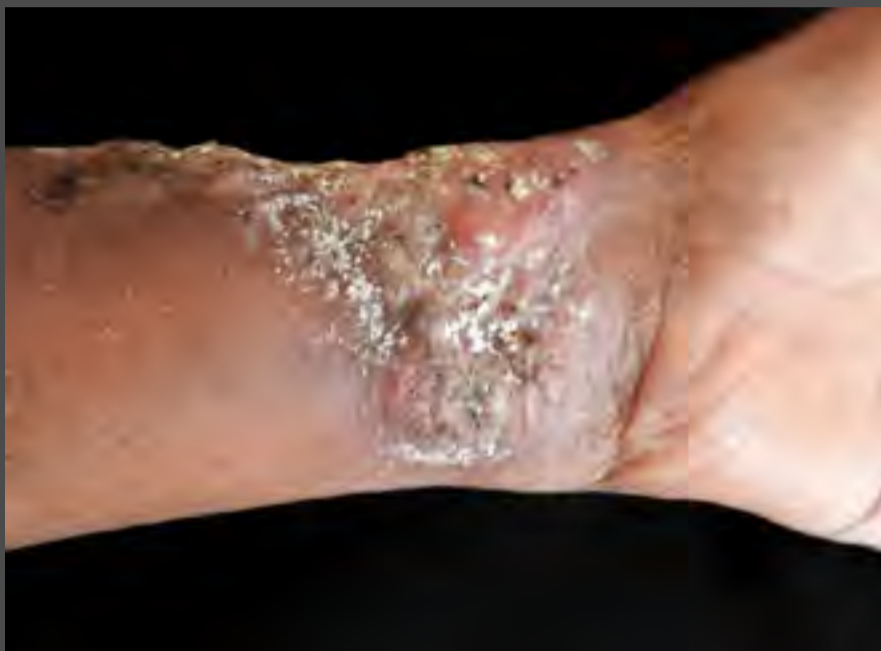Man aged 52 years with nine-year-old lesions on right leg. He was diagnosed with cutaneous leishmaniasis and received incomplete treatment with pentavalent antimonials, with partial improvement. Subsequently, with a clinical diagnosis of chromomycosis without mycological verification, he received 200 mg of itraconazole daily for six months with no improvement. Four years ago, the lesions persisted and amastigotes were visible, so he received a full treatment of pentavalent antimonials, with no improvement. Six months later, he was treated with amphotericin B deoxycholate, for a cumulative dose of 2 g, with apparent improvement. Six months later, the lesions were active and had amastigotes, so he received 150 mg of miltefosine daily for 28 days and six sessions of aerosol cryotherapy, with considerable improvement. Six months later, several active areas persisted.

## Chronic relapsing cutaneous leishmaniasis

**Figures 3.210E and F.**

The same patient in Figures 3.210A, B, C, and D. After a full course of antimonial therapy and six months of amphotericin B deoxycholate, the lesions were active and had amastigotes, so he received 150 mg of miltefosine daily for 28 days and six sessions of aerosol cryotherapy, with considerable improvement. Six months later, some active areas persisted.

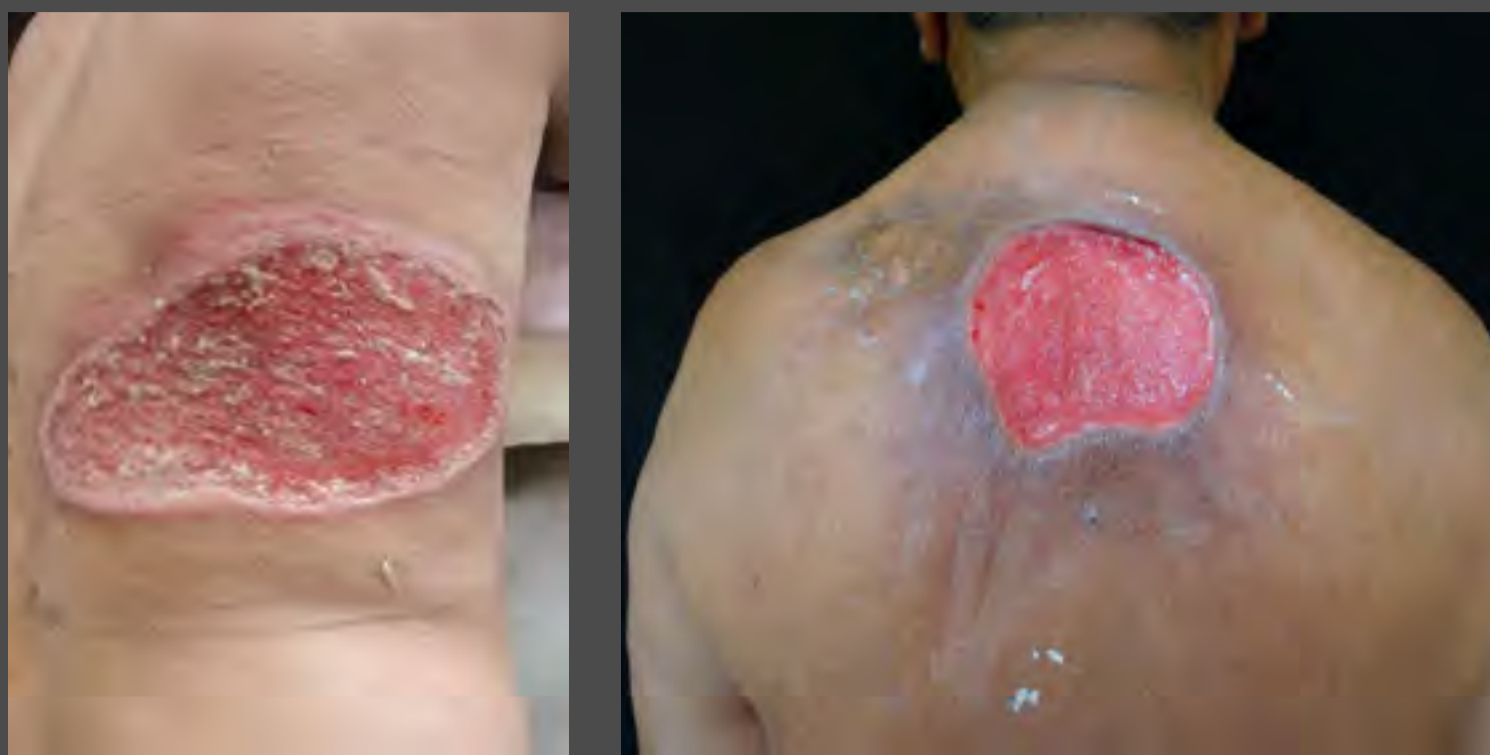## Chronic relapsing cutaneous leishmaniasis



**Figures 3.211A, B and C.**

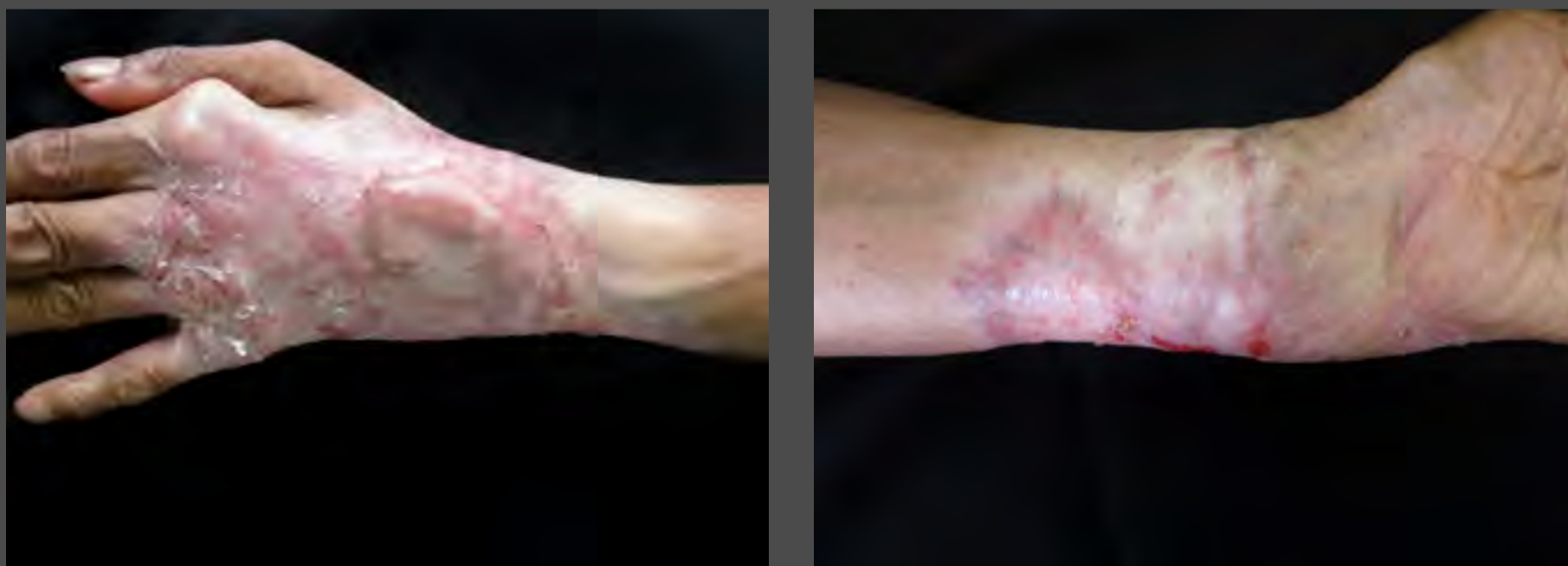Man aged 50 years with 12-year-old lesions on both arms and right thigh. He was treated with pentavalent antimonials and amphotericin B deoxycholate at unknown doses. He was also treated empirically for chromomycosis with itraconazole for four months. The lesions were erythematous, squamous, and crusted plaques, and multiple and extensive warty ulcerated plaques. The biopsy found occasional amastigotes, so he received amphotericin B deoxycholate, which was suspended due to intolerance, and then 150 mg of miltefosine daily for 28 days, with partial improvement. Given the persistence of the lesions, a new schedule of miltefosine was used, plus seven doses of 4 mg/kg of pentamidine given every other day, and six sessions of cryotherapy. He improved but follow up is pending.

### Chronic relapsing cutaneous leishmaniasis



**Figures 3.212A and B.**

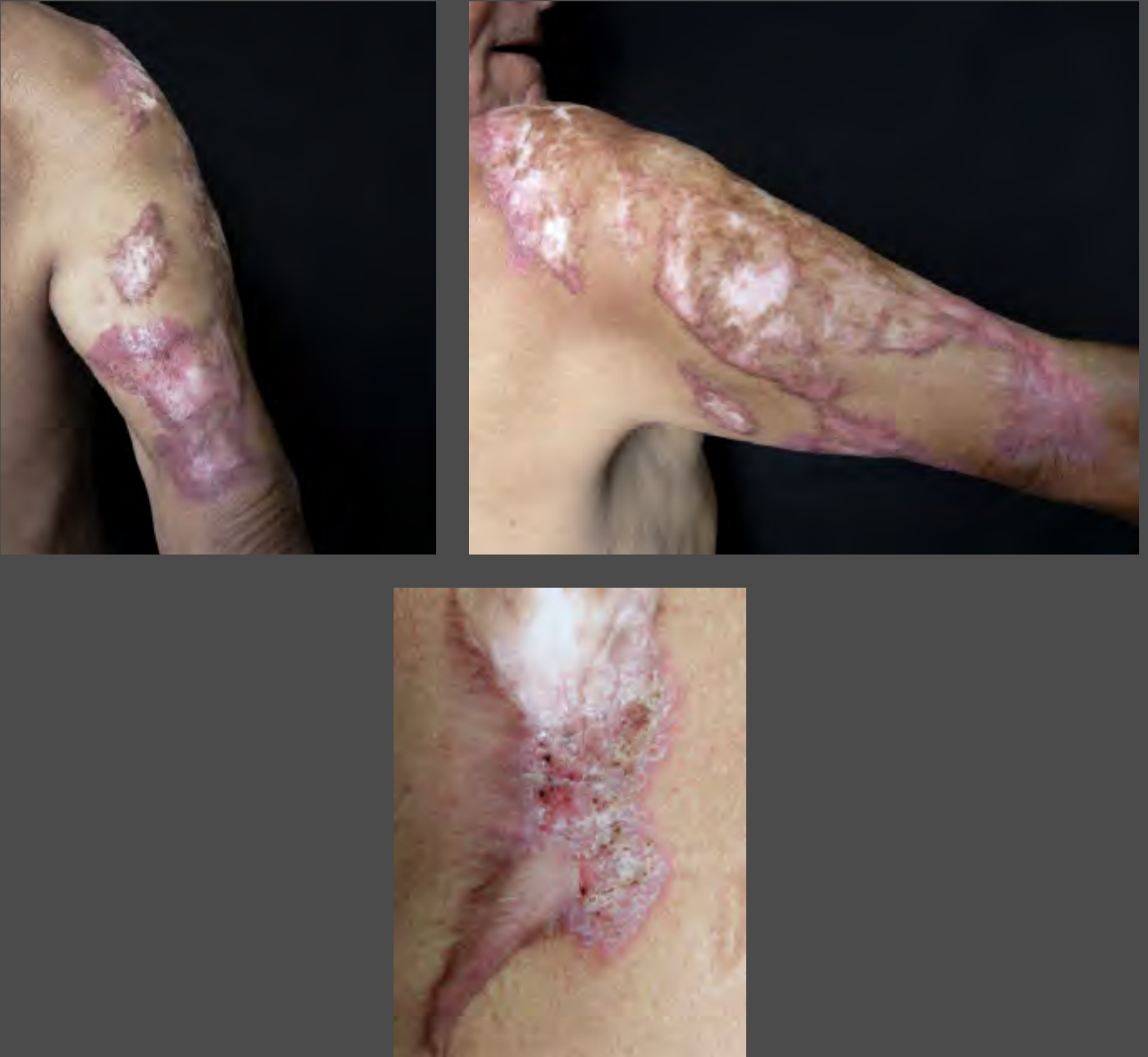Two men with parasitologically verified leishmaniasis lesions, 19 and 30 months old, respectively, that reached a size of 23 x 13 cm and 14 x 12 cm. They were treated with pentavalent antimonials, with no improvement, and then with miltefosine, with moderate improvement, but the ulcers did not heal. Finally, they received simultaneous treatment with oral miltefosine and intramuscular pentamidine, and the lesions healed five months later. They did not return for follow up.



**Figures 3.213A and B.**

Man aged 63 years with 16-year-old lesions located on the arms and trunk. He was treated for a year with ketoconazole based on an initial clinical diagnosis of chromomycosis, with no improvement. Amastigotes were observed in the biopsy, but he could not receive pentavalent antimonials due to heart disease, and therefore he received 50 mg of amphotericin B deoxycholate every other day for a total of 1.4 g, with partial improvement. Six months later, amastigotes continued to be found in the active lesions, for which he received 150 mg of miltefosine daily for 28 days, with improvement, but without cure.

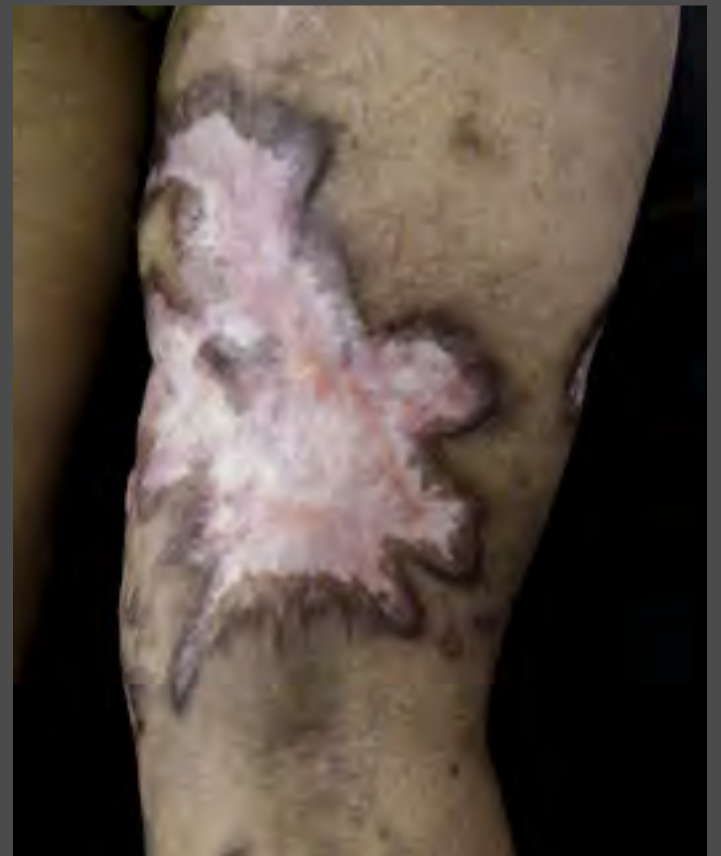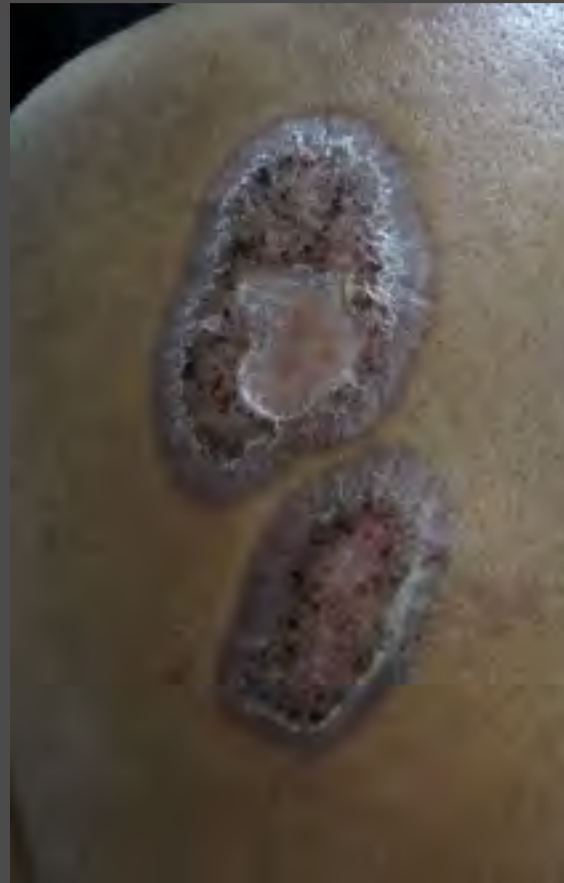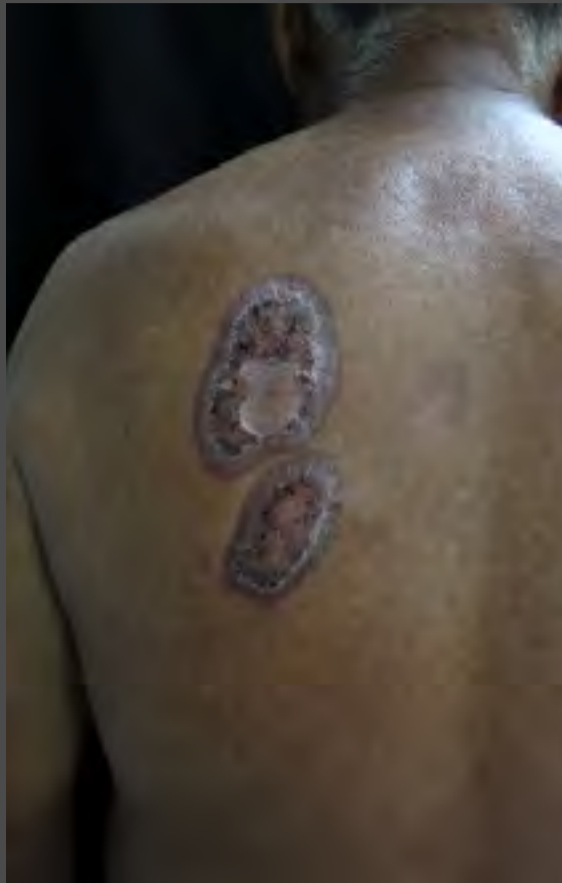## Chronic relapsing cutaneous leishmaniasis

**Figures 3.213C, D and E.**

The same patient in Figures 3.213A and B. He was treated for a year with ketoconazole according to an initial clinical diagnosis of chromomycosis, with no improvement. Amastigotes were observed in the biopsy, but he could not receive pentavalent antimonials due to heart disease, and therefore received 50 mg of amphotericin B deoxycholate every other day for a total of 1.4 g, with partial improvement. Six months later, amastigotes continued to be found in the active lesions, for which he received 150 mg of miltefosine daily for 28 days, with improvement, but without cure.

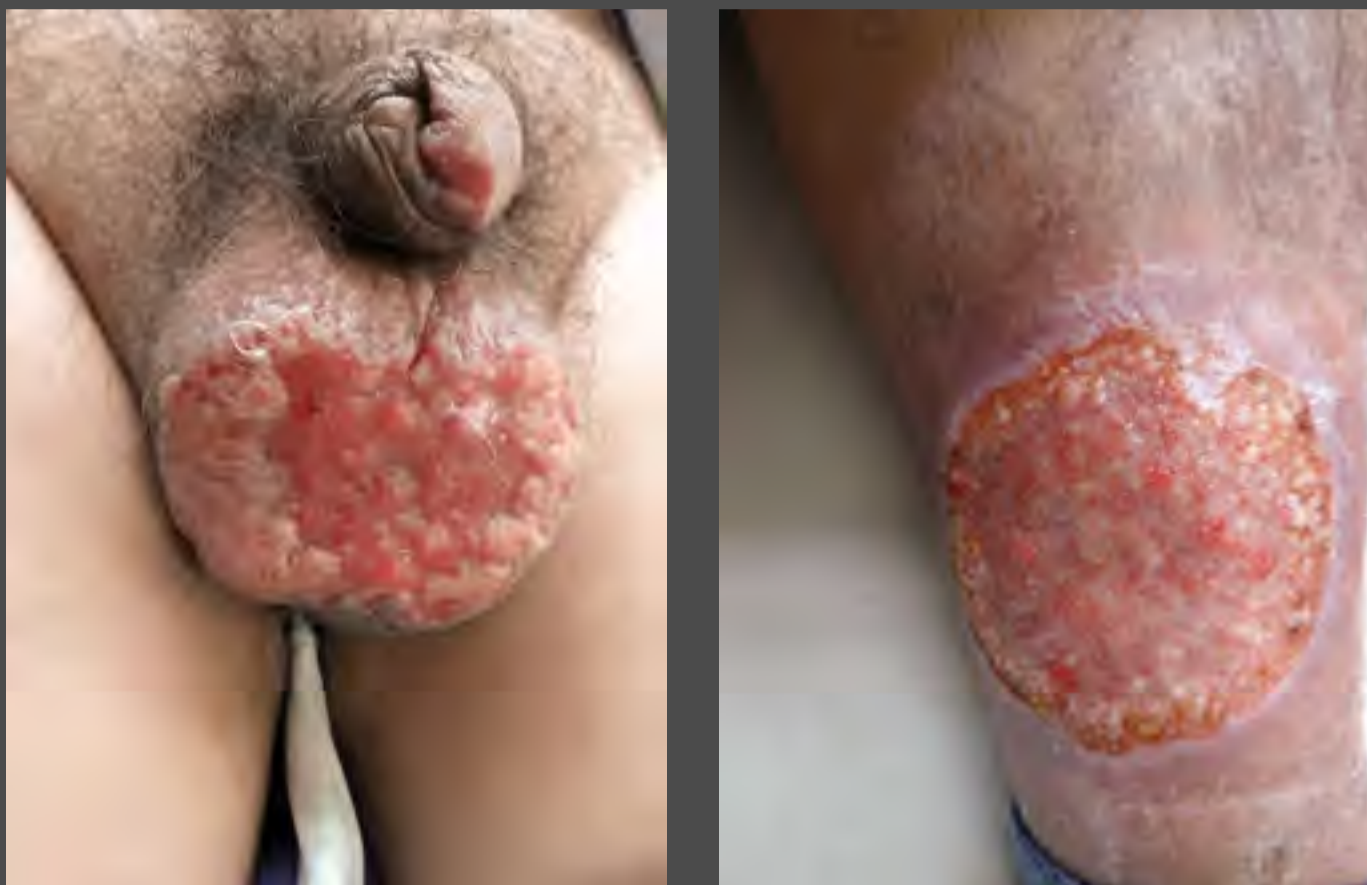

## Chronic relapsing cutaneous leishmaniasis

**Figures 3.214A, B, C and D.**

Man aged 60 years with 12-year-old infiltrated, crusted plaques on the back and knee. He received itraconazole for chromomycosis for six months, without improvement, followed by a course of amphotericin B deoxycholate totaling 1.5 g. The biopsy found a few amastigotes and fungi cultures were negative, so he was given 20 mg/kg of pentavalent antimonials daily for 20 days, with improvement. Six months later, the lesions had reactivated, so he received 7 doses of 4 mg/kg of pentamidine administered every other day, and 10 sessions of aerosol cryotherapy, with considerable improvement. Three months later, there was reactivation.

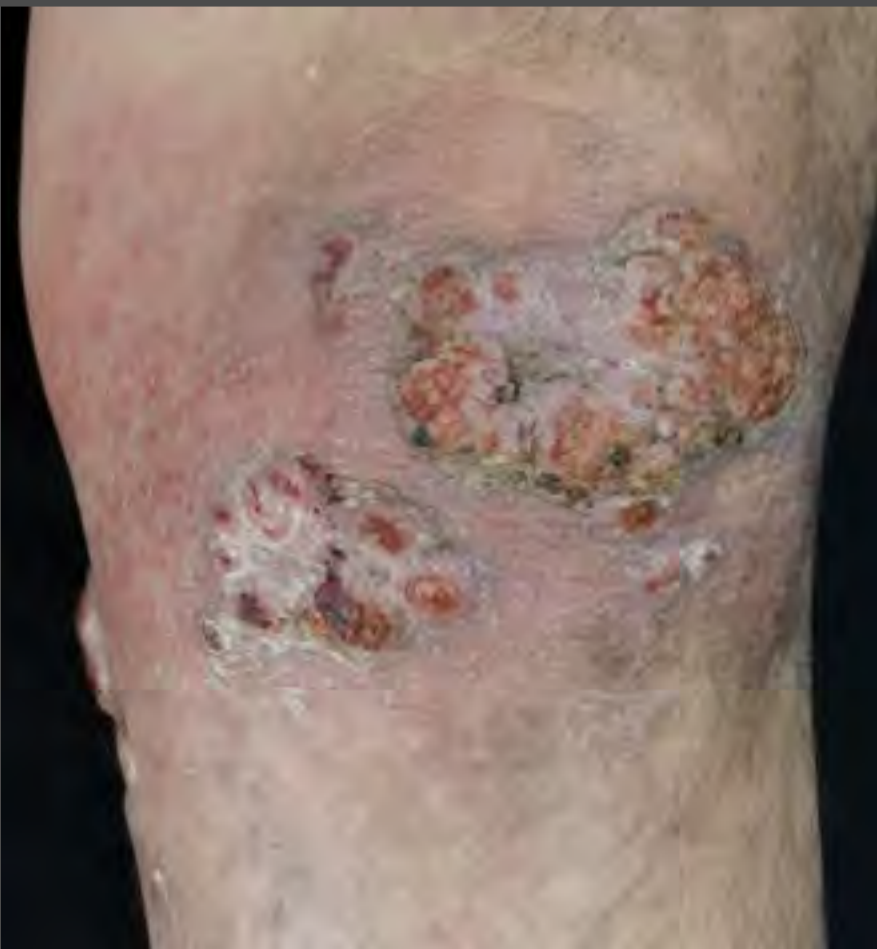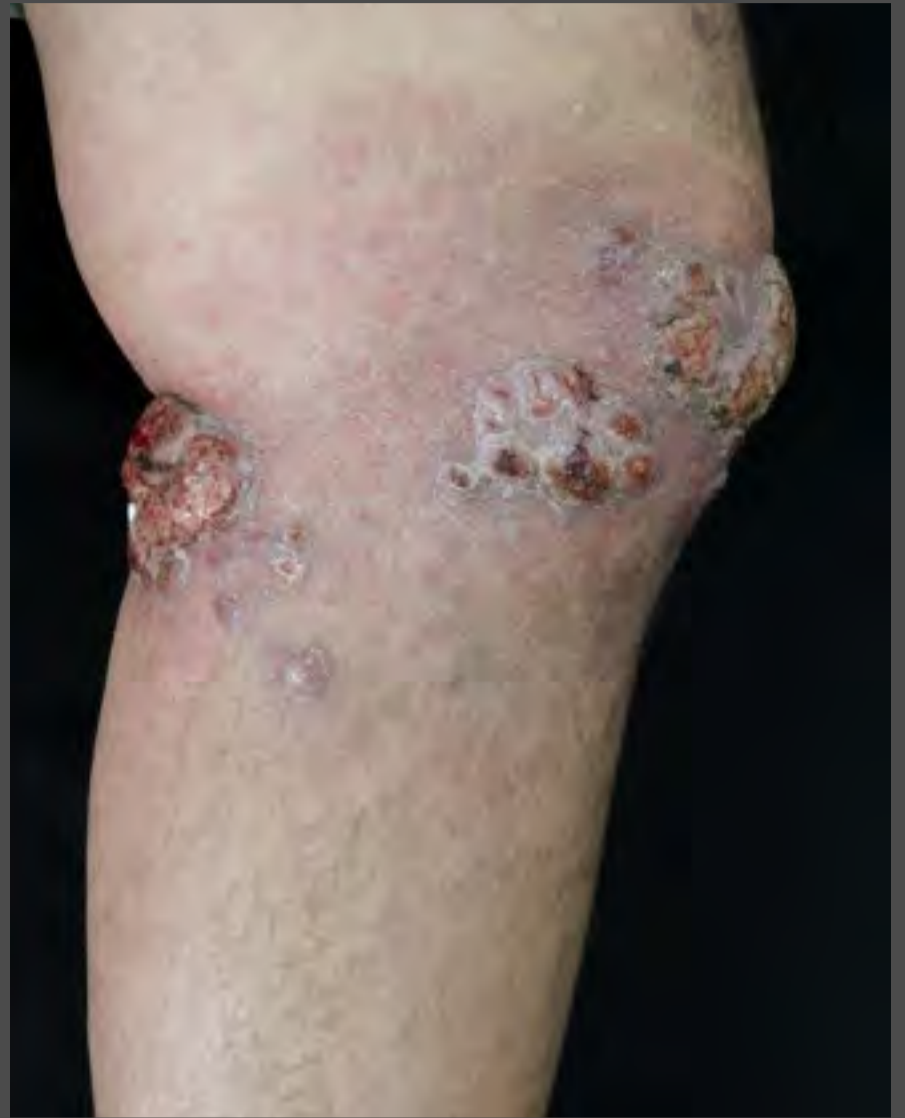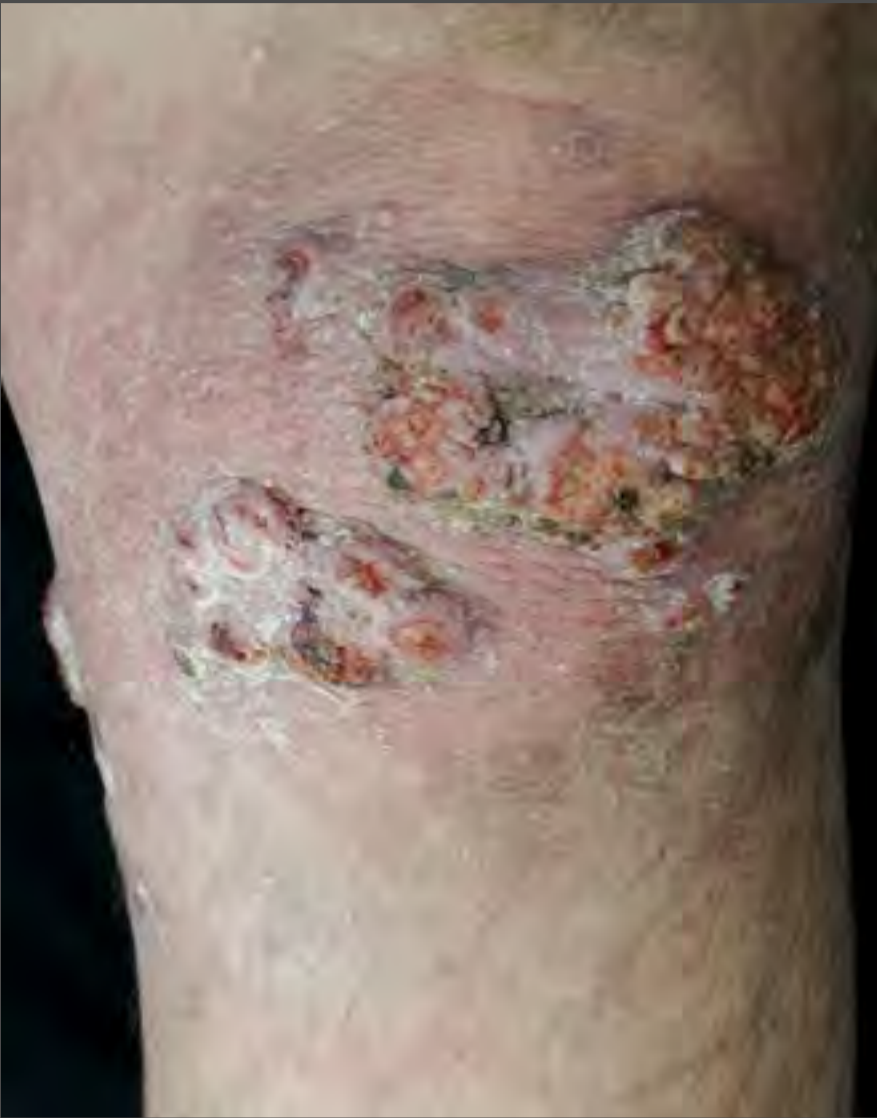## Chronic relapsing cutaneous leishmaniasis



**Figures 3.215A and B.**

Man aged 68 years with a 30-month-old ulcer on the leg 12 cm in diameter, a three-month old ulcer of 7 cm on the scrotum, and a small ulcer on the foreskin. Amastigotes were found on examination of the leg and scrotum. He received 20 mg/kg of pentavalent antimonials daily for 20 days; the genital lesions improved, but the one on the leg did not. Four months later, the lesions continued to be active and positive for amastigotes, so he was administered 150 mg of miltefosine daily for 28 days; the genital lesions healed but the one on the leg persisted three months later, so he was treated with 12 doses of liposomal amphotericin B at 3 mg/kg daily. The lesion improved but had not cured.

## Chronic relapsing cutaneous leishmaniasis



**Figures 3.216A, B and C.**

Man aged 33 years with 17-year-old cutaneous leishmaniasis, for which he had received 20 mg/kg of pentavalent antimonials daily for 20 days, with two 3-day interruptions due to injection site pain. The ulcer healed and, 11 years later, warty plaques appeared next to the scar, which extended across the knee toward the popliteal fossa. He received pentavalent antimonials again, but the lesions did not change, so he was treated with 150 mg of miltefosine daily for 28 days. There was partial, transient improvement, and five months later he deteriorated, so he was treated with 4 mg/kg of pentamidine in 7 doses given every other day, 150 mg of miltefosine daily for 28 days, and 7 sessions of aerosol cryotherapy, with clear improvement. Follow up is pending.

Lesions develop over months or years, and simultaneously affect several body segments where ulcers, warty plaques, nodules, scars, and areas of healthy skin coexist. There can be cutaneous and mucosal lesions at the same time. Numerous or no amastigotes may be found, a skin test reaction may be intense or negative. In evaluating the immune response, lower production of interferon gamma (IFN- $\gamma$ ) and tumor necrosis factor (TNF) is found, as well as greater concentrations of interleukin 10 (IL-10) and 17 (IL-17) produced by peripheral blood cells, compared to patients with localized cutaneous leishmaniasis. Most of these patients have already received one or more courses of treatment with pentavalent antimonials or amphotericin B.

Response to conventional treatments is also variable, although partial improvement without complete cure is frequent, after one to six months, the lesions reactivate. Management of these patients is very difficult and, as a result, they should be referred to specialized services for treatment, which should include at least two specific drugs for leishmaniasis.

# Differential Diagnosis



Jaime Soto, Carlos Arturo Hernández,  
Ana Nilce Silveira Maia-Elkhoury,  
Gerzaín Rodríguez, Clemencia  
Ovalle-Bracho, Claudia Arenas and  
Carolina Camargo

Numerous diseases with ulcers can resemble cutaneous leishmaniasis. Cutaneous ulcers may be most frequently confused clinically with those caused by common bacteria, mycobacteria, deep mycoses, tumors, traumas, and vascular insufficiency of the legs.

The following is a summary of the main differential diagnosis of cutaneous leishmaniasis, with characteristics of the lesions (*Table 3.4*) and useful paraclinical examinations for confirming these diagnosis (*Table 3.5*). They are listed in three different groups: infections, inflammatory and reactive diseases, and malignancies. A short, detailed description of each of them is included.

Table 3.4. Diseases for cutaneous leishmaniasis differential diagnosis by clinical characteristics of the lesions

	Diseases	Ulcer	Papule	Plaque	Nodule	Verruca	Tumor	Lymphangitis	Scar
Infections	Pyogenous ulcer	x							
	Furunculosis		x		x				
	Syphilis	x		x					
	Atypical mycobacteria	x		x	x	x			
	Cutaneous tuberculosis	x	x	x		x			
	Leprosy		x						
	Chromomycosis			x	x	x			x
	Sporotrichosis	x	x	x	x	x		x	
	Histoplasmosis	x	x	x	x				
	Lobomycosis		x	x	x				
	Paracoccidioidomycosis	x	x	x	x				
	Ecthyma	x		x					
	Impetigo			x					

	Diseases	Ulcer	Papule	Plaque	Nodule	Verruca	Tumor	Lymphangitis	Scar
Inflammatory Reactive	Venous ulcer	x							
	Arterial ulcer	x							
	Mixed ulcer	x							
	Diabetic ulcer	x							
	Discoid lupus		x	x		x			
	Psoriasis			x					
	Dermal necrosis	x		x					
	Sickle cell anemia	x							x
	Traumatic ulcer	x							
	Insect bites	x	x	x					x
	Pyoderma gangrenosum	x	x	x					x
	Sarcoidosis	x	x	x					
	Banal ulcer	x						x	
	Granuloma faciale		x	x	x				



	Diseases	Ulcer	Papule	Plaque	Nodule	Verruca	Tumor	Lymphangitis	Scar
Tumors	Basal cell carcinoma	x	x	x		x	x		x
	Squamous cell carcinoma	x	x	x		x	x		x
	Keratoacanthoma	x	x				x		
	Cutaneous lymphoma	x	x	x			x		
	Lymphocytoma cutis		x	x					

Table 3.5. Diseases for differential diagnosis of cutaneous leishmaniasis and respective paraclinical examinations to confirm diagnosis

	Diseases	Giemsa/Gram Direct Smear	KOH	Z-N	Mycological Culture	Bacteriological Culture	Mycobacteria Culture	Parasitological Culture	Biopsy	Serology	Skin Test	Images
Infections	Pyogenous ulcer*	1				2			3			
	Furunculosis*	2				1						
	Syphilis								2	1		
	Atypical mycobacteria											
	Cutaneous tuberculosis			1			5		3		2	4
	Leprosy			2					1			
	Chromomycosis		1		2				3			
	Sporotrichosis				1				2		3	
	Histoplasmosis				1				3	2		4
	Lobomycosis		1						2			
	Paracoccidioidomycosis		1		3				2	4	5	6
	Ecthyma*	1					2					
	Impetigo*	1										

\* In these diseases, history and clinical examination may be sufficient to make the diagnosis.

Note: The numerical order in the table indicates the priority for requesting tests when there is no conclusive diagnosis.

	Diseases	Giemsa/Gram Direct Smear	KOH	Z-N	Mycological Culture	Bacteriological Culture	Mycobacteria Culture	Parasitological Culture	Biopsy	Serology	Skin Test	Images
Inflammatory - Reactive	Venous ulcer*											1
	Arterial ulcer*											1
	Mixed ulcer*											
	Diabetic ulcer*											
	Discoid lupus								1			
	Psoriasis*								1			
	Dermal necrosis											
	Sickle cell anemia											
	Traumatic ulcer*											
	Insect bites*								1			
	Pyoderma gangrenosum								1			
	Sarcoidosis								1			
	Banal ulcer*											
	Granuloma faciale								1			

\* In these diseases, history and clinical examination may be sufficient to make the diagnosis.

Note: The numerical order in the table indicates the priority for requesting tests when there is no conclusive diagnosis.

	Diseases	Giemsa/Gram Direct Smear	KOH	Z-N	Mycological Culture	Bacteriological Culture	Mycobacteria Culture	Parasitological Culture	Biopsy	Serology	Skin Test	Images
Tumors	Basal cell carcinoma								1			
	Squamous cell carcinoma								1			
	Keratoacanthoma								1			
	Cutaneous lymphoma								1			
	Lymphocytoma cutis								1			

\* In these diseases, history and clinical examination may be sufficient to make the diagnosis.

Note: The numerical order in the table indicates the priority for requesting tests when there is no conclusive diagnosis.

## Infections

Bacterial and fungal infections are the most frequent differential diagnosis for cutaneous leishmaniasis.

***Pyogenous bacterial ulcers.*** This is a frequent clinical differential diagnosis for cutaneous leishmaniasis. These ulcers may occur as a complication of mosquito bites or of open wounds of any etiology. They can be any size and shape, single or multiple, and be located on any area of the body, but they always present purulent discharge and acute or subacute signs of inflammation, that is, swelling, redness, and warmth (*Figures 3.217 to 3.222*).

***Ecthyma.*** This disease is frequent in children and the elderly or in people with diabetes, immunosuppression, malnutrition, or neglect. It begins as pustules on the skin's surface that rapidly deepen into the middle dermis and form irregular, usually multiple, cutaneous ulcers that are 0.5 to 3 cm in diameter, covered by hard adherent crusts, primarily on the legs. They tend to leave irregular scars when they heal.

***Impetigo.*** Some forms of leishmaniasis that do not develop into open ulcers form erythematous plaques, covered by scales and crusts, that resemble impetigo vulgaris, a superficial skin infection caused by streptococci. However, impetigo develops rapidly and lasts a short time as it resolves with removal of the crusts and local antibiotic therapy.

## Bacterial ulcers

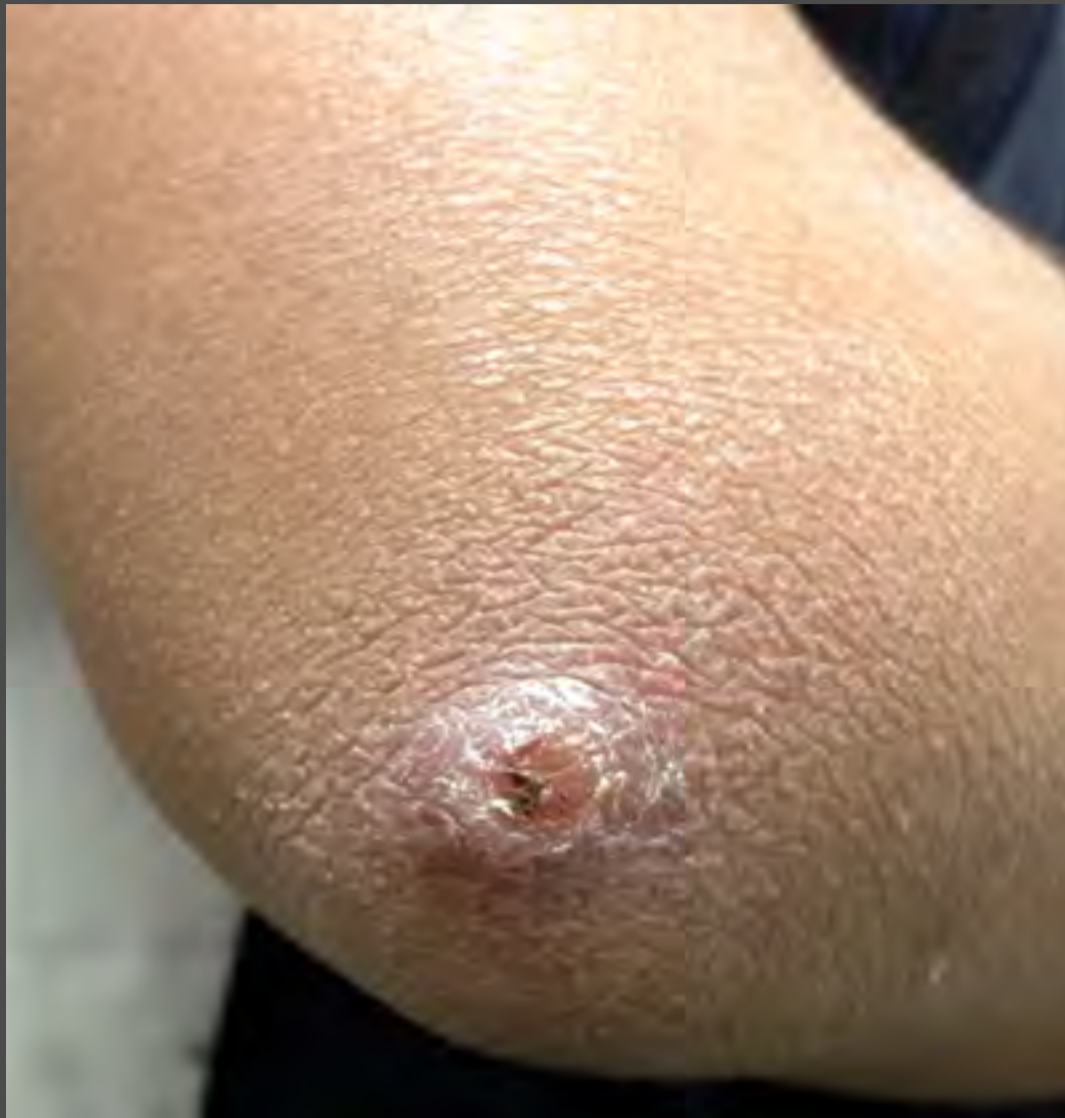
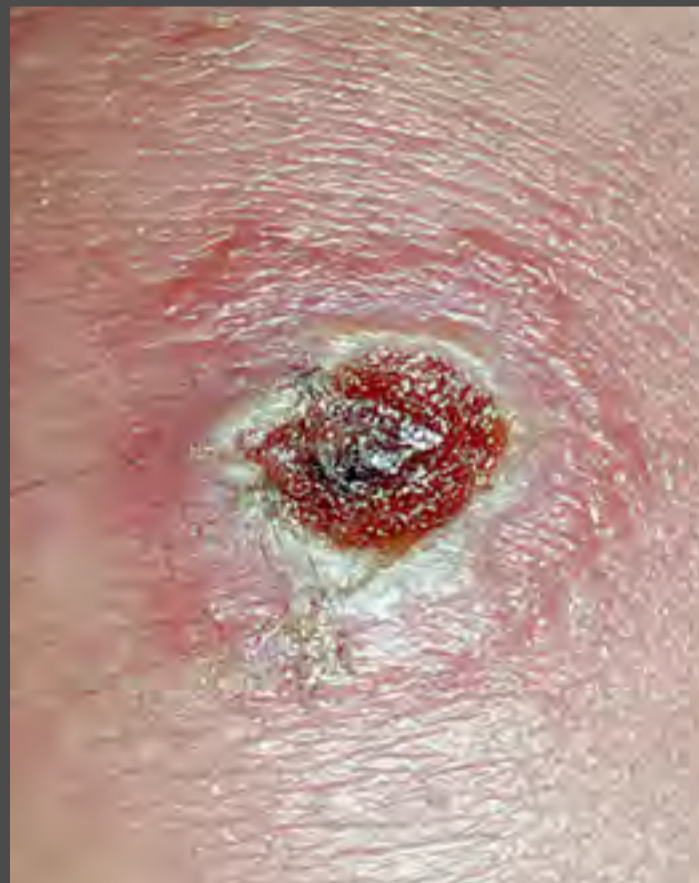
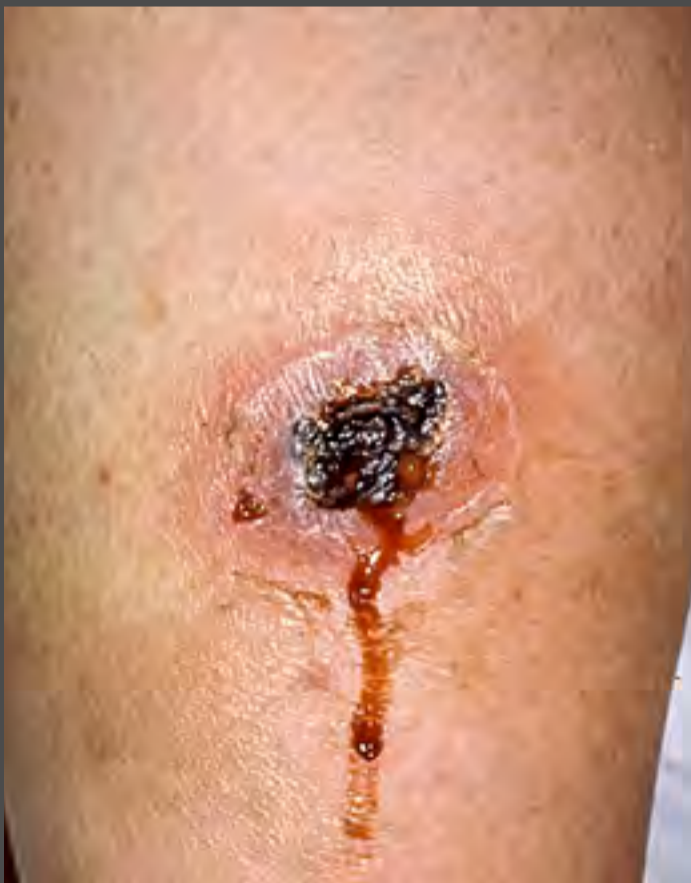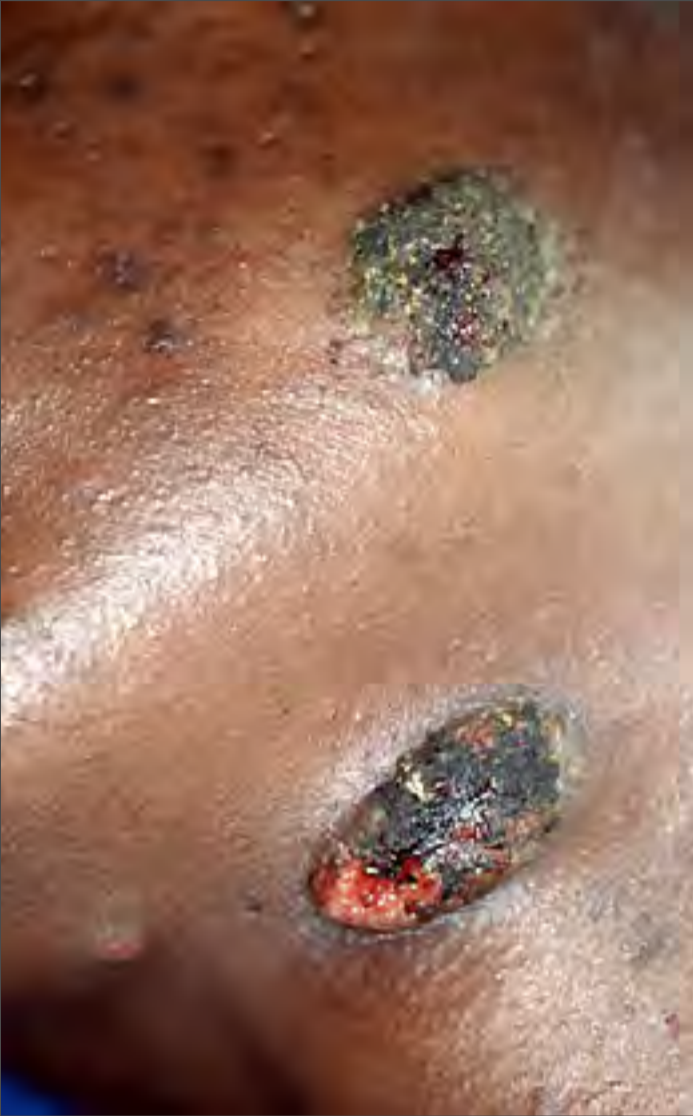Figure 3.217A.  
Ulcerated papule  
of the elbow



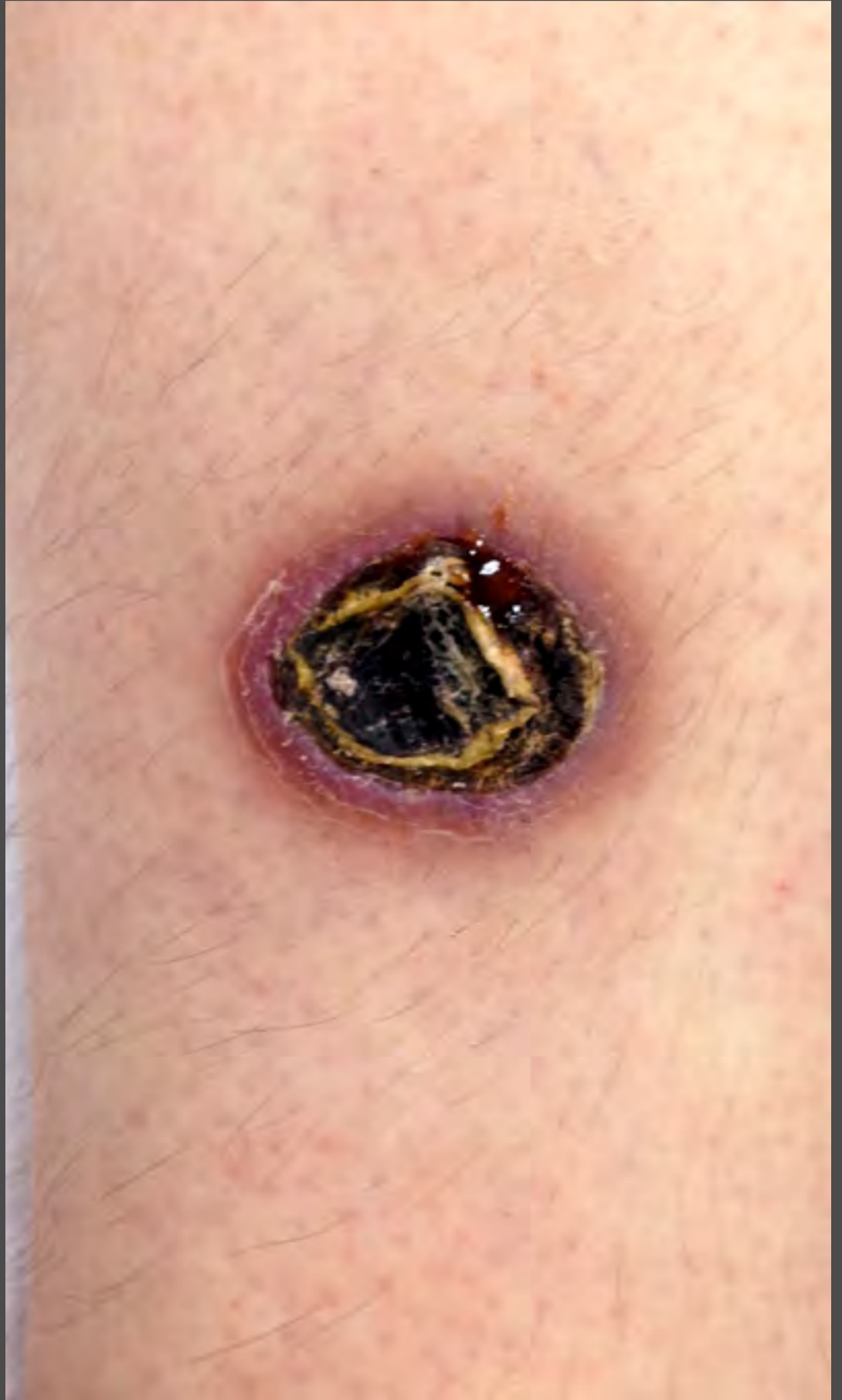Figures 3.217B and C.

Ulcers with irregular edges and necrotic floor, with bloody purulent or frankly purulent discharge, surrounded by erythematous skin

## Bacterial ulcers

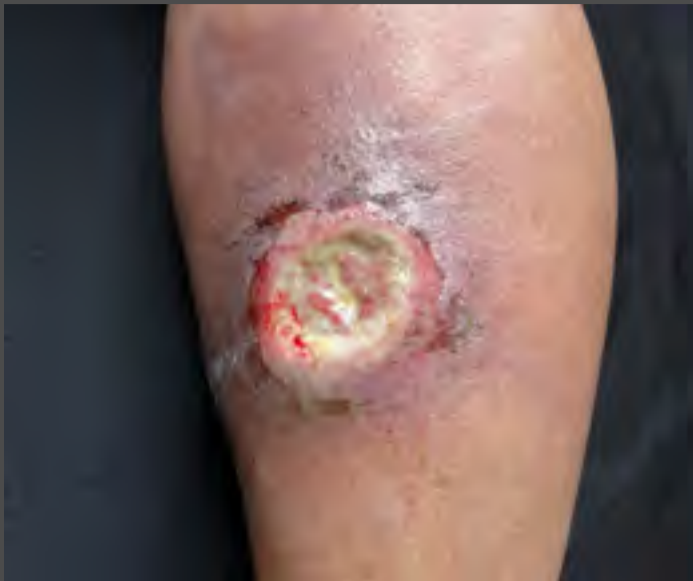

**Figure 3.217D.**  
Ulcers secondary to insect bites in a leishmaniasis endemic area

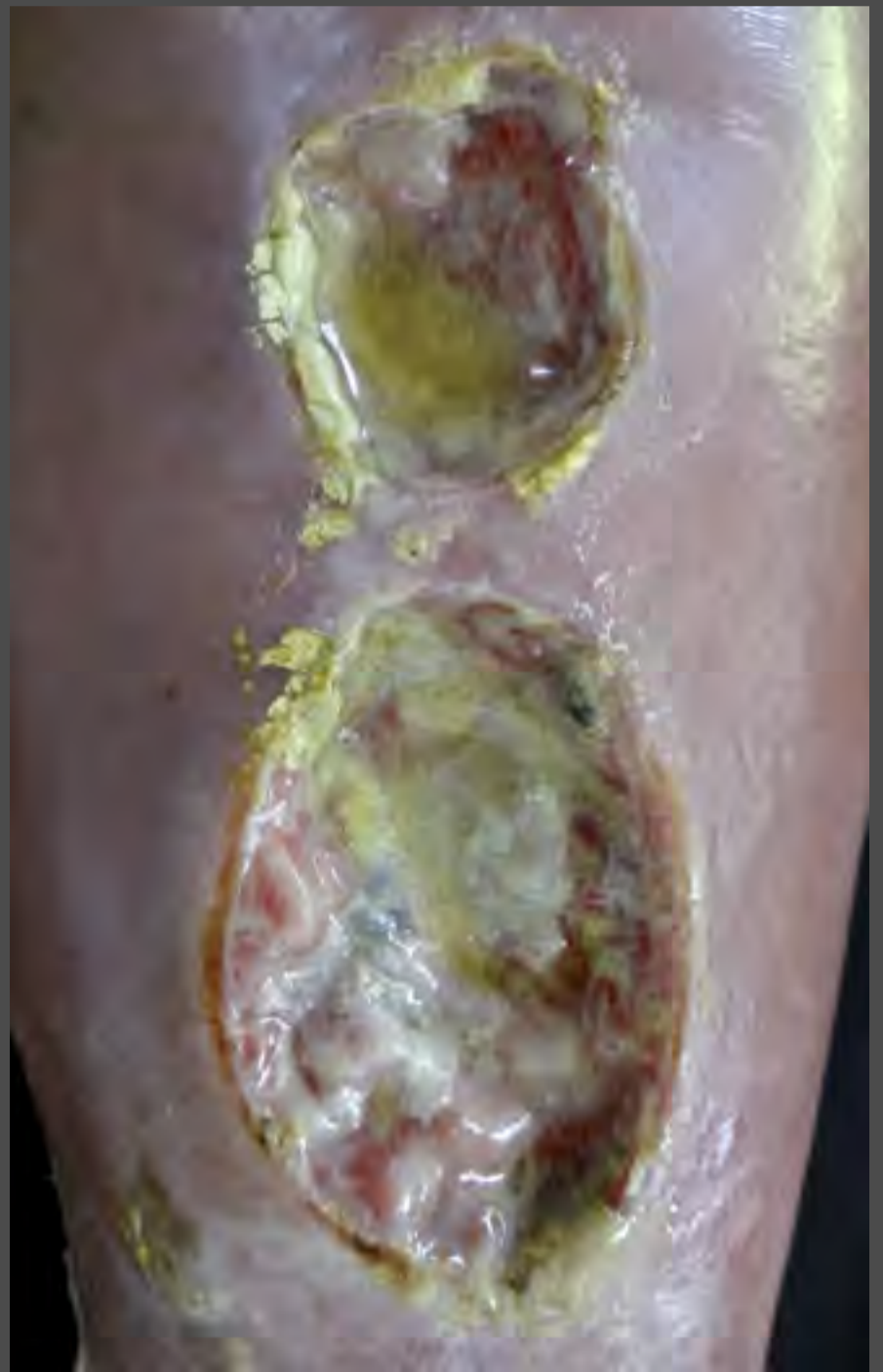
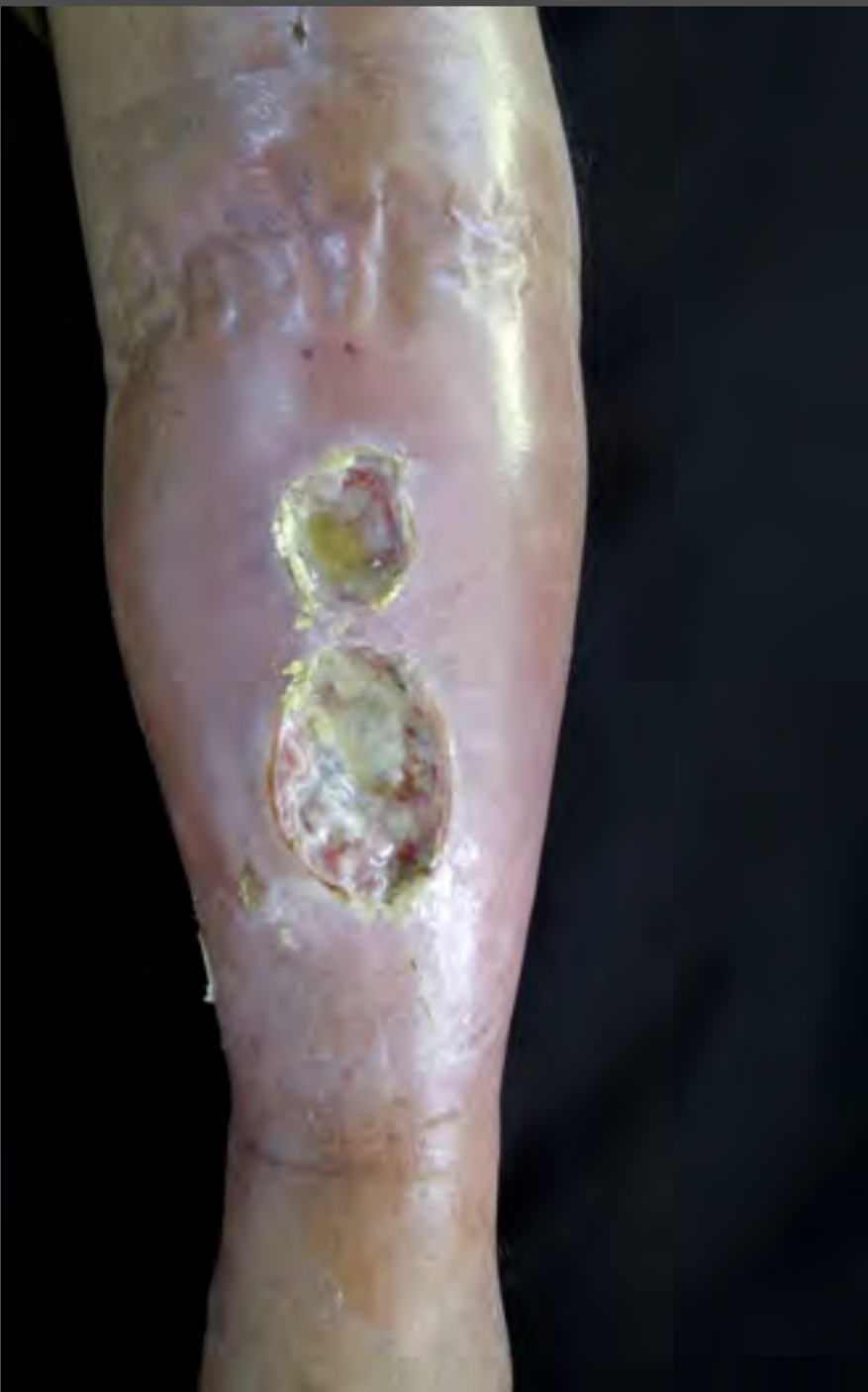
**Figure 3.217E.**  
Hemorrhagic ulcer with irregular edge and necrotic floor, surrounded by erythematous skin

## Bacterial ulcers

**Figure 3.218.**

Ecthyma gangrenosum. Dirty, purulent ulcer, with fibrinous, pyogenous membranes and an irregular border, surrounded by an inflamed, erythematous, and hyperpigmented area

**Figures 3.219A and B.**

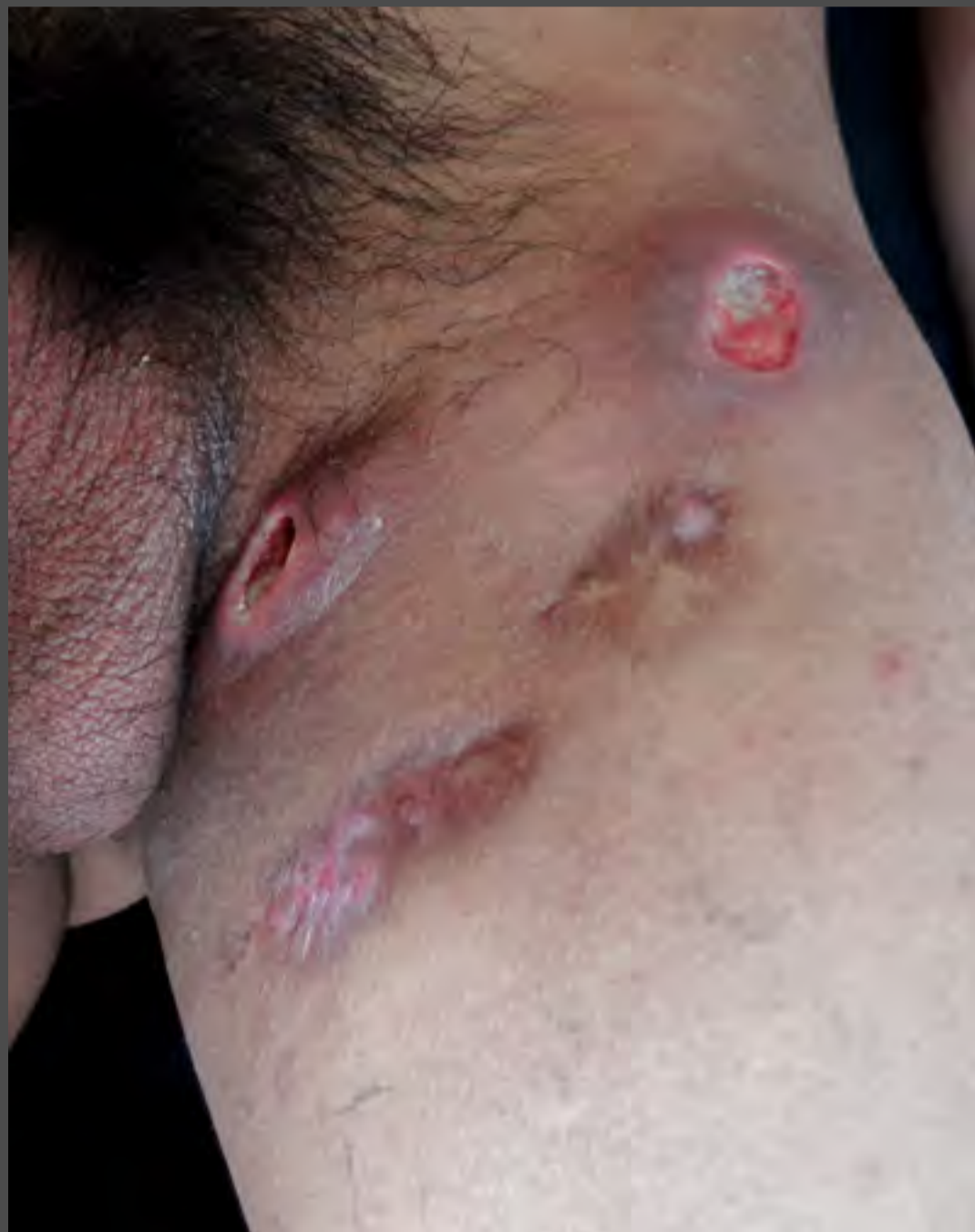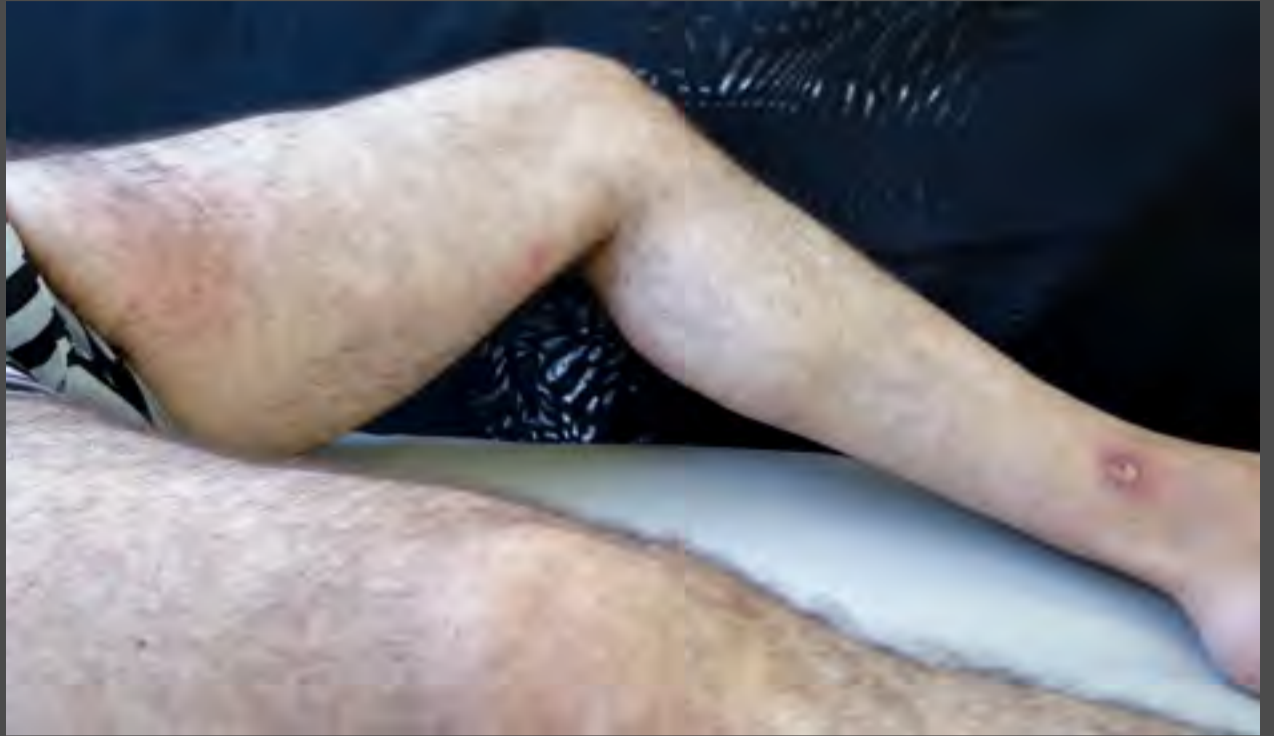Traumatic ulcer with cellulitis. One day after direct blunt trauma that left a small erosion on the anterior aspect of the leg, erythema, edema, and local heat occurred. In a few days, a serious, acute, suppurative inflammatory process with deep, wide-spread cellulitis had affected the entire leg and two ulcers had formed.



## Bacterial ulcers

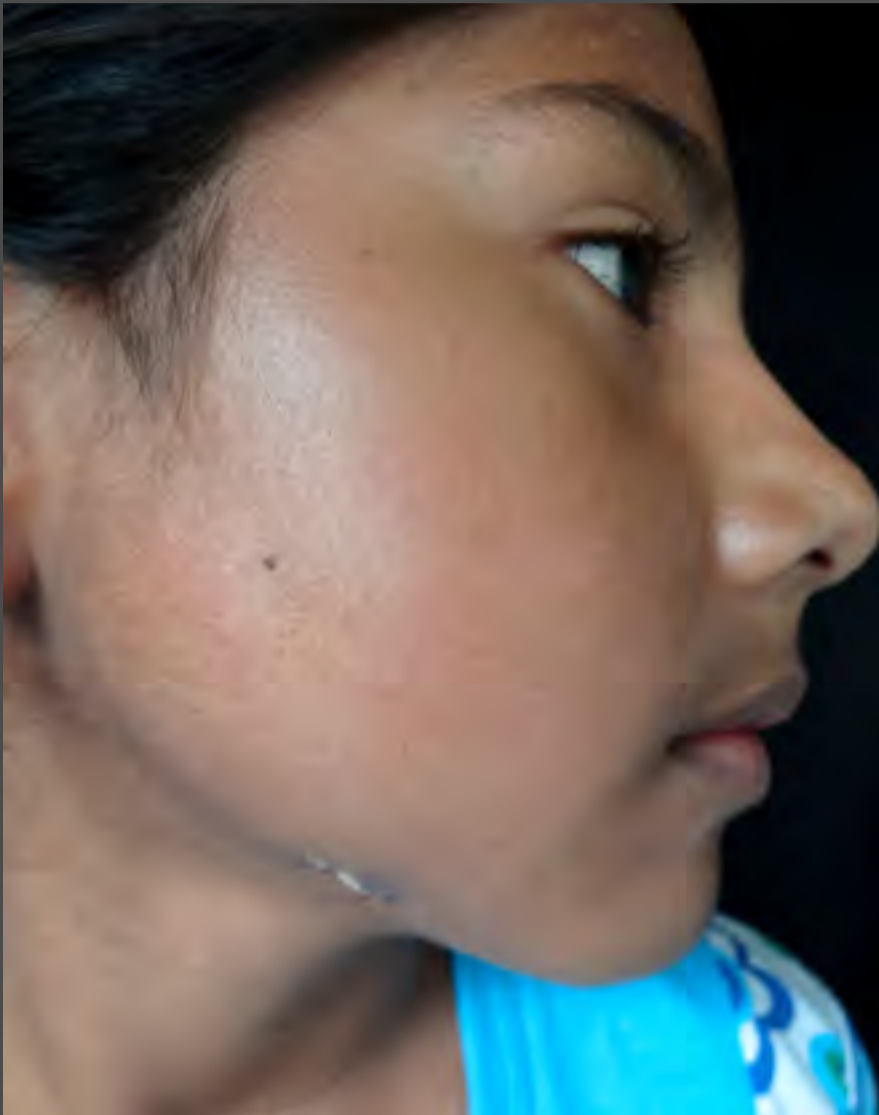**Figure 3.220.**

Traumatic ulcer with superinfection and lymphangitis. Three days after a puncture wound, a papule developed that progressed to a nodule, and then ulcerated and drained abundant purulent material. Edematous erythematous macules and plaques can be seen in some areas, on a palpable, warm pathway reaching the groin.

**Figure 3.221.**

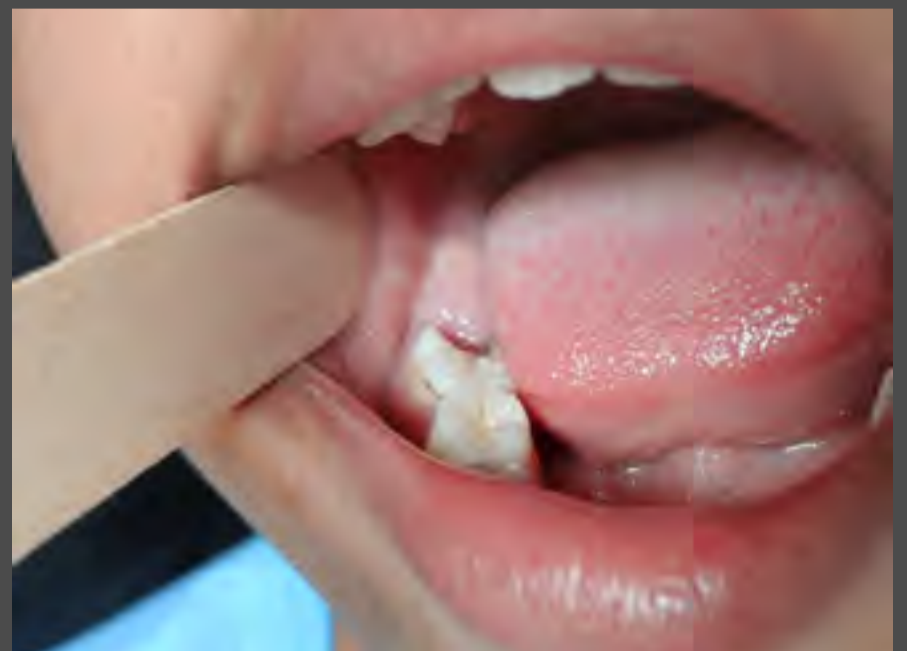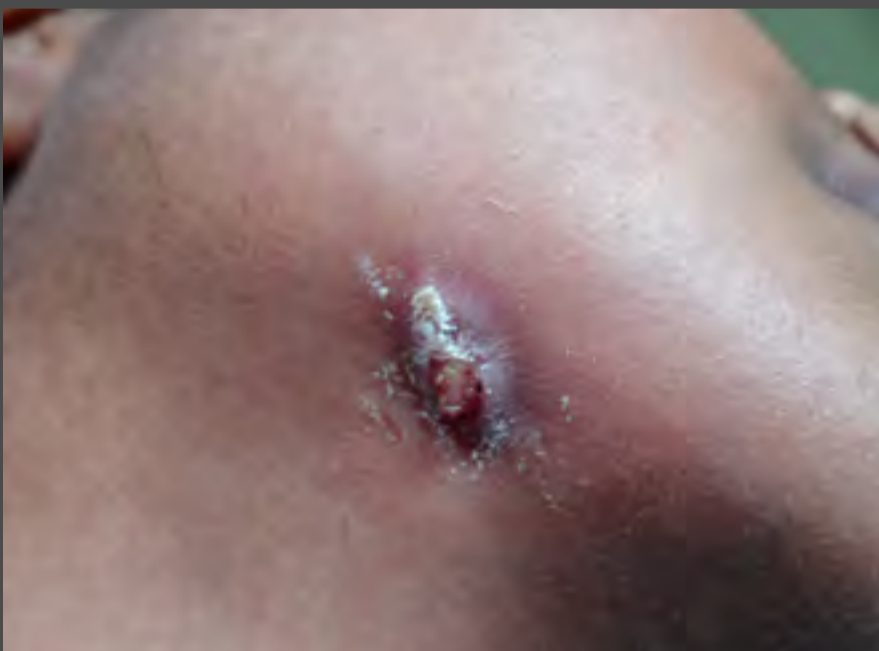Inguinal granuloma. Three months earlier, the patient presented with slightly painful “swollen glands” in the left inguinal region, which progressed and ulcerated with production of a small amount of purulent material. He had had promiscuous sexual relations five weeks earlier.

## Bacterial ulcers



**Figures 3.222A, B and C.**

Dental fistula. Girl aged 13 years with a three-month-old ulcerated plaque under the mandibular arch with signs of inflammation, which felt adhered to the deep planes. On examination of the oral cavity, a molar was found to be in poor condition, with caries.

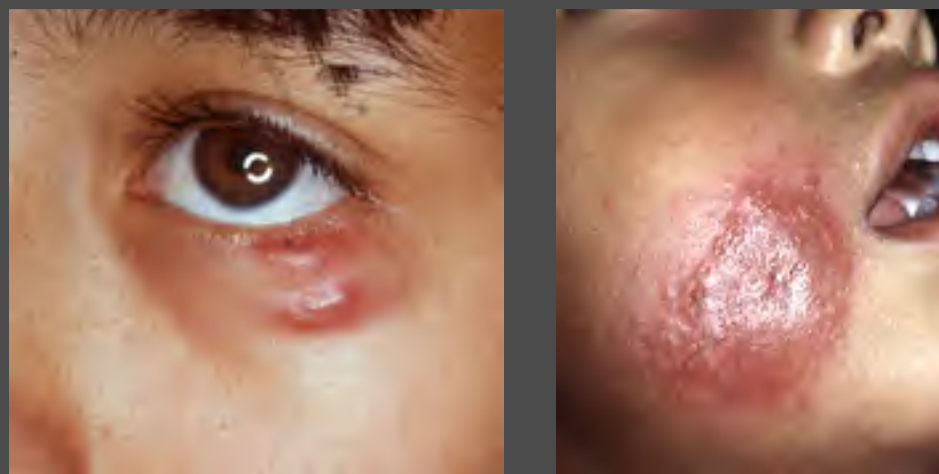

***Furunculosis.*** Furunculosis (boils) and furuncular myiasis can resemble the appearance of initial cutaneous leishmaniasis that has become superinfected, which is why there is erythema, edema, perilesional infiltration, and purulent discharge. In general, the course lasts days or a few weeks; the ulcerated area is a few millimeters and resolves rapidly with specific therapy. In myiasis, the larva can also be seen and extracted.

***Primary syphilis.*** An ulcer located on the glans, foreskin, or scrotum might be from leishmaniasis if the patient has been in an endemic area in the past three months. Although leishmaniasis lesions on body areas habitually covered by clothing are rare, at times the patient exposes these areas during urination or defecation. Clinically, they can be quite similar, but healing in a few weeks, even without antibiotic treatment, is more characteristic of syphilis.

***Nontuberculous mycobacteria.*** These fast-growing environmental mycobacteria penetrate the skin through trauma, including accidents, surgery, and, especially, through mesotherapy and contact with polluted water. It is usually asymptomatic, although it can be painful. It produces papules, plaques, nodules, and abscesses that ulcerate and form sinuses that drain purulent material (*Figures 3.223 to 3.227*). A history of trauma, aesthetic or medical procedures, or immersion in water guide the diagnosis. Ziehl-Neelsen stain can detect the acid-fast forms, however, culture is required to properly identify the germ.

## Atypical mycobacteria



Figures 3.223A and B.

These two children have erythematous plaques and papules that were diagnosed as leishmaniasis. The review of the biopsies and cultures found that they were produced by *Mycobacterium chelonae*.

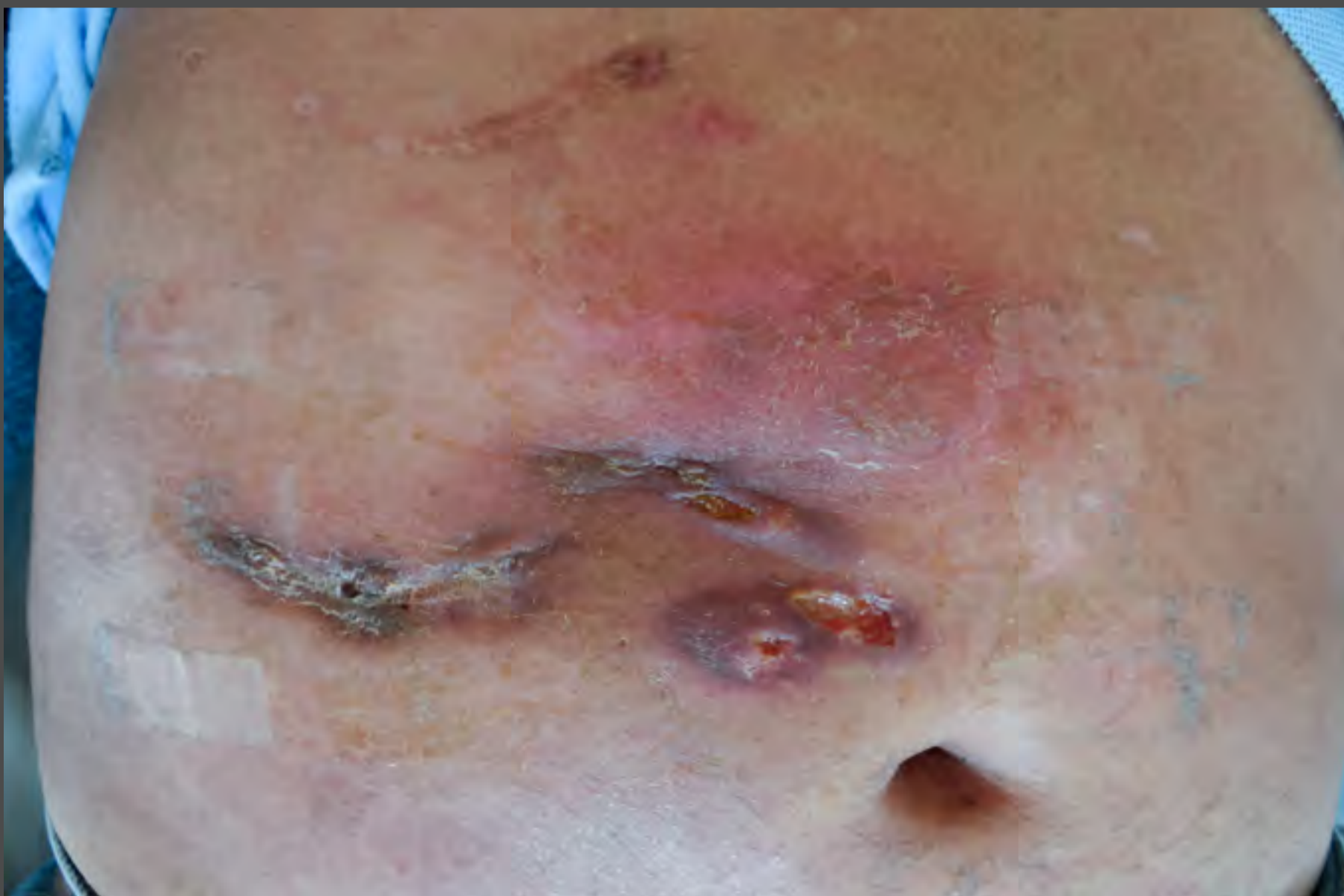
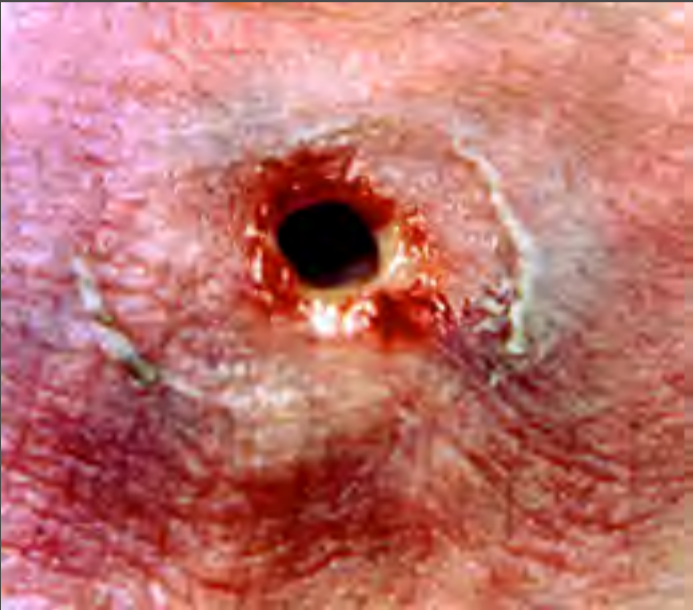
Figure 3.224.

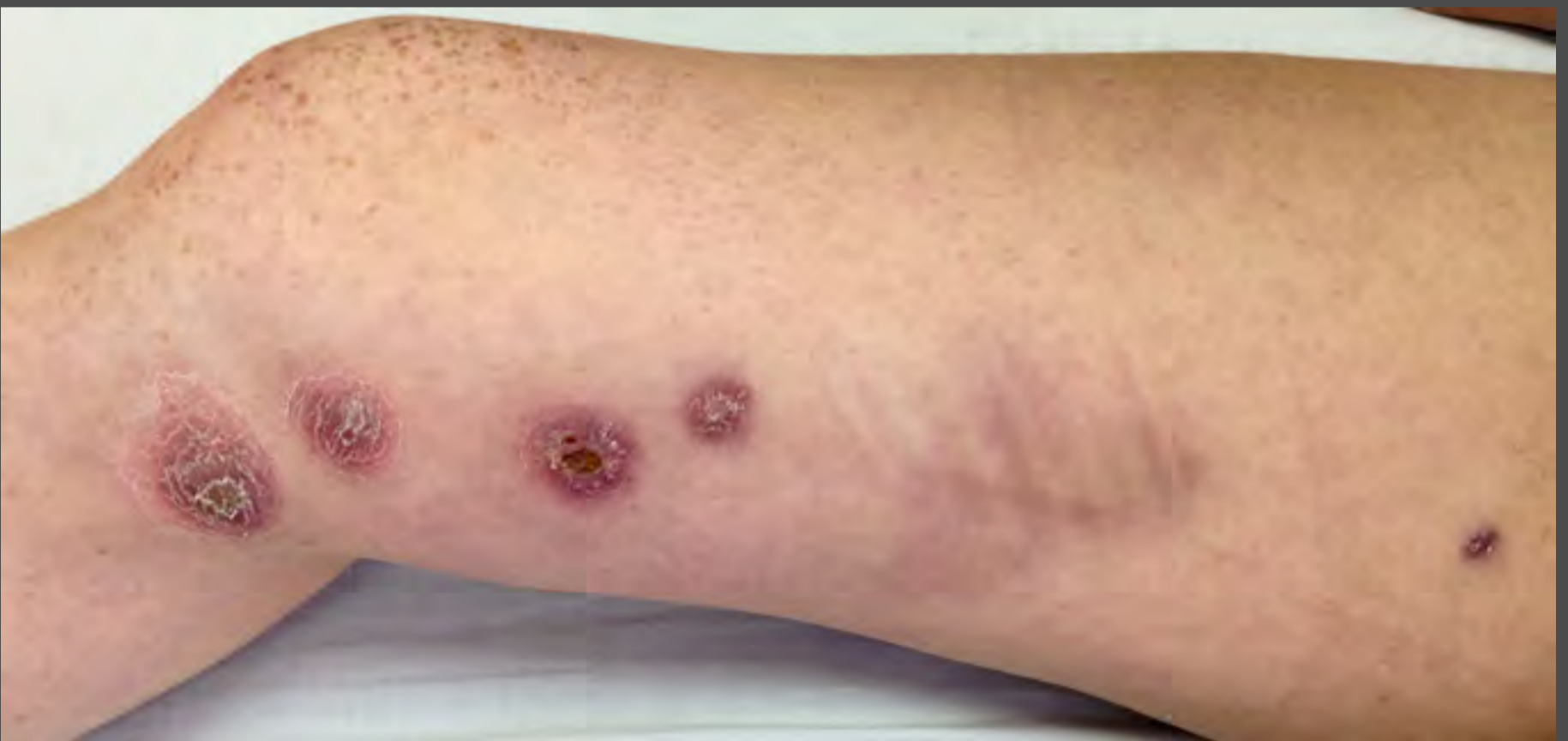Patient underwent mesotherapy to lose weight three months earlier. She received antimonial treatment without parasitological testing. The abdomen contained multiple irregular, dirty, depressed ulcers with purulent discharge, in addition to other nodular lesions and fibrous cords. The upper area was erythematous and edematous and had renitent, fluctuating areas that were draining purulent material.

## Atypical mycobacteria



**Figure 3.225.**

Deep ulcer of the abdominal skin, without a thick edge, which was a drainage sinus, surrounded by erythematous edematous skin, and lesions from local injections (mesotherapy)



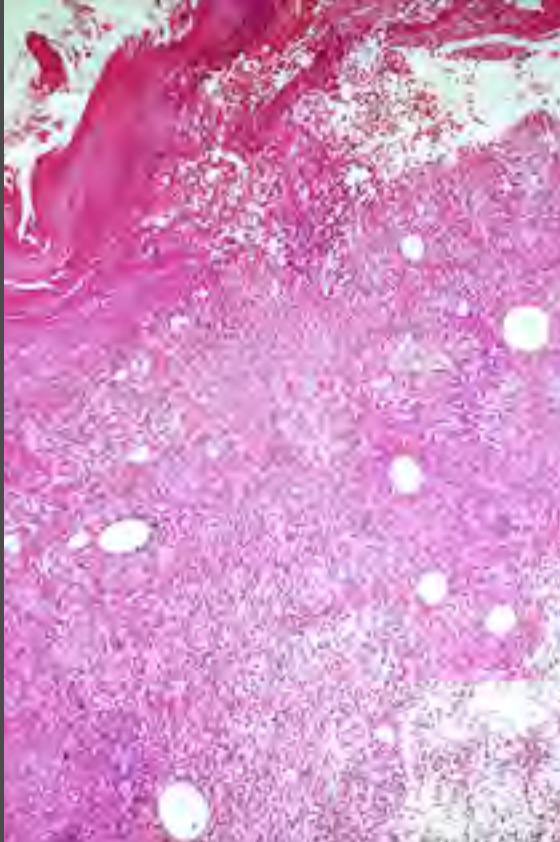
**Figure 3.226.**

Nodules on the leg and thigh with a lymphangitic distribution, and lesions from local injections (mesotherapy)

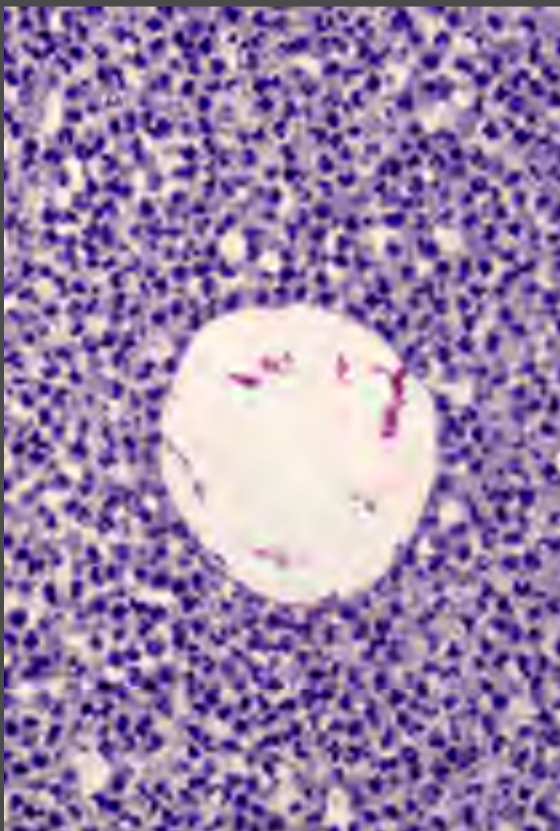
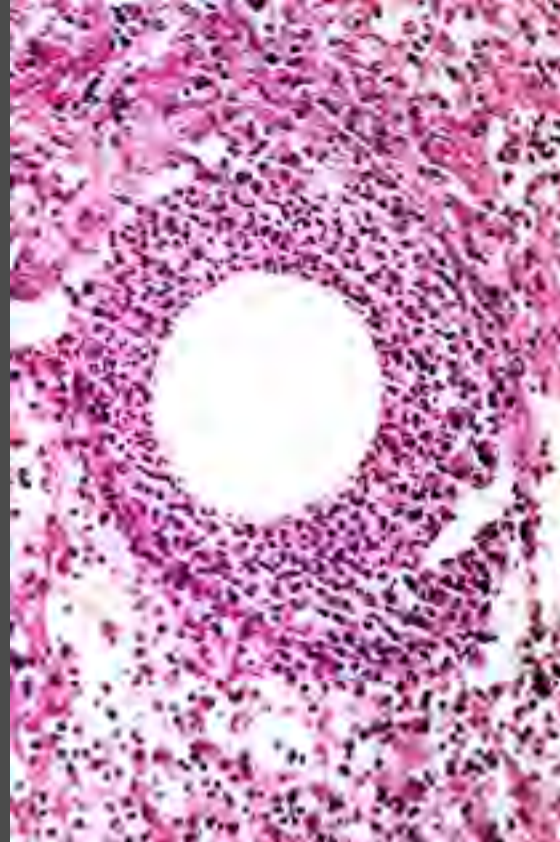
## Atypical mycobacteria

**Figure 3.227A.**

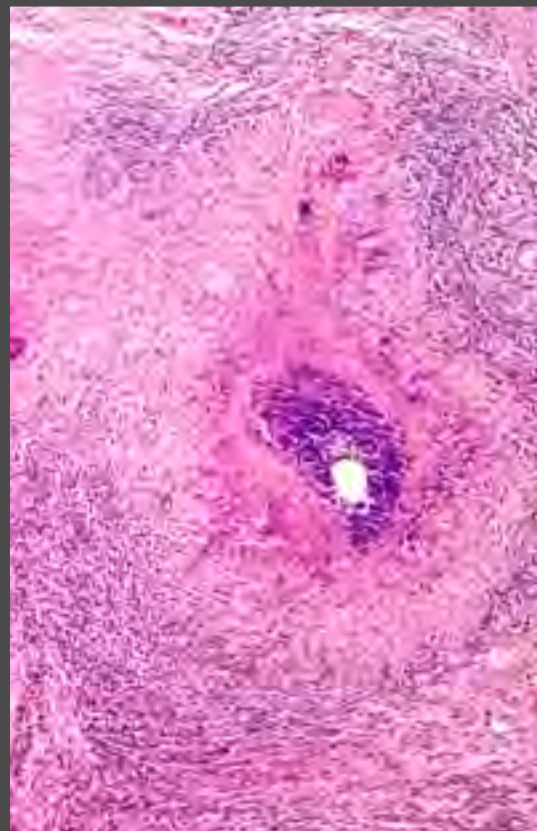
Ulcer with thick scaly crust, mild epidermal hyperplasia, and diffuse granulomatous dermal inflammation, with numerous vacuoles surrounded by polymorphonuclears; hematoxylin and eosin, 6.3X

**Figure 3.227B.**

Magnification of Figure 3.240A; hematoxylin and eosin, 40X

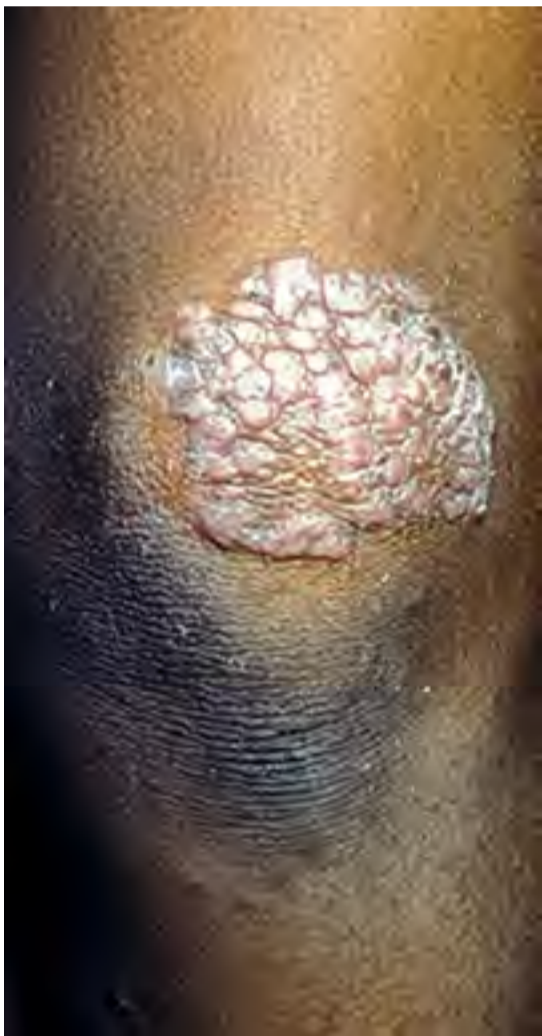**Figure 3.227C.**

This vacuole contains acid-fast bacilli; Ziehl-Neelsen, 100X.

**Figure 3.227D.**

Typical deep, hypodermic tuberculoid granuloma, with central necrosis and with a vacuole surrounded by polymorphonuclears; hematoxylin and eosin, 6.3X

**Cutaneous tuberculosis.** here are several clinical forms of cutaneous tuberculosis: scrofuloderma, orificial, verrucosa, and lupus vulgaris, among others. Tuberculosis verrucosa cutis is acquired by cutaneous inoculation by the bacillus, in a patient highly immune to the germ. It presents as a papillomatous, hyperkeratotic, and crusty lesion that can mimic verrucous leishmaniasis (*Figures 3.228 a 3.234*).

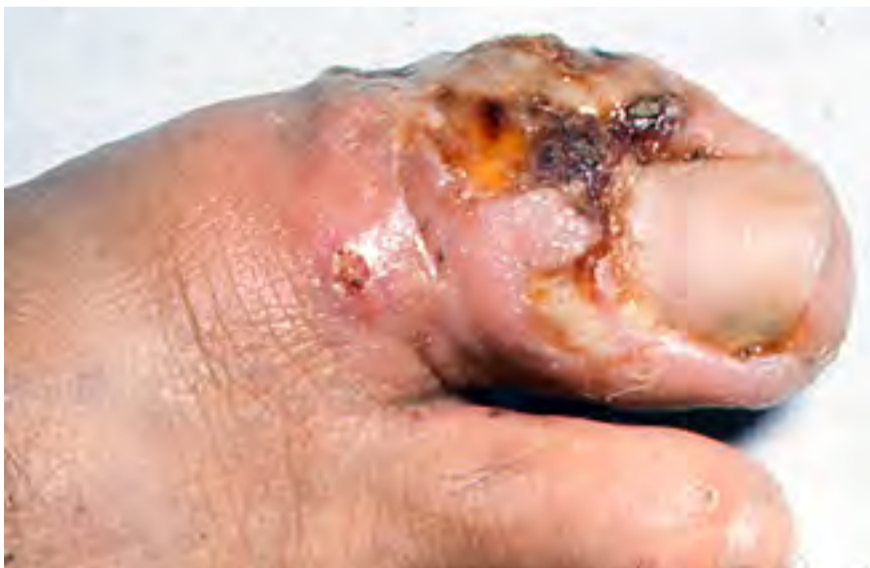
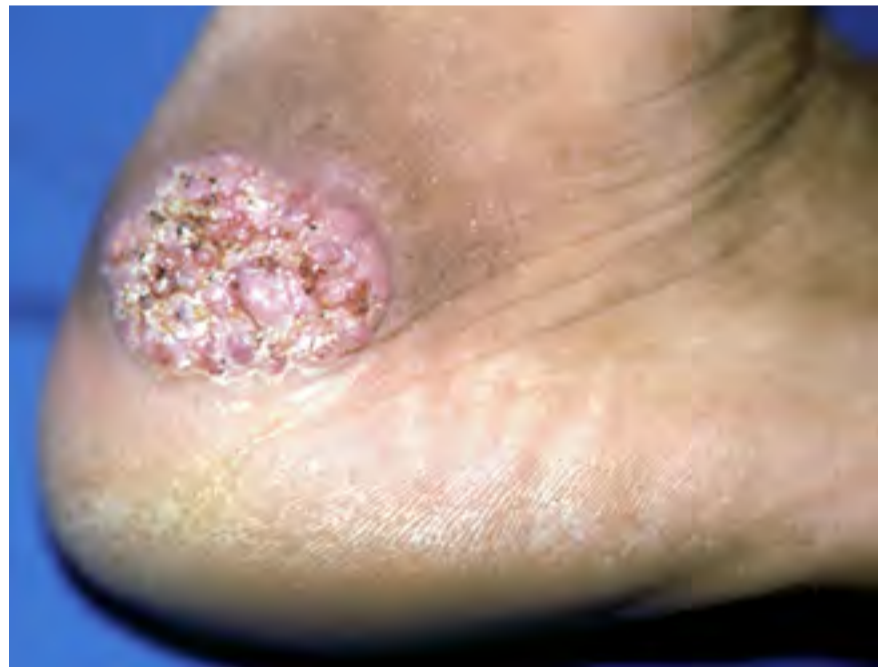
**Figure 3.228A.**

Plaque formed by hyperkeratotic, warty papules

**Figure 3.228B.**

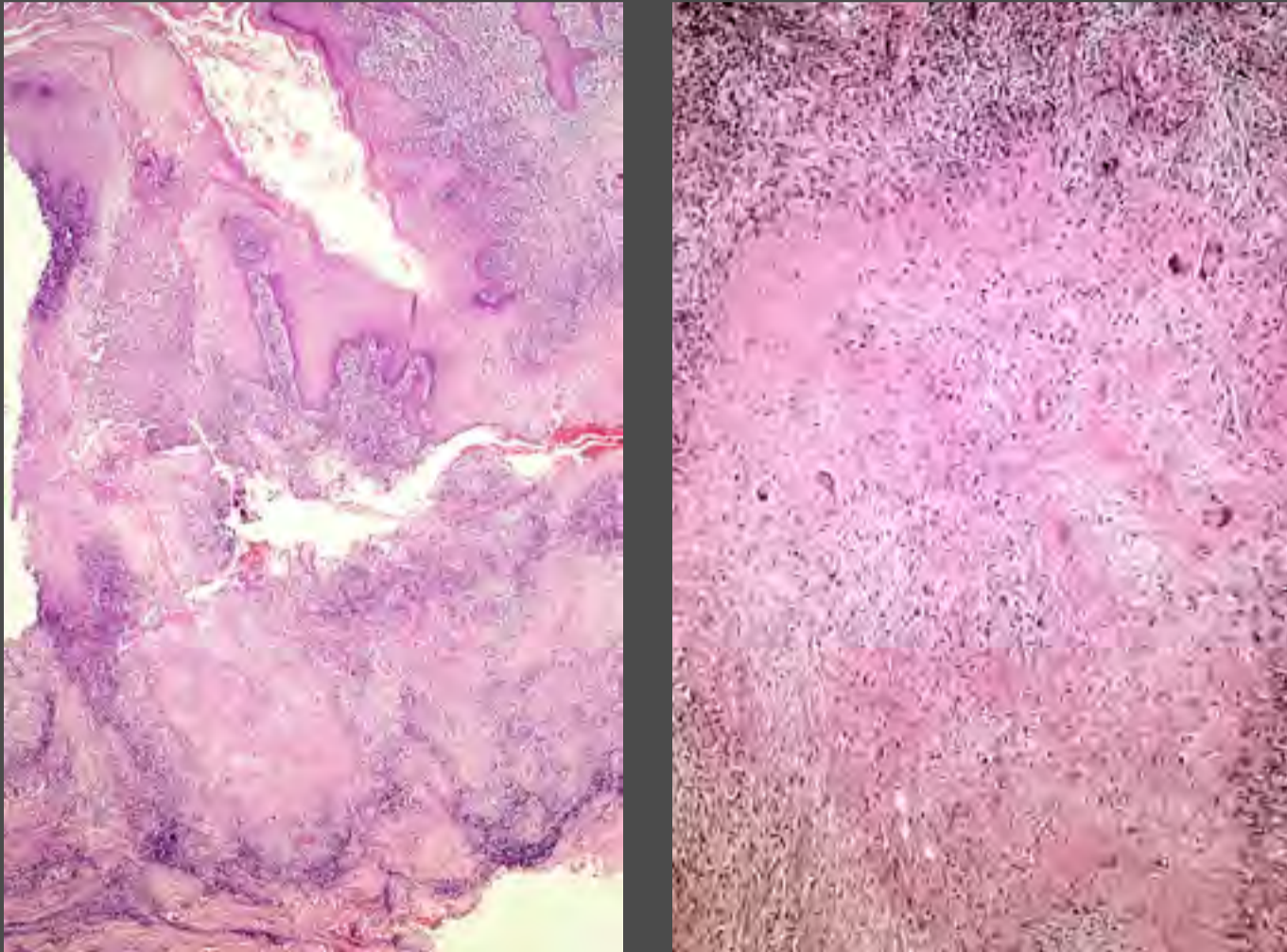
Ulcerated, hyperkeratotic, warty plaque



**Figure 3.228C.**

Ulcerated, hyperkeratotic, crusty, edematous plaque

## Verrucous tuberculosis

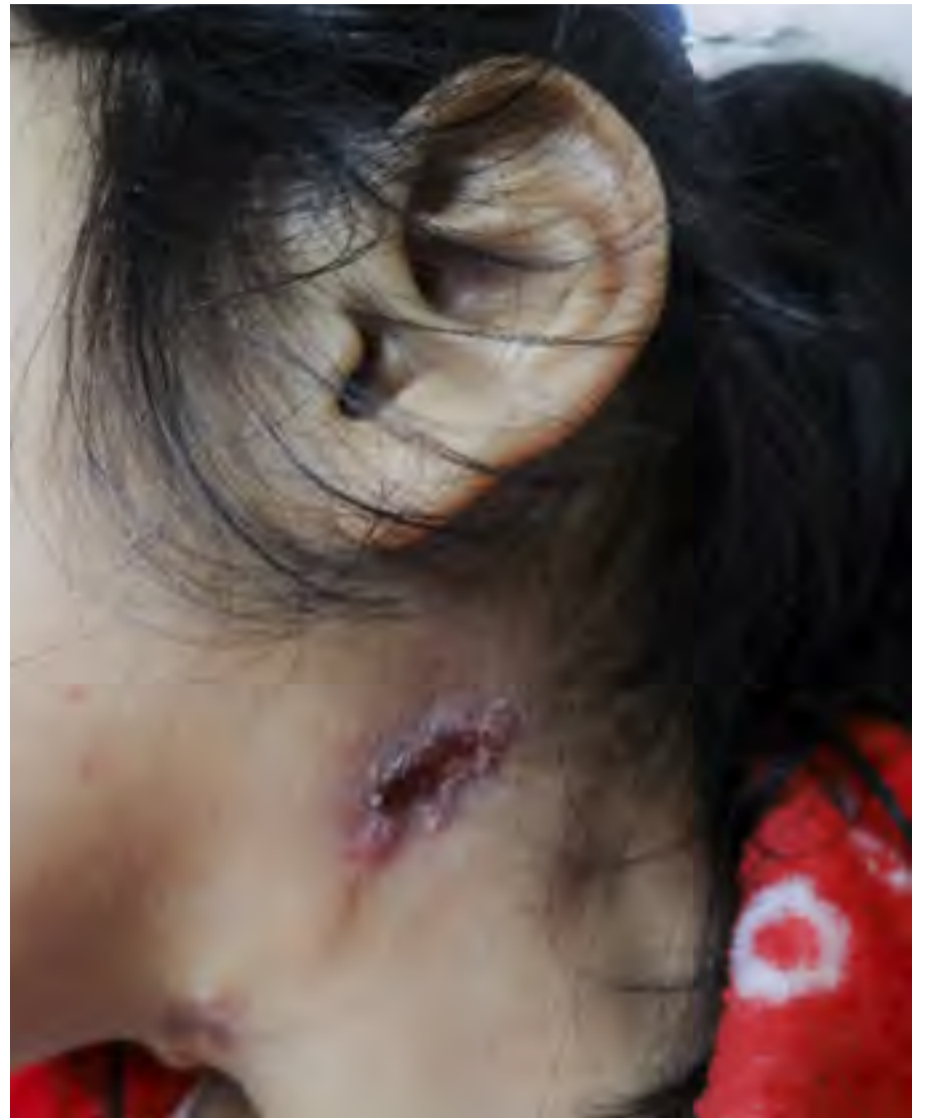

**Figures 3.229A and B.**

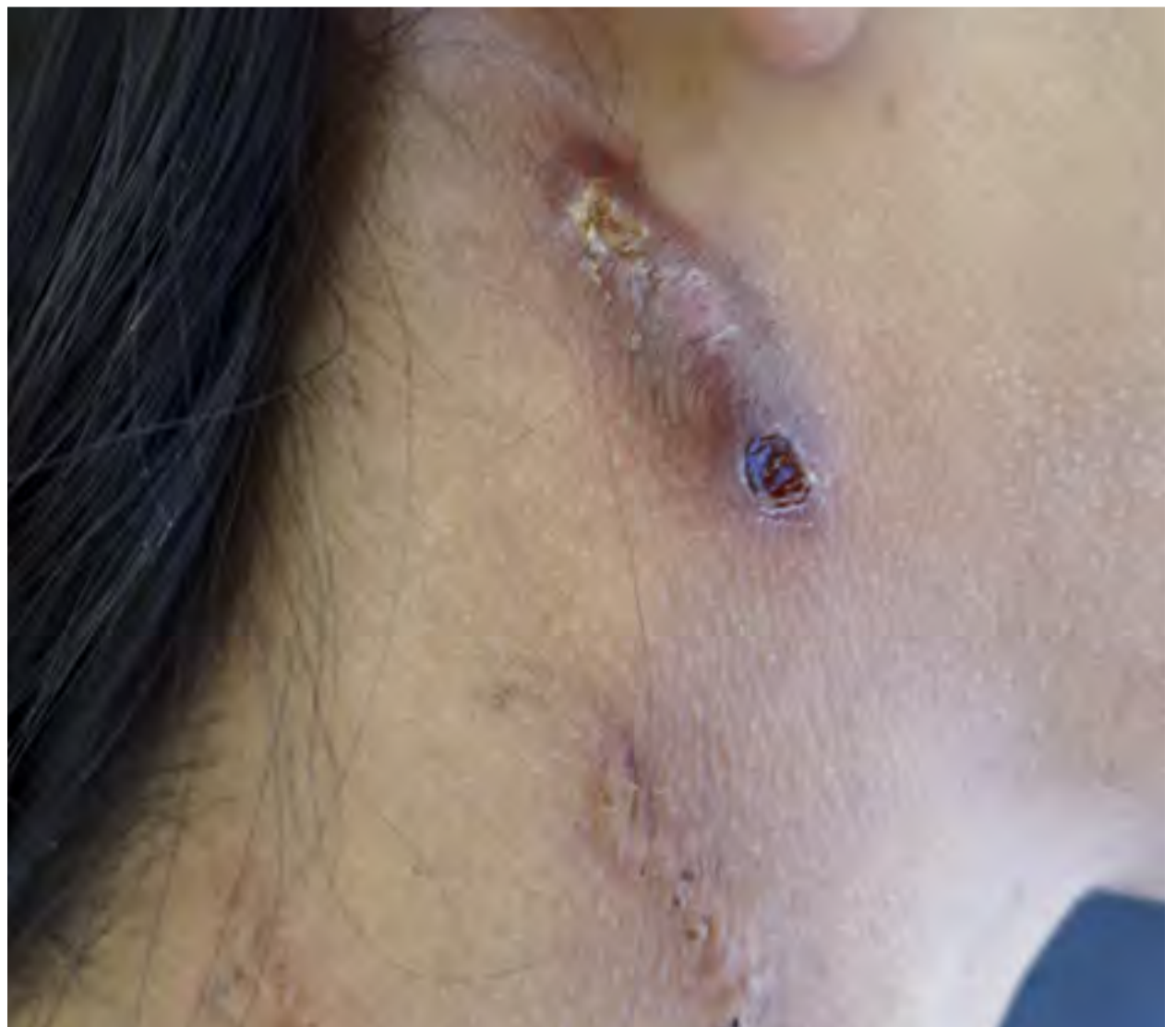Epidermal hyperplasia and dermis with tuberculoid granulomata with extensive central necrosis, surrounded by epithelioid, giant, and lymphocyte cells; hematoxylin and eosin, A. 2.5X and B. 6.3X



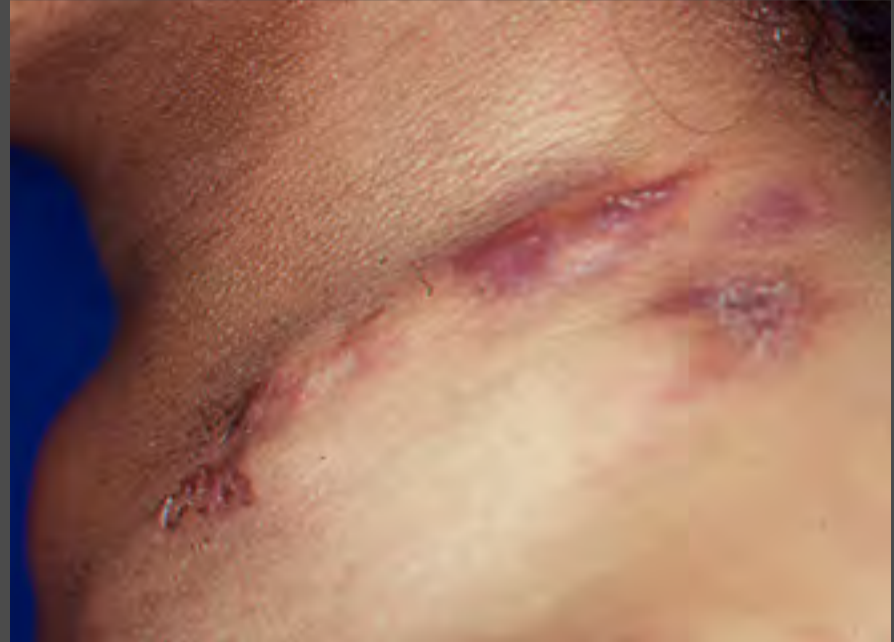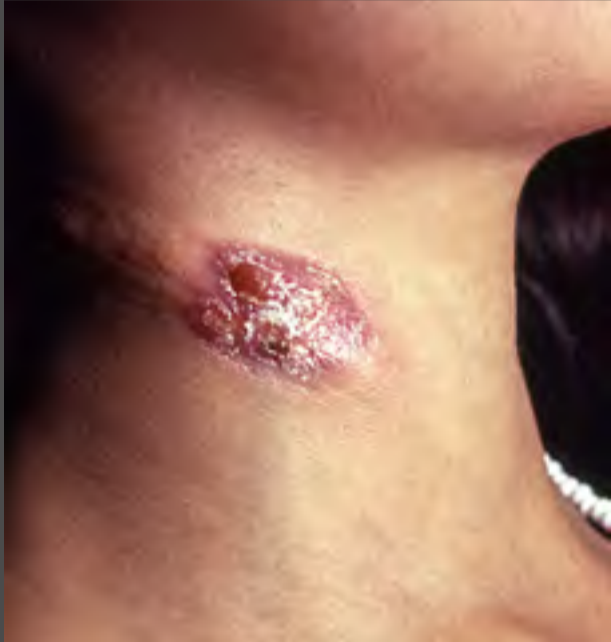**Scrofuloderma.** This is the most common form of cutaneous tuberculosis; it spreads to the skin from an underlying organ, such as a lymph node, bone, or joint. The lesion is most frequent in the neck and chest, and when it ulcerates, it resembles leishmaniasis, but often has seropurulent discharge, which is not common in leishmaniasis (Figures 3.230 a 3.231).



**Figures 3.230A and B.** Scrofuloderma. This is the most frequent form of cutaneous tuberculosis and consists of suppurative ulcers (A) or nodules (B). Lesions are indurated, adhered to deep planes, with little purulent discharge.

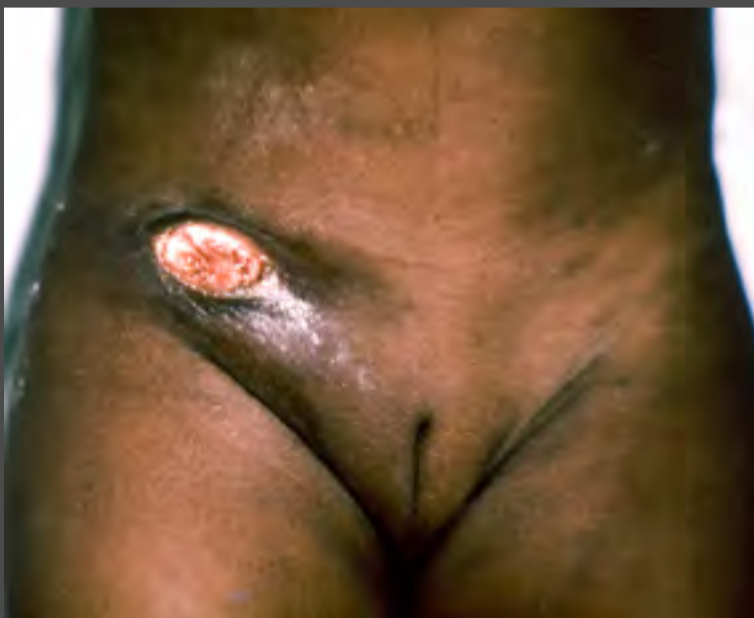

## Scrofuloderma - tuberculosis



**Figures 3.230C and D.**

Ulcerated nodules and plaques on cervical adenopathies



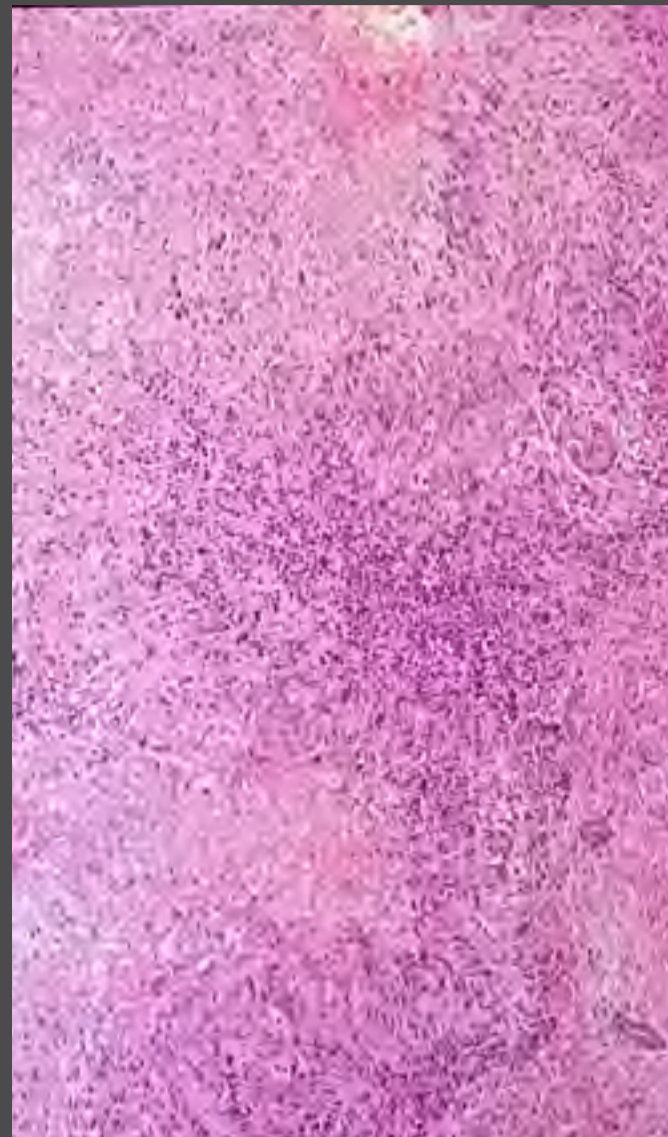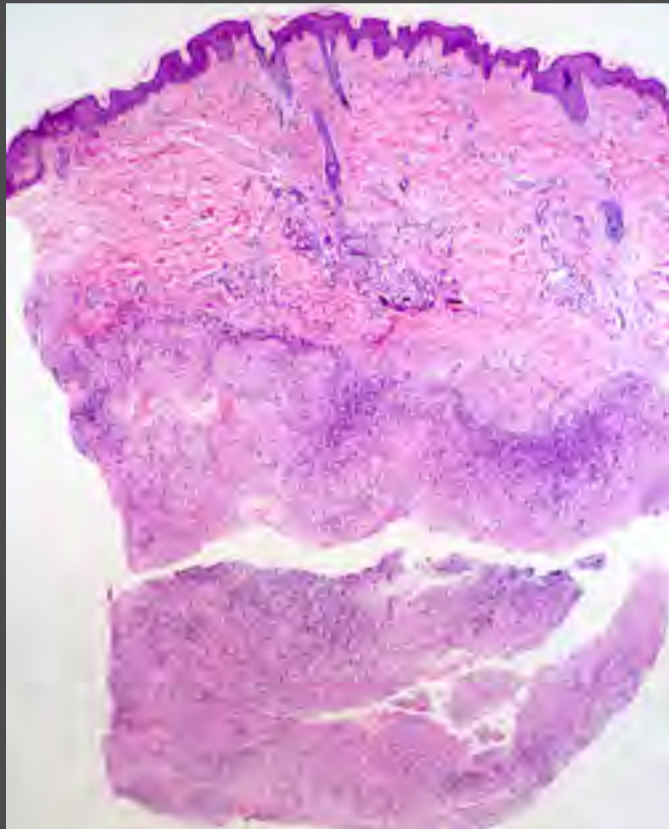
**Figure 3.230E.**

Girl with ulcer with thick edges and granular floor on inguinal adenopathy

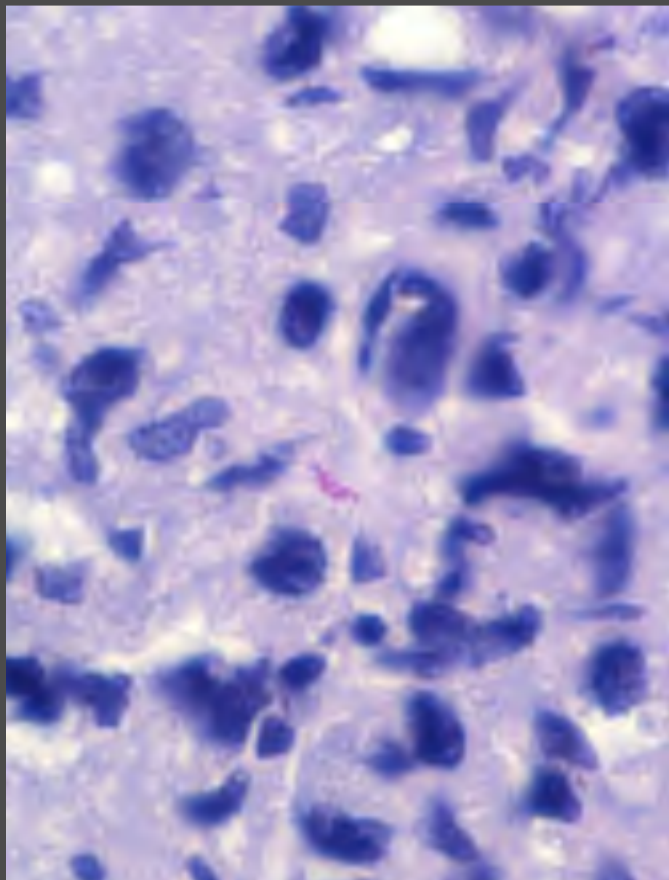
## Scrofuloderma - tuberculosis

**Figure 3.231A.**

Granulomatous inflammation with extensive necrosis on the deep dermis and in the hypoderm; hematoxylin and eosin, 2.5X

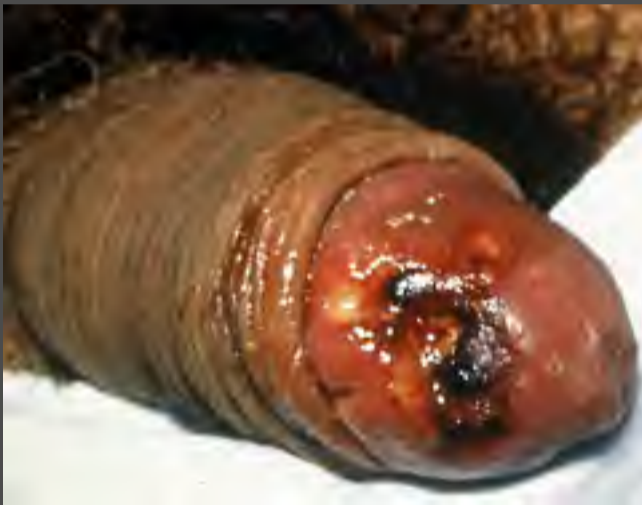**Figure 3.231B.**

Granulomata of epithelioid, giant, and lymphocyte cells that surround extensive areas of fibrinoid necrosis; hematoxylin and eosin, 10X.

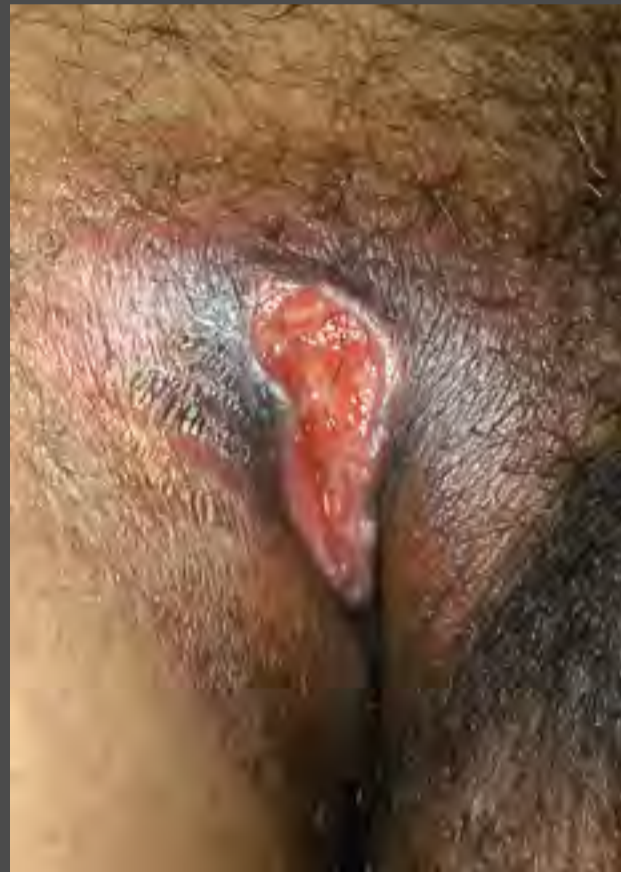**Figure 3.231C.**

Limited bacilli in lesions; Ziehl-Neelsen, 100X

## Cutaneous tuberculosis of the orifices

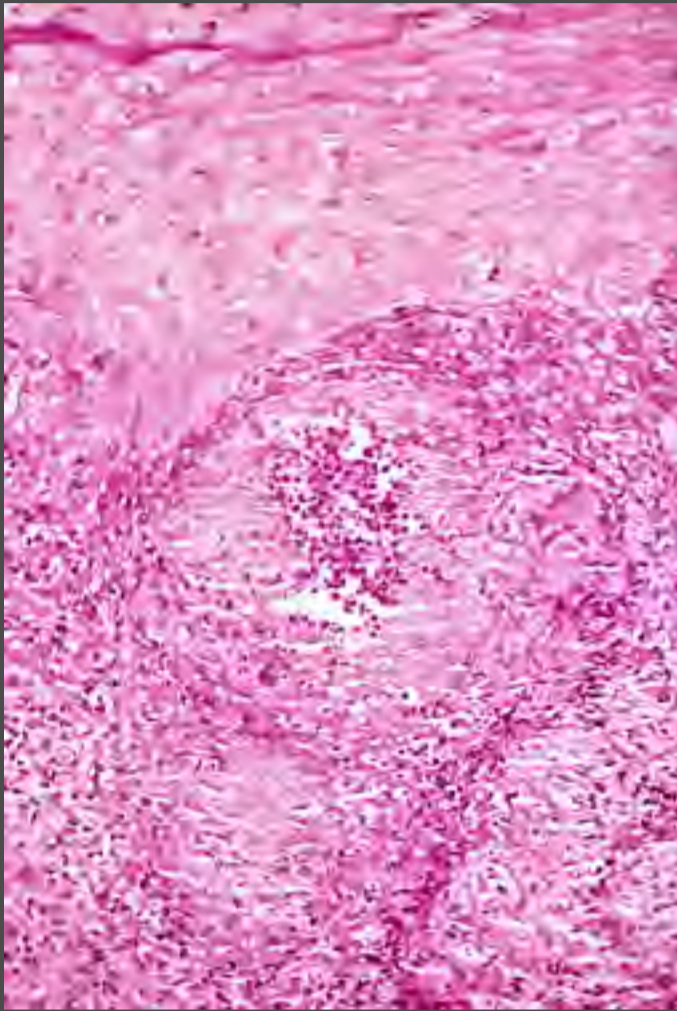


**Figure 3.232A.**  
Tubercular ulcer rich in bacilli; a tubercular inoculation chancre or genitourinary tuberculosis should be investigated.

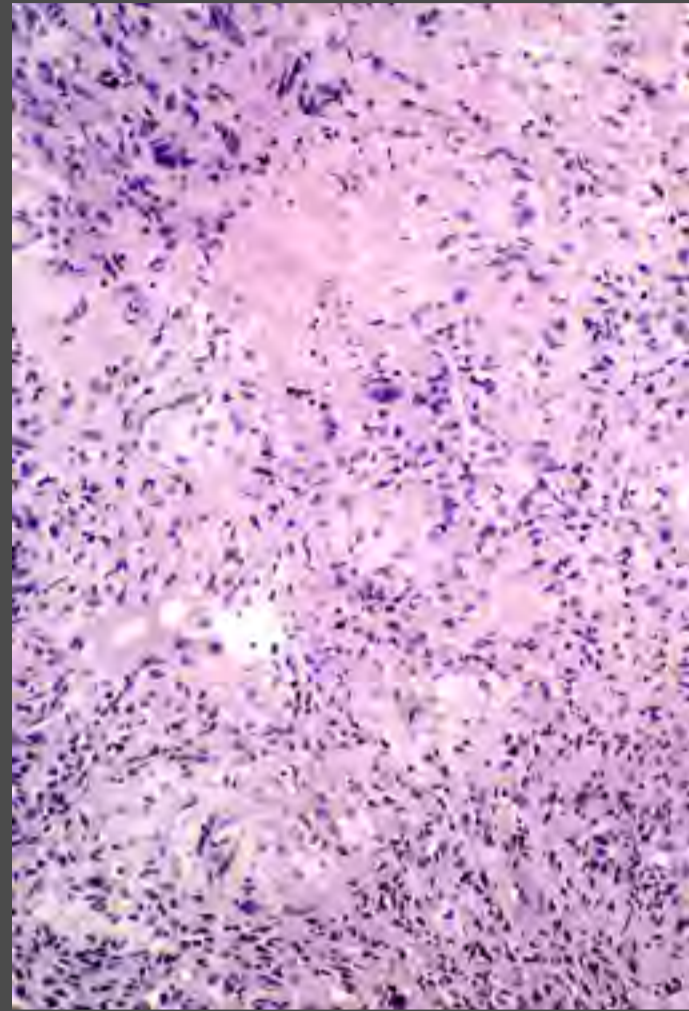


**Figure 3.232B.**  
Perianal tuberculosis with concomitant intestinal and pulmonary involvement

## Cutaneous tuberculosis of the orifices

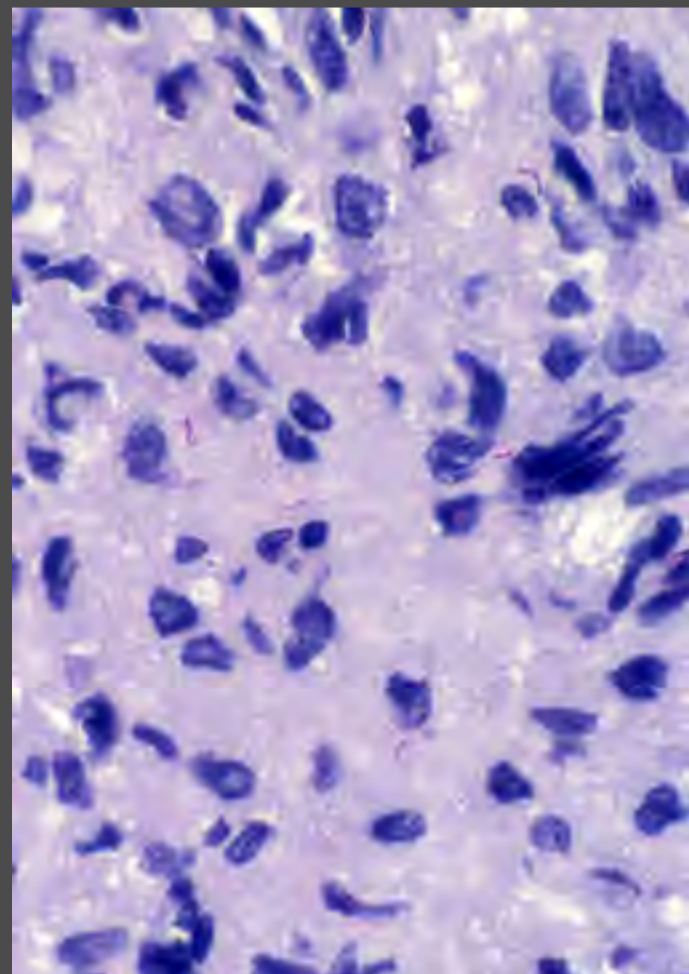


**Figure 3.233A.**  
Tongue. Subepidermal tuberculoid granulomata, one of them with a central abscess; hematoxylin and eosin, 16X

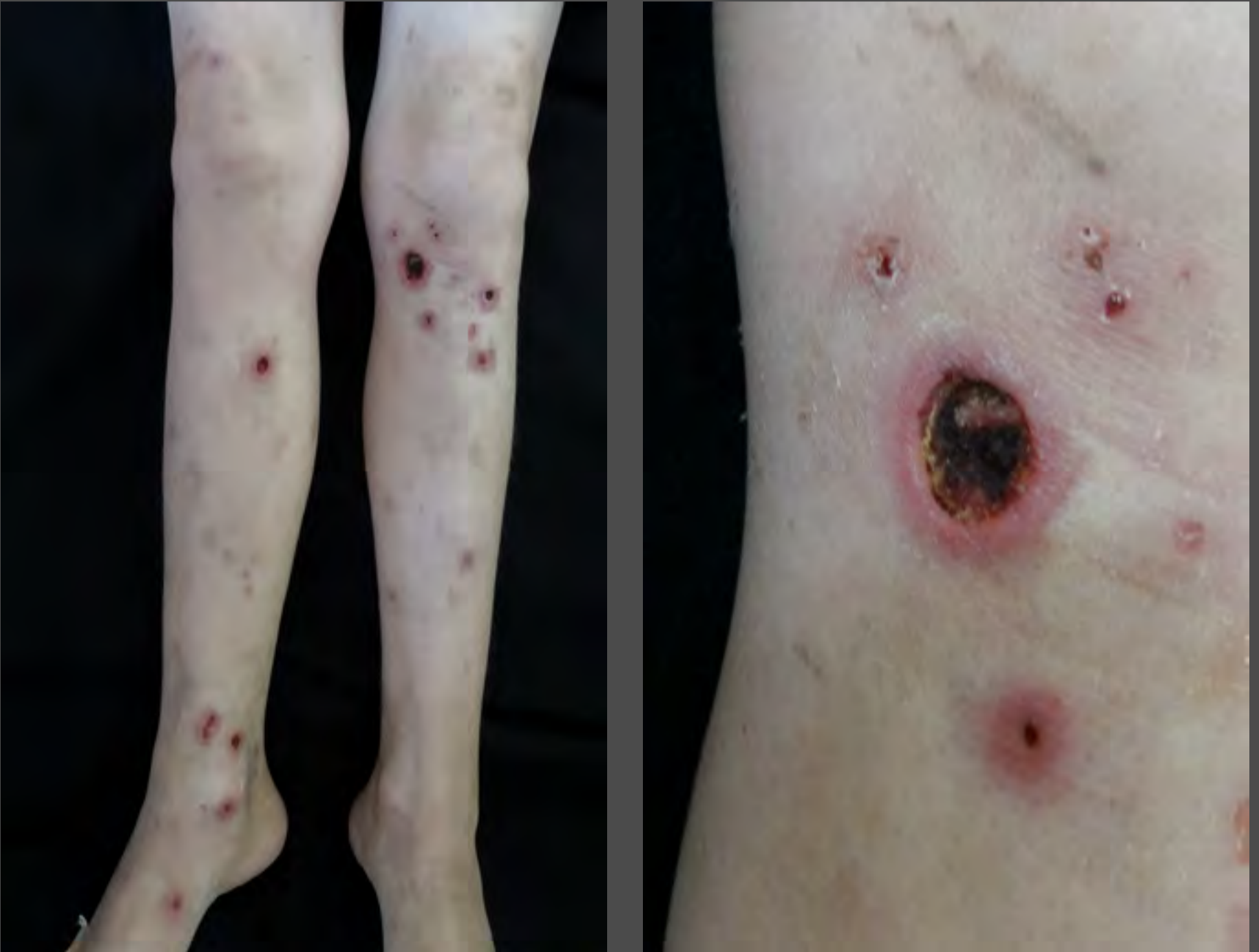

**Figure 3.233B.**  
Tuberculoid granulomata with broad central necrosis; hematoxylin and eosin, 16X

**Figure 3.233C.**  
Abundant Koch's bacilli; Ziehl-Neelsen, 100X.



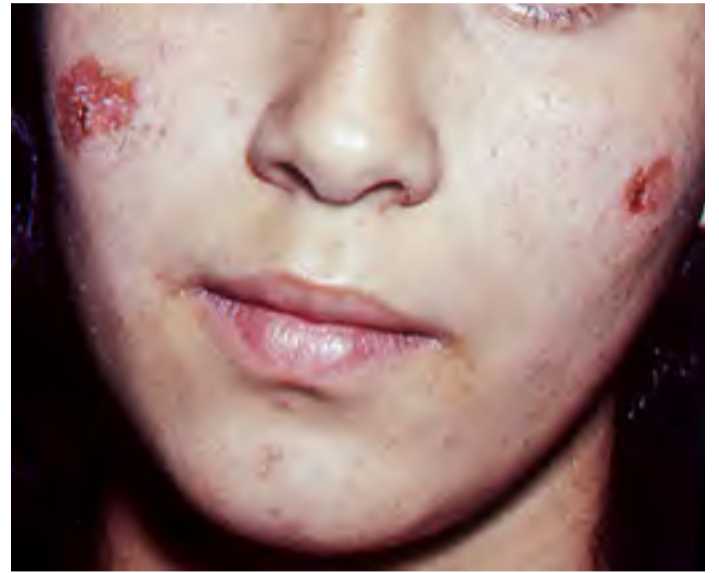## Papulonecrotic tuberculid



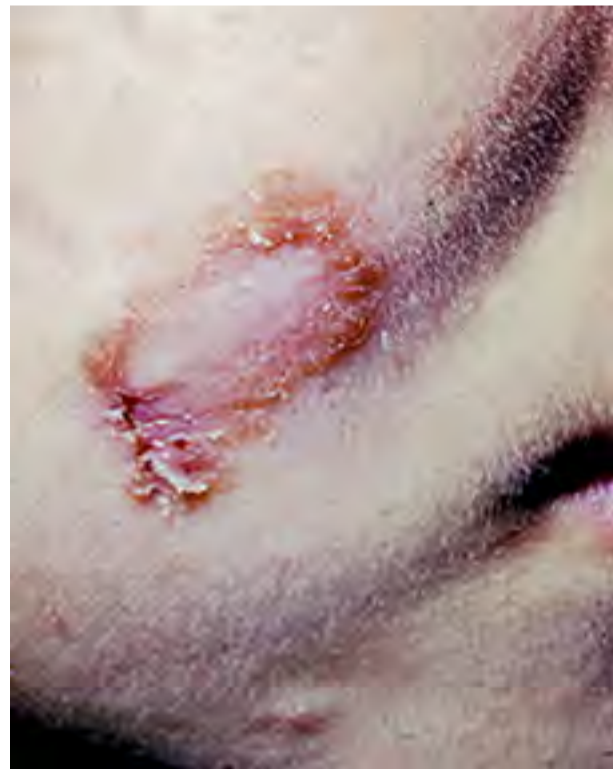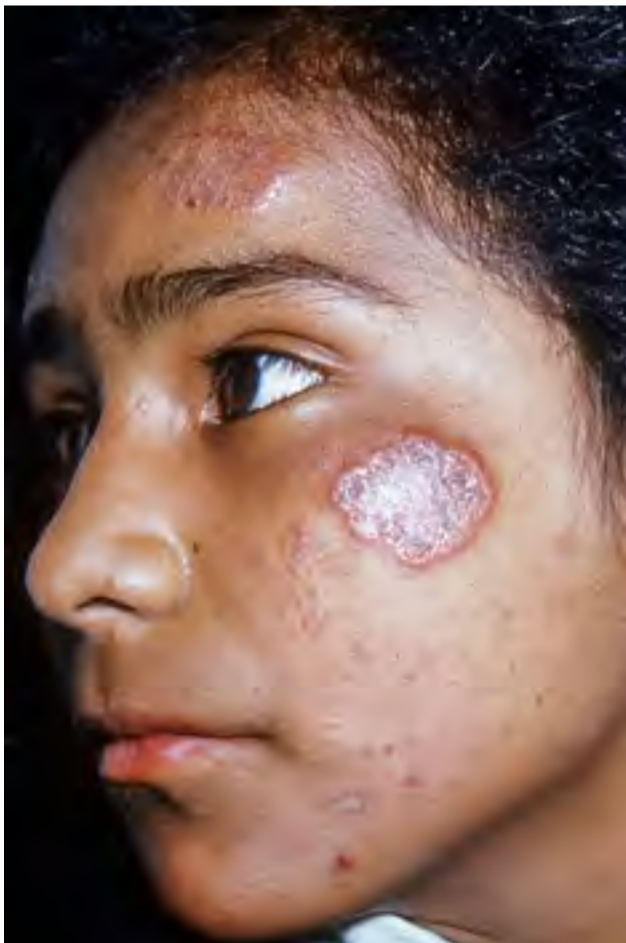**Figures 3.234A and B.**

Papulonecrotic tuberculid. Multiple small ulcerated lesions of necrotic appearance and different sizes on both legs, in a patient whose condition had deteriorated and who had lost weight. He had a history of similar lesions during a previous episode.

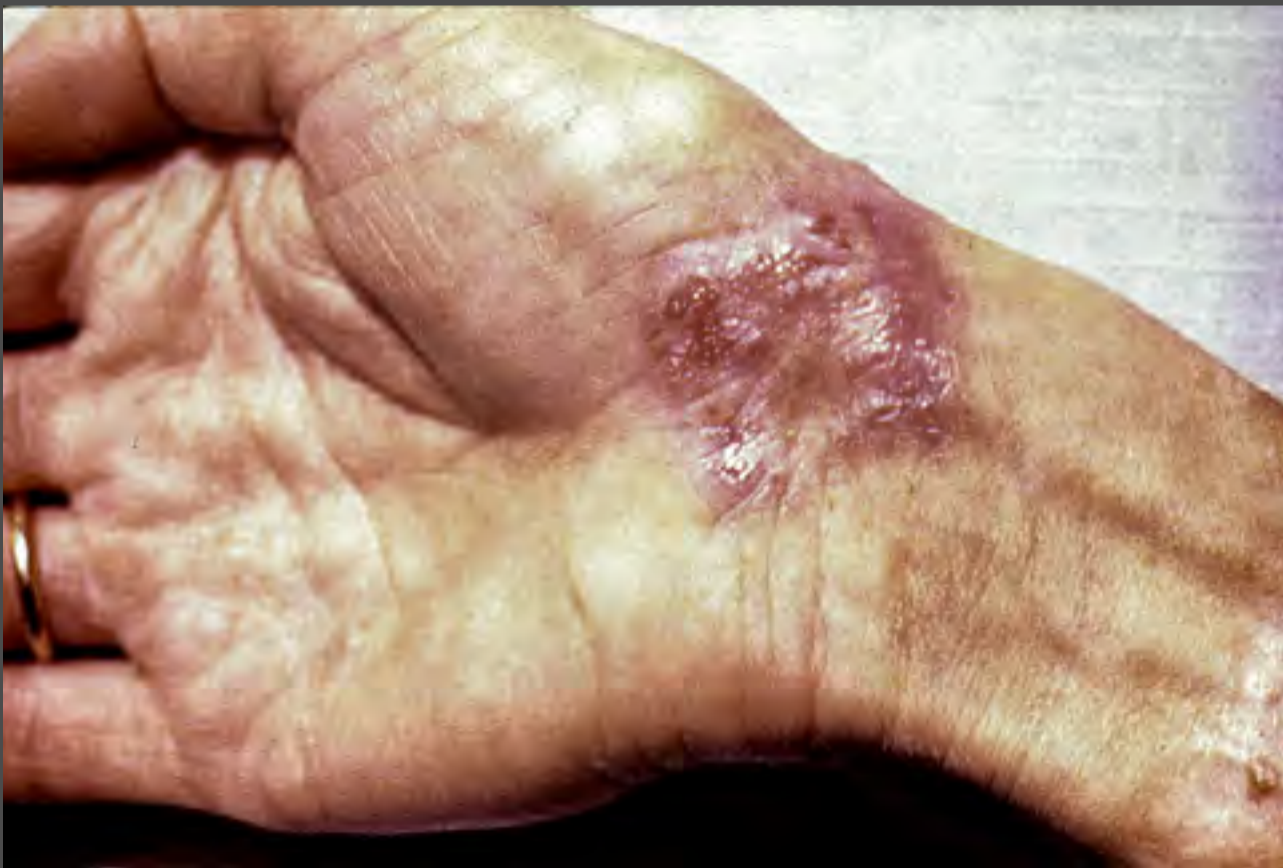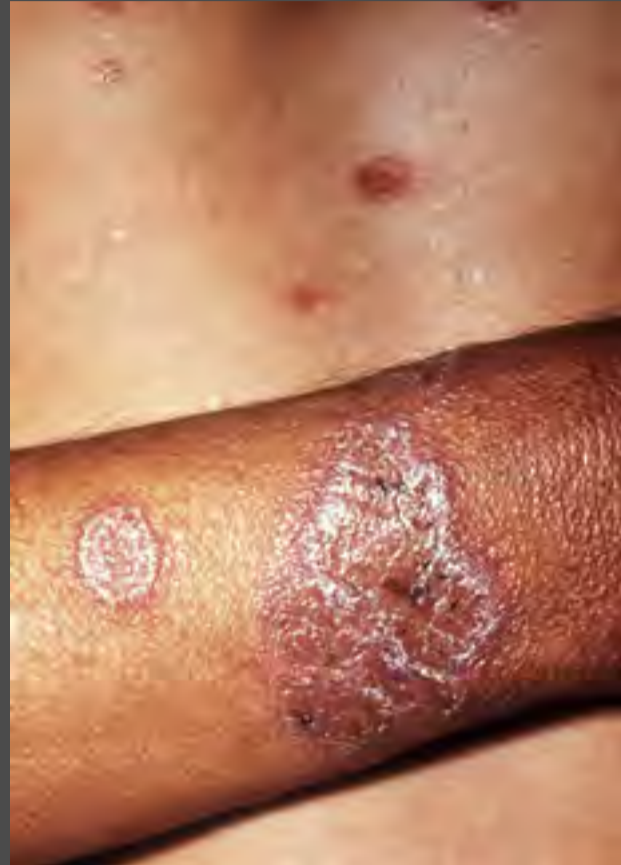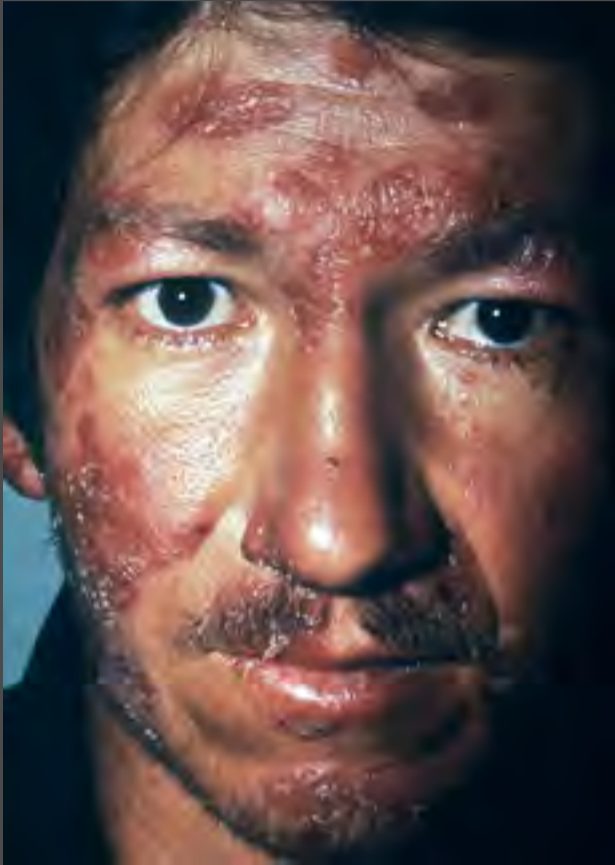***Lupus vulgaris.*** This is the least frequent clinical form of cutaneous tuberculosis. It is located most often on the face and neck with erythematous plaques that appear yellowish and nodular when pressed with a microscope slide (*Figures 3.235 to 3.236*). They progress very chronically and atrophy, and new lesions may appear over them.



**Figures 3.235A, B and C.**  
Plaques with depressed center and thick squamous, erythematous edge



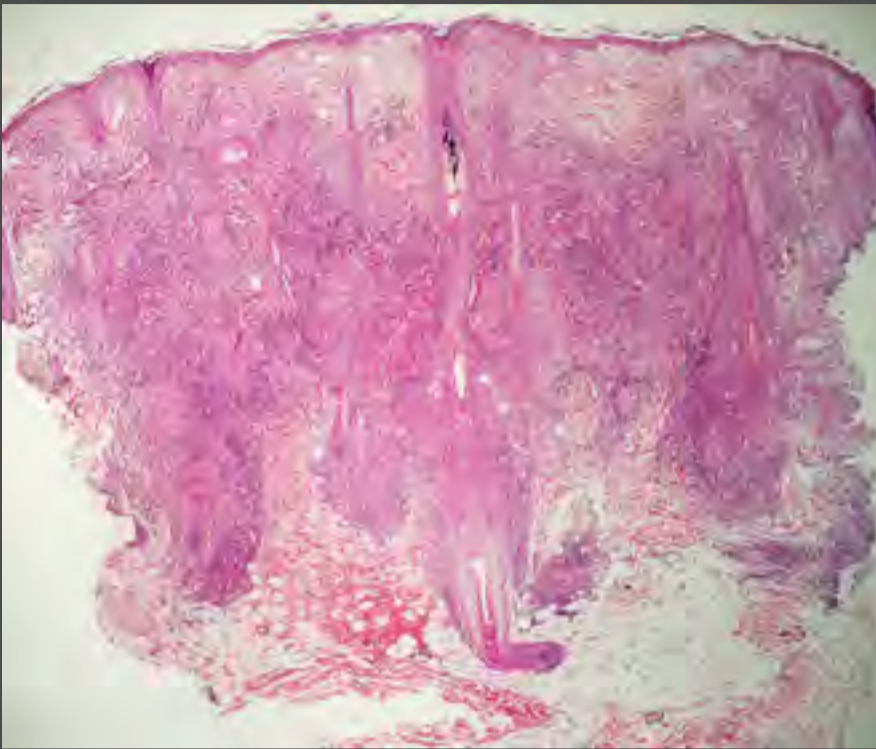## Cutaneous tuberculosis - lupus vulgaris



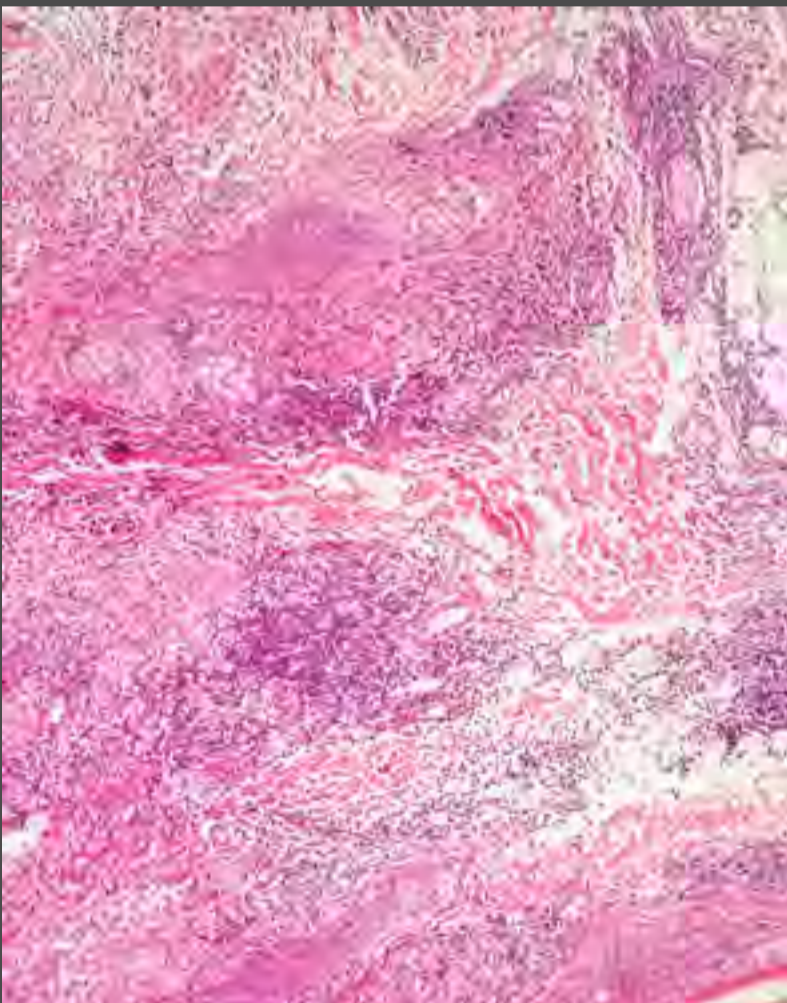
Figures 3.235D, E and F.  
Plaques with depressed center and thick squamous, erythematous edge



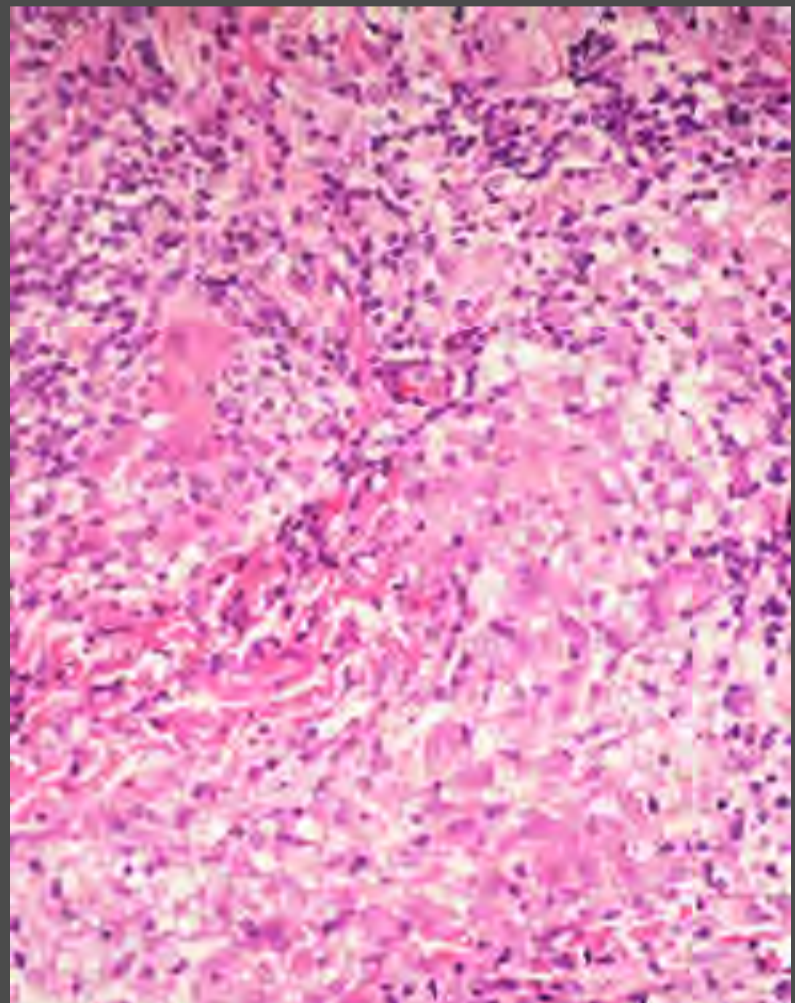
## Cutaneous tuberculosis - lupus vulgaris

**Figure 3.236A.**

Thin epidermis and dermis with diffuse granulomatous inflammation and perifollicular predominance; hematoxylin and eosin, 2.5X

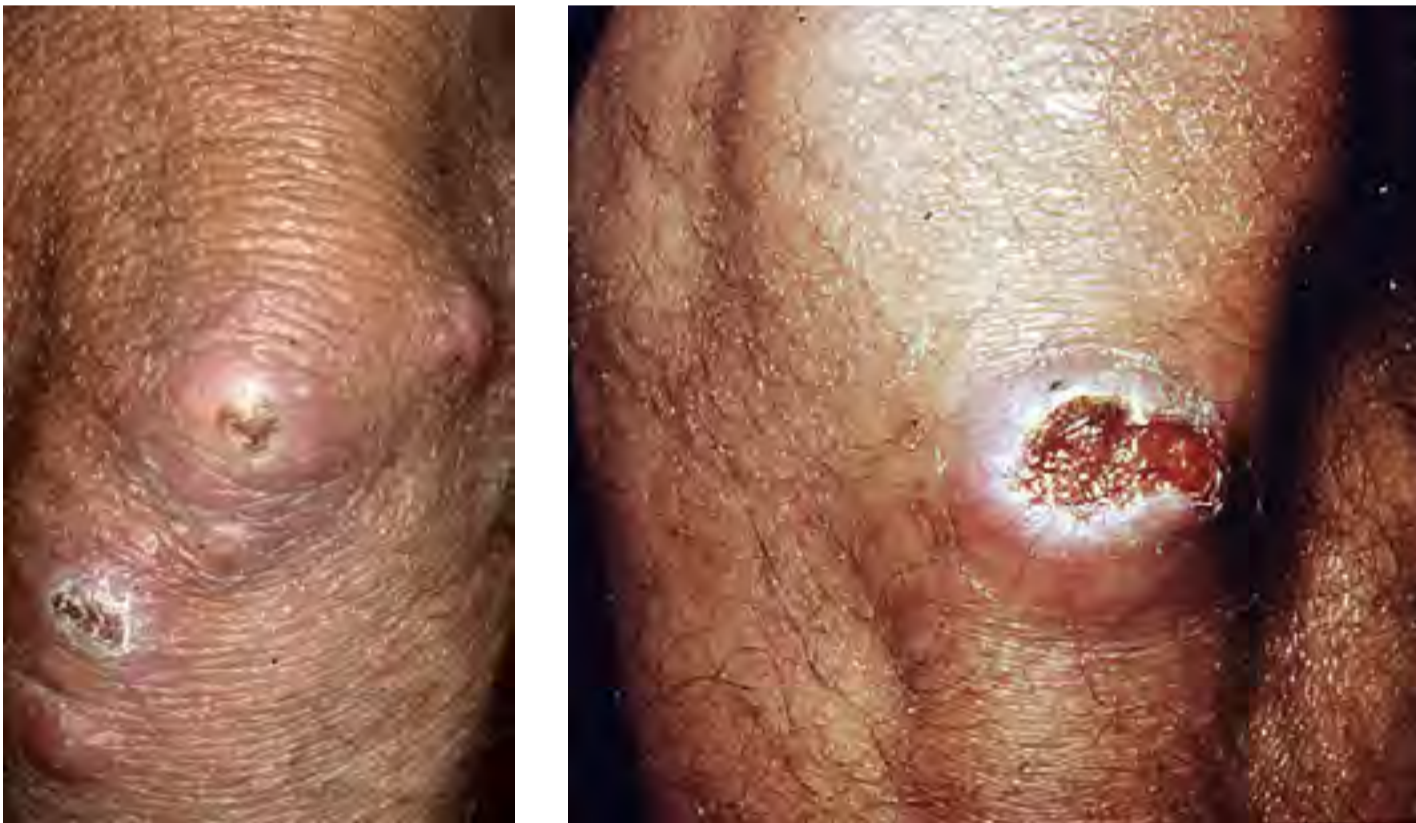**Figure 3.236B.**

Prominent epithelioid granulomata with abundant lymphocytes. The nerve (bottom right) is well preserved, which indicates that the lesion is not leprosy, a possible differential diagnosis in this inflammatory pattern; hematoxylin and eosin, 10X.

**Figure 3.236C.**

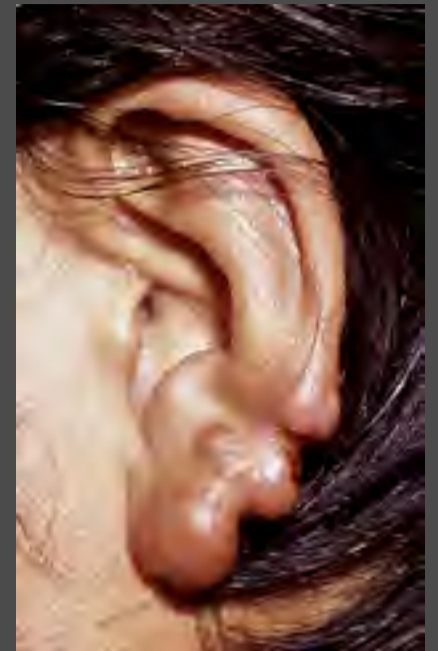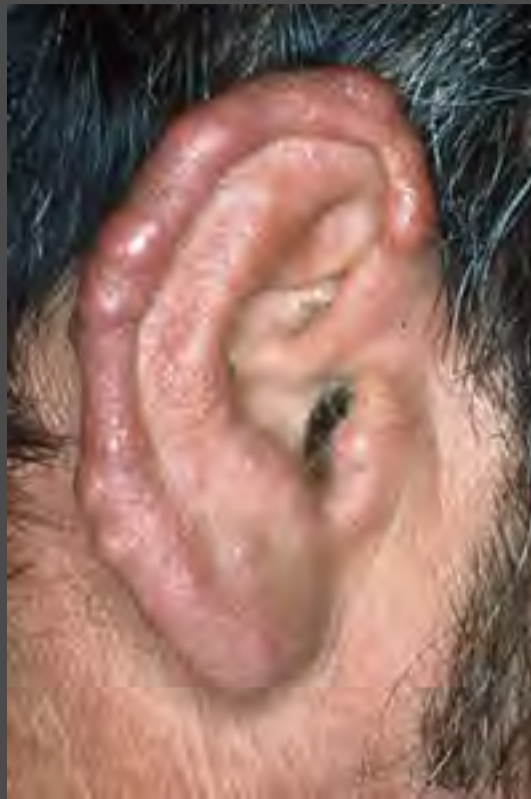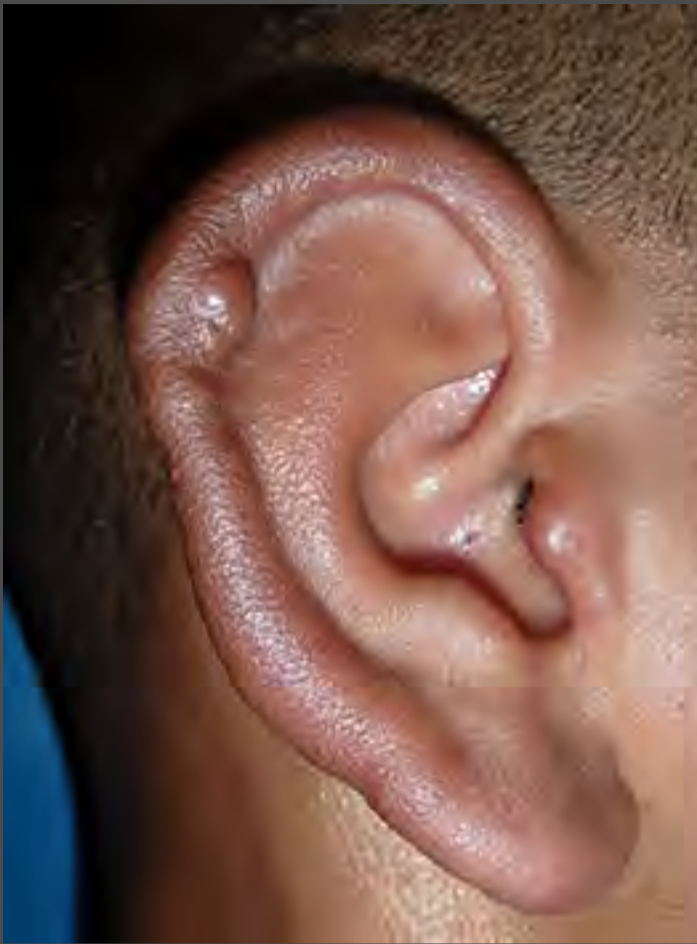Prominent epithelioid granulomata with abundant lymphocytes. The nerve is well preserved, which indicates that the lesion is not leprosy, a possible differential diagnosis in this inflammatory pattern; hematoxylin and eosin, 20X.

***Leprosy.*** The papules and plaques of diffuse cutaneous leishmaniasis resemble the lesions of lepromatous leprosy. Some ulcerated lepromas and nodular lesions of the ear may be confused clinically with leishmaniasis (*Figures 3.237 a 3.245*).



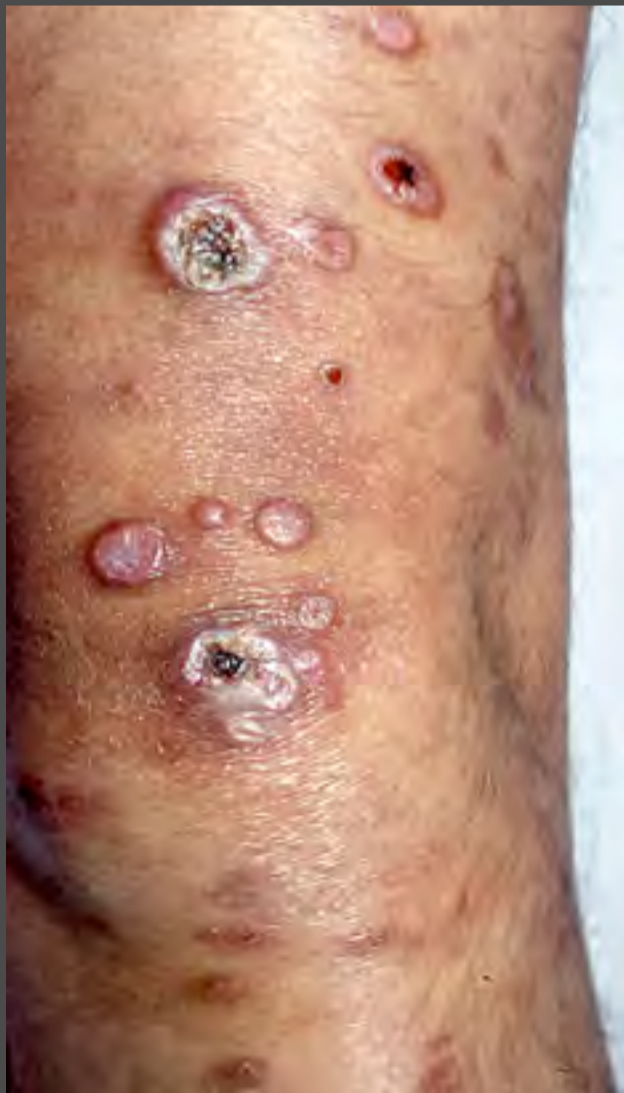**Figures 3.237A and B.**  
Lepromas. Ulcerated nodules and tubercles that clinically suggested leishmaniasis.

## Leprosy



**Figures 3.237C, D and E.**

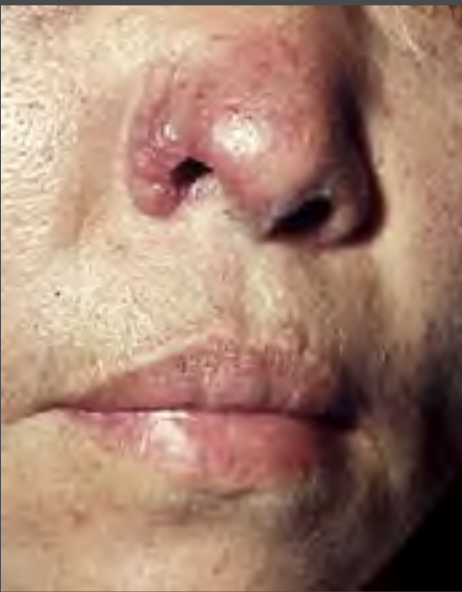Auricular lepromas. Anesthetic auricular papules and nodules in patient with lepromatous leprosy



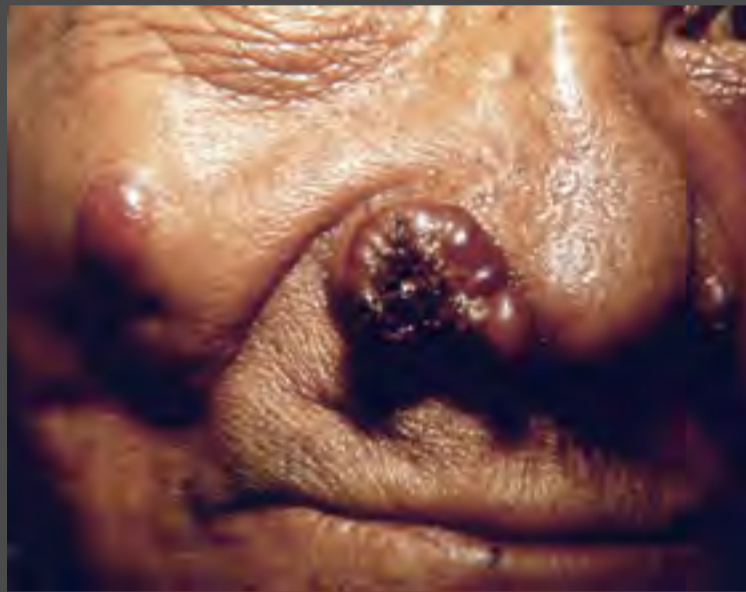**Figure 3.237F.**

Ulcerated nodules and tubercles that clinically suggested leishmaniasis.

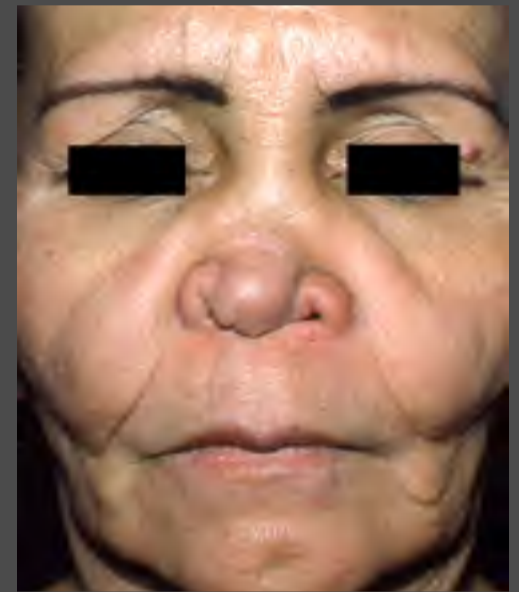## Leprosy



**Figure 3.238A.**  
Lepromatous leprosy.  
Women with  
erythematous nasal plaque  
with infiltrated edges

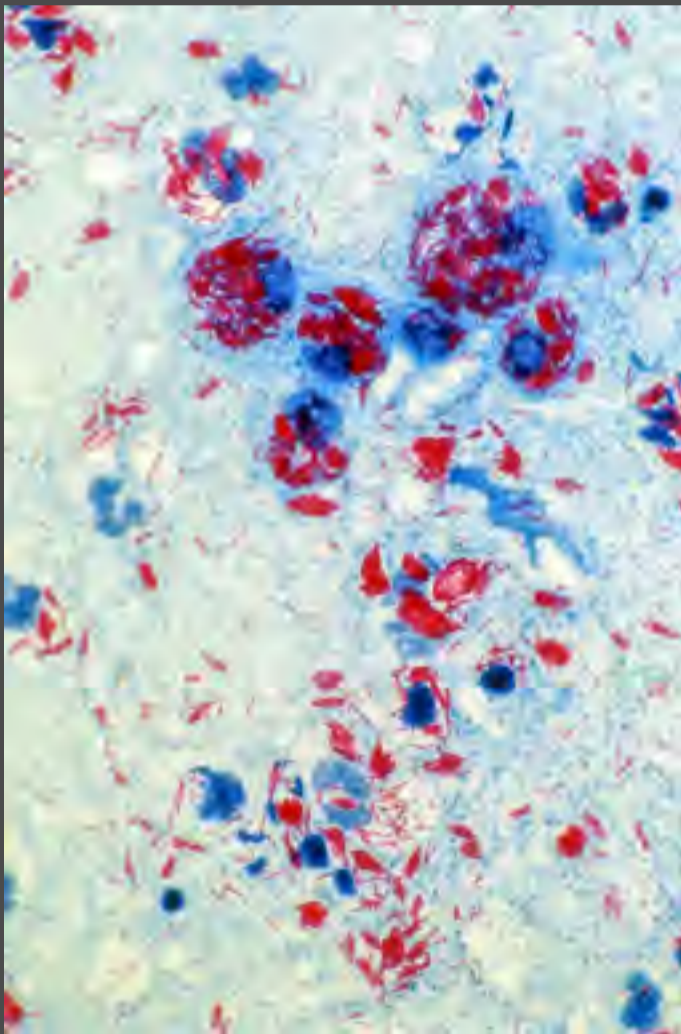


**Figure 3.238B.**  
Lepromatous leprosy. Nasal ulcer with  
papular edges and malar nodule



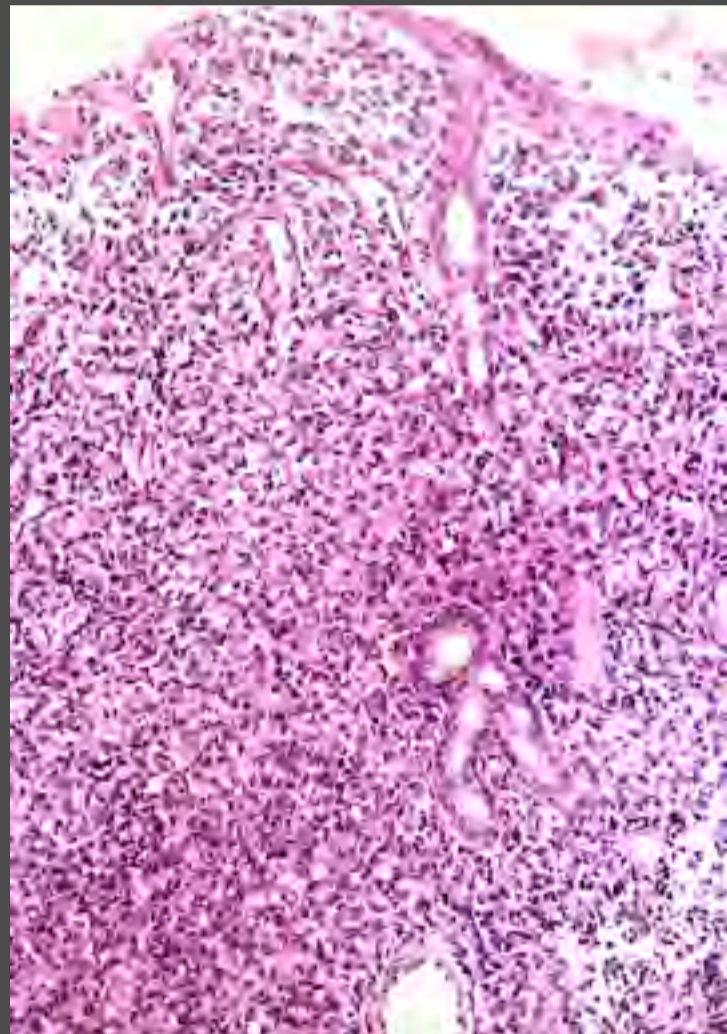
**Figure 3.238C.**  
Lepromatous leprosy.  
Droopy nose and facial  
infiltration. Madarosis is  
concealed with make-up.

## Leprosy



**Figure 3.239A.**

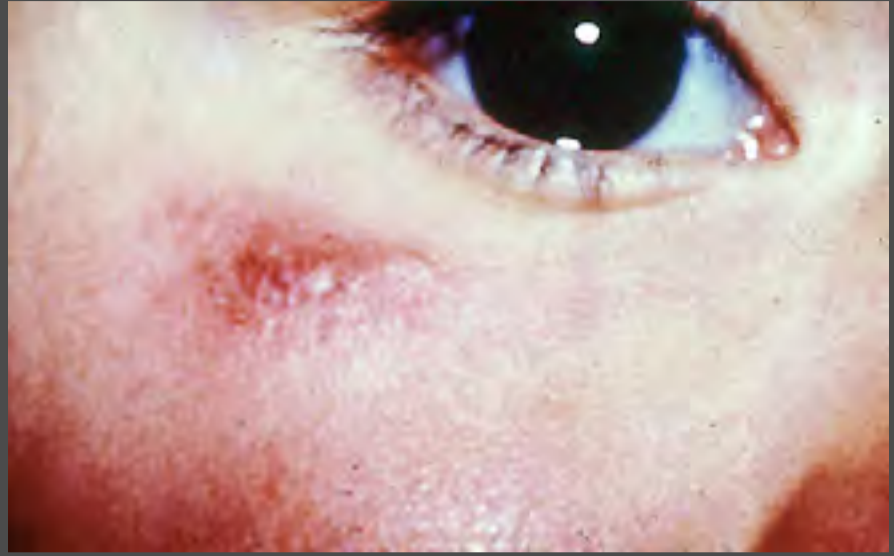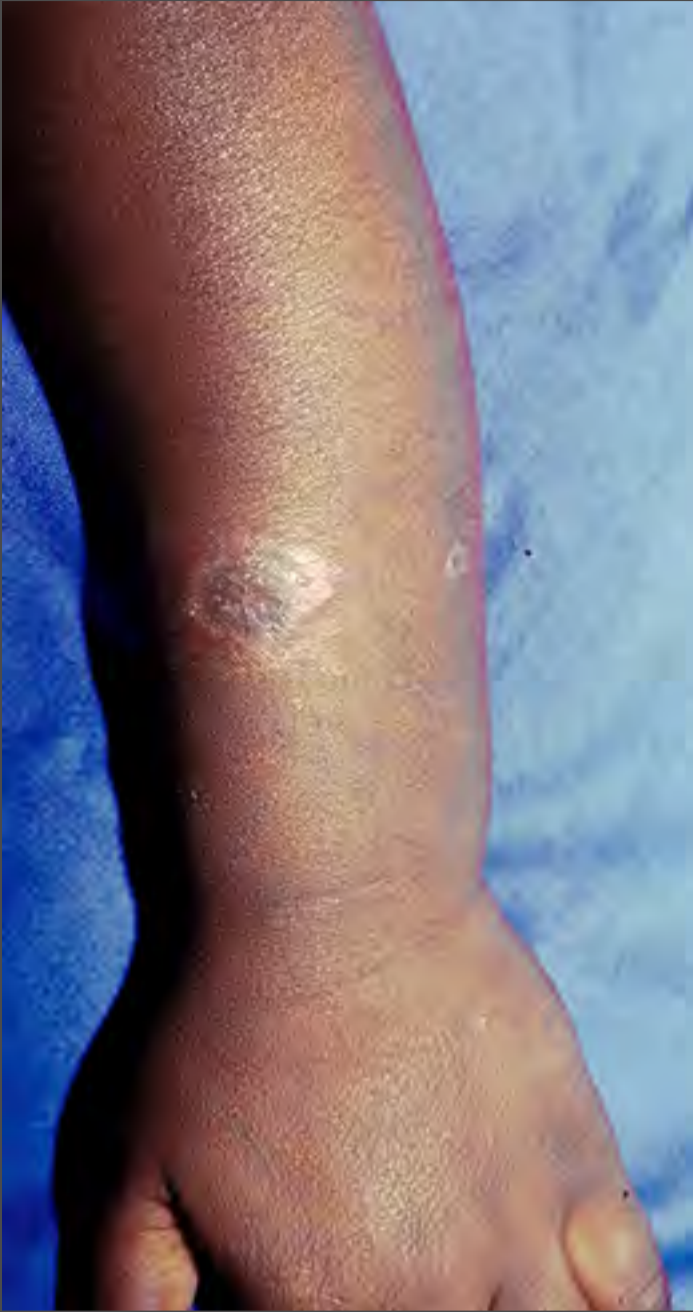Hansen bacilli and globi were found in direct nasal or pharyngeal smear in all the patients in Figures 3.237 and 3.238; Ziehl-Neelsen, 100X.



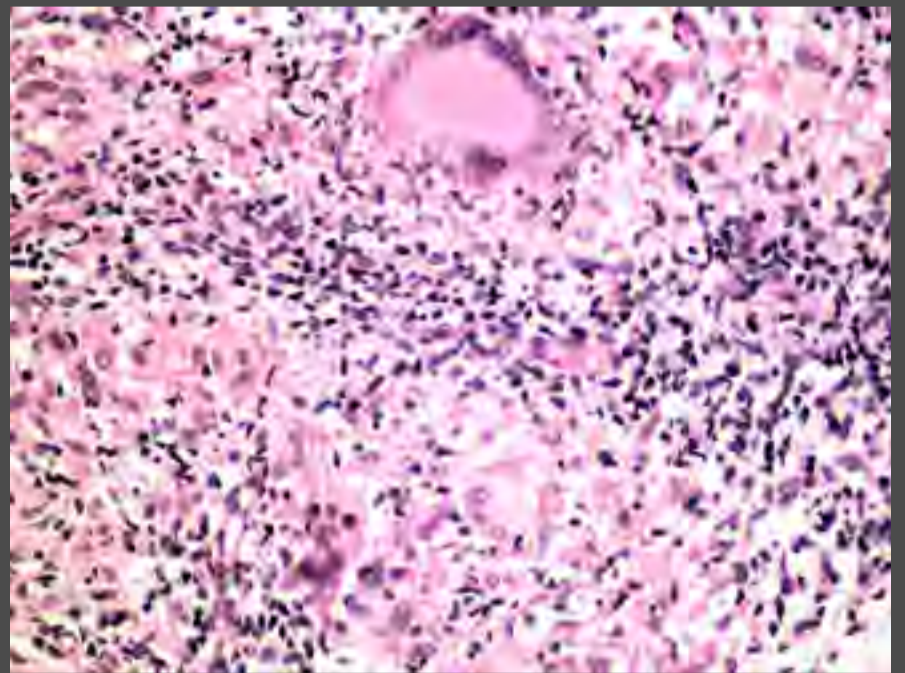
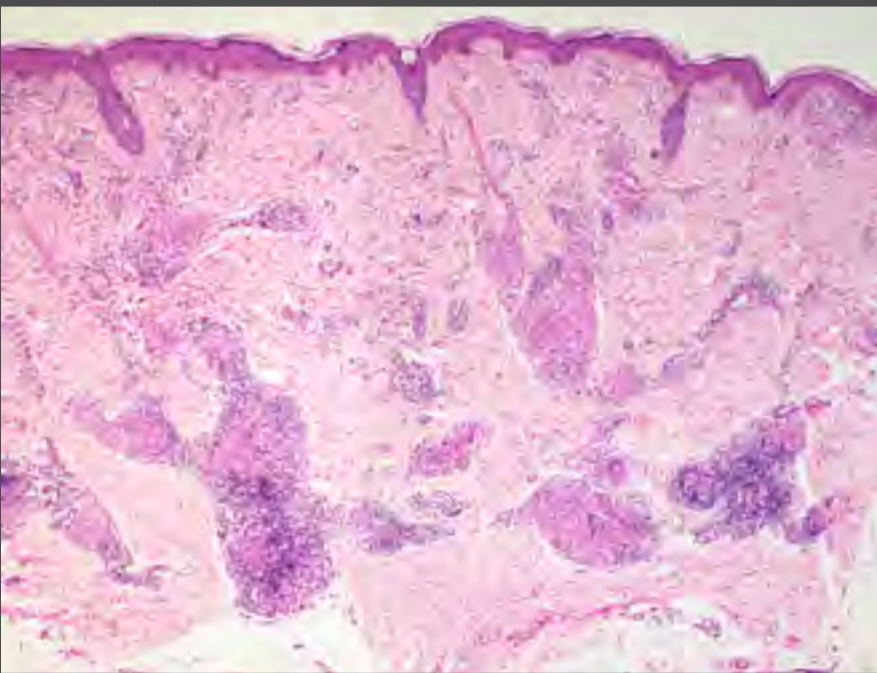
**Figure 3.239B.**

Nasal mucosa biopsies of suspected leishmaniasis. Findings: diffuse inflammation, rich in vacuolated macrophages (Virchow cells), containing abundant bacilli and globi; hematoxylin and eosin, A, 16X.

## Leprosy

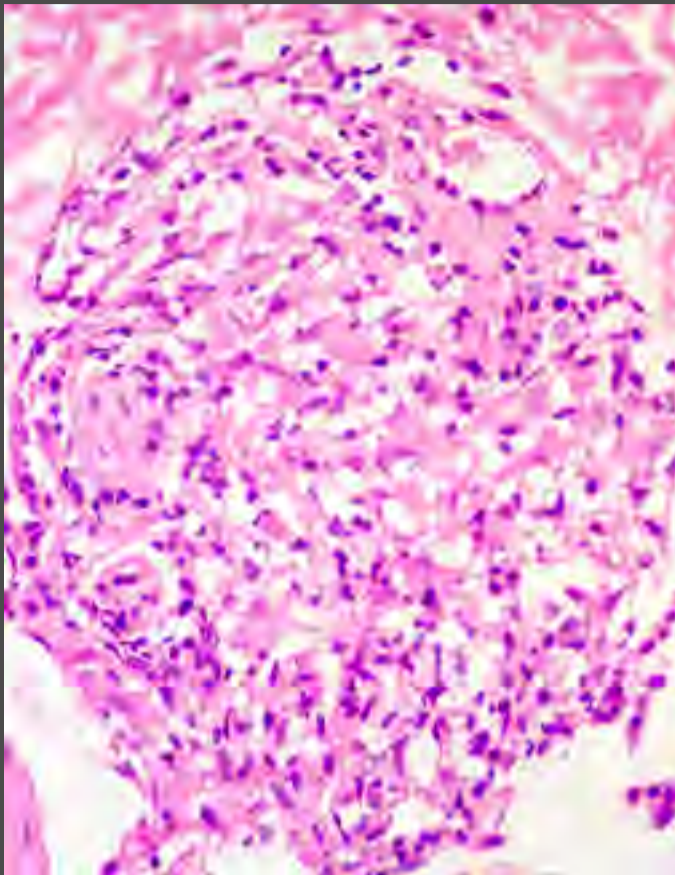


**Figures 3.240A and B.**  
Nodular and plaque lesions, of nodular tuberculoid leprosy of childhood

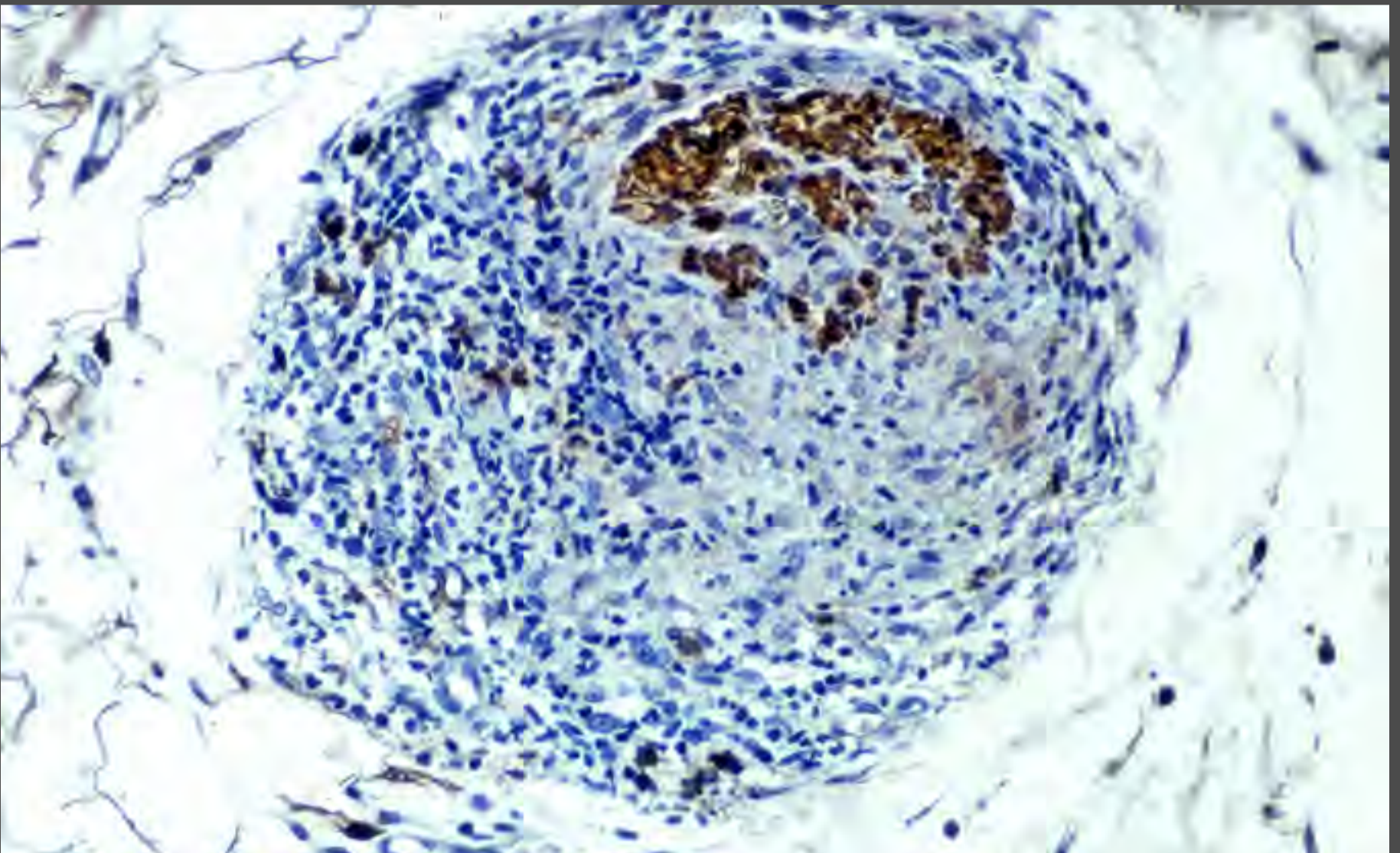


**Figures 3.241A and B.**  
Granulomatous, nodular, epithelioid inflammation, with giant cells and abundant lymphocytes; hematoxylin and eosin, A 2.5X and B 16X.

## Leprosy

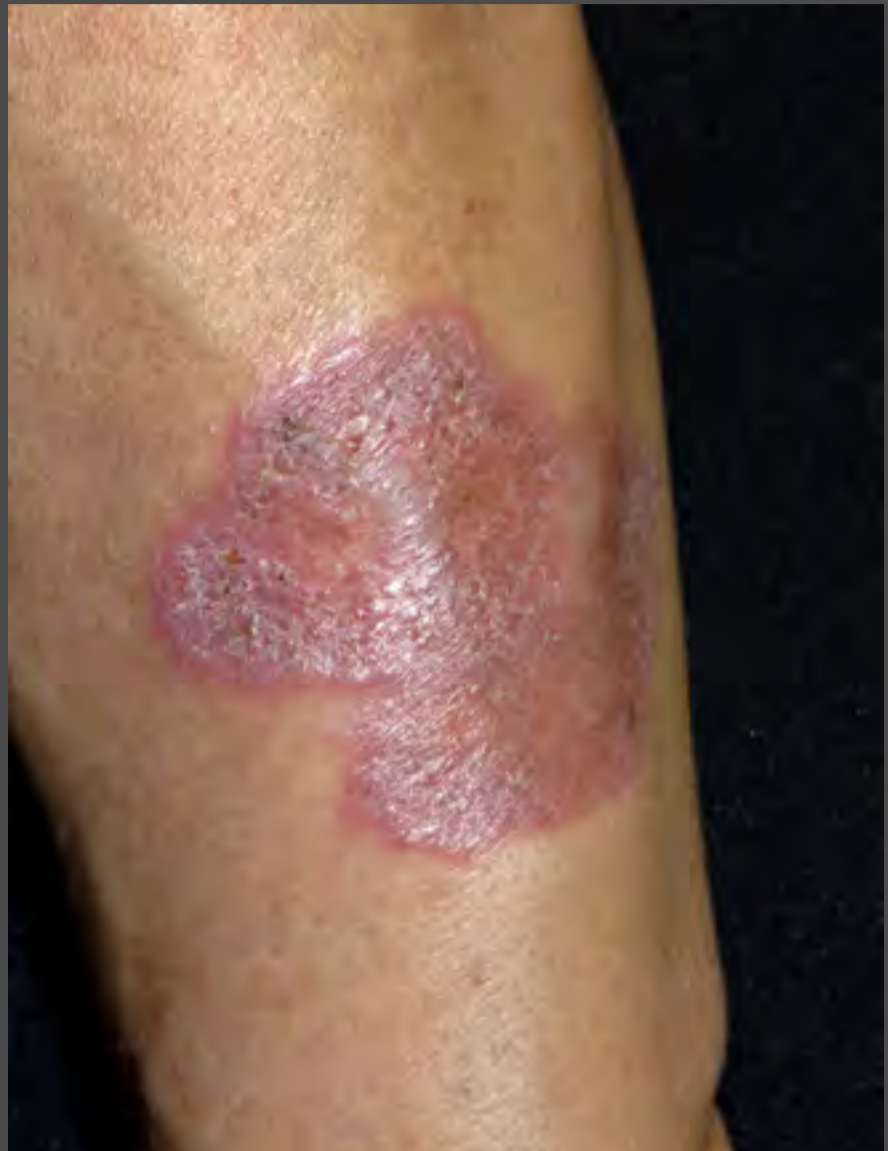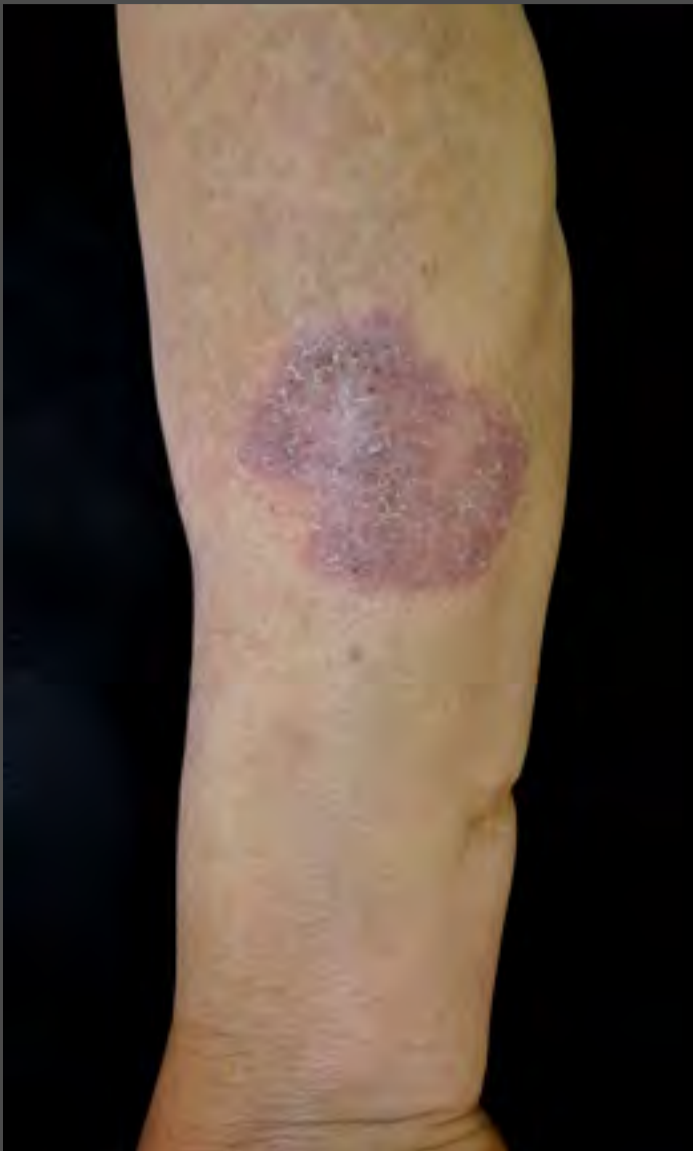**Figure 3.241C.**

A granuloma is seen damaging a nerve (left), which is frayed and disintegrating; hematoxylin and eosin, 16X.

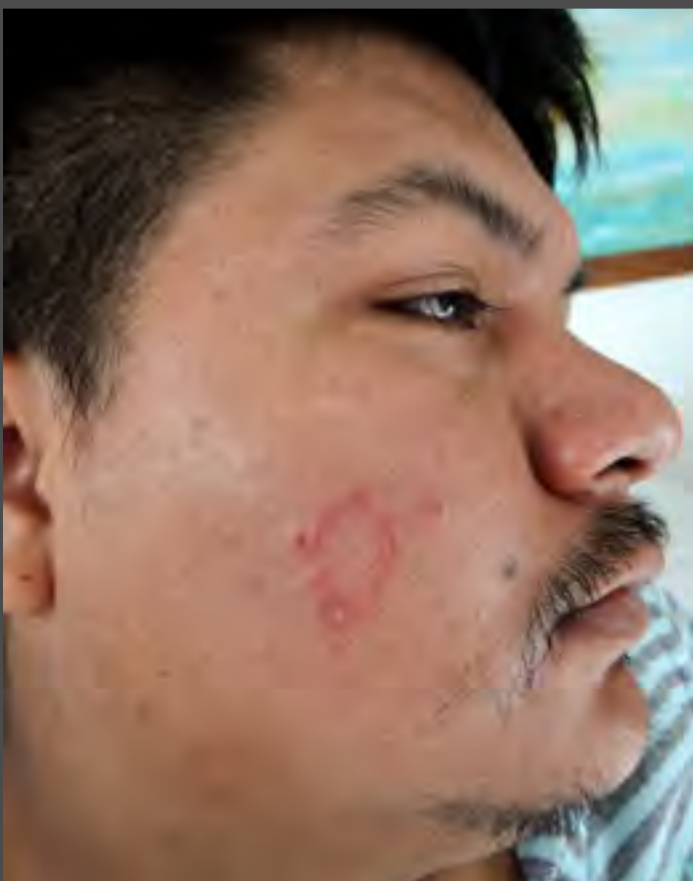**Figure 3.241D.**

Immunohistochemistry technique for S100 protein, 32X

## Leprosy



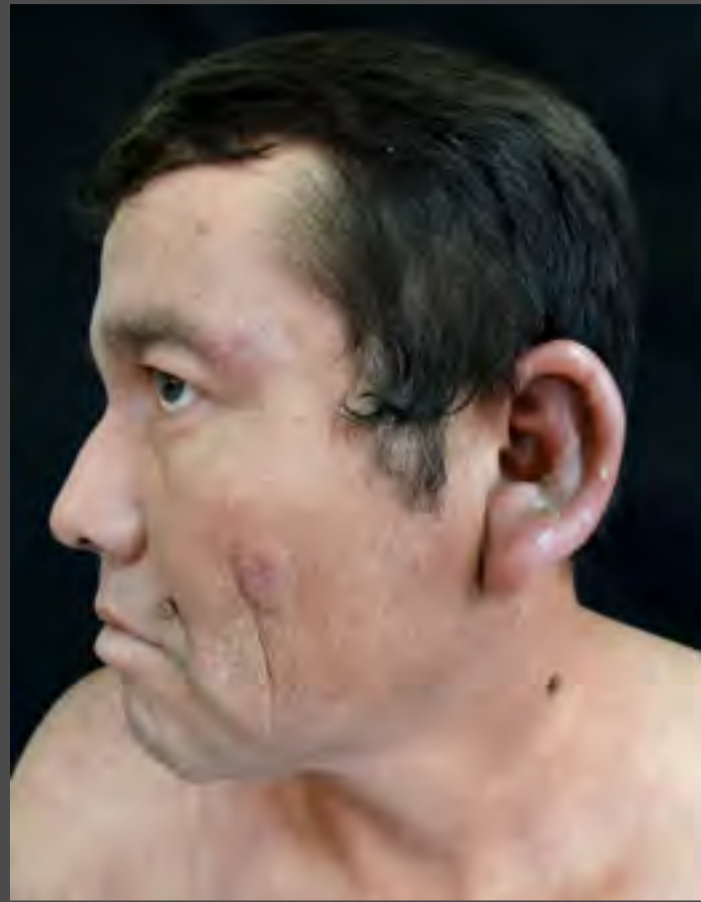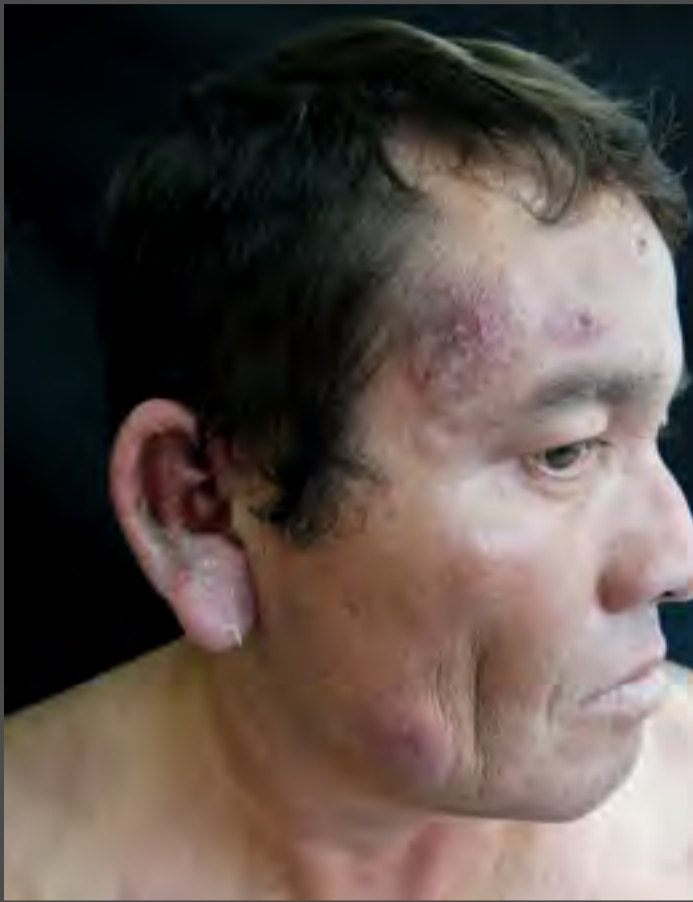**Figures 3.242A and B.**  
Borderline tuberculoid leprosy that should be differentiated from plaque leishmaniasis.



**Figure 3.243.**  
Tuberculoid leprosy that mimics leishmaniasis in plaques on the face.

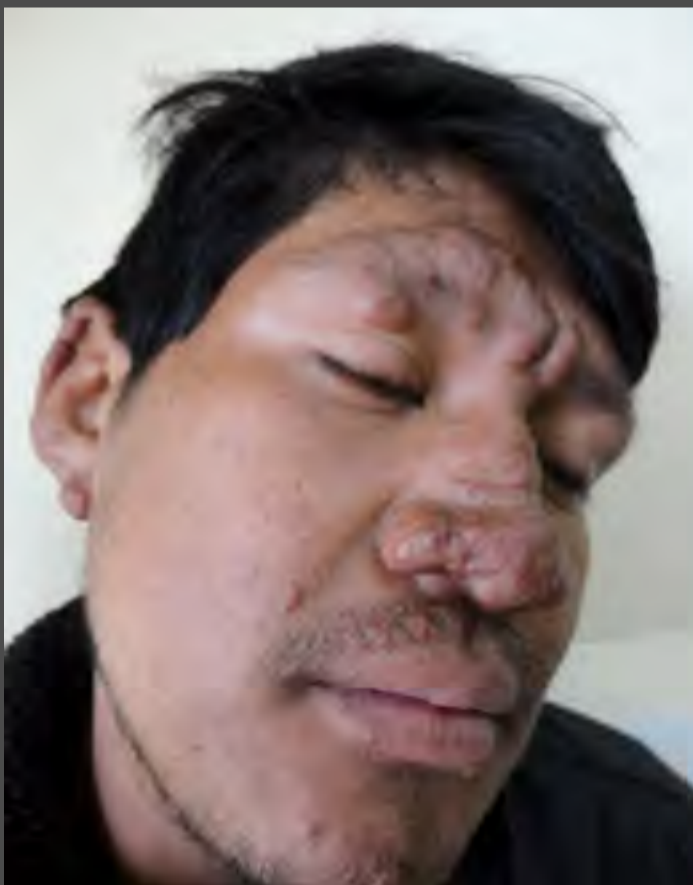

## Leprosy



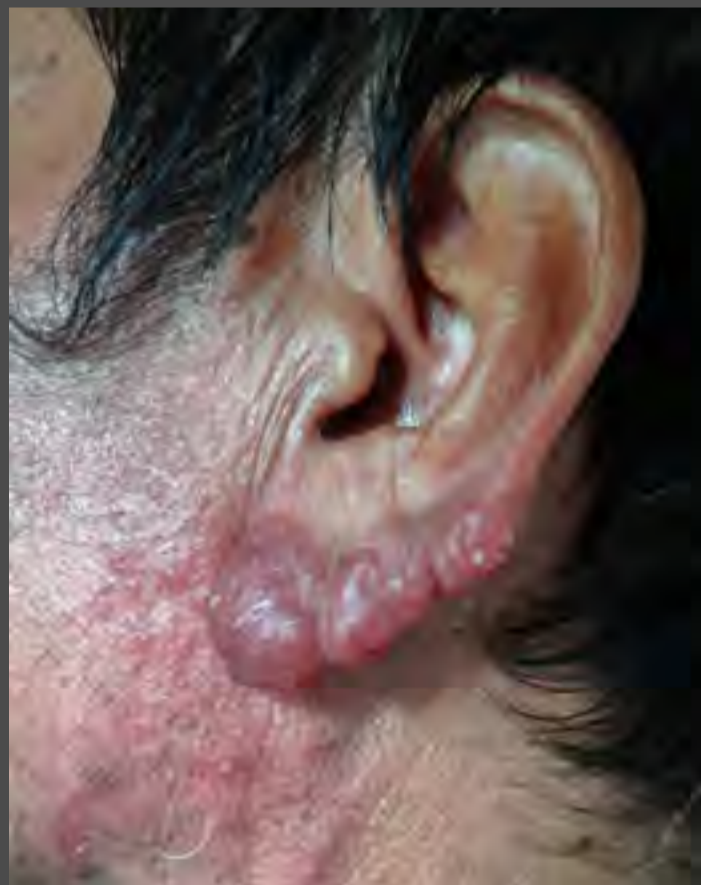**Figure 3.244A and B.**

Lepromatous leprosy with plaques and papules on face and ears



**Figure 3.245A.**

Lepromatous leprosy. Infiltrated lesions on the bridge of the nose. Infiltrated supraciliary and frontal lesions, and madarosis help differentiate it.

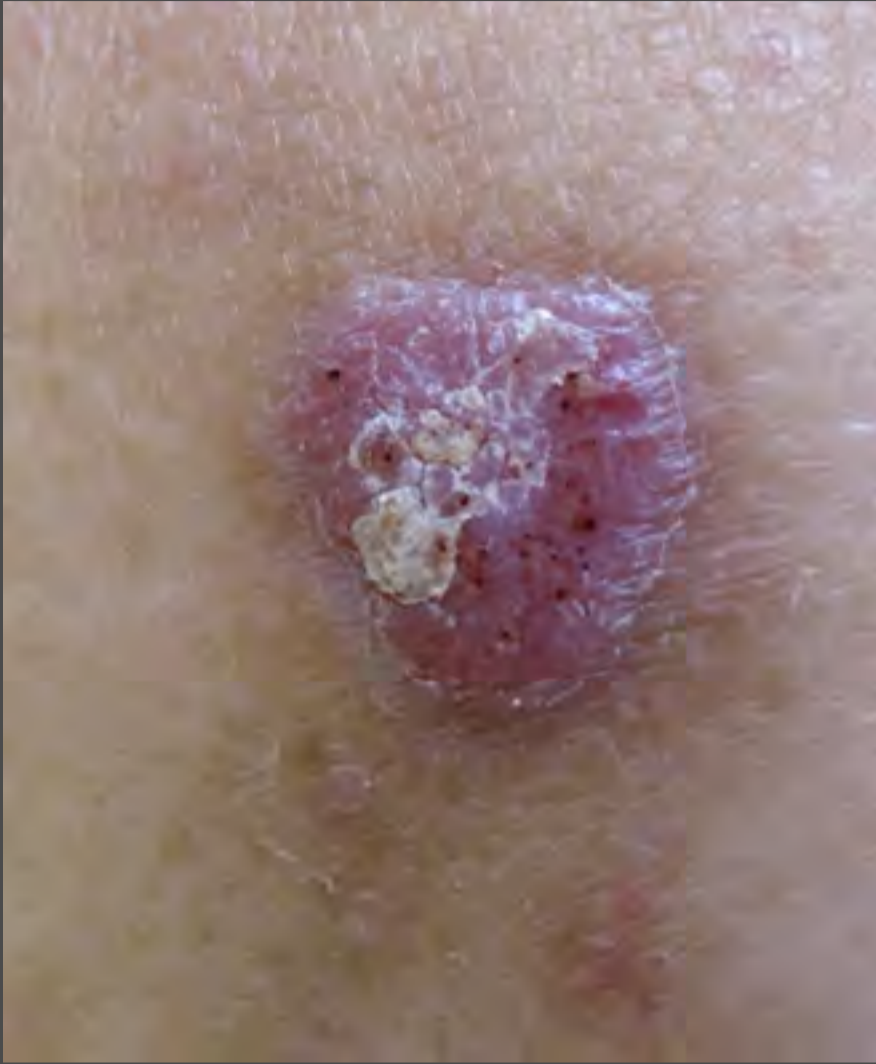

**Figure 3.245B.**

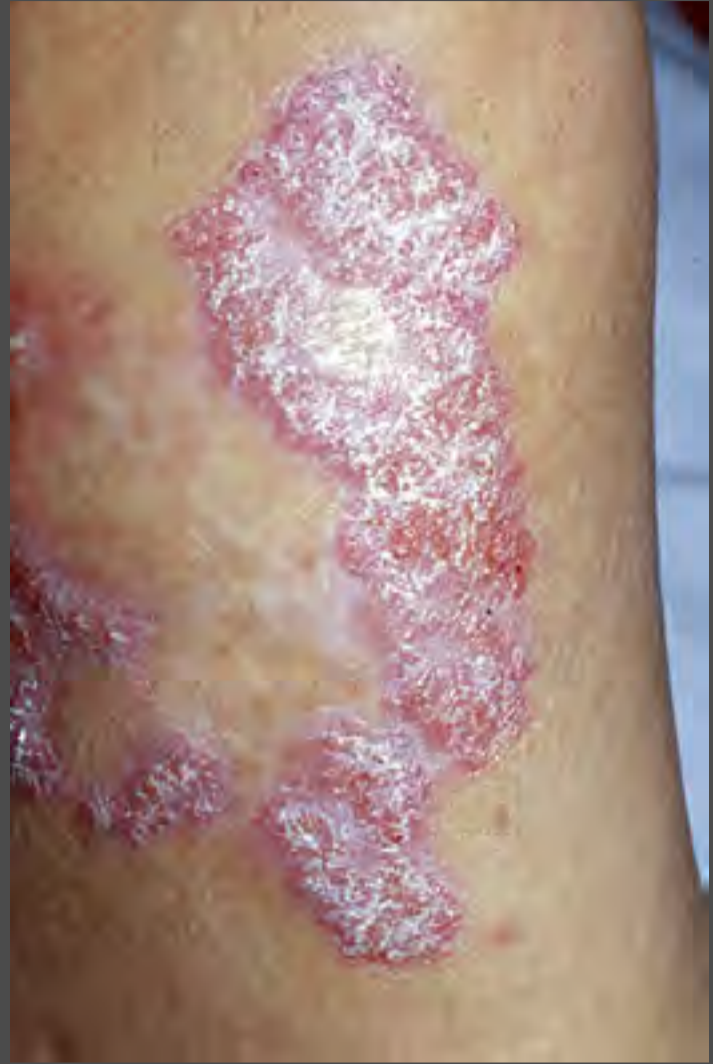Lepromatous leprosy. Plaques and papules on the ear

***Chromomycosis.*** This is a subcutaneous, chronic, slow-growing mycosis that mainly affects the limbs and trunk where the fungus penetrates due to trauma involving plant material or soil. It may be a single small plaque, or multiple and extensive lesions that alternate with erythematous-squamous, crusty, and warty plaques, with scarring areas that alternate with areas of apparently healthy skin; they rarely ulcerate (*Figures 3.246 to 3.247*). Warty areas include abundant brown-reddish points from 0.5 to 1 mm that get confused with blood, but that are actually accumulations of yeast that can be easily identified on direct examination with 10% potassium hydroxide (KOH).

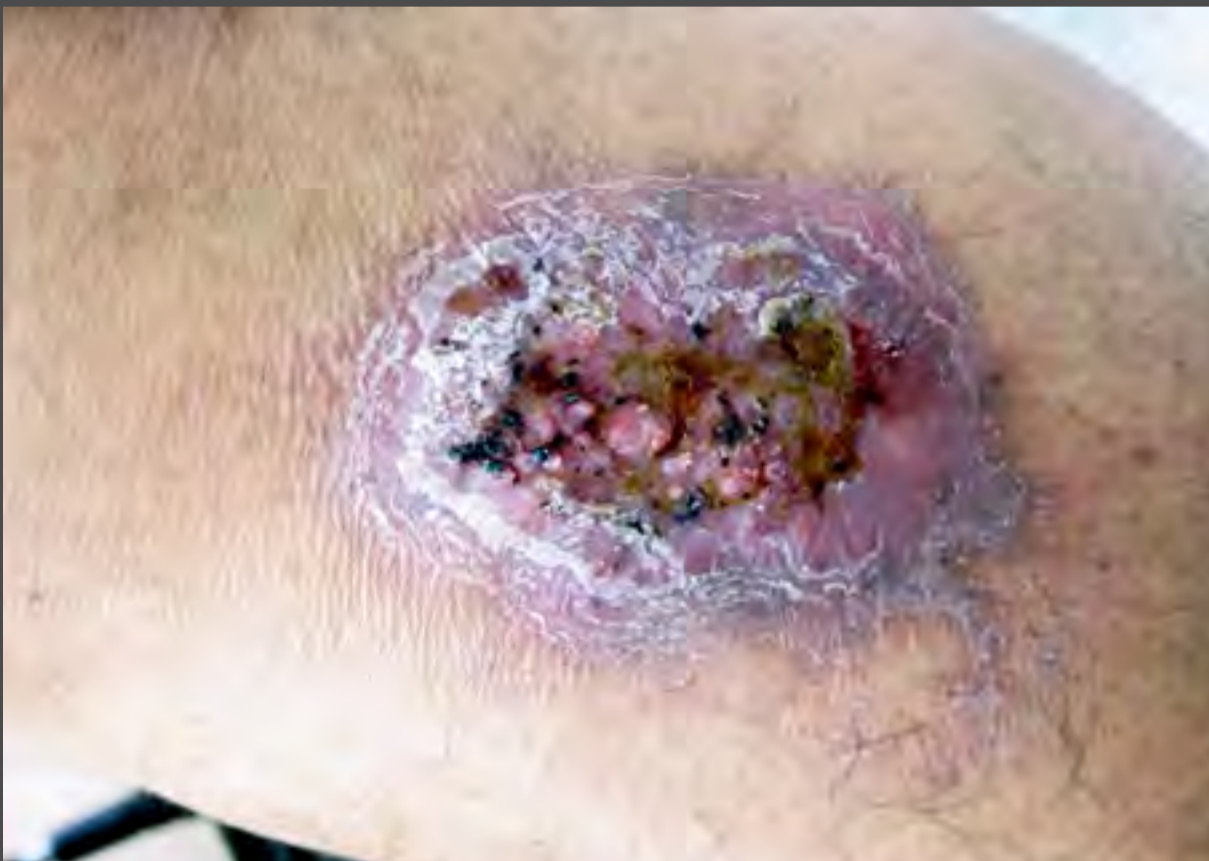## Chromomycosis



**Figure 3.246A.**  
Small erythematous, infiltrated plaque covered by large crusts and scales, with other small adherent brown crusts. It takes several months to two or three years to reach this size.

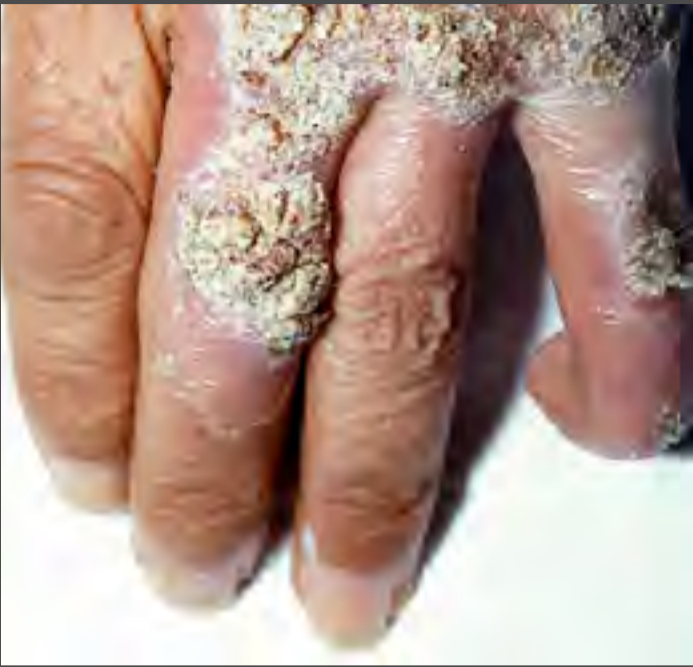

**Figure 3.246B.**  
Leishmaniasis in plaques. This looks similar to the previous figure, but is only a few months old.



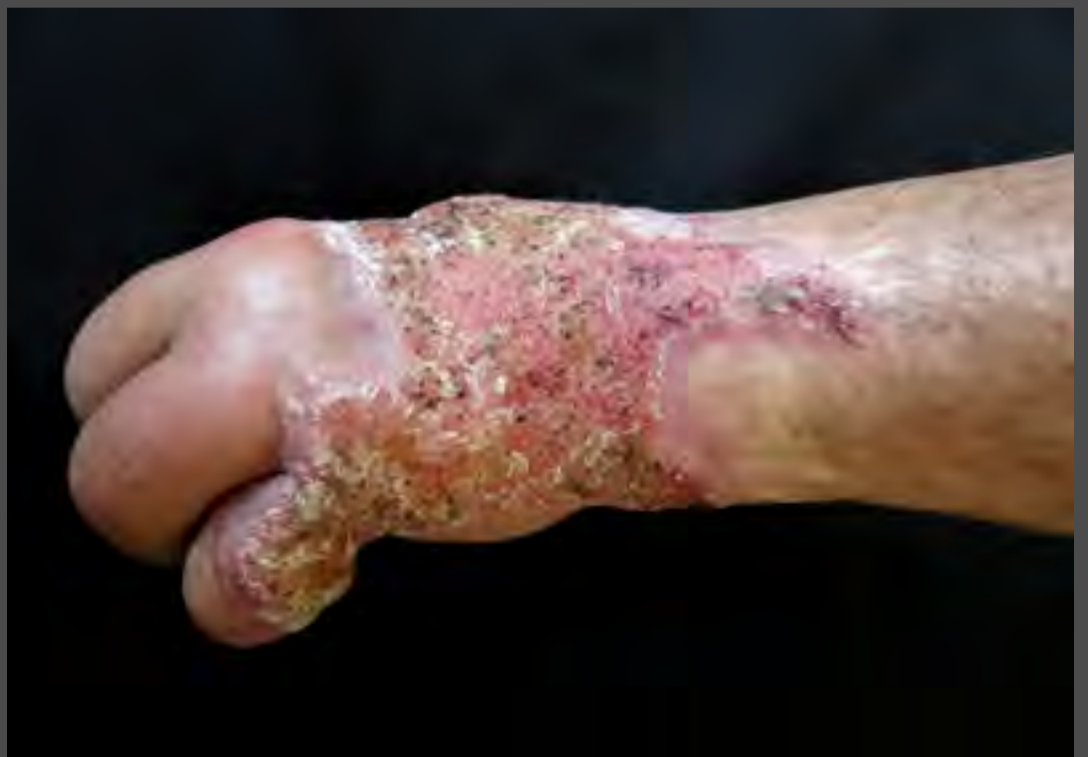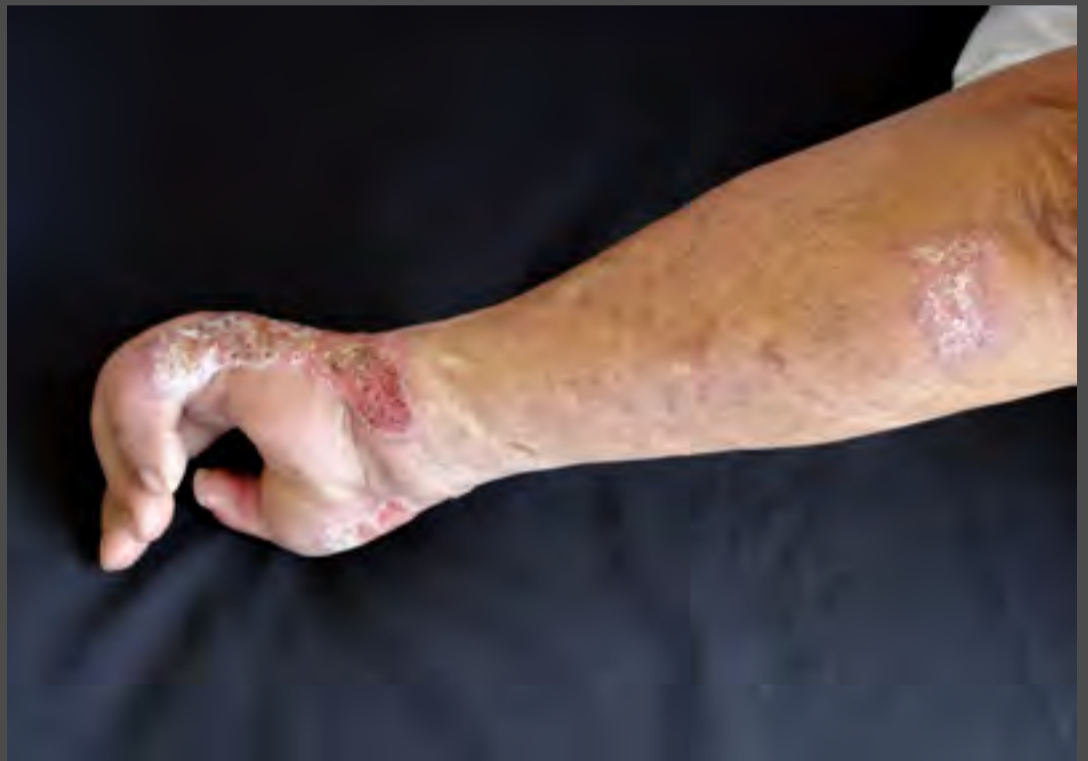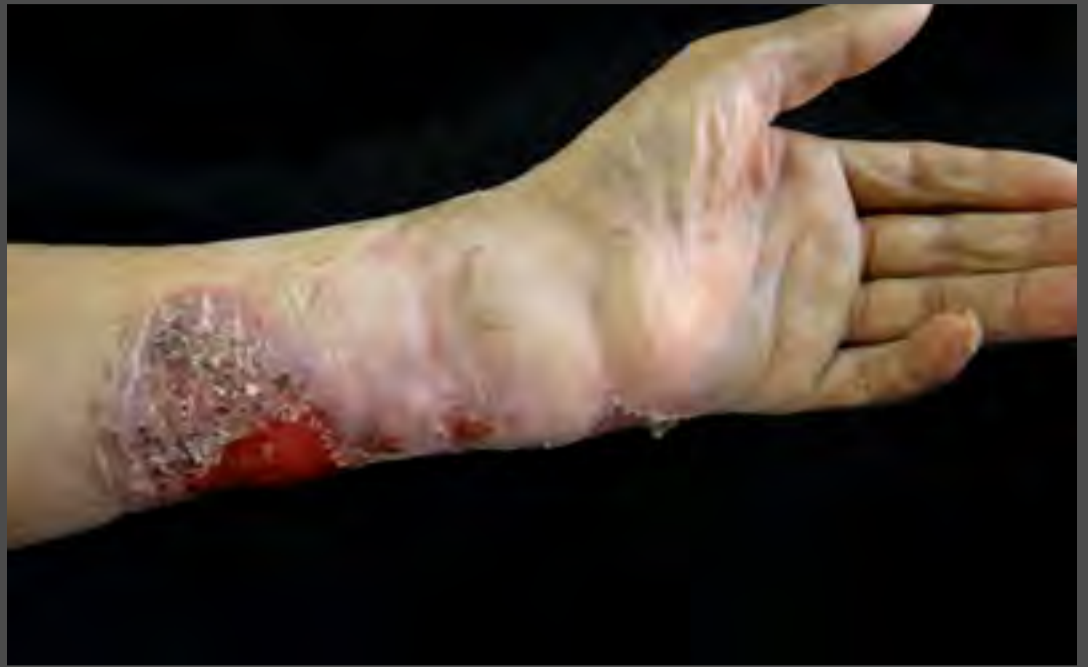**Figure 3.246C.**  
Extensive ulcerated plaque with thick edges, granular floor, and black dots. Direct smears from these sites more easily reveal sclerotic (Medlar) bodies.

## Chromomycosis

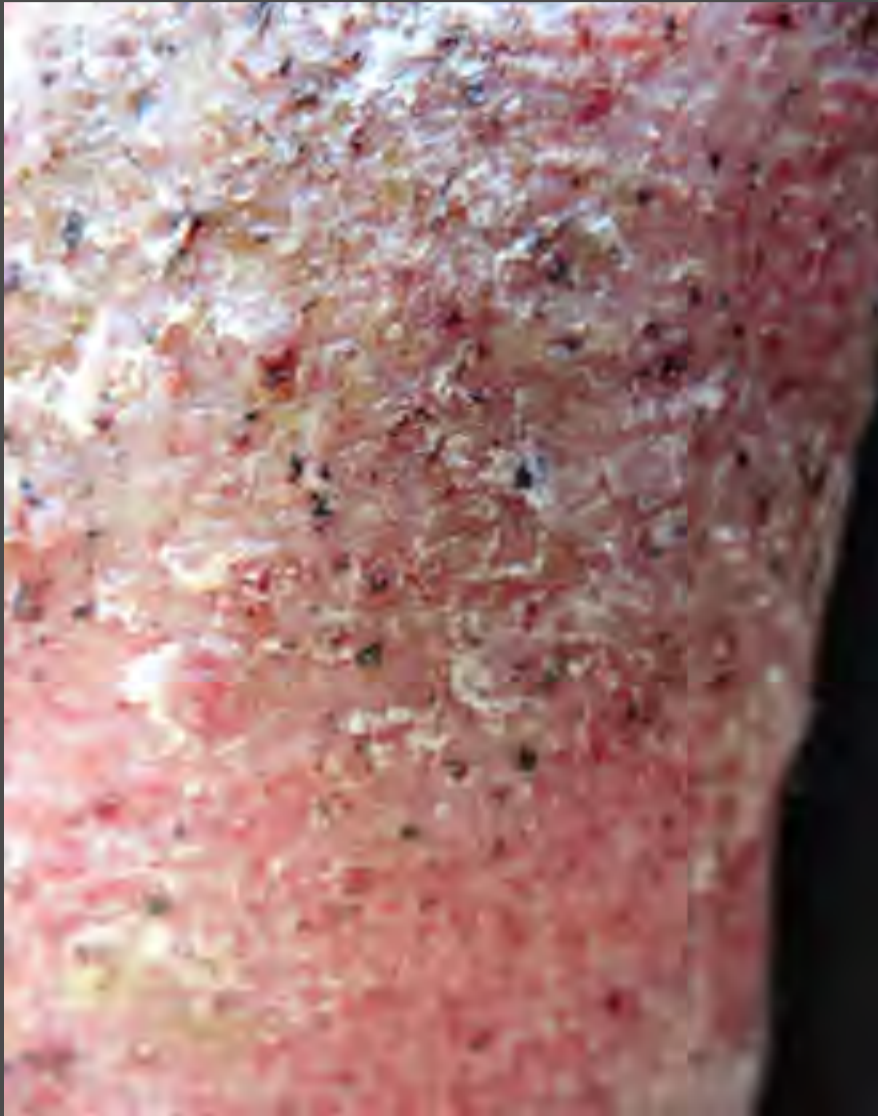

**Figure 3.246D.**  
Warty hyperkeratotic plaques, “tropical verrucous syndrome”

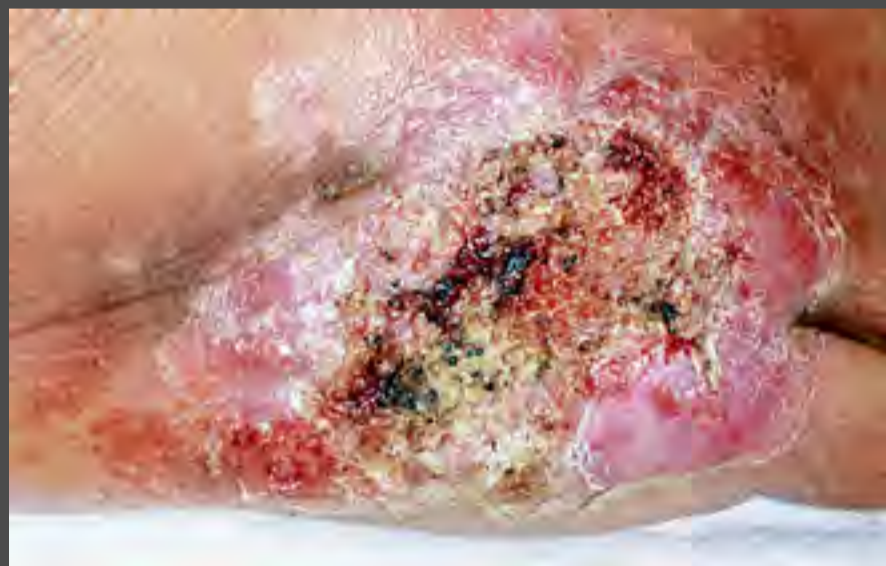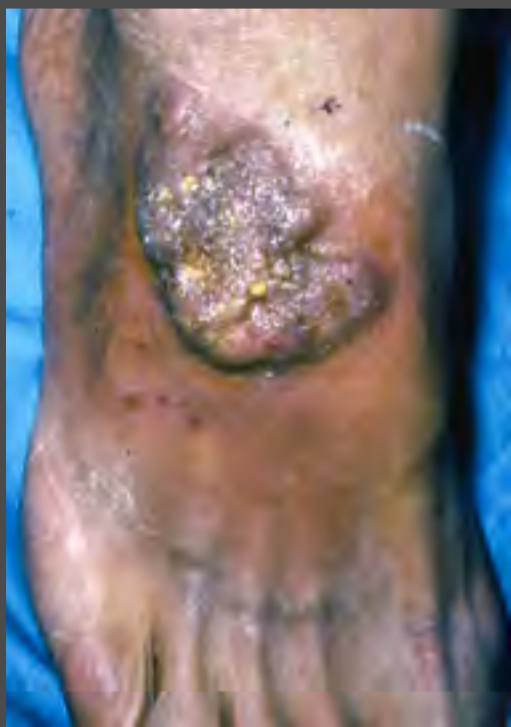**Figures 3.246E, F and G.**  
Small to mid-size, infiltrated plaques that alternate with ulcerative areas, and other areas in which residual scars and areas of healthy skin are visible.



## Chromomycosis



**Figure 3.246H.**  
Close-up showing dark brown grains that are accumulations of mycotic cells.

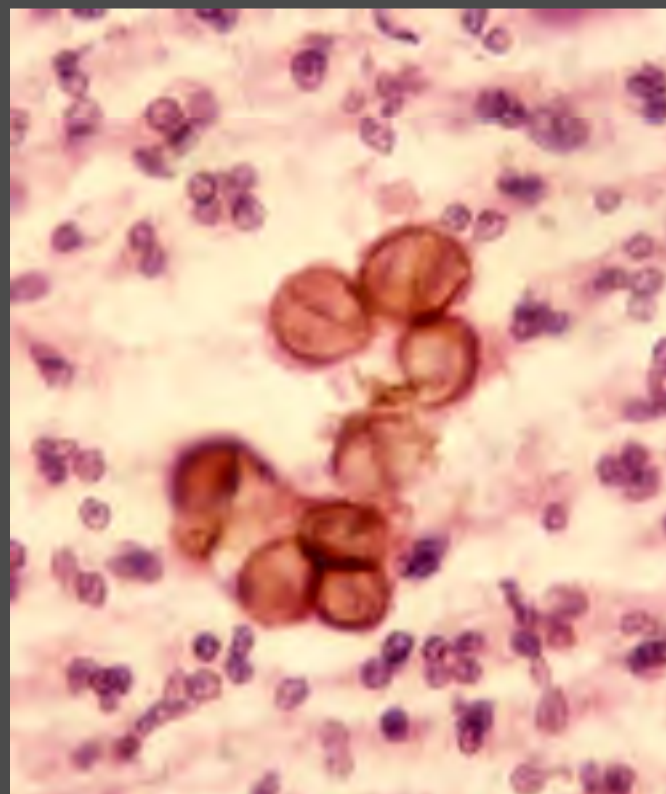
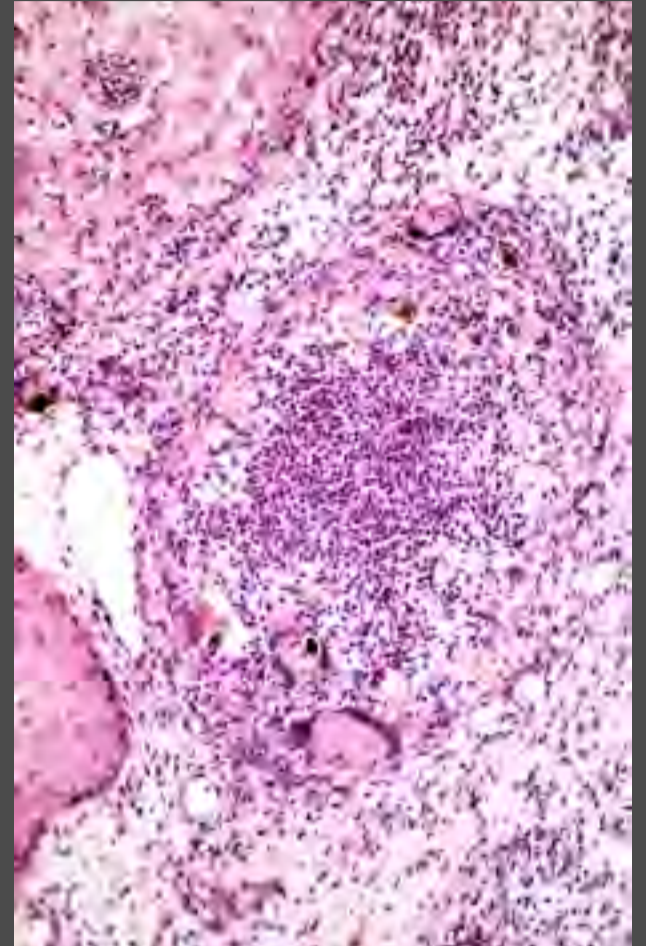
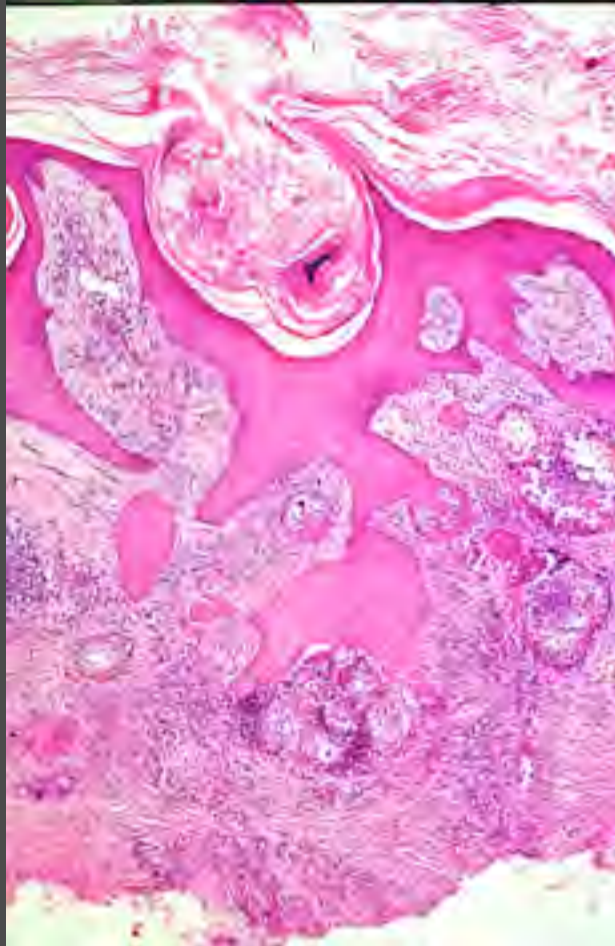


**Figure 3.246I and J.**  
Ulcerated, crusty, hyperkeratotic, and irregular plaques

## Chromomycosis

**Figure 3.247A.**  
Skin with pseudocarcinomatous hyperplasia and dermis with epithelioid granulomata with central abscesses; hematoxylin and eosin, 4X

**Figure 3.247B.**  
Sclerotic (Medlar) bodies, brown dematiaceous or pigmented fungi, are phagocytized by giant or free cells in the abscess, surrounded by neutrophils; hematoxylin and eosin, 20X.



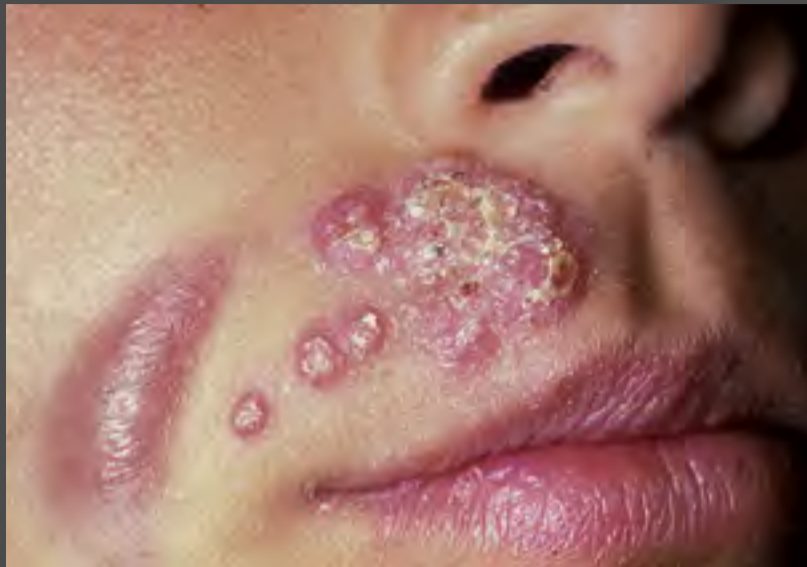**Figure 3.247C.**  
Sclerotia are also seen in the stratum corneum; hematoxylin and eosin, 64X

**Figure 3.247D.**  
Greater magnification of sclerotic bodies, with central cleft in some, surrounded by neutrophils; hematoxylin and eosin, 100X

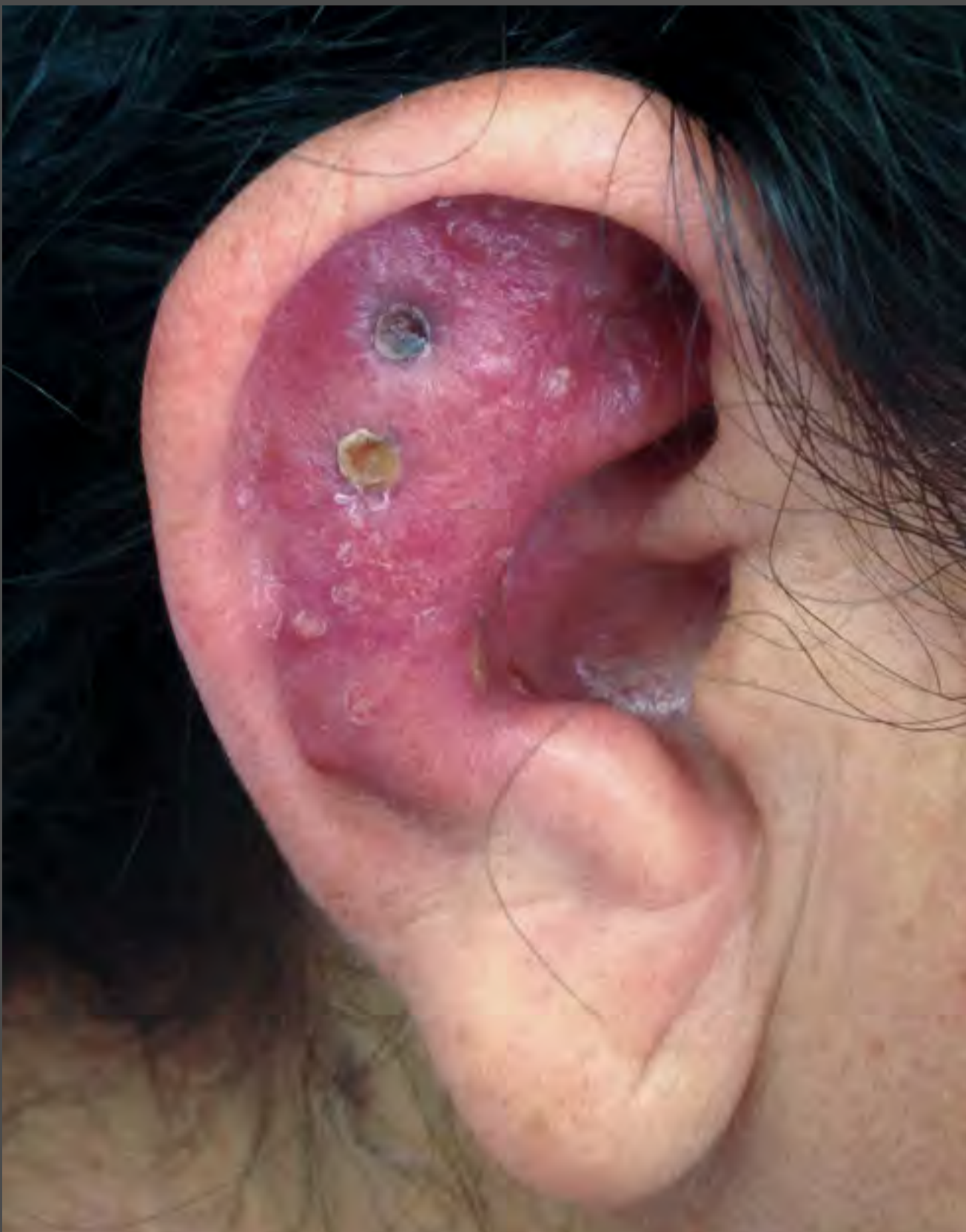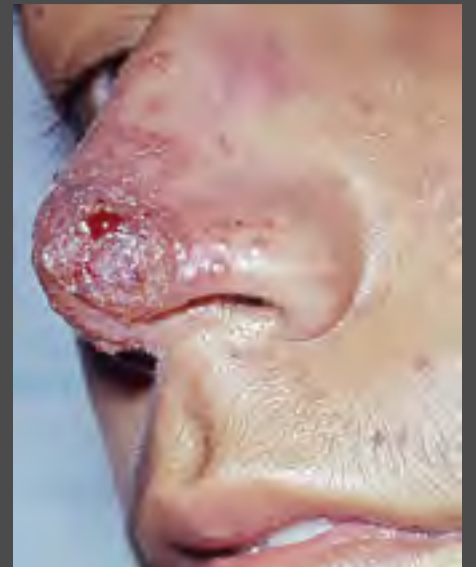***Sporotrichosis.*** This is a subcutaneous mycosis that most often appears on the extremities as nodules, plaques, or fixed ulcers (gummas) that may have bloody seropurulent drainage and that follow an upward lymphatic pathway that advances rapidly, in days or weeks (*Figures 3.248 to 3.251*). Although leishmaniasis lesions have more or less the same clinical characteristics and the same progression, in sporotrichosis it is common for the oldest lesion to be the most advanced—almost always ulcerated or a gumma—while more recent lesions—the more proximal—are barely papules or nodules.

## Sporotrichosis

**Figure 3.248A.**  
Linear nodule and plaque  
formed by erythematous  
hyperkeratotic papules



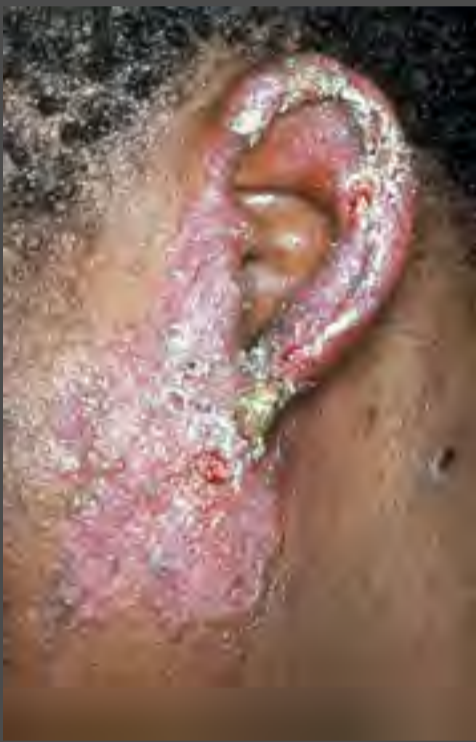**Figure 3.248B.**  
Erythematous, micropapular,  
ulcerated plaque



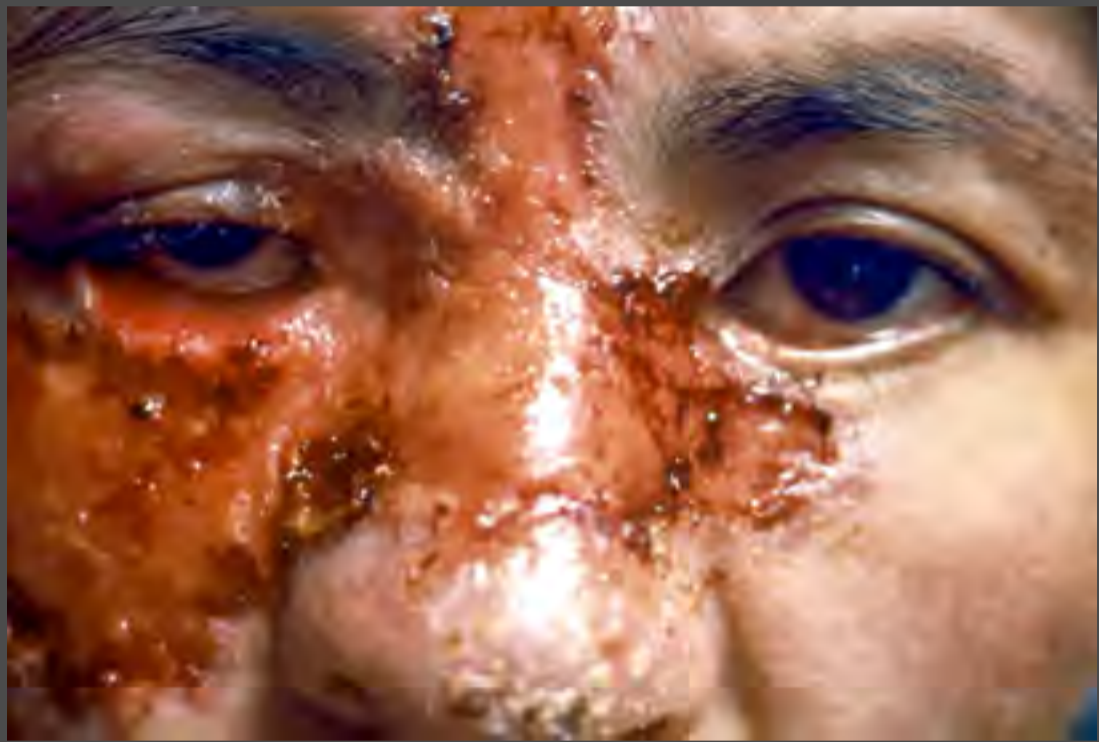**Figure 3.248C.**  
Erythematous infiltrated  
plaque, with some pustules



## Sporotrichosis

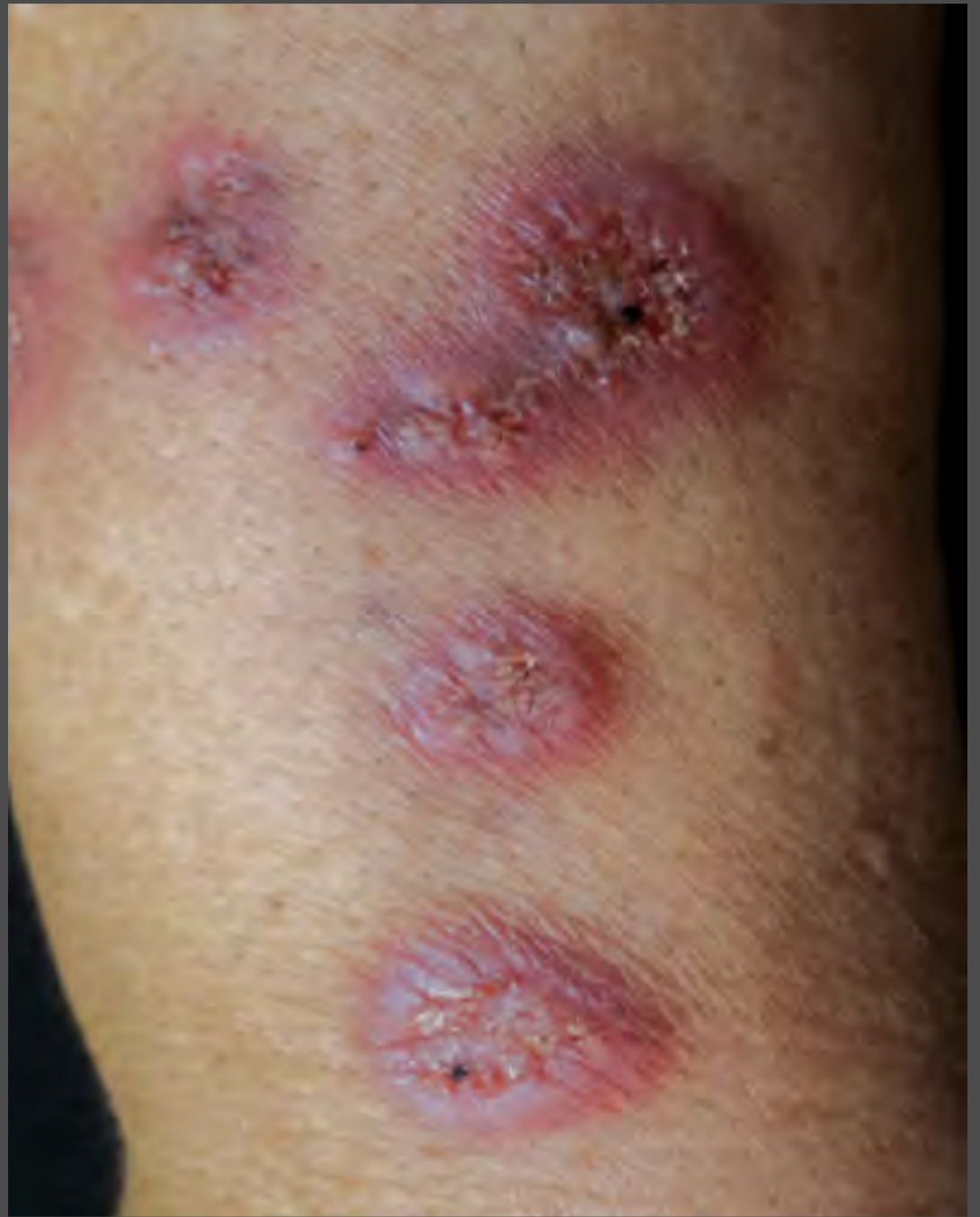
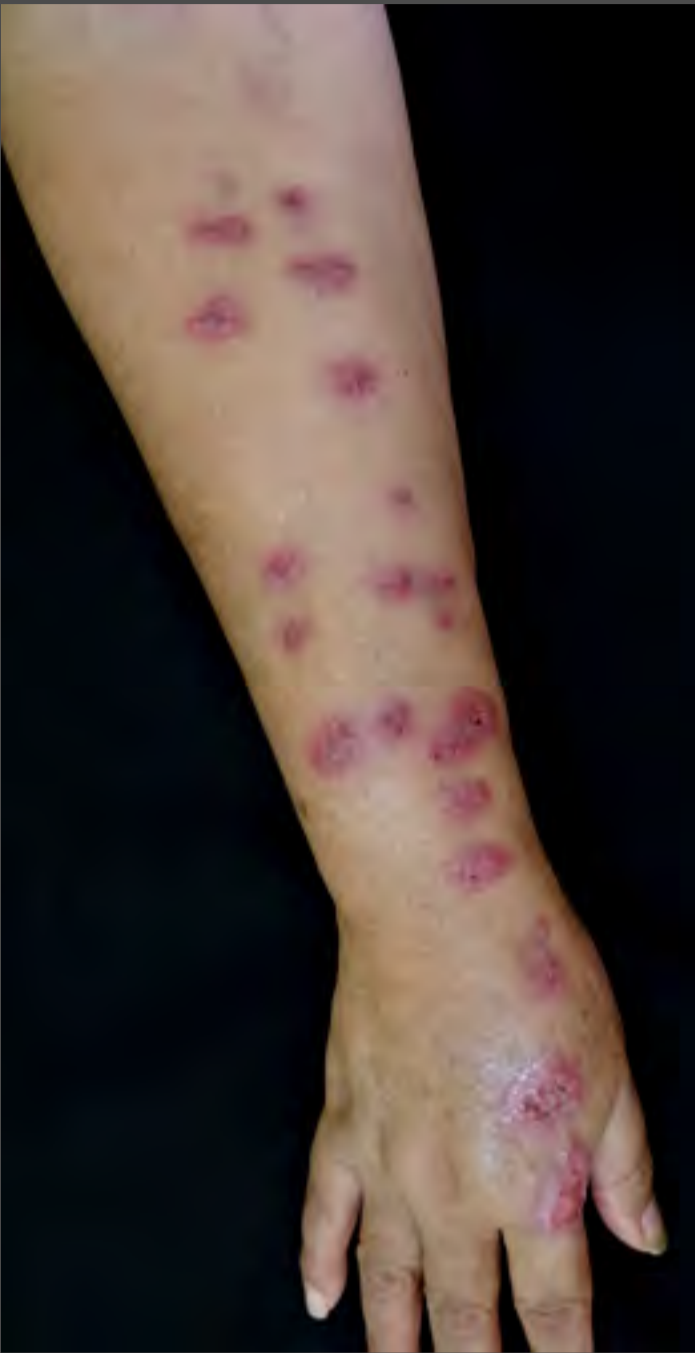
**Figure 3.248D.**  
Crusty plaque with erosions,  
on auricle and adjacent skin



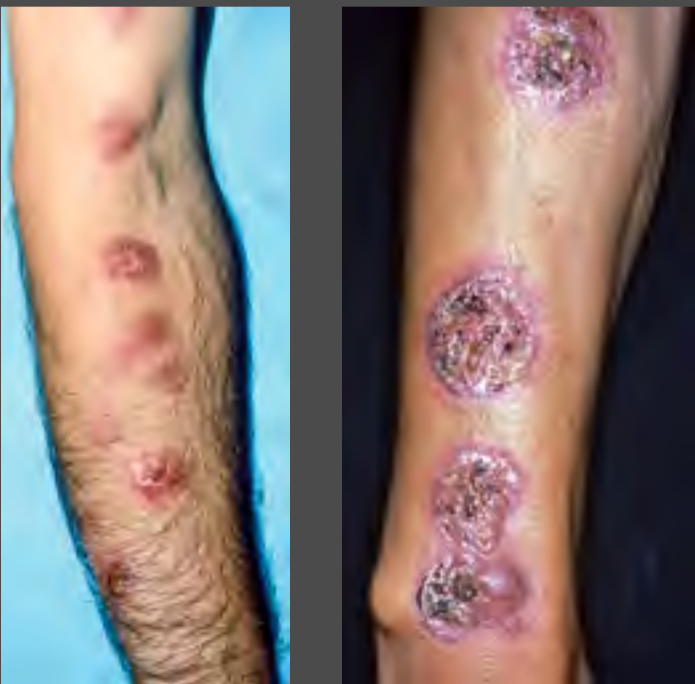**Figure 3.248E.**  
Extensive facial ulcer in a woman  
with generalized sporotrichosis

## Sporotrichosis



**Figures 3.249A and B.**

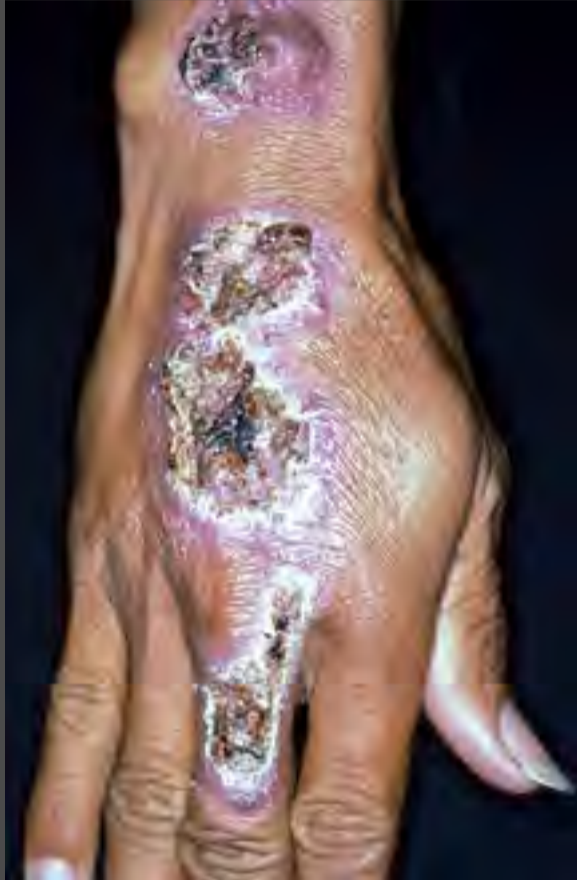Lymphangitic dissemination. Lesions tend to be ulcerated soft nodules in the same stage of development in the entire area, unlike the course of lymphangitic leishmaniasis.



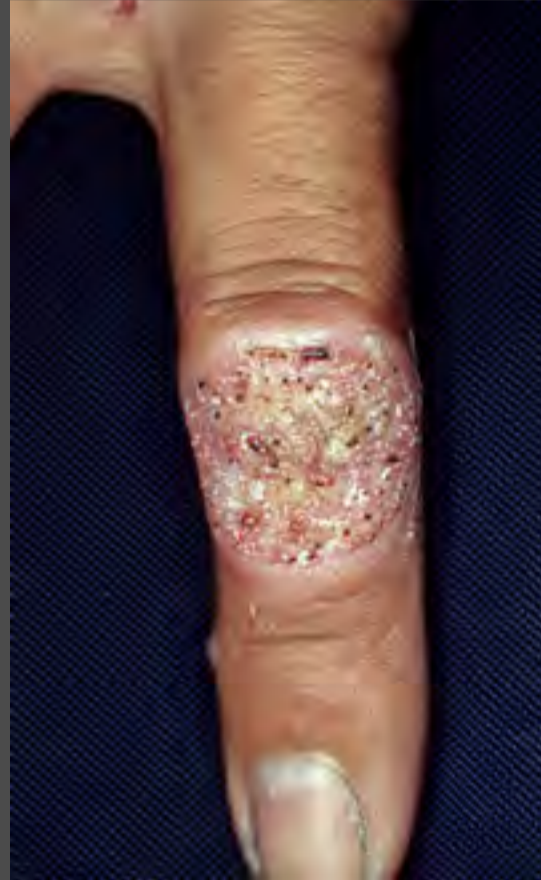**Figure 3.249C and D.**

Lymphangitic dissemination. Plaques and nodules, some ulcerated, in a line on arms

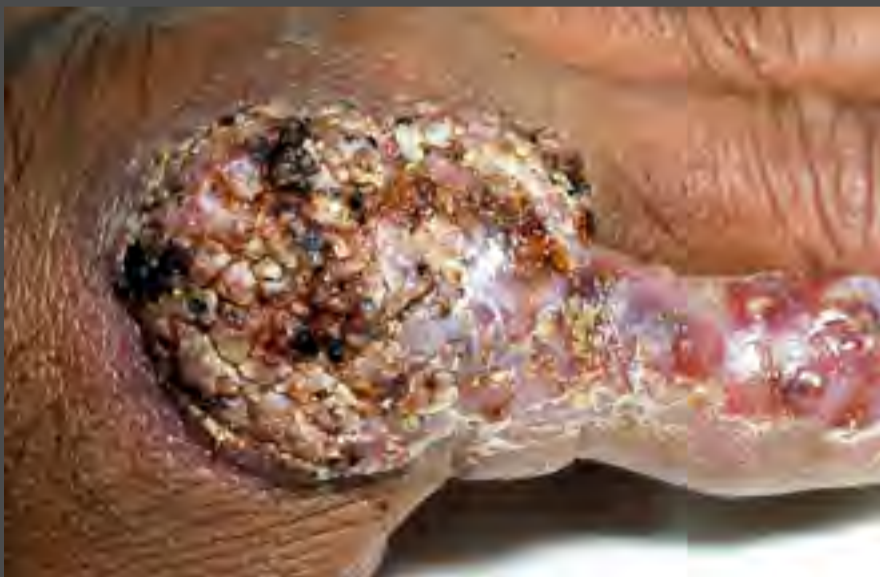## Sporotrichosis



**Figure 3.249E.**  
Back of hand. Ulcerated,  
hyperkeratotic, plaques in a line,  
with lymphangitic spread

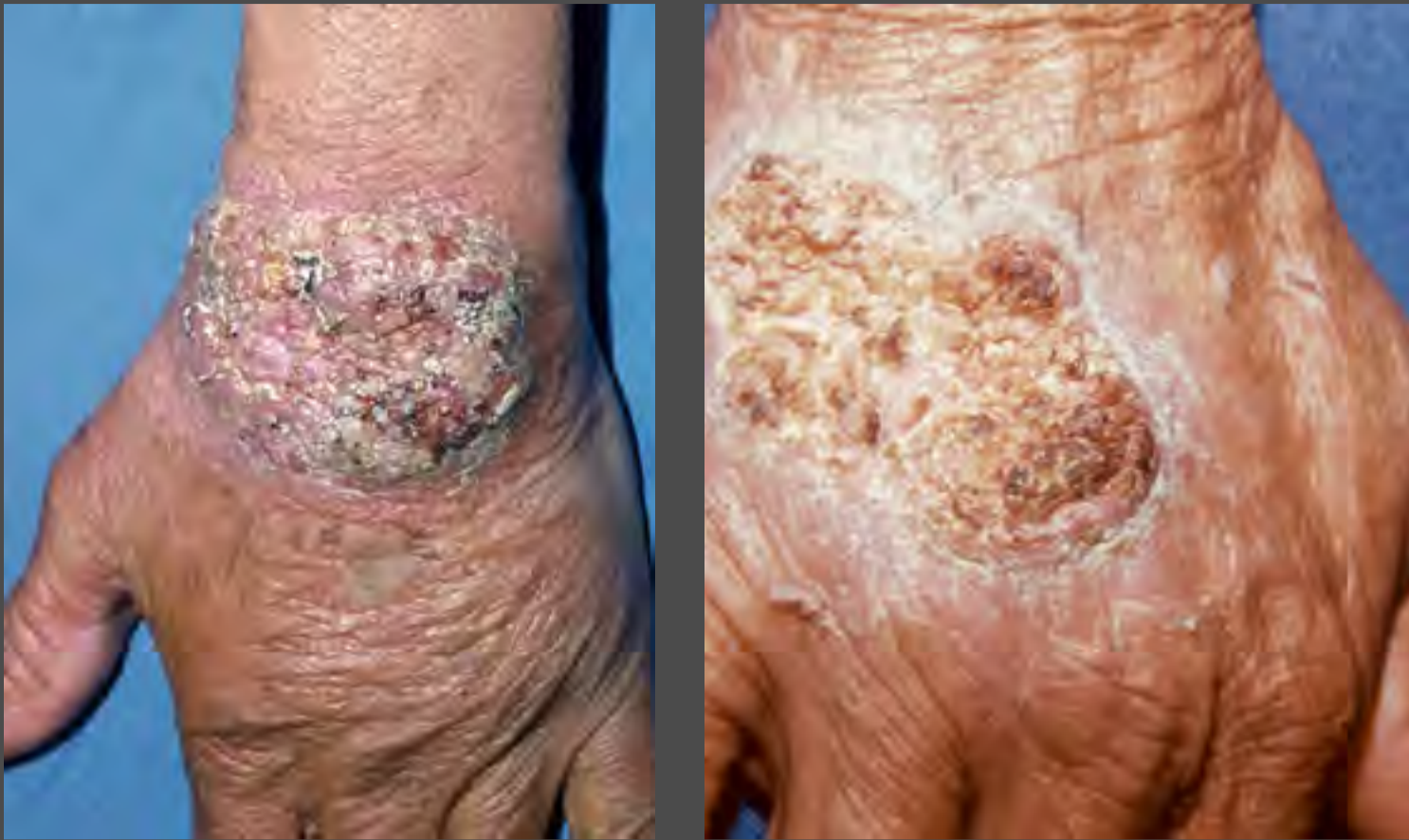

**Figure 3.249F.**  
Initial lesion on ulnar side of  
forearm, showing an ulcerated  
crusty plaque, with some purulent  
secretions; lymphangitic  
dissemination has not yet begun.

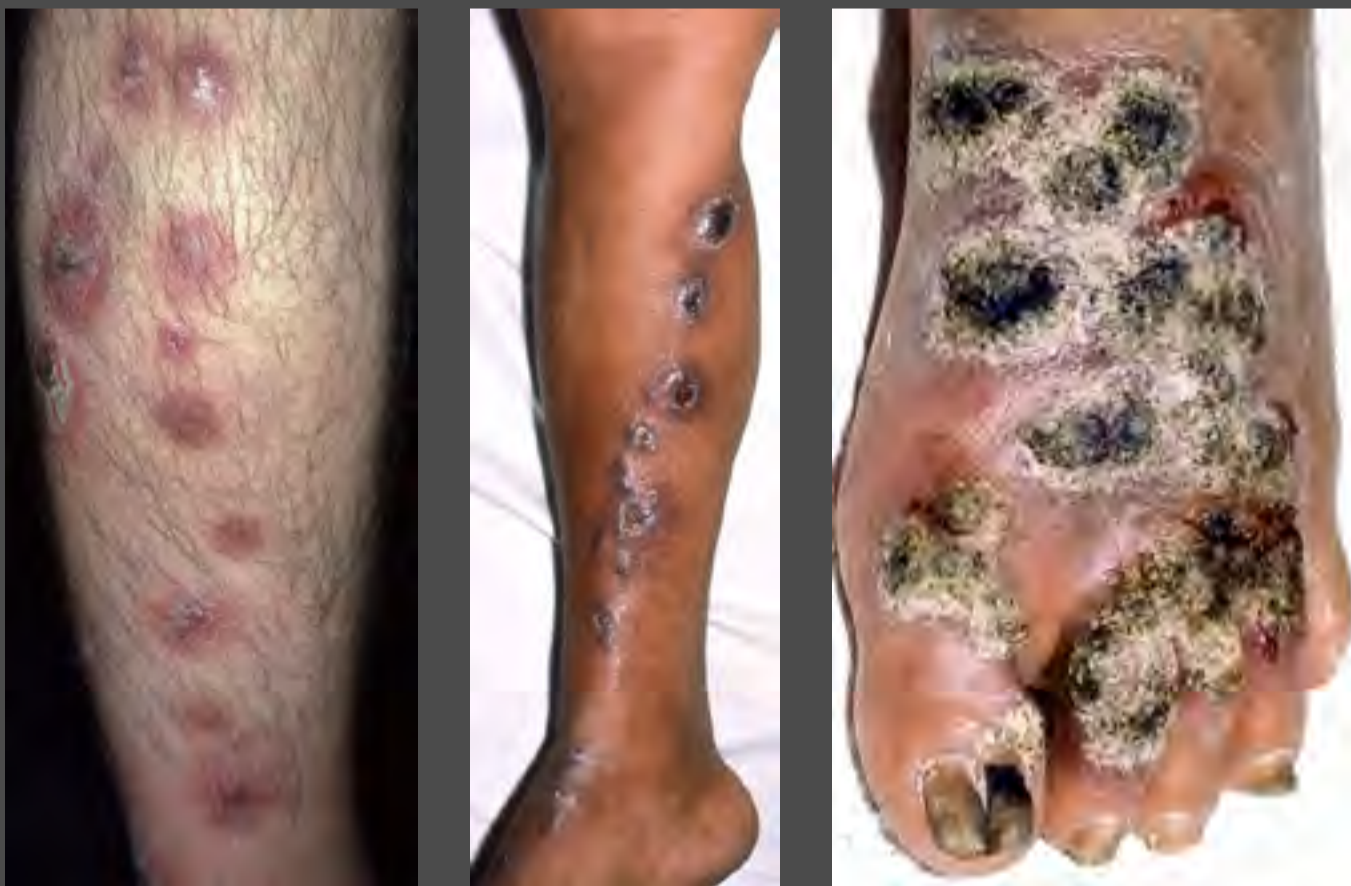

**Figure 3.249G.**  
Back of hand and index  
finger. Extensive ulcer  
with thick edge and  
floor with cobblestone  
appearance and black dots  
from hemorrhage foci.

## Sporotrichosis



**Figures 3.249H e I.**  
Ulcerated, warty plaques. Part of “tropical verrucous syndrome.”



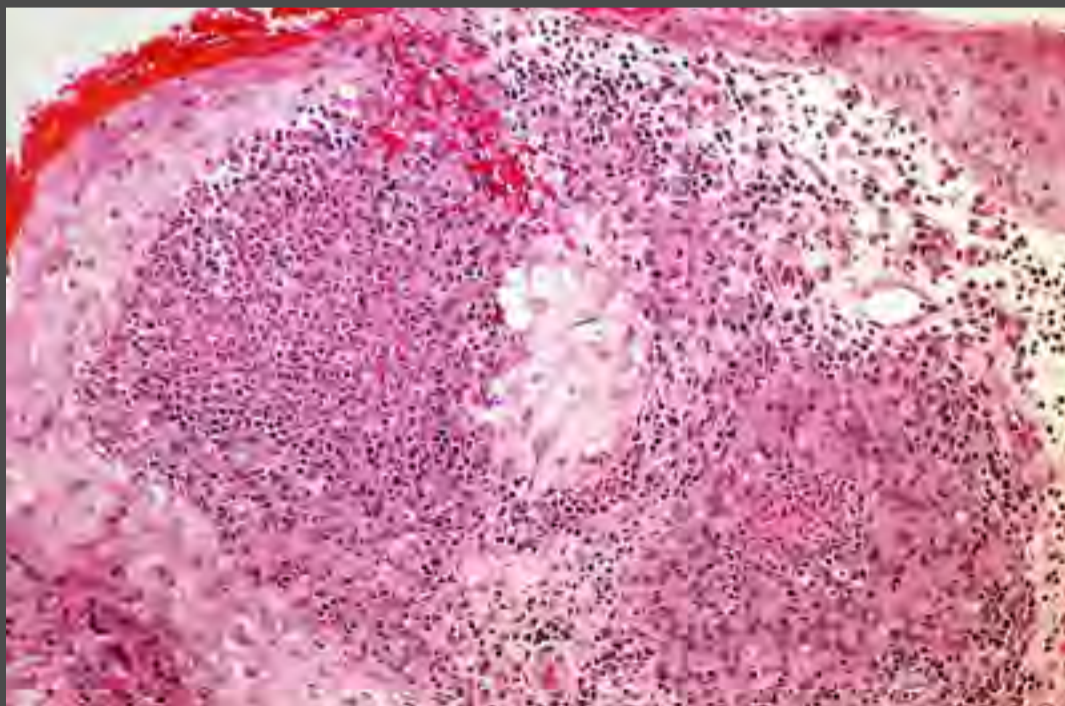
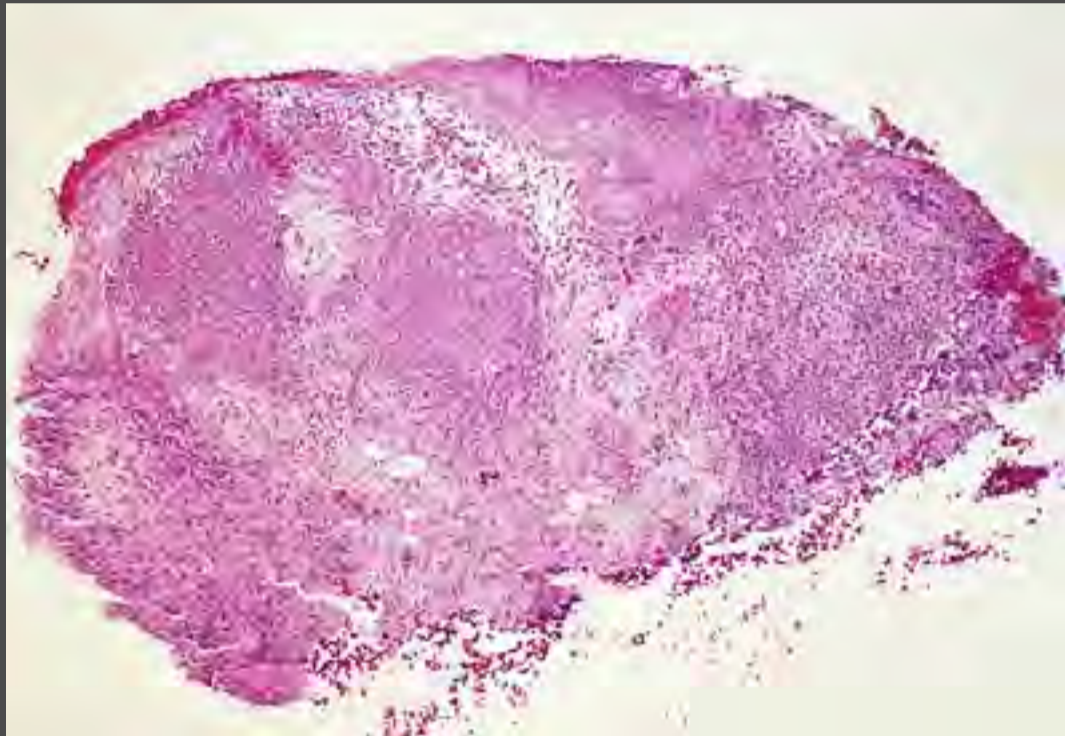
**Figures 3.250A and B.**  
Lymphangitic dissemination. A line of nodules on legs

**Figure 3.250C.**  
Extensive, ulcerated, confluent plaques, with black scaly crusts from deposits of blood in the epithelium and stratum corneum.

## Sporotrichosis

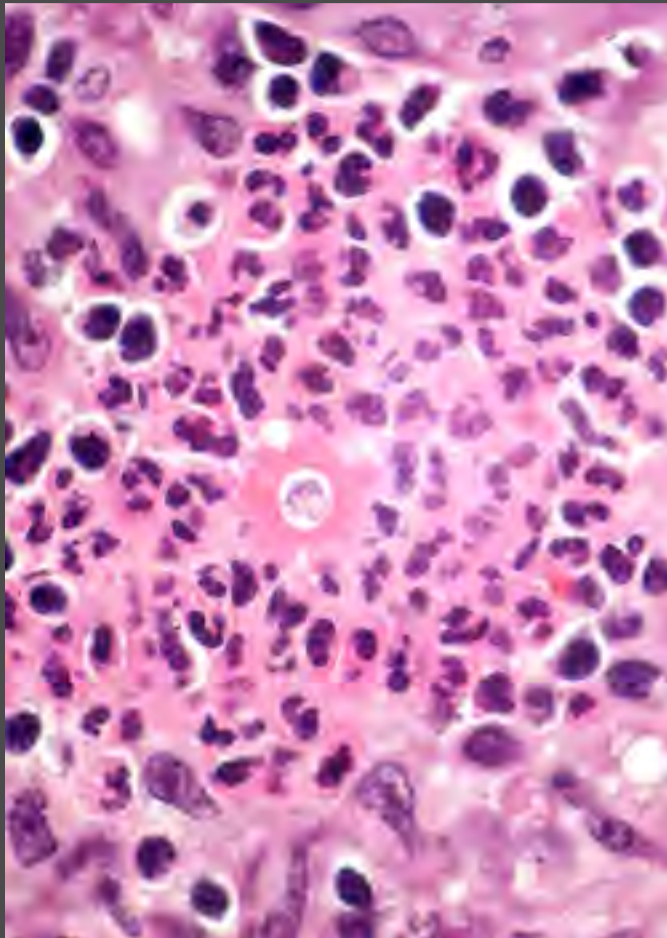
**Figure 3.251A.**

The small skin fragment shows moderate epidermal hyperplasia, ulceration; the dermis has epithelioid granulomatous inflammation with giant cells, plasmacytes, and lymphocytes, and abscesses in the center of the granulomata; hematoxylin and eosin, 6.3X.

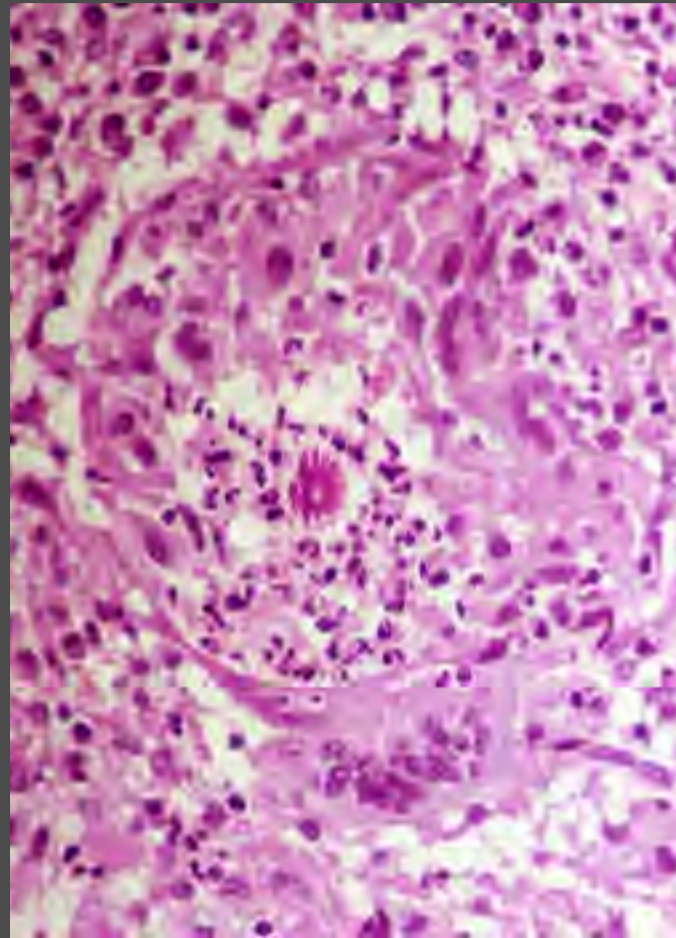
**Figure 3.251B.**

Every abscess contains an asteroid body; hematoxylin and eosin, 20X.

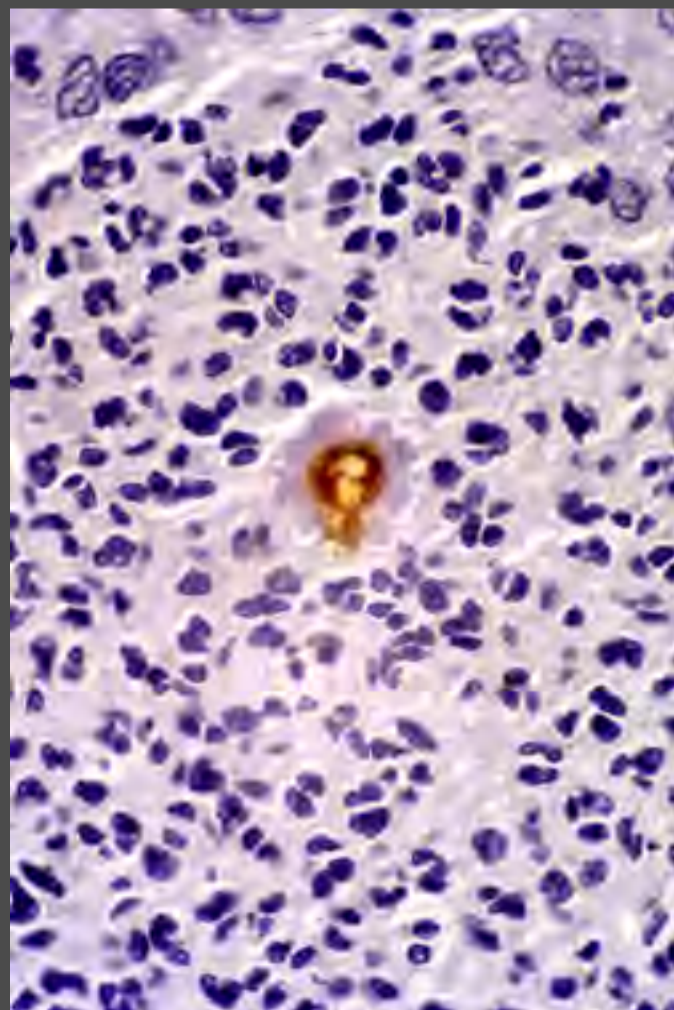
## Sporotrichosis



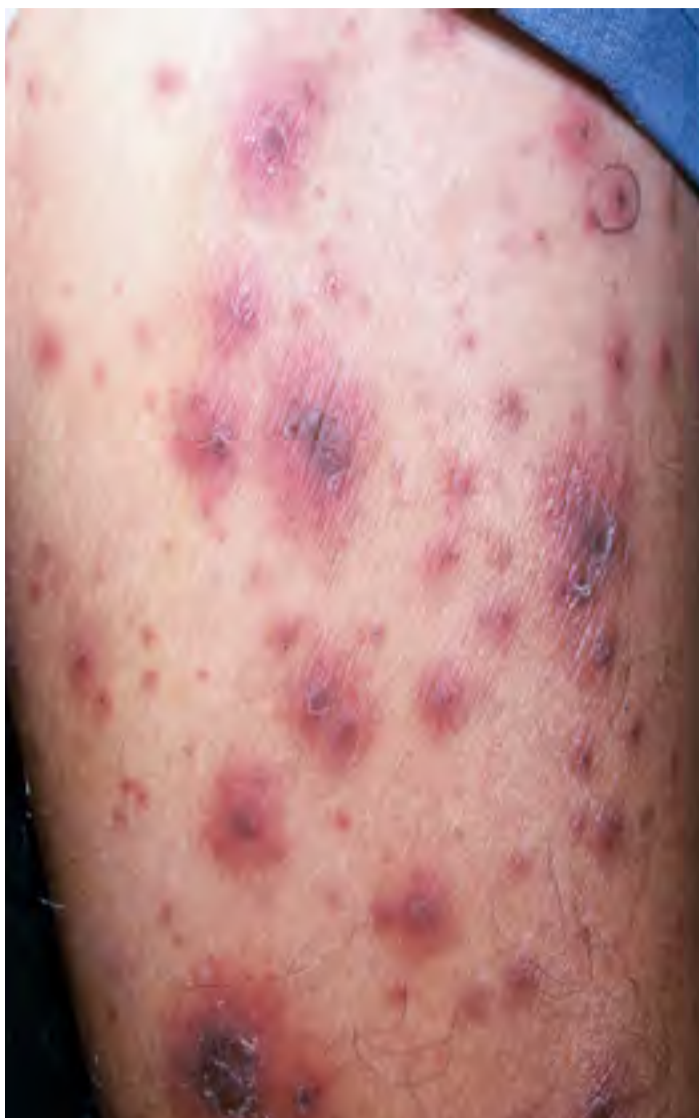**Figure 3.251C.**  
Close-up of asteroid body; hematoxylin and eosin, 100X



**Figure 3.251D.**  
The sporotrichosis asteroid body is located in the center of the abscessed granuloma and consists of a yeast surrounded by eosinophilic spicules; hematoxylin and eosin, 40X.



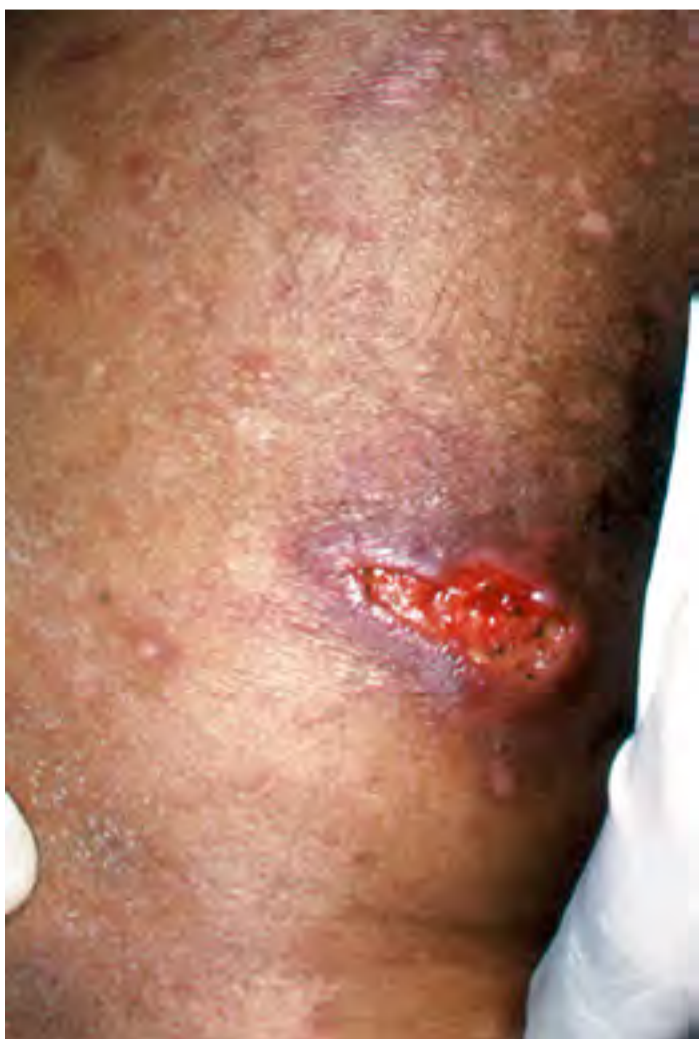**Figure 3.251E.**  
The yeast stains brown from the immunohistochemistry technique. The spicules do not stain because they are not a component of the fungus, but are antibodies directed against it or enzymatic products of degranulation of the polymorphonuclears; immunohistochemistry, 100X.



***Histoplasmosis.*** This is an opportunistic endemic mycosis that most frequently affects people with defects in cellular immunity in whom it develops aggressively, and it can be fatal. Skin lesions are widely distributed papules and nodules that resemble diffuse cutaneous leishmaniasis (*Figures 3.252 to 3.258*). This is a clinical and, especially, histopathological, differential diagnosis, from other forms of leishmaniasis, such as the cutaneous, AIDS-associated diffuse cutaneous, mucosal, and visceral forms.

**Figure 3.252A.**

Spread of AIDS-associated disseminated histoplasmosis

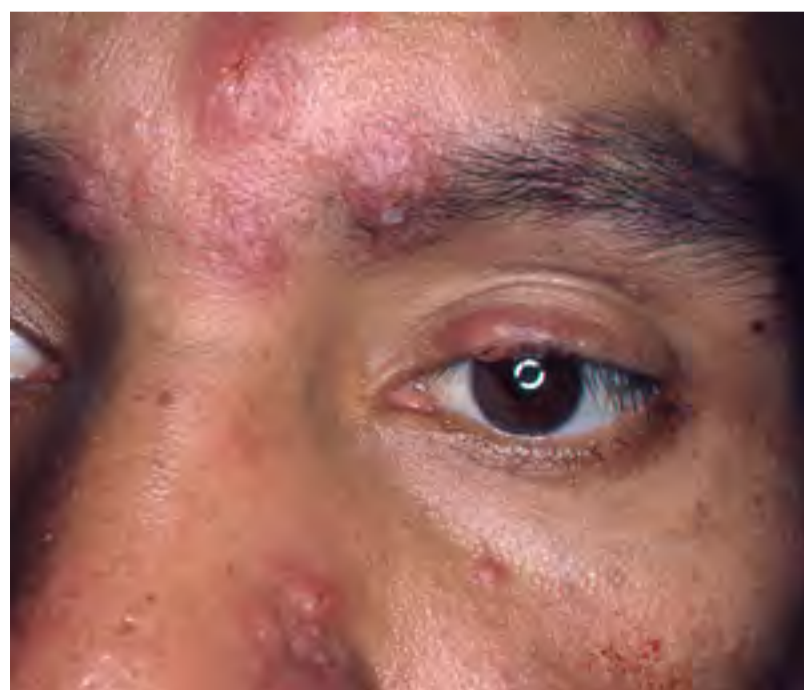

**Figure 3.252B.**

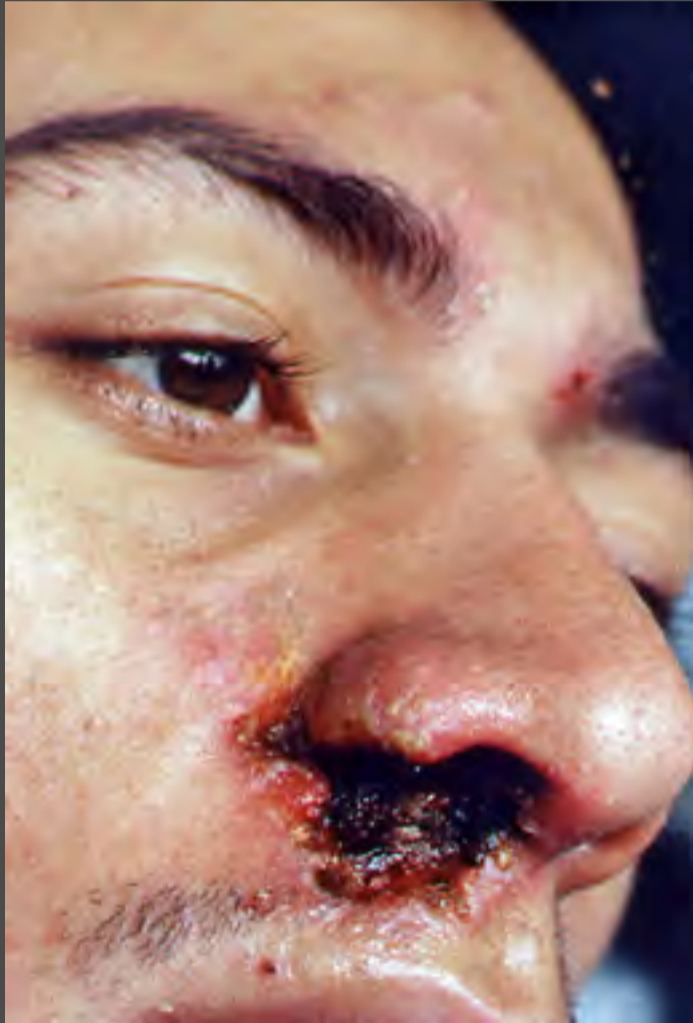Hypopigmented scars and ulcer that resembles leishmaniasis.

**Figure 3.252C.**

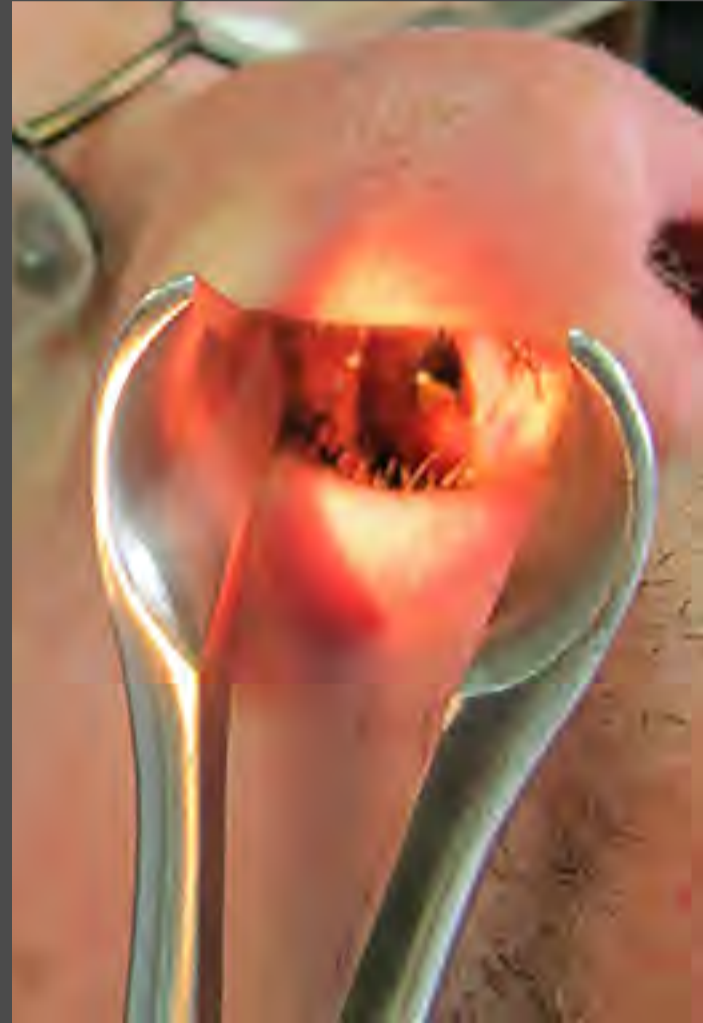Papules and plaques of face and upper eyelid



## AIDS-associated disseminated histoplasmosis



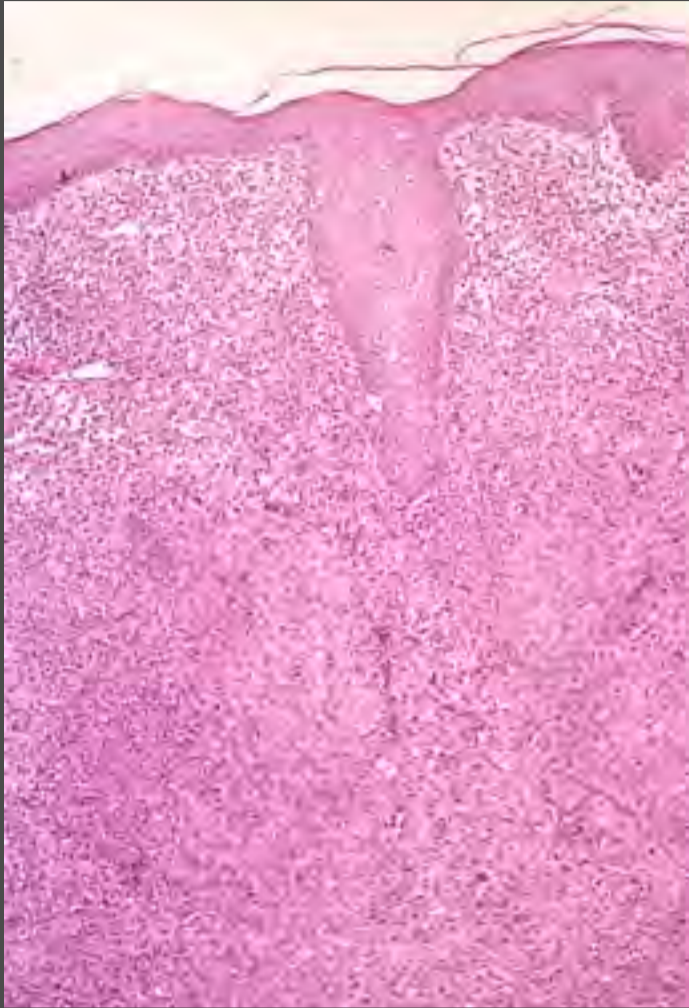**Figure 3.253A.**  
Ulcer covered by sanguineous crust that involves the nasal ridge and lower part of the nasal mucosa. Erythematous papules of the eyebrows and forehead. The initial clinical diagnosis was mucosal leishmaniasis.



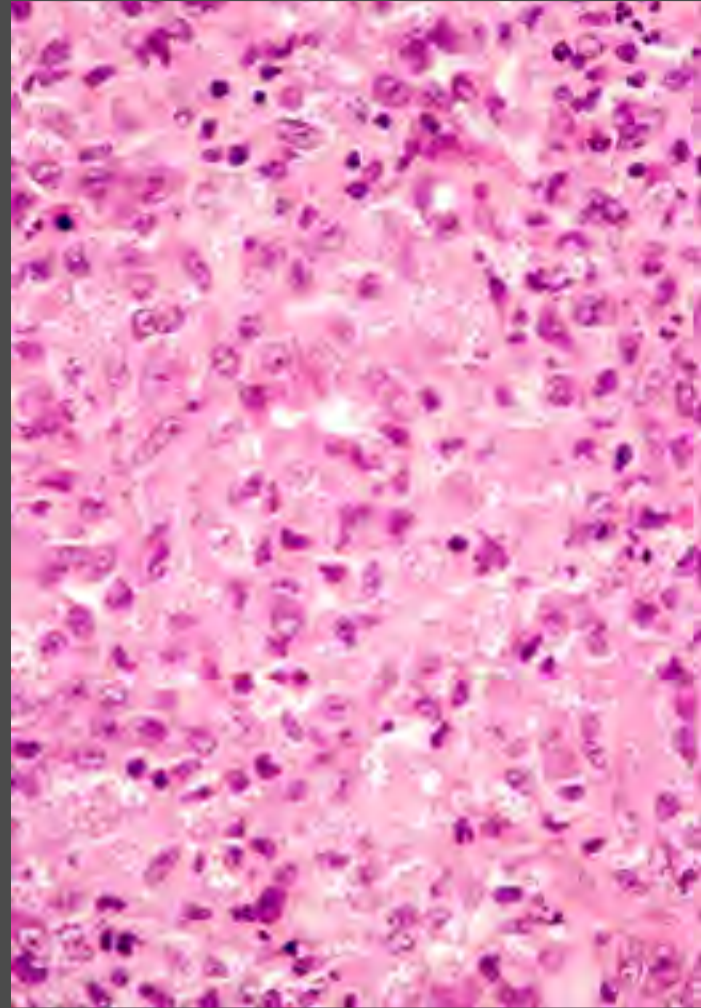
**Figure 3.253B.**  
Nasal perforation as initial manifestation of AIDS-associated histoplasmosis



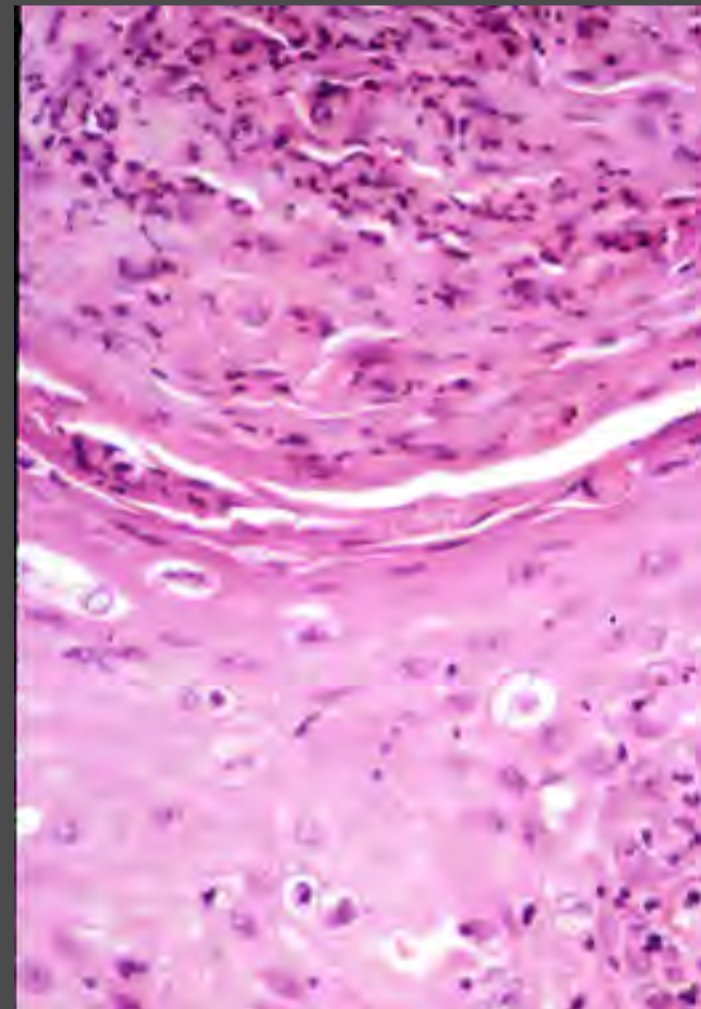
## AIDS-associated disseminated histoplasmosis



**Figure 3.254A.**  
Skin biopsy. The picture shows diffuse dermic inflammation rich in vacuolated cells, some of which are being eliminated through a hair follicle (center); hematoxylin and eosin, 6.3X.

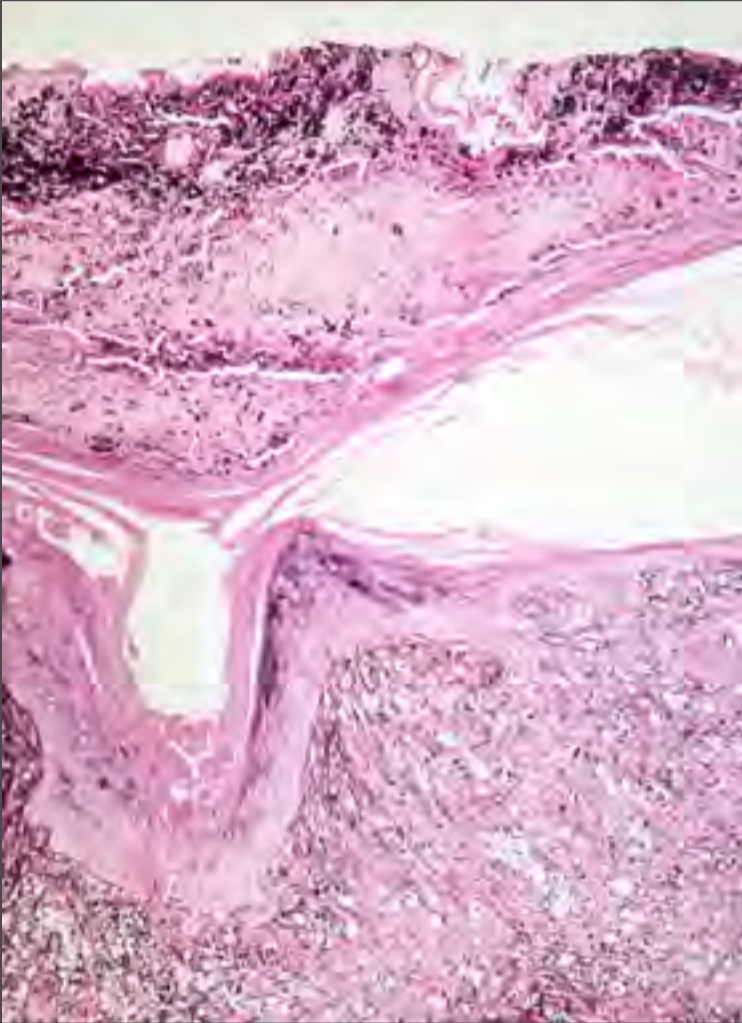


**Figure 3.254B.**  
Skin biopsy. At higher magnification, numerous tiny microorganisms phagocytized by vacuolated macrophages are visible, with few lymphocytes and plasmocytes; hematoxylin and eosin, 40X.



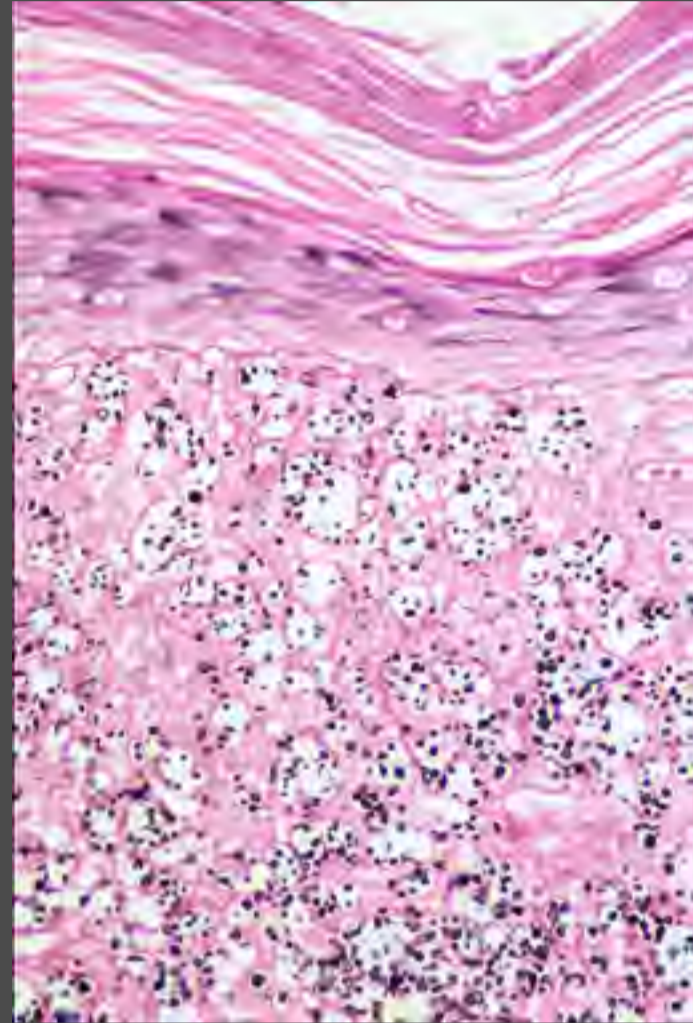
**Figure 3.254C.**  
Skin biopsy. Epidermis covered by a thick parakeratotic scaly crust. Cells with fungi inside them are visible; hematoxylin and eosin, 40X.

## AIDS-associated disseminated histoplasmosis



**Figure 3.254D.**

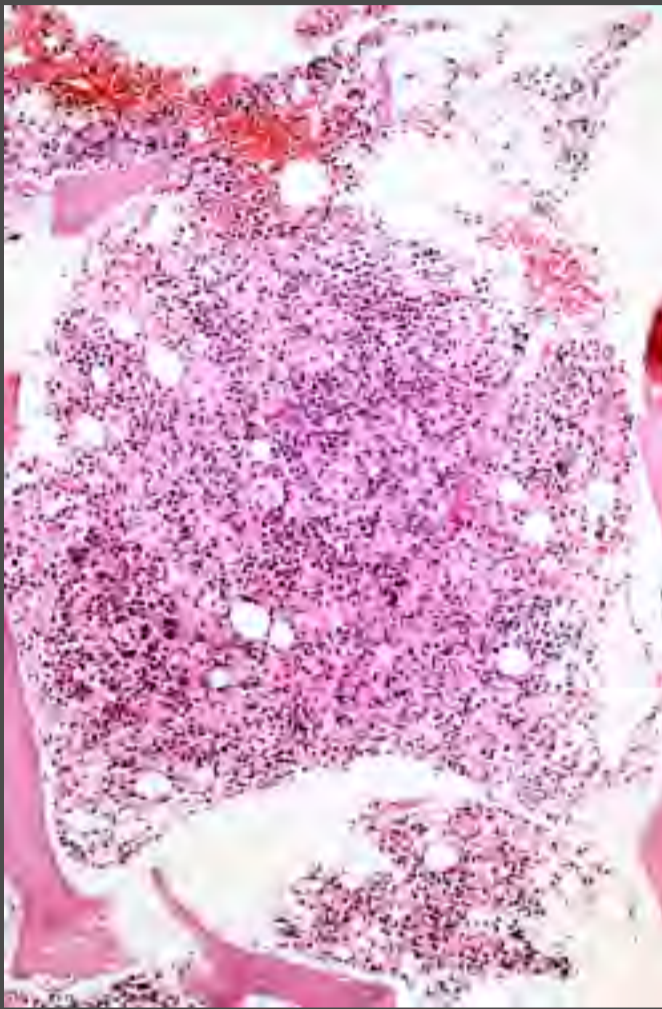
Skin biopsy of a patient with AIDS-associated disseminated histoplasmosis. This image of the scaly crust in Figure C, Grocott-stained, shows transepidermal elimination of a large number of fungi; therefore, direct smear will easily reveal them in a few minutes; Grocott stain, 10X.



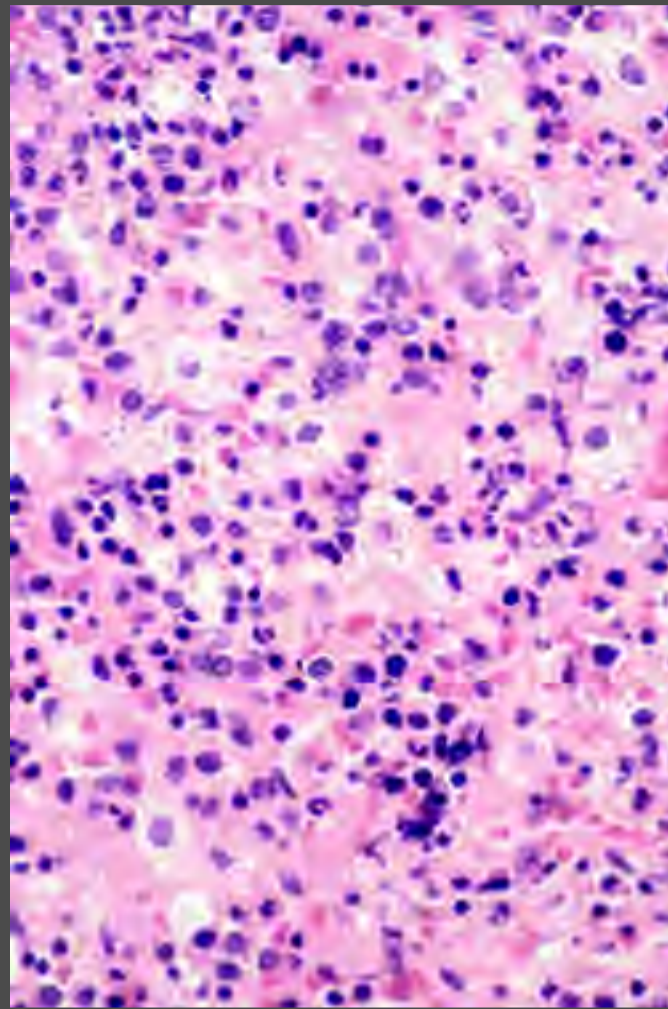
**Figure 3.254E.**

Skin biopsy of a patient with HIV-associated disseminated histoplasmosis. Grocott stain reveals an enormous number of black yeasts phagocytized by dermal macrophages; Grocott stain, 32X

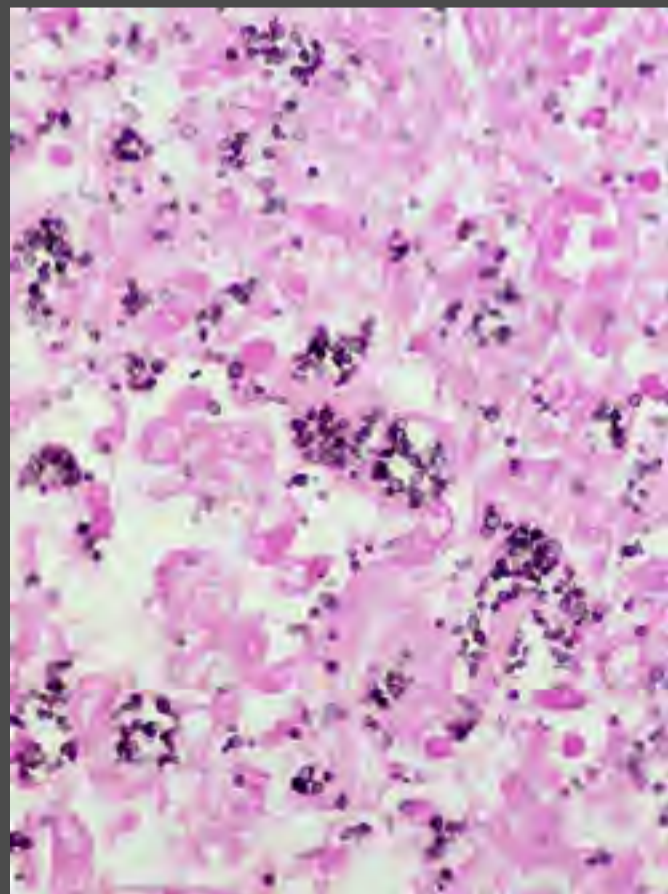
## AIDS-associated disseminated histoplasmosis



**Figure 3.255A.**  
Bone marrow. Central granuloma mixed with hematopoietic cells; hematoxylin and eosin, 12.5X

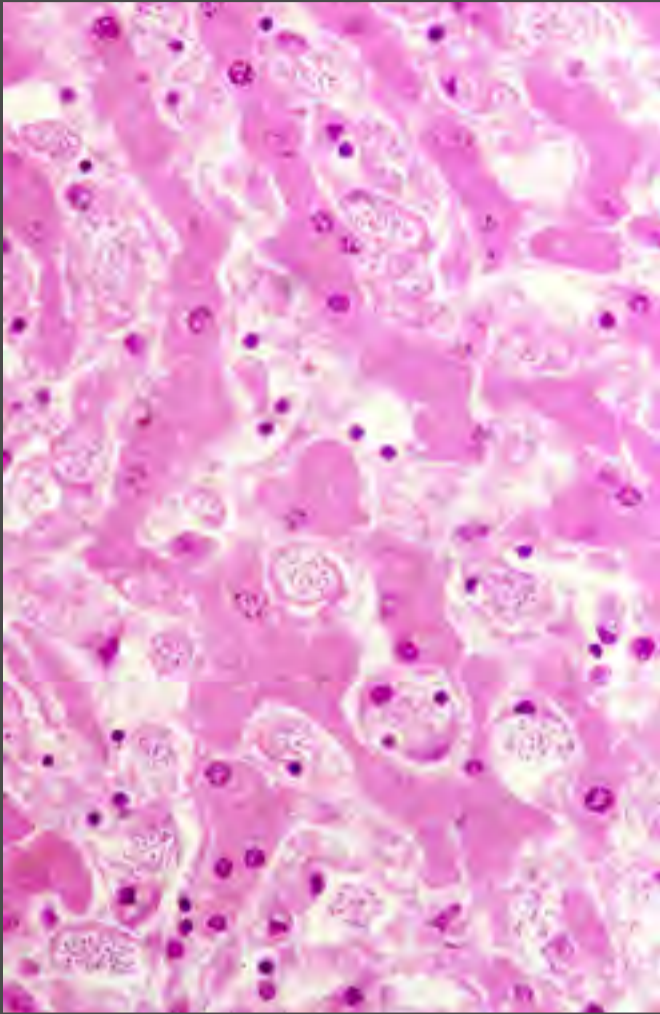


**Figure 3.255B.**  
Bone marrow. Higher magnification reveals tiny microorganisms phagocytized by macrophages; hematoxylin and eosin, 50X.

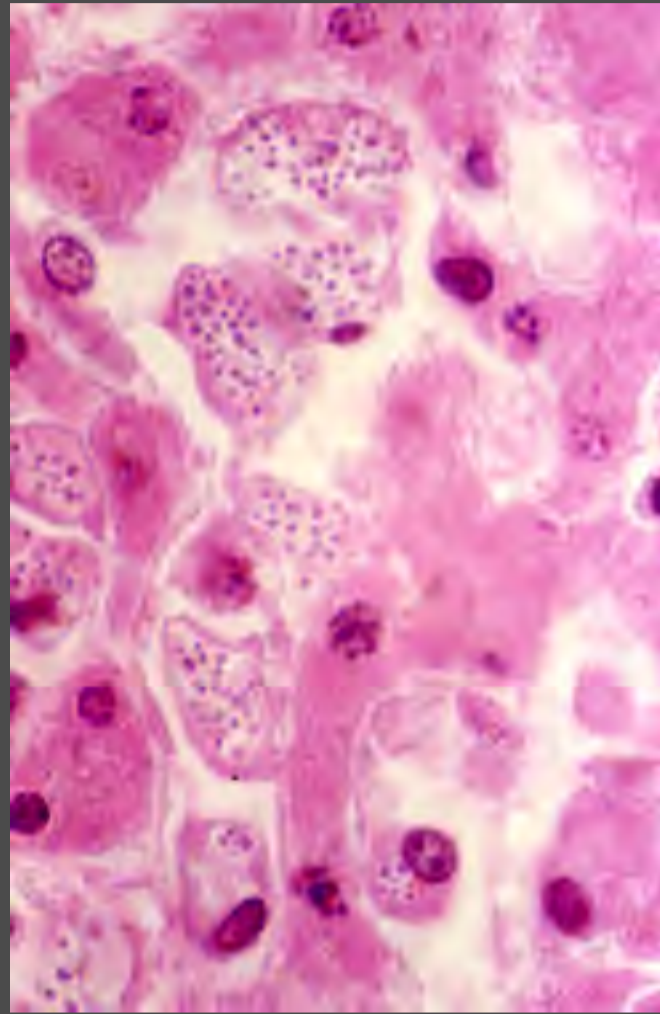


**Figure 3.255C.**  
Bone marrow. Grocott stain colors them brown, identifying them as a fungus; Grocott stain, 64X.

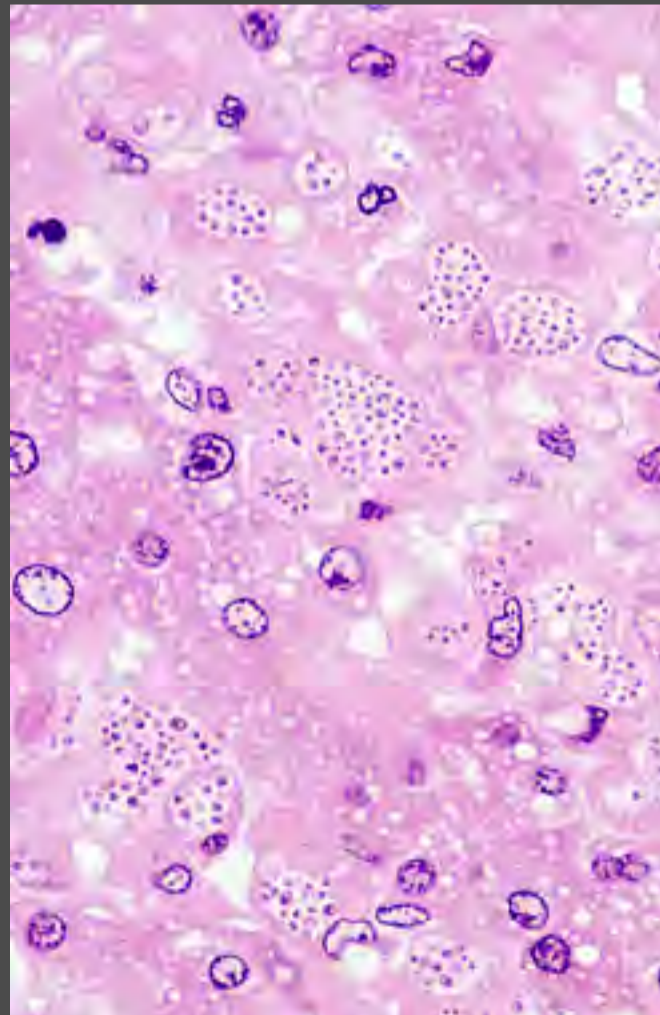
## AIDS-associated disseminated histoplasmosis



**Figure 3.256A.**  
Liver. Thin and eosinophilic hepatocyte trabeculae are between sinusoids containing enormous Kupffer cells, filled with tiny organisms; hematoxylin and eosin, 40X.

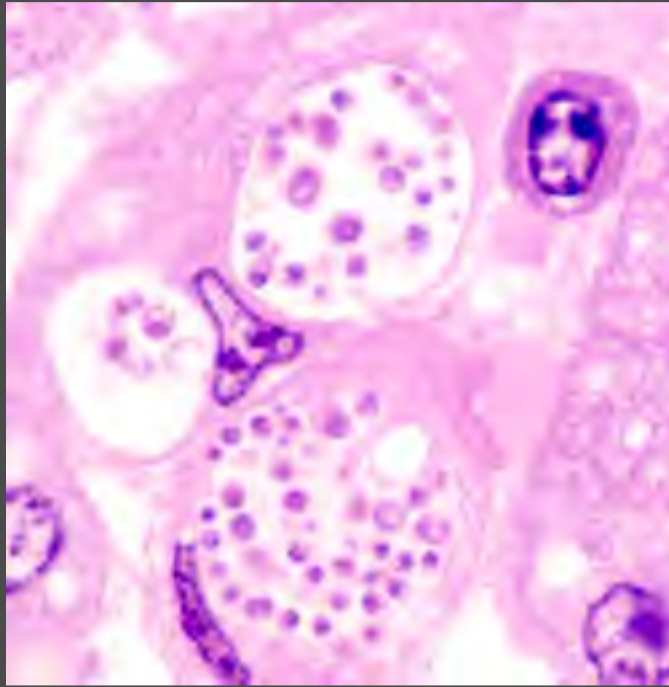


**Figure 3.256B.**  
Liver. Higher magnification reveals sinusoids with enormous Kupffer cells filled with fungi; hematoxylin and eosin, 100X.

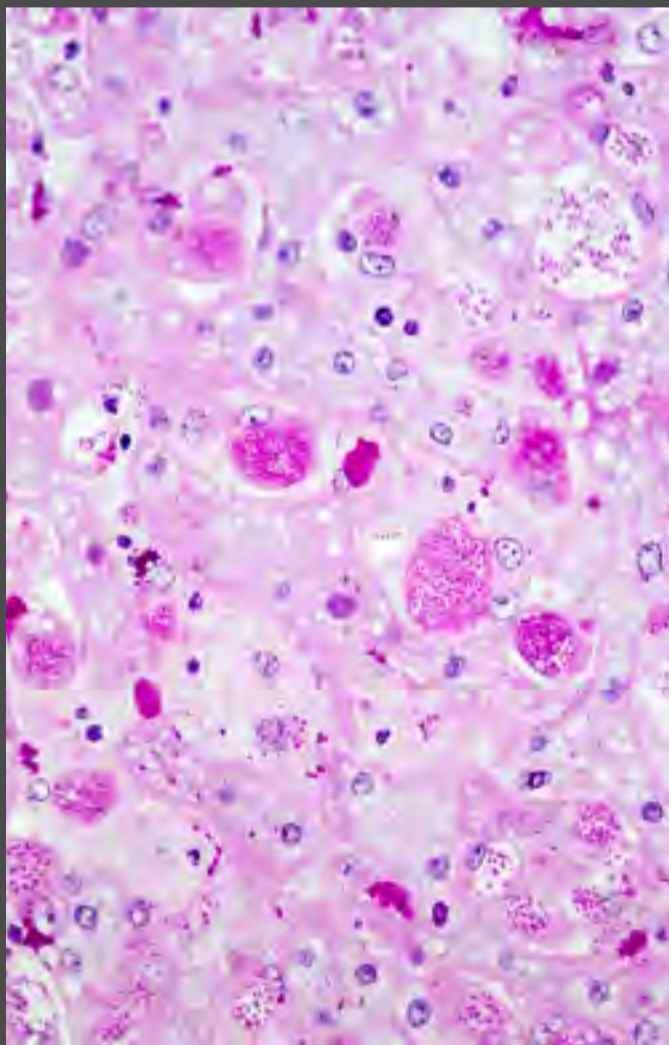


**Figure 3.256C.**  
Liver. Hepatocytes with vacuolar change from fatty infiltration, and sinusoids with voluminous Kupffer cells filled with *Histoplasma capsulatum*; hematoxylin and eosin, 50X

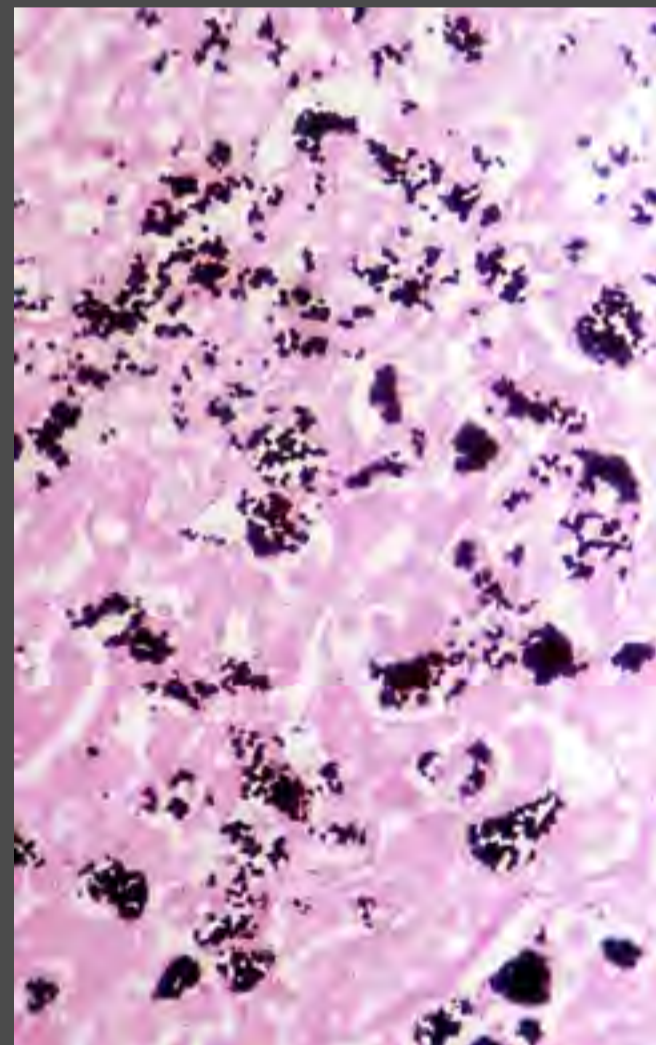
## AIDS-associated disseminated histoplasmosis

**Figure 3.256D.**

Liver. Kupffer cells with *Histoplasma capsulatum*. The thick wall of some yeasts is visible, and none have a structure resembling the *Leishmania* kinetoplast; hematoxylin and eosin, 200X.

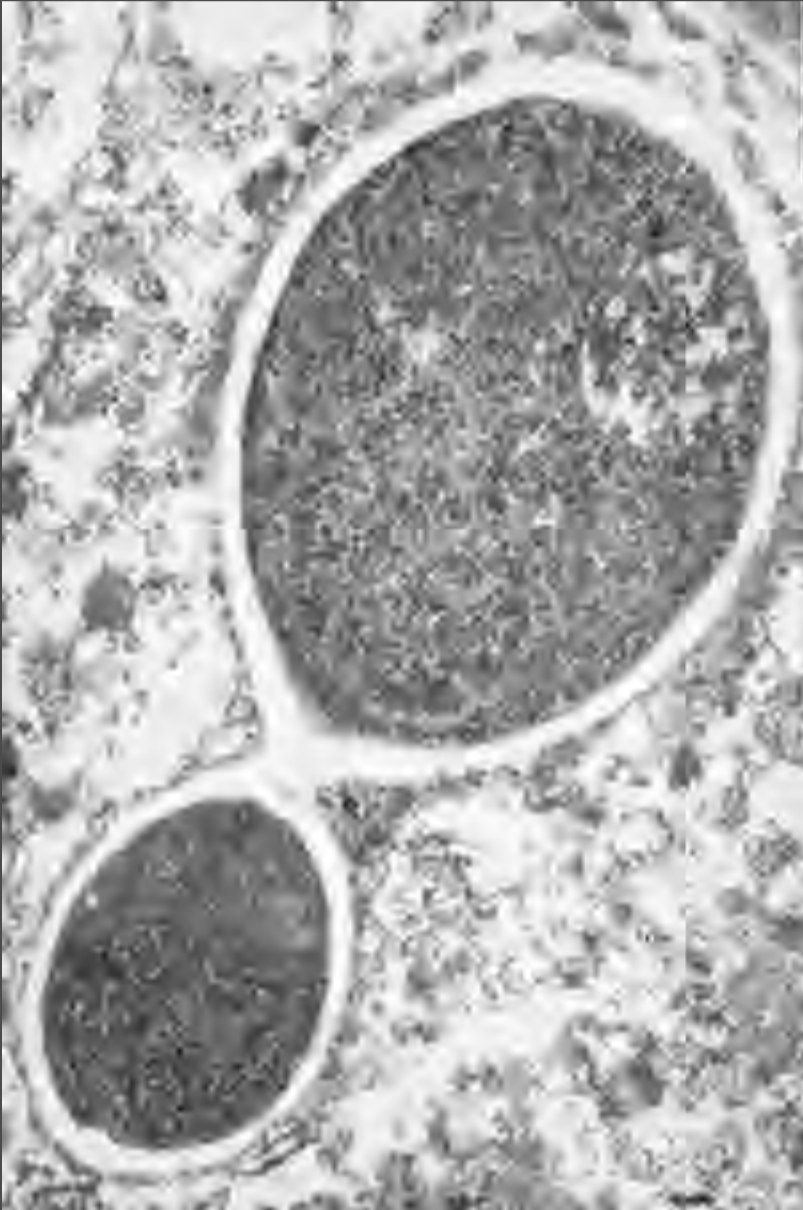
**Figure 3.256E.**

Liver. PAS stain colors the germ and shows that it has the morphology of *Histoplasma capsulatum*; PAS, 40X.

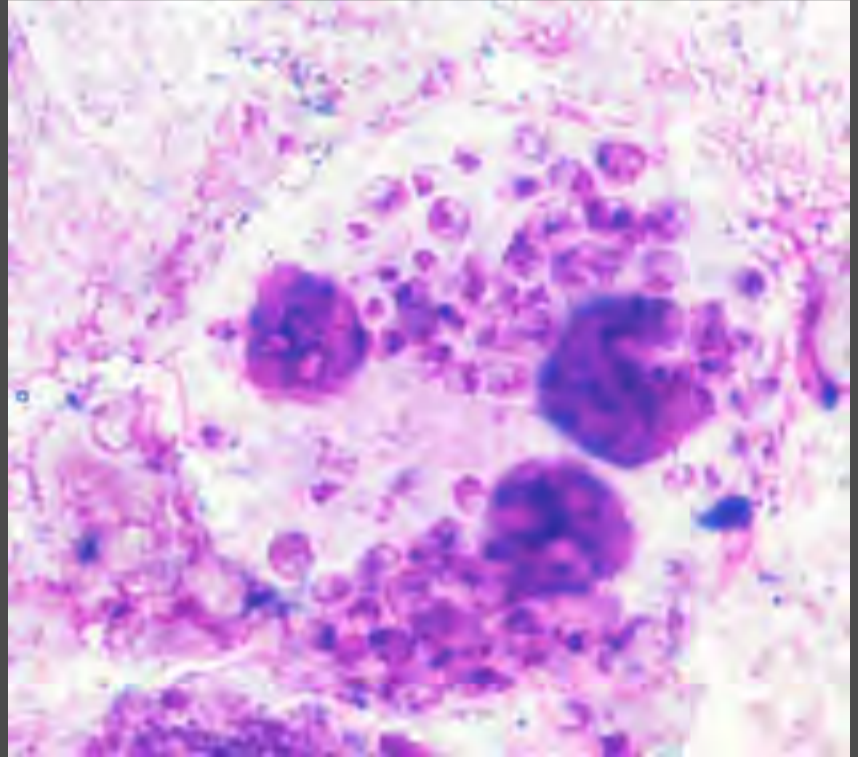
**Figure 3.256F.**

Liver. Grocott stain colors the germ and shows that it has the morphology of *Histoplasma capsulatum*; Grocott stain, 50X

## Histoplasmosis

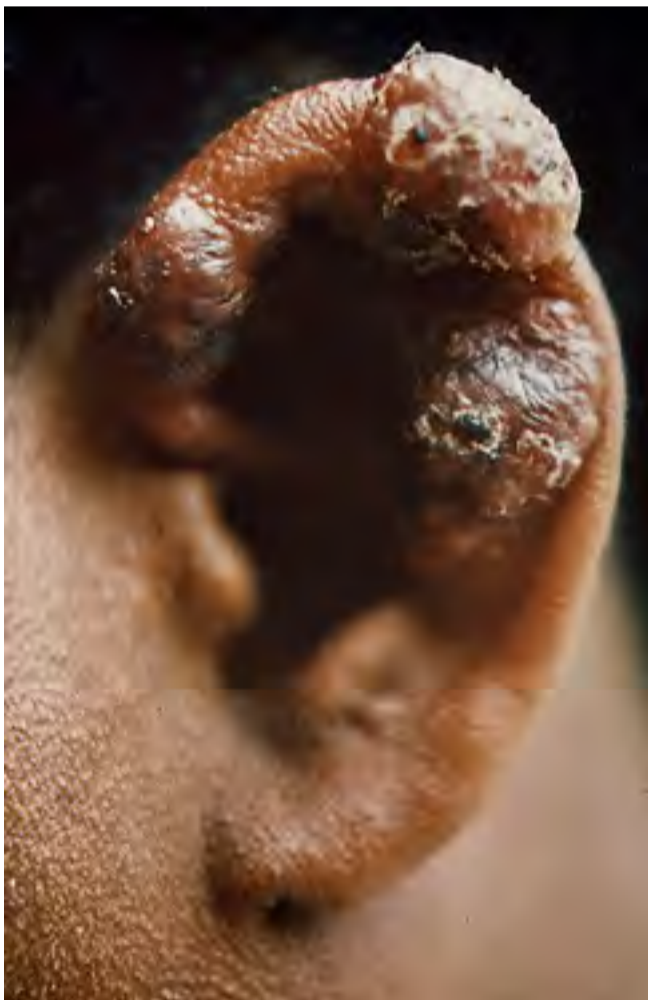

**Figure 3.257.**  
Electron micrograph of budding *Histoplasma capsulatum*. Nucleus and dense cytoplasm, surrounded by a thick, transparent, and clear cell wall

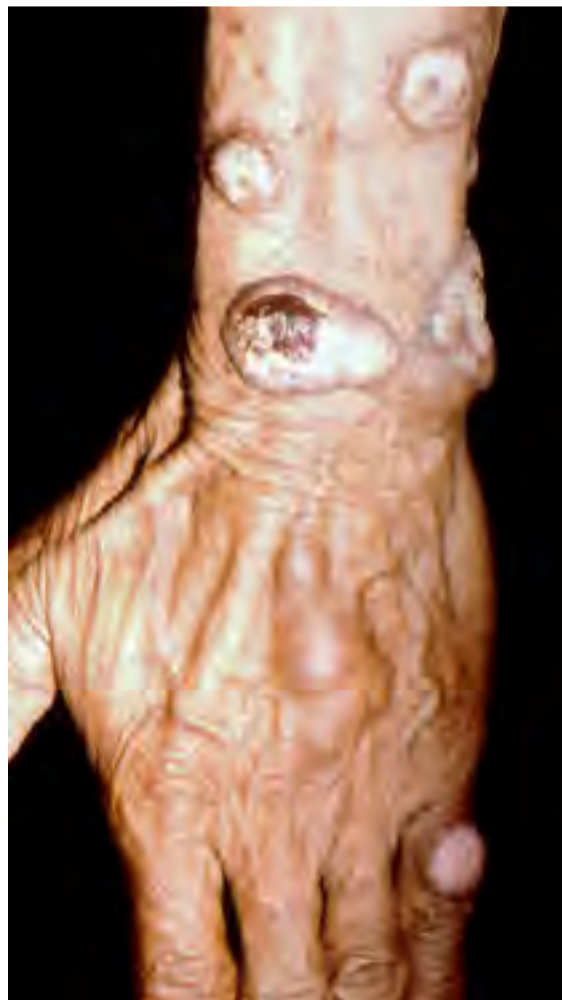

**Figure 3.258.**  
Direct smear. Abundant yeasts in clusters are visible. No structure suggests a kinetoplast.

***Lobomycosis.*** This is a cutaneous mycosis produced by *Lacazia loboi*, a fungus that has not been successfully cultured. It produces cutaneous plaques and nodules that resemble keloids, are sometimes ulcerated, and are more frequent on the legs, arms, and ears (*Figures 3.259 to 3.263*). It is common in the indigenous populations of Brazil and Colombia. There have been a few cases in soldiers who patrol the same jungle areas where they can also acquire leishmaniasis.

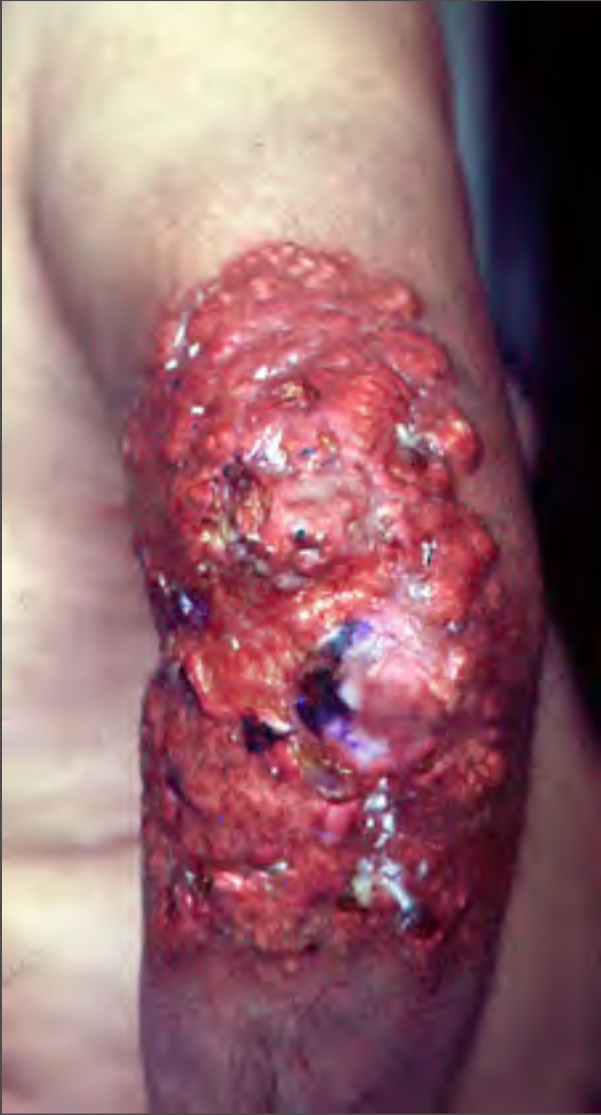

**Figure 3.259.**  
Crusty, hyperkeratotic nodules on the ear of a patient from Chocó department, Colombia

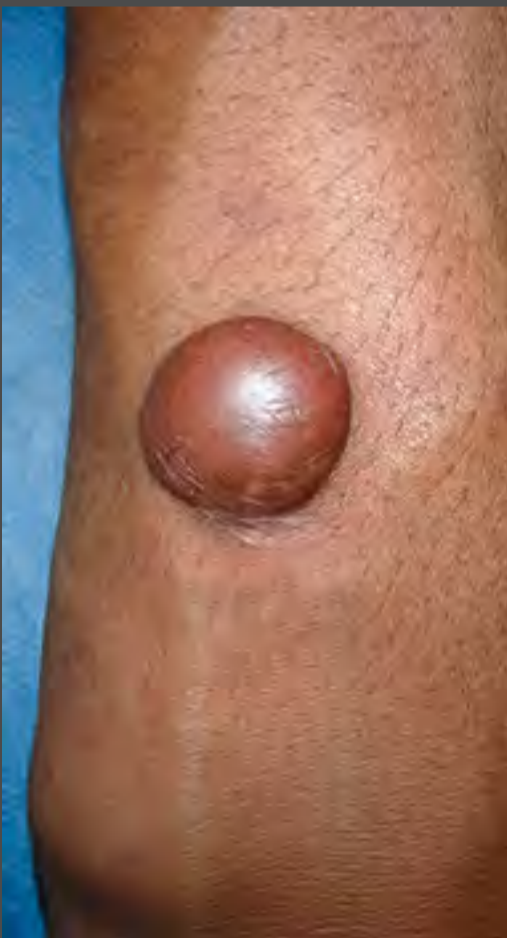

**Figure 3.260.**  
A line of firm, keloidal nodules, some ulcerated

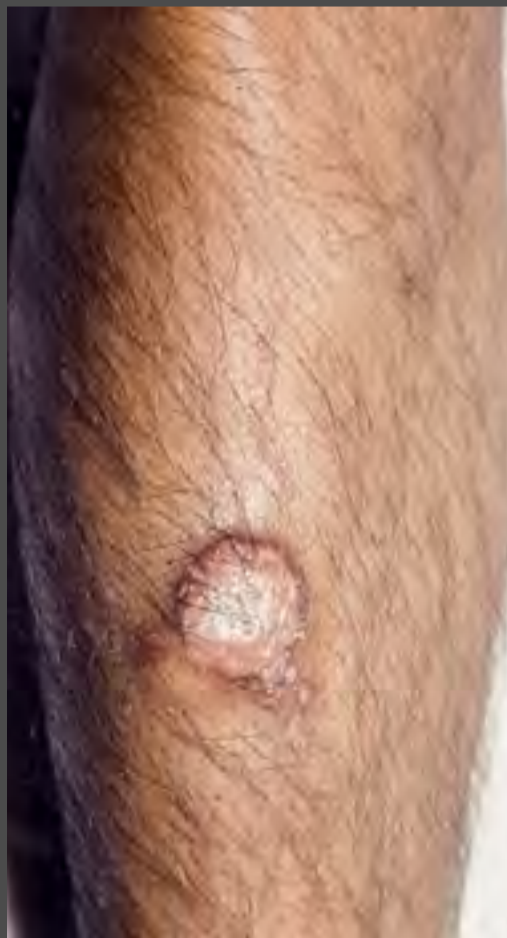## Lobomycosis



**Figure 3.261.**  
Ulcerated plaque formed by  
confluent papules and nodules  
over 25 years old



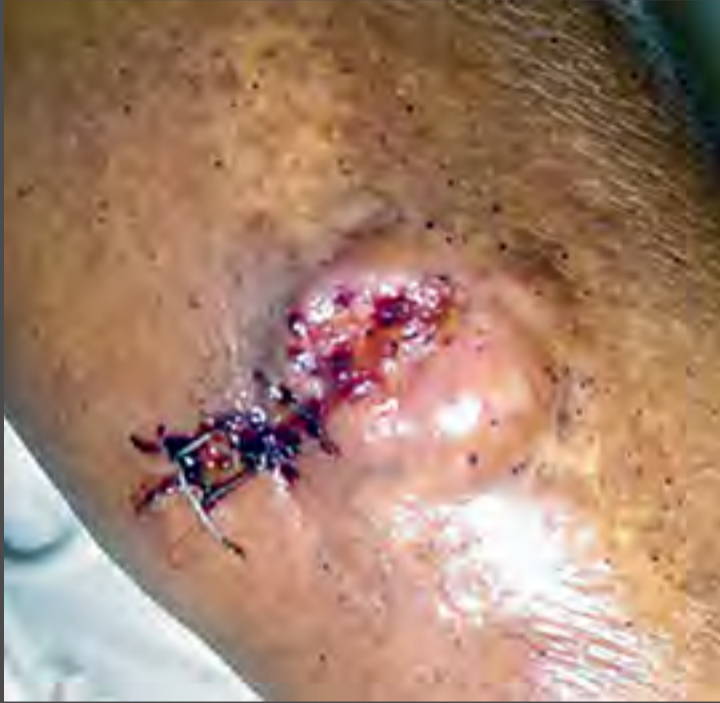**Figure 3.262A.**  
Smooth-surfaced, well-  
defined nodule, on a  
soldier's arm



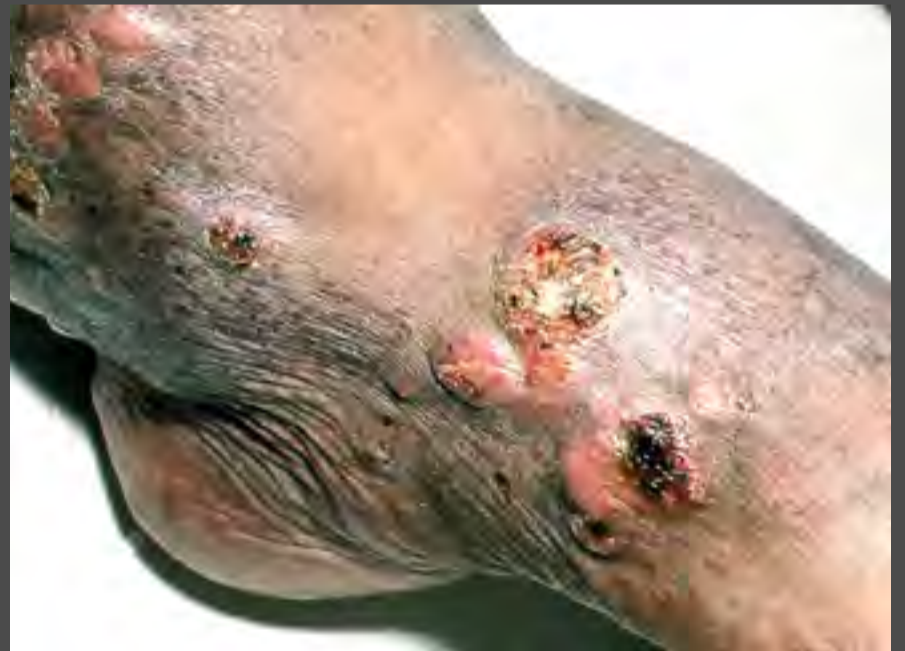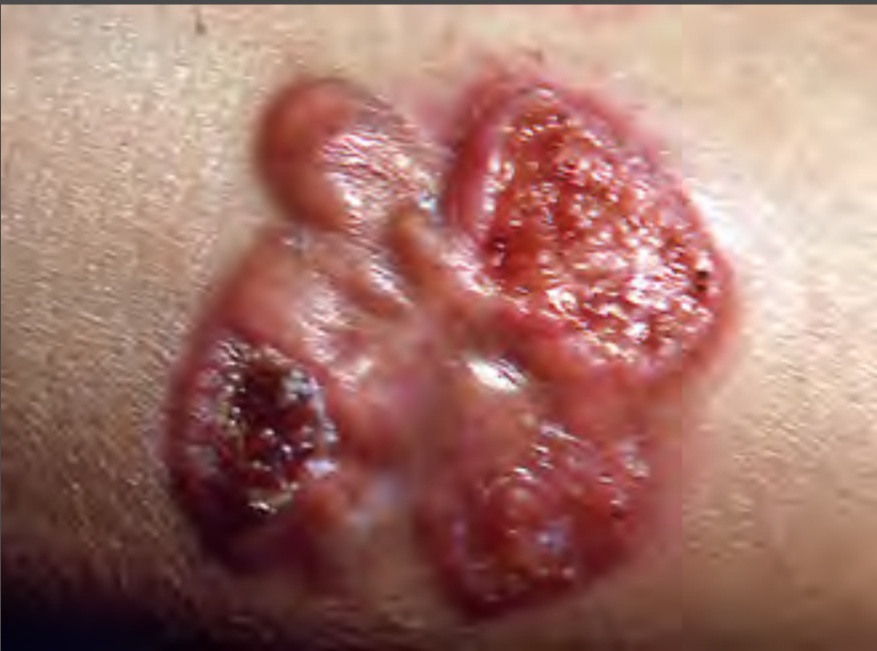**Figure 3.262B.**  
Nodule on the leg with  
small satellite papules



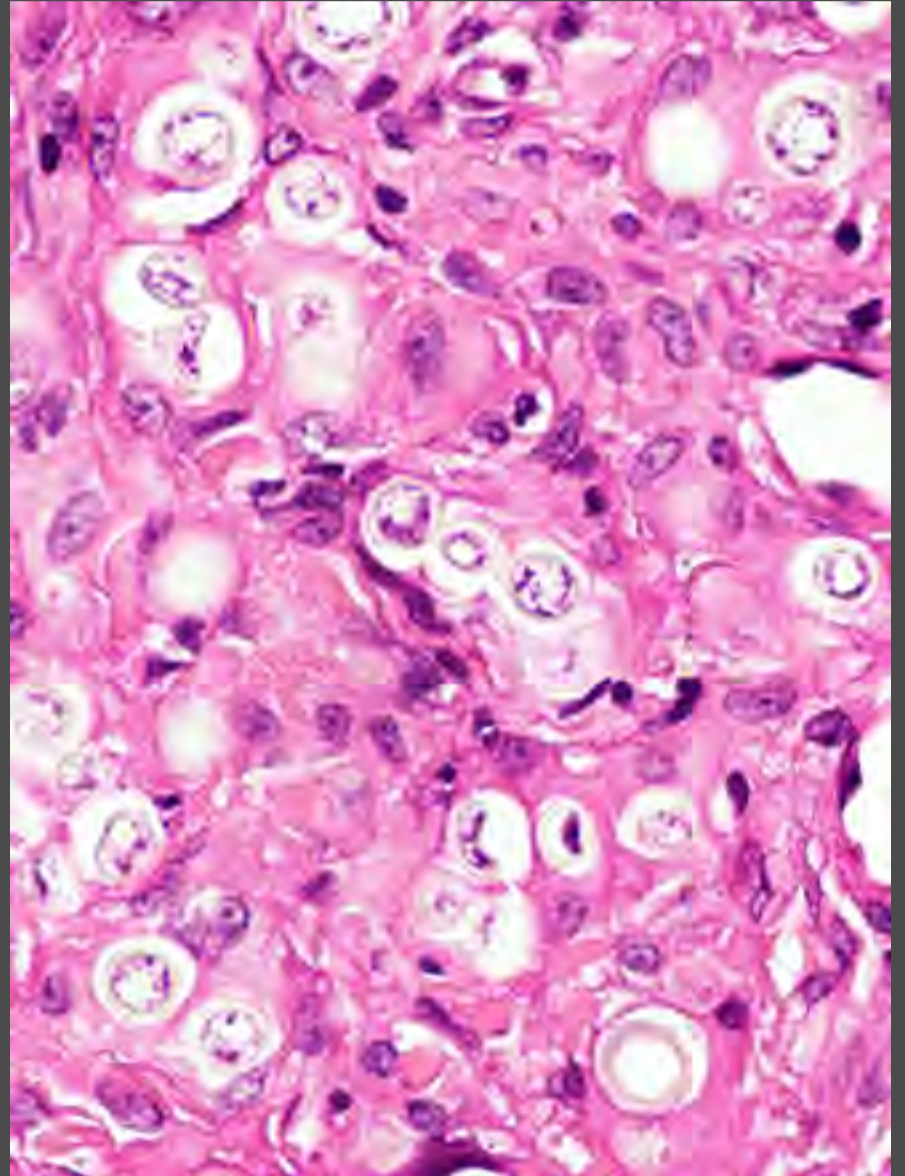
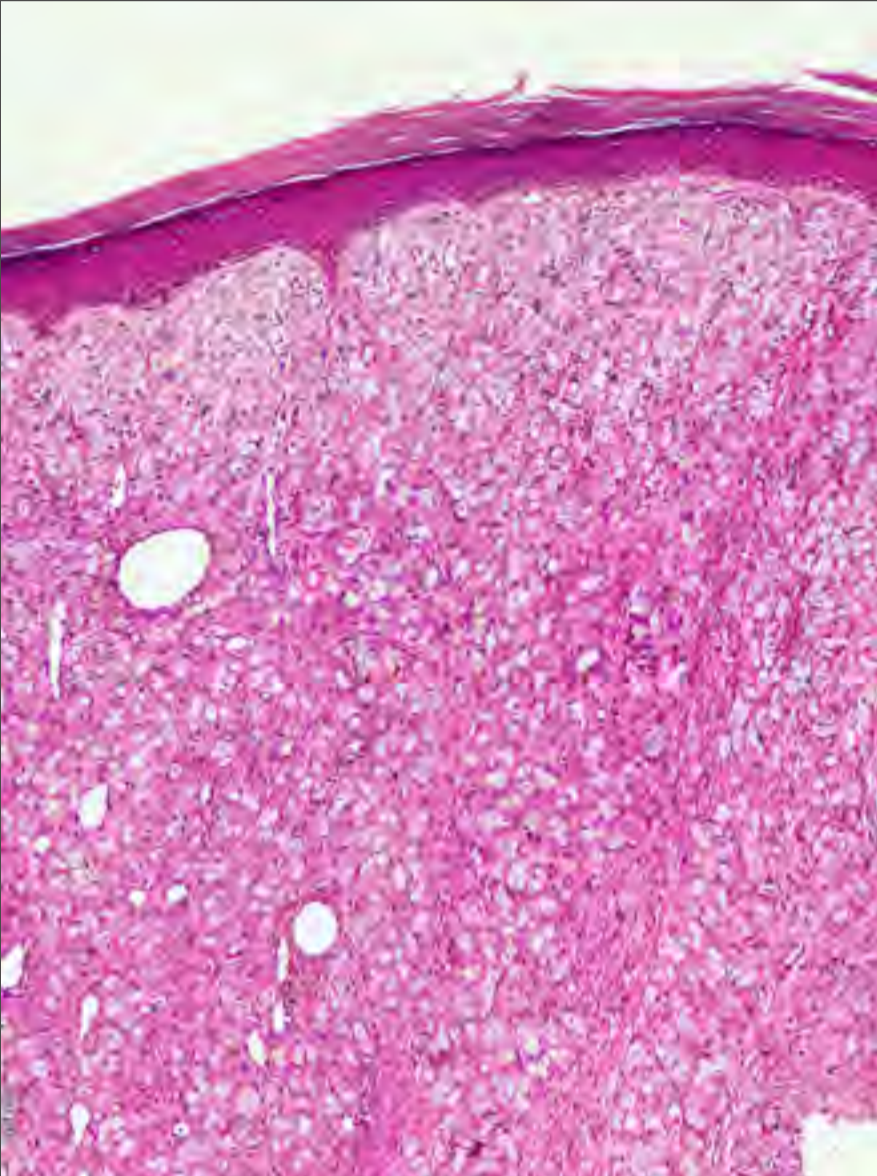
## Lobomycosis



Figures 3.262C, D and E.  
Ulcerated, keloidal lesions that  
were clinically interpreted as  
cutaneous leishmaniasis.

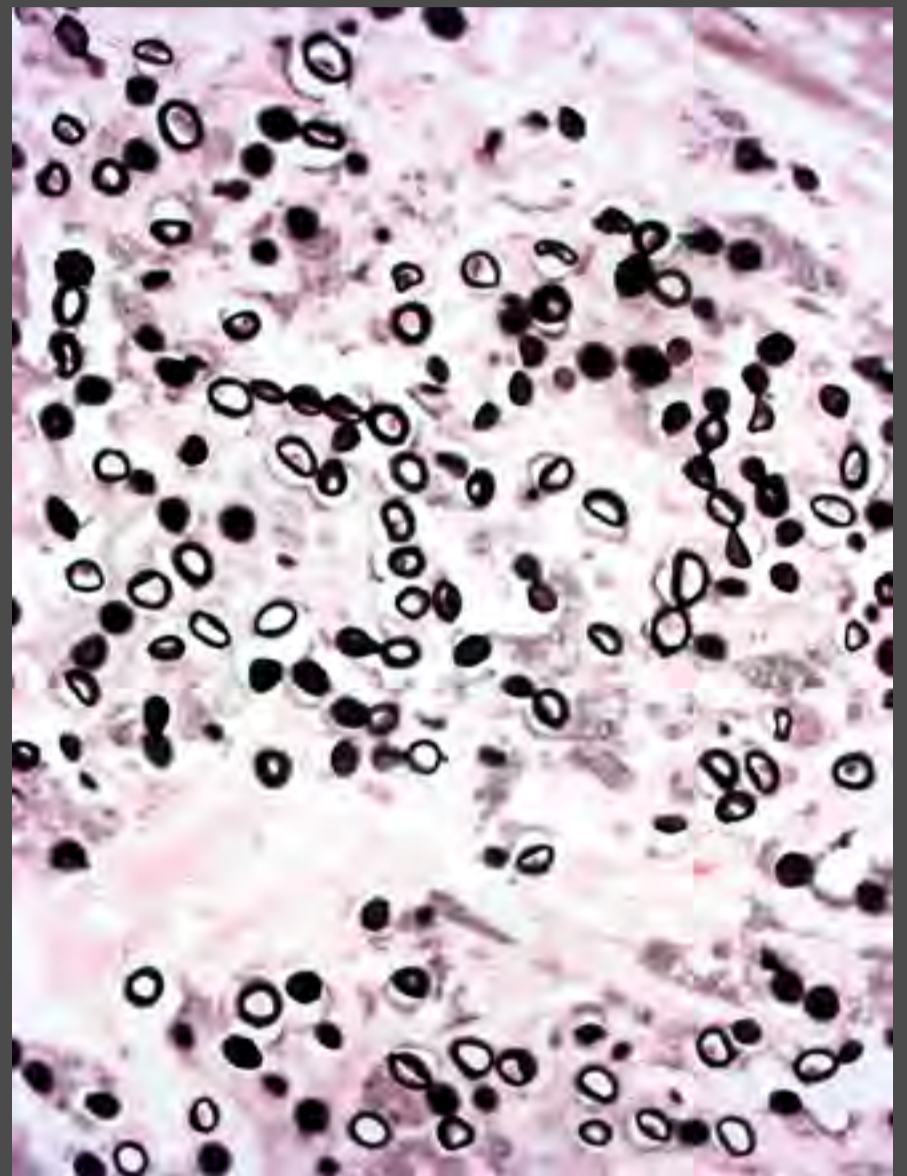
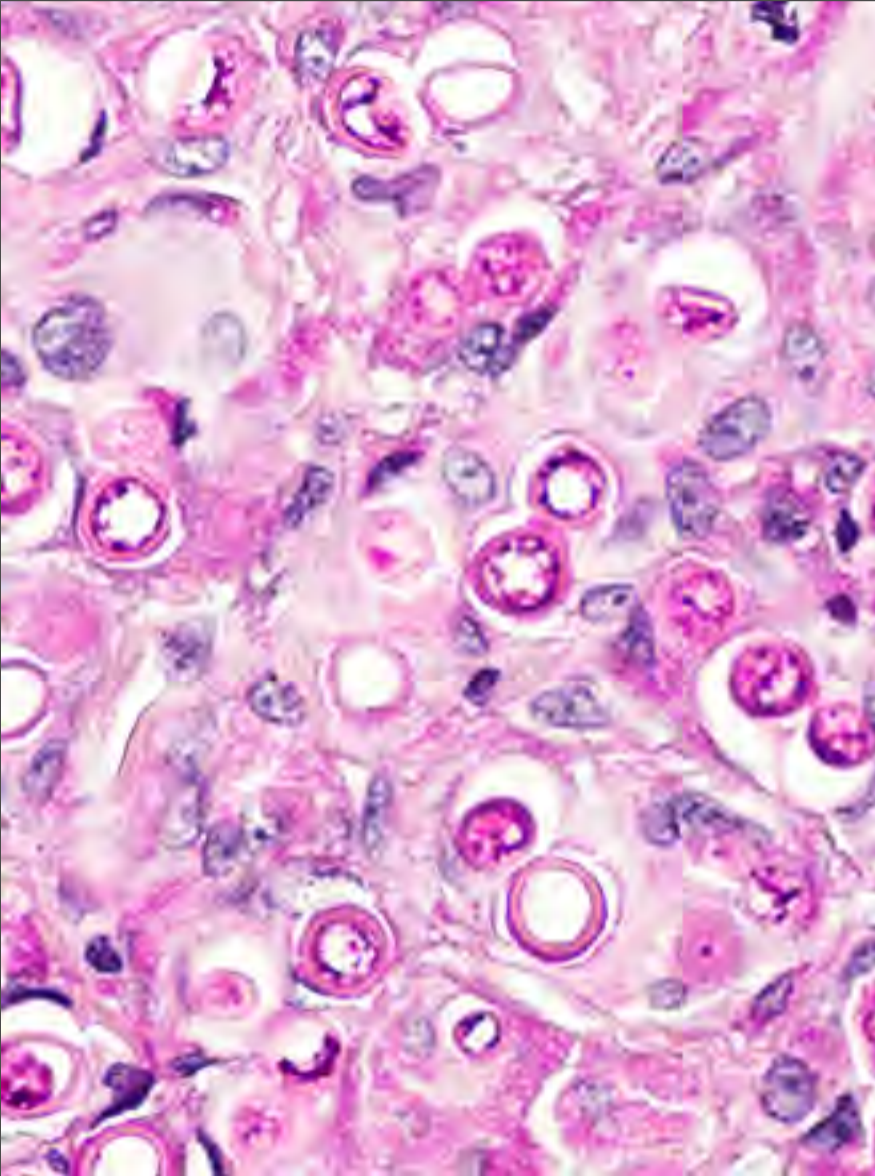


## Lobomycosis

**Figures 3.263A and B.**

Characteristic biopsy. The epidermis is of normal thickness and the dermis shows diffuse inflammation from macrophages and giant cells, all of which contain rounded, uniform fungi, 10  $\mu\text{m}$  in diameter, with a thick wall that form chains joined by small bridges. This is easy to see with PAS and Grocott stains. Hematoxylin and eosin, A 6.3X and B 40X.

## Lobomycosis

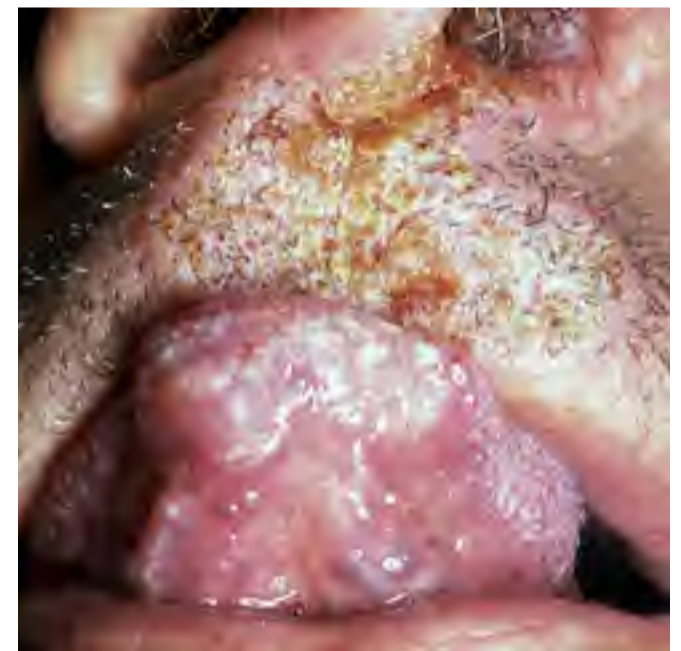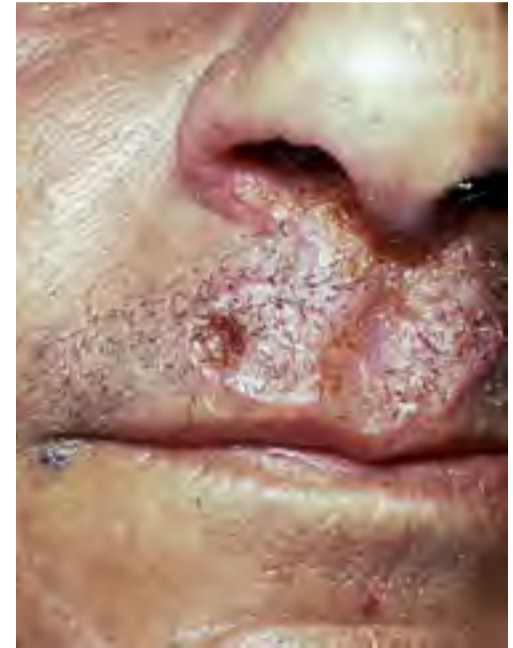**Figures 3.263C and D.**

Characteristic biopsy. The epidermis is of normal thickness and the dermis shows diffuse inflammation from macrophages and giant cells, all of which contain rounded, uniform fungi, 10  $\mu\text{m}$  in diameter, with a thick wall that form chains joined by small bridges. This is easy to see with PAS and Grocott stains. C. PAS, 40X and D. Grocott, 40X.

***Paracoccidioidomycosis.*** This is a chronic and slow-developing deep systemic mycosis that primarily affects the lung; in men, it is a differential diagnosis for both cutaneous and mucosal leishmaniasis, while the disorder is exceptional in women.

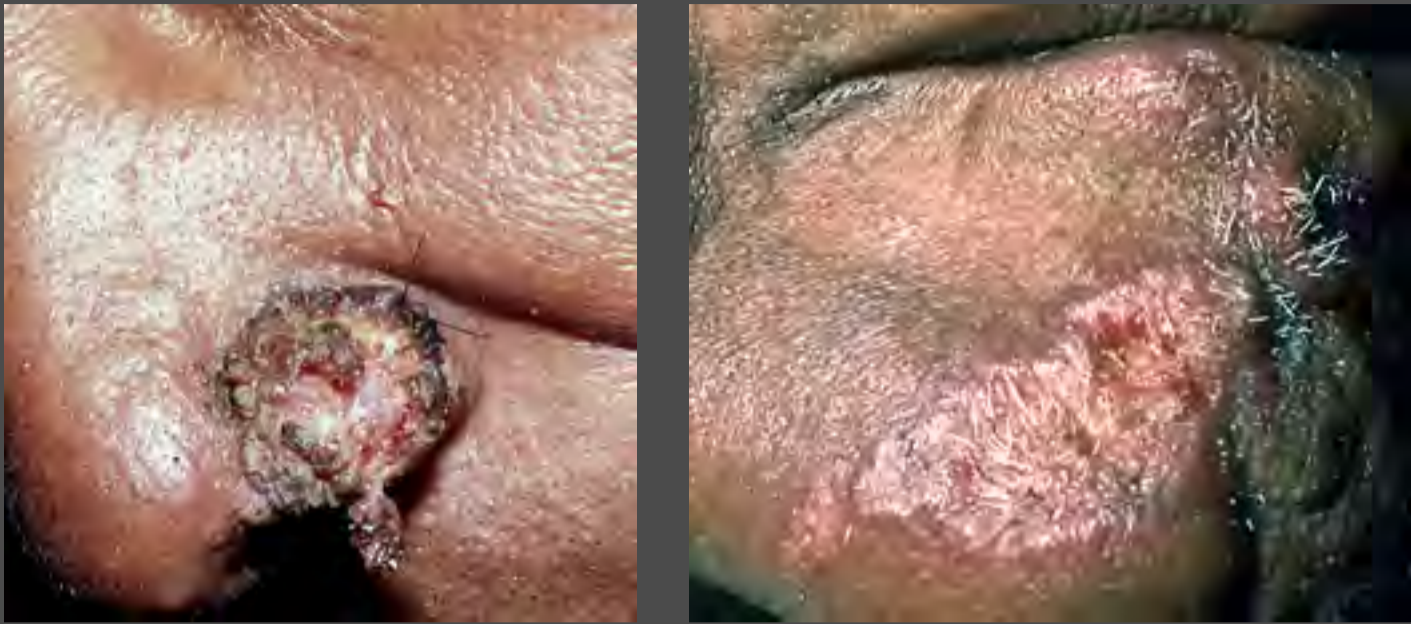The patient's general condition is considerably compromised, with weight loss, asthenia, and adynamia. Chronic idiopathic inflammation of the labial mucosa (macrocheilia), gingivitis, glossitis, and loss of teeth are common manifestations, unlike leishmaniasis, where the most frequent involvement is in the soft palate, tonsillar pillars, and pharynx (*Figures 3.264 to 3.268*). Cervical adenopathies, gummas, sinus pathways, drainage of bloody purulent material, and cutaneous ulceration are often seen. It can also affect the nasal mucosa and perforate the nasal septum. Very serious fibrosis is produced that can lead to microstomia, with a considerable reduction in the oral perimeter.

Direct smear and biopsy easily reveal the fungus. Culture and fungal antibody titers are other procedures for diagnosis and treatment follow-up.



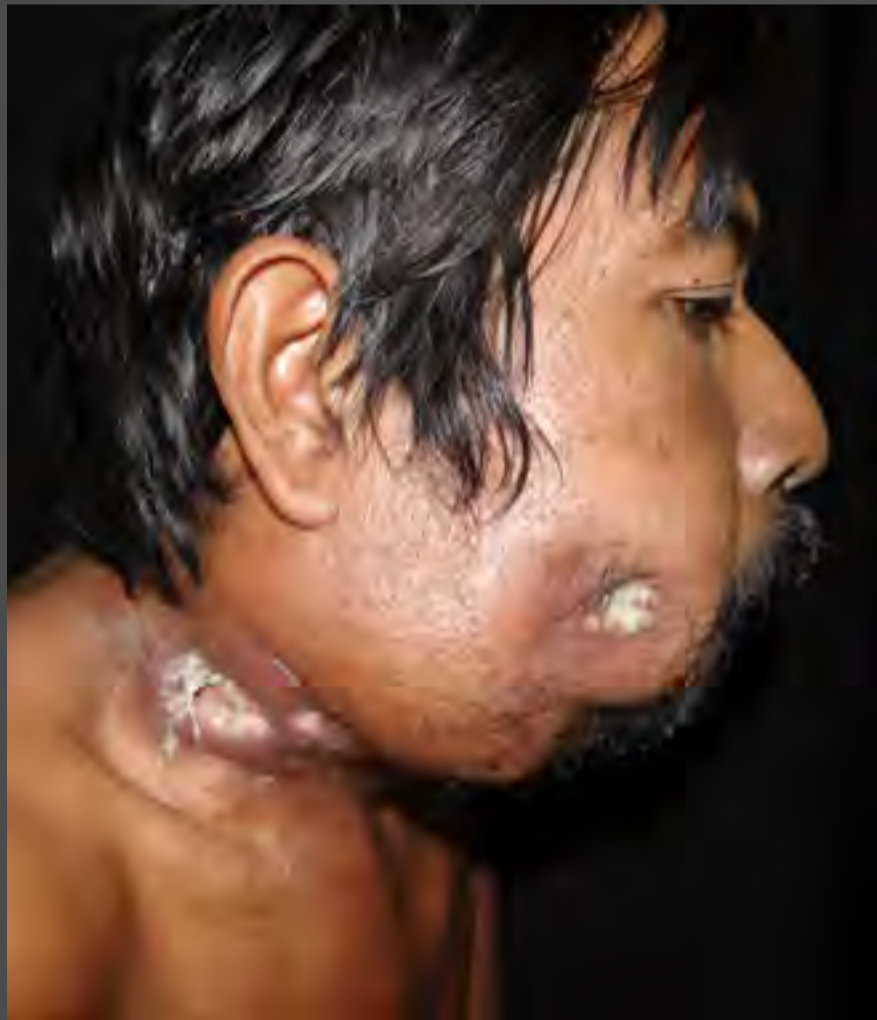**Figure 3.264A and B.** Ulcerated, crusty, hyperkeratotic, and edematous plaques of the skin and mucosa of upper lip, extending to the edge of the choanae, tongue, and gums

## Paracoccidioidomycosis



**Figures 3.265A and B.**

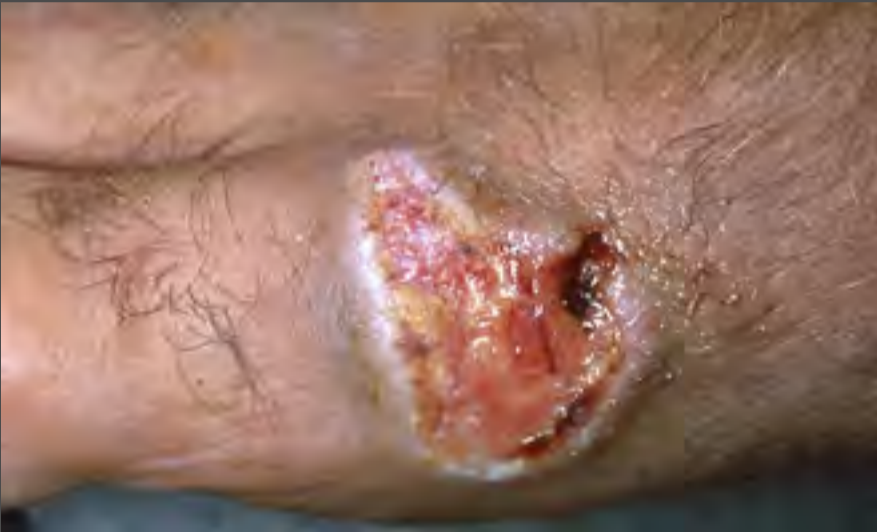Crusty thick-edged ulcers, easily confused clinically with leishmaniasis



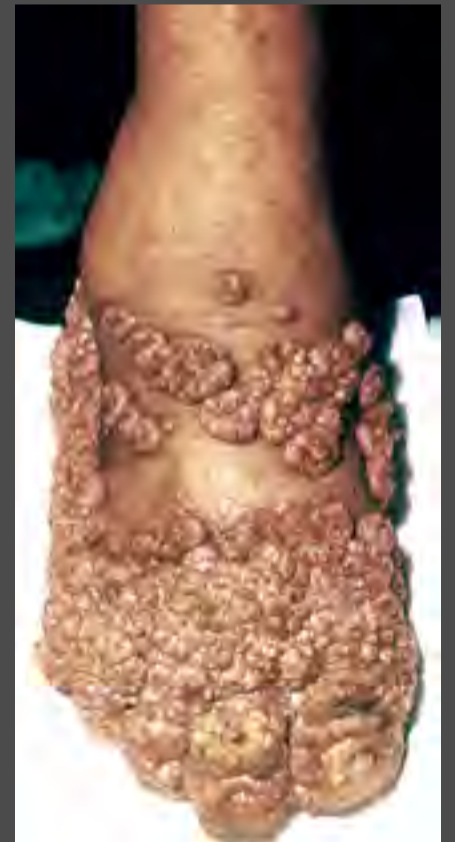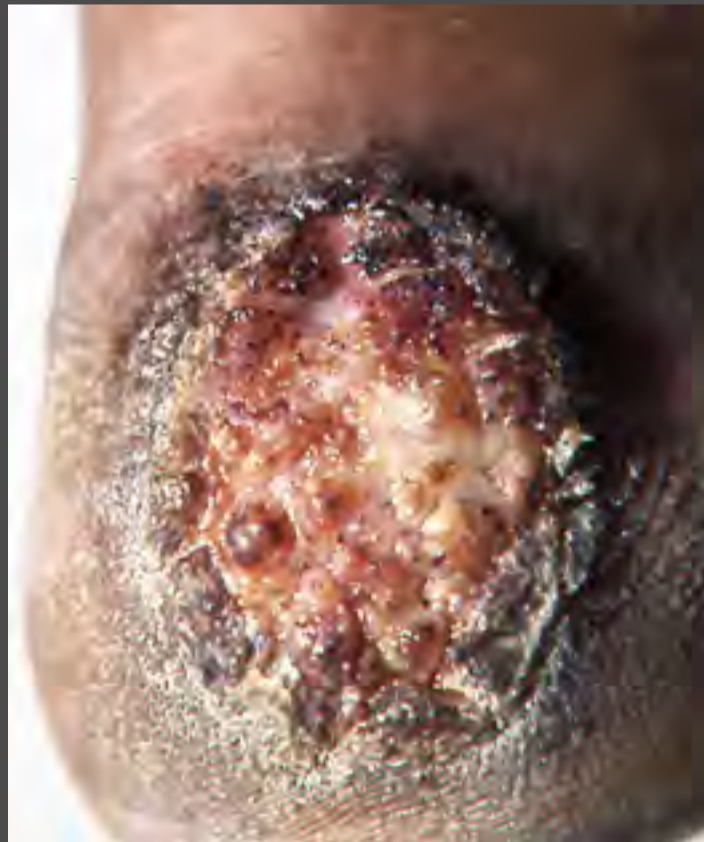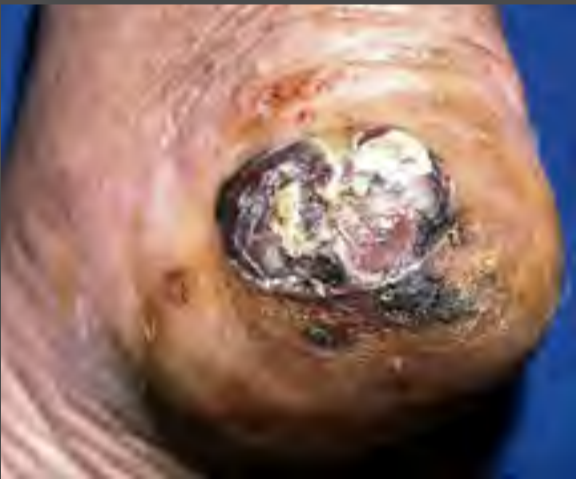**Figure 3.265C.**

Numerous ulcerated lesions of the cheek and neck, which might be confused with superinfected leishmaniasis ulcers. Patient presented major inflammatory adenopathies and, in addition, weight loss and poor general condition.

## Paracoccidioidomycosis



**Figure 3.266A.**  
Ulcer on the big toe very similar to a leishmaniasis ulcer

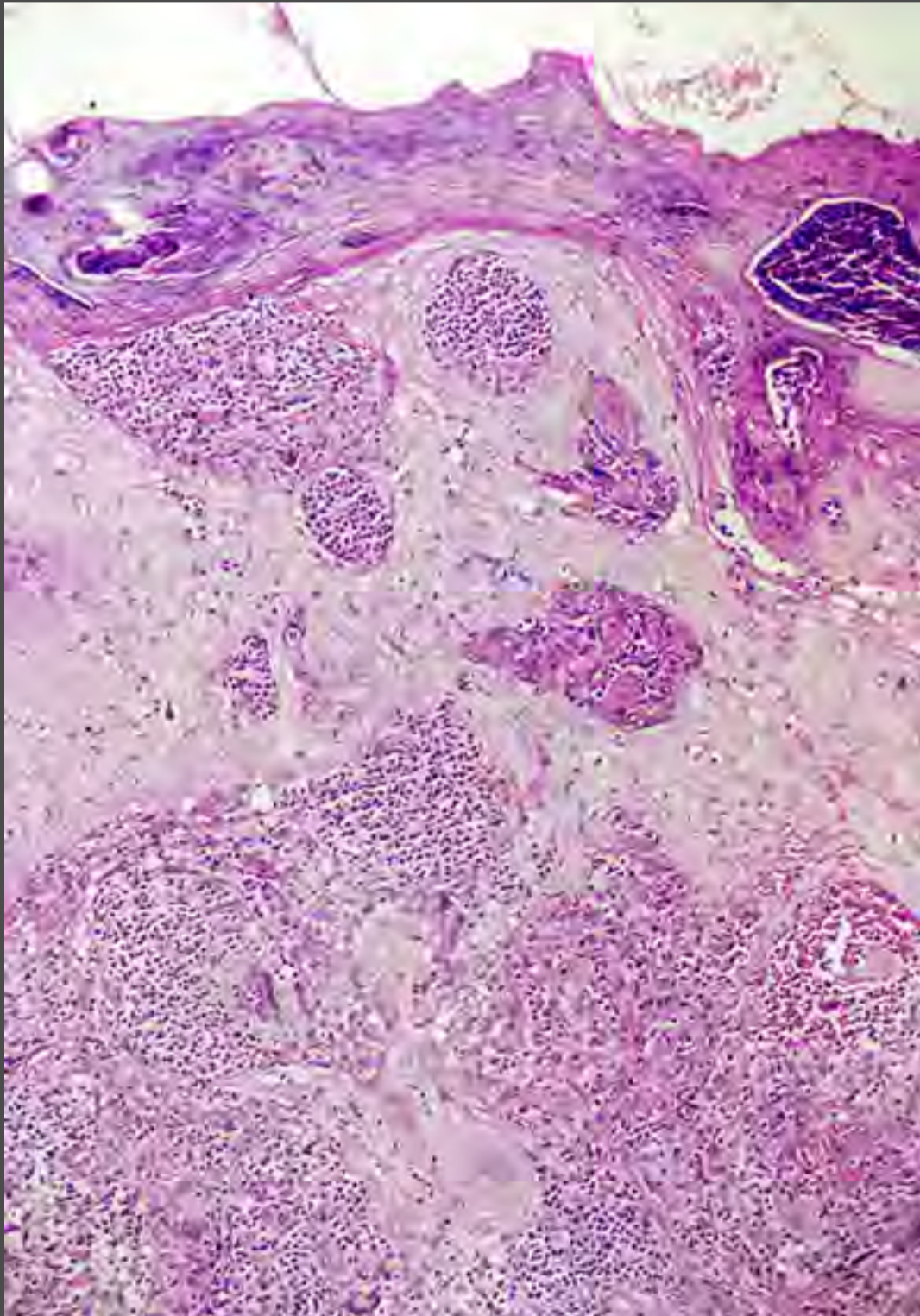
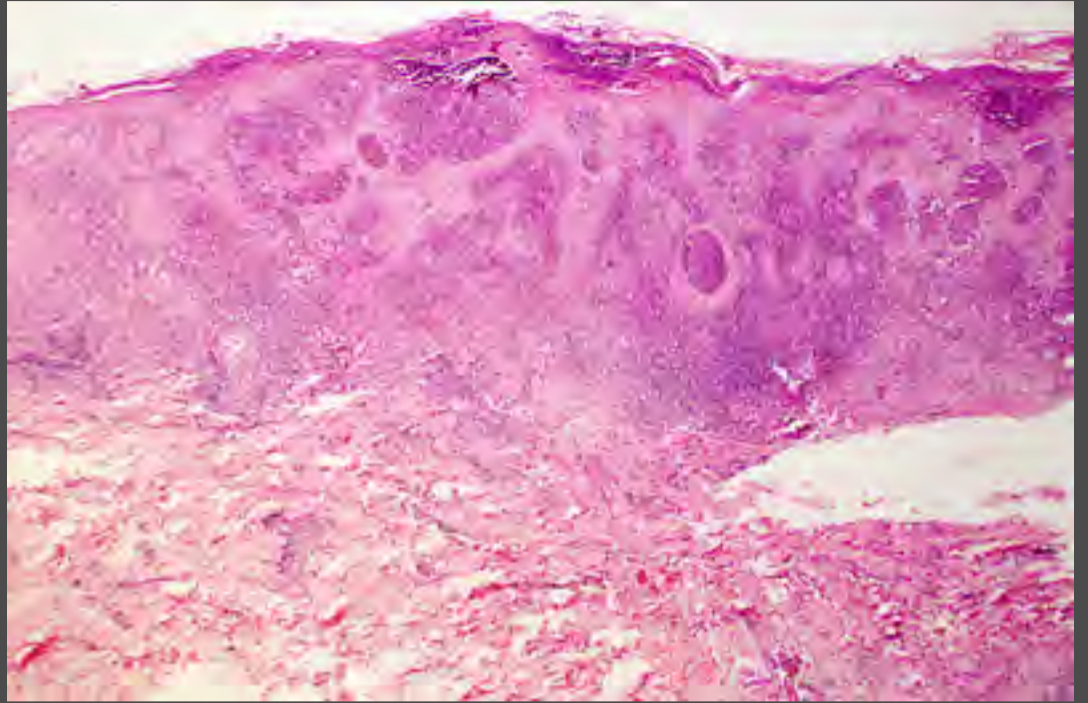


**Figures 3.266B, C and D.**  
This type of ulcer suggests a malignant tumor. It represents spread of mycosis from the lung. The biopsy clears up any diagnostic uncertainty.

## Paracoccidioidomycosis

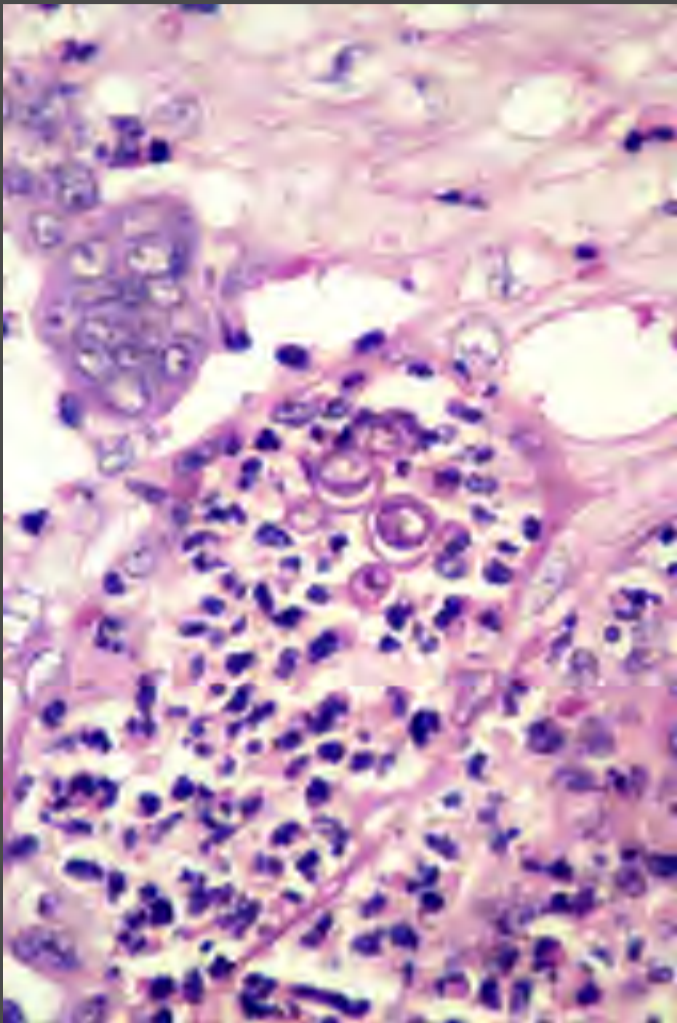
**Figure 3.267A.**

Characteristic histopathology. The picture shows epidermal hyperplasia, parakeratosis, and transepidermal elimination of inflammatory cells that include abscesses and granulomata; hematoxylin and eosin, 3X.

**Figure 3.267B.**

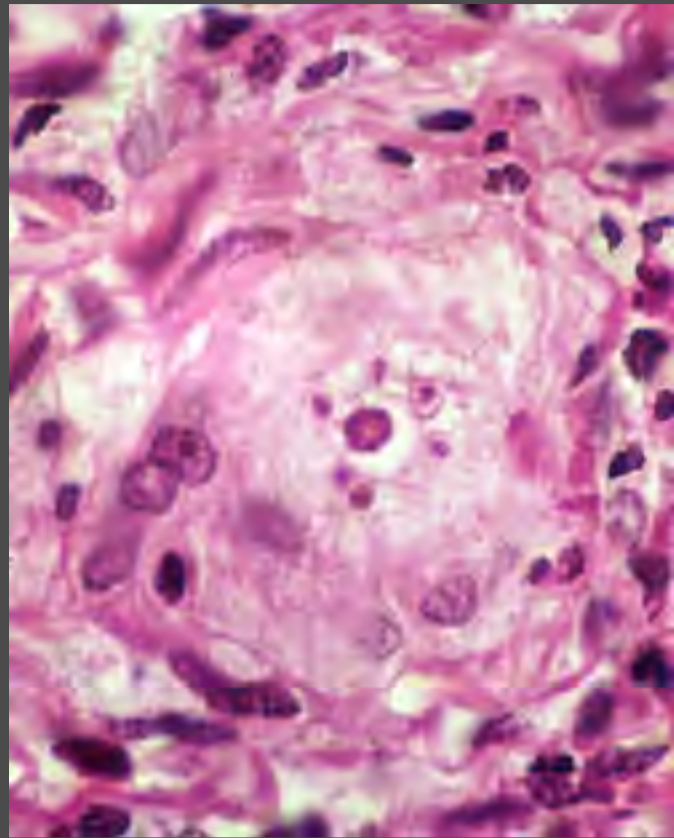
At greater magnification, the same changes can be seen in greater detail; hematoxylin and eosin, 10X.

## Paracoccidioidomycosis



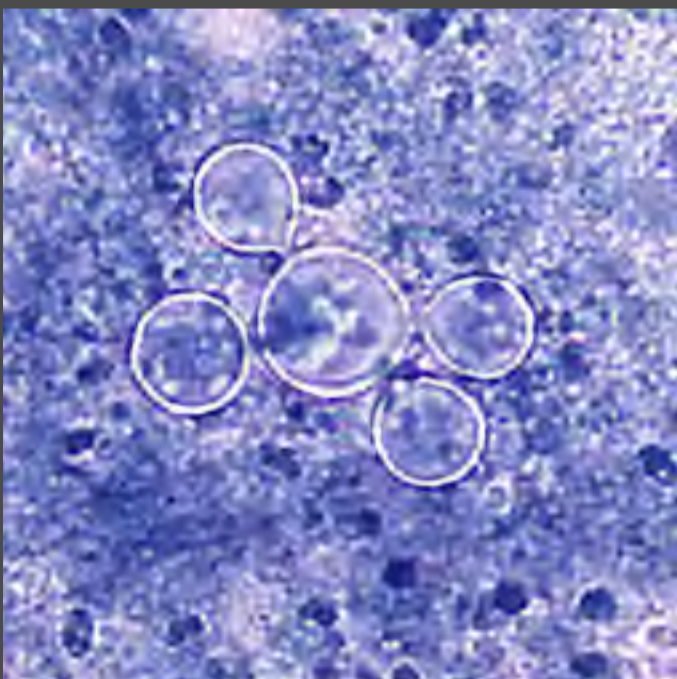**Figure 3.267C.**

Subepithelial abscess with several yeasts with multiple buds; hematoxylin and eosin, 40X



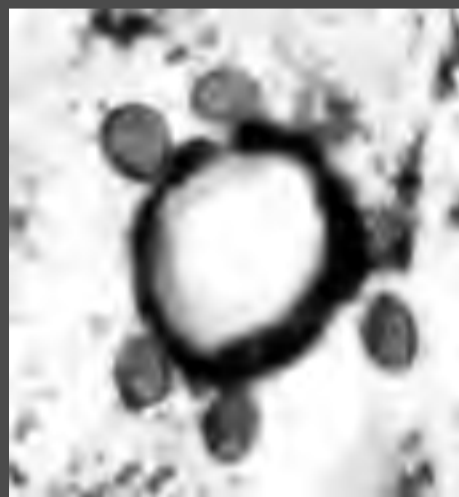**Figure 3.267D.**

Giant cell containing typical yeasts in the form of a ship's wheel; hematoxylin and eosin, 100X.



**Figure 3.268A.**

Direct smear of a lesion or sputum reveals yeasts (chlamydospores) with multiple buds attached by a small stalk to the central yeast, resembling a ship's wheel; Giemsa stain, 100X.



**Figure 3.268B.**

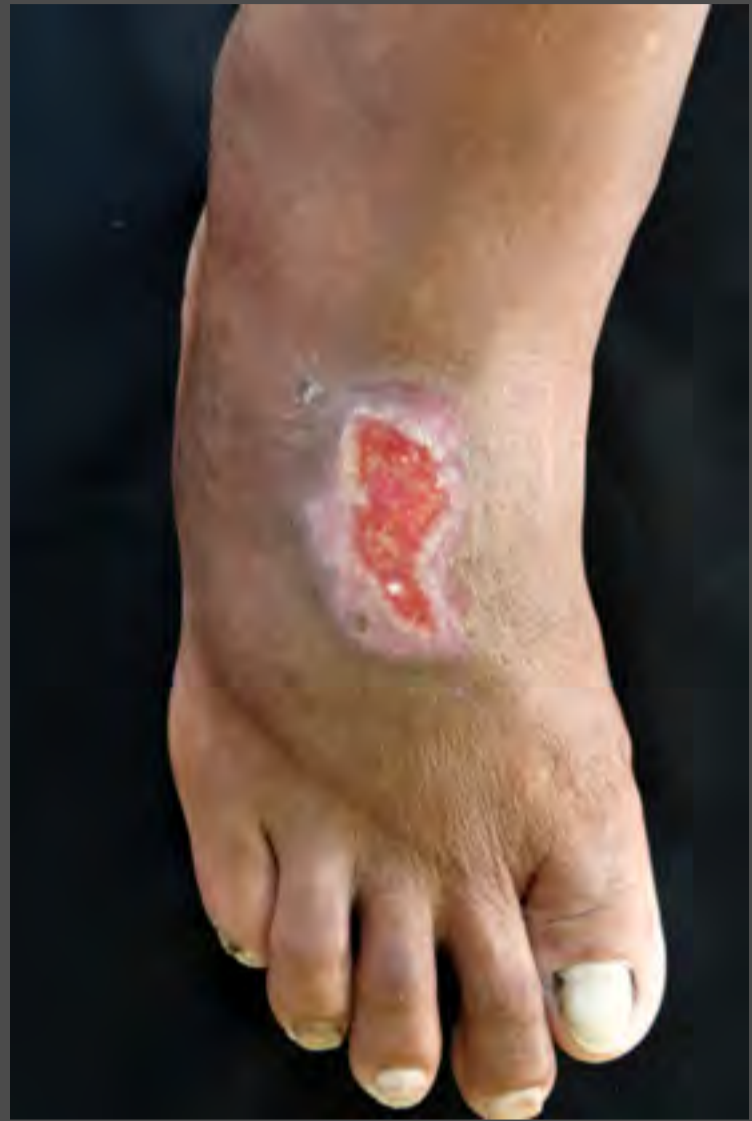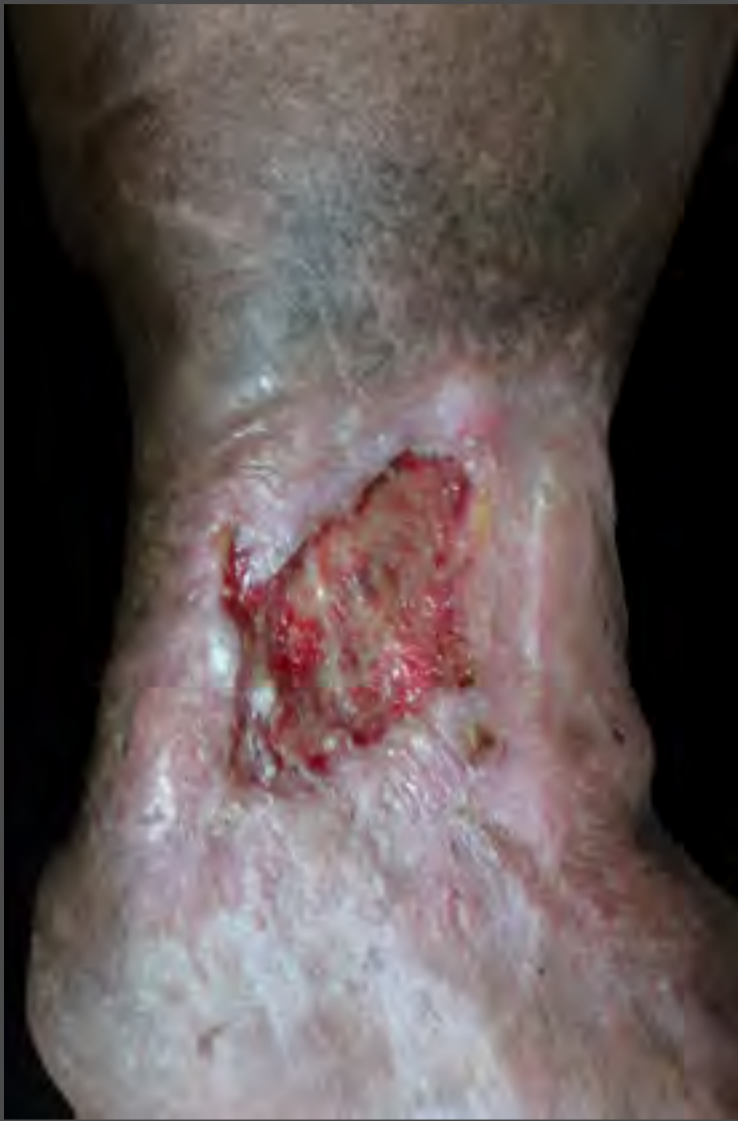Silver-methenamine staining makes the central yeast and its smaller buds easy to see; Grocott stain, 100X.



## Inflammatory and Reactive Diseases

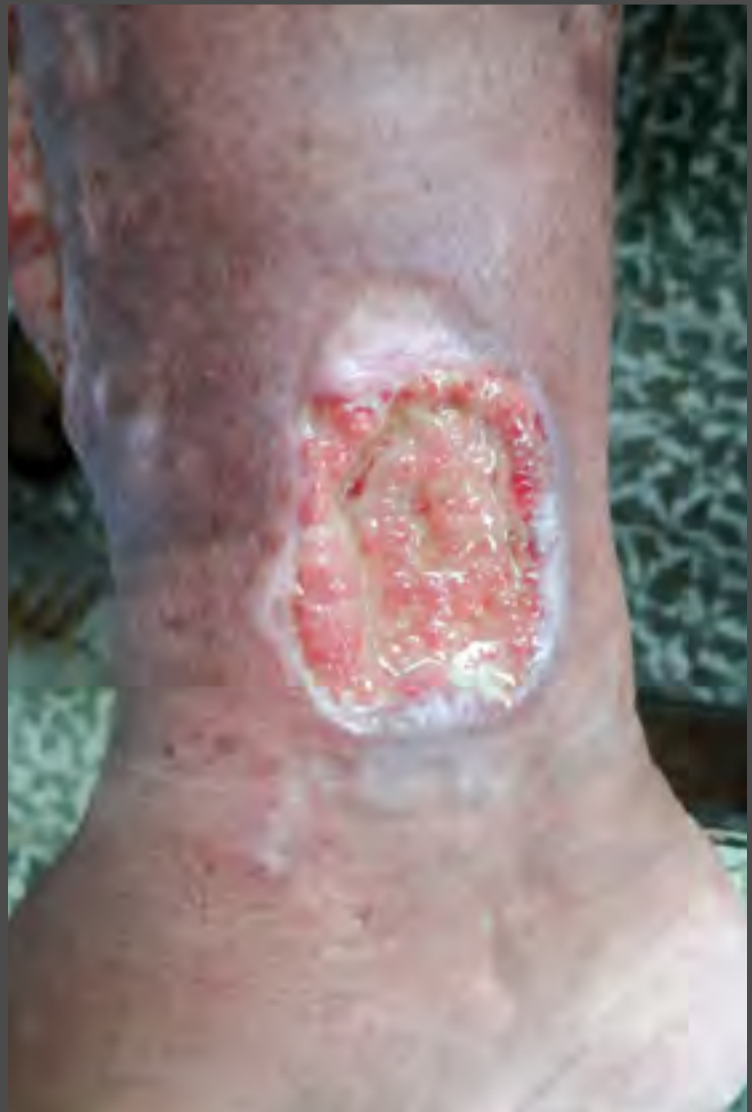*Venous ulcers.* Sometimes ulcers can occur on the legs due to insufficiency of superficial and deep veins and, therefore, they are a necessary differential diagnosis of leishmaniasis. A clinical history, the presence of evident varicosities, and trophic changes in the skin—hyperpigmentation, chronic eczema, and lichenification—are the norm. The ulcers are very irregular in shape and size, the edges are flush with the skin, they are violet in color, and the center has some granulation and tends to be coated with fibrin membranes or has a seropurulent discharge (*Figures 3.269 to 3.273*). There may be a history of repeated ulcers and confirming scars.

## Venous ulcers

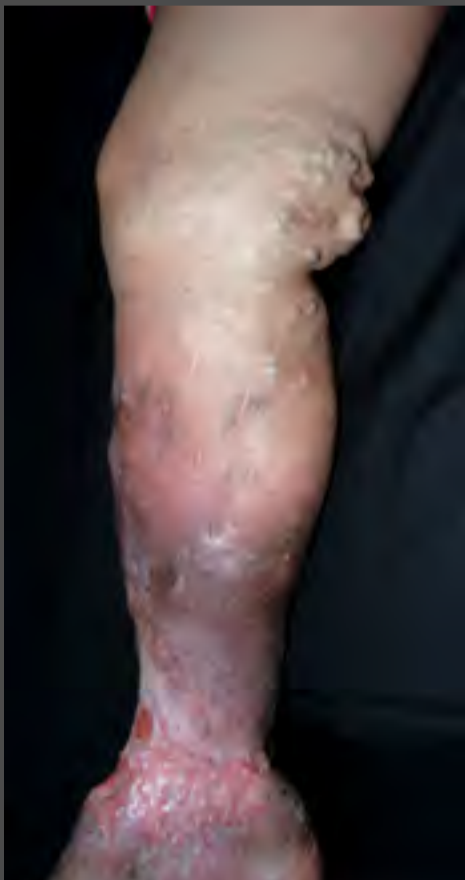
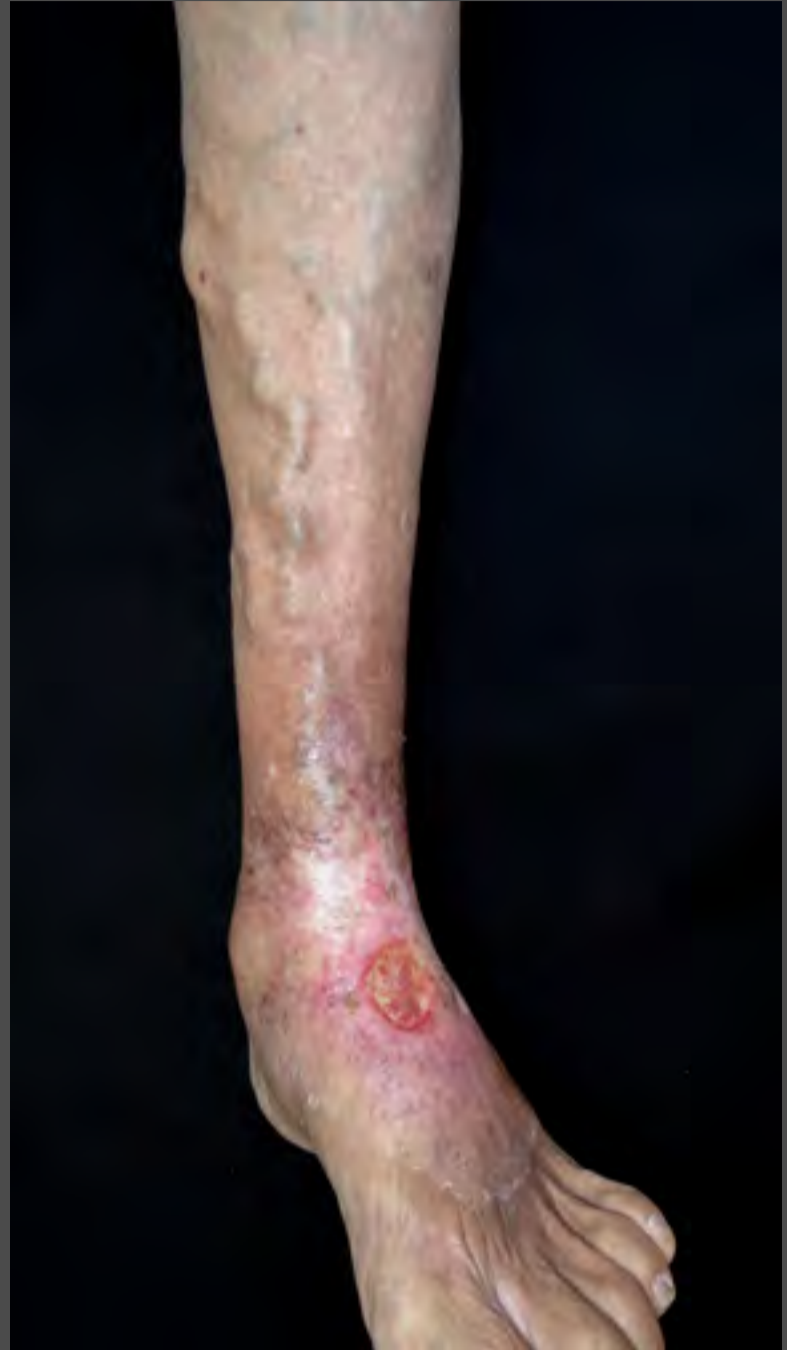
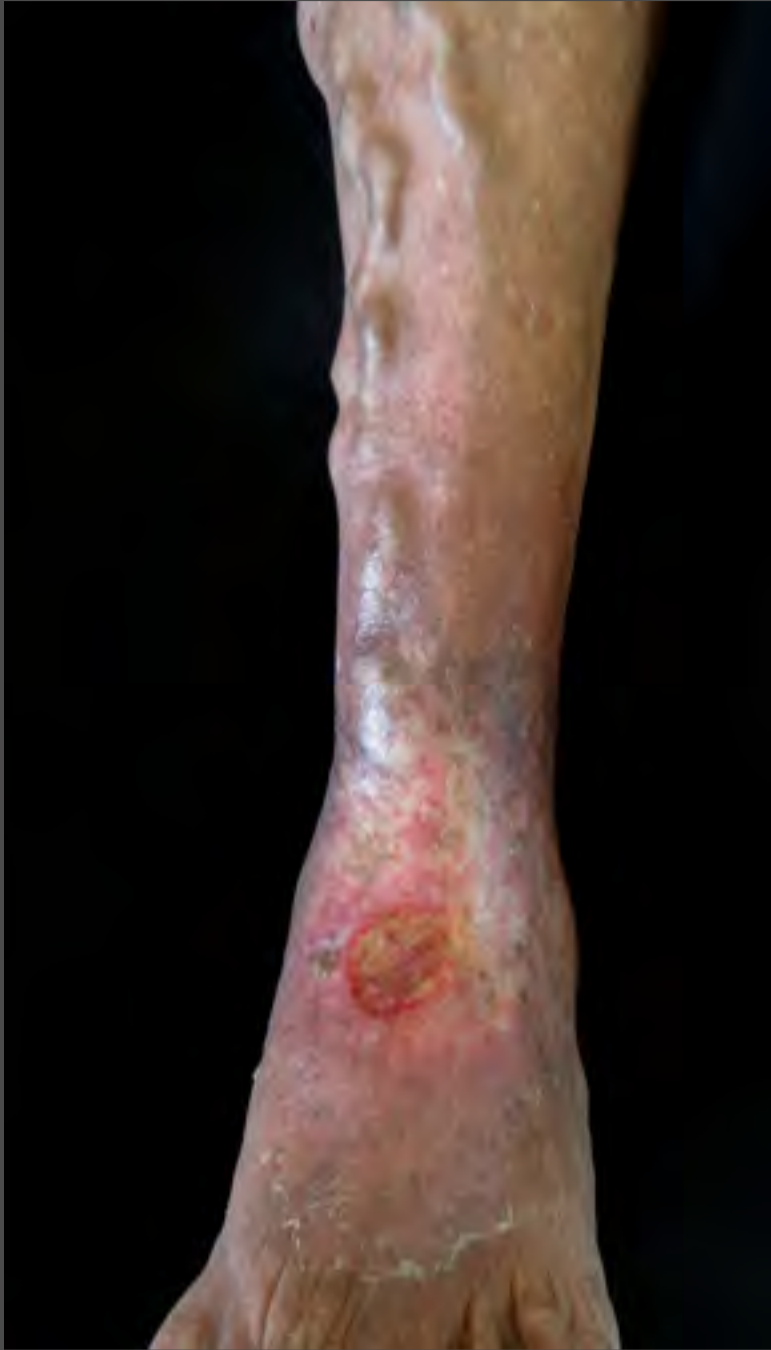**Figures 3.269A, B and C.**

Venous ulcers are more frequent on the inner malleolus, although they may affect the distal two-thirds of the leg and top of the feet.



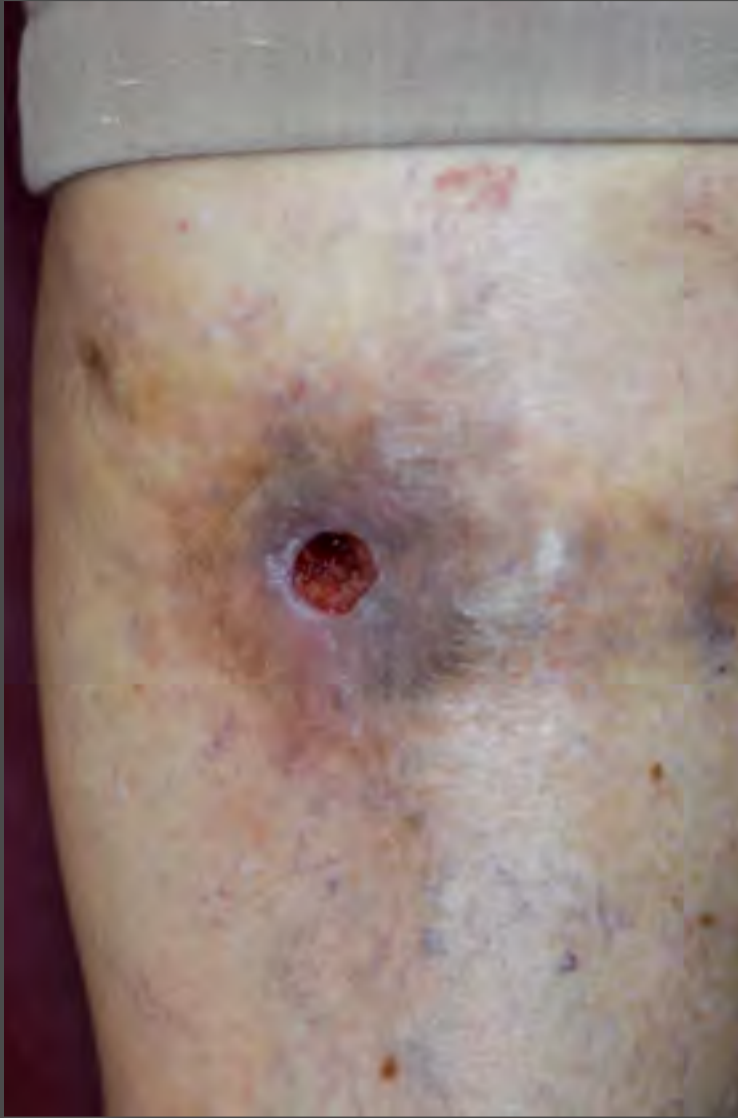## Venous ulcers



**Figures 3.270A, B and C.**

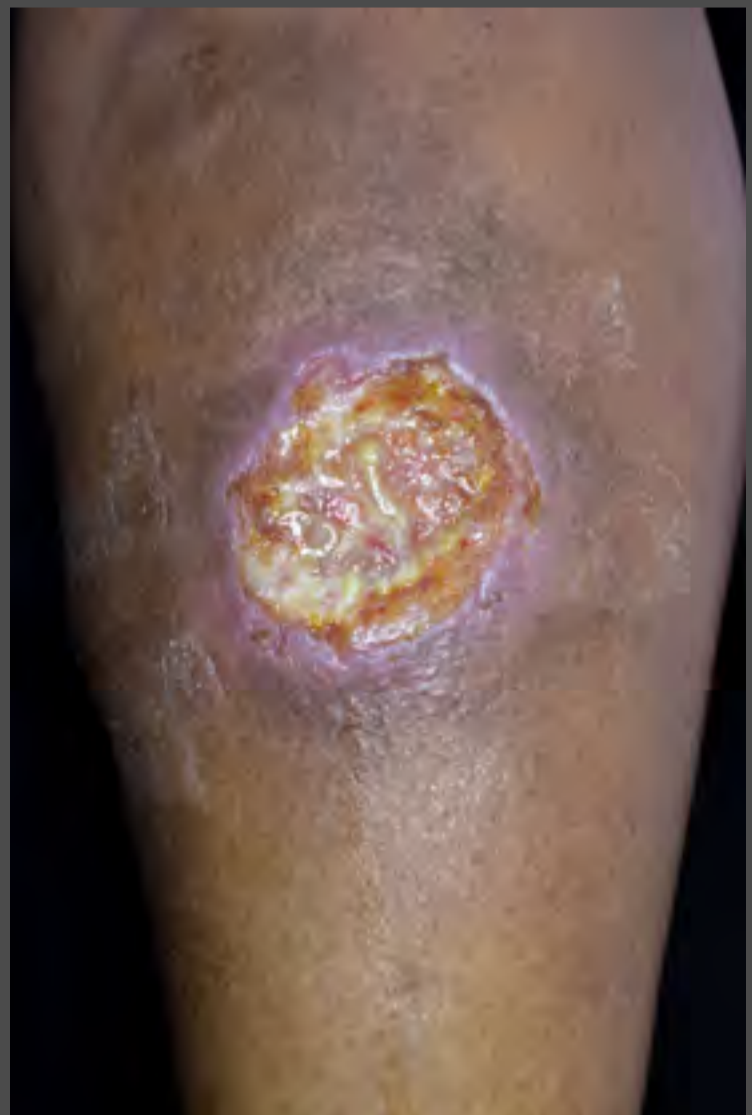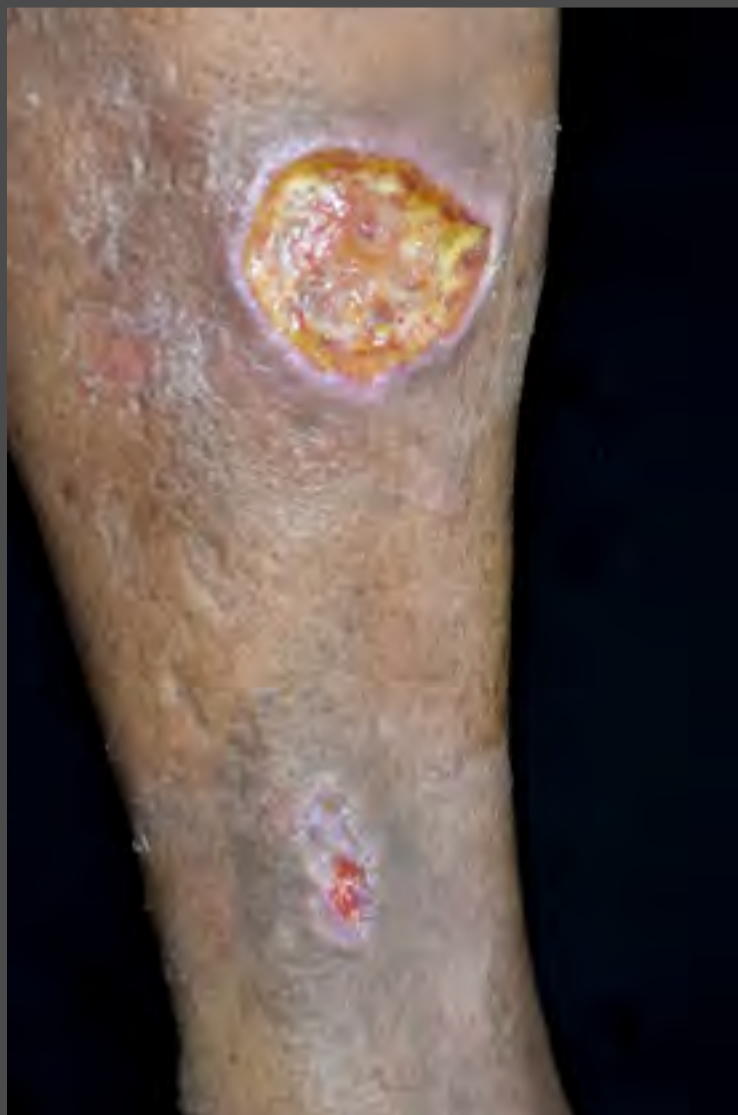The superficial venous system of the legs may become visible due to chronic insufficiency from valvular dysfunction, incompetent perforator veins, damage to the deep venous system, or muscle pump failure.

## Venous ulcers

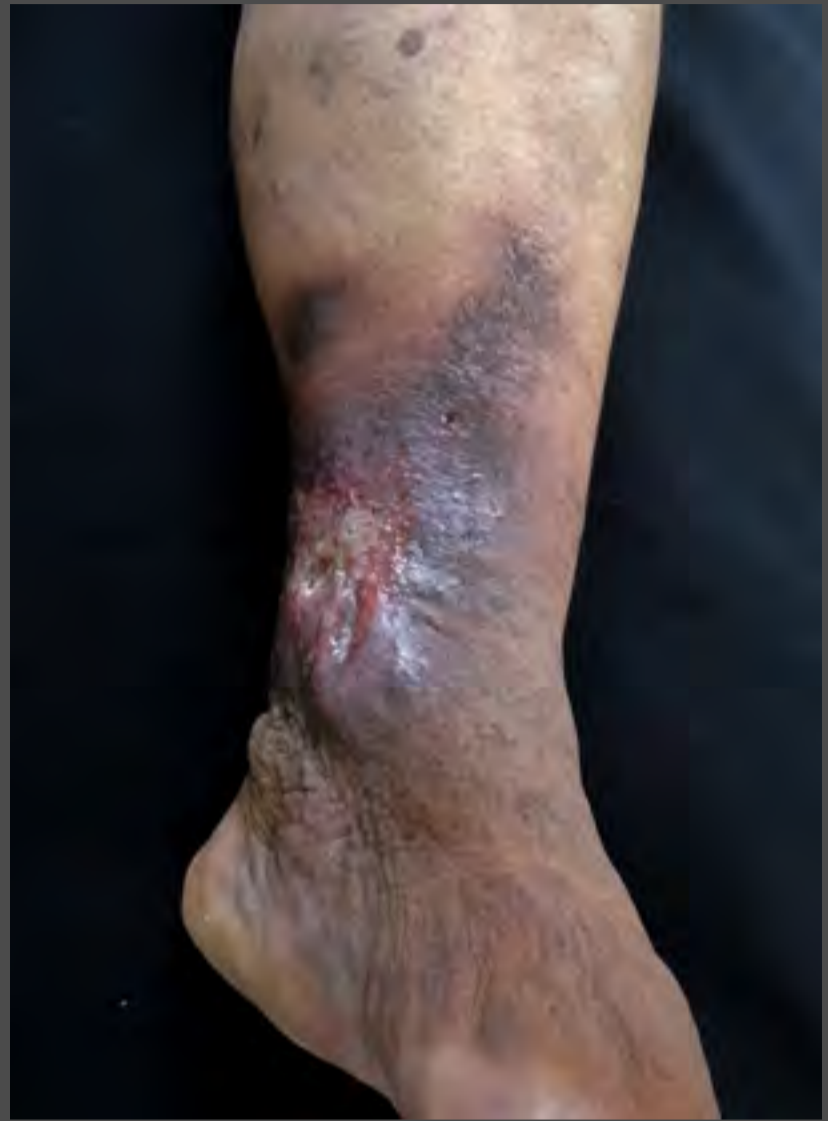
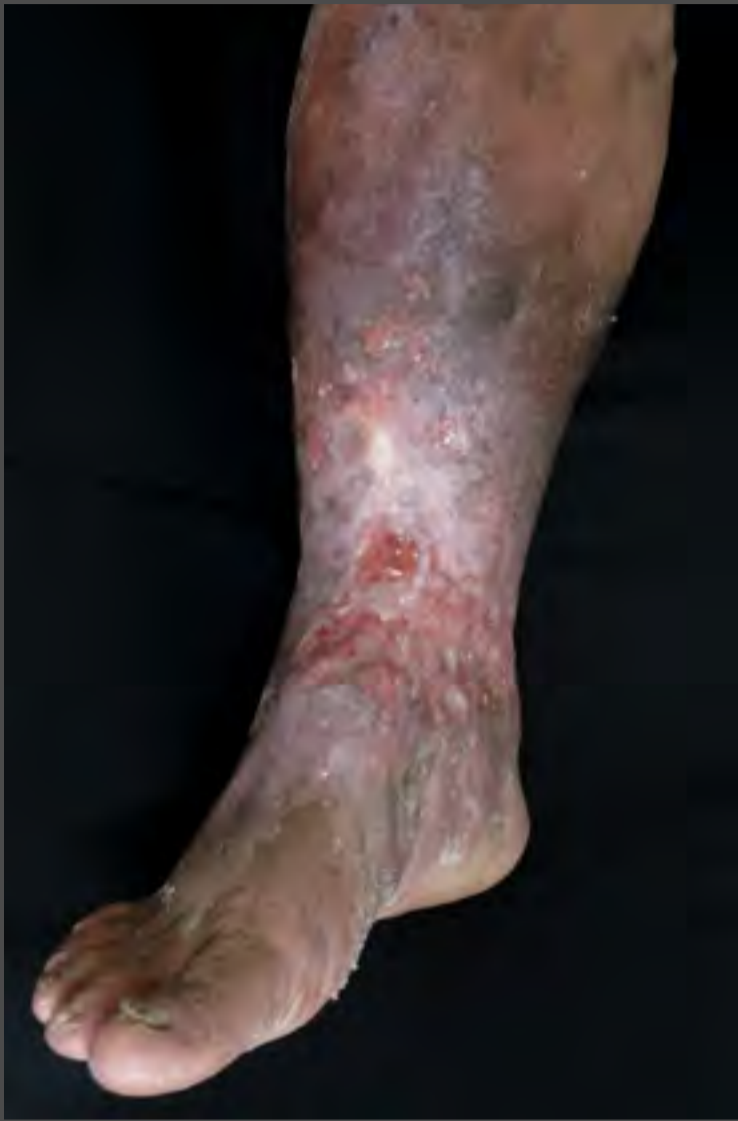
**Figures 3.271A, B and C.**

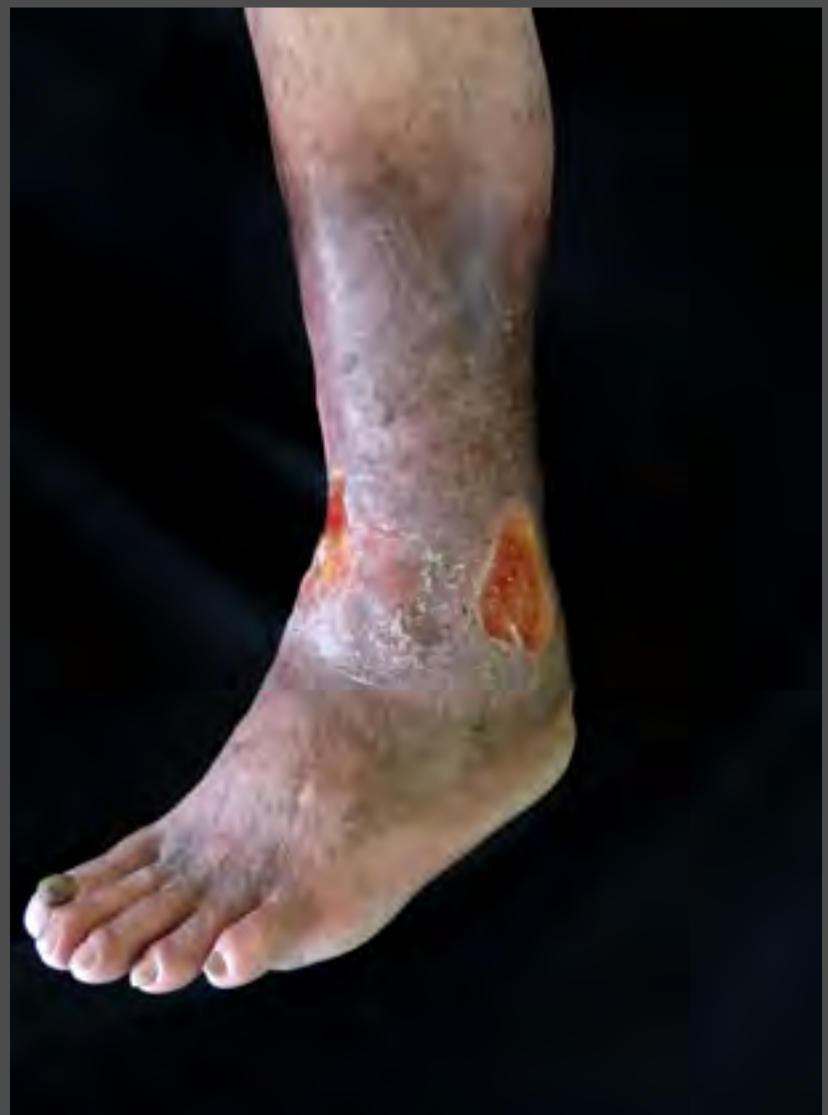Venous ulcers may appear without evident superficial varicose veins, due to deep venous system incompetence or thrombosis causing local venous hypertension.



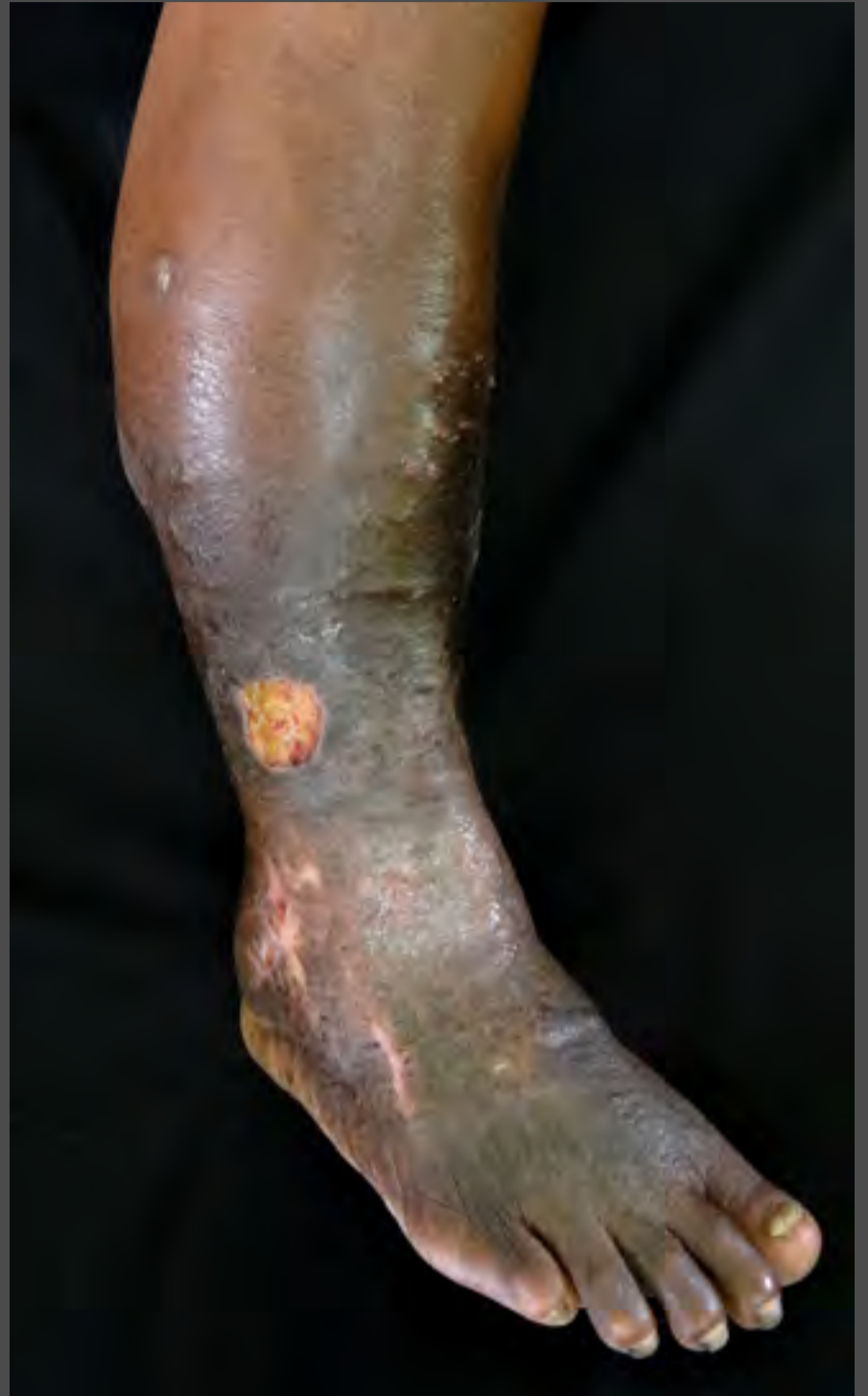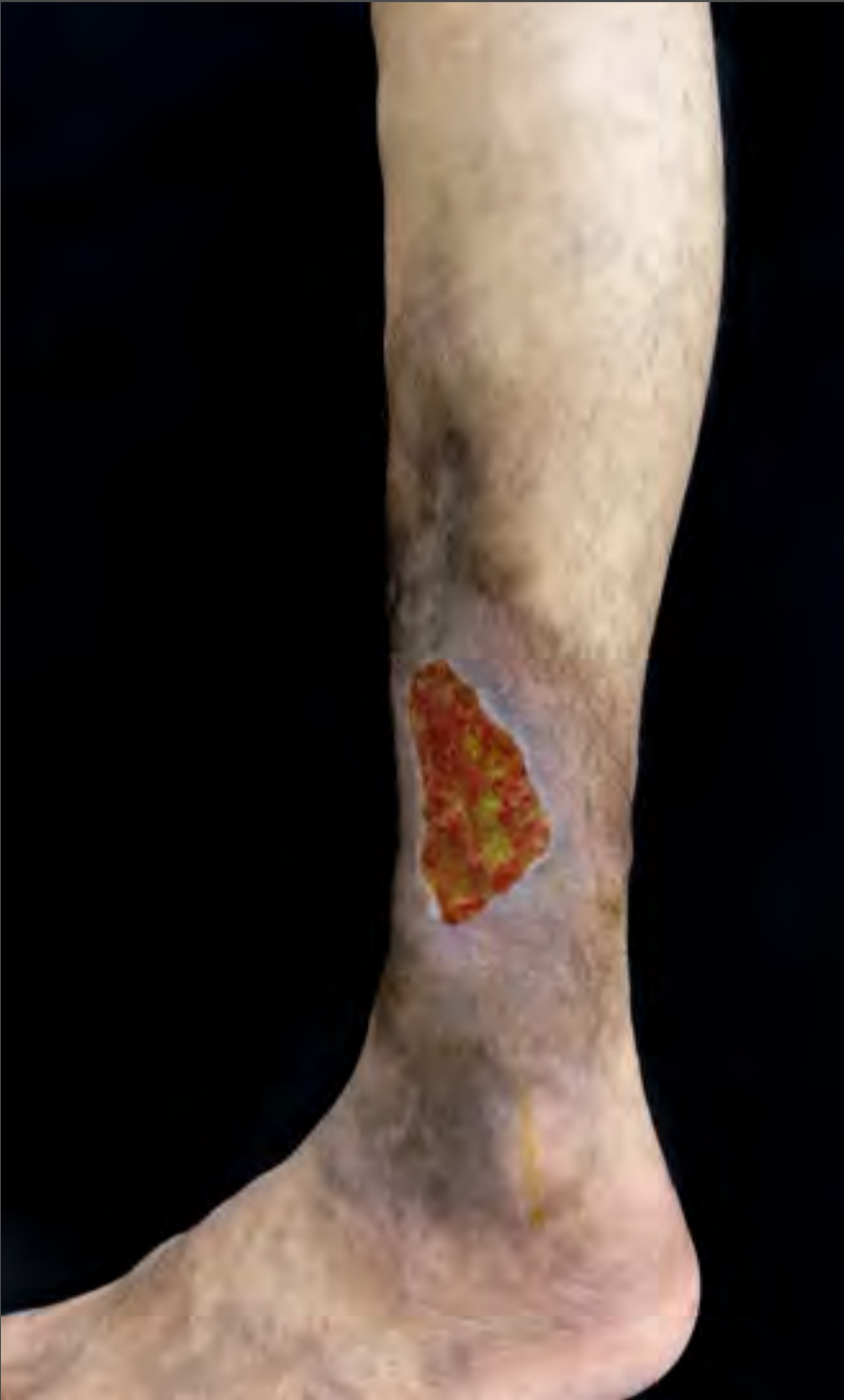## Venous ulcers

**Figures 3.272A, B and C.**

Slow blood flow, edema, and extravasation of cells and fibrin lead to fibrosis, thickening of the skin, and diffuse hyperpigmentation and, frequently, pruritus, which constitute stasis dermatitis, a chronic disorder that lasts for years and is accompanied by ulcers. Previous ulcer scars are frequently found.



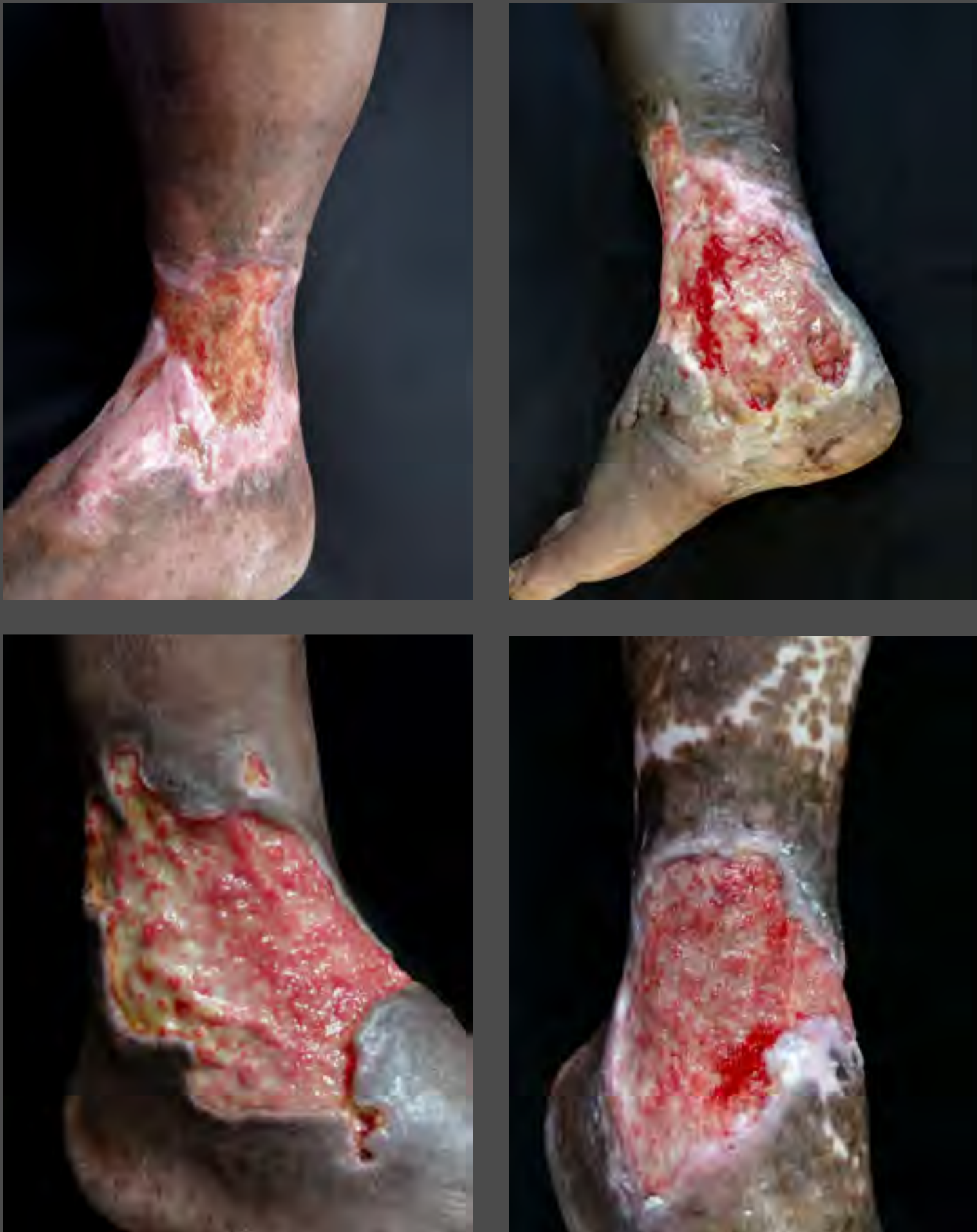## Venous ulcers



**Figures 3.272D and E.**

Slow blood flow, edema, and extravasation of cells and fibrin lead to fibrosis, thickening of the skin, and diffuse hyperpigmentation and, frequently, pruritus, which constitute stasis dermatitis, a chronic disorder that lasts for years and is accompanied by ulcers. Previous ulcer scars are frequently found.

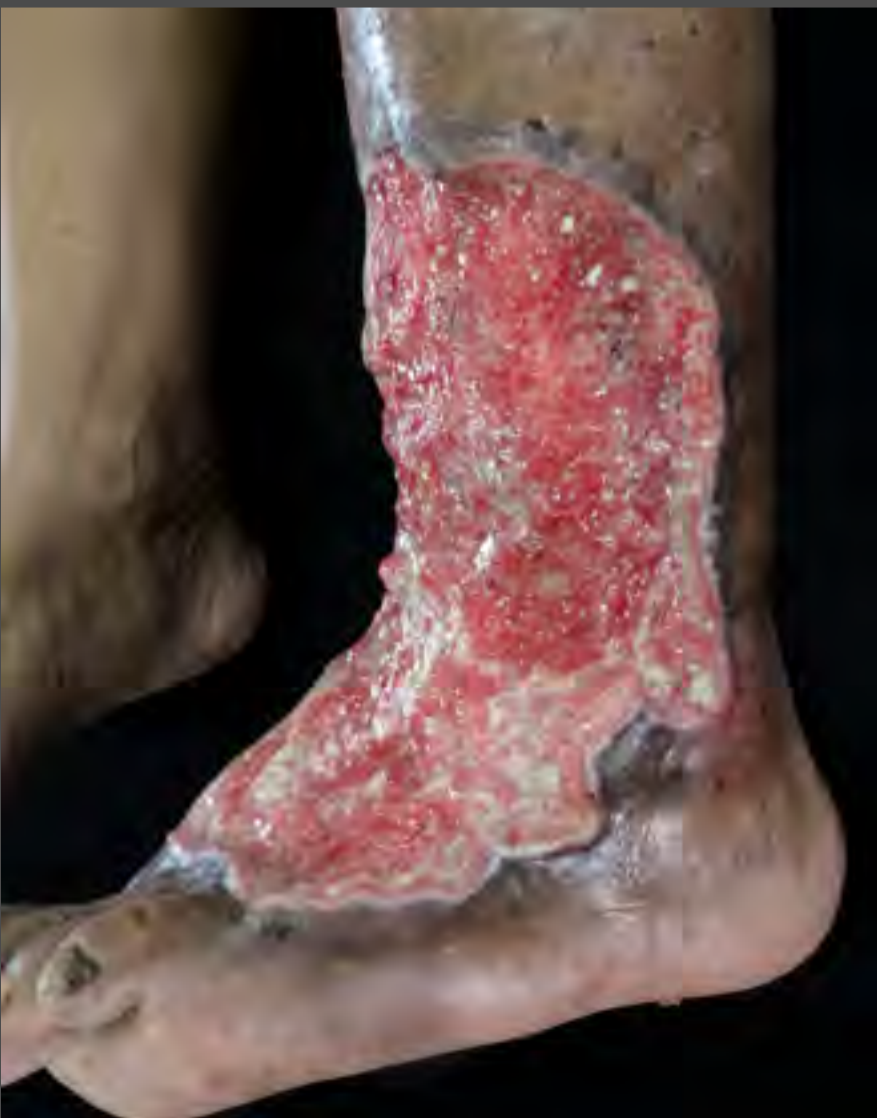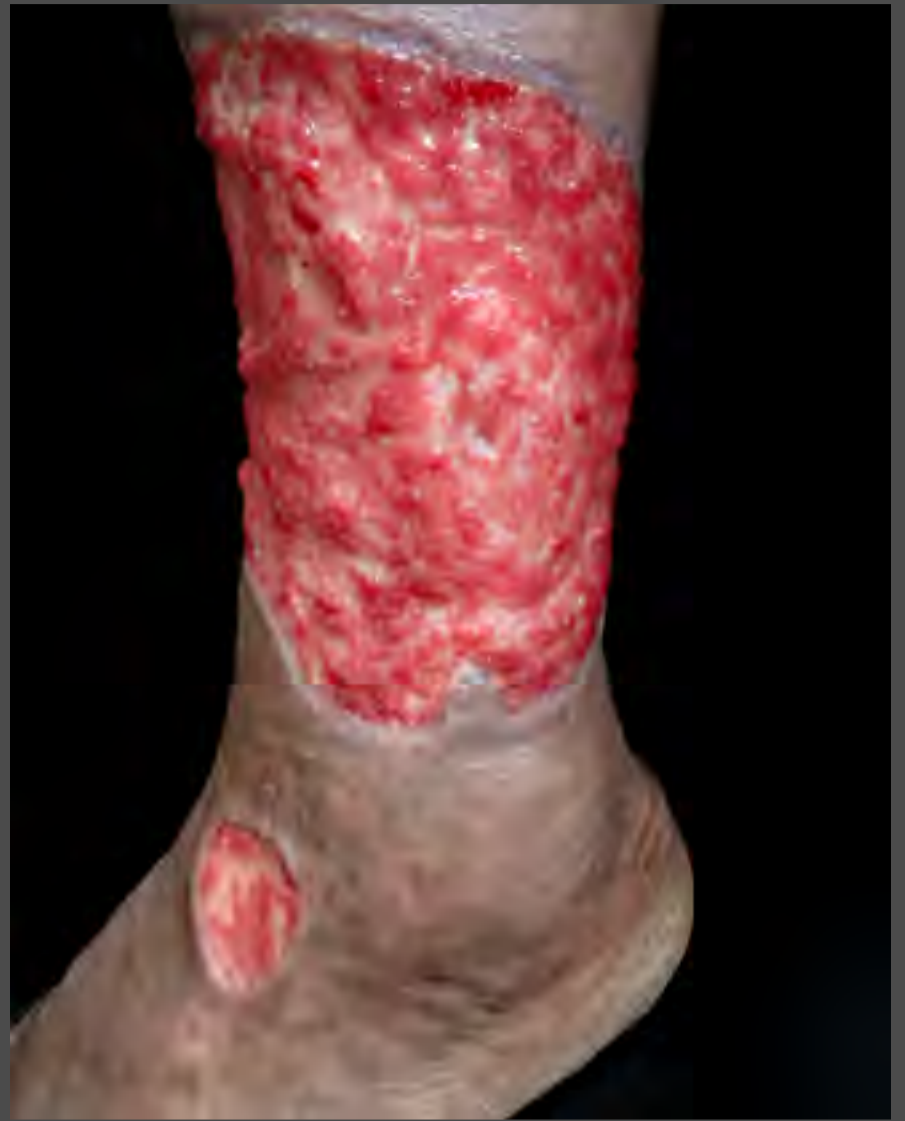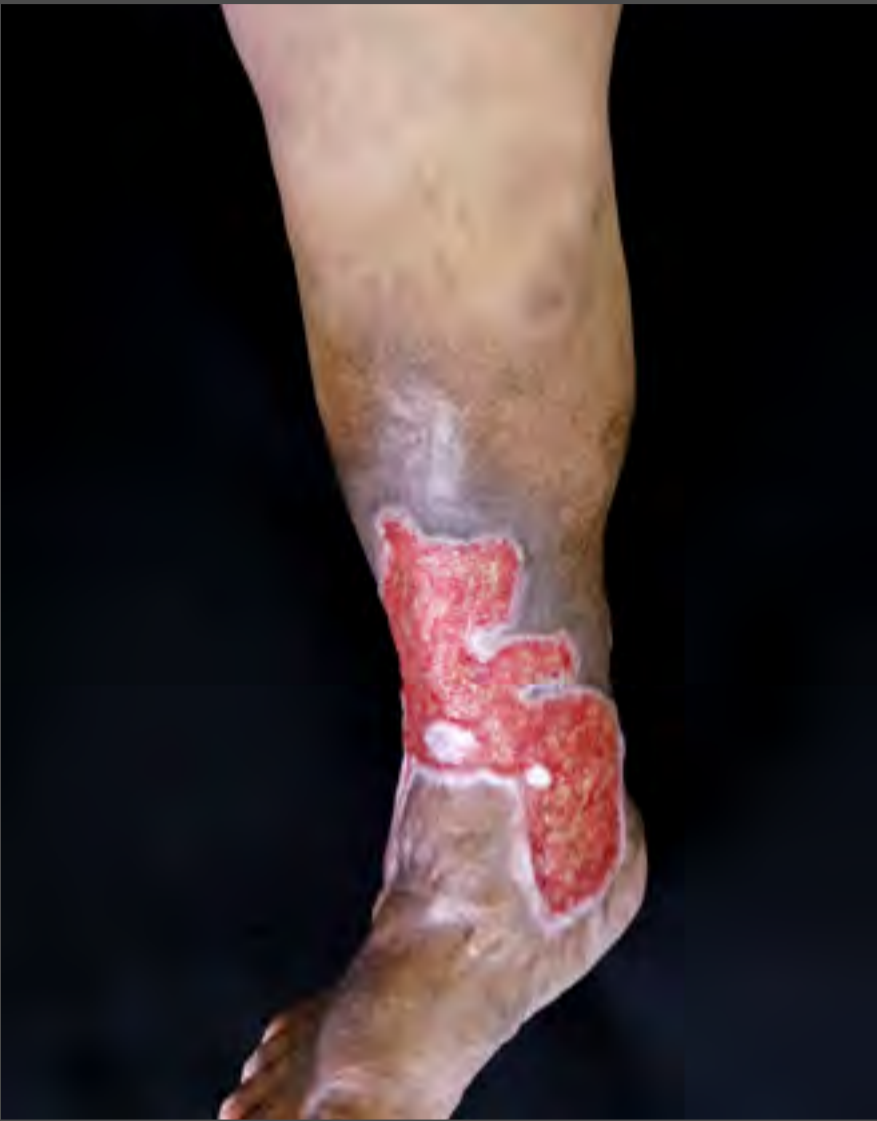## Venous ulcers



**Figures 3.273A, B, C and D.**

Ulcers may develop spontaneously or after minor trauma, growing to affect very large areas of the leg and the foot in a matter of weeks or a few months. They tend to be very irregularly shaped, with anfractuous, flat, or depressed edges, and the floor may be covered with serous or purulent membranes or crusts. They are surrounded by chronic dermatitis, evident from edema, erythema, hyperpigmentation, purpura, healing areas, atrophic areas, excoriations, and lichenification. Fat necrosis, loss of subcutaneous cellular tissue, and repeated cicatrization of the skin lead to lipodermatosclerosis, with thinning where the ulcer is located, and thick and edematous skin above it.

## Venous ulcers

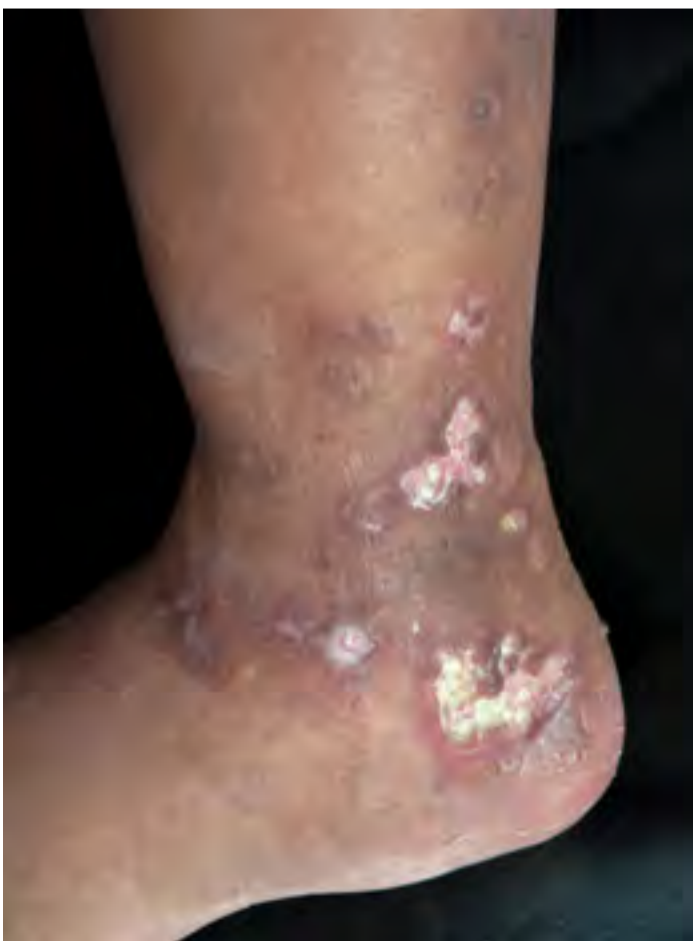
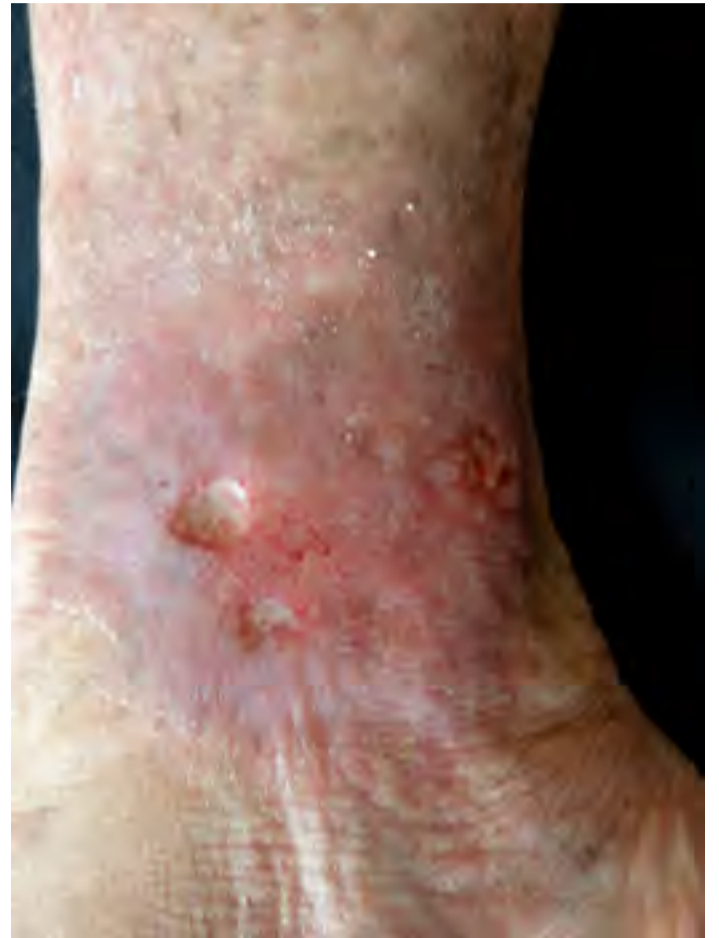
**Figures 3.273E, F and G.**

Ulcers may develop spontaneously or after minor trauma, growing to affect very large areas of the leg and the foot in a matter of weeks or a few months. They tend to be very irregularly shaped, with anfractuous, flat, or depressed edges, and the floor may be covered with serous or purulent membranes or crusts. They are surrounded by chronic dermatitis, evident from edema, erythema, hyperpigmentation, purpura, healing areas, atrophic areas, excoriations, and lichenification. Fat necrosis, loss of subcutaneous cellular tissue, and repeated cicatrization of the skin lead to lipodermatosclerosis, with thinning where the ulcer is located, and thick and edematous skin above it.



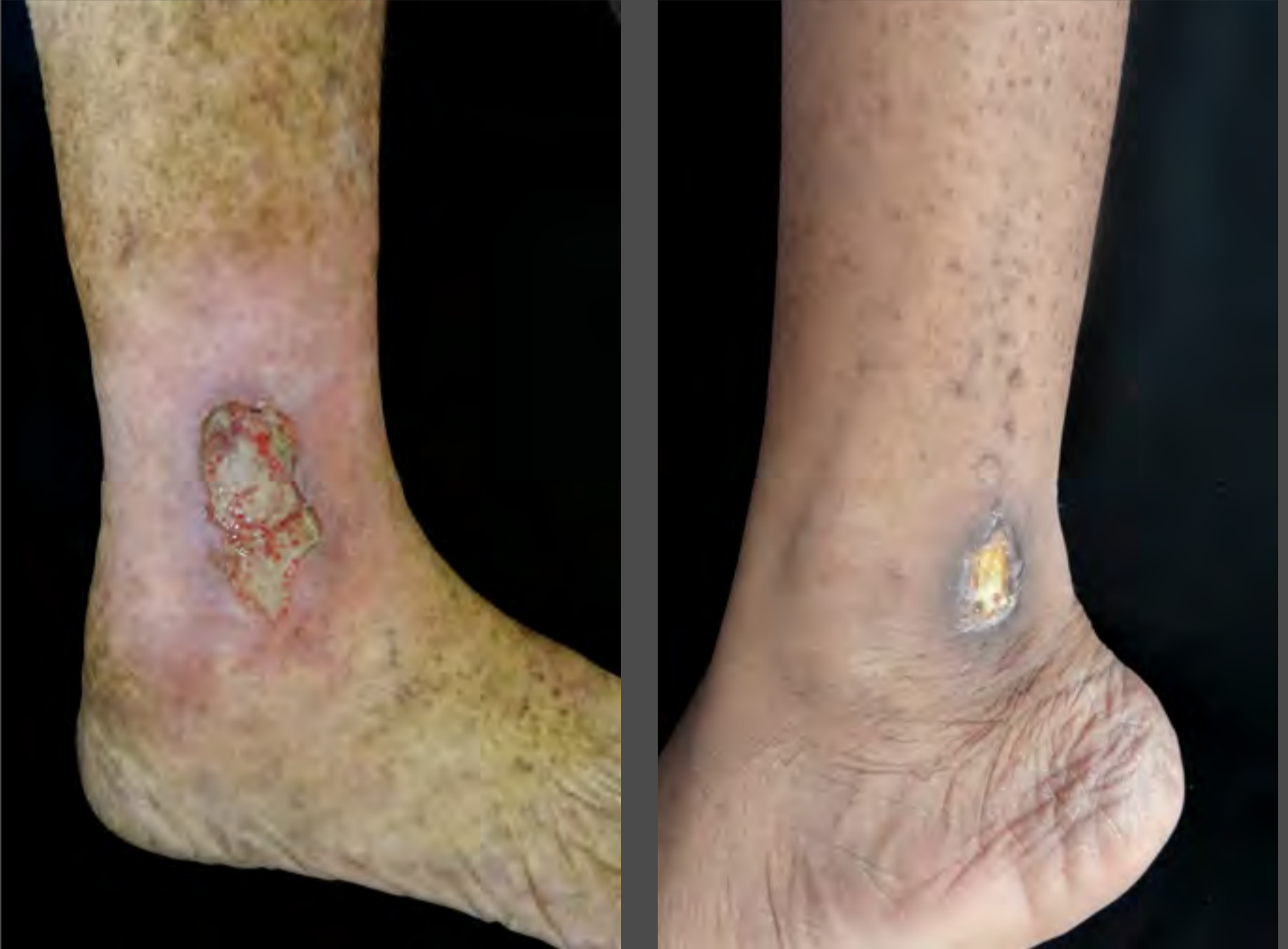
**Arterial ulcers.** As a consequence of a reduction in blood flow of the small vessels in the skin, sores develop on the distal third of the legs and the feet that can be intensely painful. At first, the ulcers are punctiform and grow very irregularly, surrounded by a violet halo, with sunken necrotic edges, and a dirty necrotic center. Other changes secondary to tissue hypoxia are observed, such as atrophy, thinning and shininess of the skin, atrophie blanche, and multiple scars of various sizes, and there is always a history of hypertension, diabetes, dyslipidemia, tobacco use, or other factors that cause atherosclerosis and peripheral arterial insufficiency, with diminished or absent pulses (*Figures 3.274*).



**Figures 3.274A and B.**

Arterial ulcers of the legs result from tissue ischemia secondary to poor tissue perfusion, which causes necrosis. The clinical history is essential for the differential diagnosis; usually, there is a history of hypertension, diabetes, arteriosclerosis, obesity, kidney failure, smoking, or any other condition that involves the microcirculation. They are frequent on the lateral malleolus, distal third of the leg, top of the foot, or backs of the fingers. They begin as small punched-out ulcers with distinct but irregular edges, a reddish or purplish halo, and can be very painful, especially when lying down or doing exercise. The pedis and popliteal pulses may be diminished or absent.

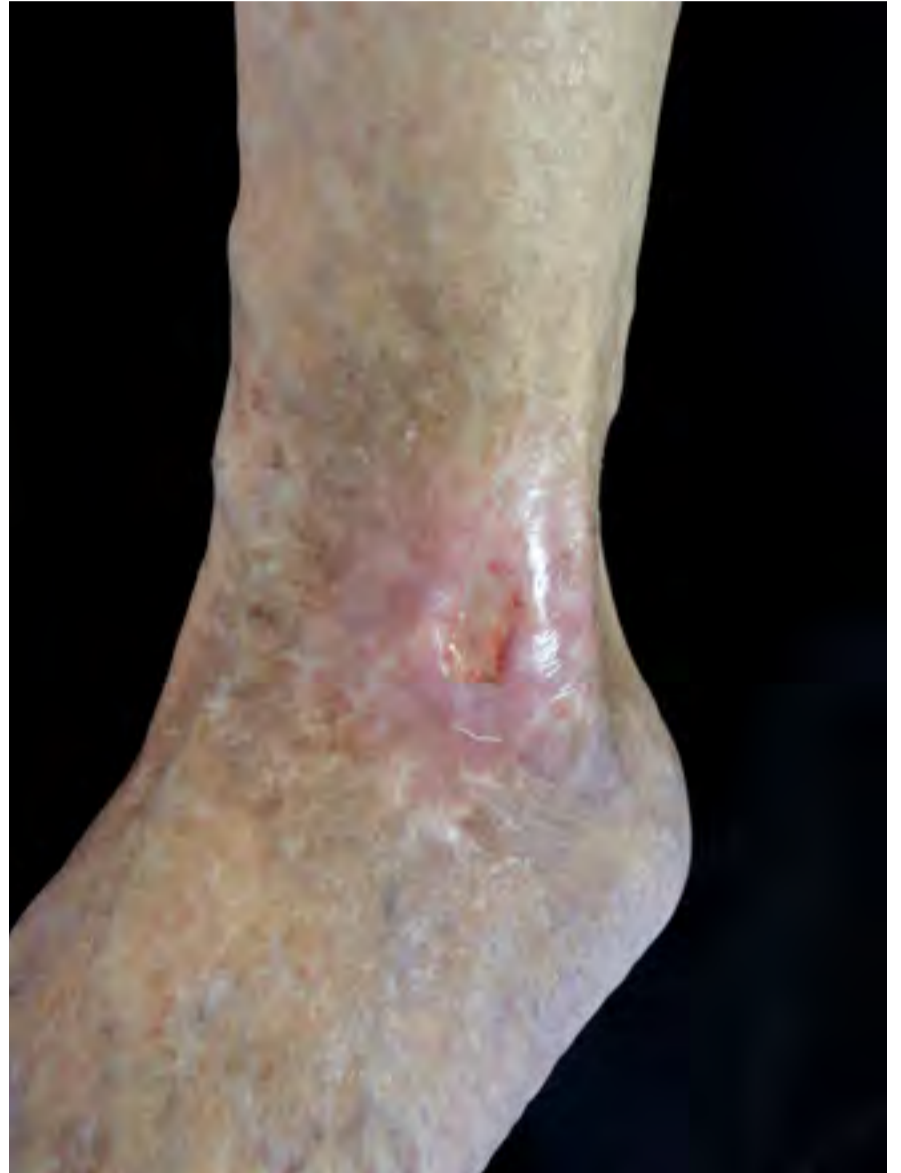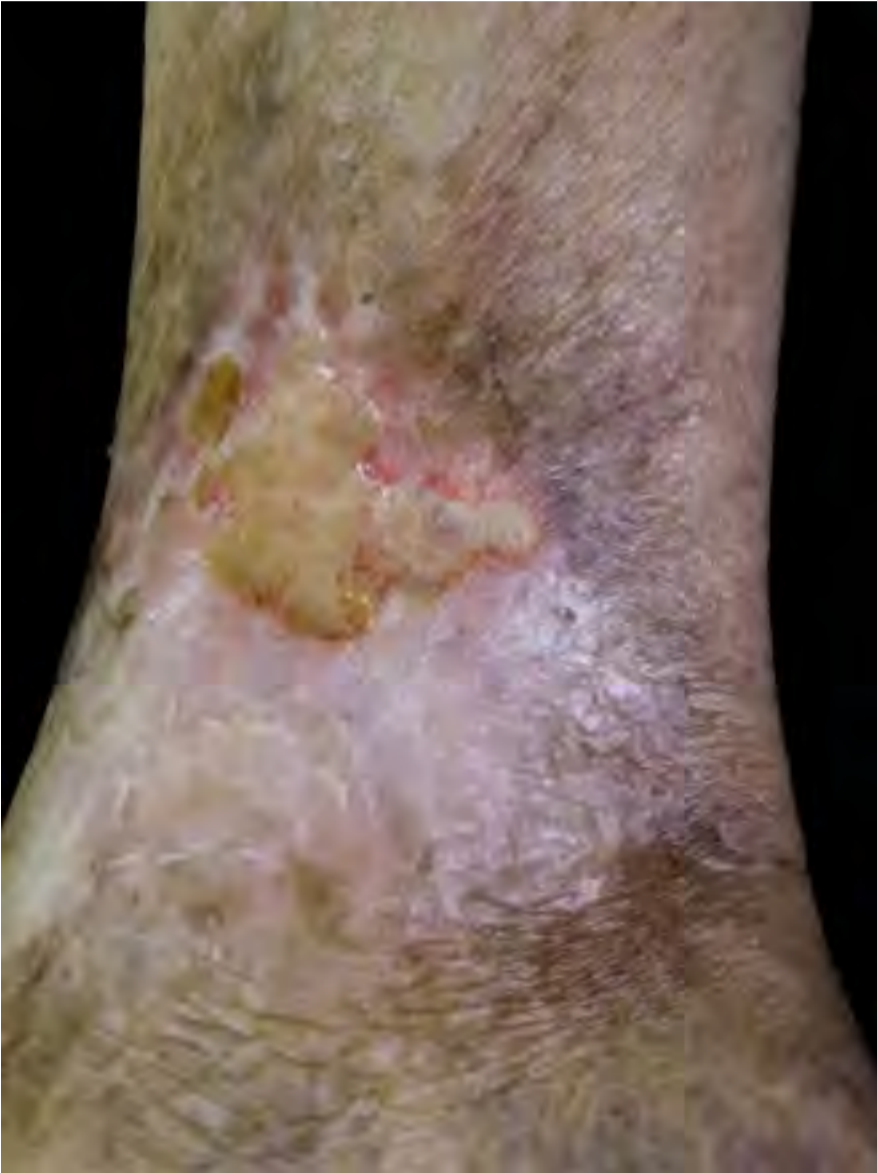## Arterial ulcers



**Figures 3.274C and D.**

Arterial ulcers of the legs result from tissue ischemia secondary to poor tissue perfusion, which causes necrosis. The clinical history is essential for the differential diagnosis; usually, there is a history of hypertension, diabetes, arteriosclerosis, obesity, kidney failure, smoking, or any other condition that involves the microcirculation. They are frequent on the lateral malleolus, distal third of the leg, top of the foot, or backs of the fingers. They begin as small punched-out ulcers with distinct but irregular edges, a reddish or purplish halo, and can be very painful, especially when lying down or doing exercise. The pedis and popliteal pulses may be diminished or absent.

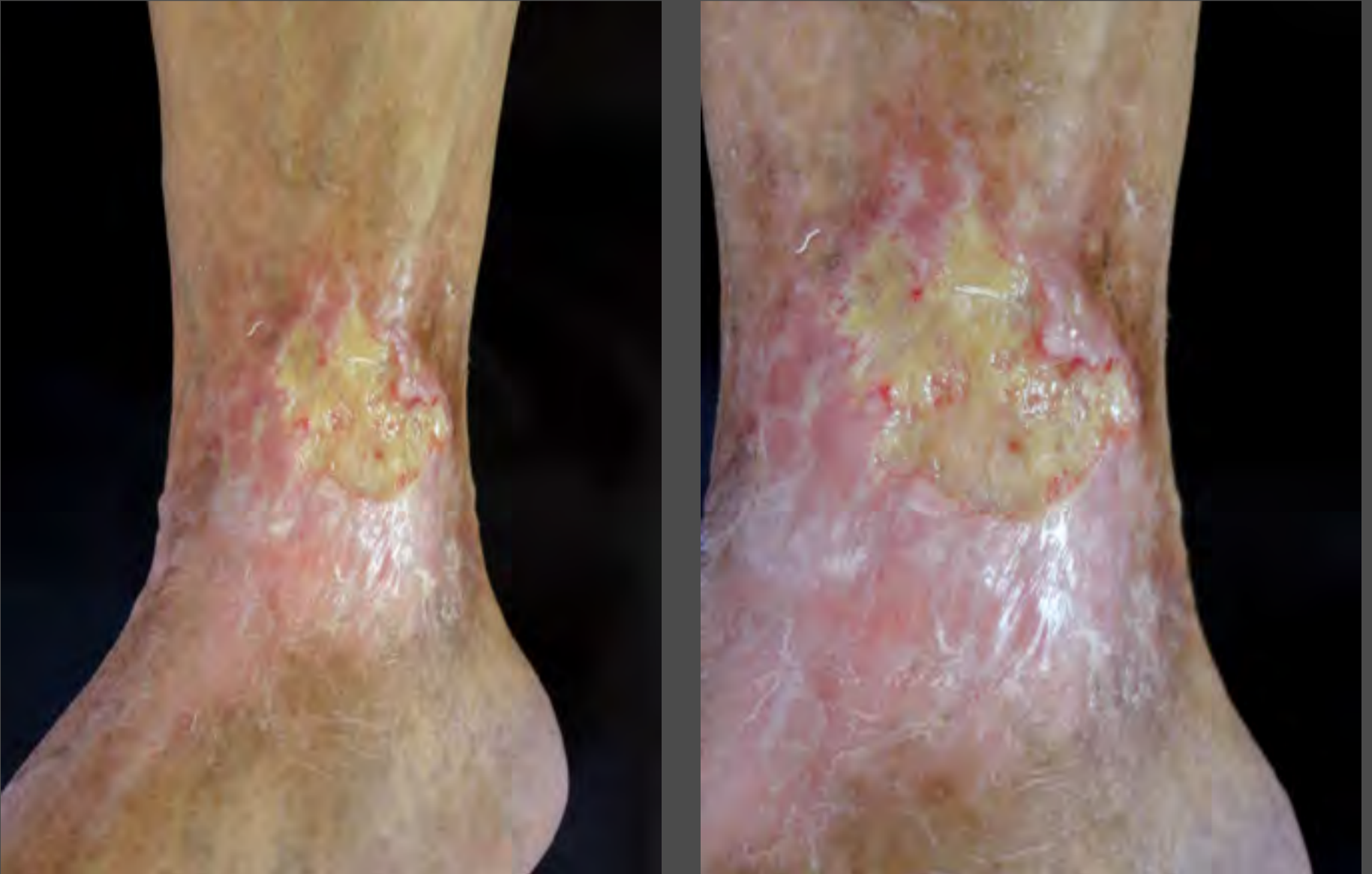
*Mixed vascular ulcers (Figures 3.275 a 3.276)*



**Figures 3.275A and B.**

The skin surrounding the ulcers looks atrophic, smooth, thinned, with fewer appendages, and whitish scarred areas that are punctiform or somewhat larger. The edges are anfractuous, the floor is dirty or has yellowish membranes, there is little granulation, and they usually do not bleed. The leg becomes hot and erythematous when hanging down, and cold and pale when elevated. They are hard to cure and heal slowly. There is a greater risk of infections, and complications can be serious and even lead to amputation.

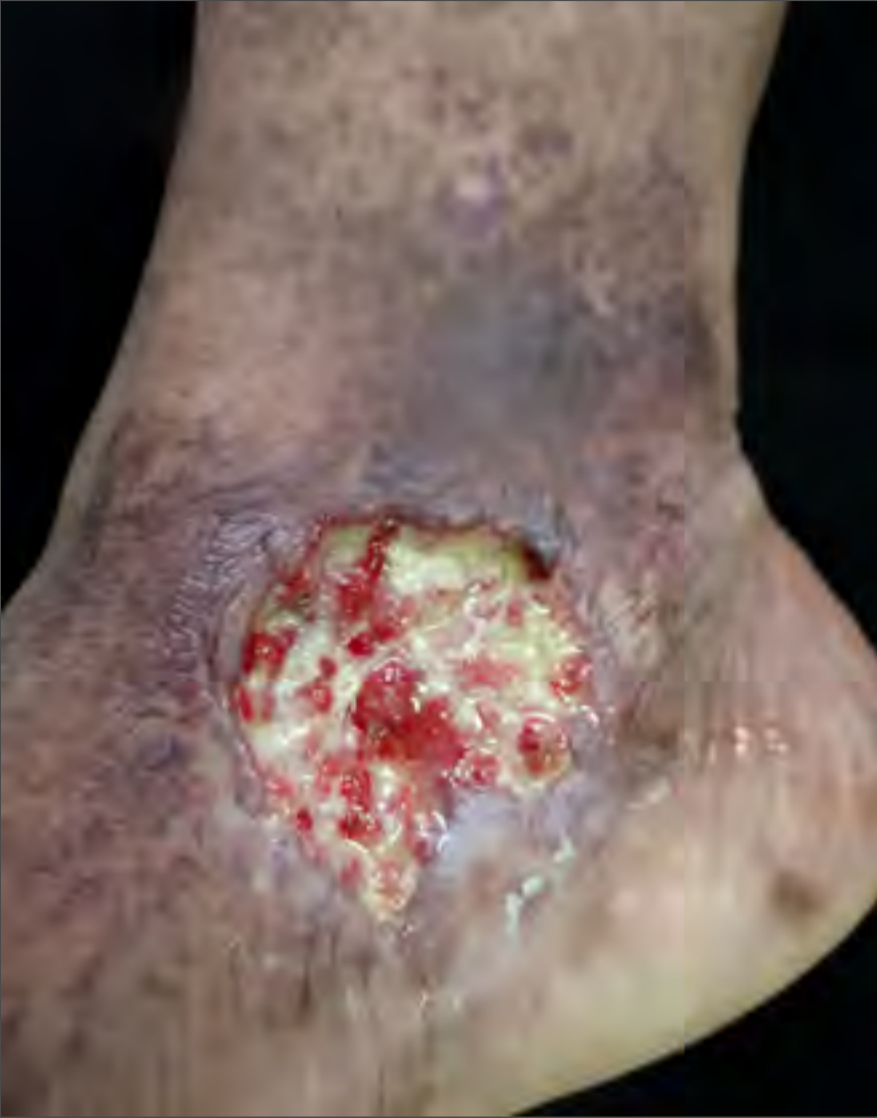## Mixed vascular ulcers



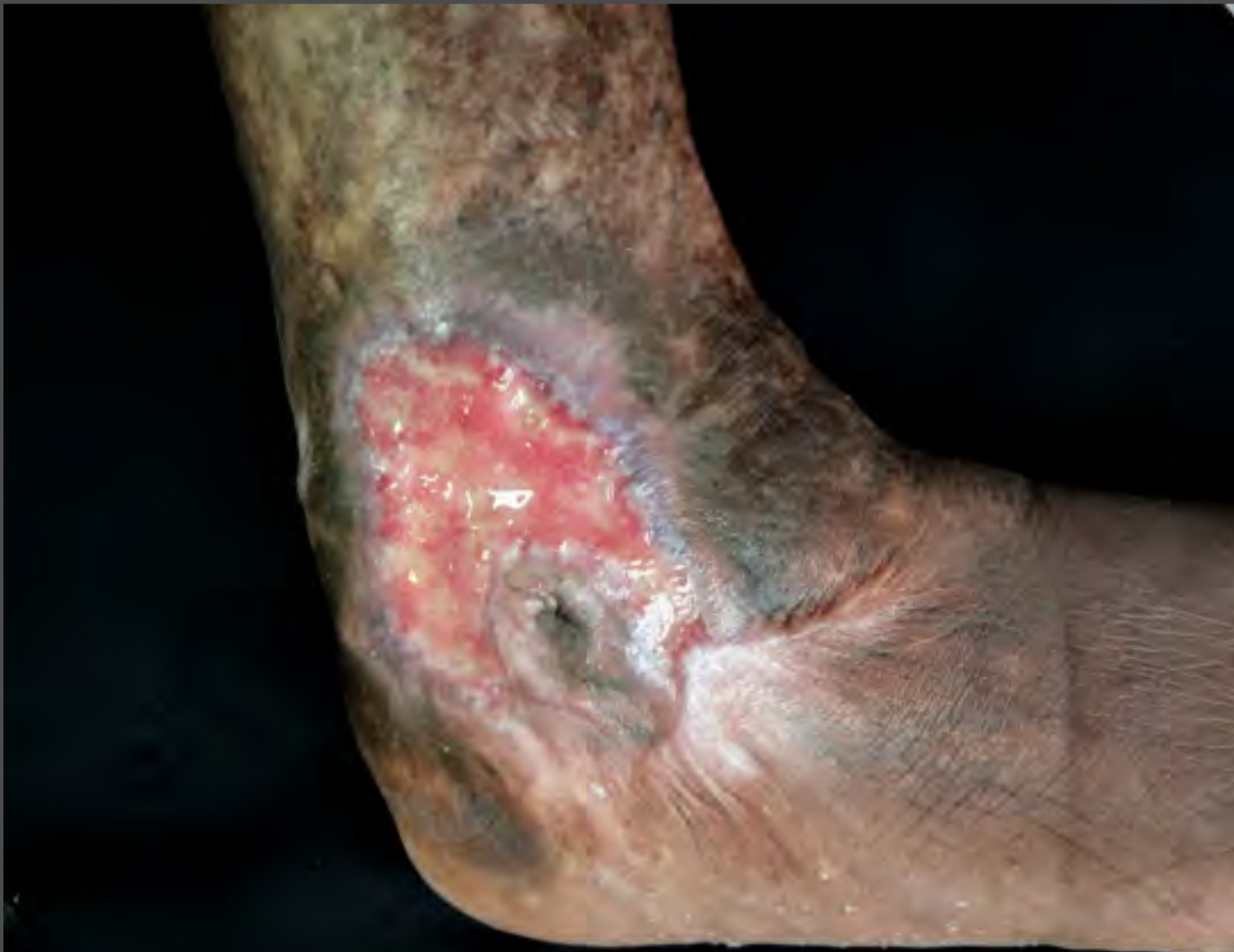**Figures 3.275C and D.**

The skin surrounding the ulcers looks atrophic, smooth, thinned, with fewer appendages, and whitish scarred areas that are punctiform or somewhat larger. The edges are anfractuous, the floor is dirty or has yellowish membranes, there is little granulation, and they usually do not bleed. The leg becomes hot and erythematous when hanging down, and cold and pale when elevated. They are hard to cure and heal slowly. There is a greater risk of infections, and complications can be serious and even lead to amputation.

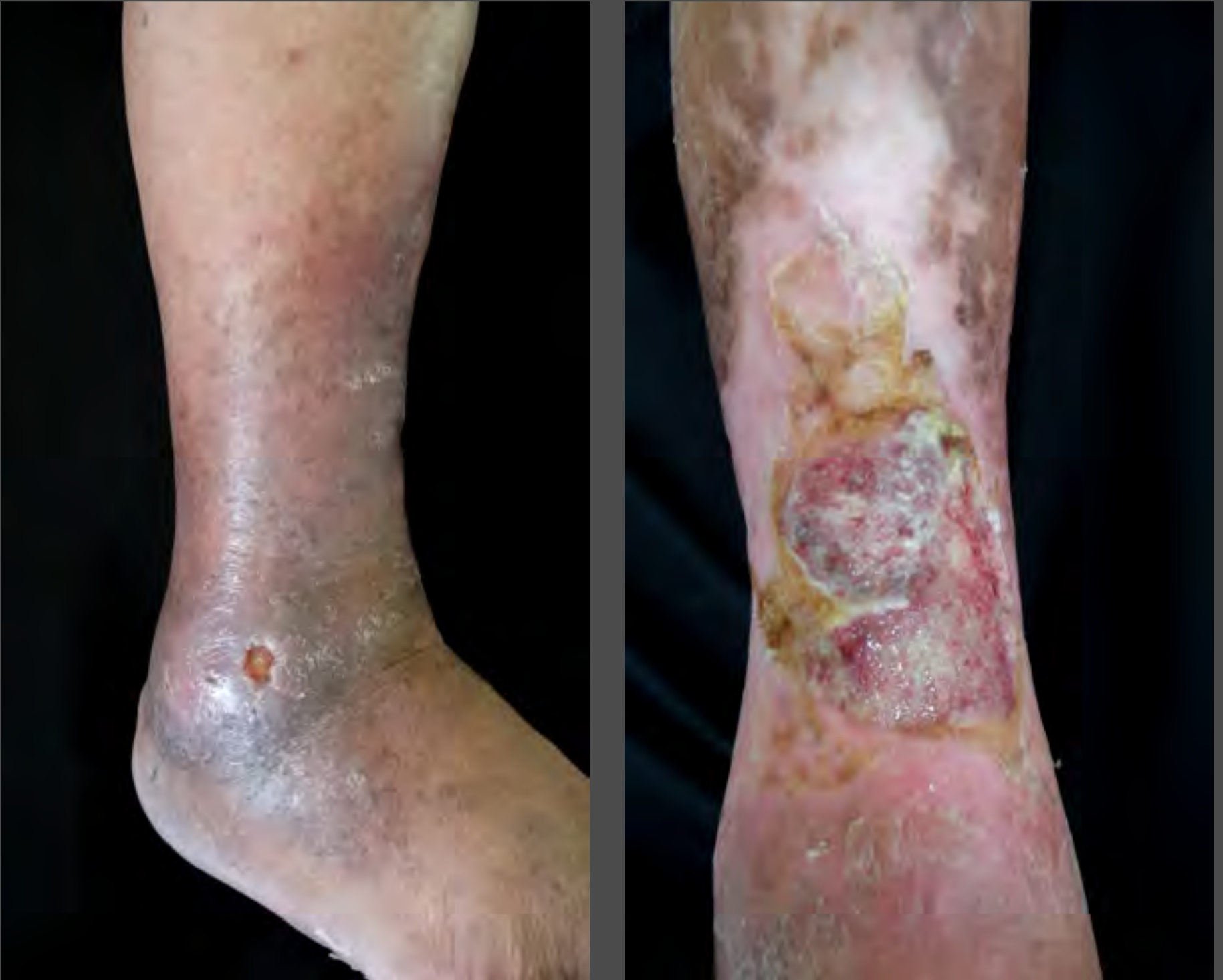## Mixed vascular ulcers

**Figures 3.275E and F.**

The skin surrounding the ulcers looks atrophic, smooth, thinned, with fewer appendages, and whitish scarred areas that are punctiform or somewhat larger. The edges are anfractuous, the floor is dirty or has yellowish membranes, there is little granulation, and they usually do not bleed. The leg becomes hot and erythematous when hanging down, and cold and pale when elevated. They are hard to cure and heal slowly. There is a greater risk of infections, and complications can be serious and even lead to amputation.



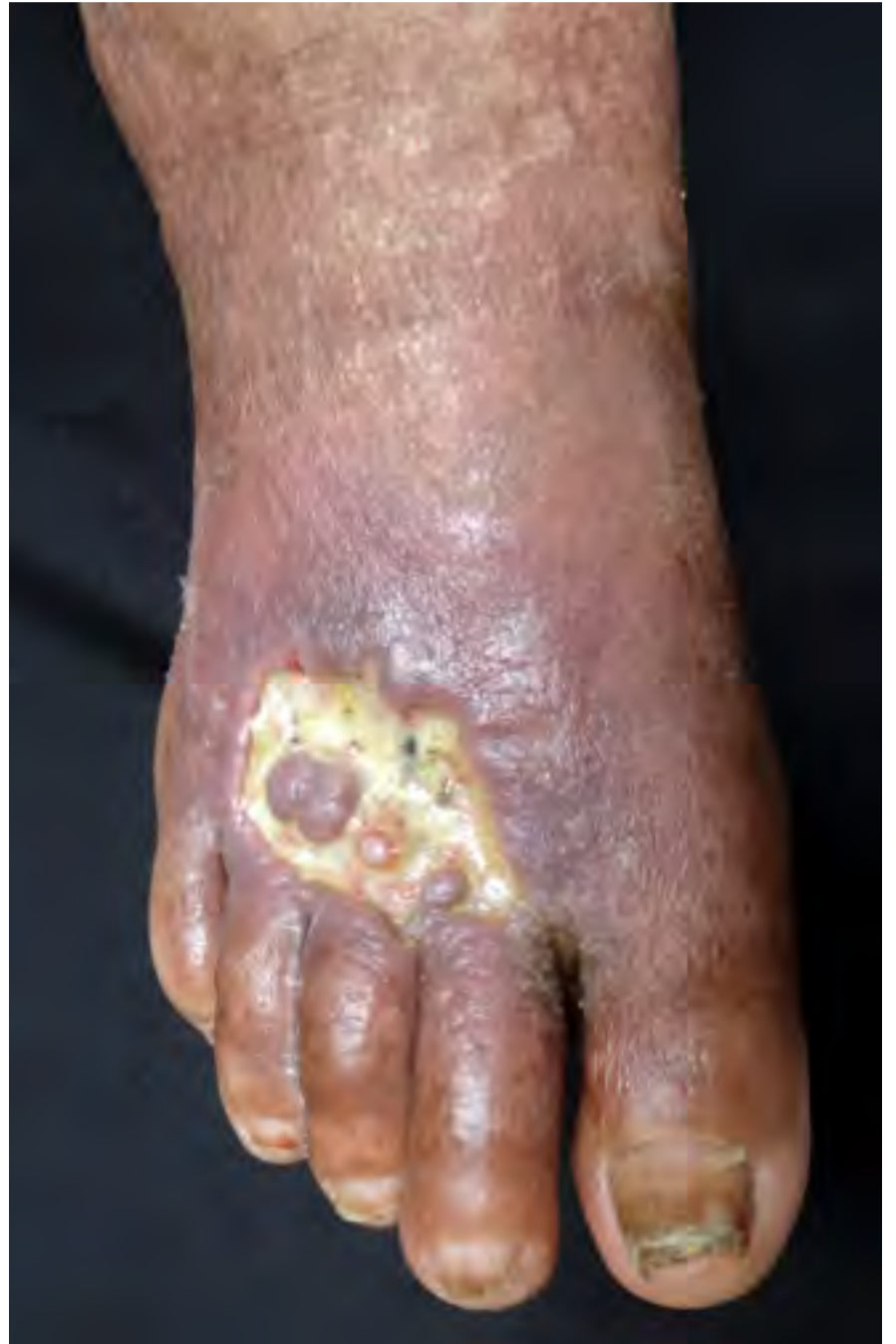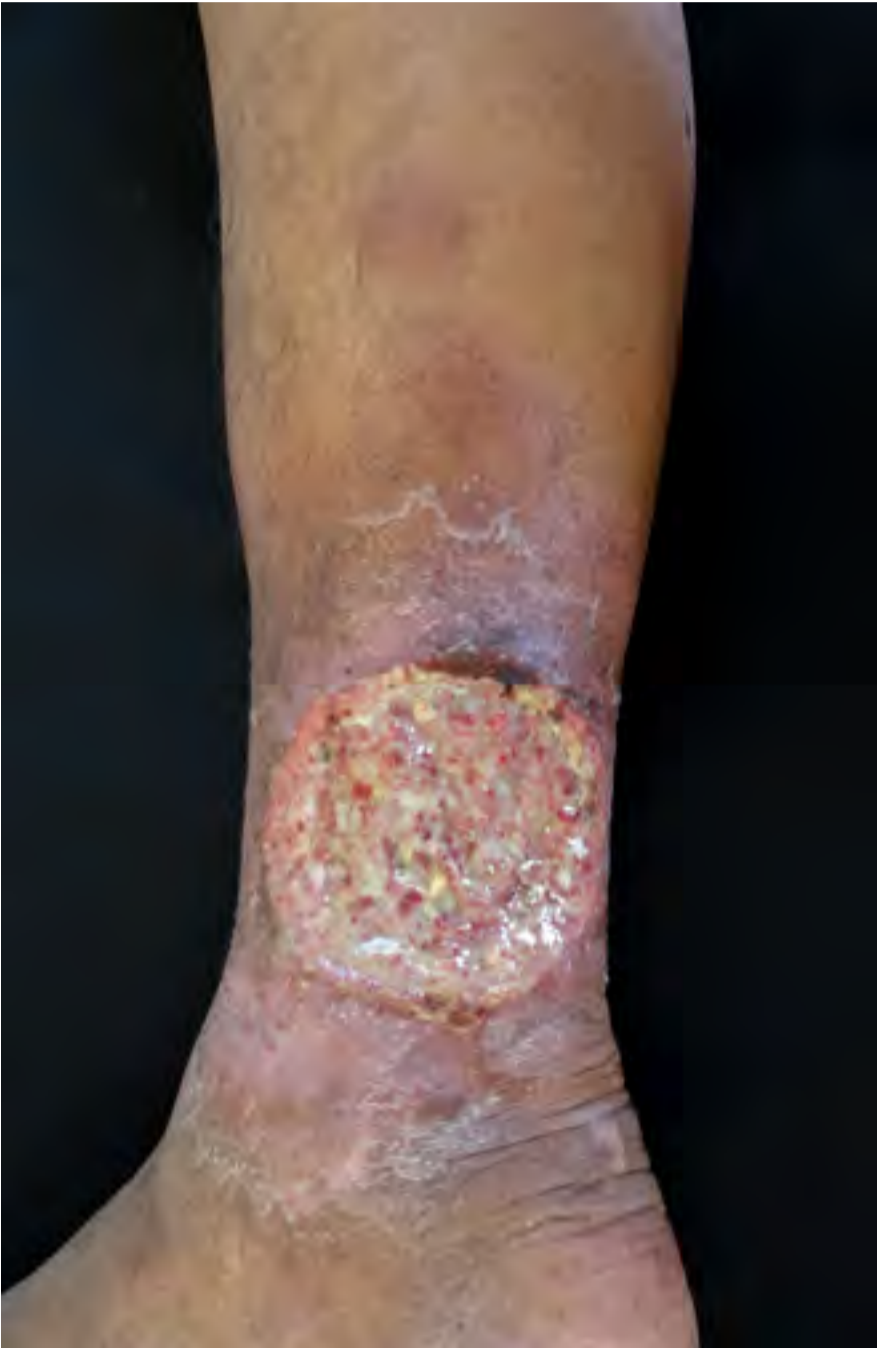## Mixed vascular ulcers



**Figures 3.276A and B.**

Consequence of a combination of venous and arterial insufficiency, without a critical deterioration in blood flow. There are clinical signs and a history of peripheral artery and venous disease.

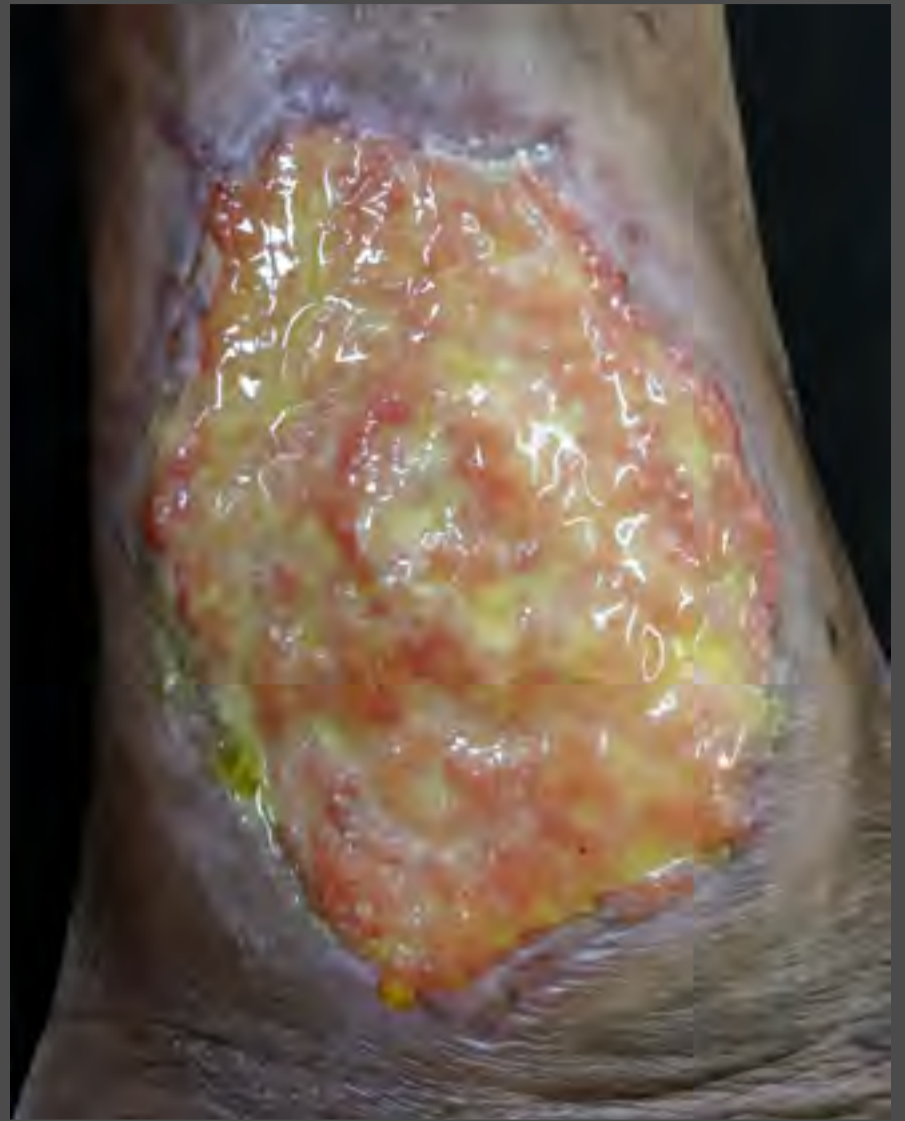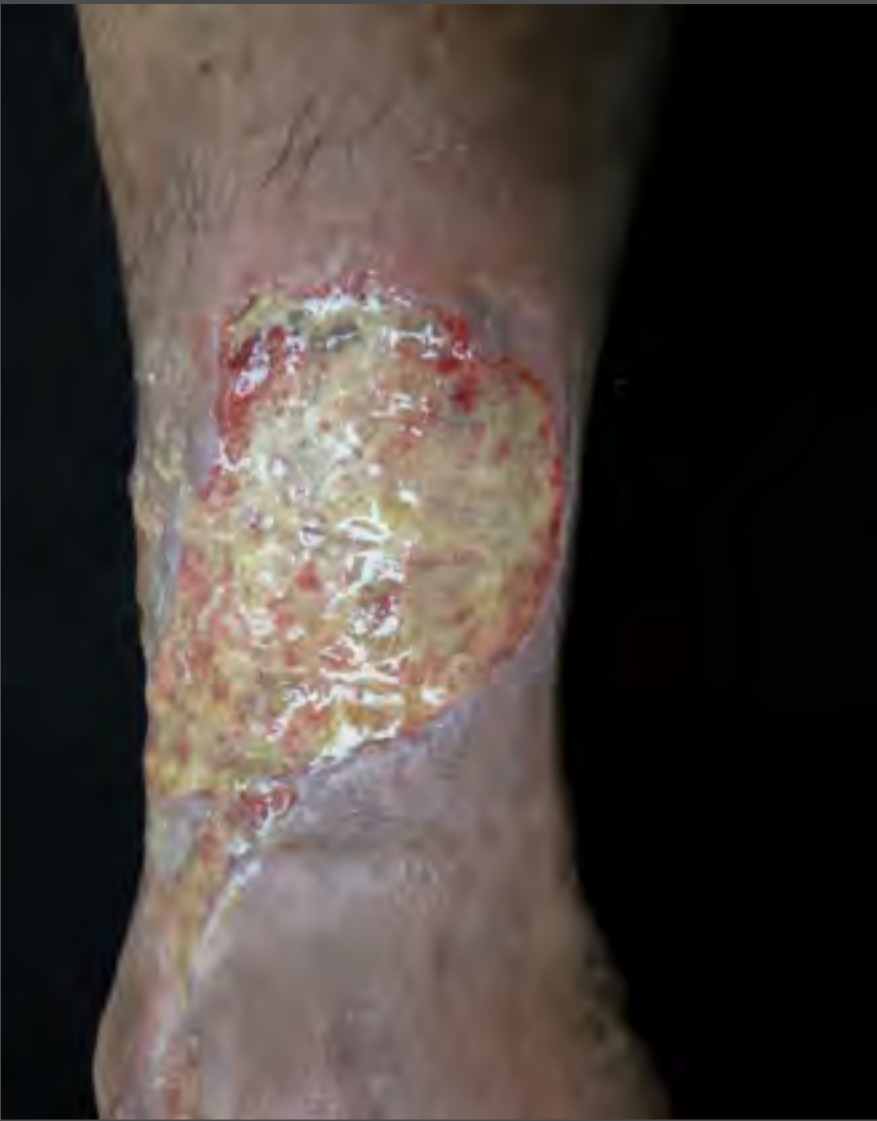*Infections in vascular ulcers (Figures 3.277 a 3.278)*



**Figures 3.277A and B.**

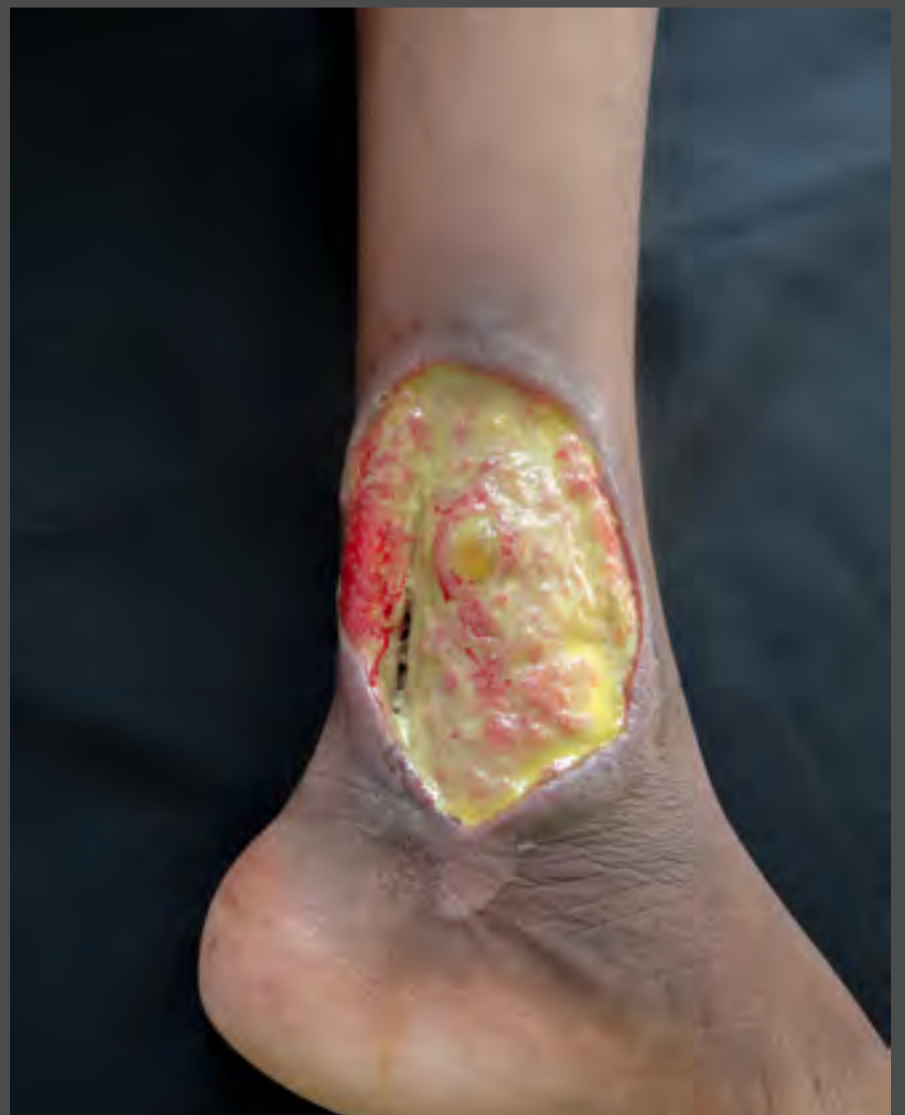Because they are open wounds, in areas of poor blood supply where the force of gravity has a greater impact, and because they are below the waist, all vascular ulcers have bacteria that colonize them, although they do not necessarily cause infections, which means that regular topical or systemic antibiotics should not be used. Clinical signs of infection require cultures in which almost any germ can grow, and mixed infections are common. Cellulitis and lymphangitis are common complications.

## Infections in vascular ulcers



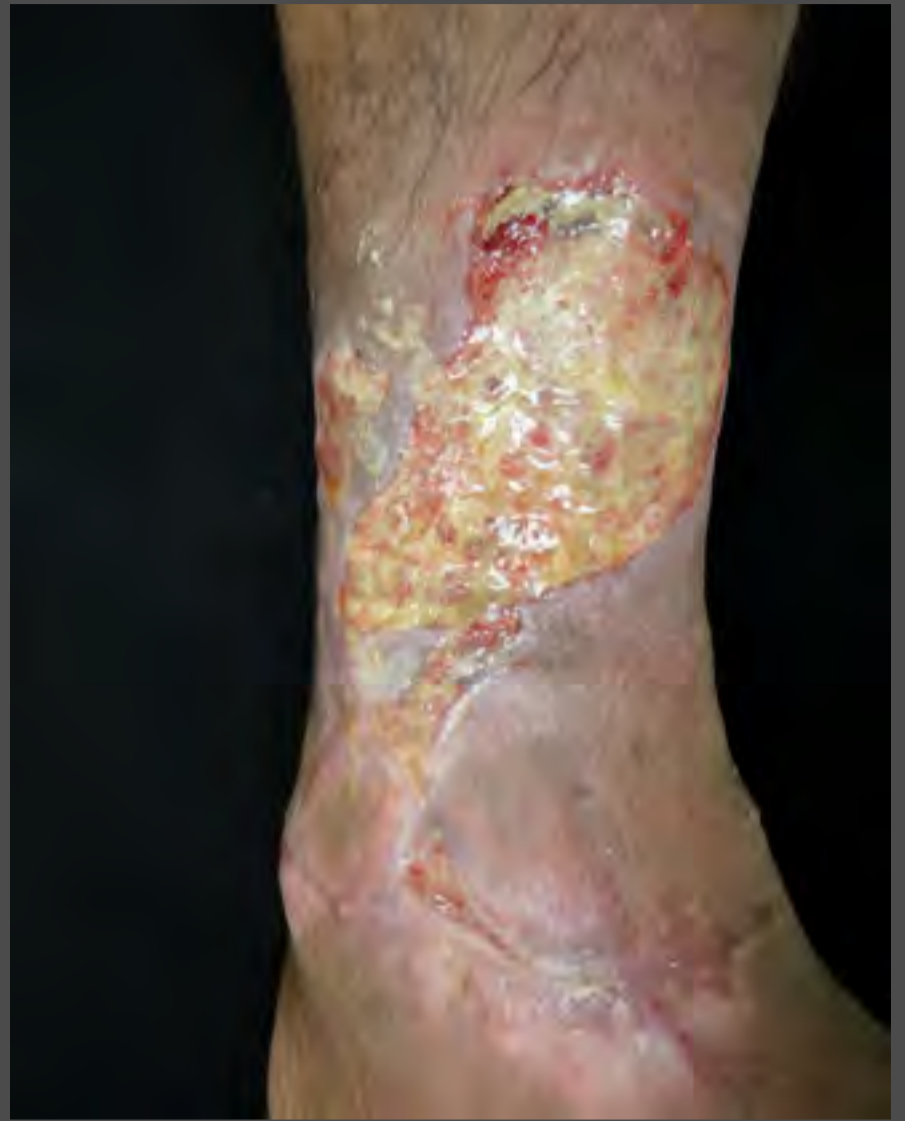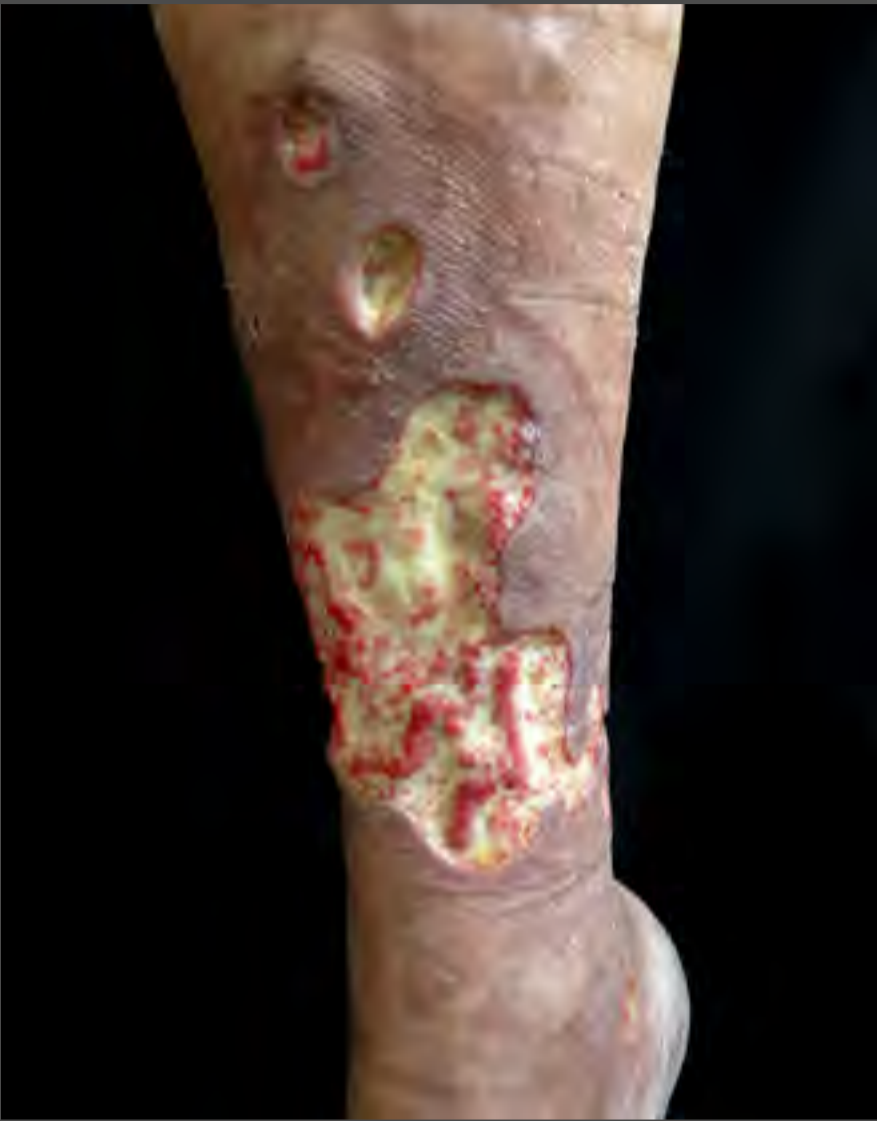**Figures 3.277C, D and E.**

Because they are open wounds, in areas of poor blood supply where the force of gravity has a greater impact, and because they are below the waist, all vascular ulcers have bacteria that colonize them, although they do not necessarily cause infections, which means that regular topical or systemic antibiotics should not be used. Clinical signs of infection require cultures in which almost any germ can grow, and mixed infections are common. Cellulitis and lymphangitis are common complications.



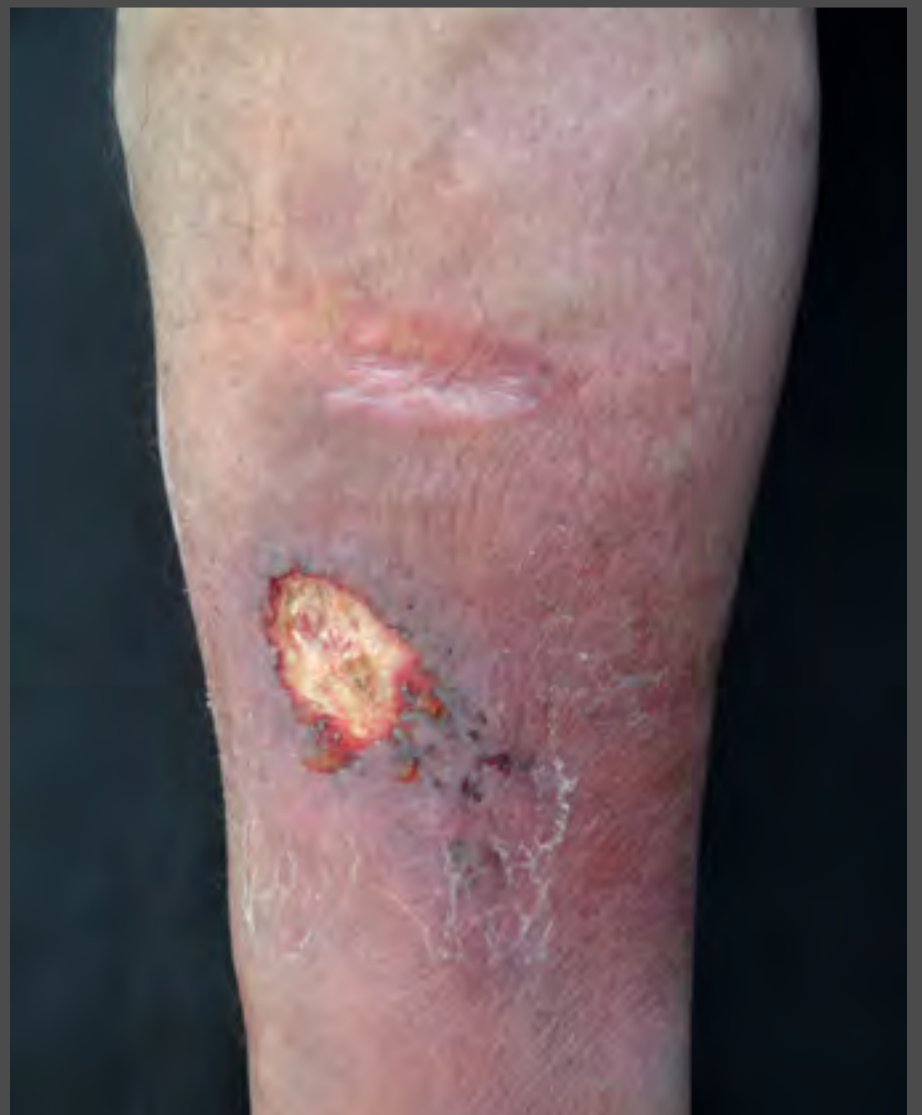

## Infections in vascular ulcers

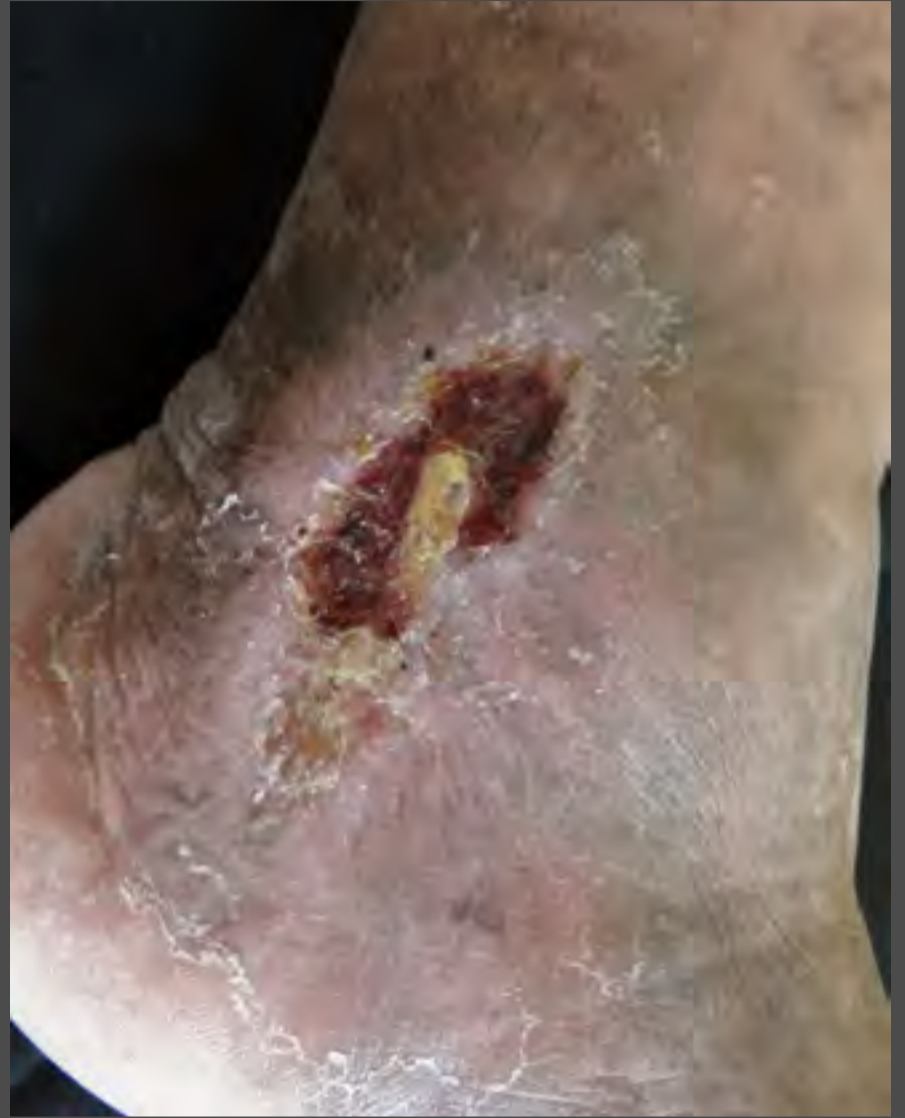
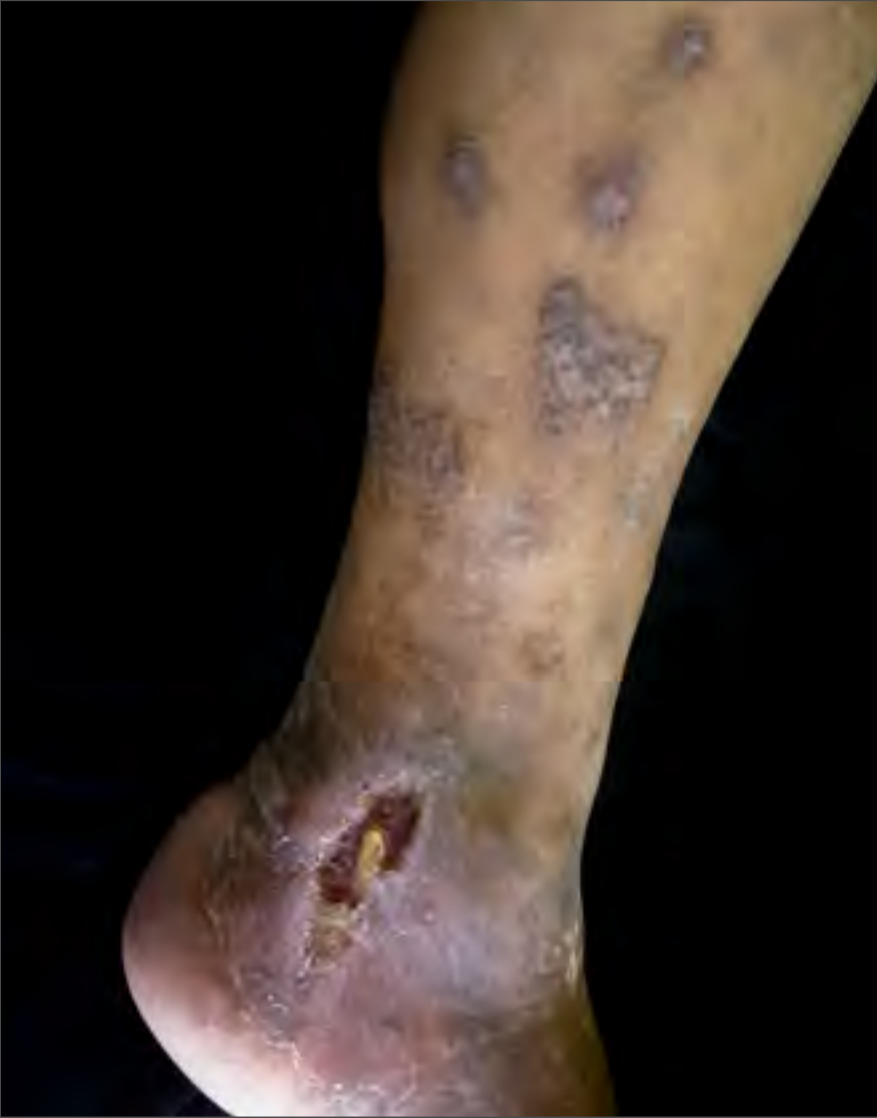
**Figures 3.277F, G and H.**

Because they are open wounds, in areas of poor blood supply where the force of gravity has a greater impact, and because they are below the waist, all vascular ulcers have bacteria that colonize them, although they do not necessarily cause infections, which means that regular topical or systemic antibiotics should not be used. Clinical signs of infection require cultures in which almost any germ can grow, and mixed infections are common. Cellulitis and lymphangitis are common complications.

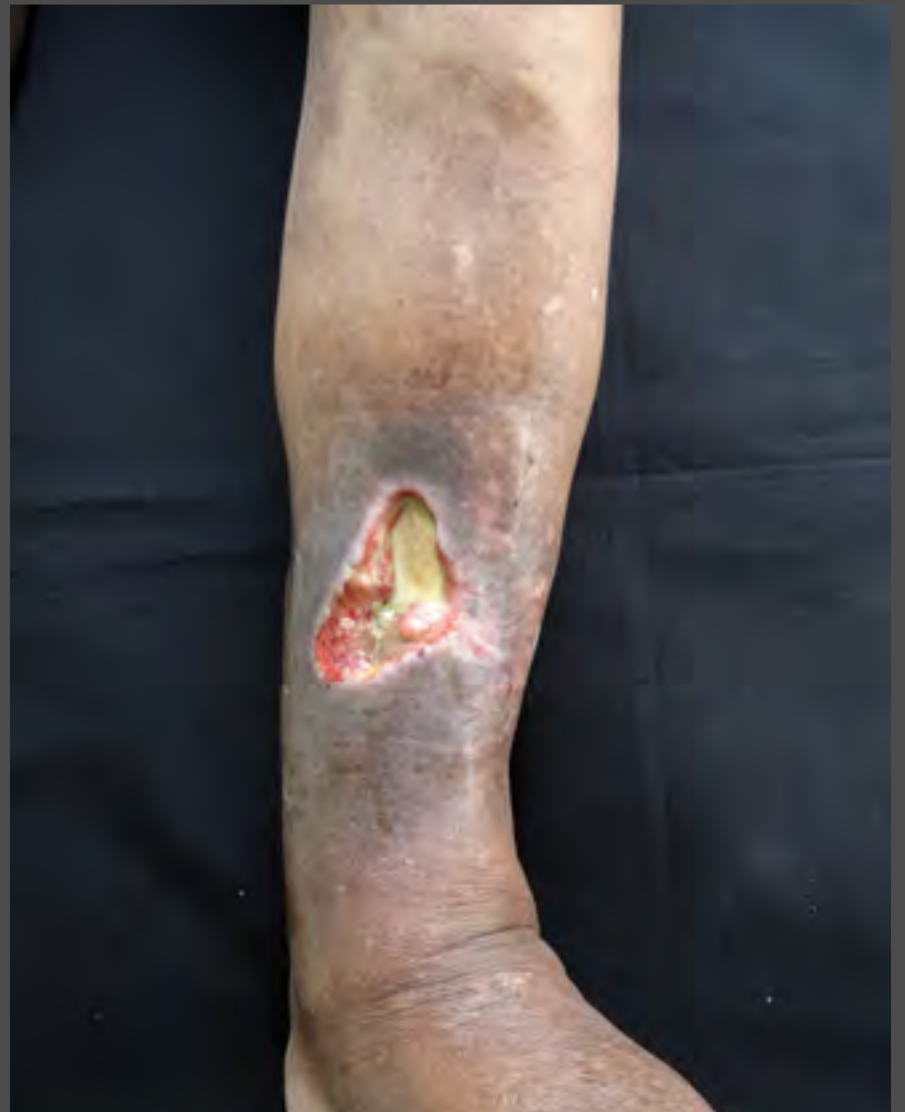

## Infections in vascular ulcers

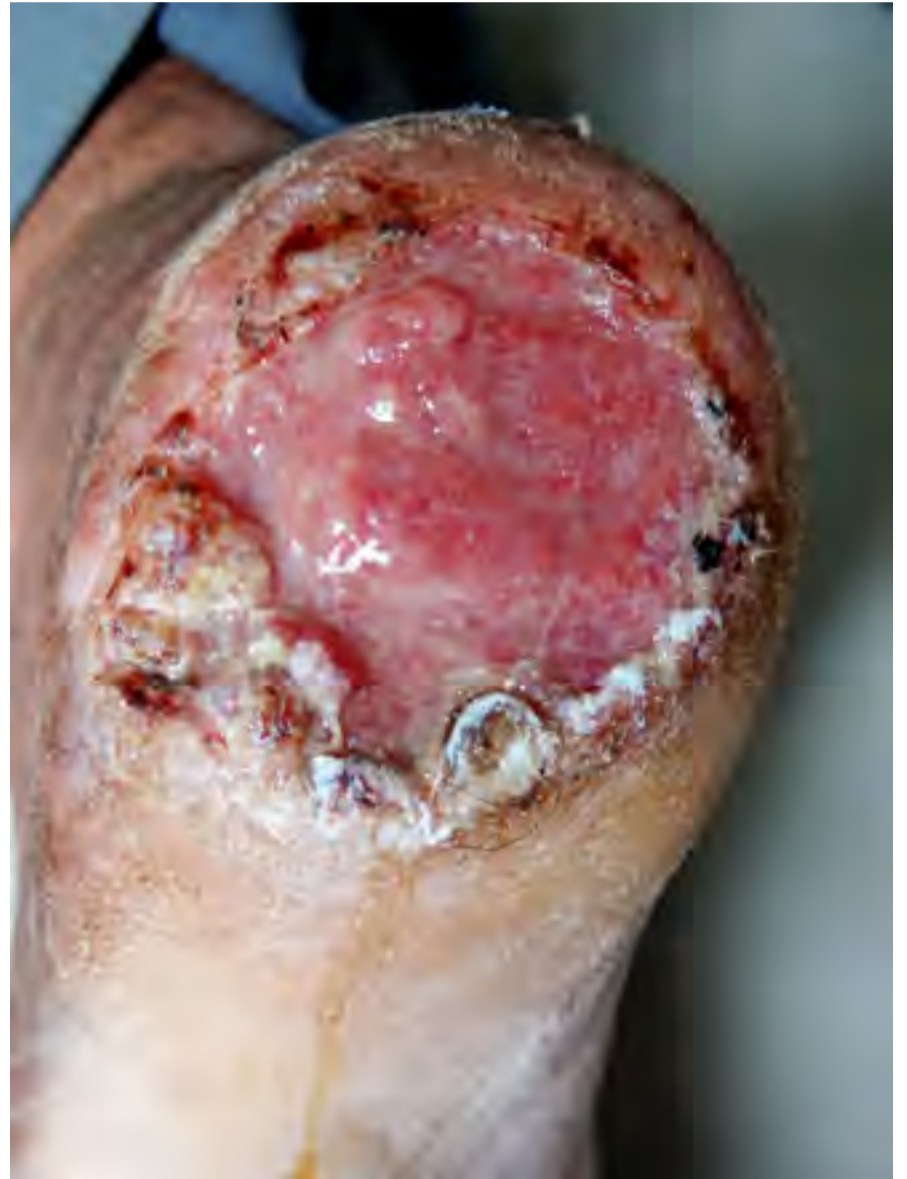
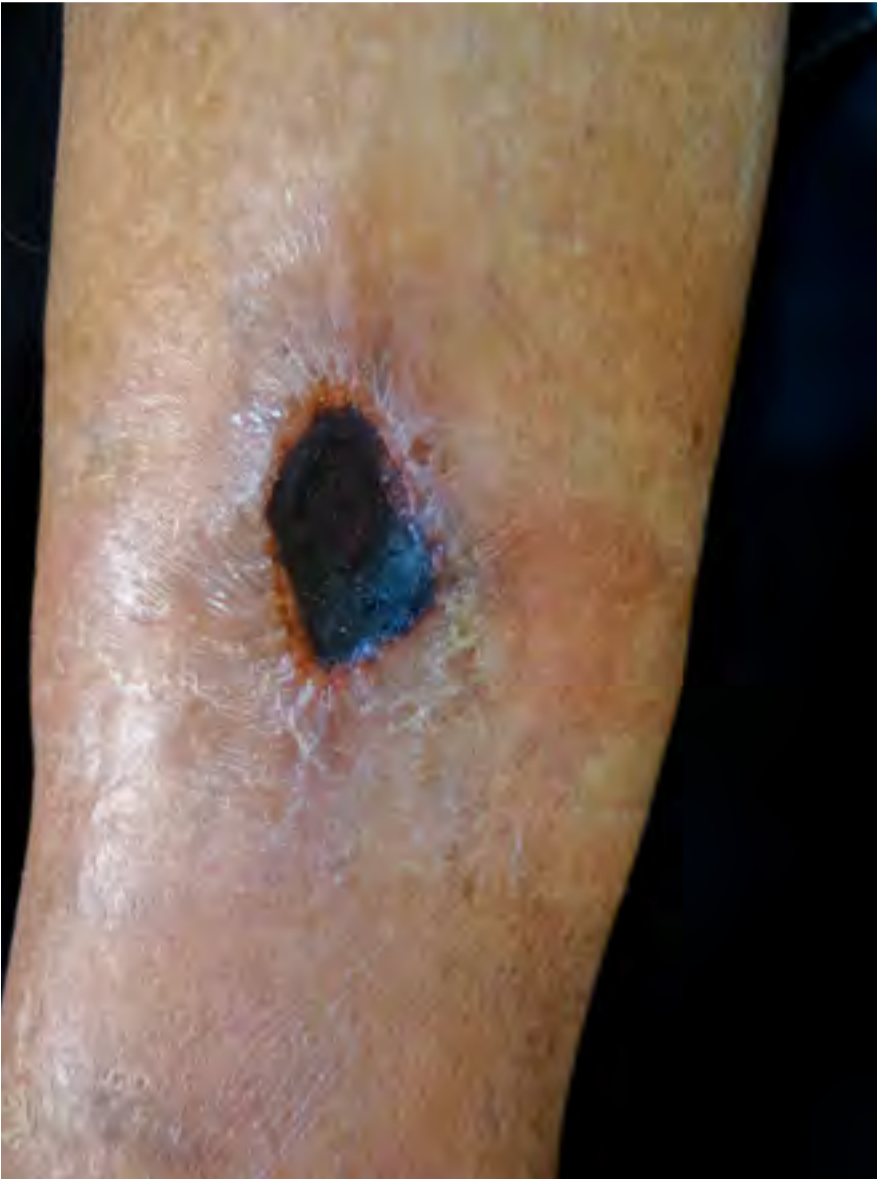
**Figures 3.278A, B and C.**

Vascular ulcers can deepen until exposing tendons or bone, which is very rare in leishmaniasis.



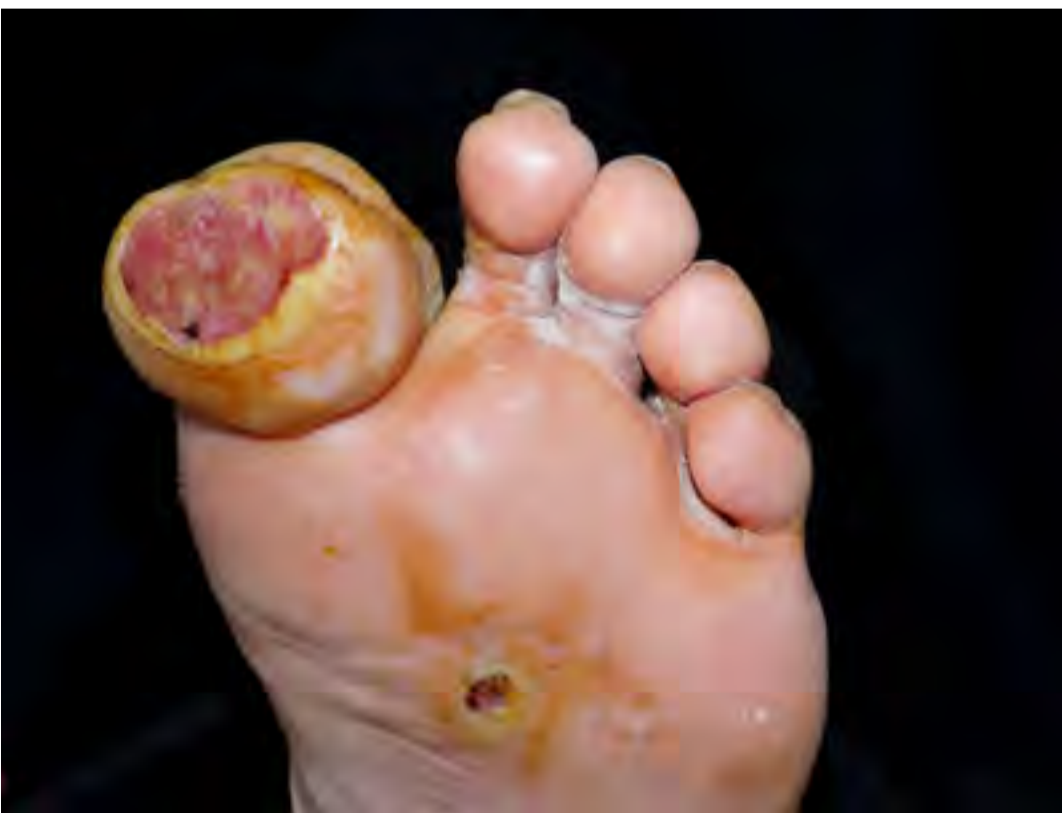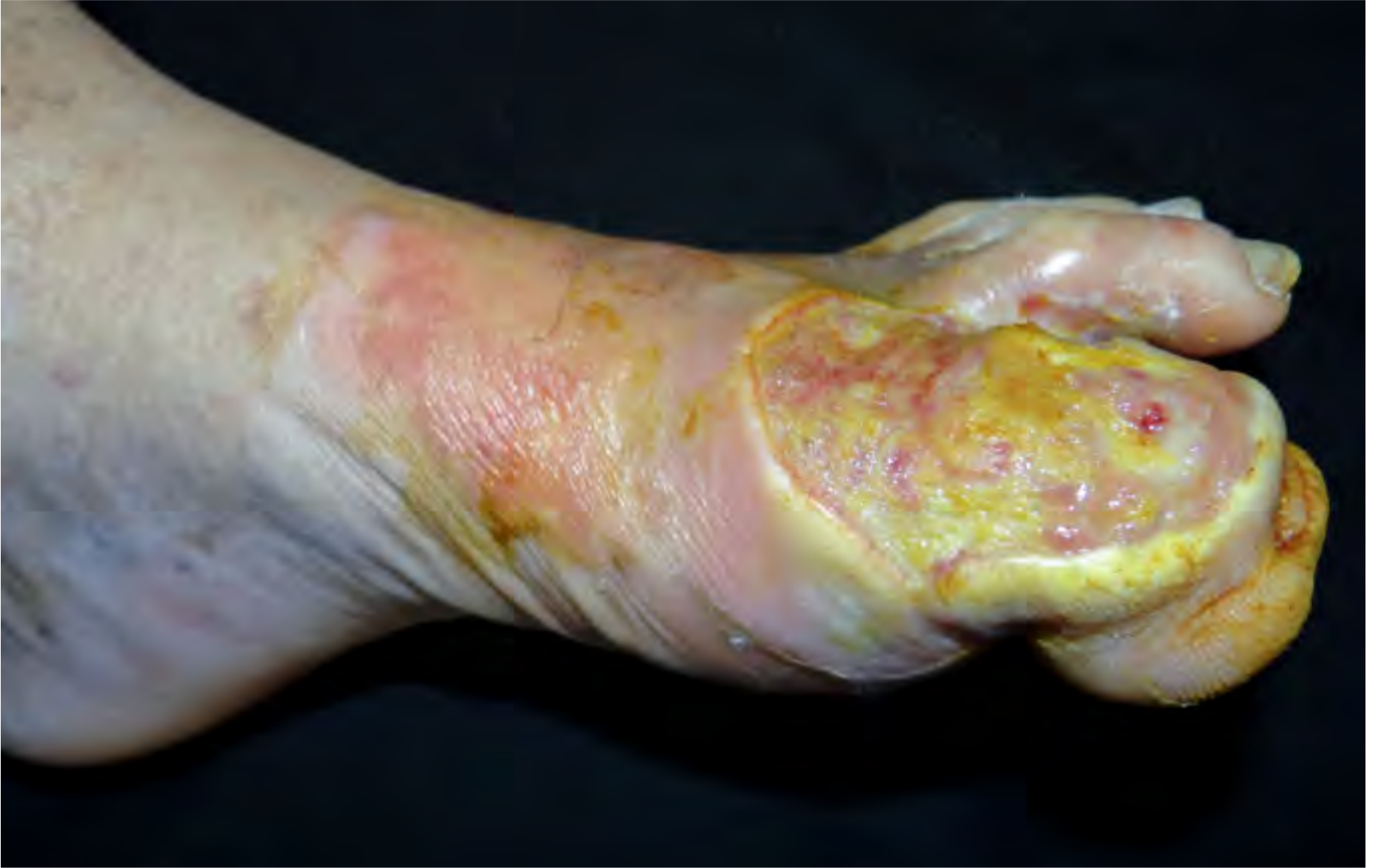*Vascular diseases (Figures 3.279)*



**Figures 3.279A and B.**

Systemic vascular (polyarteritis nodosa) or metabolic (diabetes mellitus) diseases may cause ulcers on the legs that have a rapid onset, a chronic course, and are difficult to manage if their causes are not corrected.

*Diabetic ulcer (Figures 3.280)*



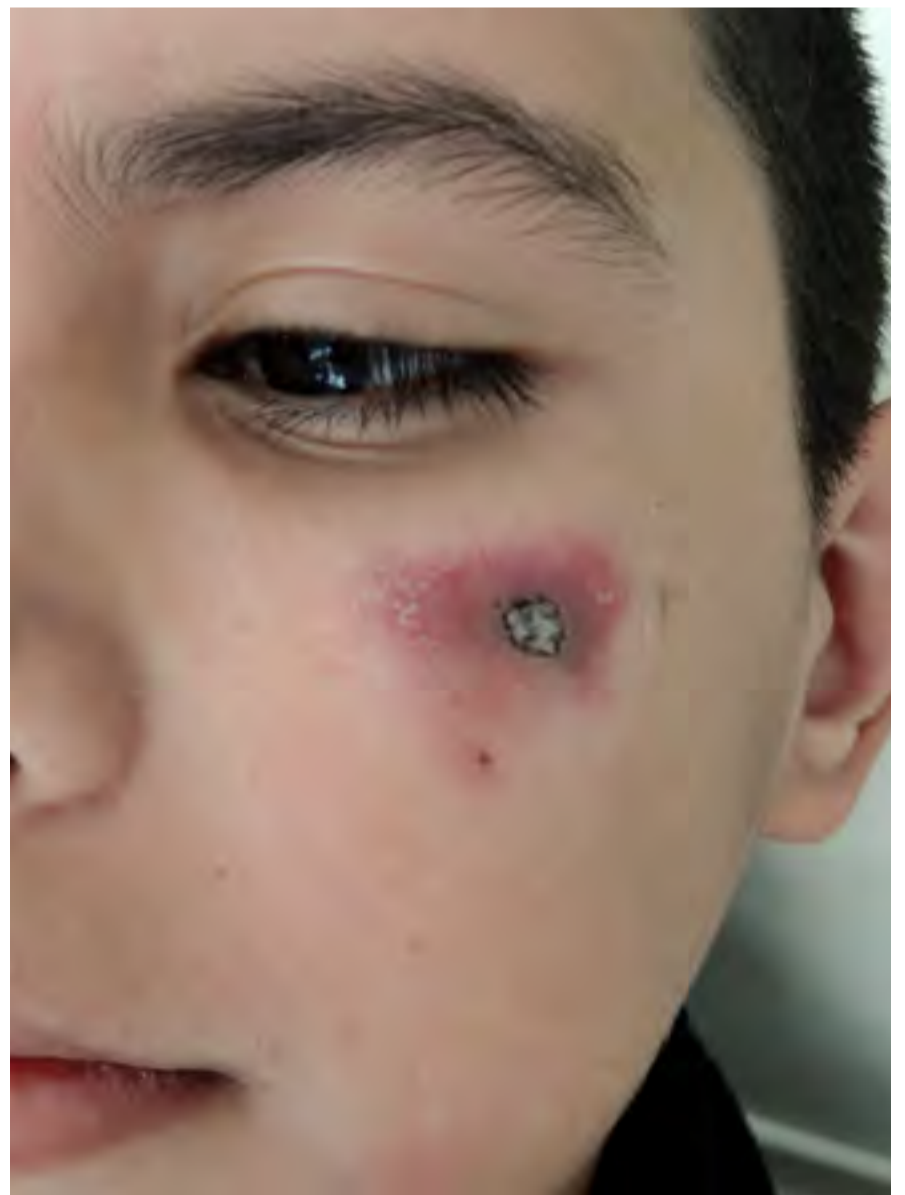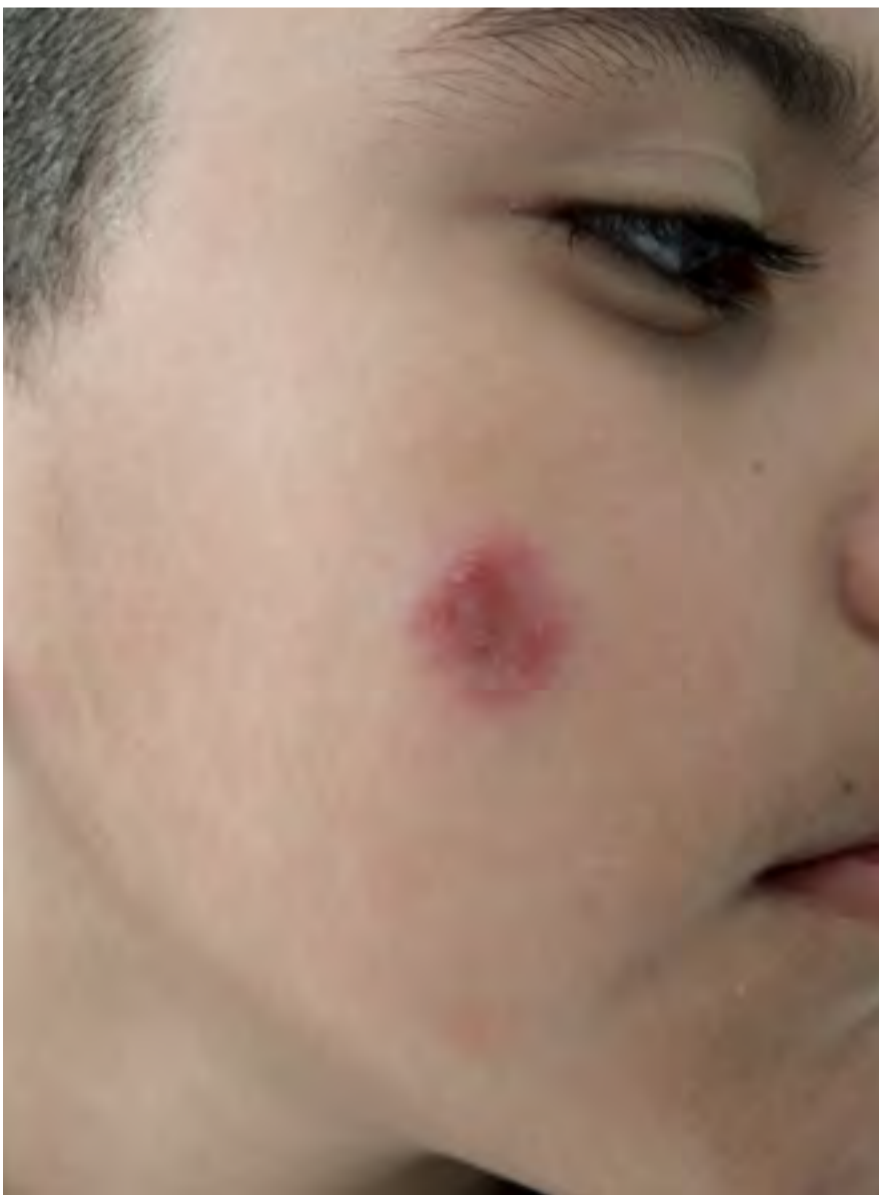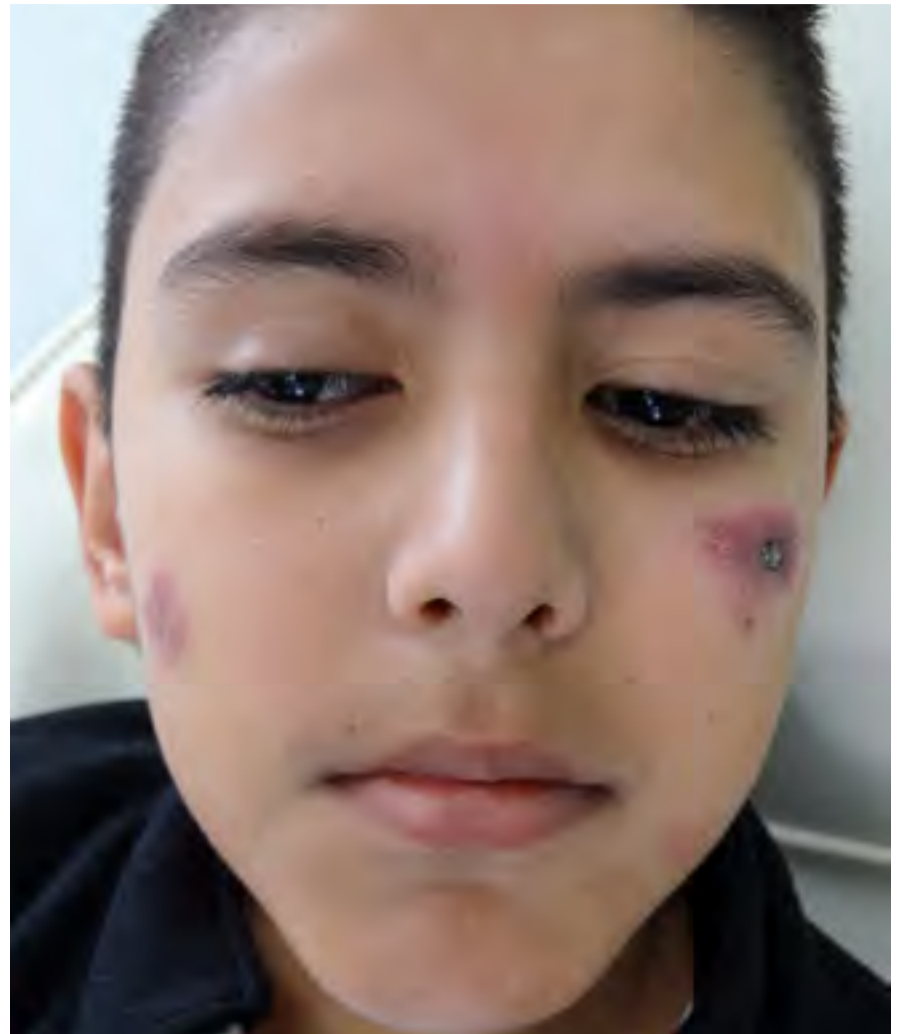**Figures 3.280A and B.**

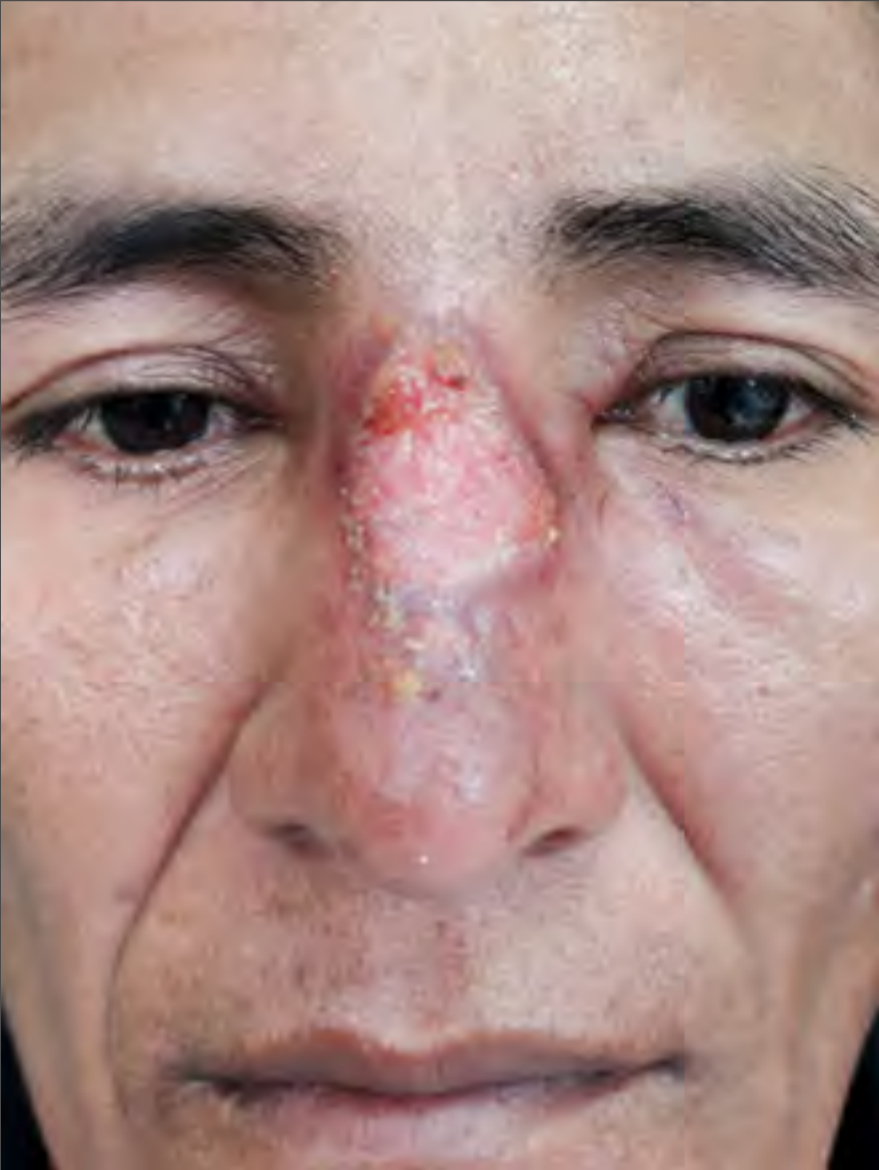Diabetic ulcer. These differ from leishmaniasis ulcers because they are more chronic and are located where it is unlikely that an insect can bite, in areas of support or friction on the feet. They are irregular, with flush or inverted edges, and exuberant granulation.

**Discoid lupus.** Discoid lupus plaques are rounded, erythematous, squamous, and crusty, with epidermal atrophy primarily on the face (*Figures 3.281 to 3.283*). Sometimes, leishmaniasis can resemble this disease. A history of worsening with sun exposure, multiple punctiform atrophies, and photosensitivity guide the diagnosis.

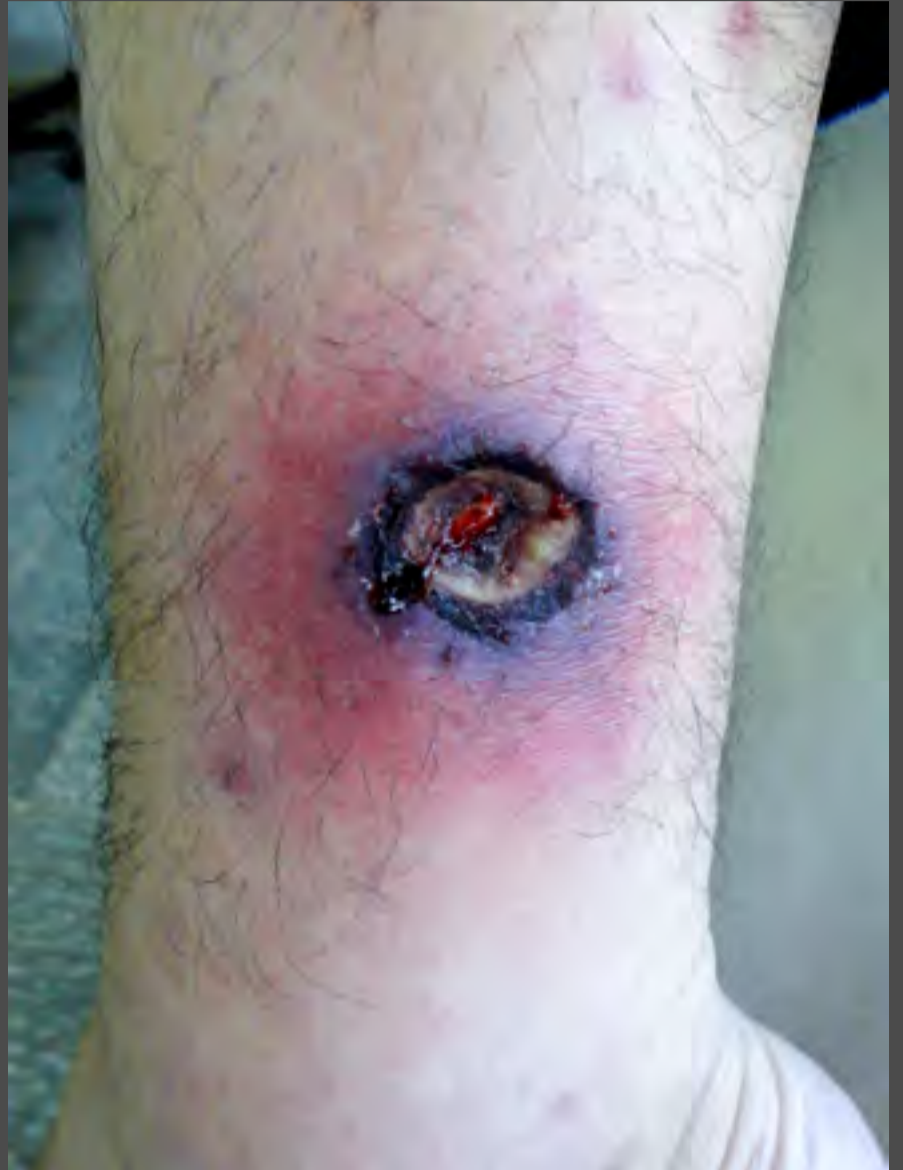**Figures 3.281A, B and C.**

Chronic discoid lupus erythematosus, confirmed by biopsy. Child aged 11 years with 10-month-old irregular, erythematous, edematous, infiltrated, and asymptomatic plaques on both cheeks. He did not present other lesions, nor did he come from leishmaniasis endemic areas.



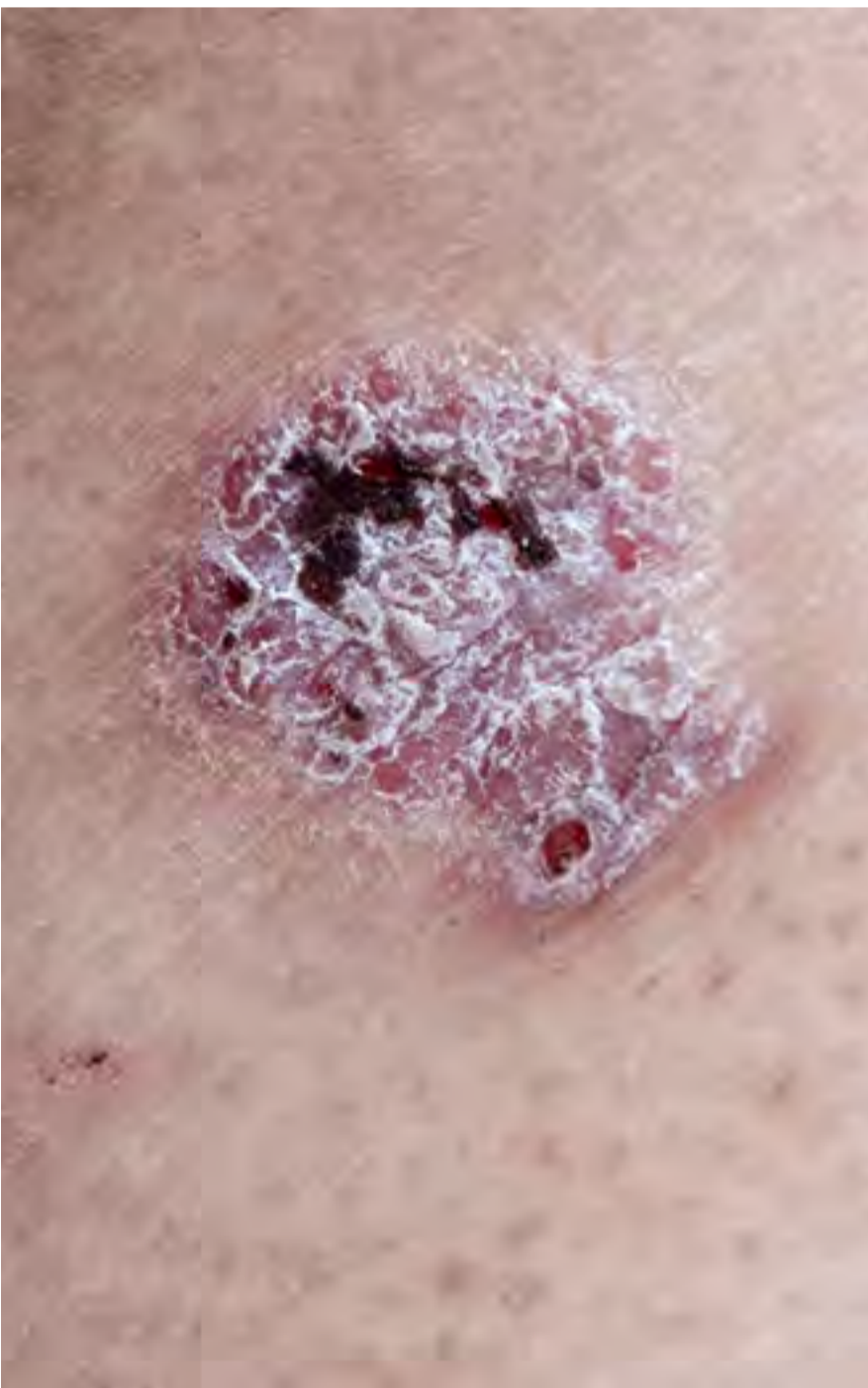◆◆◆  
Discoid lupus**Figure 3.282.**

Chronic discoid lupus erythematosus, confirmed by biopsy. Man aged 41 years with a four-month-old asymptomatic plaque on the bridge of his nose. The plaque is infiltrated, erythematous, and oval-shaped, with hyperpigmented edges, and the center is covered with adherent crusts and scales.

**Figure 3.283.**

Lupus vasculitis. Man aged 24 years with painful two-week-old lesion on right leg, which started with erythema and rapid induration, a violet color, and necrosis, and developed into a rounded ulcer with necrotic edges and an adherent scab, surrounded by intense erythema. A few days later, multiple small, painful ulcerations developed on the oral mucosa. The biopsy confirmed the clinical diagnosis of lupus erythematosus-associated vasculitis.

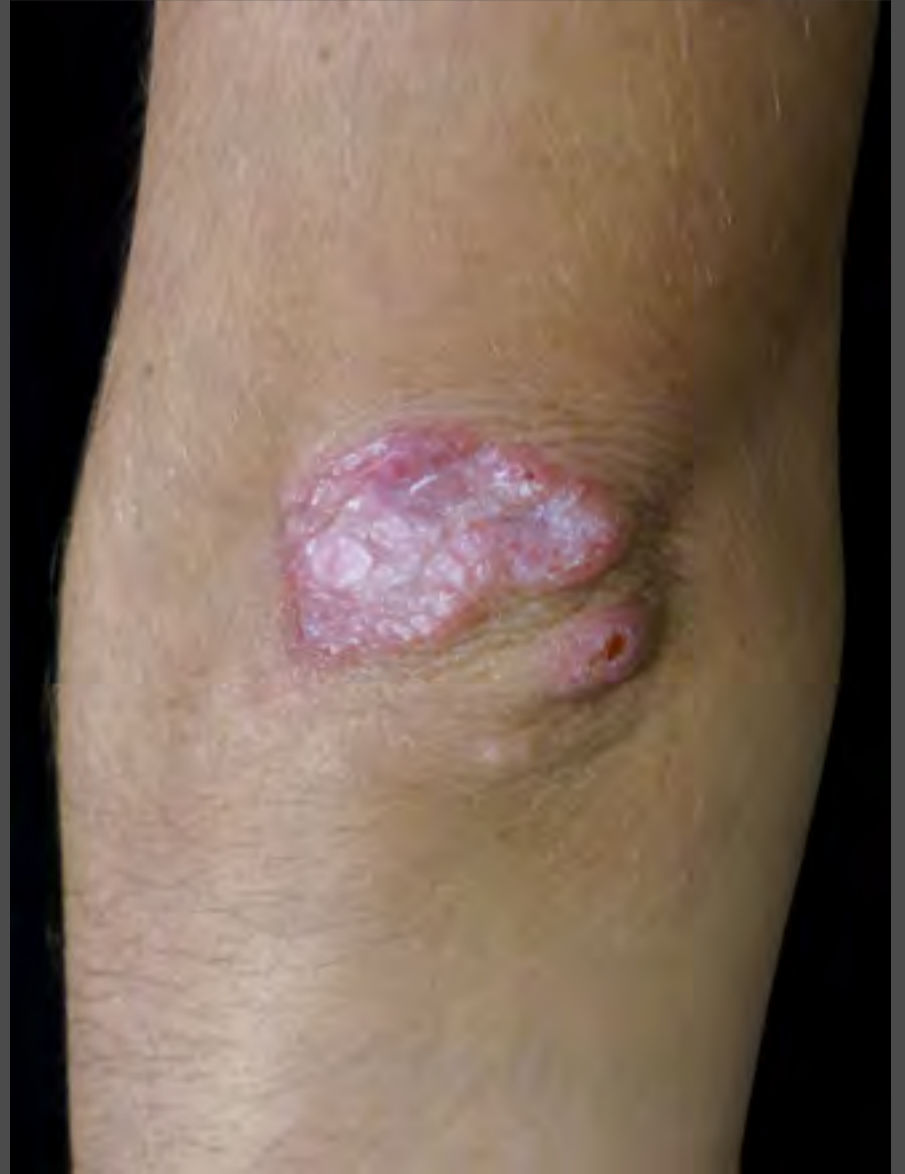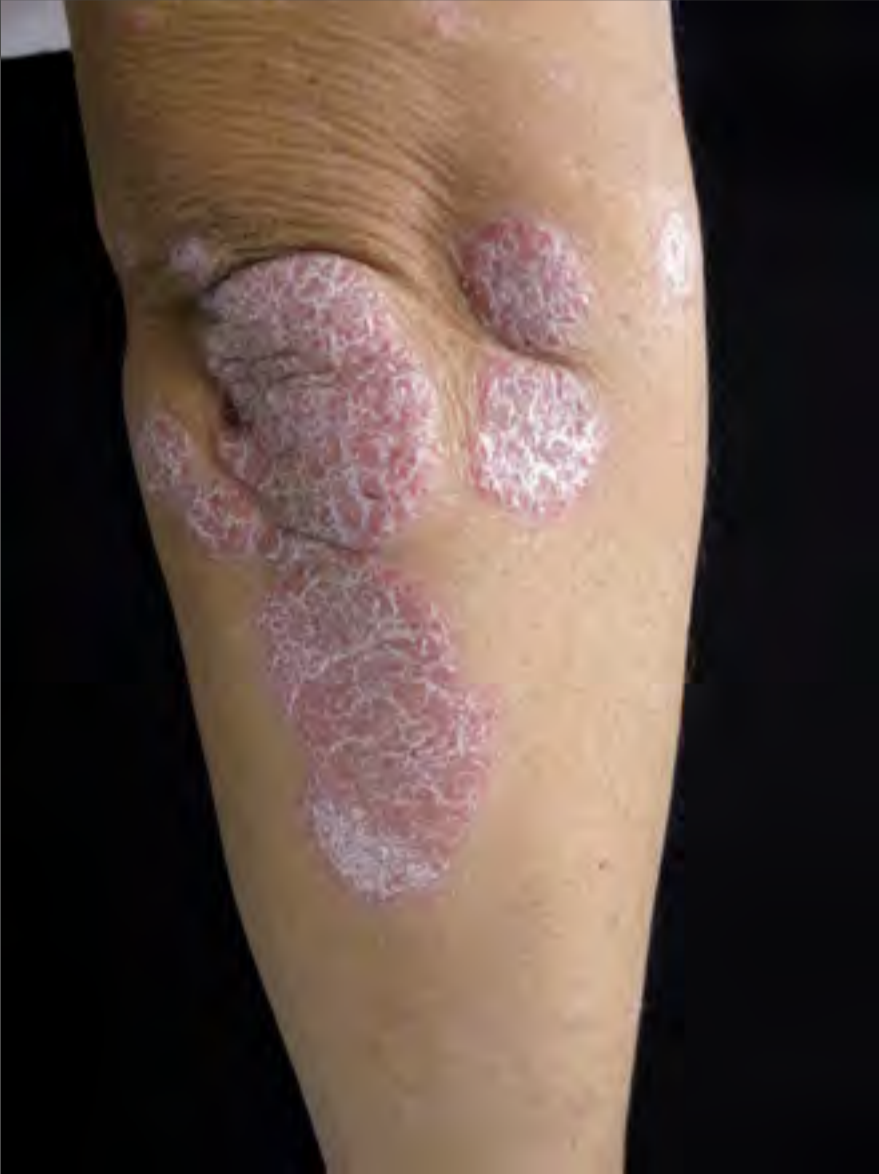**Psoriasis.** Some cutaneous leishmaniasis plaques resemble psoriasis, especially when there are only one or a few plaques. Lesions are usually erythematous, from 1 to 4 cm in diameter, round or oval in shape, coated with scales and crusts, sometimes with small blood spots, and with discrete infiltration at the base. In this case, a differential diagnosis should also be made with chromomycosis. The presence of erythematous and flaking lesions on other areas of the body, particularly the scalp, elbows, knees, buttocks, or legs, and a history of repeated episodes alternating with periods of healthy skin, point to a diagnosis of psoriasis (*Figures 3.284 a 3.285*).



**Figure 3.284.**

Psoriasis. In psoriasis, desiccated serosanguineous crusts and scales cover the entire erythematous area, while in leishmaniasis they are limited to the central area without covering the edges. A leishmaniasis ulcer is more infiltrated and the skin cannot be folded. Furthermore, in psoriasis, when scales are detached by gentle scratching, the “bleeding dew” sign appears, as fine drops of blood on the plaque’s surface, which is explained by the proliferation of the superficial vascular network very close to the dermo-epidermal junction.

## Psoriasis

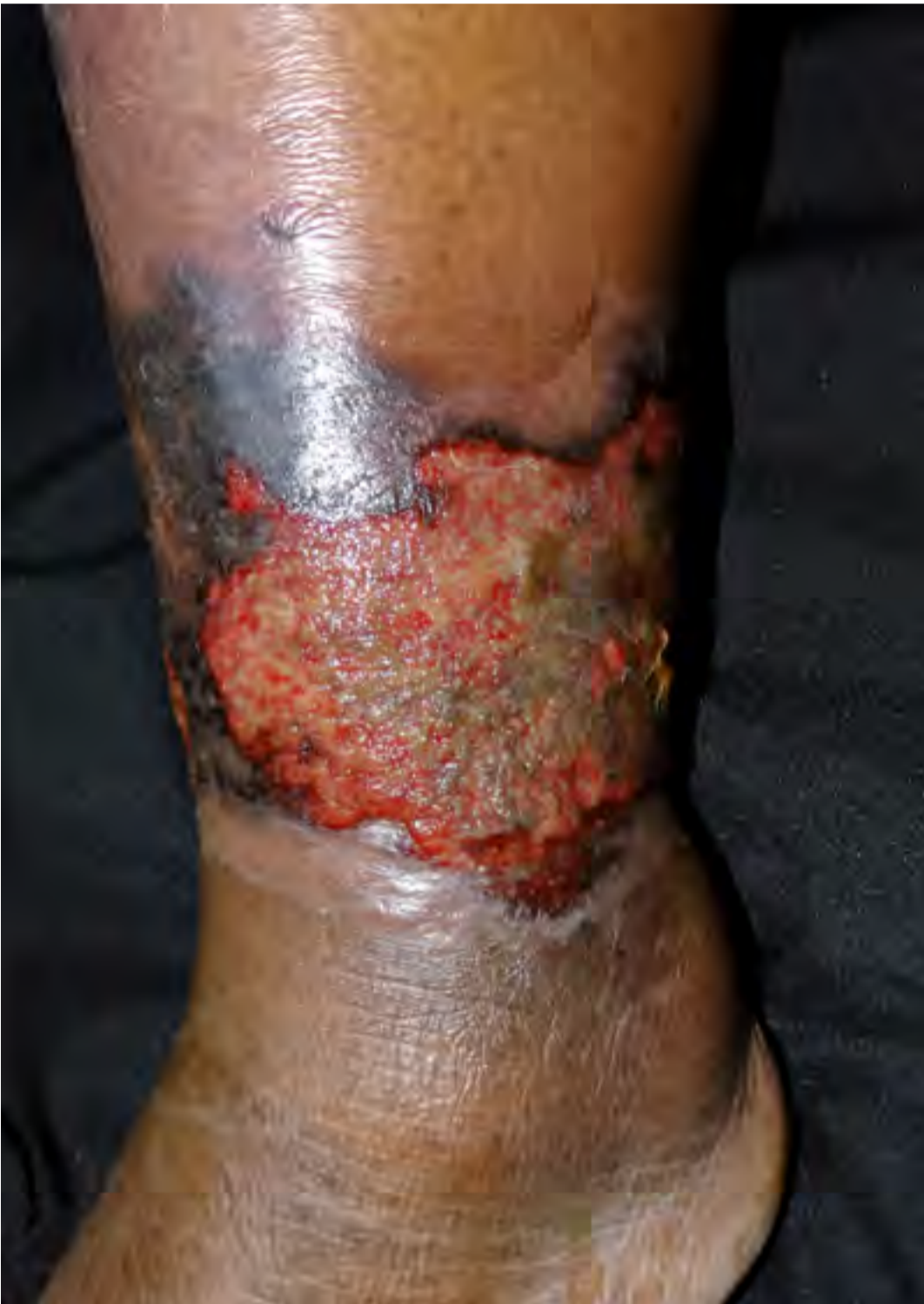

**Figures 3.285A and B.**

Classical psoriasis plaques on the elbows; erythematous, well defined, and prominent, completely covered by small, adherent, whitish scales. Usually there are multiple widely-distributed plaques, frequently on the scalp.



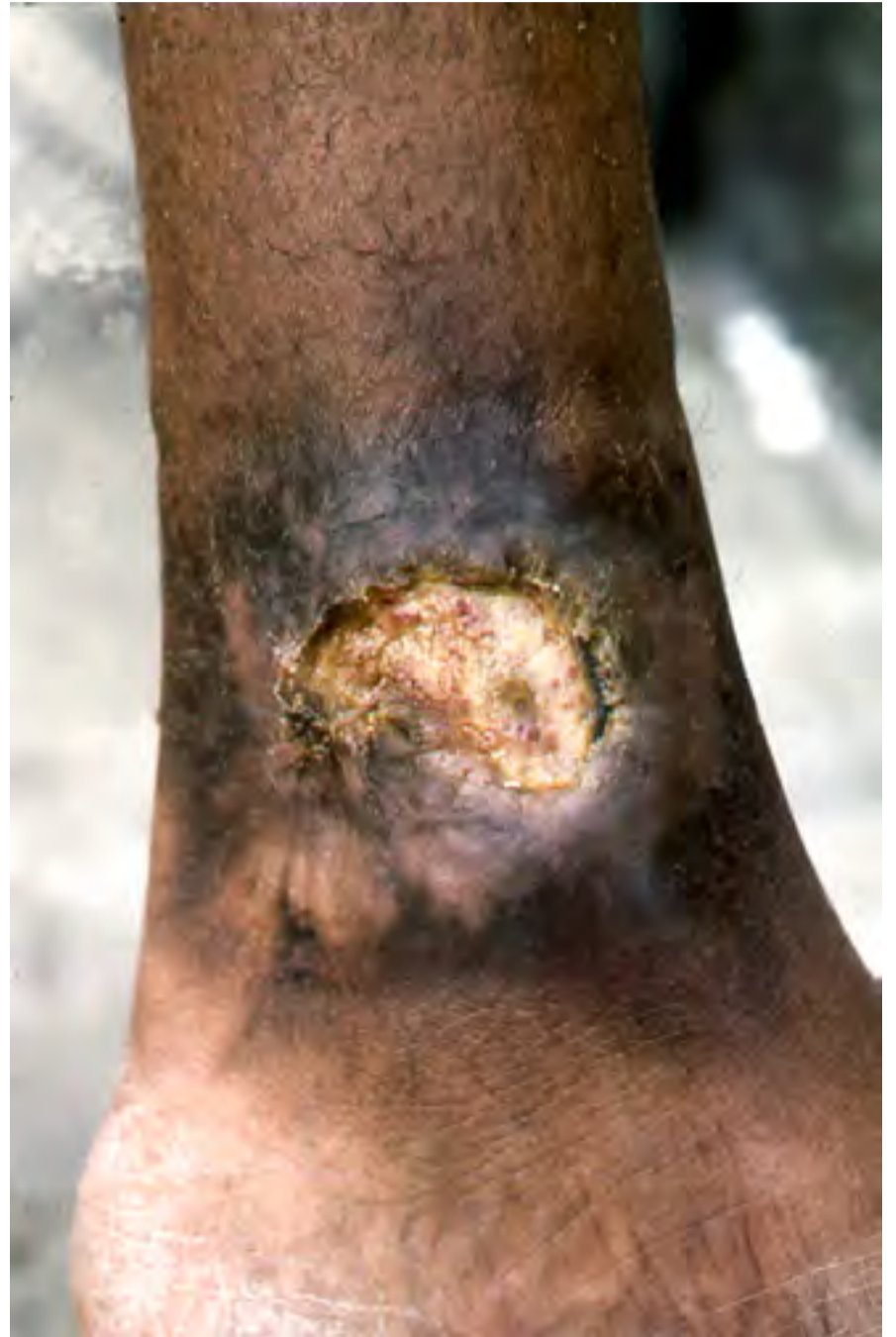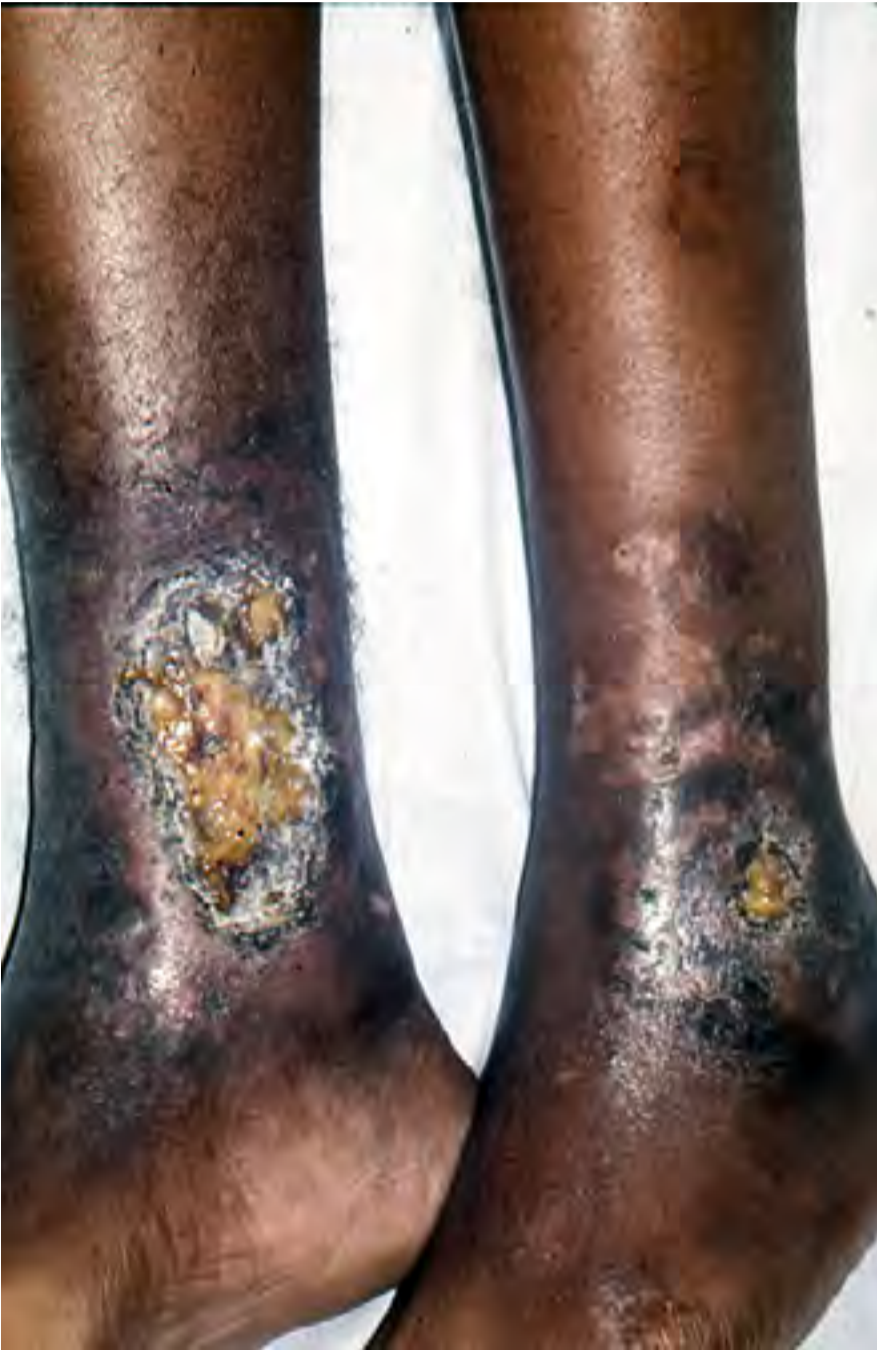*Dermal necrosis (Figure 3.286)*



**Figure 3.286.**

Cutaneous necrosis. Man aged 55 years from a leishmaniasis endemic area, with a painful one-week-old lesion on the leg. It started with burning and erythema, and very rapidly became a soft, blood-filled blister that broke easily and left a raw, ulcerated area, covered by fibrinoid membranes. It developed very quickly, and the lesion never got any deeper. Finally, the ulceration covered the entire necrotic area and took a month to heal. Possible diagnoses included cutaneous necrosis from animal poisoning (although he never described a history of bites) or cutaneous necrosis associated with a systemic disease, but the patient did not return to continue the work up.

*Sickle cell anemia (Figures 3.287)*

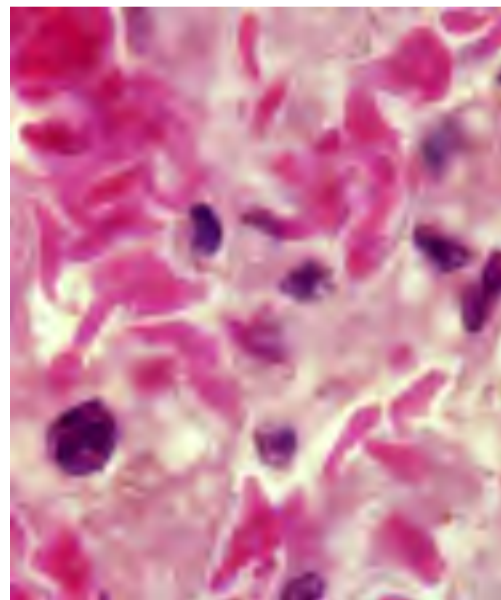


**Figures 3.287A and B.**

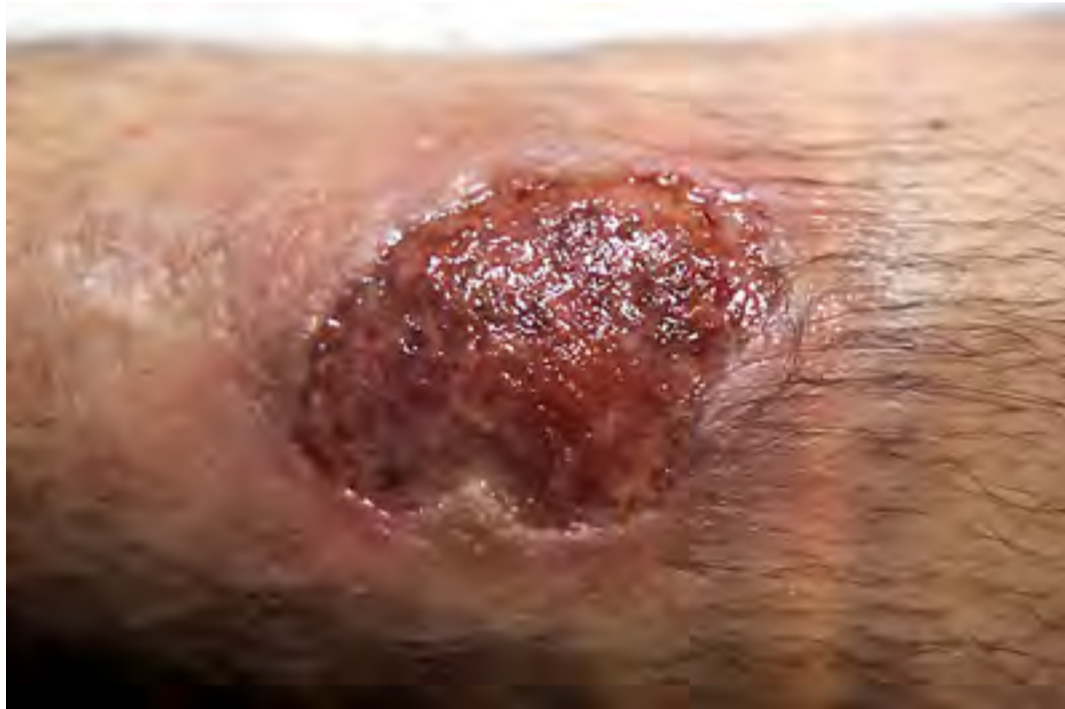Ulcers from sickle cell anemia. Malleolar ulcers confused with cutaneous leishmaniasis

**Figure 3.287C.**

Sickle-shaped red blood cells that occlude the small dermal vessels; hematoxylin and eosin, 100X.



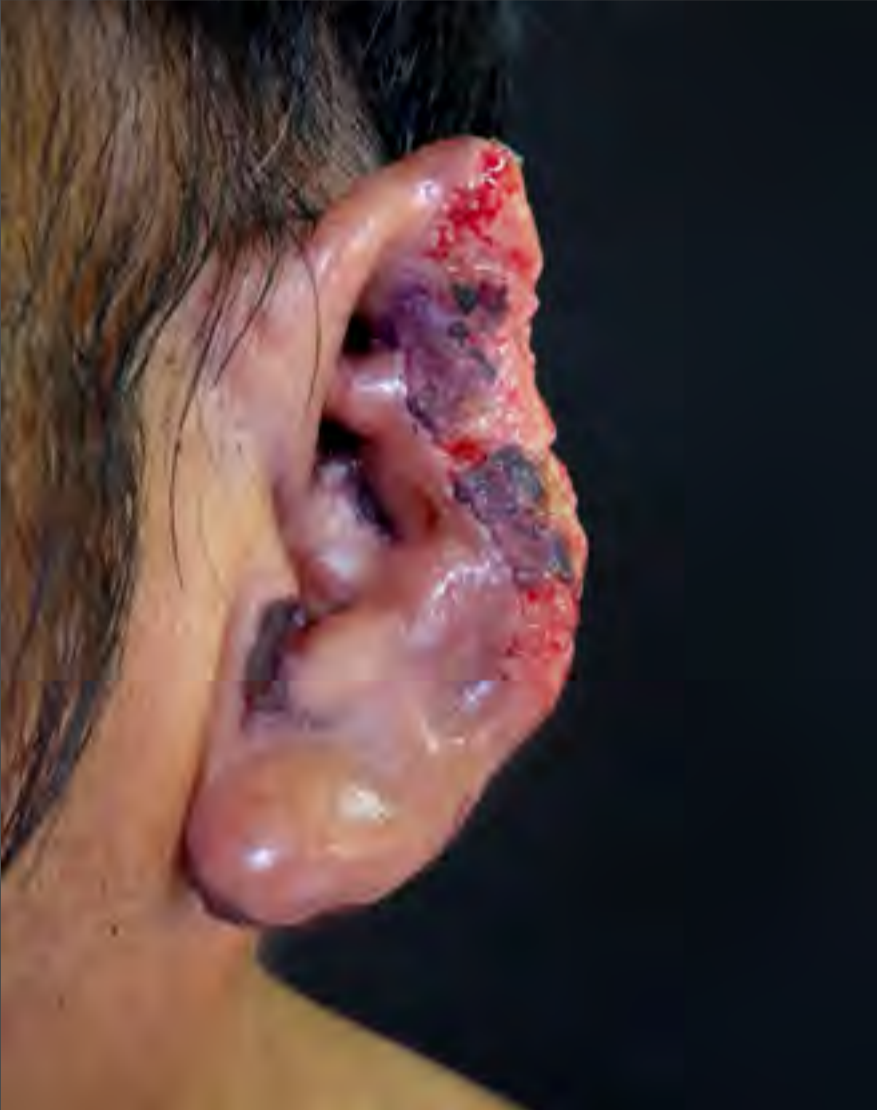***Traumatic ulcers.*** These usually occur on the legs and feet and on the forearms and hands; often, the history of trauma is very obvious to the patient. They grow rapidly, have an irregular outline, and can take the shape of the trauma. The edge is flat, the floor may be irregular, with little granulation tissue, and fibrinous membranes or frank purulent discharge are frequent. The ulcer heals slowly (*Figures 3.288 and 3.289*).



**Figure 3.288.**

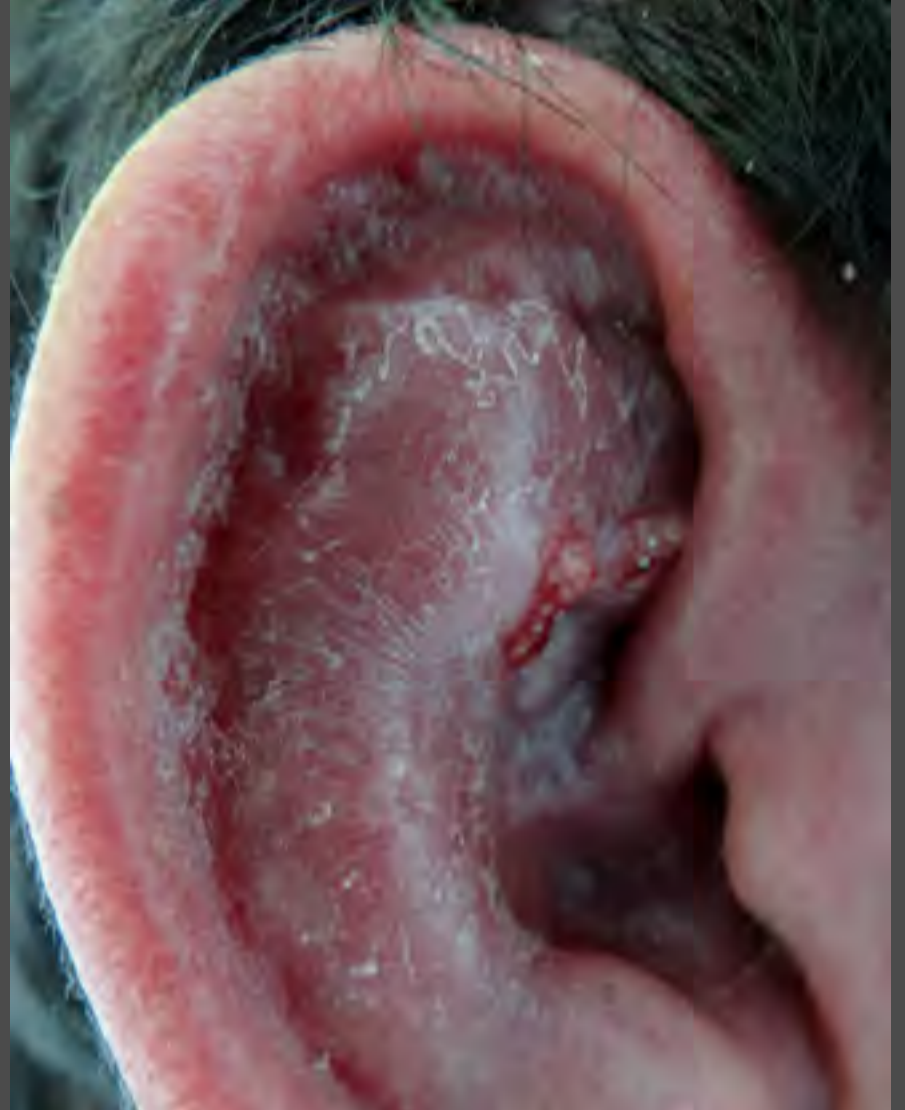Traumatic ulcer. Ulcer with thin edges and erythematous floor, secondary to old trauma

## Traumatic ulcers



**Figure 3.289A.**

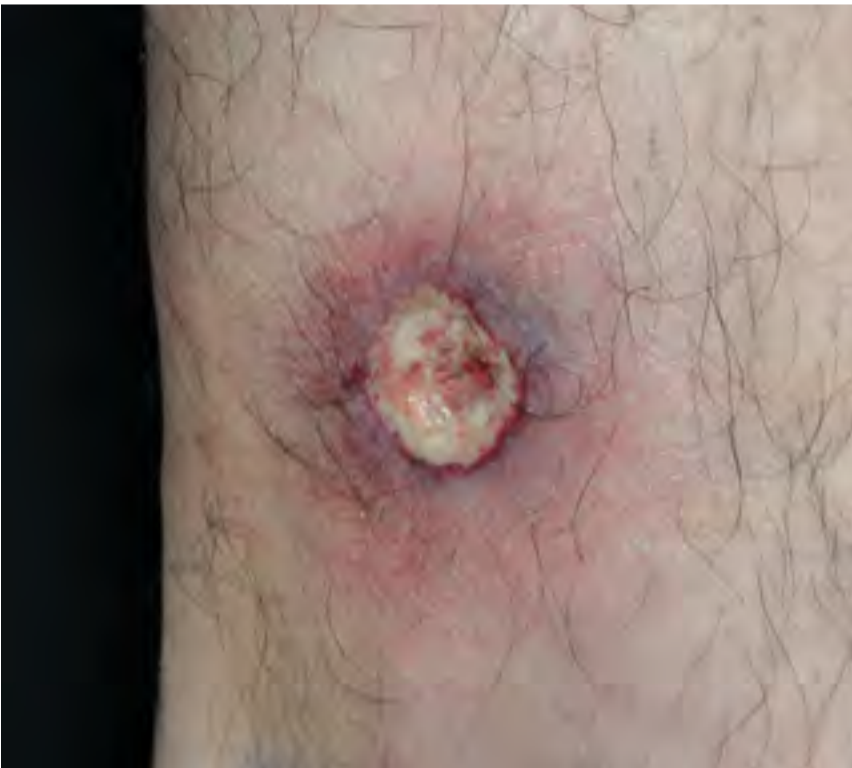After trauma or bites, the ears may become inflamed and infected and, if the processes are very serious, there could be destruction and loss of cartilage or generalized chondritis.



**Figure 3.289B.**

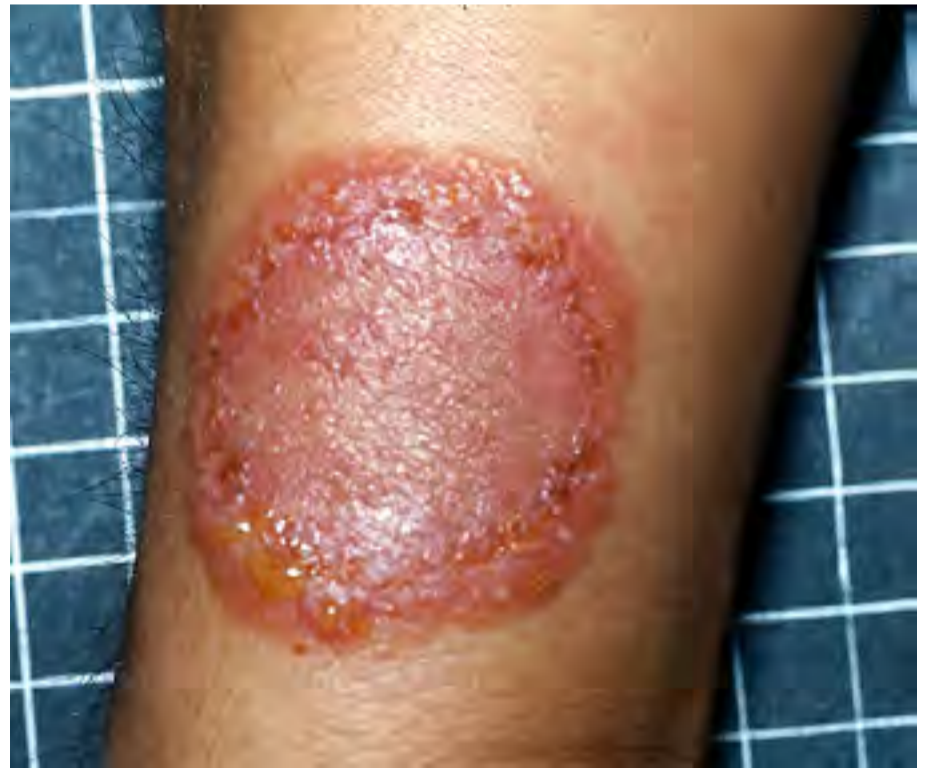The ear can become inflamed and infected after trauma or insect bites. If the process is very serious, there could be destruction and loss of cartilage or generalized chondritis.

***Insect bites.*** All mosquito bite lesions start similarly: single or multiple itchy erythematous-edematous papules that can be located on any area of the body, but, most frequently, on uncovered areas. Bites by common mosquitoes (*Culicoides*) rarely ulcerate, unless a serious allergic reaction occurs (poisoning) or the patient causes it by excessive scratching. Unlike bites from *Lutzomyia* spp., these bites last only a few days and resolve spontaneously. If they last more than two weeks, with persistent itching, growth of the lesion, and have started to or are ulcerated, leishmaniasis should be considered (*Figures 3.290*).



**Figure 3.290A.**

Ulcer from animal poisoning. A week after a bite that initially produced necrosis, an ulcer appeared, with a reddish-purplish halo and the center covered by adherent purulent membranes.



**Figure 3.290B.**

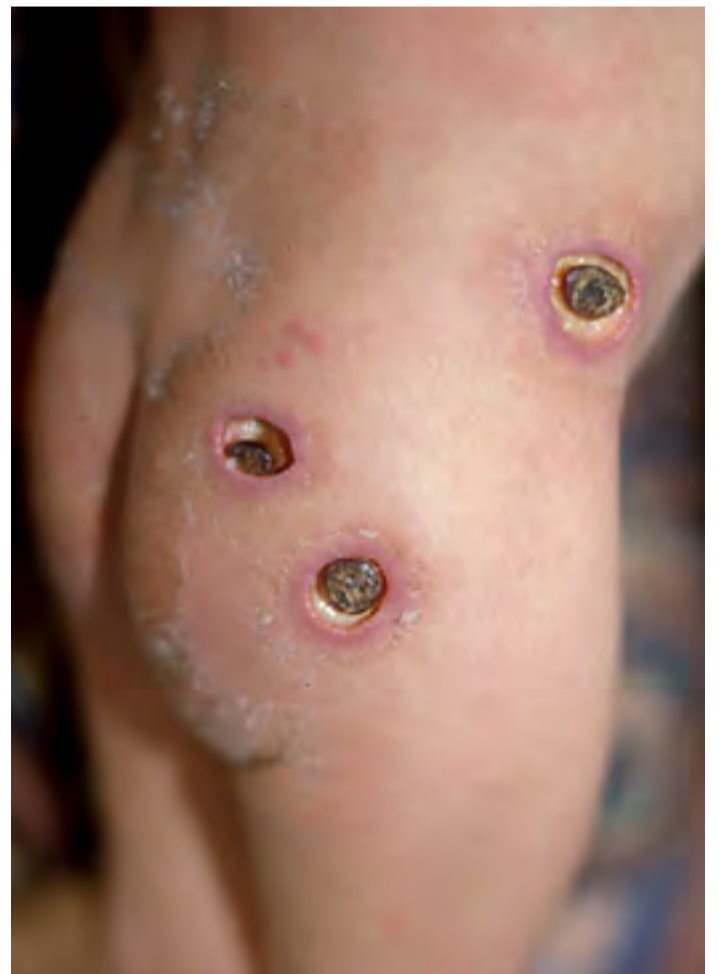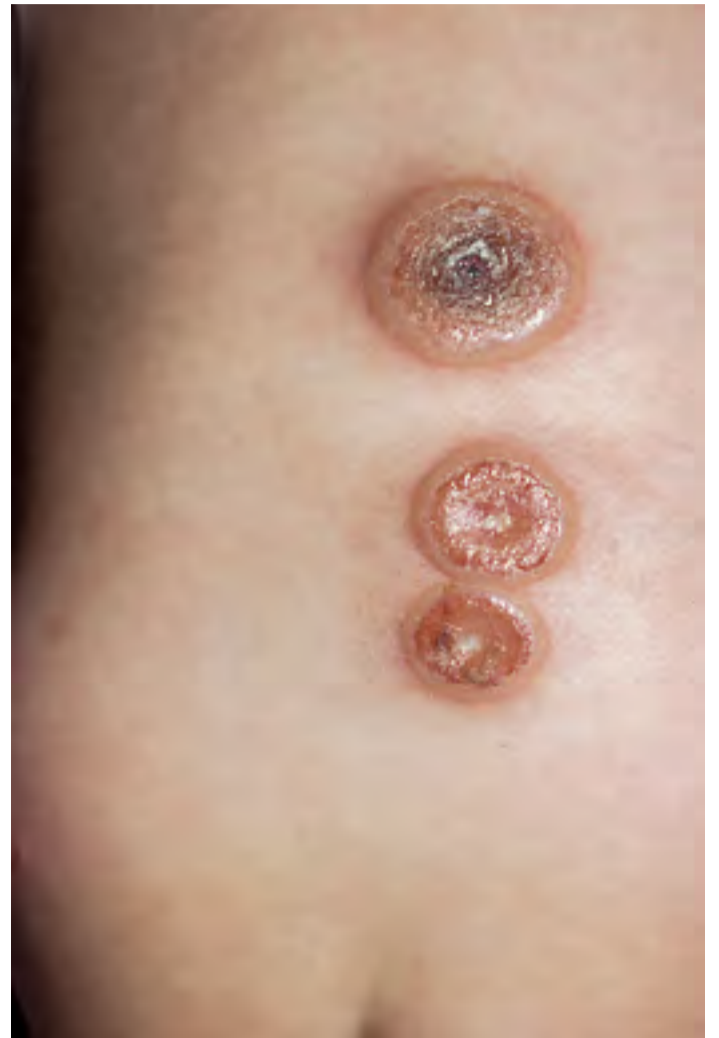On other occasions, poisoning produces an acute eczematous reaction, with abundant vesicles, desquamation, and crusting on top of underlying inflammation.

***Pyoderma gangrenosum.*** This disease presents as one or multiple extensive, necrotic, anfractuous, and excavated ulcers, with reddish-purple edges, a dirty or frankly purulent floor, and surrounded by a violet halo. Often, the necrosis is dry and extends under the skin beyond the apparent edge (*Figures 3.291 to 3.292*). They begin as a papule or pustule that ulcerates and spreads extensively and quickly. They are primarily located on the legs, although they can appear on any part of the body; they are painful, chronic, and can appear at the sites of trauma or venipuncture, displaying pathergy, which, although not pathognomonic of the disease, is characteristic.

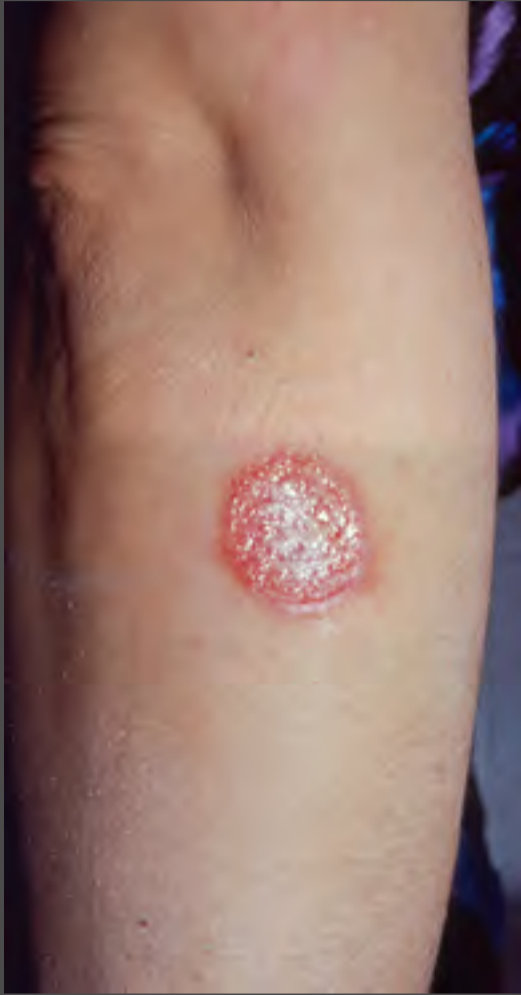This severe, ulcerative, neutrophilic, noninfectious, and recurrent dermatitis can be associated with autoimmune diseases, ulcerative colitis, Crohn's disease, various liver diseases, leukemias, and lymphomas, and with the use of some drugs. A history of previous episodes and the presence of irregular scars of varying size on different body segments suggest pyoderma gangrenosum more than leishmaniasis.

**Figures 3.291A and B.**

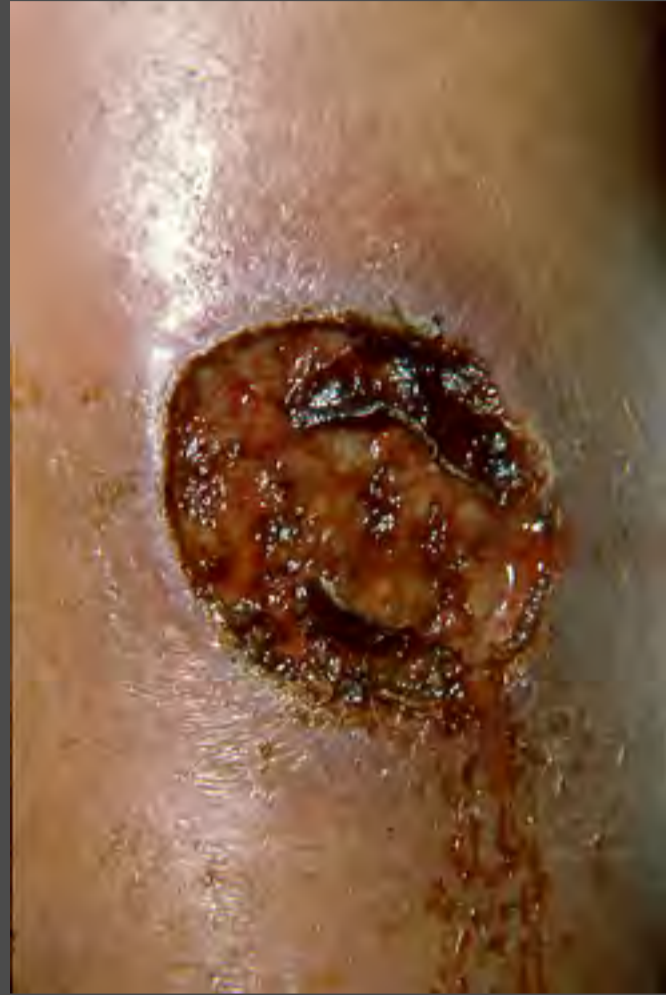Dermatitis gangrenosum infantile. These ulcers suggest cutaneous leishmaniasis, but the punched-out appearance and necrotic floor do not occur in cutaneous leishmaniasis. The biopsy clarifies the diagnosis.



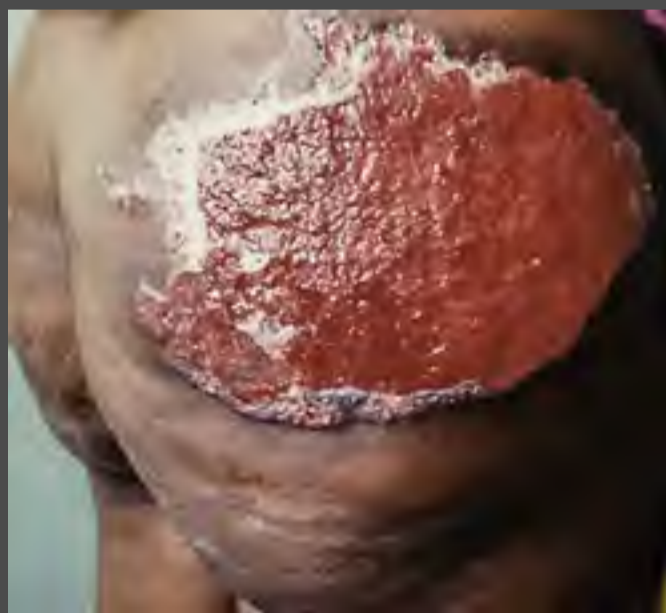## Pyoderma gangrenosum



**Figures 3.292A.**  
Ulcer with defined edges,  
difficult to clinically  
differentiate from leishmaniasis

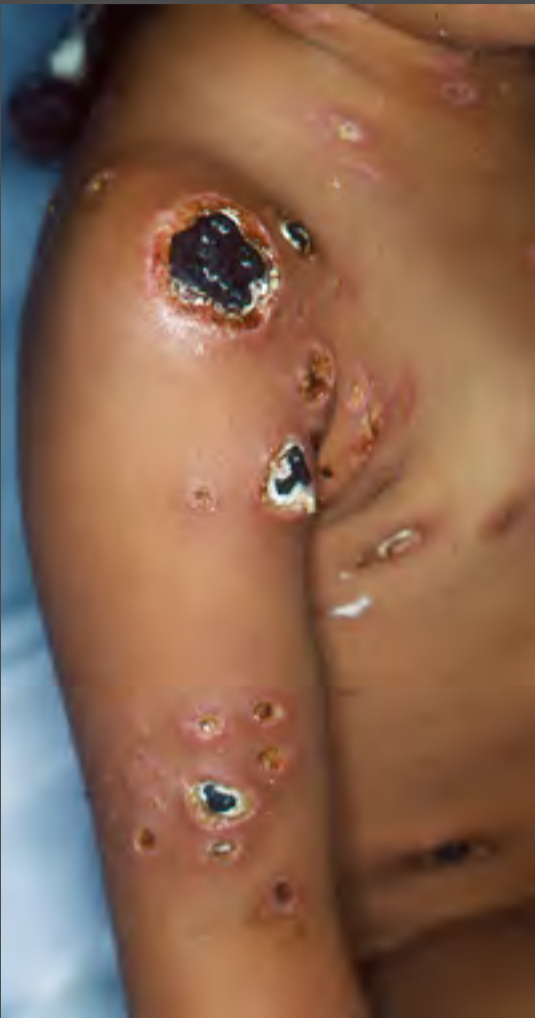

**Figures 3.292B.**  
Ulcer with flat edges and  
secretory floor

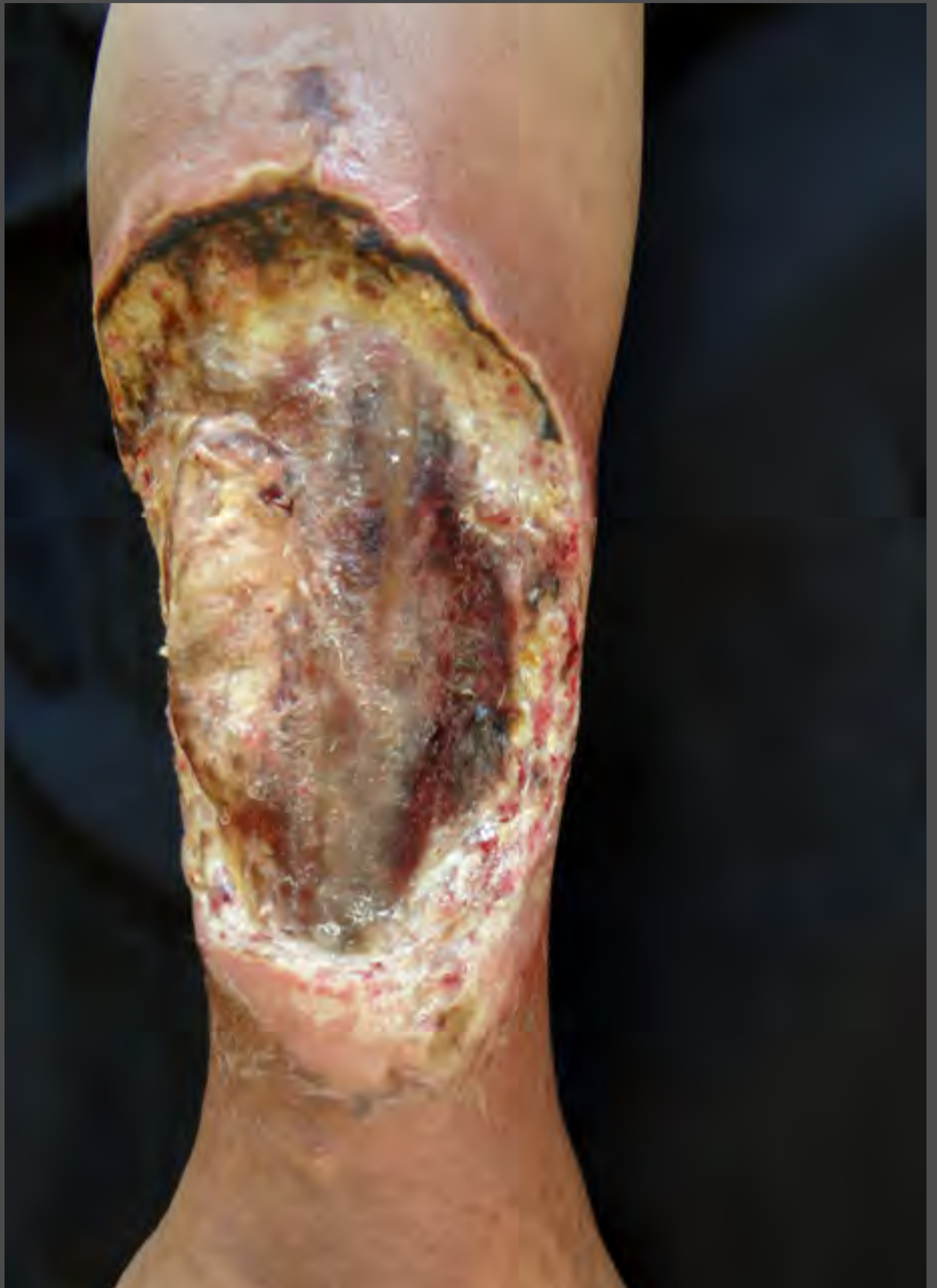

**Figures 3.292C.**  
Extensive ulcer characteristic of  
pyoderma gangrenosum

## Pyoderma gangrenosum



**Figures 3.292D.**  
Multiple ulcers with  
necrotic floor

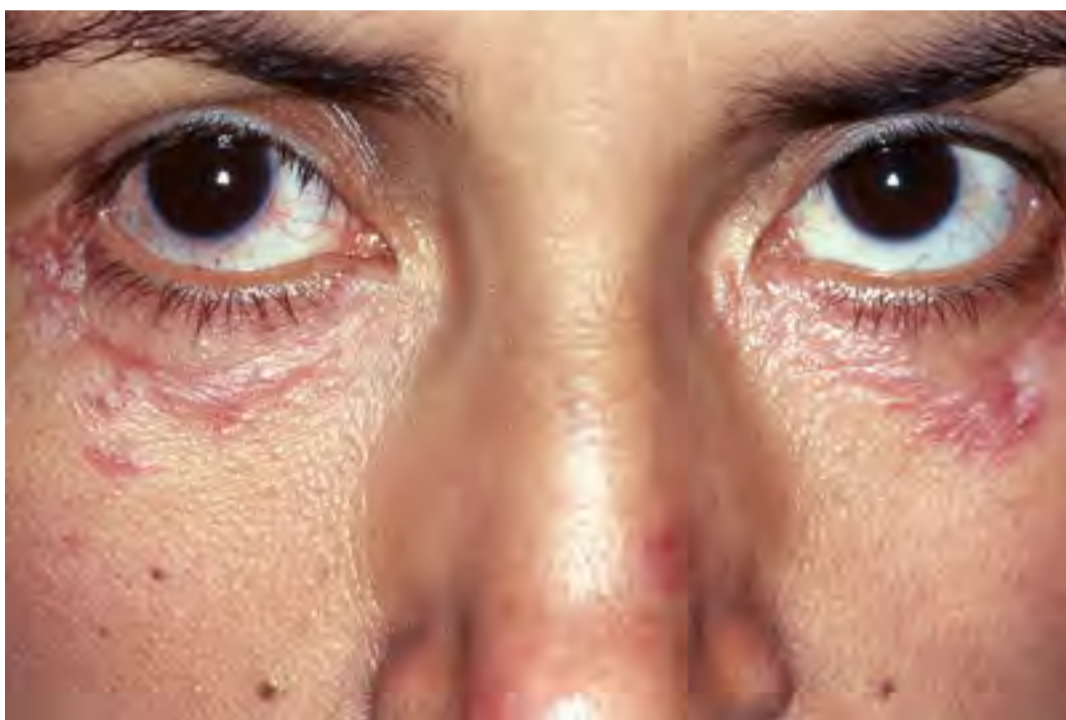

**Figures 3.292E.**

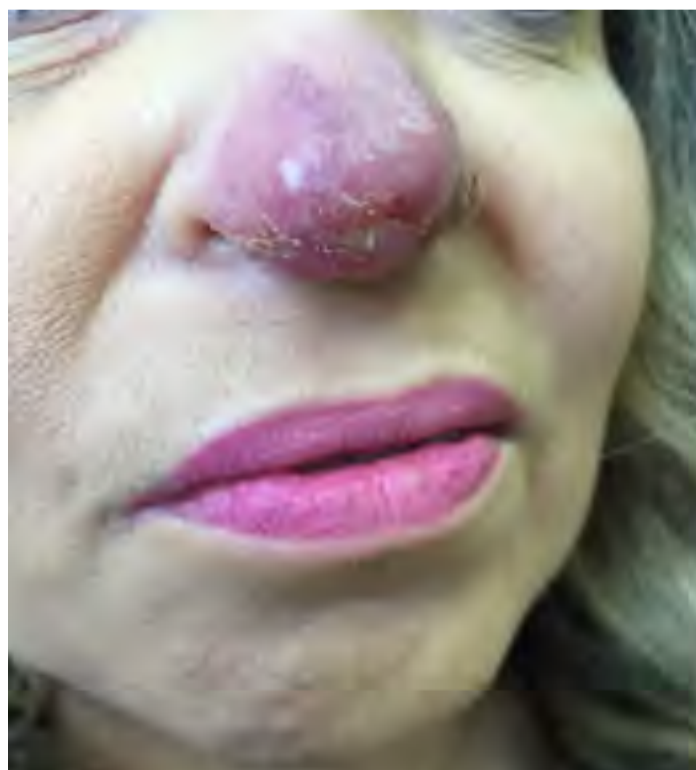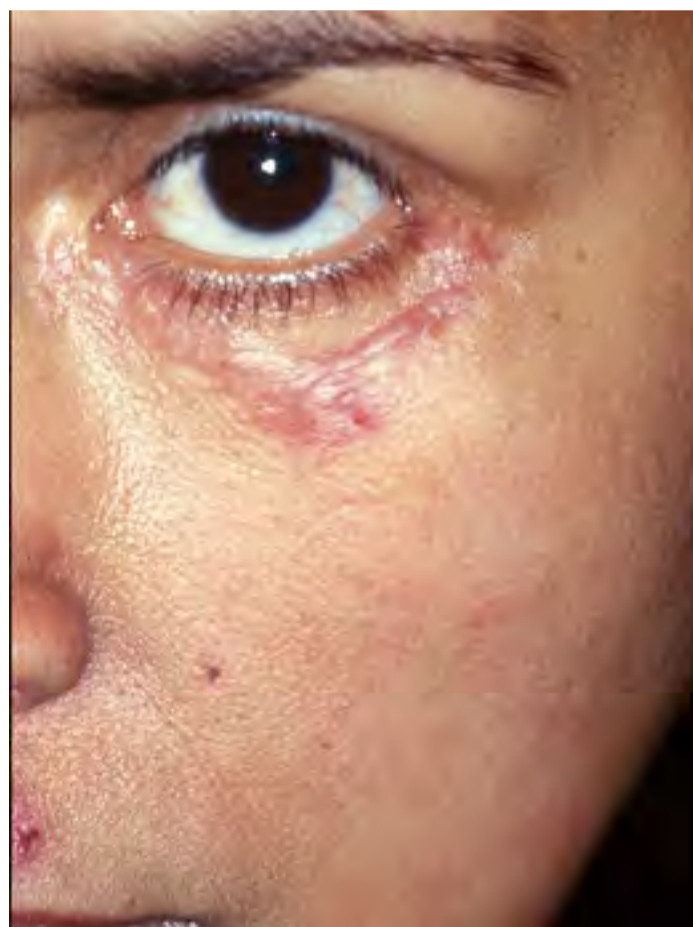This is an ulcerative disease of unknown origin, associated with an autoimmune process, characterized by episodes of ulcers from 0.5 to 10 cm or more in diameter, on any part of the body, but most commonly on the limbs. The ulcers are irregular, with flat or inverted edges, dirty, with purulent secretions, and adherent necrotic eschars. A skin biopsy is indispensable to confirm the diagnosis; laboratory tests are requested based on clinical data. The disease is chronic, with recurrent episodes and, after the ulcers heal, atrophic scars remain.



***Cutaneous sarcoidosis.*** This is a chronic granulomatous disease of undefined etiology that affects multiple organs, among them the skin. The lesions are usually brown papules and plaques, erythematous and infiltrated, with a smooth surface, and they rarely ulcerate (*Figures 3.293 to 3.295*). Involvement of the nose, cheeks, and ears can resemble leishmaniasis in plaques or its lupoid form.

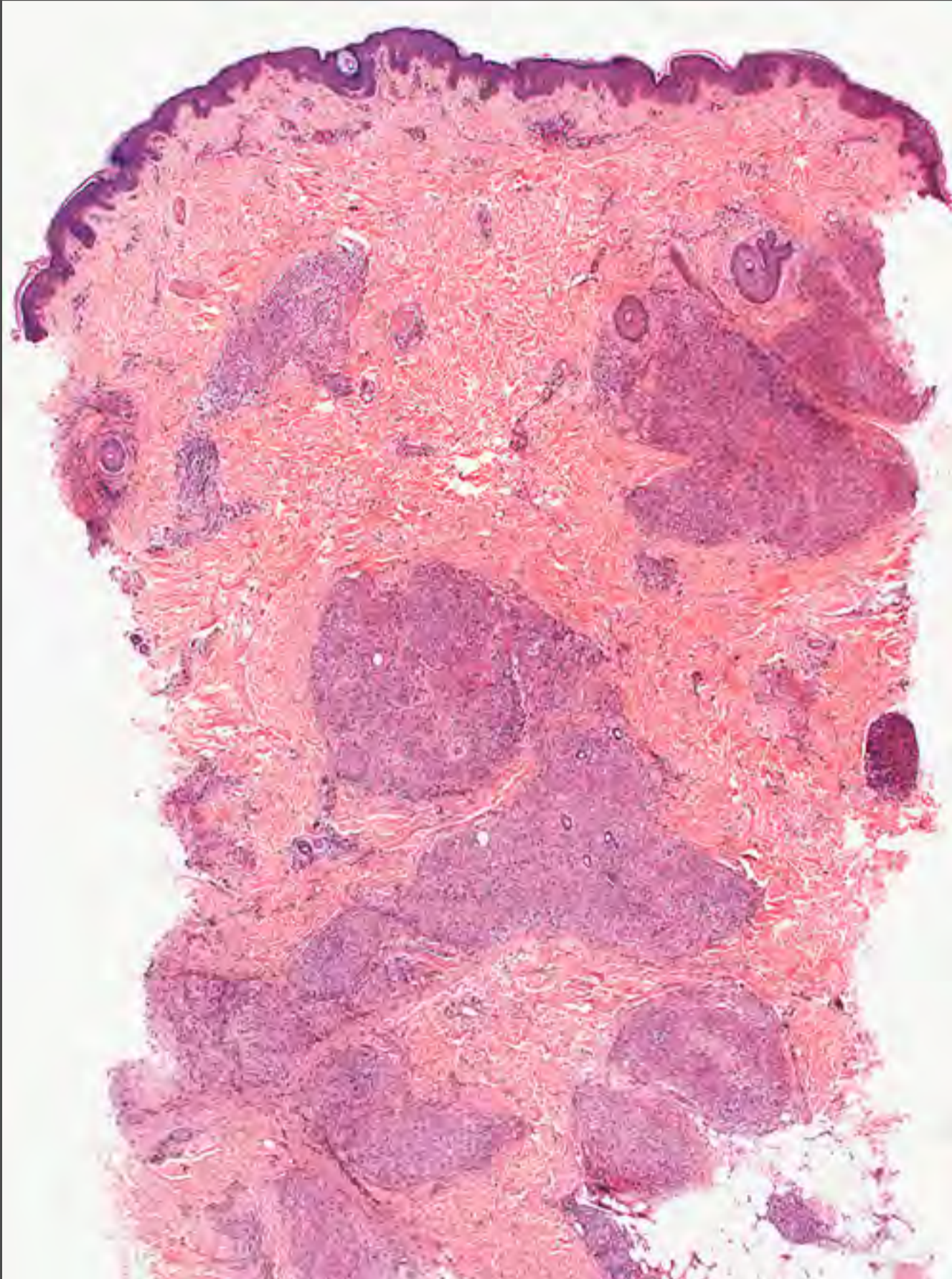


**Figures 3.293A and B.**  
Erythematous papules and plaques



**Figure 3.294.**  
Sarcoidosis. Infiltrative lesion in the external nasal region

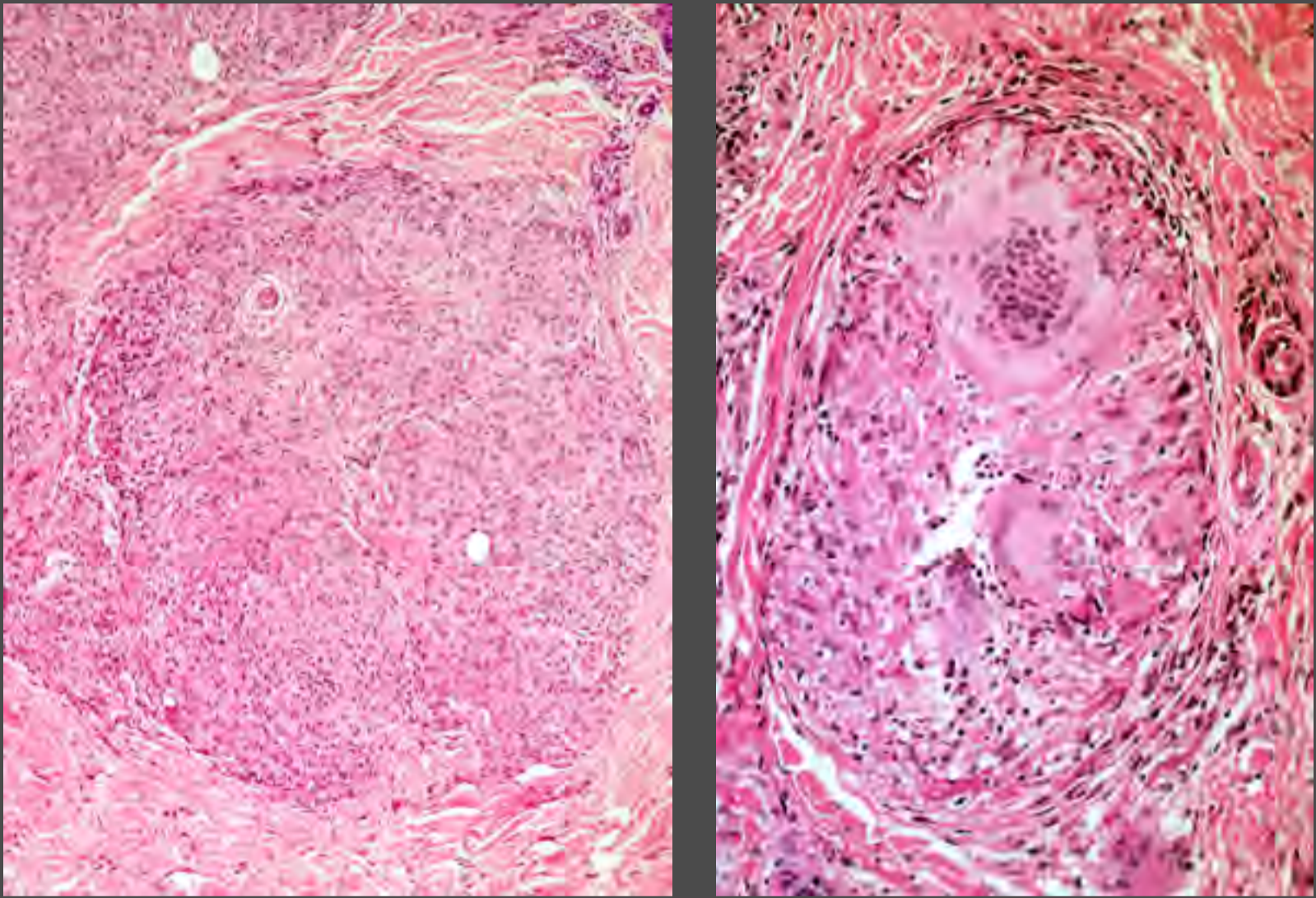
## Cutaneous sarcoidosis



**Figure 3.295A.**

Skin biopsy. Well-defined epithelioid granulomata throughout the dermis layer, with few lymphocytes, and with giant multinucleated cells; hematoxylin and eosin, 2.5X.

## Cutaneous sarcoidosis

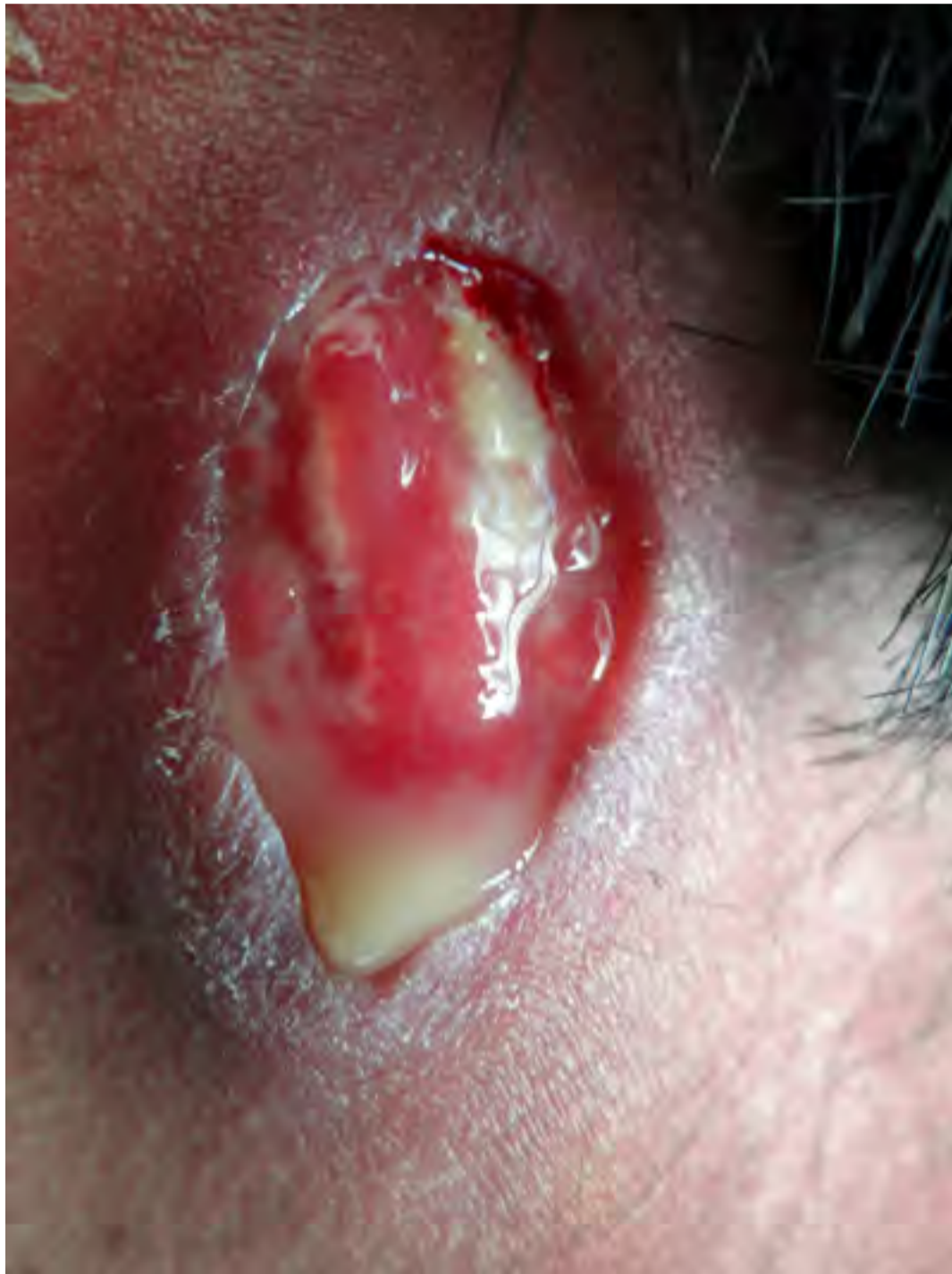

**Figures 3.295B and C.**

Skin biopsy. Well-defined epithelioid granulomata throughout the dermis layer, with few lymphocytes, and with giant multinucleated cells; hematoxylin and eosin, 40X.

*Granuloma faciale.* These are erythematous or brown papules, nodules, and plaques located on areas of high sun exposure that grow slowly and can last years.

*Banal ulcer (Figure 3.296)*



**Figures 3.296.**

Superinfected banal ulcer with purulent discharge, without an established cause, located in the retroauricular area

## Malignant Neoplasms

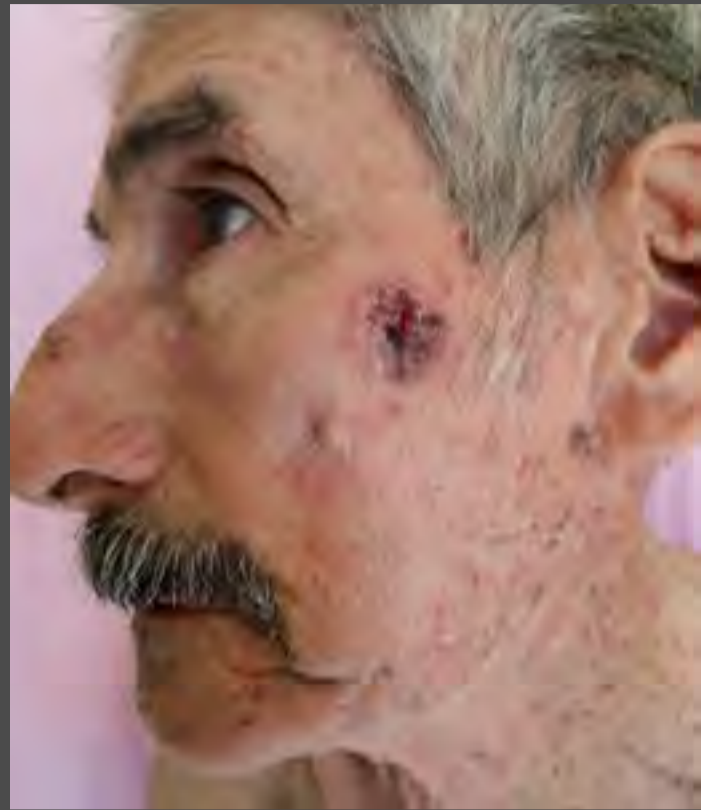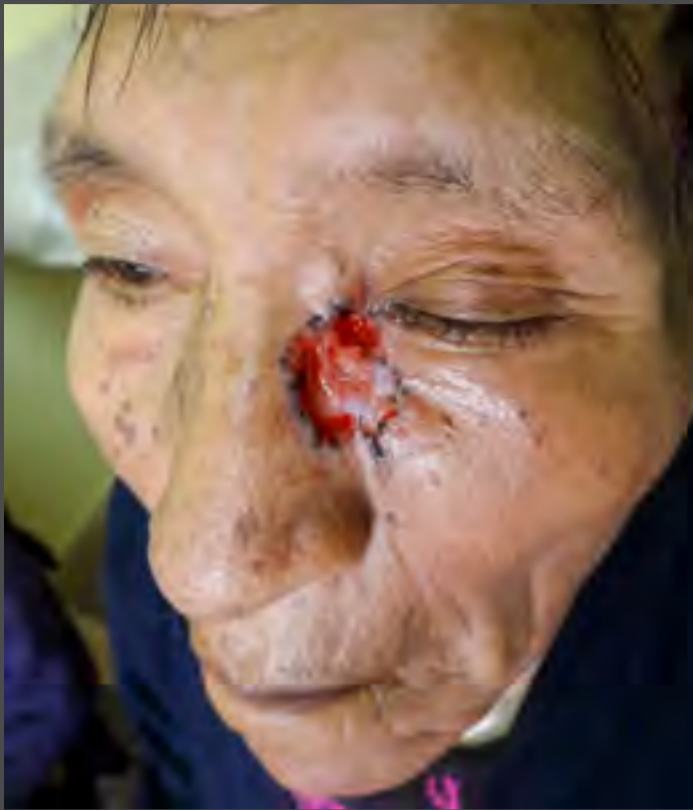Any ulcerated cutaneous tumor can resemble leishmaniasis. Usually, these are basal cell carcinomas, squamous cell carcinomas, or keratoacanthomas, although they can also be lymphomas.

It is exceptional for a leishmaniasis ulcer to be the origin of squamous cell or basal cell carcinoma, since that anaplastic transformation takes years and leishmaniasis usually heals long before it appears; however, reactive epidermal hyperplasia of the edge of the leishmaniasis ulcer can be difficult to differentiate from squamous cell carcinoma.

Leishmaniasis may manifest, or become more extensive and disseminated, in patients with cancer, mainly hematolymphoid, because of the immunosuppression associated with the neoplasm.

***Basal cell carcinoma.*** Ulceration is frequent in basal cell carcinoma, but the history of several years of development and the patient's description of a papular or pigmented lesion preceding the ulcer, as well as the presence of lesions from chronic sun damage on exposed areas—melanosis, keratosis, and wrinkles—is more suggestive of cancer than leishmaniasis. When examining the edges of ulcerated basal cell carcinoma, bright pearly or pigmented papules can be seen, with very irregular borders, little infiltration of the base of the ulcer, with pigmentation changes in areas peripheral to the ulcer, increased blood vessels, and signs of sun damage (*Figures 3.297 to 3.316*). Epidemiological (origin and residency) and demographic (age and sex) data can help define the difference on some occasions.

## Basal cell carcinoma

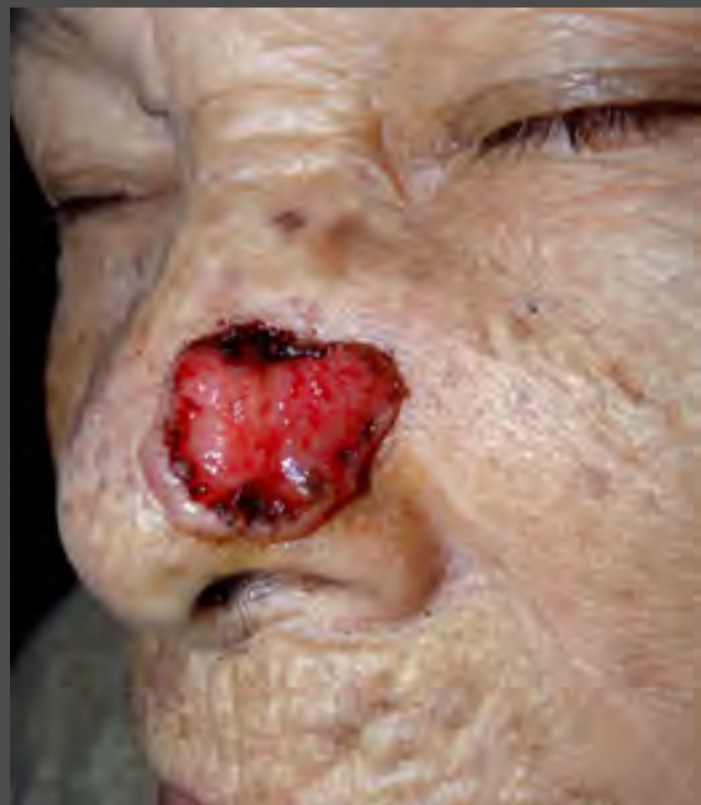
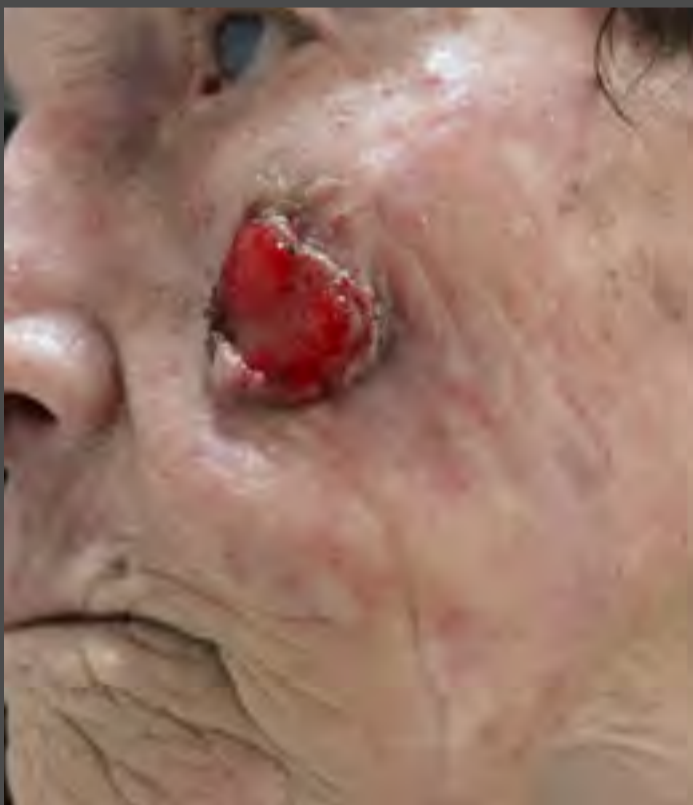
**Figure 3.297.**

Patient aged 70 years with four-year-old lesion, which is slow and asymptomatic. Nodular in form, pigmented, and ulcerated, with a noteworthy papular and heavily pigmented edge.

**Figure 3.298.**

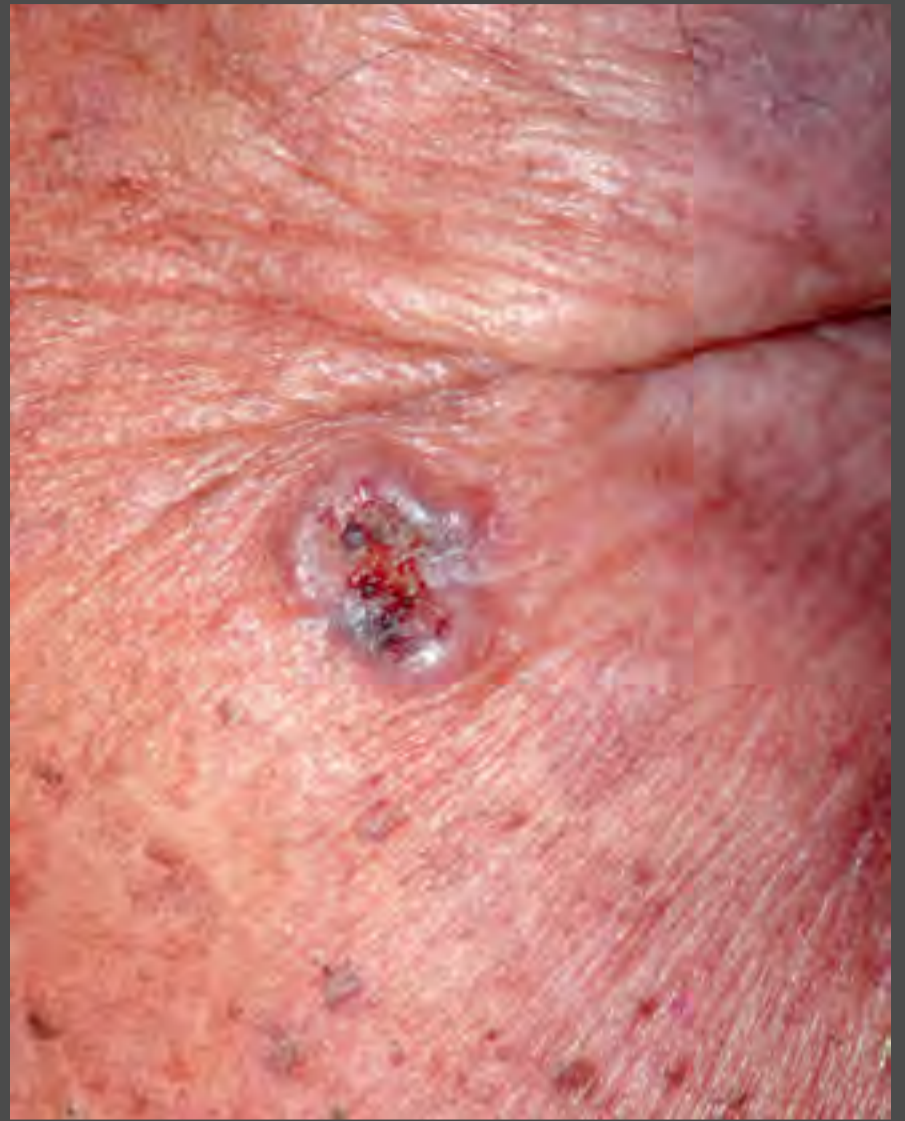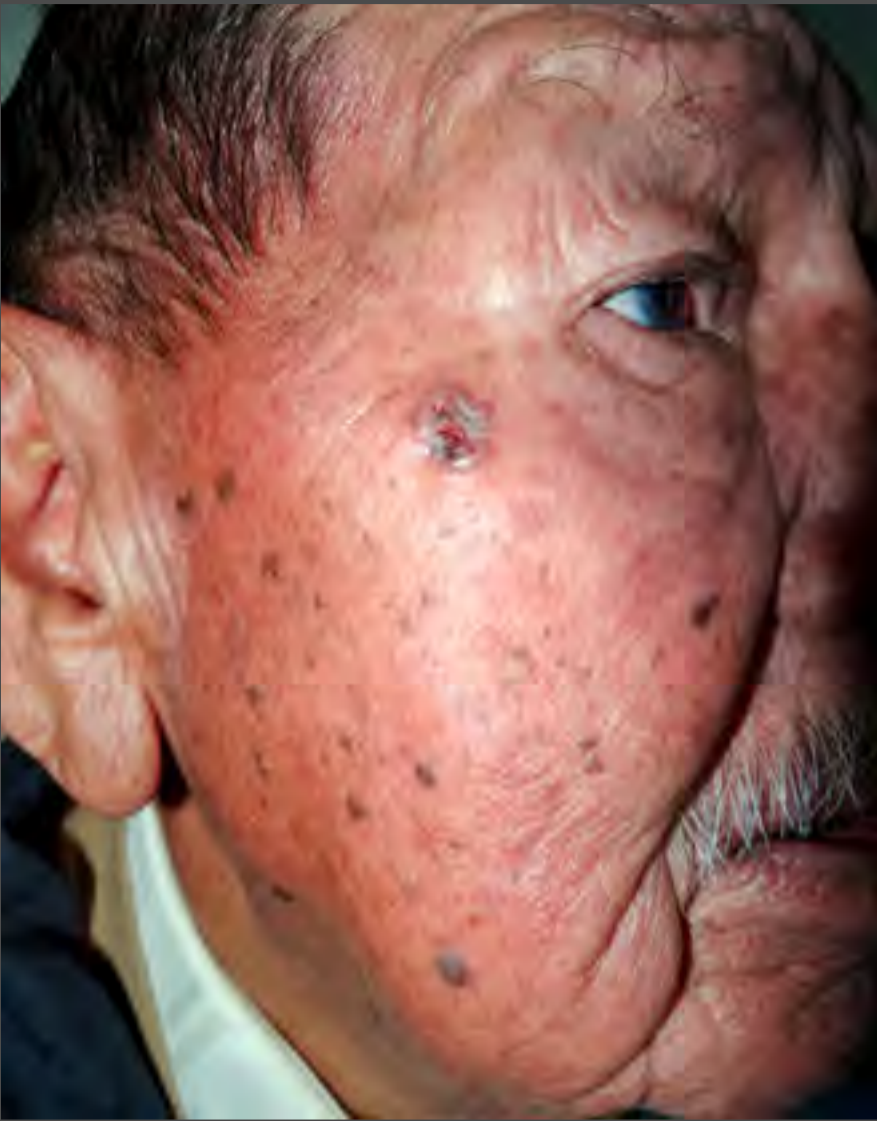Patient aged 65 years with two-year-old asymptomatic lesion. It is nodular in form, with an infiltrated plaque and irregular ulceration covered by bloody crusts, and several lesions due to sun damage on the face.



**Figures 3.299A and B.**

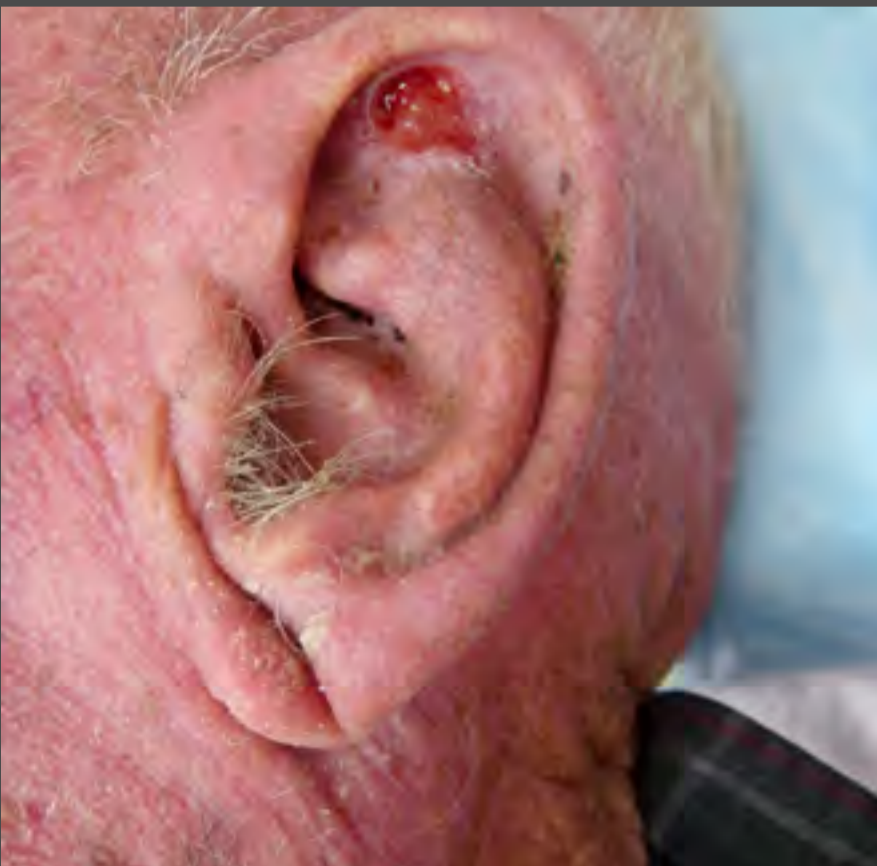Two very similar lesions in older women. Ulcers with raised edges and ulcerated centers, superficial floor, and tissue proliferation that forms buttons that are flush with or above the surrounding skin. The patient's age, evident sun damage, and origin reduce the possibility that this is leishmaniasis.

## Basal cell carcinoma



**Figures 3.300A and B.**

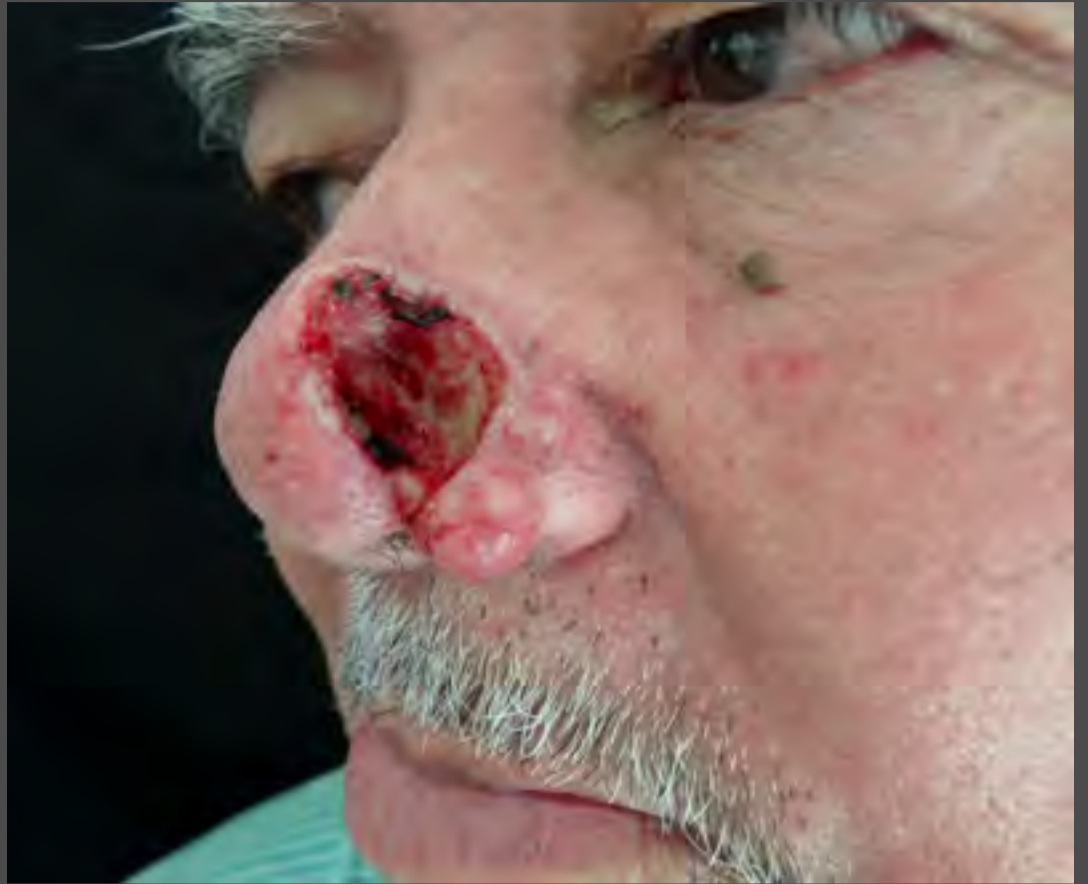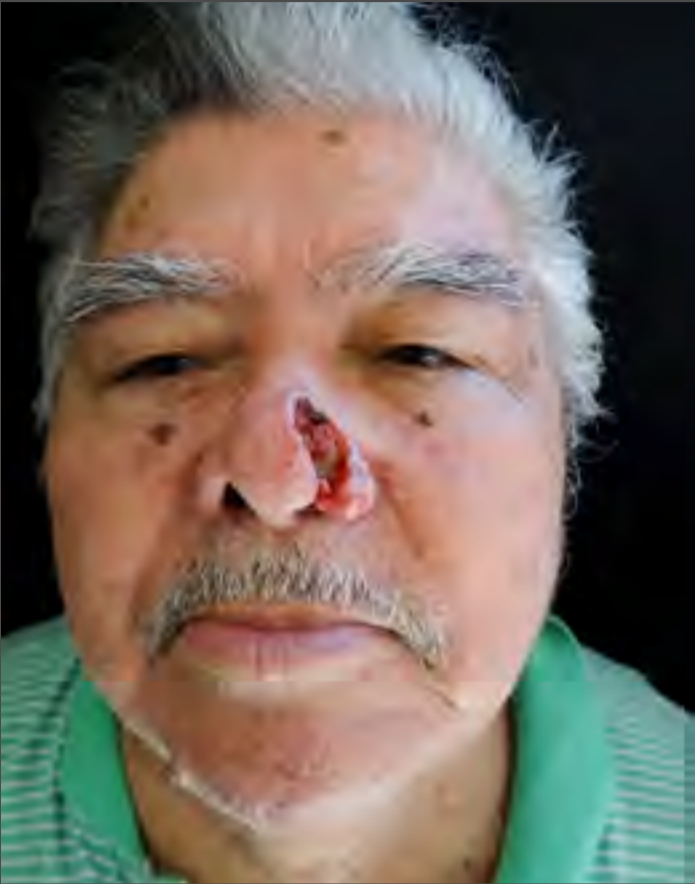Man aged 67 years with three-year-old asymptomatic lesion on the cheek. The center is ulcerated, but superficial, with pearly raised edges that resemble cordoned cutaneous leishmaniasis lesions.



**Figure 3.301.**

Man aged 73 years with one-year-old ulcer on the ear. Lesion is well defined, with sharp slightly-raised edges and a granular center. Leishmaniasis and basal cell carcinoma are frequent on the ears, but phototype I and serious chronic sun damage orient the clinical diagnosis, confirmed with the biopsy.

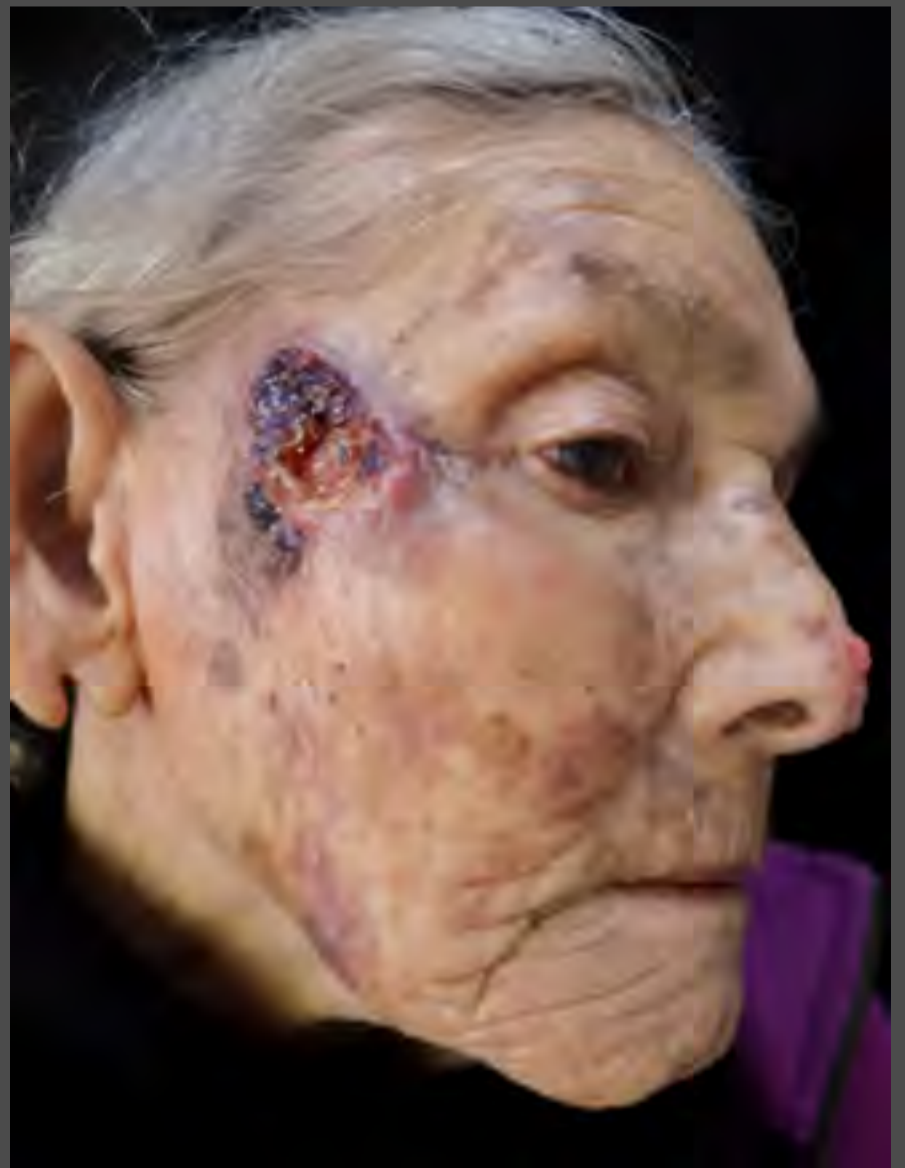## Basal cell carcinoma

**Figures 3.302A and B.**

Patient aged 57 years with 15-month-old nodular-type, ulcerated lesion on the nasal ala. The ulcer is deep and irregular, with pearly edges and with one papule with telangiectasias on the lower pole. He also has another pigmented basal cell carcinoma on the right cheek.

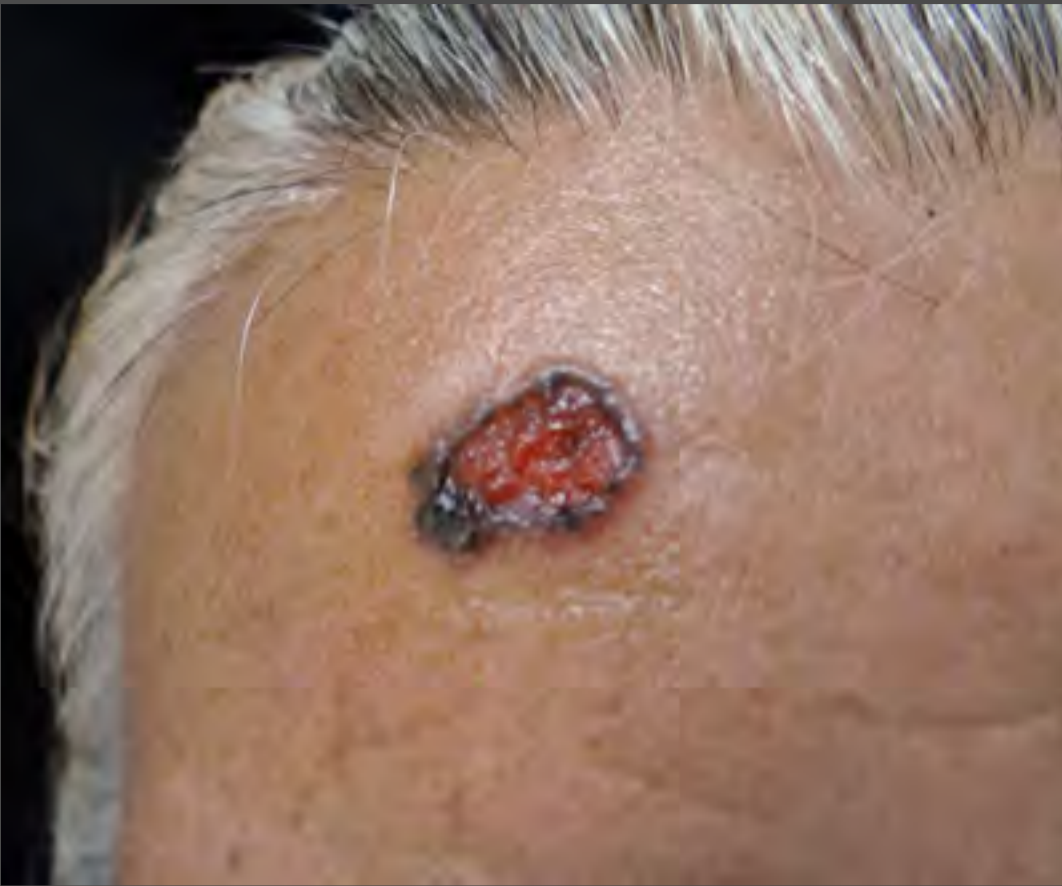**Figure 3.303.**

Woman aged 72 years with two-year-old ulcerated, nodular basal cell carcinoma. The edges are raised, cordoned, and violet, and it has irregular central granulation. Another neoplasm was found on the bridge of the nose and multiple lesions due to serious chronic sun damage



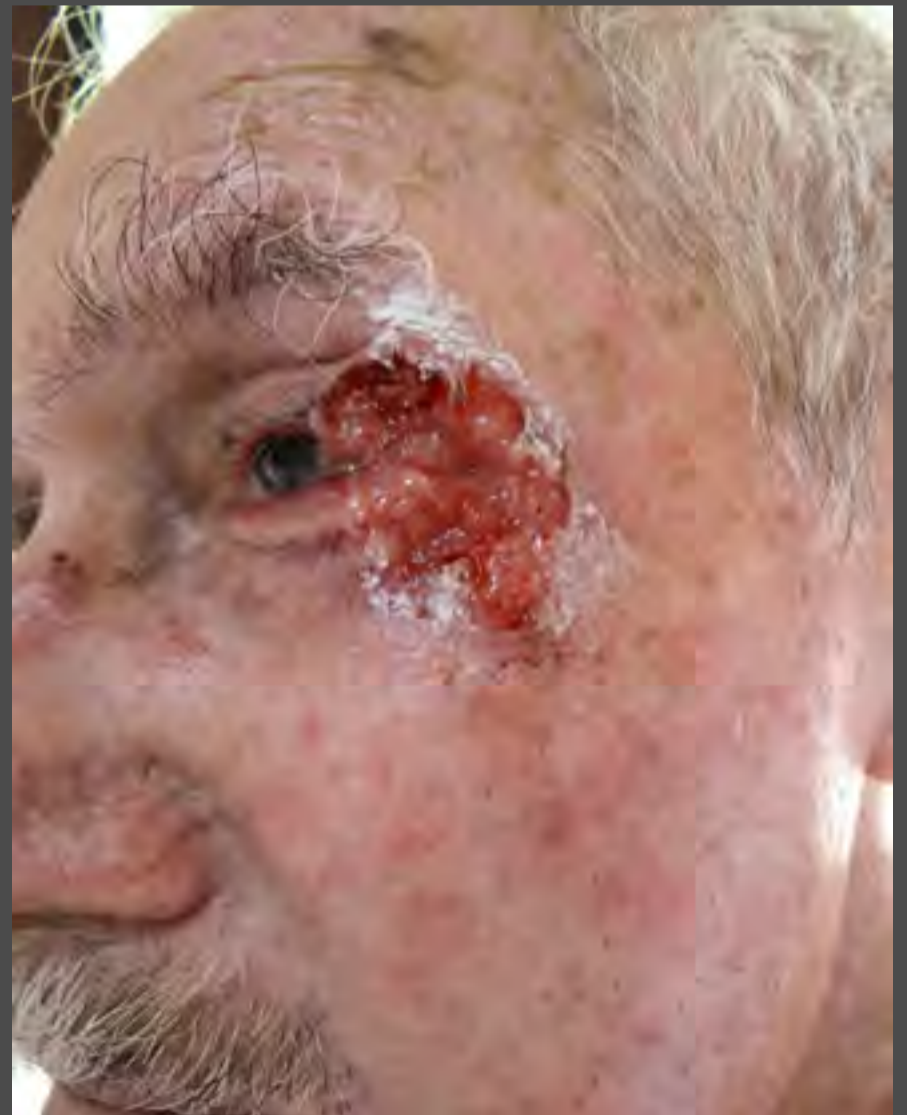
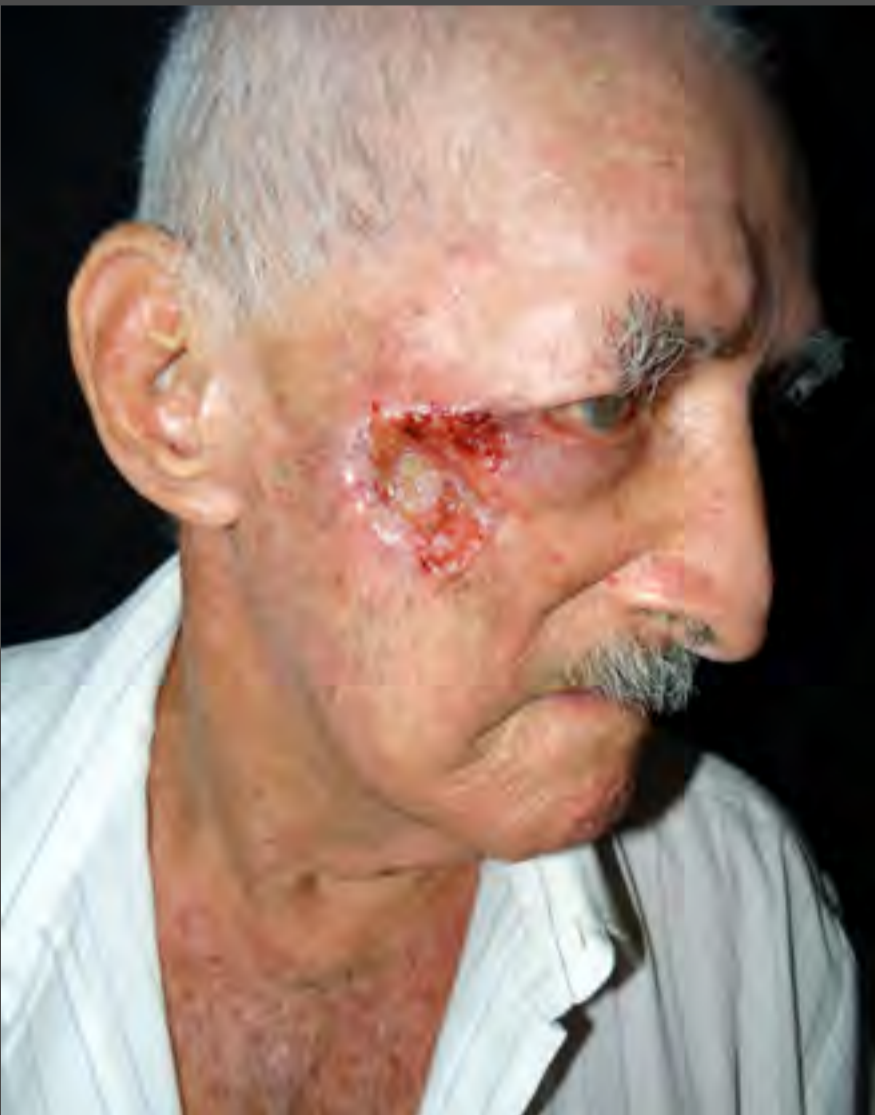
## Basal cell carcinoma



**Figure 3.304.**

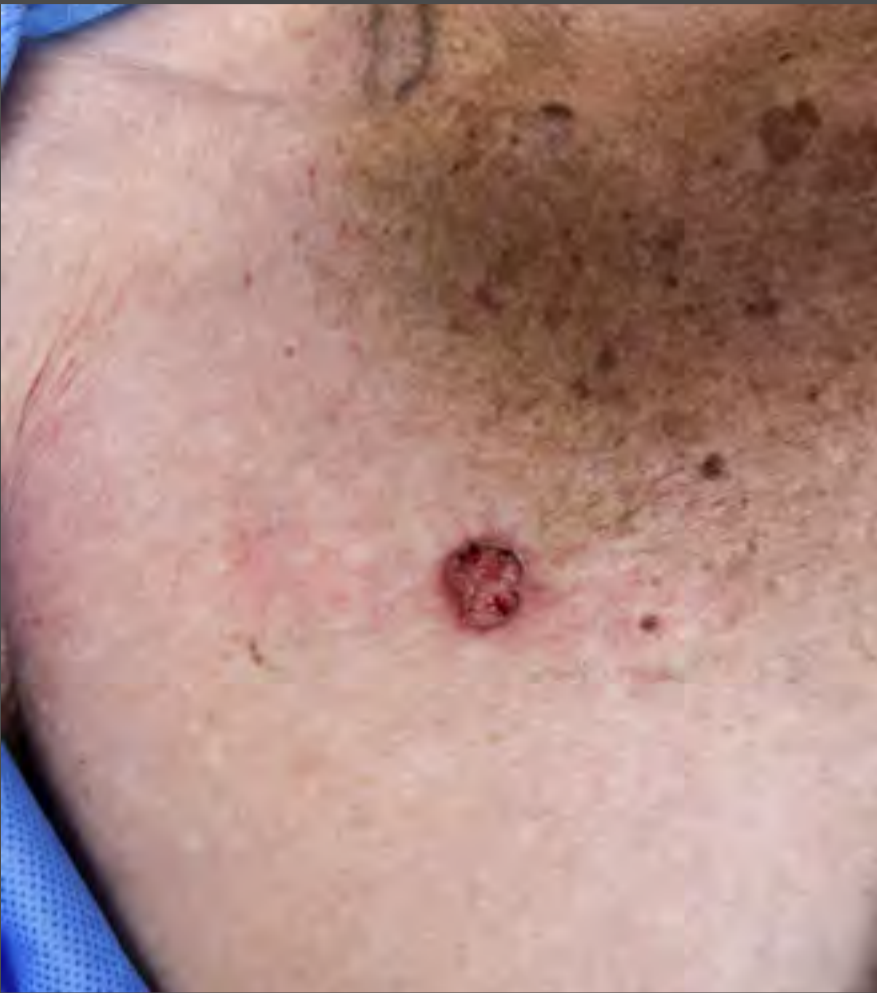Man aged 59 years with a one-year-old nodular, pigmented, ulcerated lesion, in which the pigmentation of the entire edge is notably dark. Histopathology confirmed the clinical diagnosis.



**Figures 3.305A and B.**

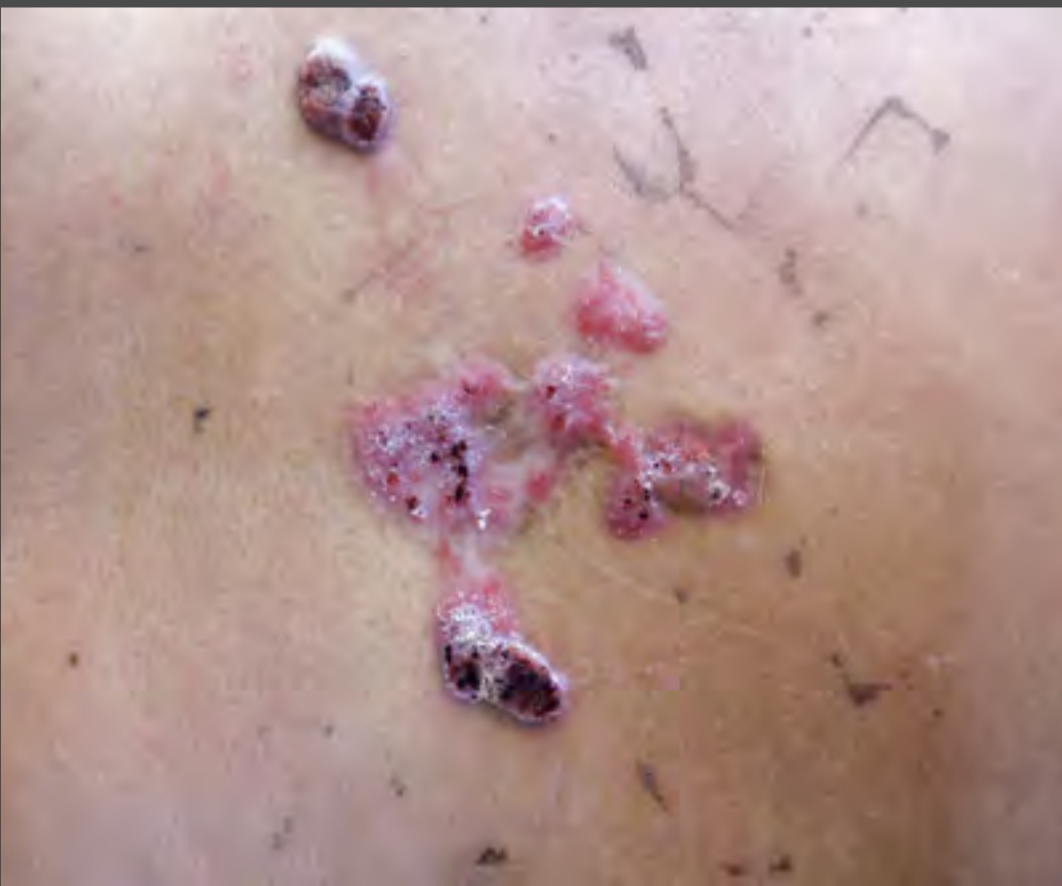Patients with white skin with considerable sun damage and a five-year-old ulcerated, asymptomatic lesion on the lateral palpebral commissure. The histopathological study confirmed the clinical diagnosis.

## Basal cell carcinoma



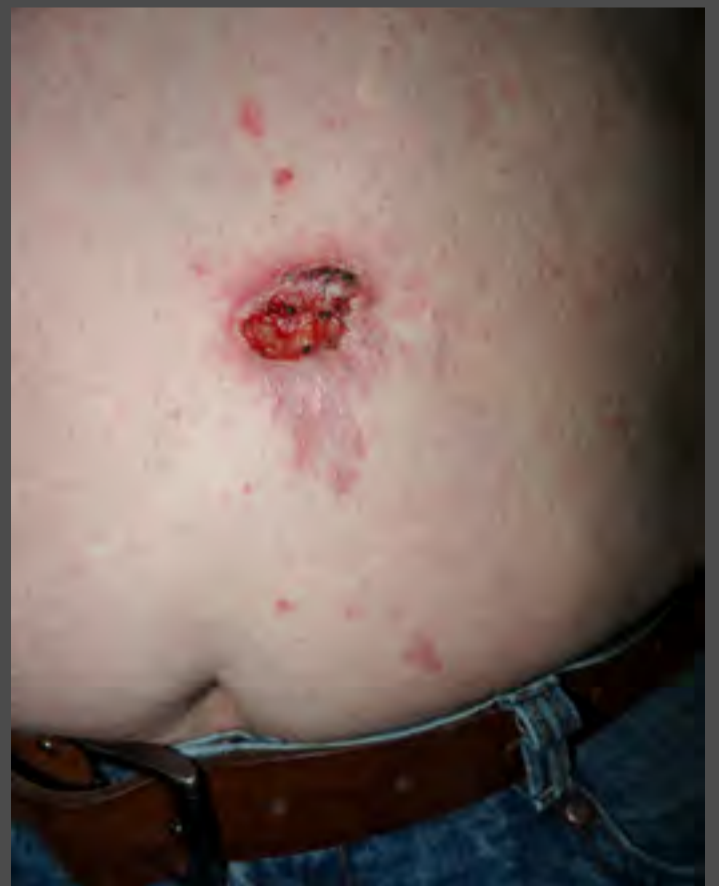**Figure 3.306.**

Man aged 53 years with two-year-old asymptomatic lesion on the chest on the edge of a plaque from major sun damage. It is an oval-shaped ulcer with pearly edges, crusts, and a depressed, dry center. The histopathological study confirmed the clinical diagnosis.



**Figure 3.307.**

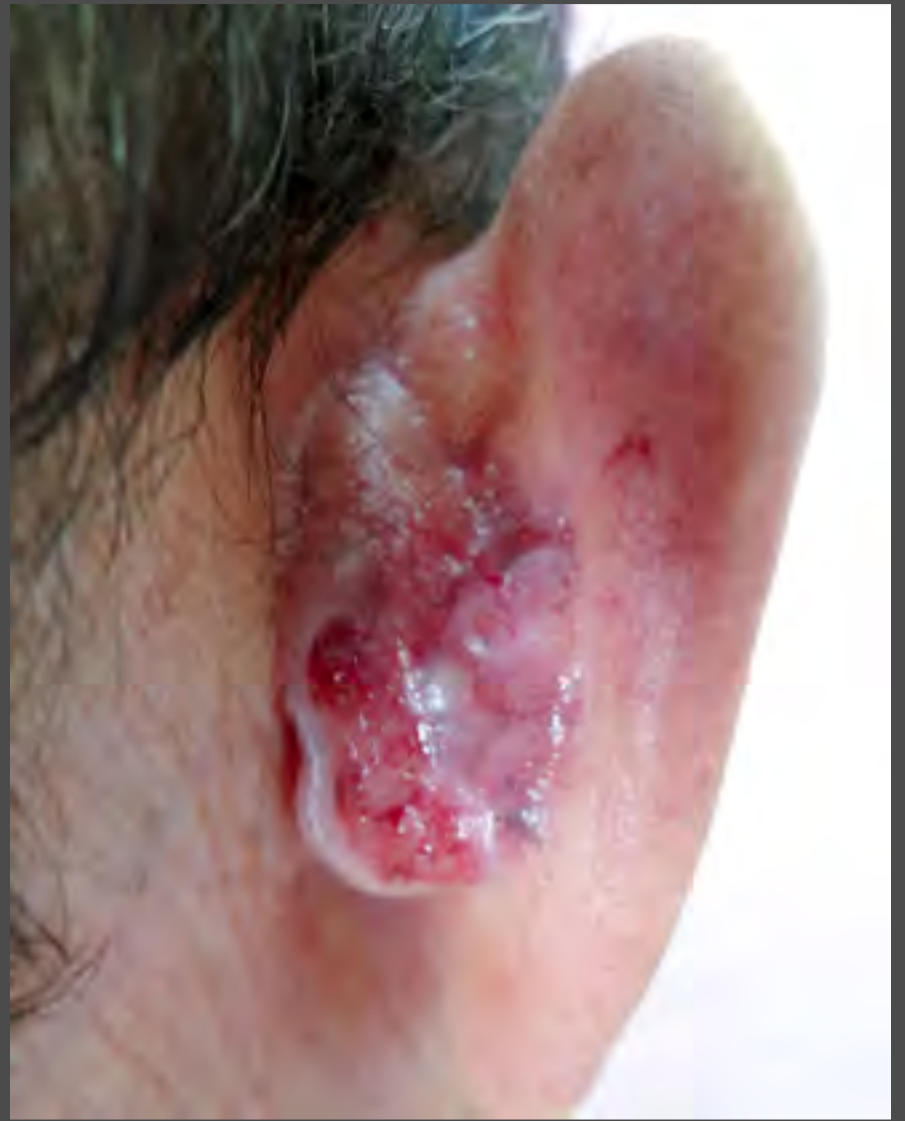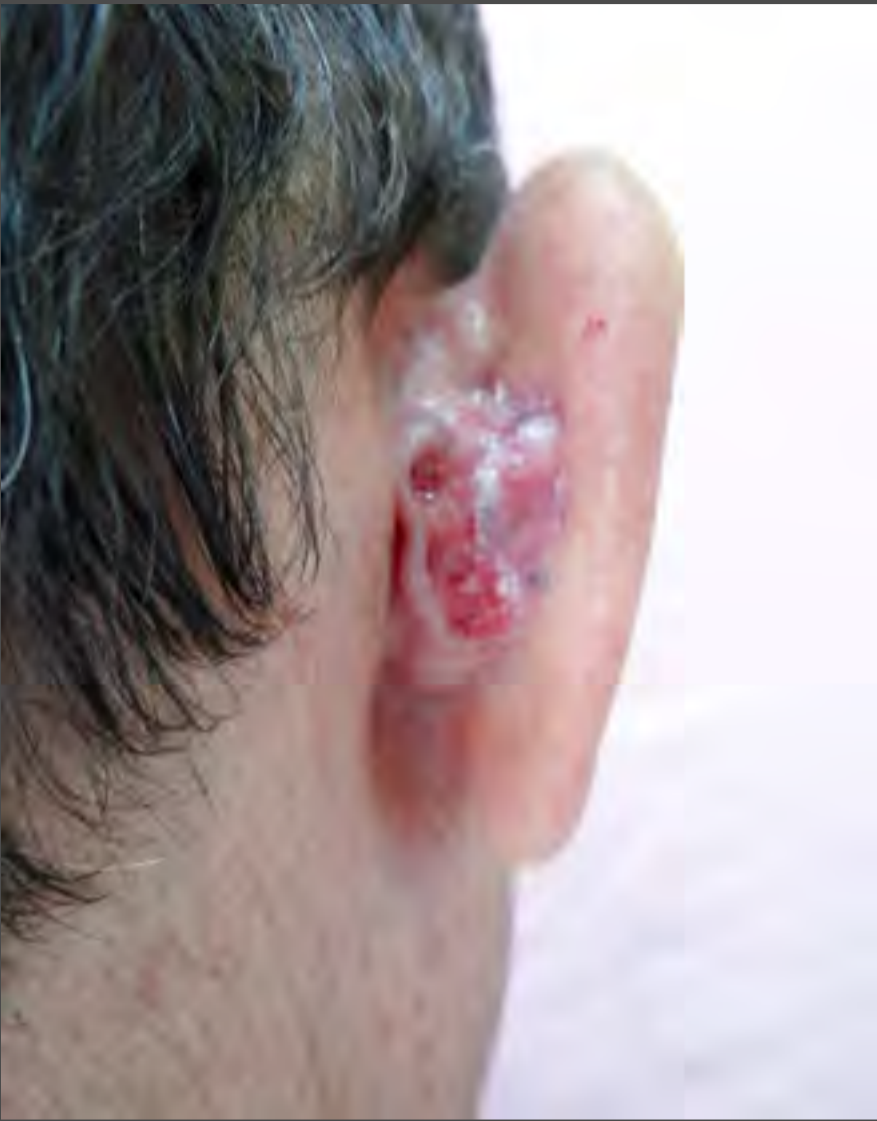Superficial lesion, resembling the recurrence of cutaneous leishmaniasis.



**Figure 3.308.**

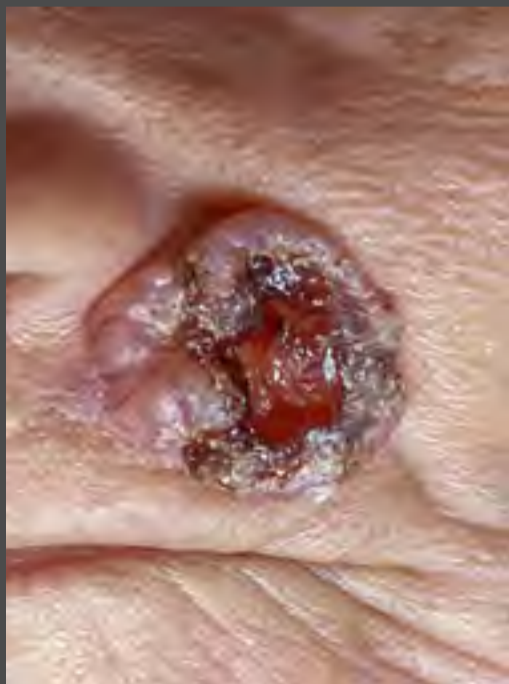The upper edge of this lesion on the abdomen is raised and cordoned and its lower half is flush with the skin. Histopathology confirmed the clinical suspicion.

## Basal cell carcinoma

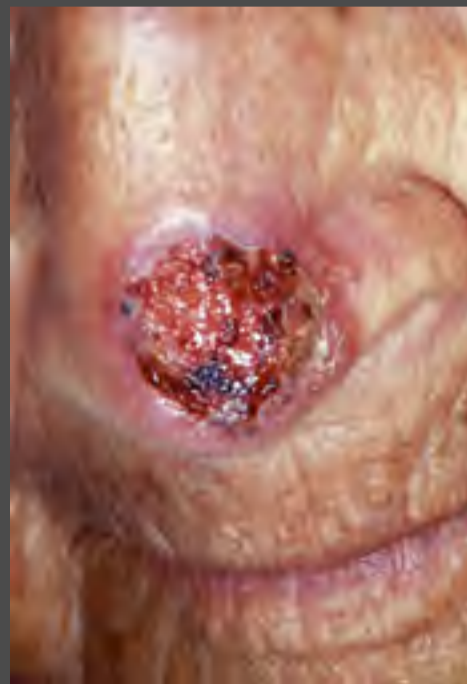

**Figures 3.309A and B.**

Ulcerated lesions on the posterior aspect of the ear, with pearly edges and proliferating papules with tortuous telangiectasias on the surface. In endemic areas, it is frequent for all lesions on the ears to be erroneously regarded as leishmaniasis.

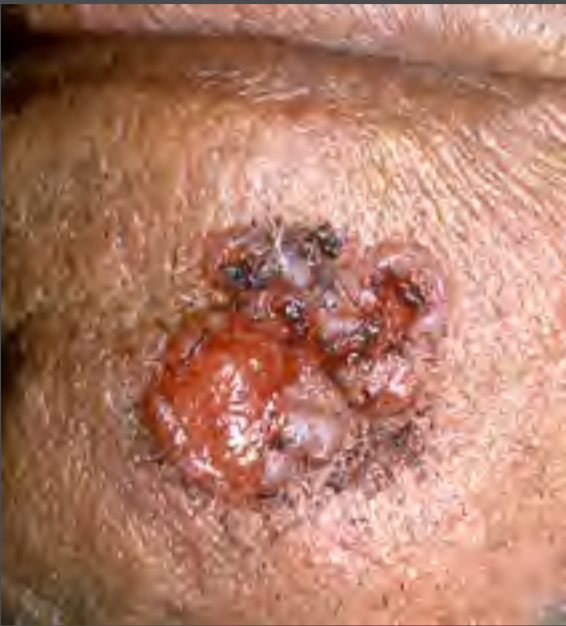

**Figure 3.310.**  
Basal cell carcinoma

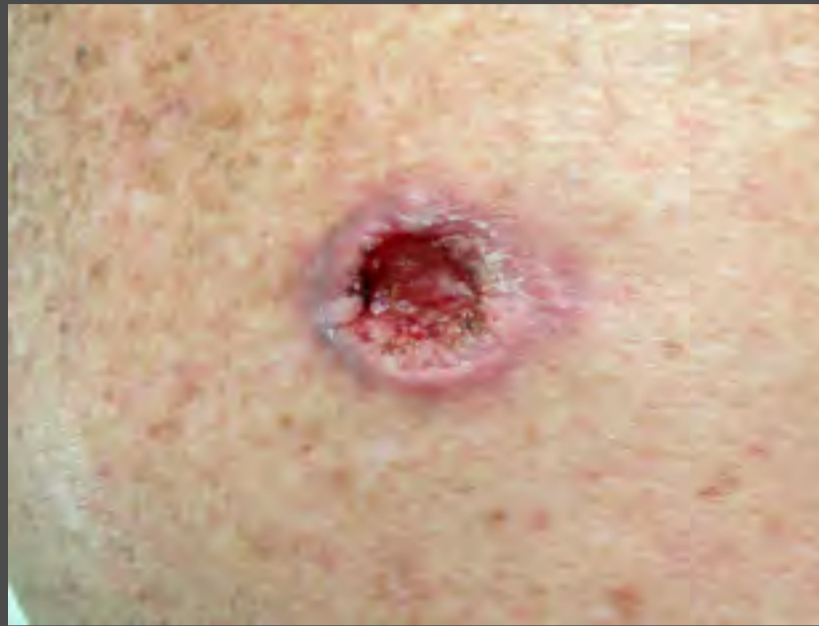

**Figure 3.311.**  
Basal cell carcinoma

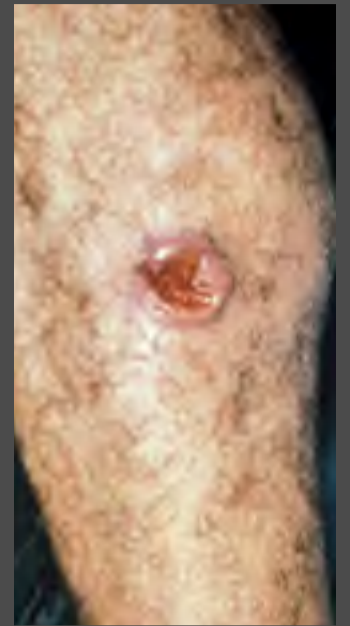## Basal cell carcinoma



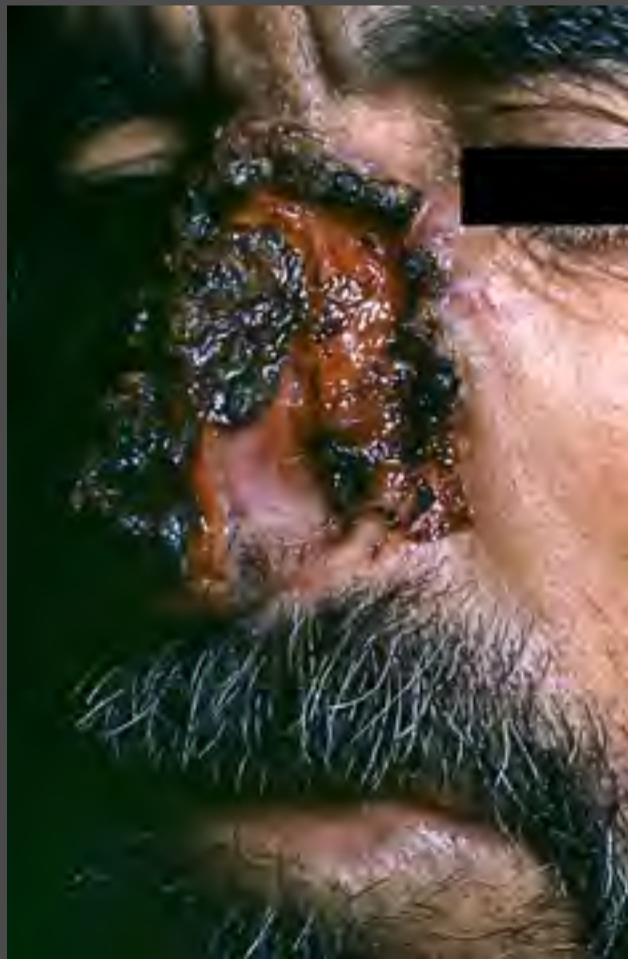**Figure 3.312.**  
Basal cell carcinoma



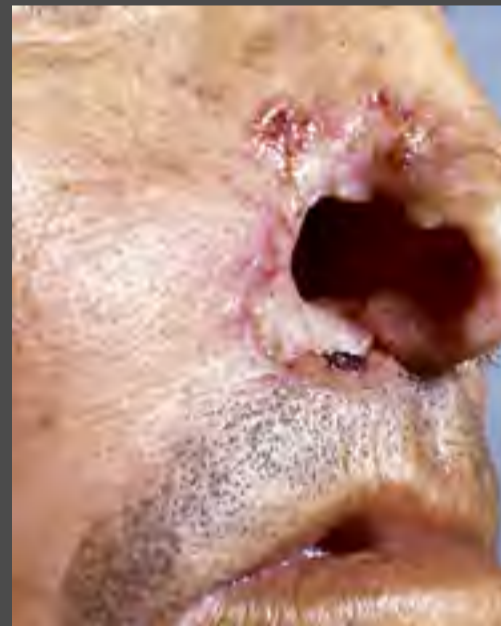**Figure 3.313.**  
Basal cell carcinoma



**Figure 3.314.**  
Porocarcinoma.  
Patient found in a leishmaniasis case-finding campaign

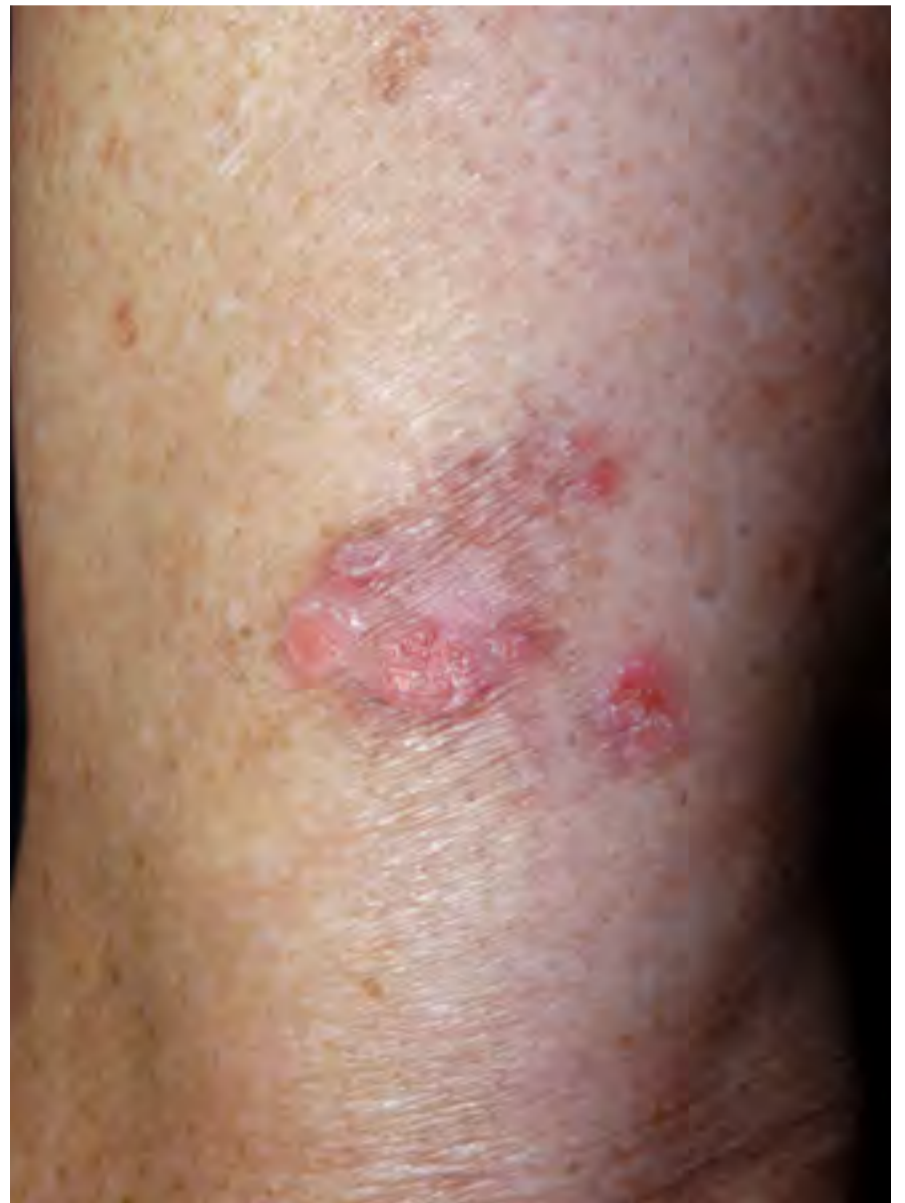
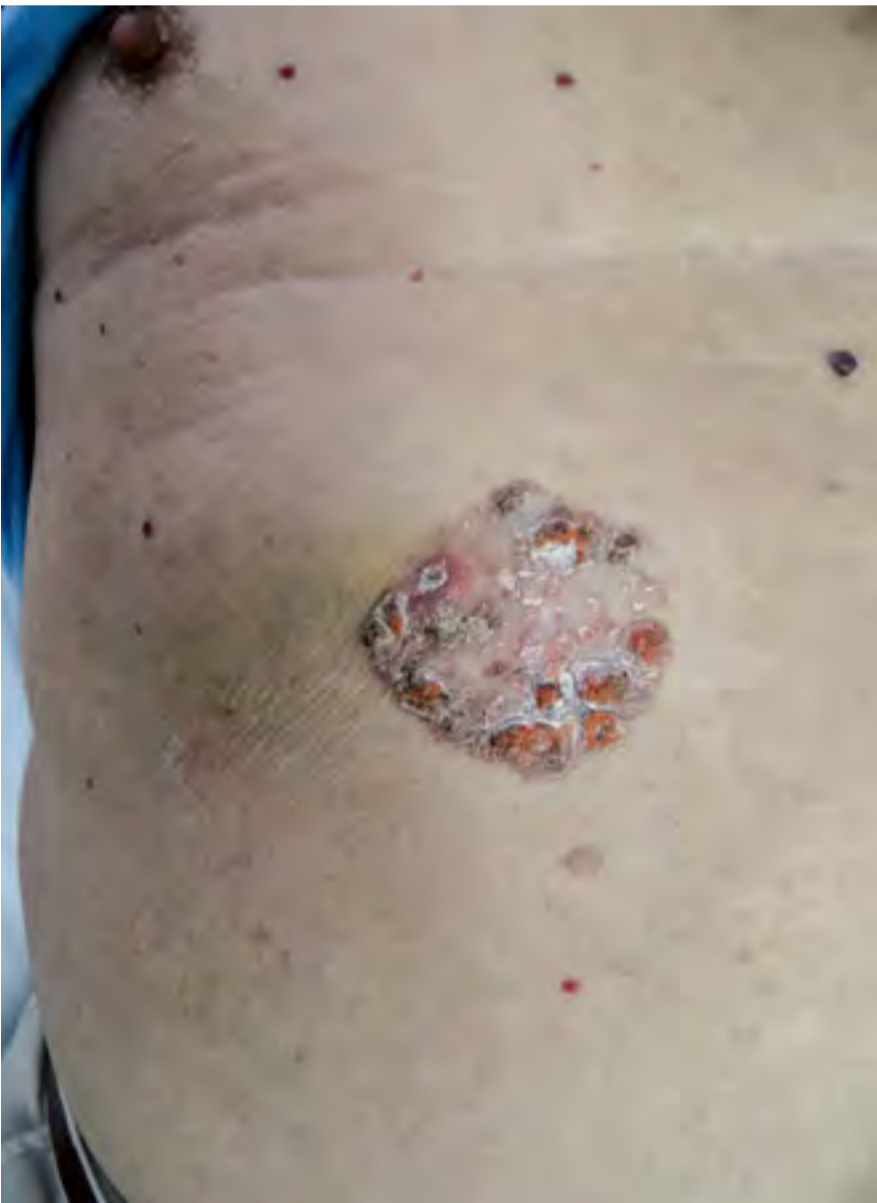
**Figure 3.315.**  
Basal cell carcinoma with  
extensive nasal destruction



**Figure 3.316.**  
Basal cell carcinoma with  
extensive nasal destruction

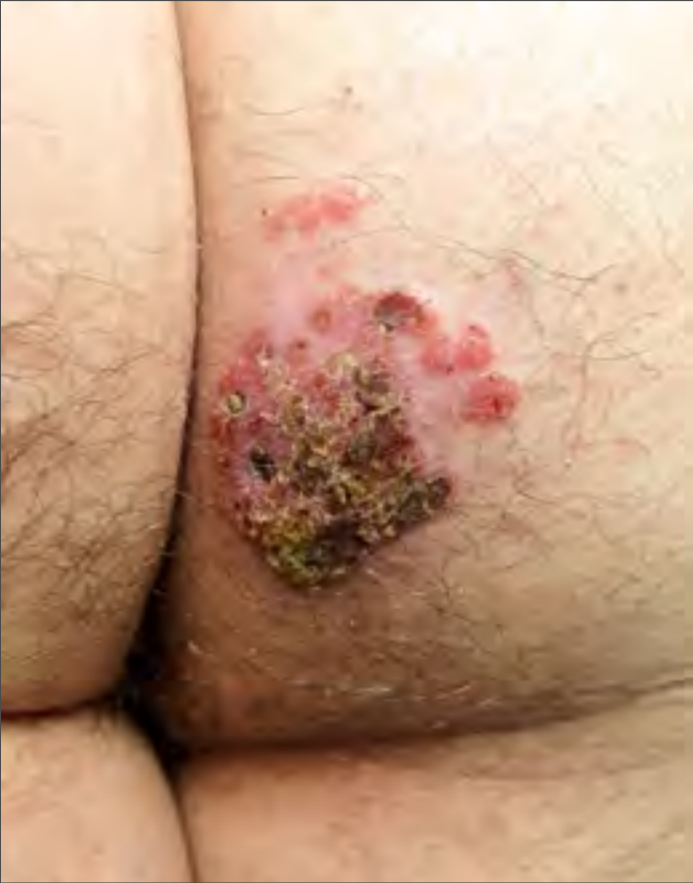***Squamous cell carcinoma.*** The lesion is located in areas exposed to the sun and occurs most often in people with light skin, eyes, and hair. The ulcer can develop over months or up to one or two years, with a history of a crusty, reddish, and irritated plaque. The ulcer is irregularly shaped and has anfractuous edges, with an exuberant, fast-growing proliferative center (*Figures 3.317 a 3.329*).



**Figures 3.317A and B.**

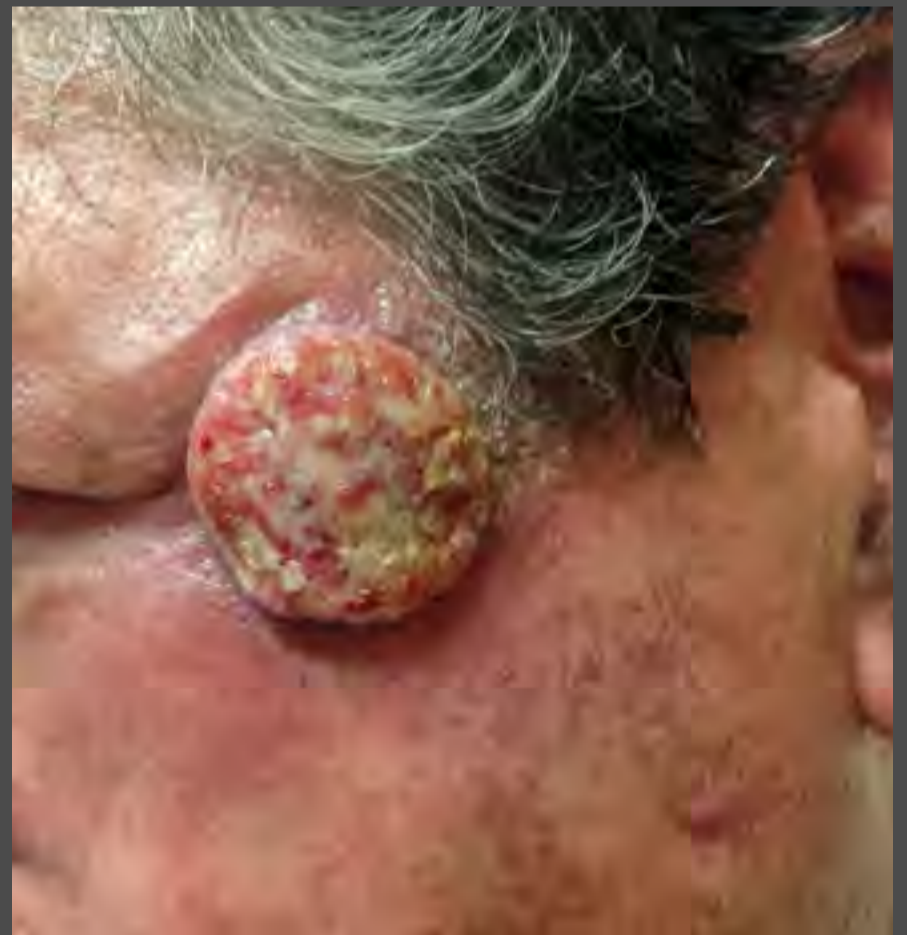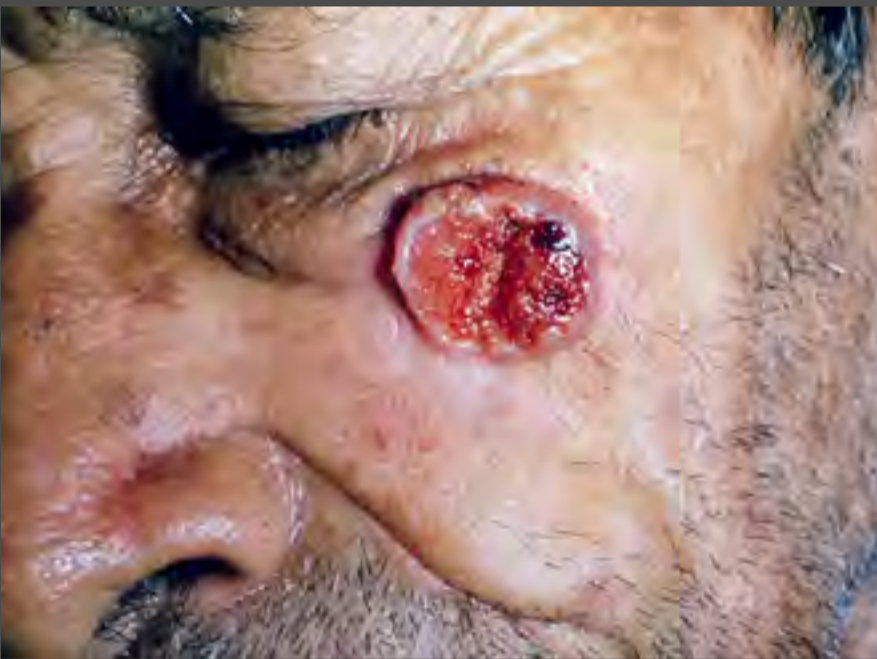Bowen's disease. This squamous cell carcinoma in situ may not progress for months or years. It consists of erythematous, non-infiltrated, hypochromic, or normochromic plaques, with active areas alternating with areas of apparently healthy skin and crusty skin. It can be confused with plaque leishmaniasis or with the relapsing or recurrent forms. Diagnosis is confirmed by histopathological examination.

## Squamous cell carcinoma - Bowen's disease

**Figure 3.318.**

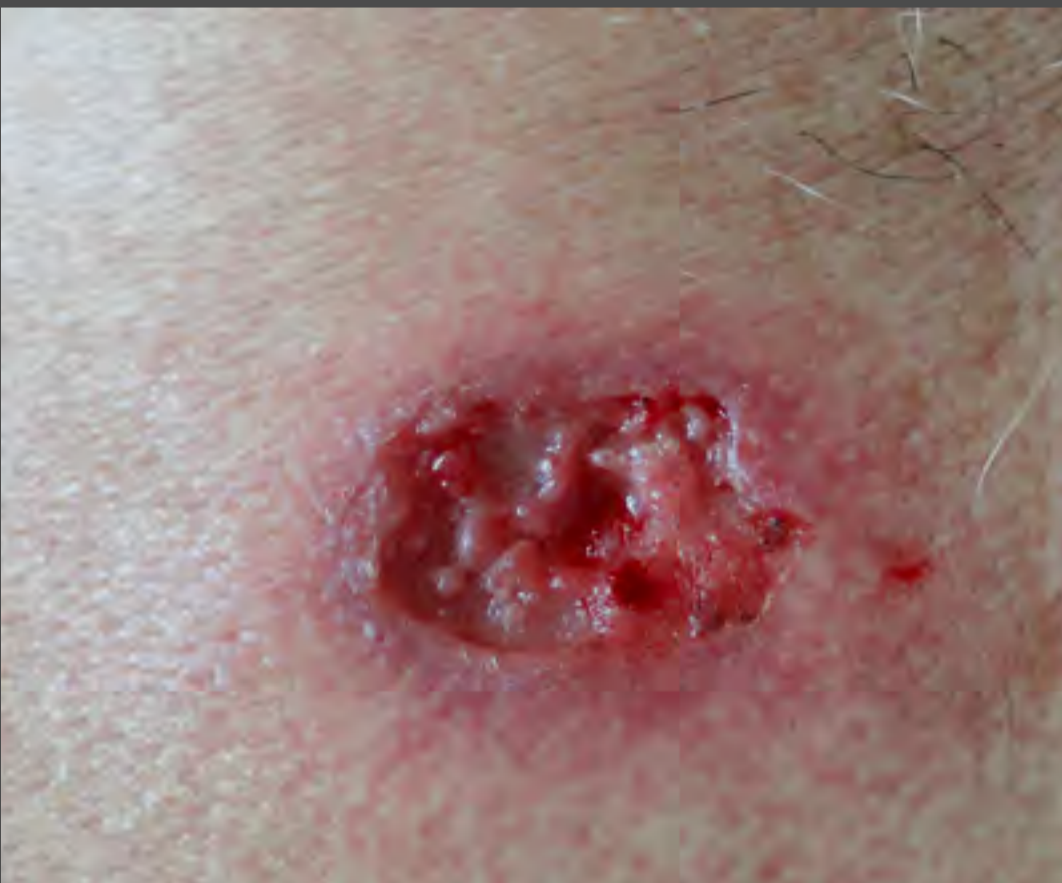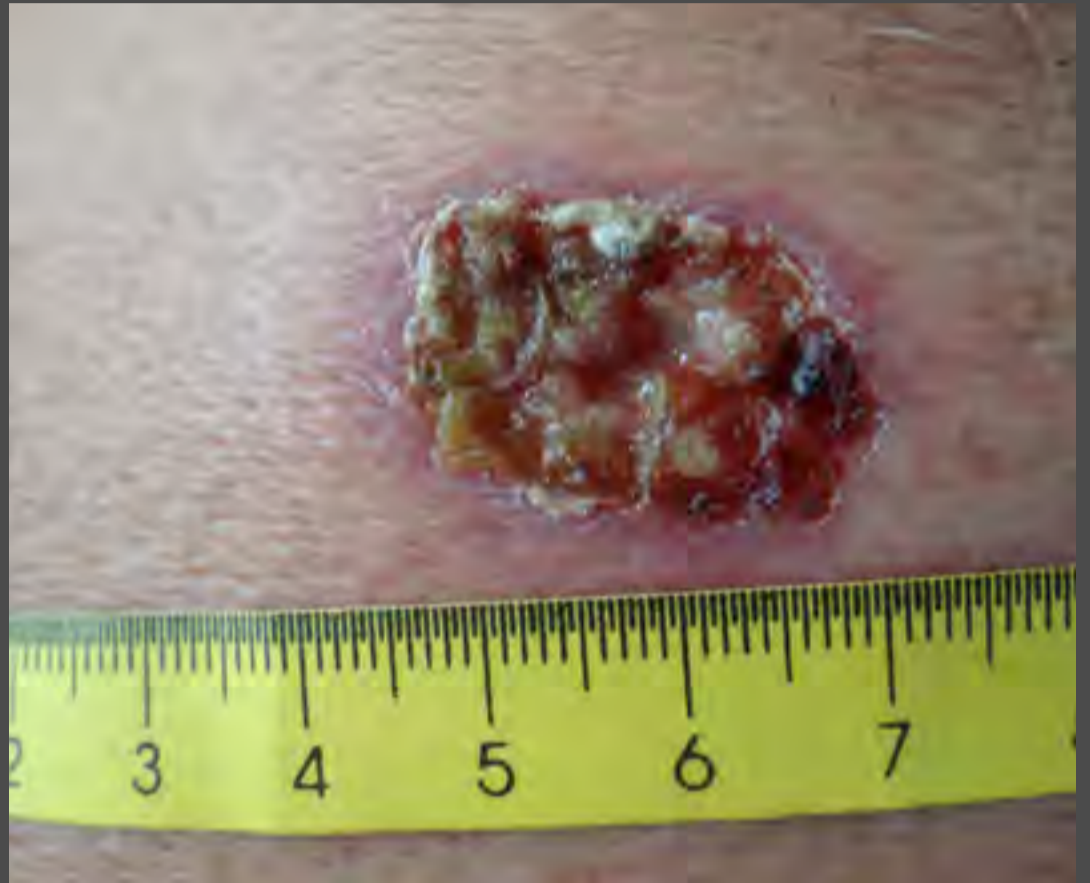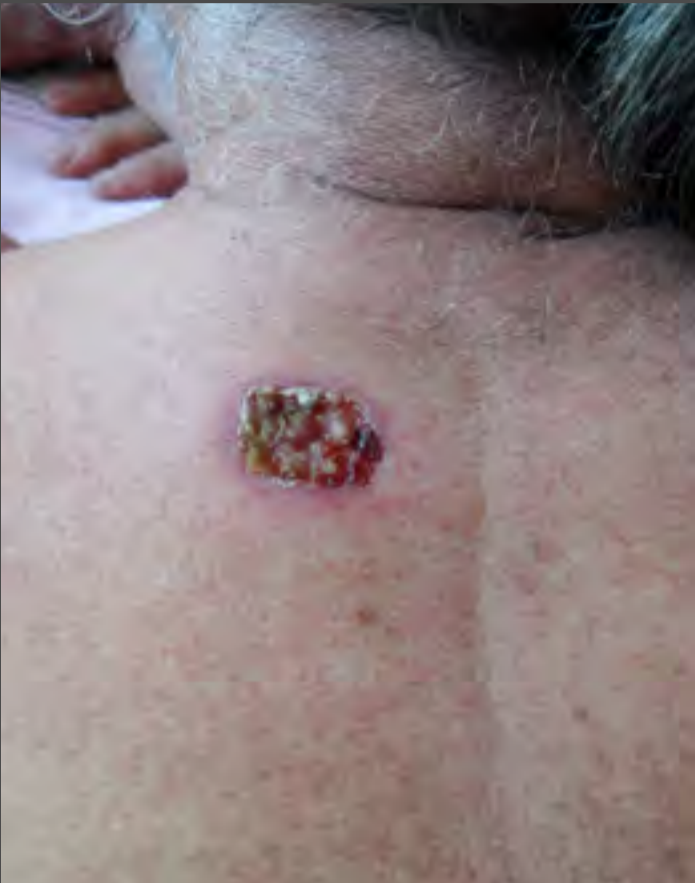Erythematous, crusted, infiltrated plaque, with clinical suspicion of cutaneous leishmaniasis

## Squamous Cell Carcinoma

**Figures 3.319A and B.**

Ulcerated carcinoma that resembles leishmaniasis

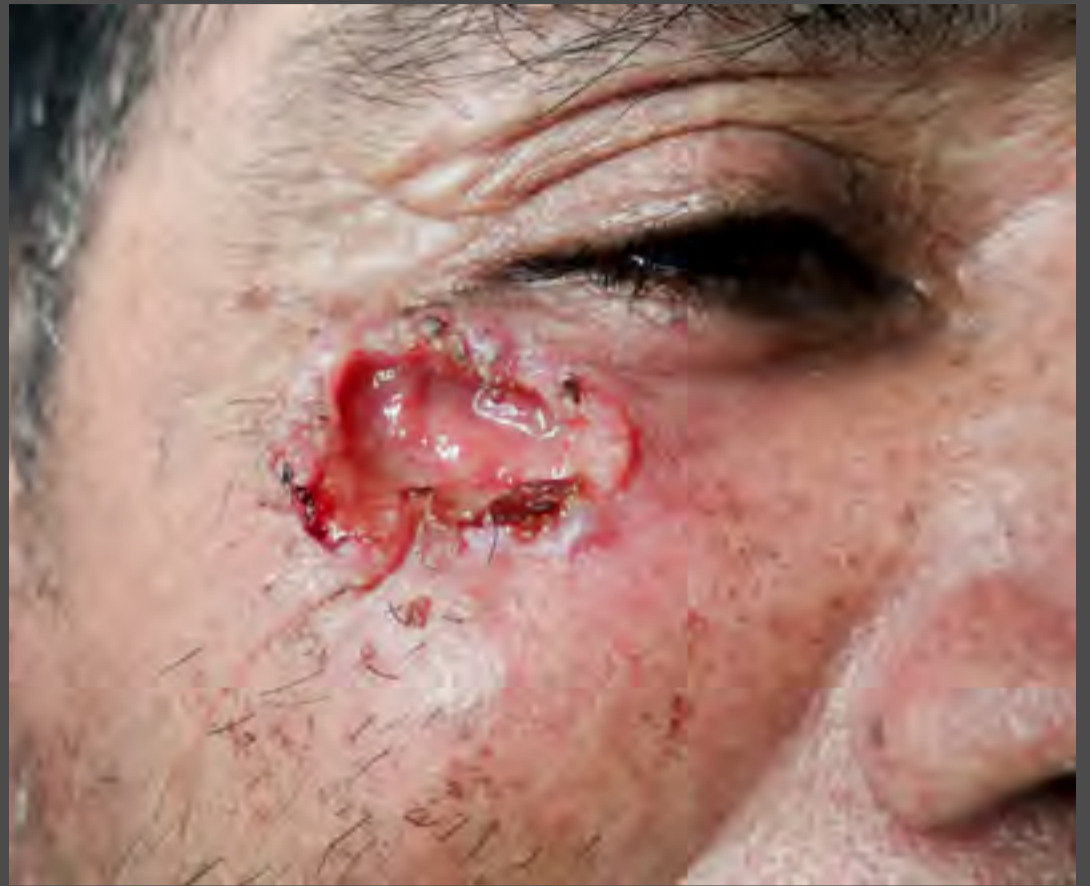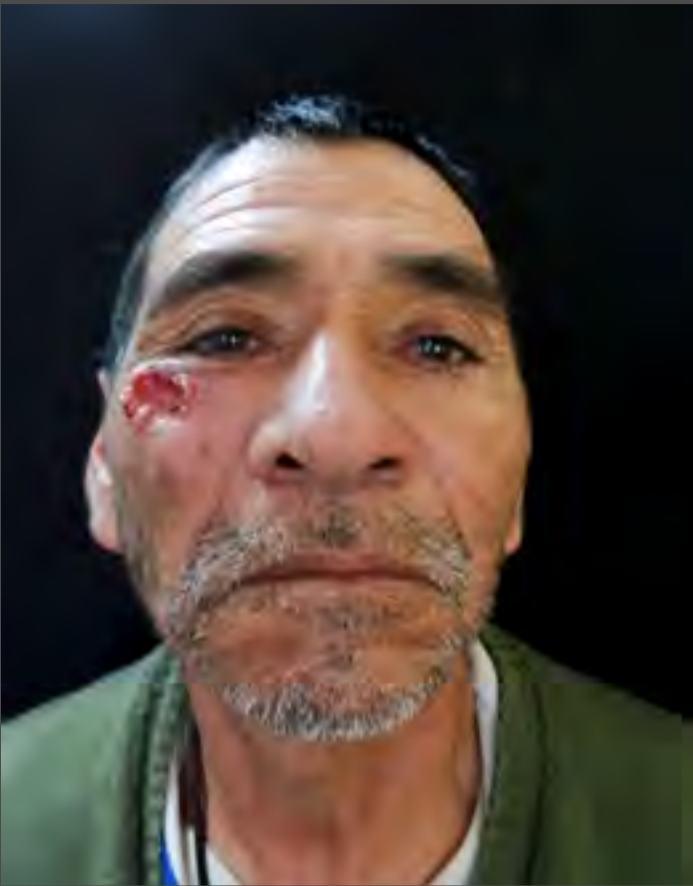## Squamous cell carcinoma



**Figures 3.320A, B and C.**

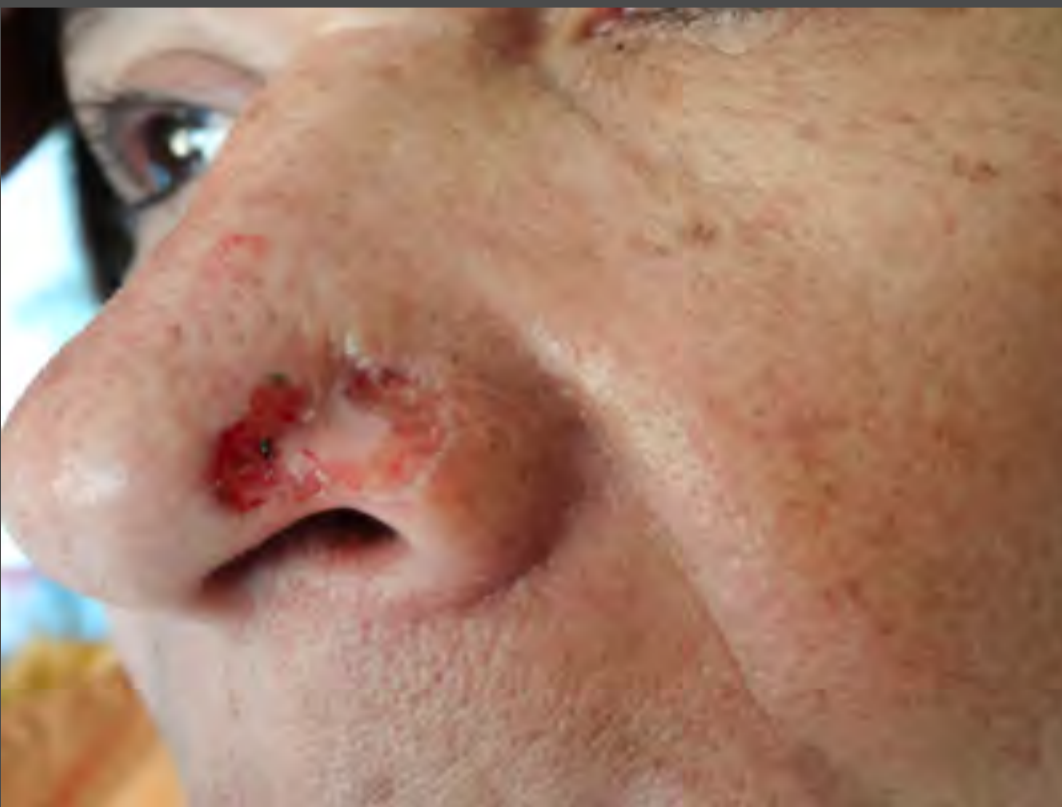Woman aged 54 years with a one-year-old asymptomatic lesion on the back. It is an irregular ulcer with sinuous edges, covered by a serosanguineous adherent crust that, when detached, reveals proliferative granular tissue in its center, with an appearance similar to pseudoepitheliomatous hyperplasia; slight frequent bleeding, even with minimal trauma, for example, scratching.

## Squamous cell carcinoma



**Figures 3.321A and B.**

Man aged 50 years with a lesion that started as a small wound that did not improve with topical drugs and, 14 months later, was a deep ulcer, with very irregular edges, dirty, and firmly adhered to the deep plane.

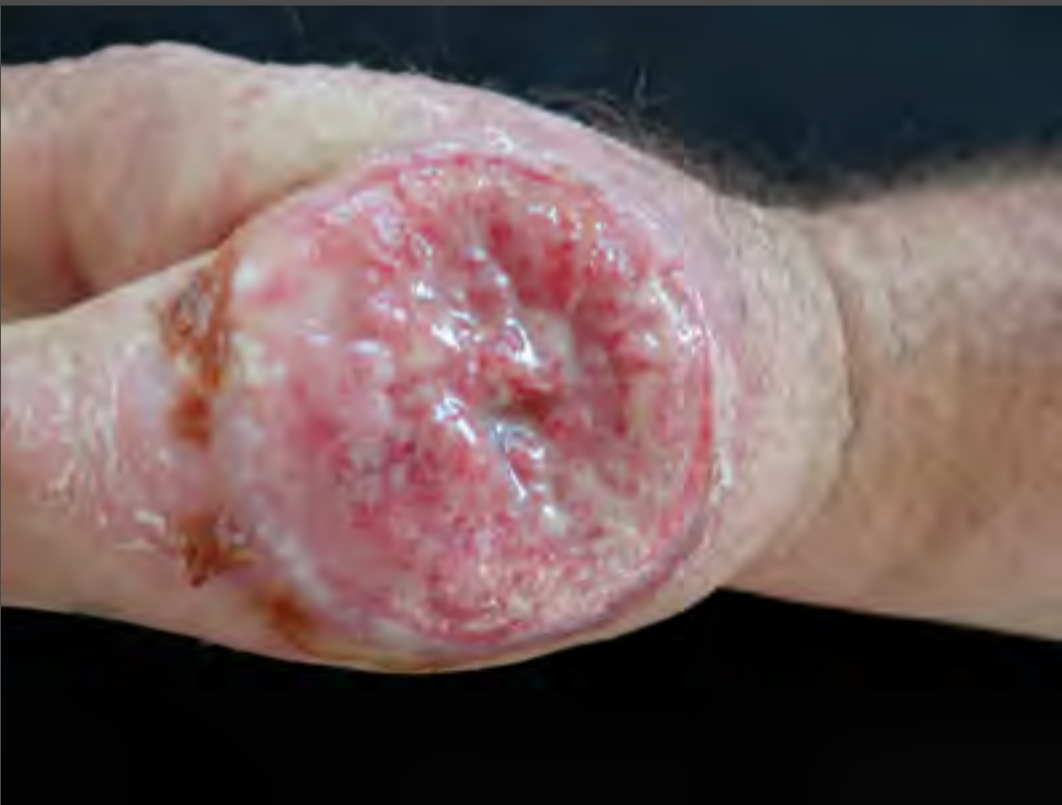
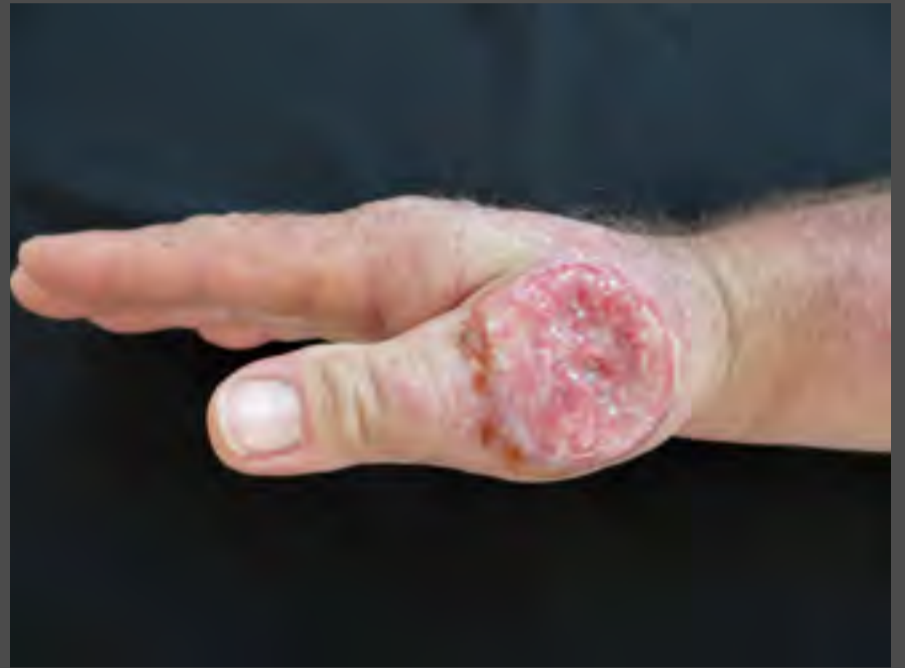
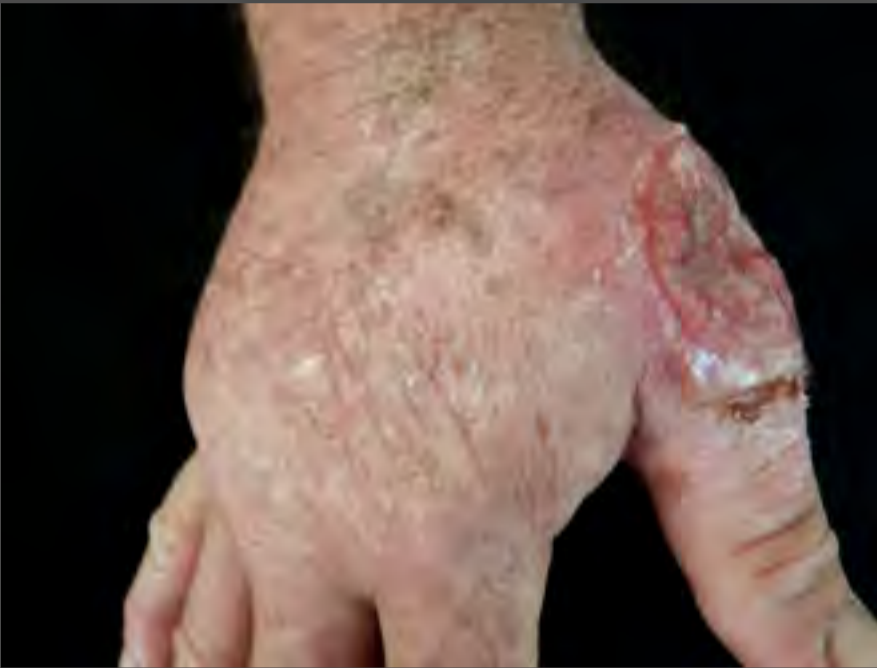**Figure 3.322.**

Woman aged 54 years with an 18-month-old irregular, infiltrated, hard, ulcerated plaque, on left nasal ala

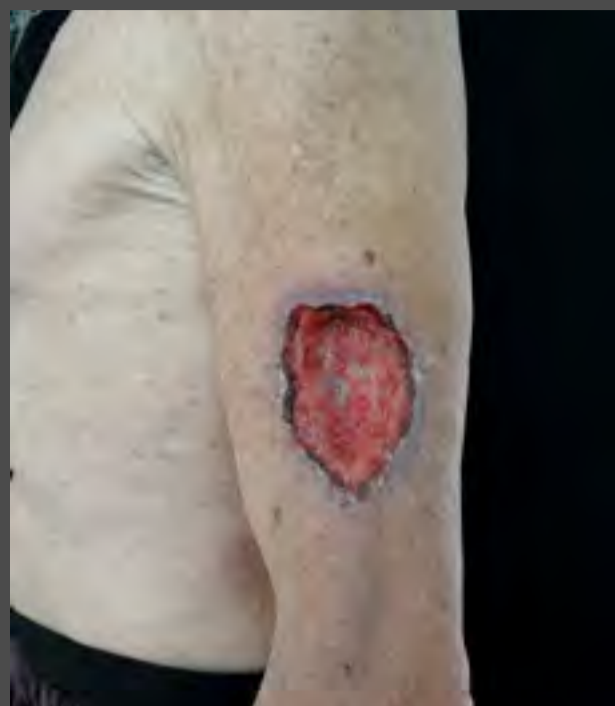
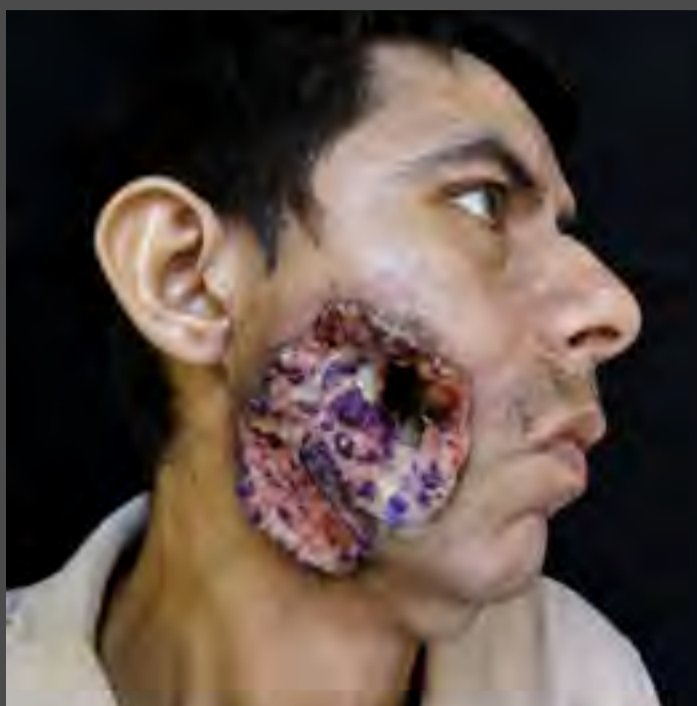
## Squamous cell carcinoma

**Figures 3.323A, B and C.**

Man aged 49 years with a six-month-old fast-growing ulcer on the back of the hand. It was a rounded ulcer, with regular edges; the center had exuberant granulation that was even higher than the surrounding skin in some areas. In Figure A, severe sun damage is evident; the biopsy confirmed the diagnosis of squamous cell carcinoma. The patient had received treatment with pentavalent antimonials due to clinical suspicion without parasitological verification.

## Squamous cell carcinoma

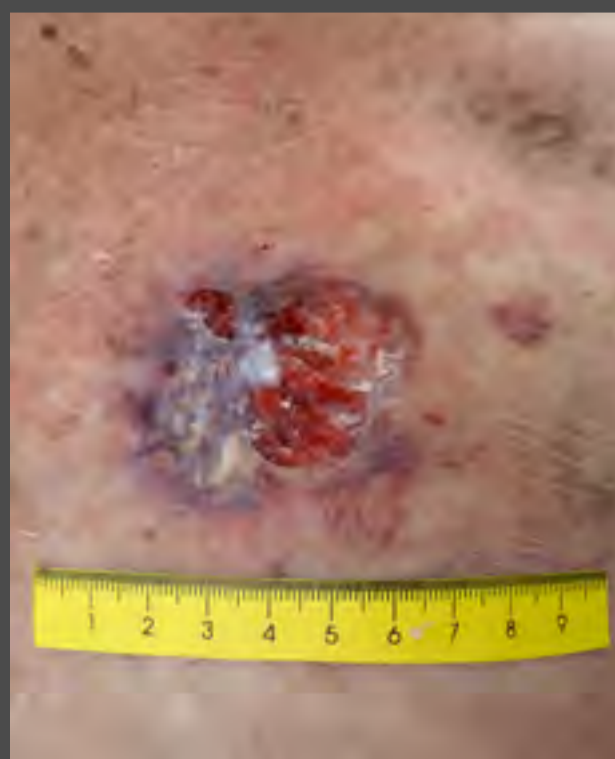
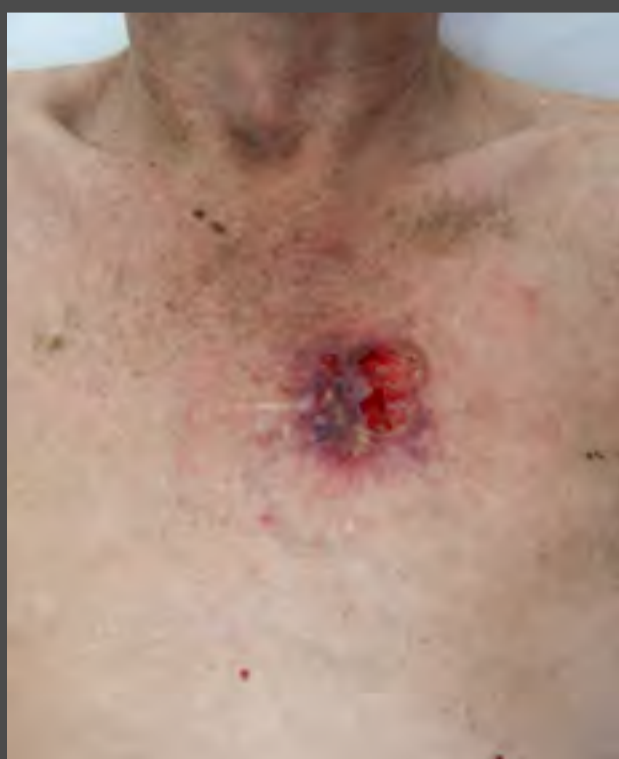
**Figure 3.324.**

Man aged 40 years with 11-month-old small asymptomatic plaque on the cheek, which then ulcerated and grew rapidly. He received multiple treatments, even electrofulguration after the ulceration, and, on direct examination, amastigotes were observed. Numerous hard, indurated, and immobile adenopathies were found in the neck. The biopsy confirmed carcinoma.

**Figure 3.325.**

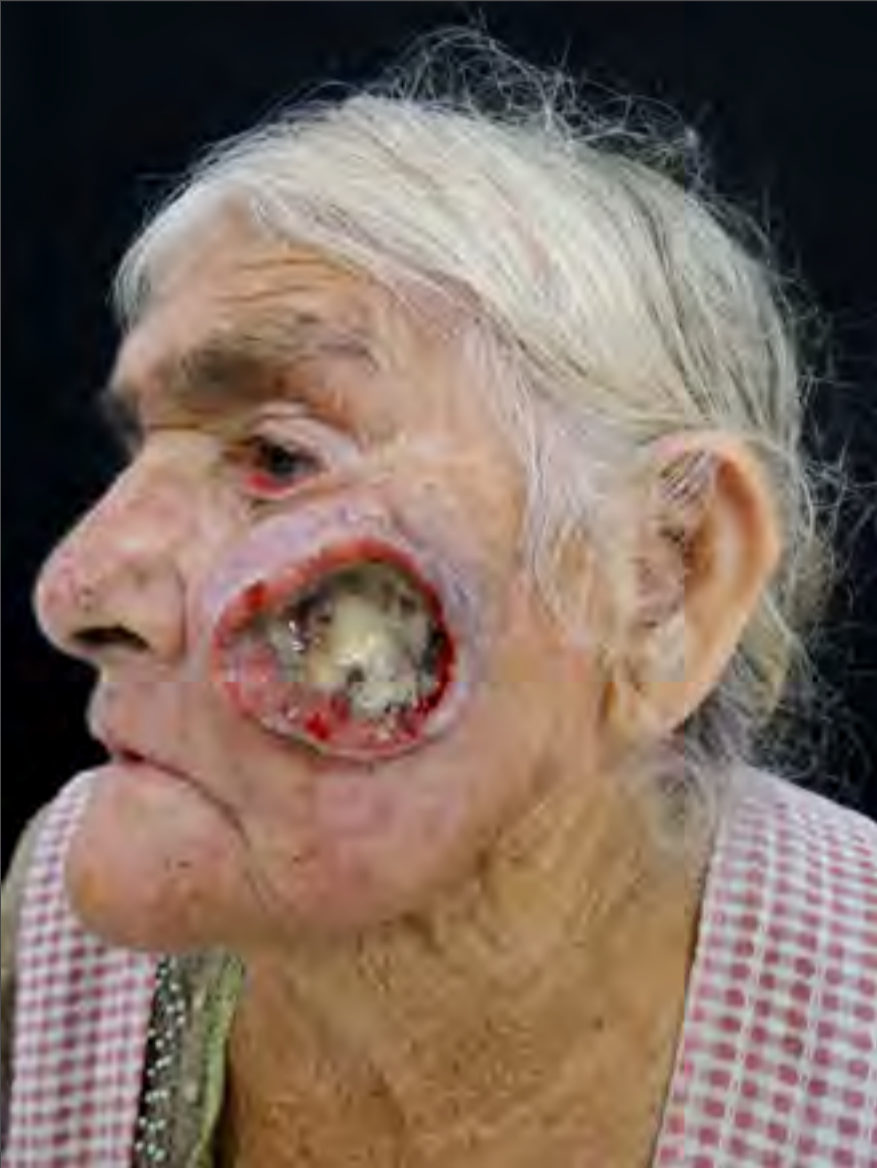Man aged 82 years with an eight-year-old, slow-growing asymptomatic lesion, with an irregularly-shaped ulcer with a somewhat tortuous edge, considerable infiltration, and fixation to deep planes



**Figures 3.326A and B.**

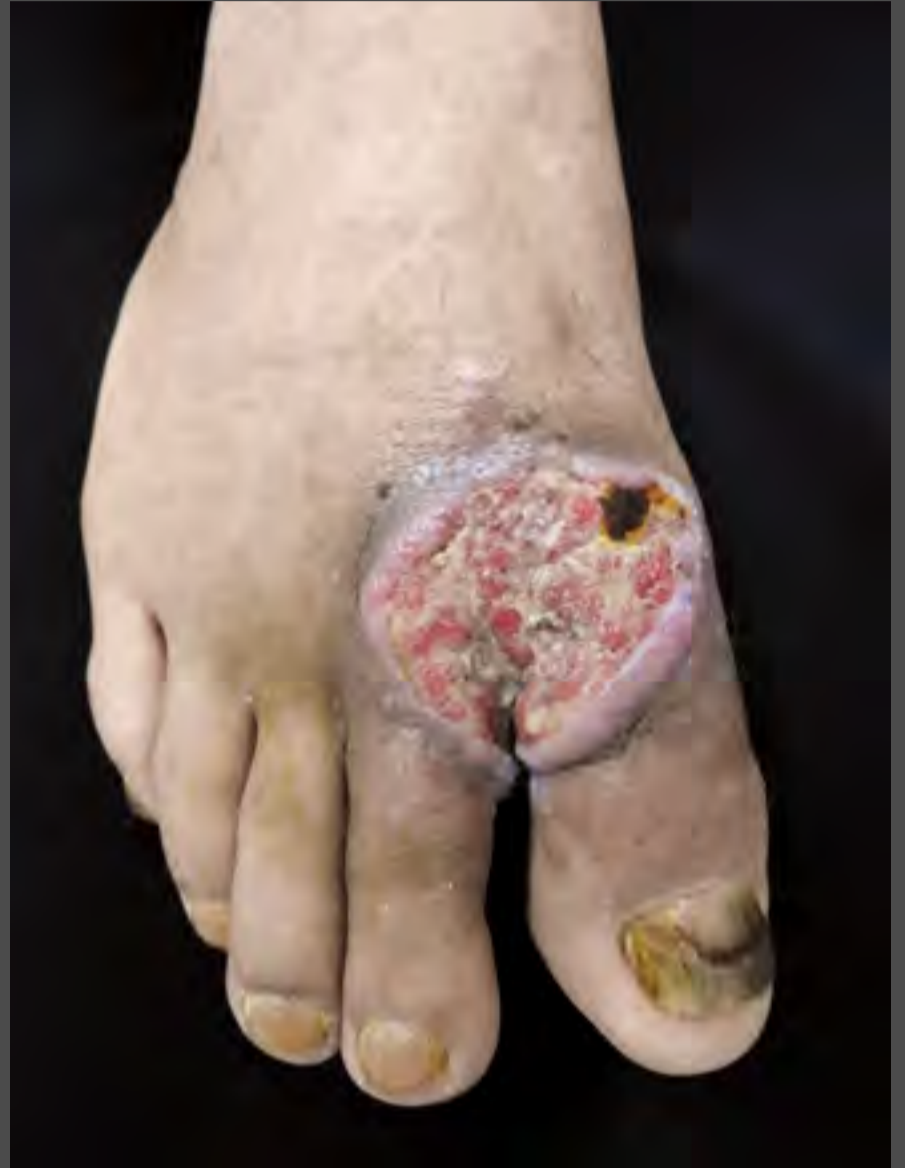Man aged 52 years with 19-month-old lesion on the edge of the "V" of his neckline. It is an irregular, infiltrated plaque, 6 cm in diameter, with two irregular ulcerated areas and evident adjacent sun damage.

## Squamous cell carcinoma



**Figure 3.327.**

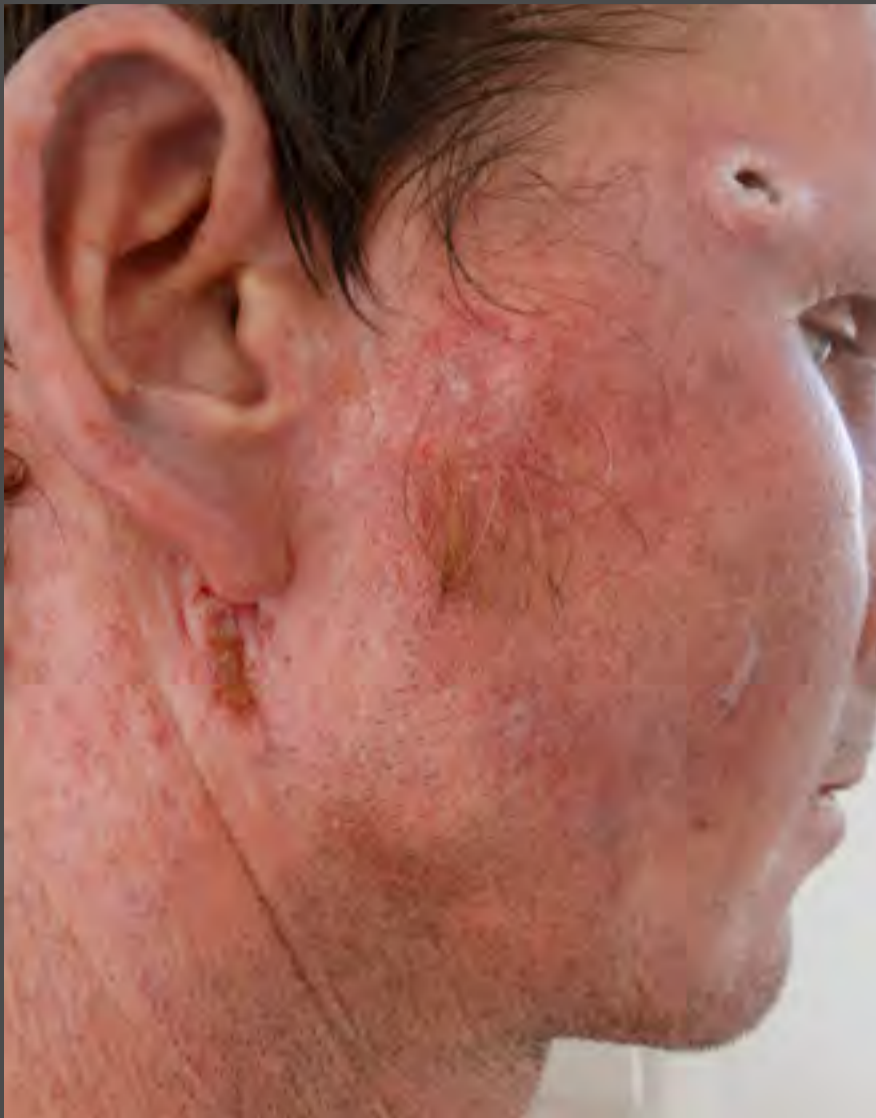Woman aged 79 years with phototype II skin and a one-year-old lesion 7 cm in diameter on the cheek. It is a rounded well-defined ulcer with distinct, raised edges, surrounded by infiltration, a deep dirty center covered with fibrinous purulent membranes, and it bleeds easily. No cervical adenopathies were apparent. The biopsy confirmed carcinoma.



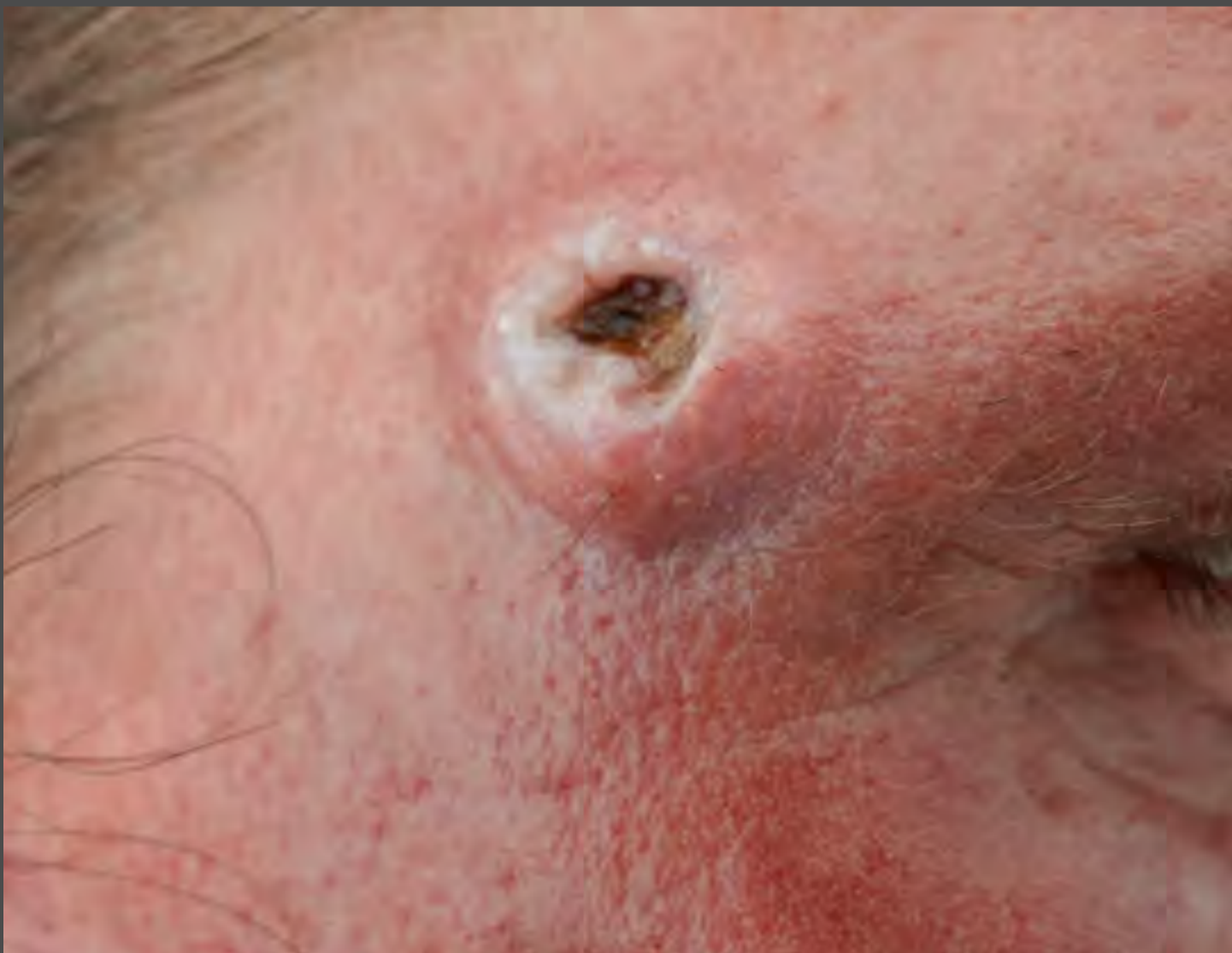**Figure 3.328.**

Man aged 57 years with an 18-month-old asymptomatic lesion, which began as a small papule and developed into a round ulcer, with a granular floor and raised, cordoned edges. He came from an endemic area and was treated for leishmaniasis. The lack of improvement and exuberance of the granulation tissue suggested a proliferative lesion, which was confirmed through biopsy.

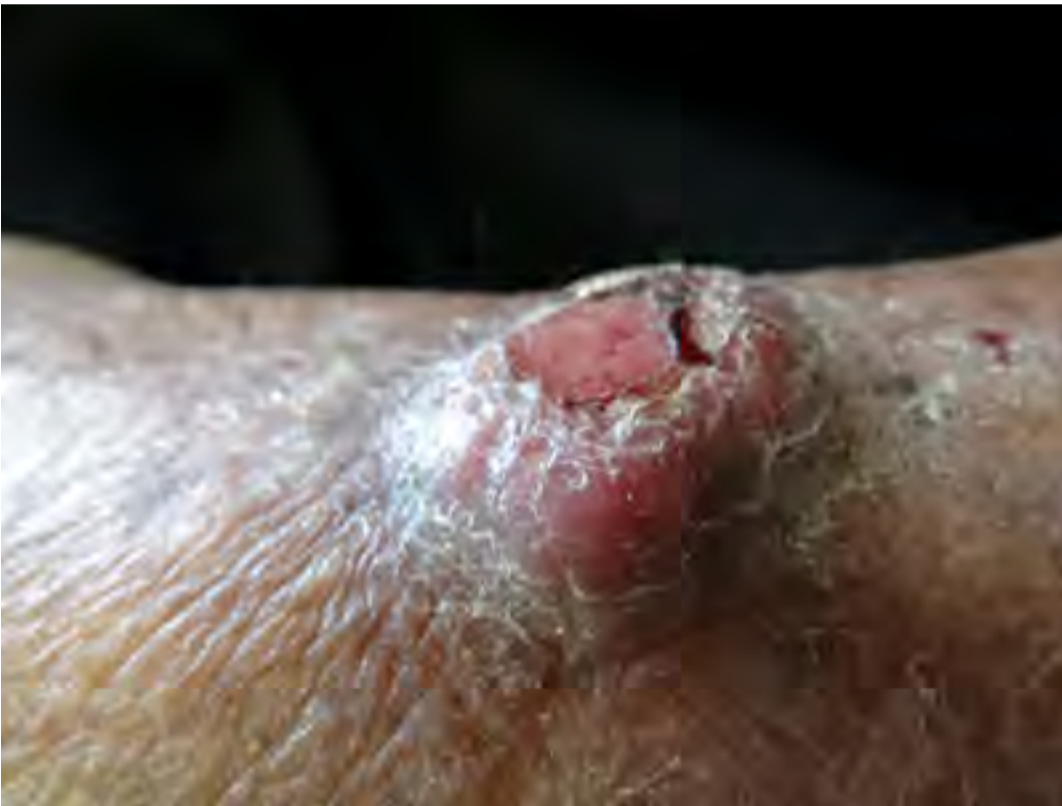## Squamous cell carcinoma



**Figures 3.329A and B.** Man aged 44 years with a nine-month-old lesion; an ulcerated and crateriform lump. Extensive sun damage on phototype II skin is evident in the photo.

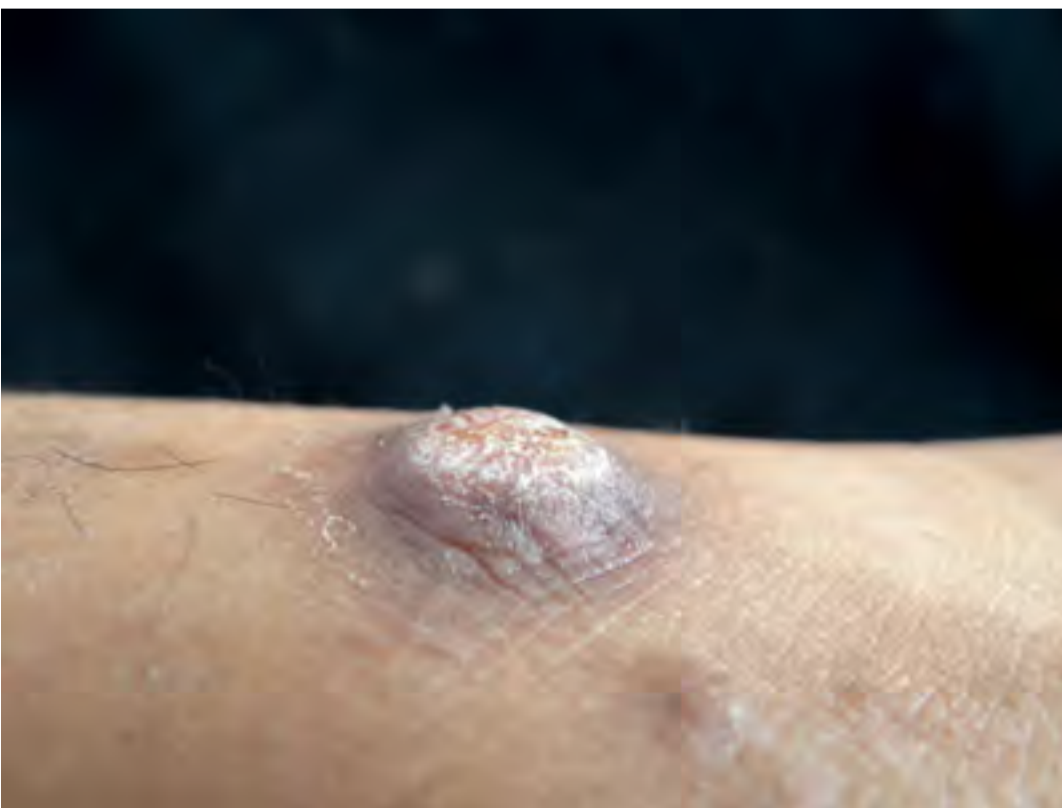

***Keratoacanthoma.*** This is a less aggressive form of fast-growing squamous cell carcinoma—weeks or months—that forms a thick, raised-edge tumor with an ulcerated center covered with a keratin crust (*Figures 3.330 to 3.333*). It usually occurs on the exposed areas of people with light skin, hair, and eyes.

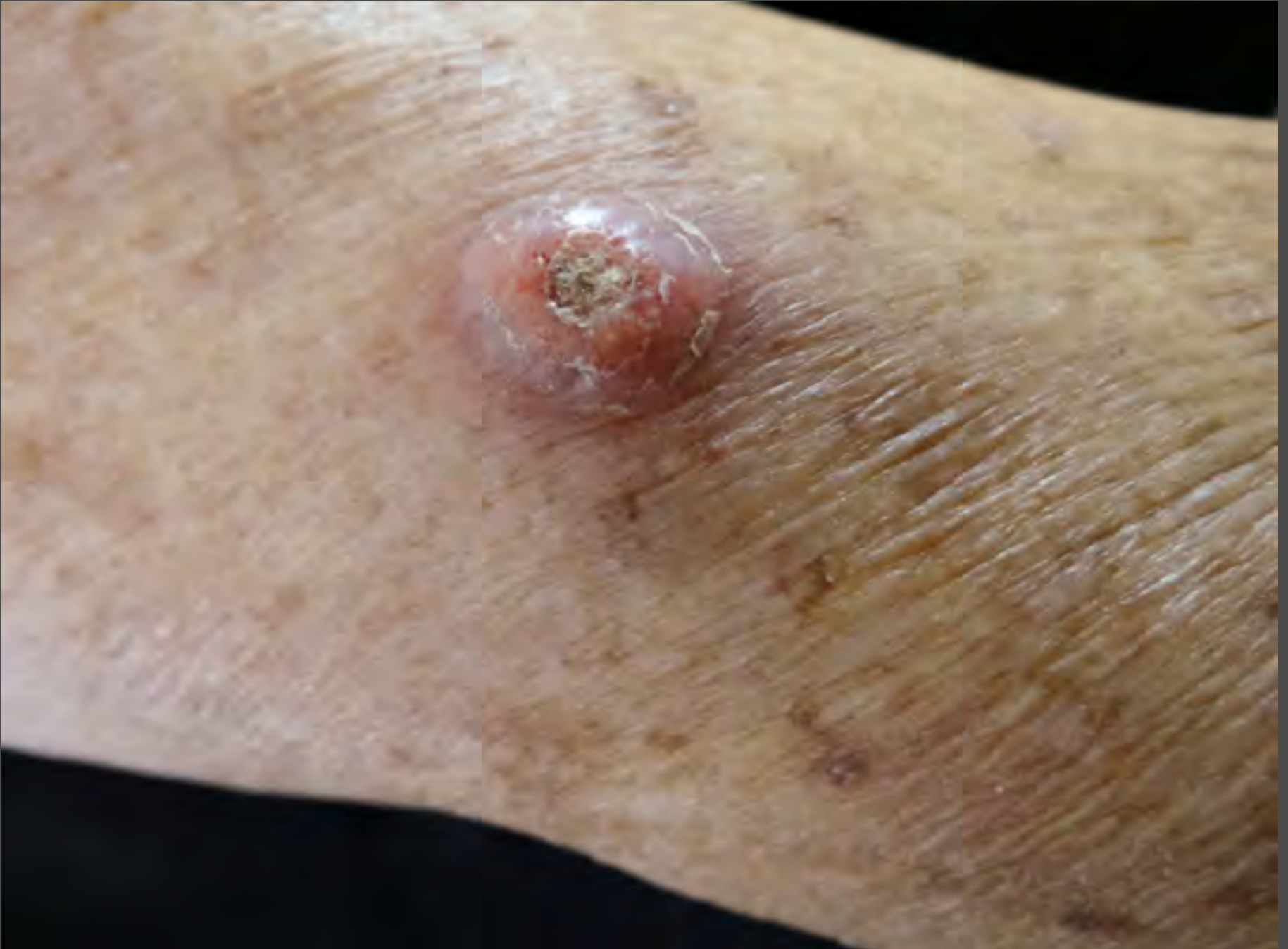

**Figures 3.330A and B.**

Figure A is a man aged 62 years with a two-month-old asymptomatic lesion on the forearm. It is a lump 2.5 cm in diameter, with raised, distinct edges and depressed center, covered by a keratin plug. The diagnosis was confirmed by histopathology. Figure B is of a similar lesion. The keratoacanthoma is an anaplastic, histologically malignant lesion, but it is not biologically aggressive. It should be treated.



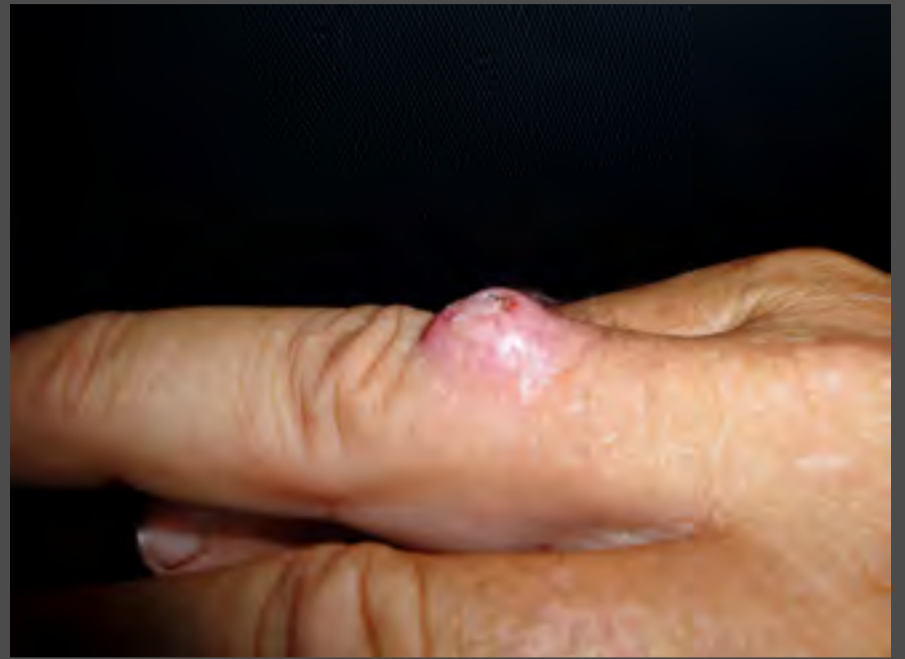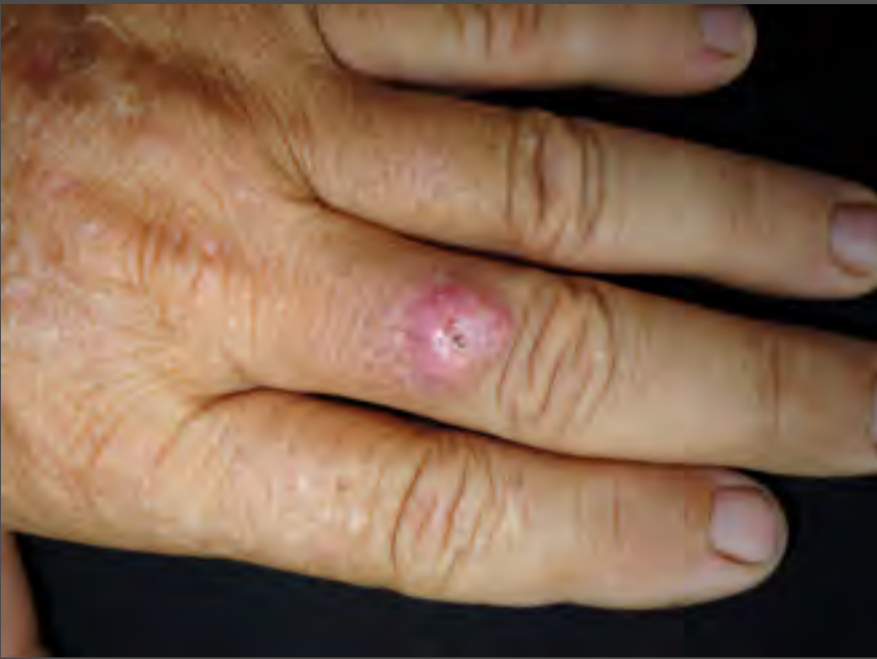## Keratoacanthoma



**Figure 3.331.**

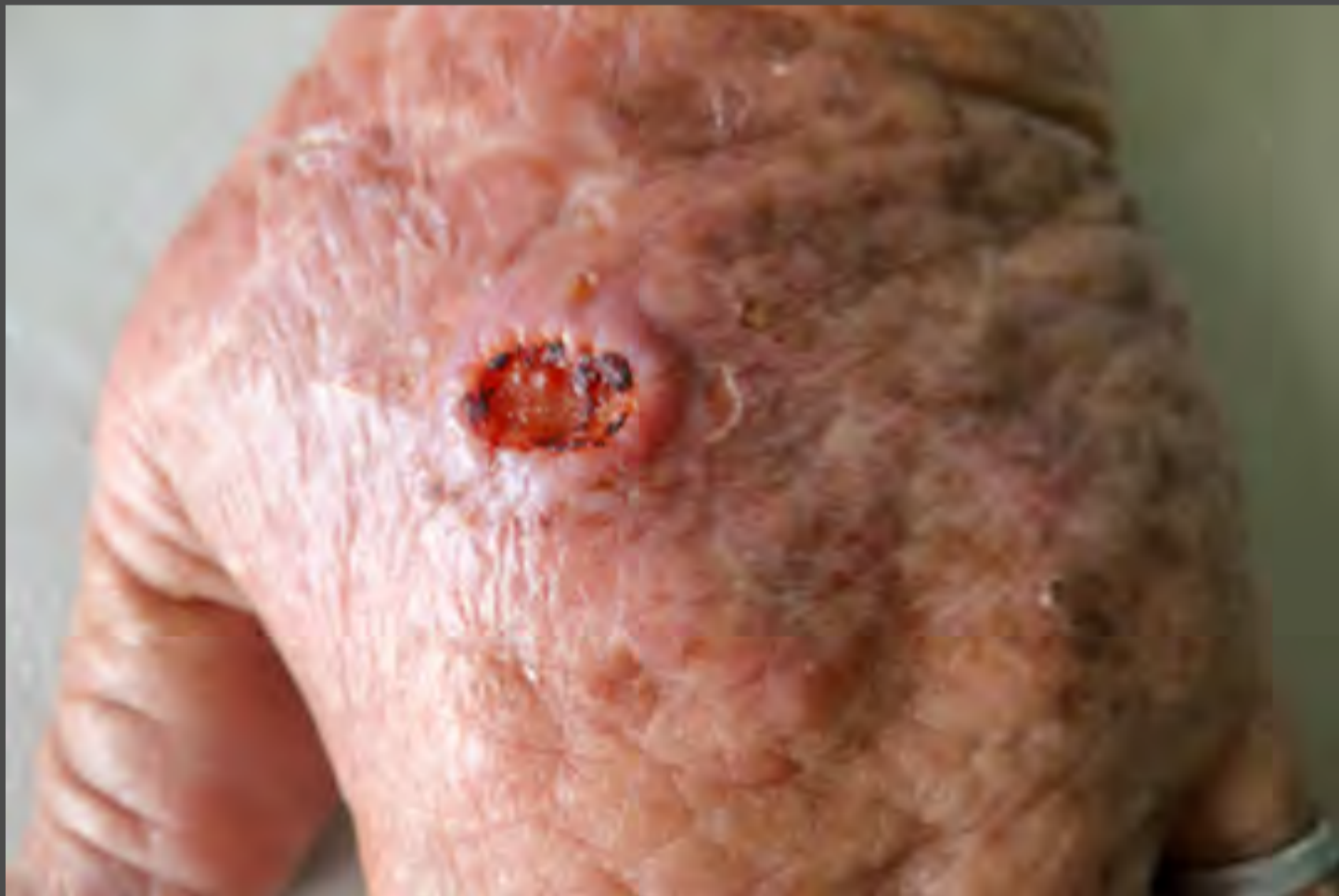Woman aged 72 years with a four-month-old raised lesion, with distinct well-defined edges, and a central crater covered by a keratin plug

## Keratoacanthoma



**Figures 3.332A and B.**

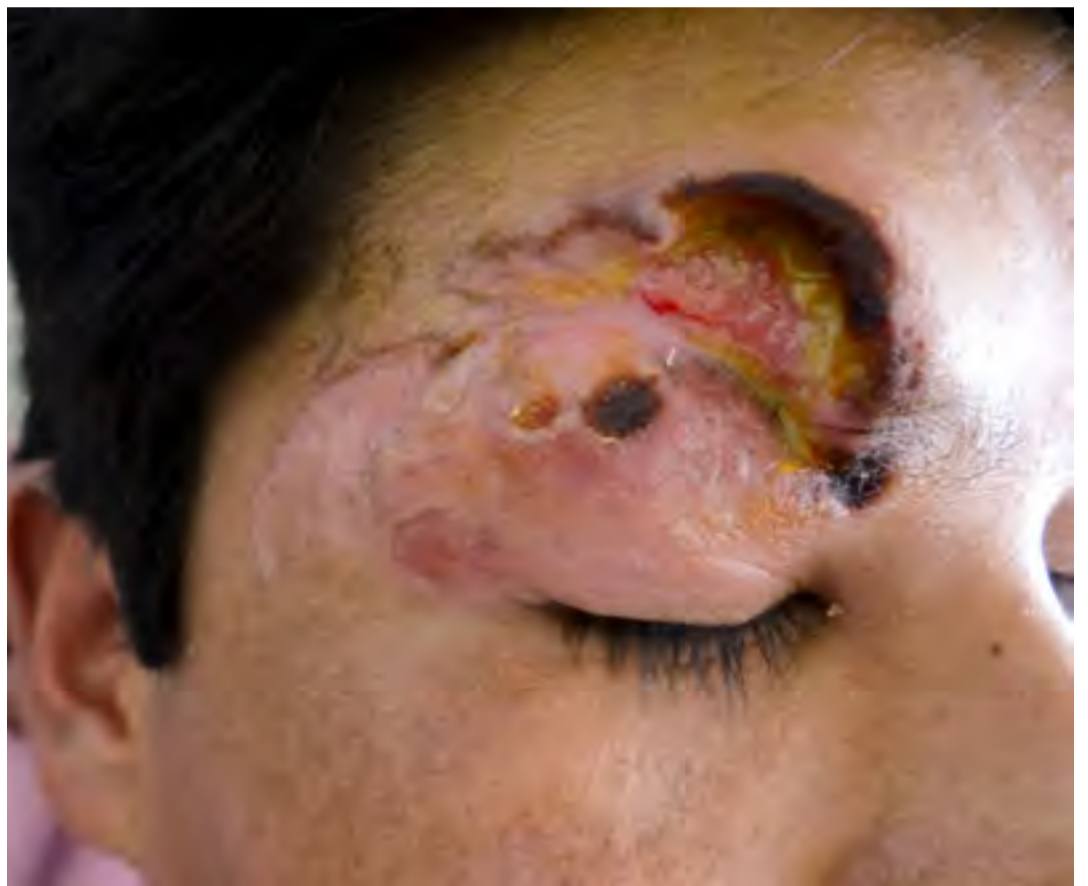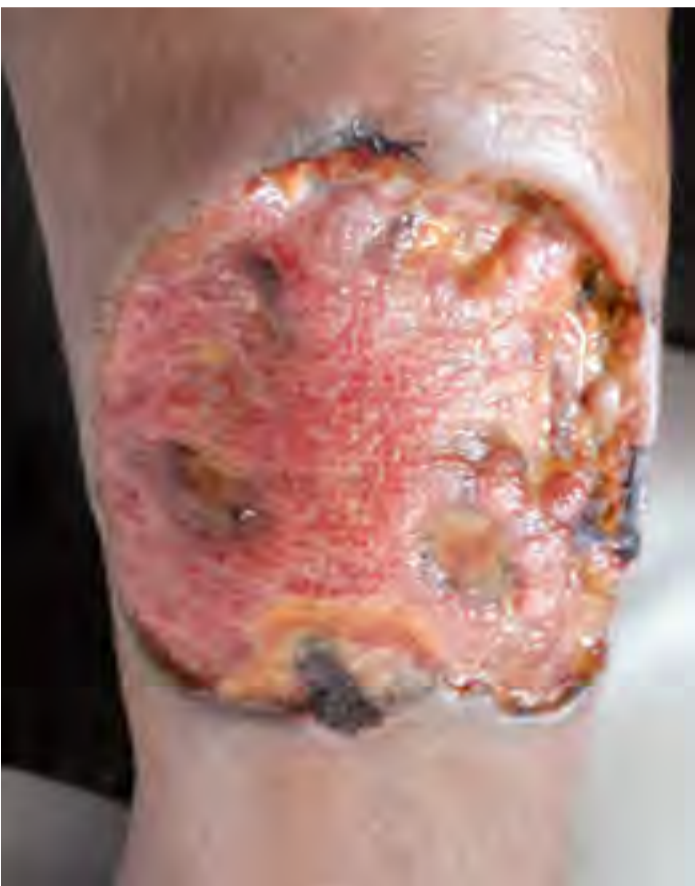Man aged 58 years with a two month old single lesion on the back of the hand. A lump 11 mm in diameter with distinct, raised edges and depressed center, but not ulcerated.



**Figure 3.333.**

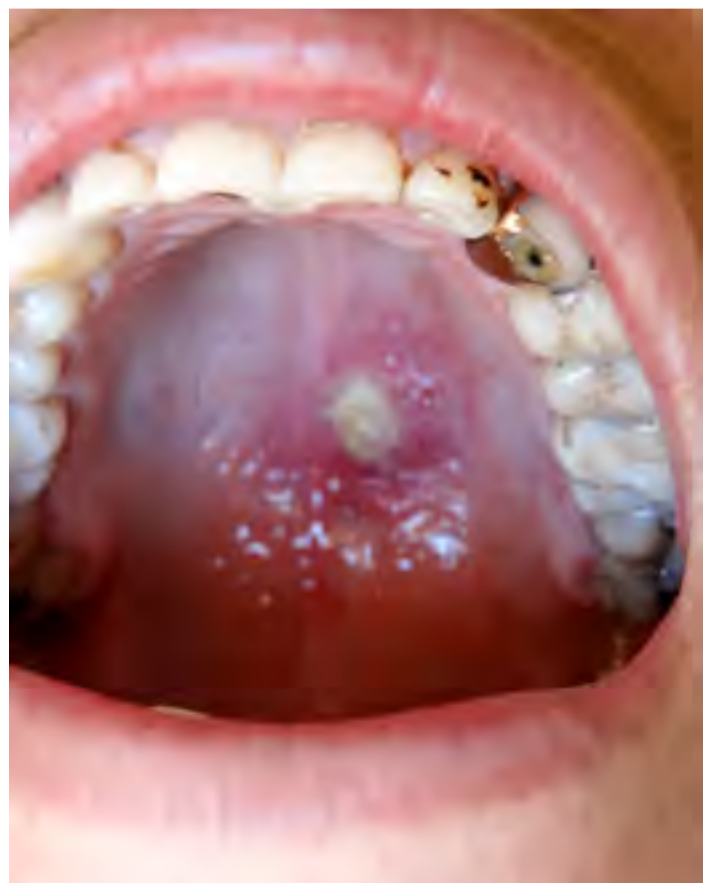Woman aged 70 years with three-month-old severe actinic damage and ulcer on the back of the hand. The ulcer was very characteristic of leishmaniasis, but epidemiology, a negative direct examination, and the sun damage led to the suspected diagnosis, which was verified with biopsy.

**Cutaneous lymphoma.** Cutaneous lymphoma lesions are usually macules and plaques, but, during development, fast-growing ulcers may occur that are irregular in shape and outline and almost always on top of previous plaques from the tumor (*Figures 3.334 a 3.339*).



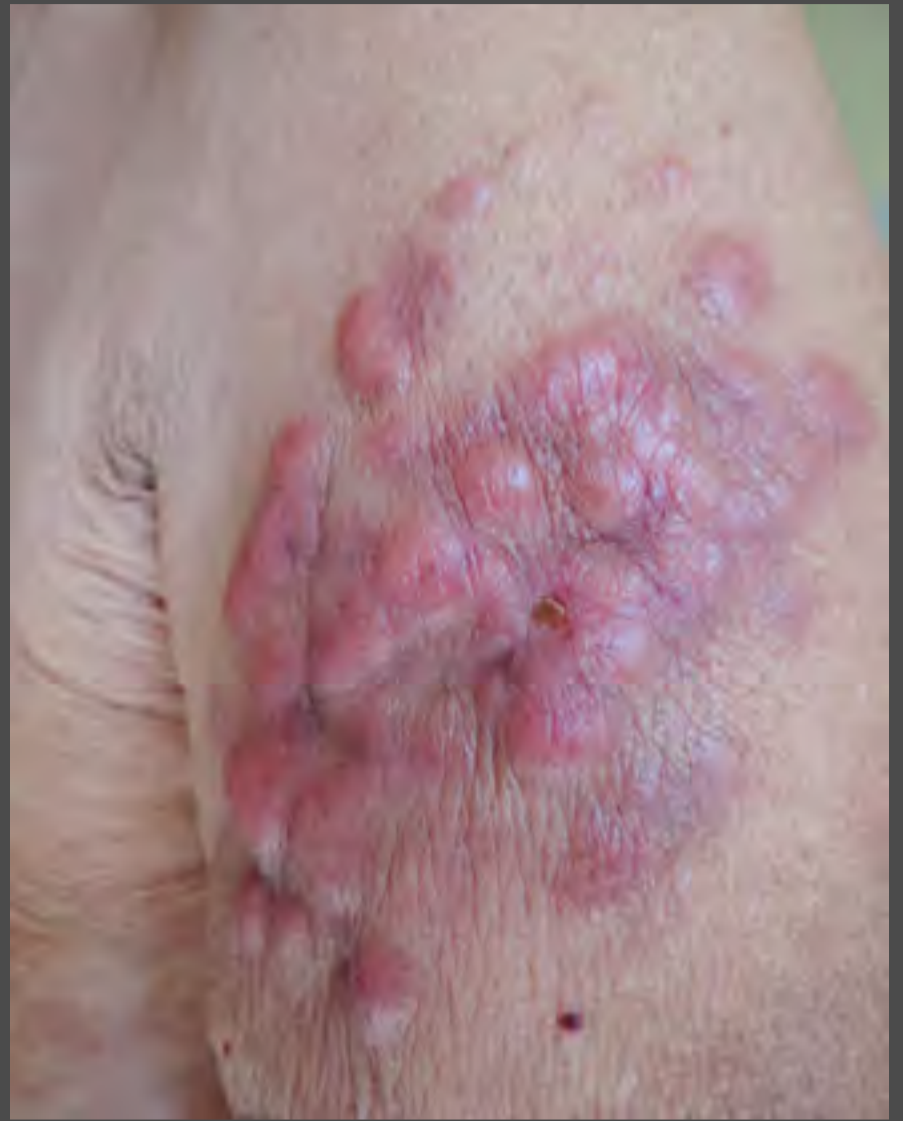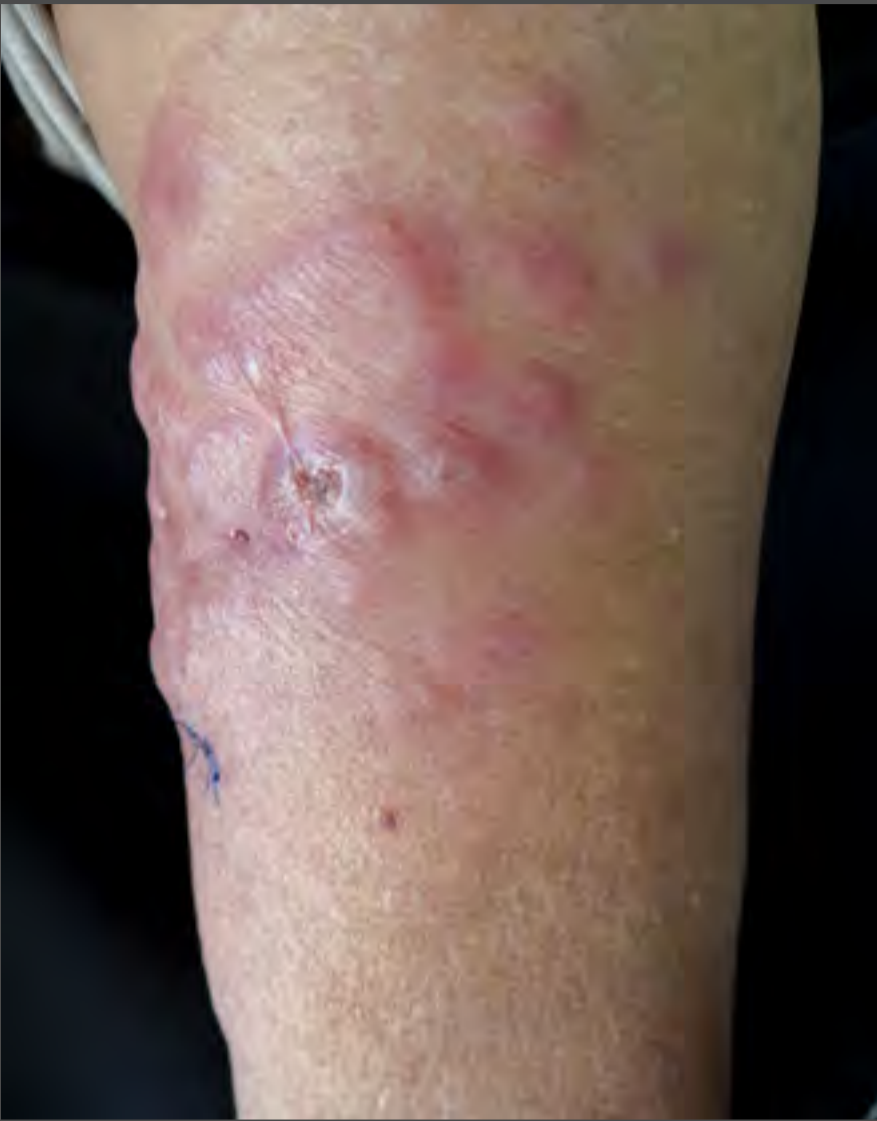**Figures 3.334A, B and C.**

Man aged 22 years with five-month-old cutaneous B-cell lymphoma. On the leg there was a rounded ulcer, 8 cm in diameter, with slightly irregular edges; on the forehead, an infiltrated plaque with deep irregular ulceration and some necrotic areas; and on the hard palate, a small ulceration. He was treated on two occasions for leishmaniasis. His poor general condition, fever, and weight loss led to the suspected diagnosis, corroborated by the histopathological study. The patient died three months later.





## Cutaneous lymphoma

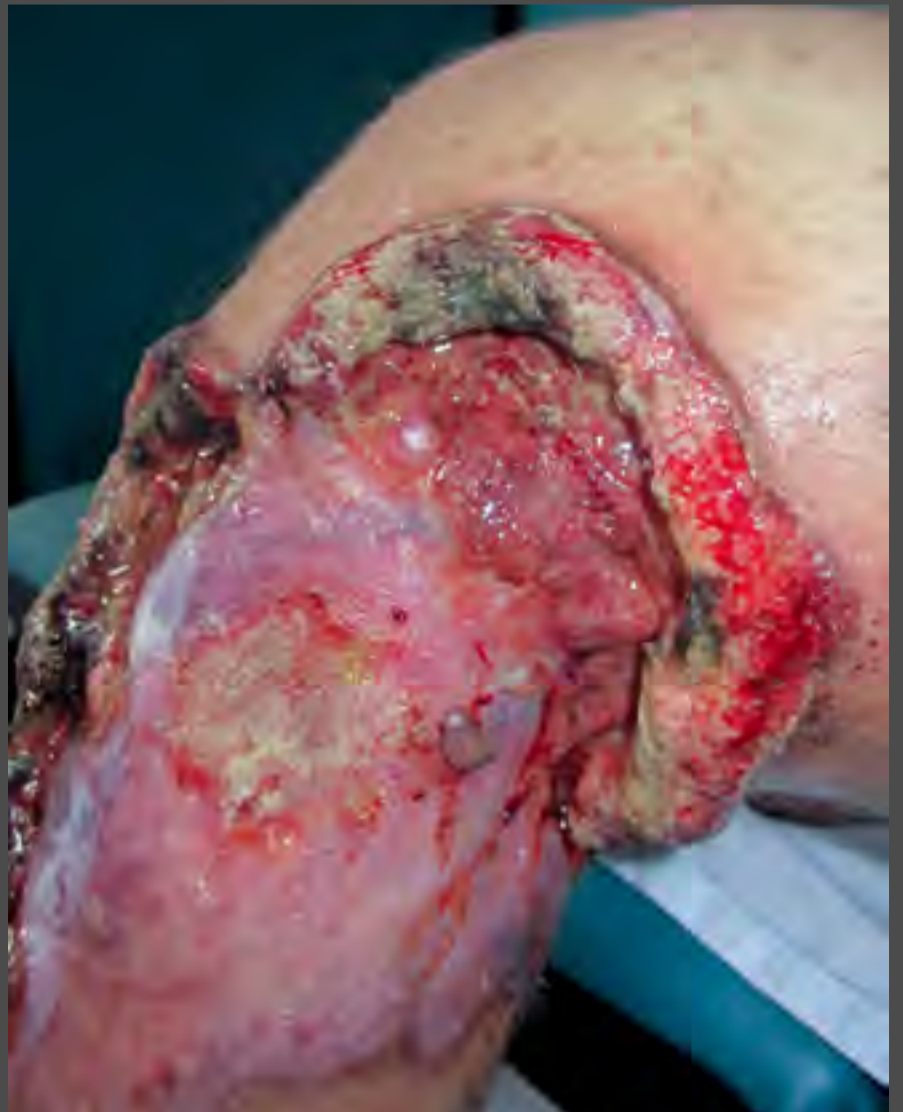

**Figures 3.335A and B.**

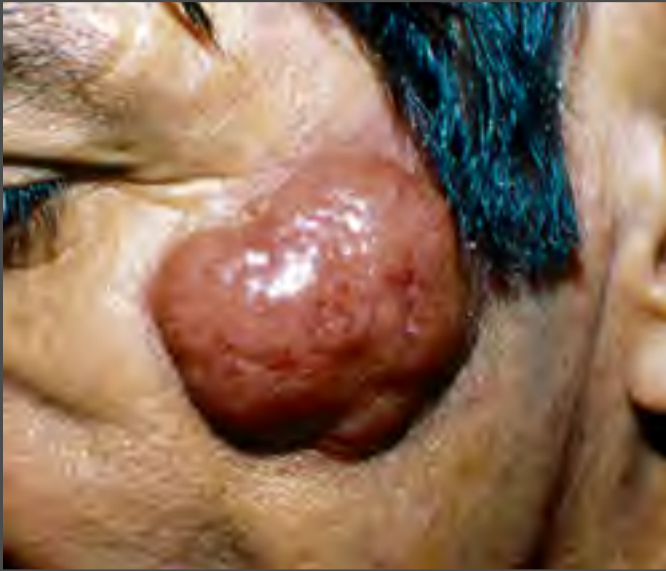Woman aged 42 years with cutaneous T-cell lymphoma. She had an infiltrative plaque with numerous erythematous papules and nodules on the arm, which, three weeks later, showed the rapid progression of this aggressive neoplasm.

**Figure 3.336.**

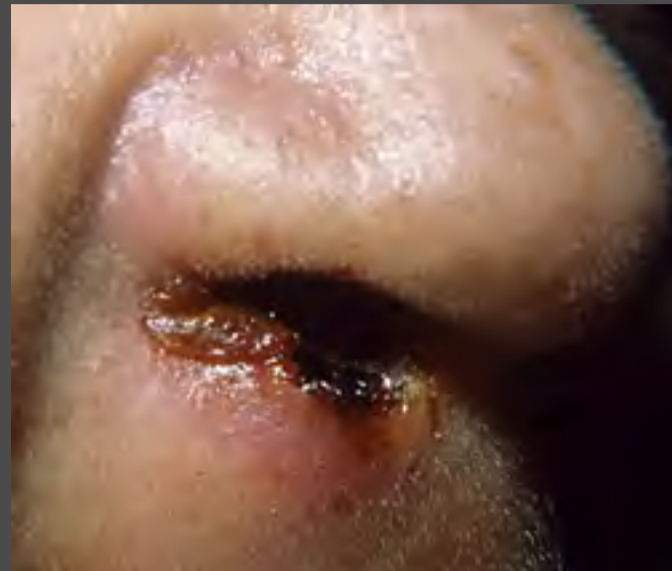Extensive ulcer of the leg and knee with clinical diagnosis of pyoderma gangrenosum and leishmaniasis. This was also suggested by the biopsy, which, on review, was found to be cutaneous lymphoma.



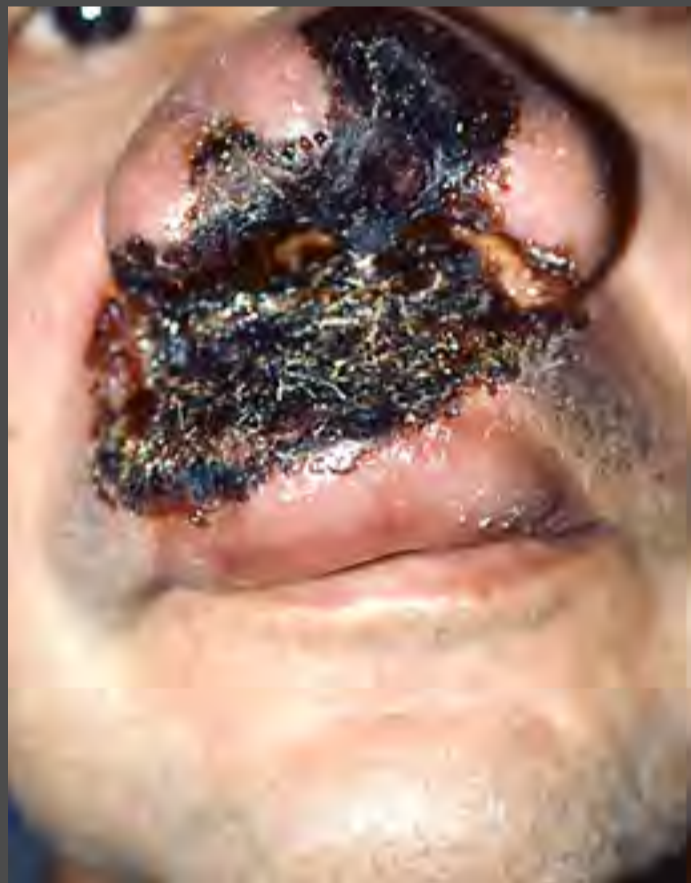## Cutaneous lymphoma



**Figure 3.337.**  
Smooth surface tumor in patient from a leishmaniasis endemic area, referred for study of this disease. Cutaneous lymphoma was found.



**Figure 3.338.**  
Midline lymphoma, ulcer, and edema of the choana

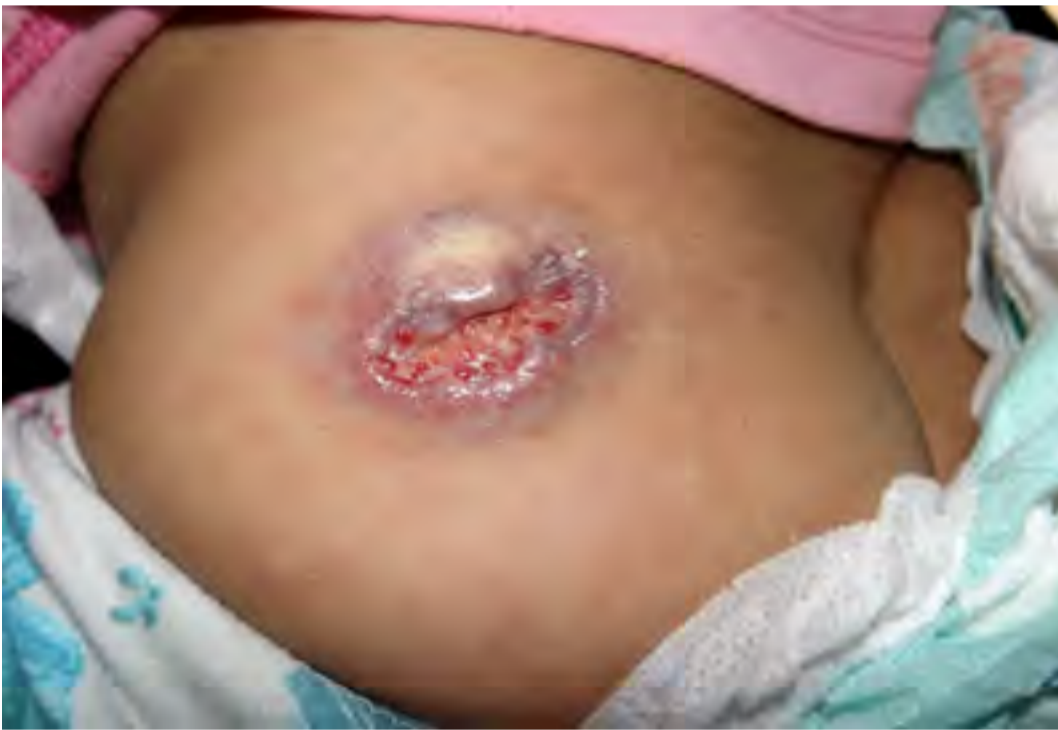

**Figure 3.339.**  
Midline lymphoma, advanced lymphoid tumor, crusty or hemorrhagic, ulcerated

*Lymphocytoma cutis.* This is a lymphoid cutaneous hyperplasia characterized by reddish or purplish papules or plaques a few centimeters in diameter, almost always on the face of young women and should be considered as a differential diagnosis of the histoid forms of cutaneous leishmaniasis.

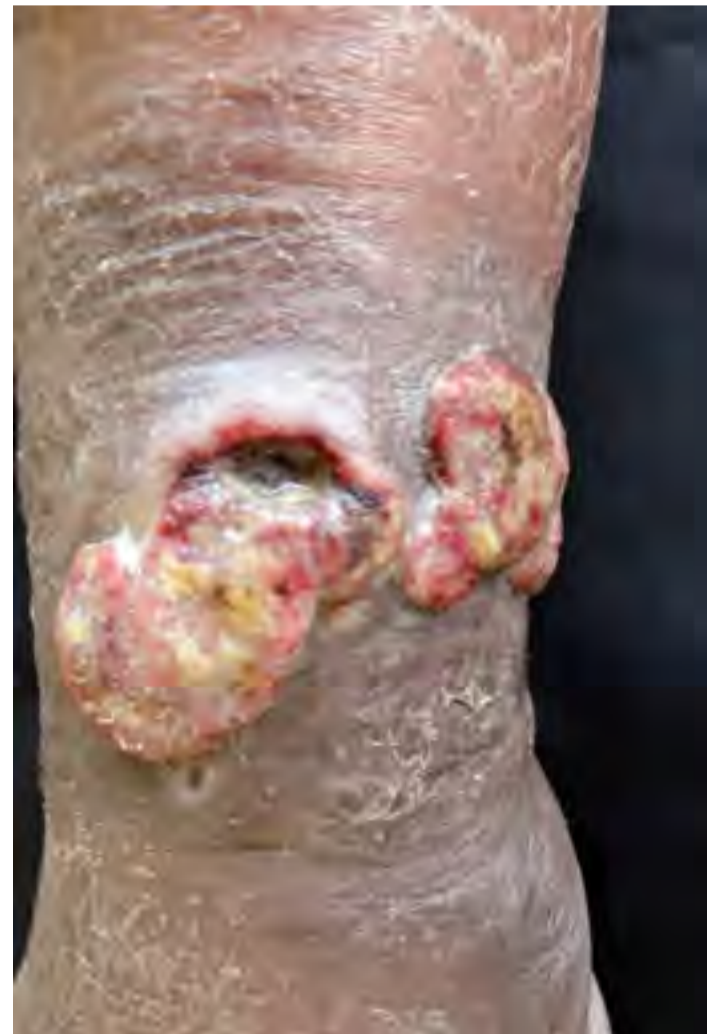*Hemangioma (Figure 3.340)*

*Kaposi's sarcoma (Figure 3.341)*



**Figures 3.340.**

Ulcerated infantile hemangioma. In children under 1 year or very young, hemangiomas may be ulcerated; lesions take on an appearance that resembles cutaneous leishmaniasis.



**Figures 3.341.**

Kaposi's sarcoma. Proliferative lesion that combines tumorous and ulcerated areas on the leg of a man aged 50 years.

## Recommended Reading

### Localized Cutaneous Leishmaniasis

#### *Agents, vectors, and reservoirs*

- Bates PA, Depaquit J, Galati EA, Kamhawi S, Maroli M, McDowell MA, Warburg A. Recent advances in phlebotomine sand fly research related to leishmaniasis control. *Parasit Vectors*. 2015;8(1):131.
- World Health Organization. Control of the leishmaniasis. Report of a meeting of the WHO Expert Committee on the Control of Leishmaniasis. Geneva: WHO; 2010.
- van der Auwera G, Dujardin JC. Species typing in dermal leishmaniasis. *Clin Microbiol Rev*. 2015;28(2):265-94.
- Heras-Mosteiro J, Monge-Maillo B, Pinart M, López-Pereira P, Reveiz L, García-Carrasco E, et al. Interventions for Old World cutaneous leishmaniasis. *Cochrane Database Syst Rev*. 2017;12:CD005067. doi: 10.1002/14651858.CD005067.pub5.
- Kevric I, Cappel MA, Keeling JH. New World and Old World leishmania infections: A practical. *Dermatol Clin*. 2015;33(3):579-93. doi: 10.1016/j.det.2015.03.018.
- McGwire BS. Leishmaniasis: Clinical syndromes and treatment. *QJ Med*. 2014;107:7-14.

#### *Clinical classification*

- Barros-Meireles C, Chaves-Maia L, Coelho Soares G. Atypical presentations of cutaneous leishmaniasis: A systematic review. *Acta Trop*. 2017;172:240-54.
- Handler MZ, Patel PA, Kapila R, Al-Qubati Y, Schwartz RA. Cutaneous and mucocutaneous leishmaniasis: Clinical perspectives. *J Am Acad Dermatol*. 2015;73(6):897-910. doi: 10.1016/j.jaad.2014.08.051.
- Handler MZ, Patel PA, Kapila R, Al-Qubati Y, Schwartz RA. Cutaneous and mucocutaneous leishmaniasis: Differential diagnosis, diagnosis, histopathology, and management. *J Am Acad Dermatol*. 2015;73(6):911-28. doi: 10.1016/j.jaad.2014.09.014.
- Paniz-Mondolfi AE, Talhari C, García-Bustos MF, Rosales T, Villamil-Gómez WE, Márquez M, et al. American cutaneous leishmaniasis in infancy and childhood. *Int J Dermatol*. 2017;56(12):1328-41. doi: 10.1111/ijd.13664.
- Torres-Guerrero E, Quintanilla-Cedillo MR, Ruiz-Esmenjaud J, Arenas R. Leishmaniasis: A review. *F1000Res*. 2017;26(6):750. doi: 10.12688/f1000research.11120.1.
- von Stebut E. Leishmaniasis. *J Dtsch Dermatol Ges*. 2015. doi: 10.1111/ddg.12595
- Scorza BM, Carvalho EM, Wilson ME. Cutaneous manifestations of human and murine leishmaniasis. *Int J Mol Sci*. 2017;18(6):e1296. doi: 10.3390/ijms18061296.

### Laboratory diagnosis

- Borges VC, Merino MC, Moreira P. Intra-dermorreação de Montenegro após sucessivas repetições do teste em Porteirinha (MG). *Rev Soc Bras Med Trop.* 2002;36:249-51.
- De Lima MB, Schubach A. Positive Montenegro skin test among patients with sporotrichosis in Rio de Janeiro. *Acta Trop.* 2005;93:41-4.
- Faber WR, Oskam L, van Gool T, Kron NCM, Knet-Junk KJ, Hofwegen H, *et al.* Value of diagnostic techniques for cutaneous leishmaniasis. *J Am Acad Dermatol.* 2003;49:70-4.
- Jara M, Aduai V, Valencia BM, Martínez D, Alba M, Castrillón C, *et al.* Real-time PCR assay for detection and quantification of *Leishmania* (*Viannia*) organisms in skin and mucosal lesions: Exploratory study of parasite load and clinical parameters. *J Clin Microbiol.* 2013;51:1826-33.
- Khairnar K, Lynde C, Ralevski F, Keystone J, McCarthy A, Levine J, *et al.* Molecular diagnosis of leishmaniasis at the subgenus and species level. *Parasitol Res.* 2013;115:49. doi 10.1007/s00436-013-3663-1.
- Manzur A, Bari AU. Sensitivity of leishmanin skin test in patients of acute cutaneous leishmaniasis. *Dermatol Online J.* 2006;12(4):2.
- Montalvo CA, Fraga J, Monzote CL, García M, Fonseca L. Diagnóstico de leishmaniasis: de la observación directa del parásito a la detección del ADN. *Rev Cub Med Trop.* 2012;64:108-31.
- Navin TR, Arana FA, Mérida A, Arana B. Cutaneous leishmaniasis in Guatemala: Comparison of diagnosis methods. *Am J Trop Med Hyg.* 1990;42:36-42.
- Shirian S, Oryan A, Hatam CR, Panahi S, Danneshbod Y. Comparison of conventional, molecular, and immunohistochemical methods in diagnosis of typical and atypical cutaneous leishmaniasis. *Arch Pathol Lab Med.* 2014;138:235-40.
- Singh S, Sivakumar R. Applications of molecular methods for *Leishmania* control. *Rev Expert Rev Mol Diagn.* 2005;5:251-65.

### Treatment

- Ashutosh, Sundar S, Goyal N. Molecular mechanisms of antimony resistance in *Leishmania*. *J Med Microbiol.* 2007; 56:143-53.
- Ballou R, Gordon D, Andujar J, McClain B, Shanks D, Berman J, Chulay J, *et al.* Safety and efficacy of high-dose sodium stibogluconate therapy of American Cutaneous Leishmaniasis. *Lancet.* 1987;2:13-6.
- Brito NC, Rabello A, Cota GF. Efficacy of pentavalent antimoniate intralesional infiltration therapy for cutaneous leishmaniasis: A systematic review. *PLoS One.* 2017;12(9):e0184777. doi.org/10.1371/journal.pone.0184777.
- Conceição-Silva F, Leite-Silva J, Morgado FN. The binomial parasite-host immunity in the healing process and in reactivation of human tegumentary leishmaniasis. *Front Microbiol.* 2018;9:1308. doi: 10.3389/fmicb.2018.01308.

- Cruz A, Rainey P, Herwaldt B, *et al.* Pharmacokinetics of antimony in children treated for leishmaniasis with meglumine antimoniate. *J Infect Dis.* 2007;195:602-8.
- Das VN, Ranjan A, Bimal S, Siddique NA, Pandey K, Kumar N, Verma N, Singh VP, Sinha PK, Bhattacharya SK, *et al.* Magnitude of unresponsiveness to sodium stibogluconate in the treatment of visceral leishmaniasis in Bihar. *Natl Med J India.* 2005;18(3):131-3.
- Demicheli C, Figueredo TL, Carvalho S, Sinisterra R, Lopes J, Frézard F. Physico-chemical characterization of meglumine antimoniate. *BioMetals* 1999;12:63-6.
- Galvão EL, Rabello A, Cota GF. Efficacy of azole therapy for tegumentary leishmaniasis: A systematic review and metaanalysis. *PLoS One.* 2017;12(10):e0186117. [doi.org/10.1371/journal.pone.0186117](https://doi.org/10.1371/journal.pone.0186117).
- Guderian RH, Chico ME, Rogers MD, Pattishall KM, Grogl M, Berman JD. Placebo controlled treatment of Ecuadorian cutaneous leishmaniasis. *Am J Trop Med Hyg* 1991;45:92-7.
- Hepburn NC, Siddique AF, Howie AF, Beckett GJ, Hayes PC. Hepatotoxicity of sodium stibogluconate therapy for American cutaneous leishmaniasis. *Trans R Soc Trop Med.* 1994;88:453-5.
- Herwaldt BL, Arana BA, Navin TR. The natural history of cutaneous leishmaniasis in Guatemala. *J Infect Dis.* 1992;165(3):518-27.
- López L, Robayo M, Vargas M, Vélez ID. Thermotherapy. An alternative for the treatment of American cutaneous leishmaniasis. *Trials.* 2012;13:58. <http://www.trialsjournal.com/content/13/1/58>.
- López-Carvajal JA, Zapata-Cardona MI, Sánchez-Giraldo V, Vélez ID, *et al.* Efficacy of cryotherapy for the treatment of cutaneous leishmaniasis: Meta-analyses of clinical trials. *BMC Infect Dis.* 2016;16:360.
- Mickeley N, Mortari SR, Schubach AO. Monitoring of total antimony and its species by ICP-MS and on-line ion chromatography in biological samples from patients treated for leishmaniasis. *Anal Bioanal Chem.* 2002;372:495-502.
- Navin T, Arana B, Arana F, Berman J, Chajón J. Placebo-controlled clinical trial of stibogluconate (Pentostam ) versus ketoconazole for treating cutaneous leishmaniasis in Guatemala. *J Infect Dis.* 1992;165:528-34.
- Oliveira-Neto MP, Schubach A, Mattos M, Goncalves-Costa SC, Pirmez C. A low dose antimony treatment in 159 patients with American cutaneous leishmaniasis: Extensive follow-up studies (up to 10 years). *Am J Trop Med Hyg.* 1997;57:651-5.
- Pan American Health Organization. Leishmaniasis in the Americas: Treatment recommendations. Washington, D.C.: PAHO; 2018.
- Pan American Health Organization. Manual of procedures for leishmaniasis surveillance and control in the Americas. Washington, D.C.: PAHO; 2019.
- Palacios R, Osorio LE, Grajales LF, Ochoa MT. Treatment failure in children in a randomized clinical trial with 10 and 20 days of meglumine antimoniate for cutaneous leishmaniasis due to *Leishmania (Viannia)* species. *Am J Trop Med Hyg.* 2001;64(3,4):187-93.

- Ribeiro de Paula CD, Duarte Sampaio JH, Rizo Cardoso D, Ribeiro Sampaio RN. A comparative study between the efficacy of pentamidine isothionate given in three doses for one week and N-methylmethyl-glucamine in a dose of 20 mg Sb<sup>v</sup>/day for 20 days to treat cutaneous leishmaniasis. *Rev Soc Bras Med Trop. Revista da Sociedade Brasileira de Medicina Tropical.* 2003;36(3):365-71.
- Rubiano LC, Miranda MC, Muvdi Muvdi-Arenas S, Montero LM, Rodríguez-Barraquer I, Garcerant D, *et al.* Noninferiority of miltefosine versus meglumine antimoniate for cutaneous leishmaniasis in children. *J Infect Dis.* 2012;205(4):684-92.
- Sereno D, Cavaleyra M, Zemzoumi K, Maquaire S, Ouaissi A, Lemesre JL. Axenically grown amastigotes of *Leishmania infantum* used as an *in vitro* model to investigate the pentavalent antimony mode of action. *Antimicrob Agents Chemother.* 1998;42(12):3097-102.
- Soto J, Toledo J, Vega J, Berman J. Efficacy of pentavalent antimony for treatment of Colombian cutaneous leishmaniasis. *Am J Trop Med Hyg.* 2005;72(4):421-2.
- Sundar S, More DK, Singh MK, Singh VP, Sharma S, Makharia A, *et al.* Failure of pentavalent antimony in visceral leishmaniasis in India: report from the center of the Indian epidemic. *Clin Infect Dis.* 2000;31:1104-7.
- Thakur CP, Sinha GP, Pandey AK, Kumar N, Kumar P, Hassan SM, *et al.* Do the diminishing efficacy and increasing toxicity of sodium stibogluconate in the treatment of visceral leishmaniasis in Bihar, India, justify its continued use as a first-line drug? An observational study of 80 cases. *Ann Trop Med Parasitol.* 1998;92(5):561-9.
- Zilberstein D, Ephros M. Clinical and laboratory aspects of *Leishmania* chemotherapy in the era of drug resistance. In: Farrell JP, editor. *World Class Parasites, Volume 4. Leishmania.* Second edition. Norwell, MA: Kluwer Academic Publisher; 2002; p. 118-36.

## Disseminated Leishmaniasis

- Convit J, Pinardi ME, Rondon AJ. leishmaniasis: A disease due to an immunological defect of the host. *Trans R Soc Trop Med Hyg.* 1972;66:603-10.
- Guerra JA, Coelho L, Pereira F, Siqueira A, Ribeiro R, Almeida TM, *et al.* American tegumentary leishmaniasis and HIV-AIDS association in a tertiary care center in the Brazilian Amazon. *Am J Trop Med Hyg.* 2011;85:524-7.
- Jirmanus L, Glesby MJ, Guimarães LH, Lago E, Rosa ME, Machado PR, *et al.* Epidemiological and clinical changes in American tegumentary leishmaniasis in an area of *Leishmania (Viannia) braziliensis* transmission over a 20-year period. *Am J Trop Med Hyg.* 2012;86(3):426-33.
- Machado PR, Rosa ME, Guimarães LH, Prates FV, Queiroz A, Schriefer A, *et al.* Treatment of disseminated leishmaniasis with liposomal amphotericin B. *Clin Infect Dis.* 2015;61(6):945-9.
- Machado PR, Rosa MEA, Costa D, Mignac M, Silva JS, Schriefer A, *et al.* Reappraisal of the immunopathogenesis of disseminated leishmaniasis: In situ and systemic immune response. *Trans R Soc Trop Med Hyg.* 2011;105:438-44.
- Queiroz A, Sousa R, Heine C, Cardoso M, Guimarães LH, Machado PR, *et al.* Association between an emerging disseminated form of leishmaniasis and *Leishmania (Viannia) braziliensis* strain polymorphisms. *J Clin Microbiol.* 2012;50(12):4028-34.
- Turetz ML, Machado PR, Ko AI, Alves F, Bittencourt A, Almeida RP, *et al.* Disseminated leishmaniasis: A new and emerging form of leishmaniasis observed in northeastern Brazil. *J Infect Dis.* 2002;186:1829-34.
- Vélez ID, Jiménez A, Vásquez D, Robledo SM. Disseminated cutaneous leishmaniasis in Colombia: Report of 27 cases. *Case Rep Dermatol.* 2015;7(3):275-86.
- World Health Organization. Control of the leishmaniasis. Report of a meeting of the WHO Expert Committee on the Control of Leishmaniasis. Technical Report Series, No. 949. Geneva: WHO; 2010.



## Diffuse Cutaneous Leishmaniasis

- Barral A, Costa JML, Bittencourt AL, Barral-Netto M, Carvalho EM. Polar and sub-polar leishmaniasis in Brazil: Clinical and immunopathologic aspects. *Int J Dermatol.* 1995;33:474-9.
- Bittencourt AL, Barral AL, Costa JML, Saldanha ACR, Badaró F, Barral-Netto M, Freitas LAR, *et al.* leishmaniasis with atypical aspects. *Int J Dermatol.* 1992;31:568-70.
- Bomfim G, Nascimento C, Costa J, Barral-Netto M, Barral A. Variation of cytokine patterns related to therapeutic response in diffuse cutaneous leishmaniasis. *Exp Parasitol.* 1996;84:188-94.
- Bryceson ADM. Diffuse cutaneous leishmaniasis in Ethiopia. I. The clinical and histological features of disease. *Trans Royal Soc Trop Med Hyg.* 1969;63:708-37.
- Bryceson ADM. Diffuse cutaneous leishmaniasis in Ethiopia. II. Treatment. *Trans Royal Soc Trop Med Hyg.* 1970;64:369-79.
- Convit J, Pinaridi ME, Rondon AJ. Diffuse cutaneous leishmaniasis: A disease due to an immunological defect of the host. *Trans Royal Soc Trop Med Hyg.* 1972;66:609-10.
- Convit J, Ulrich M, Polegre MA, Ávila A, Rodriguez N, Mazzedo M, Blanco B. Therapy of Venezuelan patients with severe mucocutaneous or early lesions of diffuse cutaneous leishmaniasis with a vaccine containing pasteurized *Leishmania* promastigotes and bacillus Calmette-Guerin – preliminary report. *Mem Inst Oswaldo Cruz.* 2004;99:57-62.
- Costa AA, Saldanha AC, Leite BM, Ramos B, Junior IA, Noronha AL, *et al.* Imaging exams of bone lesions in patients with diffuse cutaneous leishmaniasis (DCL). *Acta Trop.* 2005;96(1):9-15.
- Costa JML, Mendes S, Melo LS, Figueiredo I, Rebelo JMM, Saldanha ACR, Gama, MEA, Barral A, *et al.* Tratamento da leishmaniose cutânea difusa (LCD) com a associação anti-moniato-N-metilglucamina (Glucantime®) e sulfato de paramomicina (Gabbrox®). *Anais Brasil Dermatol.* 1999;74:63-7.
- Costa JML, Moraes MSC, Saldanha ACR, Barral A, Burattini MN. Diabetes mellitus associated with pentamidine isethionate in diffuse cutaneous leishmaniasis. *Rev Soc Bras Med Trop.* 1995;28:405-7.
- Costa JML, Saldanha ACR, Pedroso e Silva CM, Branco MRFC, Barral A, Carvalho EM, Bittencourt AL. Spontaneous regional healing of extensive skin lesions in diffuse cutaneous leishmaniasis (DCL). *Rev Soc Bras Med Trop.* 1995;28:45-7.
- Costa JML, Saldanha ACR, Silva ACM, Serra-Neto A, Galvão CES, Silva CMP. Estado atual da leishmaniose cutânea difusa (LCD) no estado do Maranhão: aspectos epidemiológicos, clínicos-evolutivos. *Rev Soc Bras Med Trop.* 1992;25:115-23.

- Costa JML. Contribuição ao estudo da leishmaniose cutânea difusa no estado do Maranhão, Brasil. I – Estudo clínico epidemiológico e evolutivo; II – Avaliação terapêutica com associação do antimoniato-N-metilglucamina+interferon gamma; isotionato de pentamidina e sulfato de aminosidina (trabalho apresentado ao concurso jovem cientista). CNPq; 1993.
- Costa JML. Estudo da leishmaniose cutânea difusa (LCD) no estado do Maranhão- Brasil: Avaliação terapêutica e correlação do perfil imunológico entre os pacientes e seus familiares (tese). Rev Soc Bras Med Trop. 1998;31:89-93.
- World Health Organization. WHO Control of the leishmaniasis: Report of a meeting of the WHO Expert Committee on the Control of Leishmaniasis. Technical Report Series No. 949. Geneva: WHO; 2010.
- Guimarães LH, Queiroz A, Silva JA, Silva SC, Magalhães V, Lago EL, *et al.* Atypical manifestations of cutaneous leishmaniasis in a region endemic for *Leishmania braziliensis*: Clinical, immunological and parasitological aspects. PLoS Negl Trop Dis. 2016;10(12):e0005100. doi: 10.1371/journal.pntd.0005100.
- Guimarães LH, Machado PR, Lago EL, Morgan DJ, Schriefer A, Bacellar O, *et al.* Atypical manifestations of tegumentary leishmaniasis in a transmission area of *Leishmania braziliensis* in the state of Bahia, Brazil. Trans R Soc Trop Med Hyg. 2009;103(7):712-5. doi: 10.1016/j.trstmh.2009.04.019.
- Lizardo-Castro GA, Ponce C, Ponce E, Sierra M. Caracterización de pacientes con leishmaniasis cutánea atípica. Rev Med Hondur 2008;76:101-7.
- Ponce C, Ponce E, Morrison A, Cruz A, Nova F. *Leishmania donovani chagasi*: new clinical variant of cutaneous leishmaniasis in Honduras. Lancet 1991;357:67-70.

## Differential Diagnosis

- Mello CX, Schubach A de O, Madeira M de F. Can yeast-like form of *Sporothrix schenckii* confuse the direct parasitological diagnosis of American cutaneous leishmaniasis? Rev Soc Bras Med Trop. 2011;44:127.
- Mulvaney P, Aram G, Maggiore PR, Kutzner H, Carlson JA. Delay in diagnosis: Trauma- and coinfection-related cutaneous leishmaniasis because of *Leishmania guyanensis* infection. J Cutan Pathol. 2009;36:53-60.
- Paniz-Mondolfi AE, Reyes O, Dávila L. Lobomycosis in Venezuela. Int J Dermatol. 2007;46:180-5.
- Quintella LP, Passos SR, de Miranda LH, Cuzzi T, Barros MB, Francesconi-do-Vale AC, et al. Proposal of a histopathological predictive rule for the differential diagnosis between American tegumentary leishmaniasis and sporotrichosis skin lesions. Br J Dermatol. 2012;167:837-46.
- Ramos-E-Silva M. Facial and oral aspects of some venereal and tropical diseases. Acta Dermatovenerol Croat. 2004;12:173-80.

# CHAPTER 4

## Mucosal Leishmaniasis

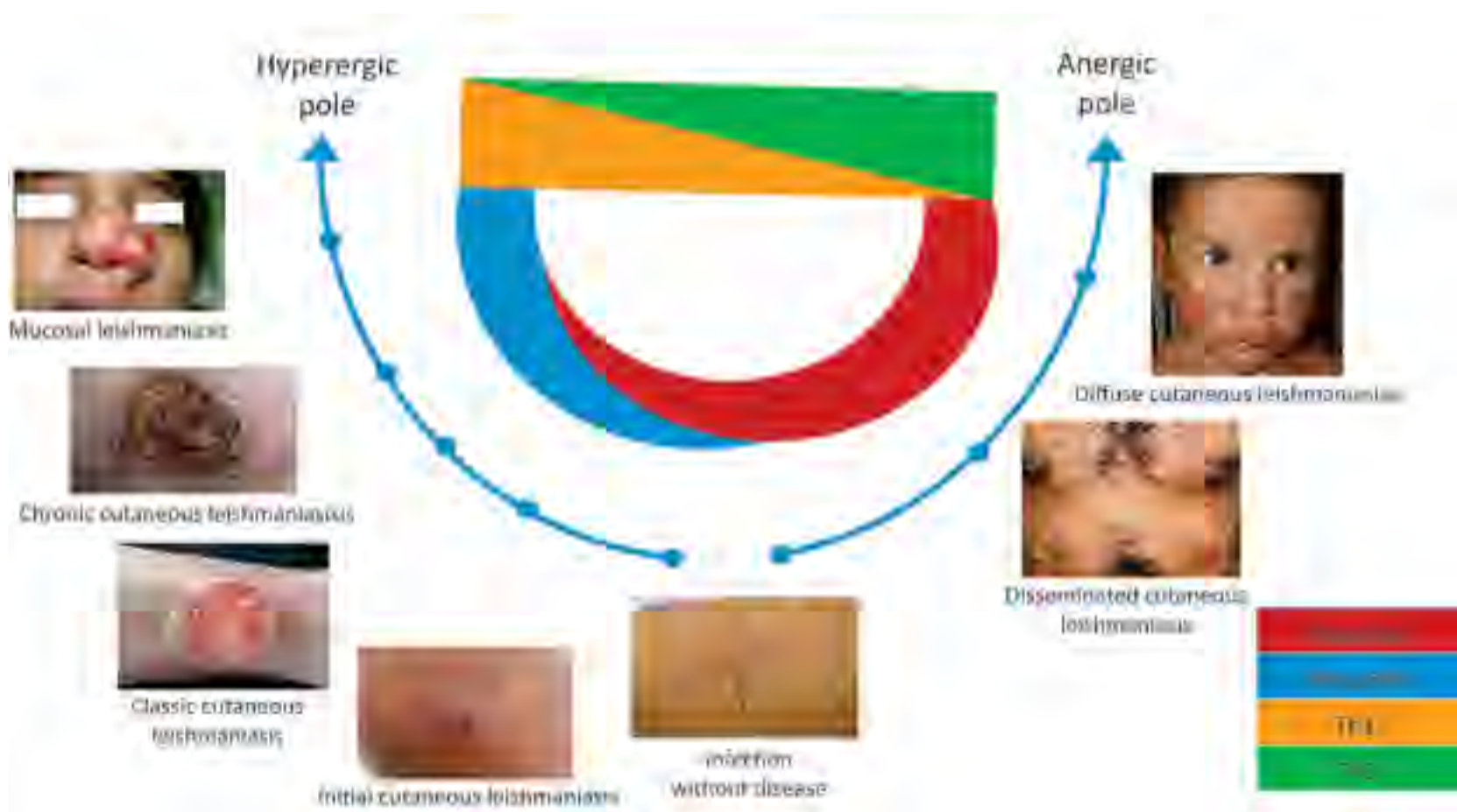


Alejandro Llanos-Cuentas, Edgar M. Carvalho, Paulo Roberto Lima Machado, Braulio Valencia, Ana Pilar Ramos and Jaime Soto

## Definition, Agents, Vectors, and Reservoirs

Mucosal leishmaniasis, also called *espundia*, is a chronic, destructive, and disfiguring form of cutaneous leishmaniasis, which affects the mucous membranes of the nose and mouth and, in the most severe cases, the larynx, trachea, and bronchi; exceptionally, it may involve the conjunctiva of the eye and semimucosa of the anus and glans.

As a consequence of the variable interaction of parasite-dependent factors (species, tropism, virulence, pathogen capacity, infection with LRV1 [*Leishmania* RNA virus 1]) and host-dependent factors (immunity, genetics), leishmaniasis is a spectral disease (*Figure 4.1*), in which the hyperergic pole is the mucosal form and the anergic pole is the diffuse cutaneous form.



**Figure 4.1.**  
The cutaneous and mucosal leishmaniasis spectrum

Mucosal leishmaniasis is the severe form of the disease and is characterized by the presence of variable—usually small—quantities of the parasite and a predominantly Th1-type immune response. It has been documented that *Leishmania (Viannia) braziliensis* is polymorphic and that there is an association between the genotypical differences of the isolates of this species and the clinical forms of tegumentary leishmaniasis.

The principal mechanism of defense against the intracellular parasites is macrophage activation by means of interferon gamma (IFN- $\gamma$ ). Although patients with cutaneous and mucosal leishmaniasis produce high concentrations of this cytokine, and its macrophages produce reactive oxygen species, they are not capable of destroying most of the parasites. With the persistence of the parasite in tissues, an exaggerated inflammatory response develops with involvement of the innate immune reaction and of TCD4+ and TCD8+ cells that is not modulated by regulatory mechanisms, which means that tissue damage occurs, and disease develops.

Mucosal involvement is by hematogenic dissemination 95% of the time; exceptionally, it is by contiguity from skin lesions next to the nasal cavity or lips.



Most patients have scars suggestive of cutaneous leishmaniasis, and 10% to 20% may have active cutaneous disease. For this reason, English-speaking authors called it mucocutaneous leishmaniasis. Some patients with mucosal leishmaniasis do not have typical skin scars, which could be due to inapparent disease, although we cannot rule out the possibility that mucosal disease may occur without prior cutaneous leishmaniasis.

The *Leishmania* species most frequently involved in mucosal leishmaniasis is *L. (V.) braziliensis* and, to a lesser degree, *L. (V.) panamensis* and *L. (V.) guyanensis*. Occasionally, cases have been described from *L. (V.) peruviana*, hybrid *L. (V.) braziliensis*—*L. (V.) peruviana*, *L. (L.) amazonensis*, and *L. (L.) mexicana*. The vectors and reservoirs are the same as those for cutaneous leishmaniasis, already extensively described in Chapter 3.

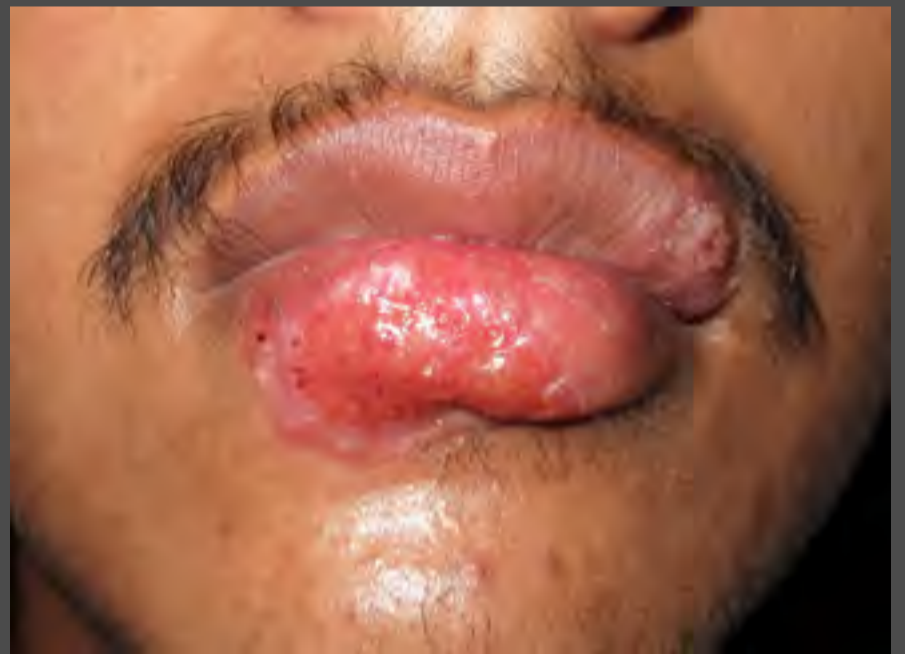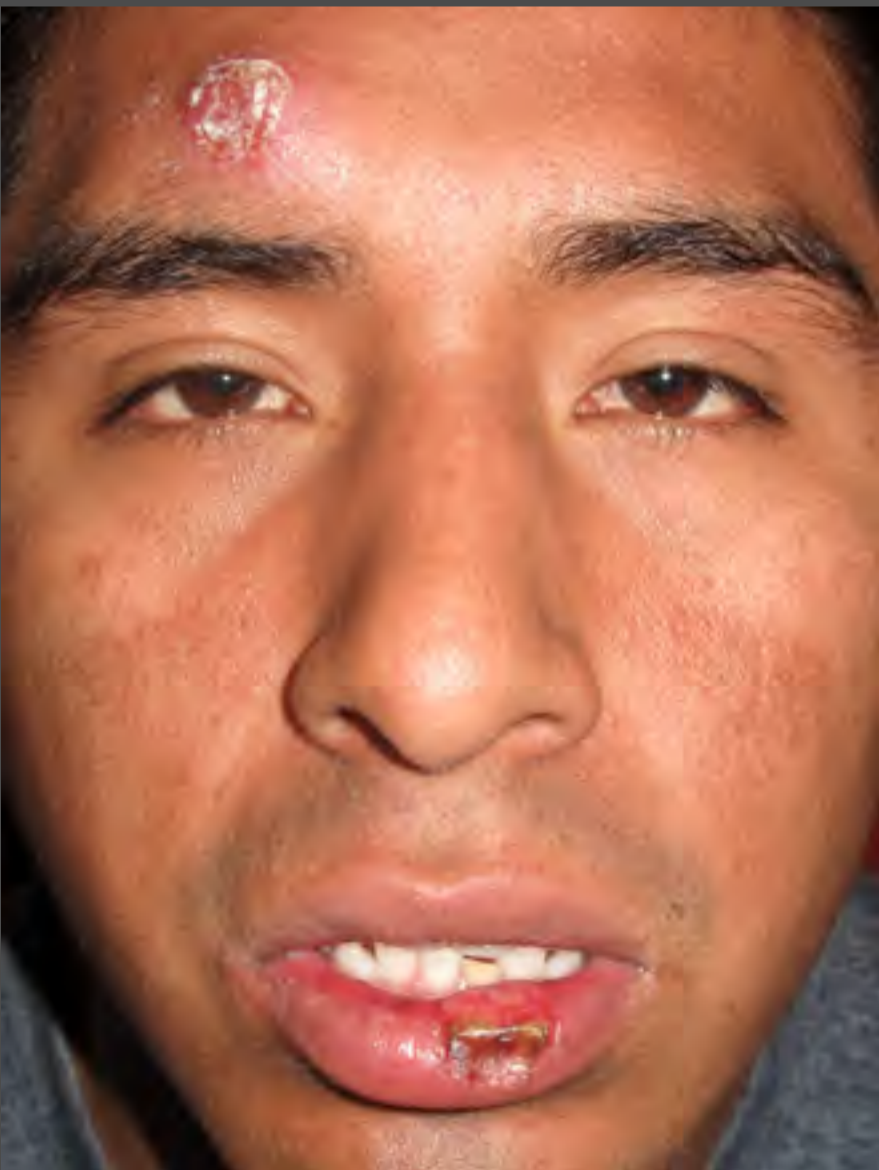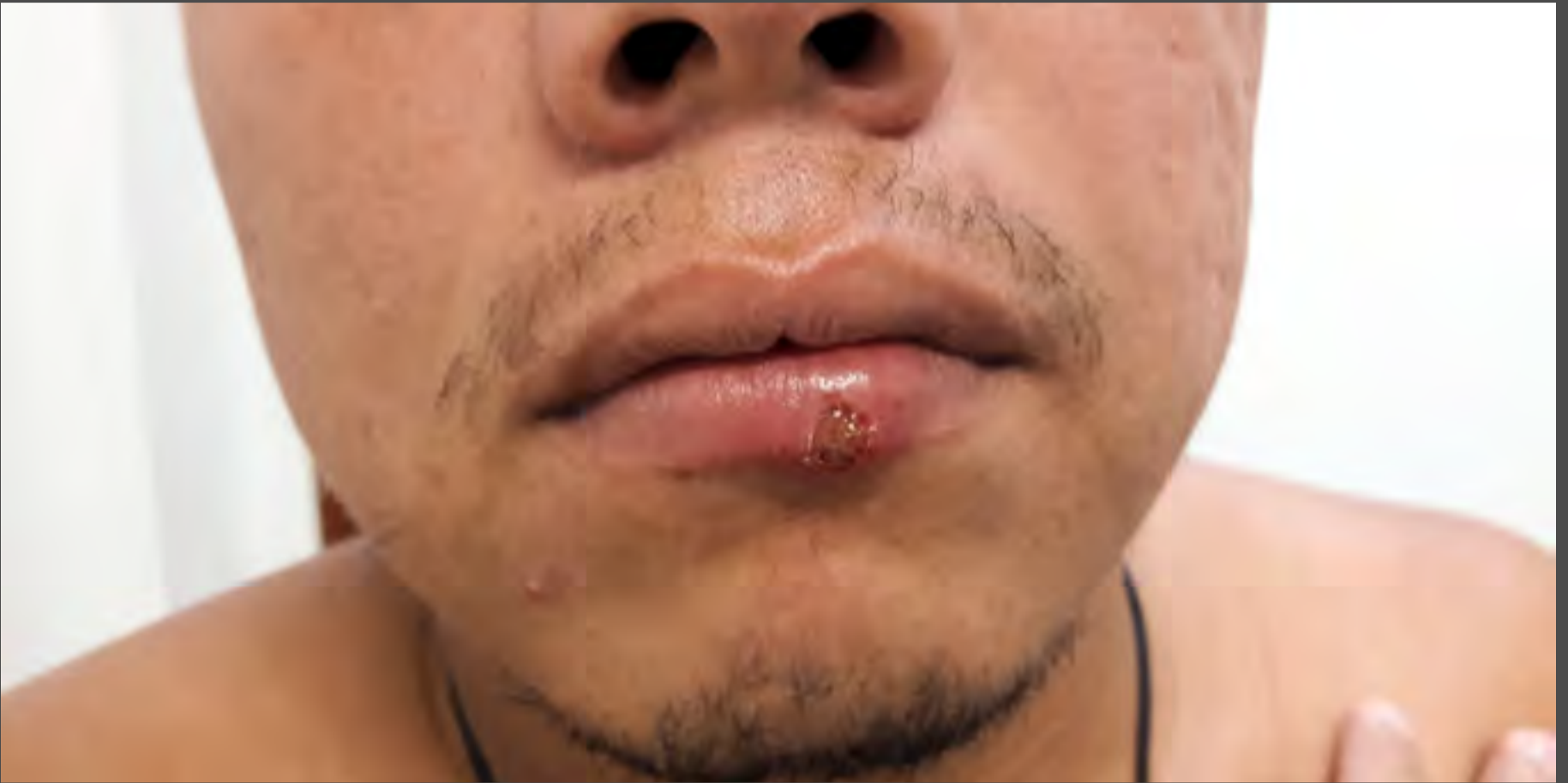## Clinical Manifestations

The initial mucosal lesion in almost all patients occurs in the nasal septum and nasal turbinates. The nasopharynx, oropharynx, uvula, soft palate, and hard palate can be progressively affected; lesions extending to the tongue or lower lip are very rare. In severe cases, the disease affects the epiglottis, vocal cords, and larynx. Involvement below the glottis, including the trachea and bronchi, is exceptional in these cases. The consequence of the infiltrative and destructive process is both anatomical and functional, which explains severe impairment in phonation, swallowing, and breathing, and pulmonary complications.

Usually, involvement of the upper lip is from spread of the nasal disease (*Figures 4.2 to 4.18*), and involvement of the conjunctiva of the eye occurs because of skin lesions near the eyelids. It is uncommon for the lower lip or tongue to be affected. Occasionally, lesions are observed on the penis and anus, possibly as a consequence of bites from infected insects there.

Histopathological study of the initial mucosal leishmaniasis lesion reveals the necrotizing granulomatous reaction with lymphocytes, macrophages, and plasmocytes, in which it is difficult to identify amastigotes, especially when infection is by *L. (V.) braziliensis* (260 parasites per  $\mu\text{g}$  of tissue; range: 3.2 to 143,000), compared to *L. (V.) guyanensis* (657,000 parasites per  $\mu\text{g}$  of tissue) and *L. (V.) peruviana* (128,465 parasites per  $\mu\text{g}$  of tissue).





**Figures 4.2A, B and C.**

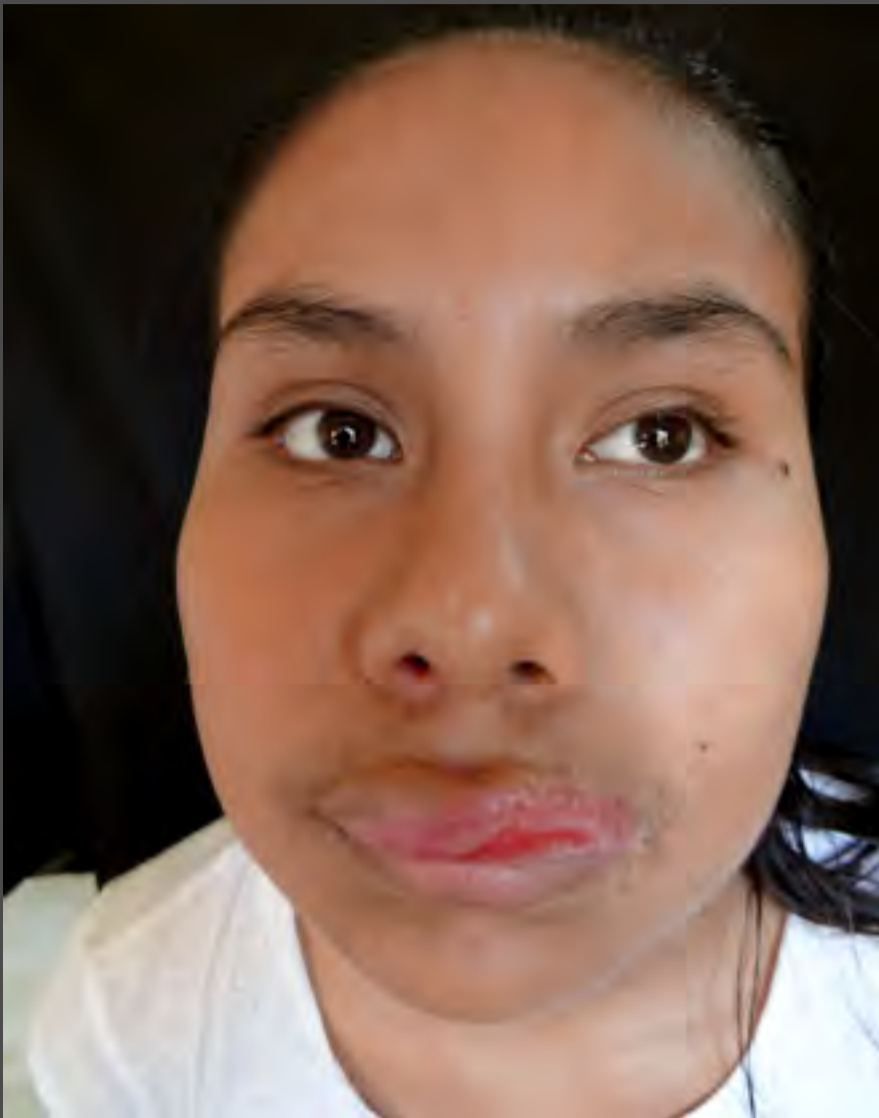
Ulcers in the semimucosa of the lower lip from direct inoculation of parasites. Neither the nasal nor the oral mucosa is involved. Although these are initial lesions, some call them mucocutaneous leishmaniasis because of their proximity to a mucous membrane. Figure 4.2C shows a crusty ulcer lesion on the forehead, which started at the same time as the lip lesion.

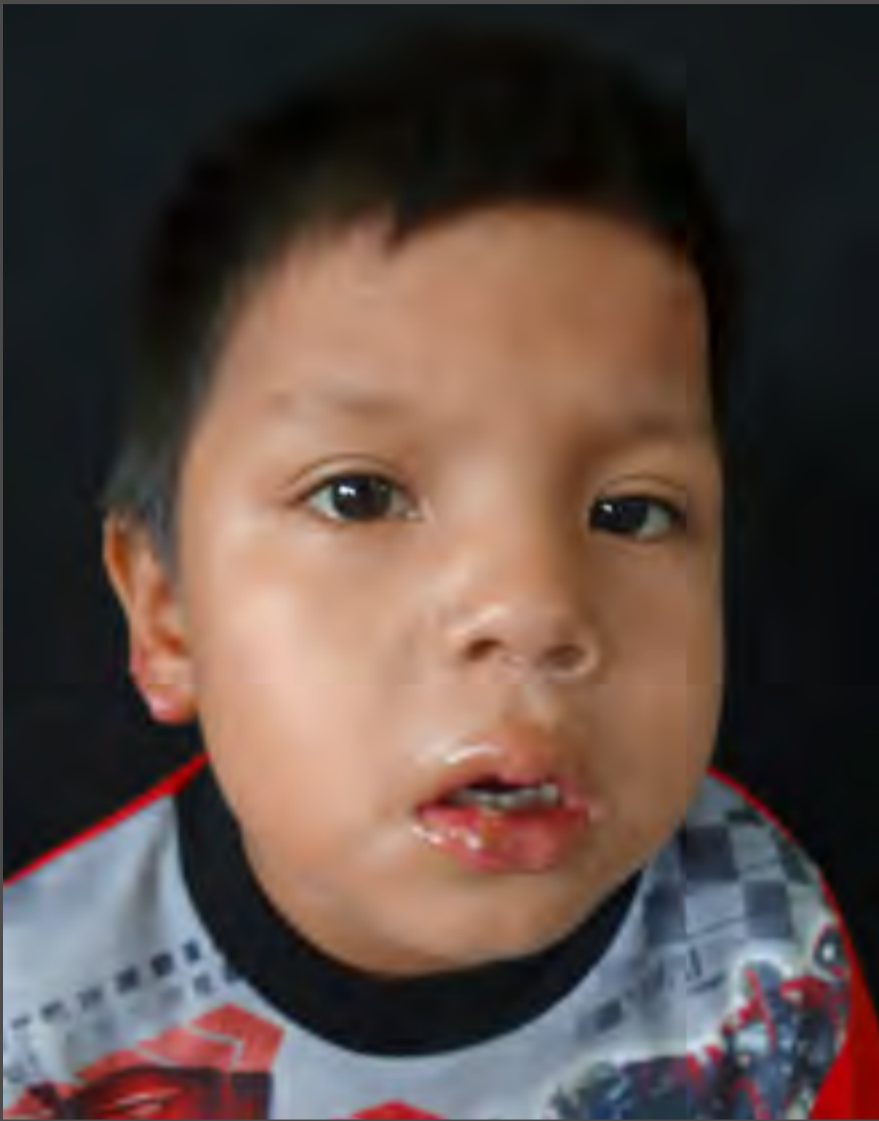
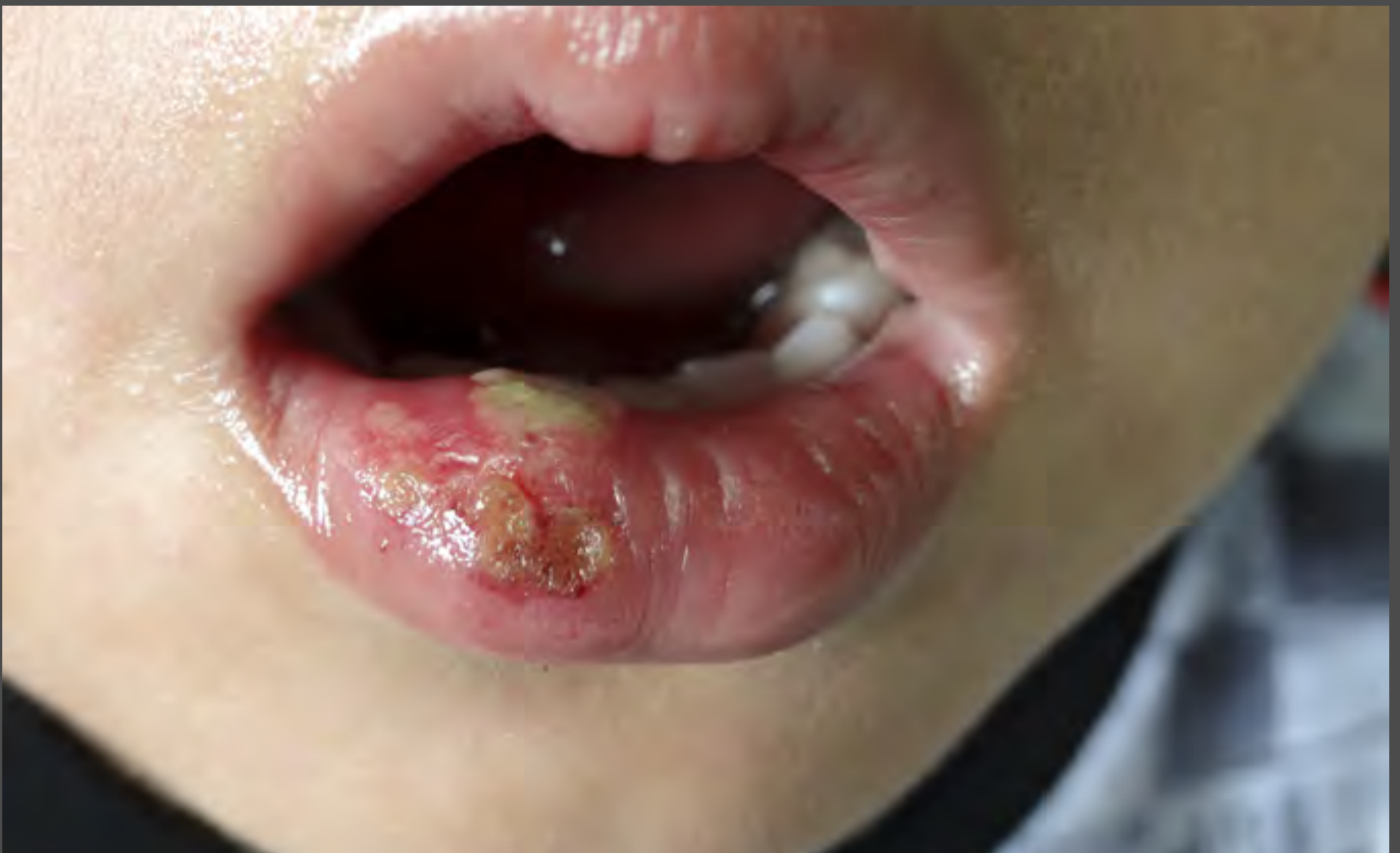
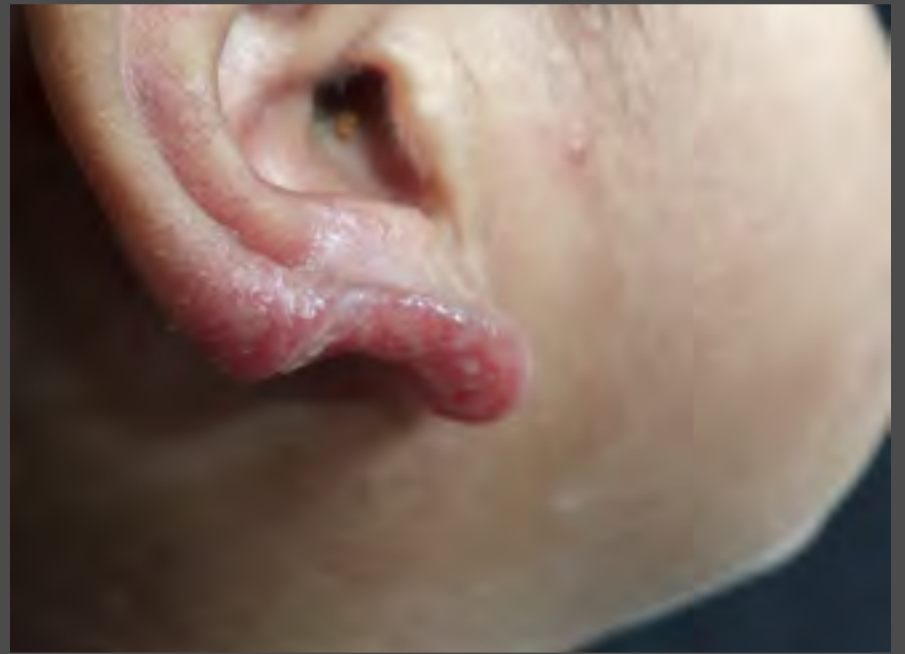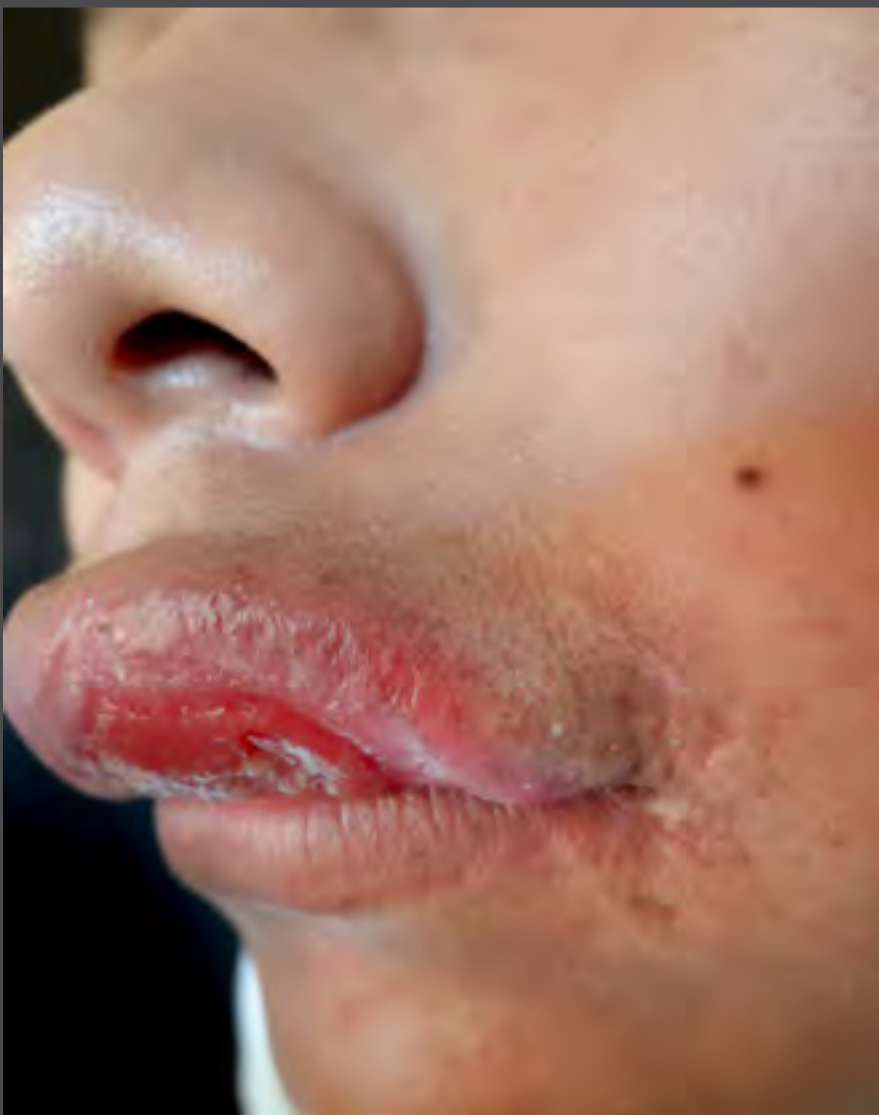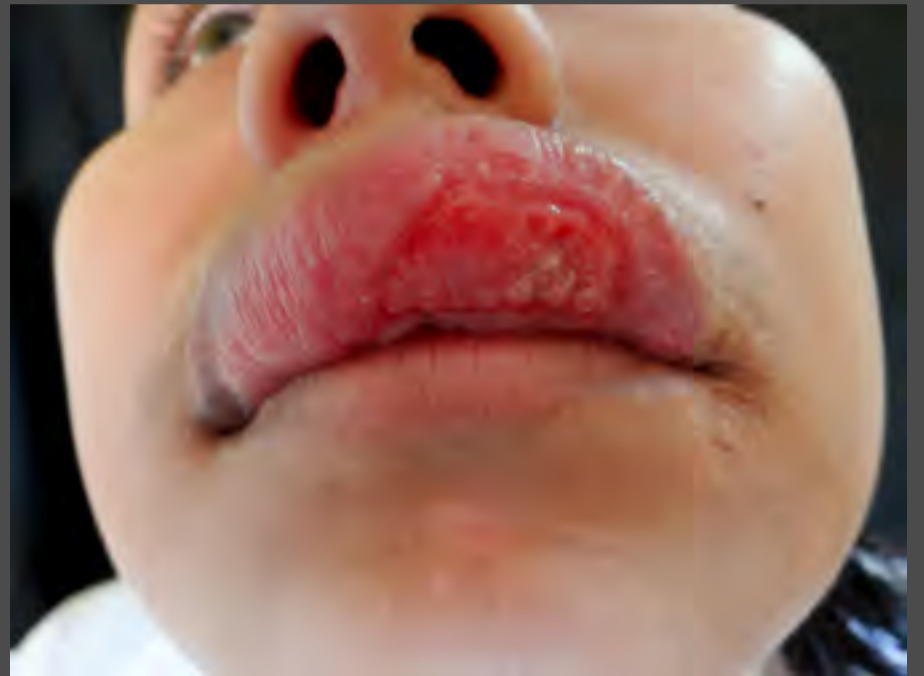Figure 4.3A, B and C.

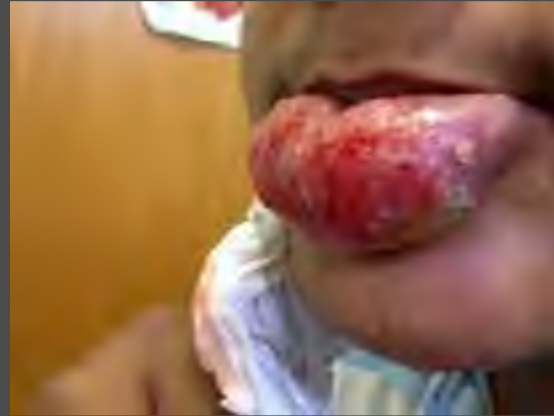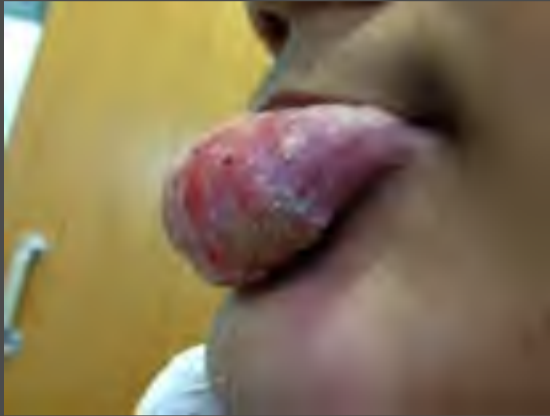Child aged 4 years, bitten two months before on the ear and lower lip. An ulcer on the ear has destroyed part of the lobe and there is an infiltrated, erythematous, crusty, and impetiginoid-appearing plaque in the mouth.



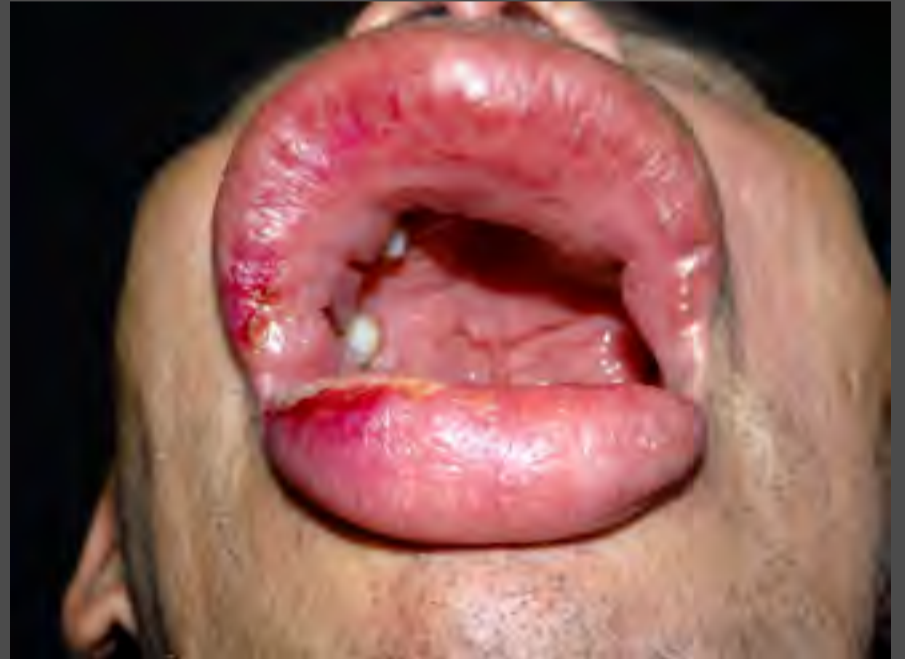

**Figures 4.4A, B and C.**

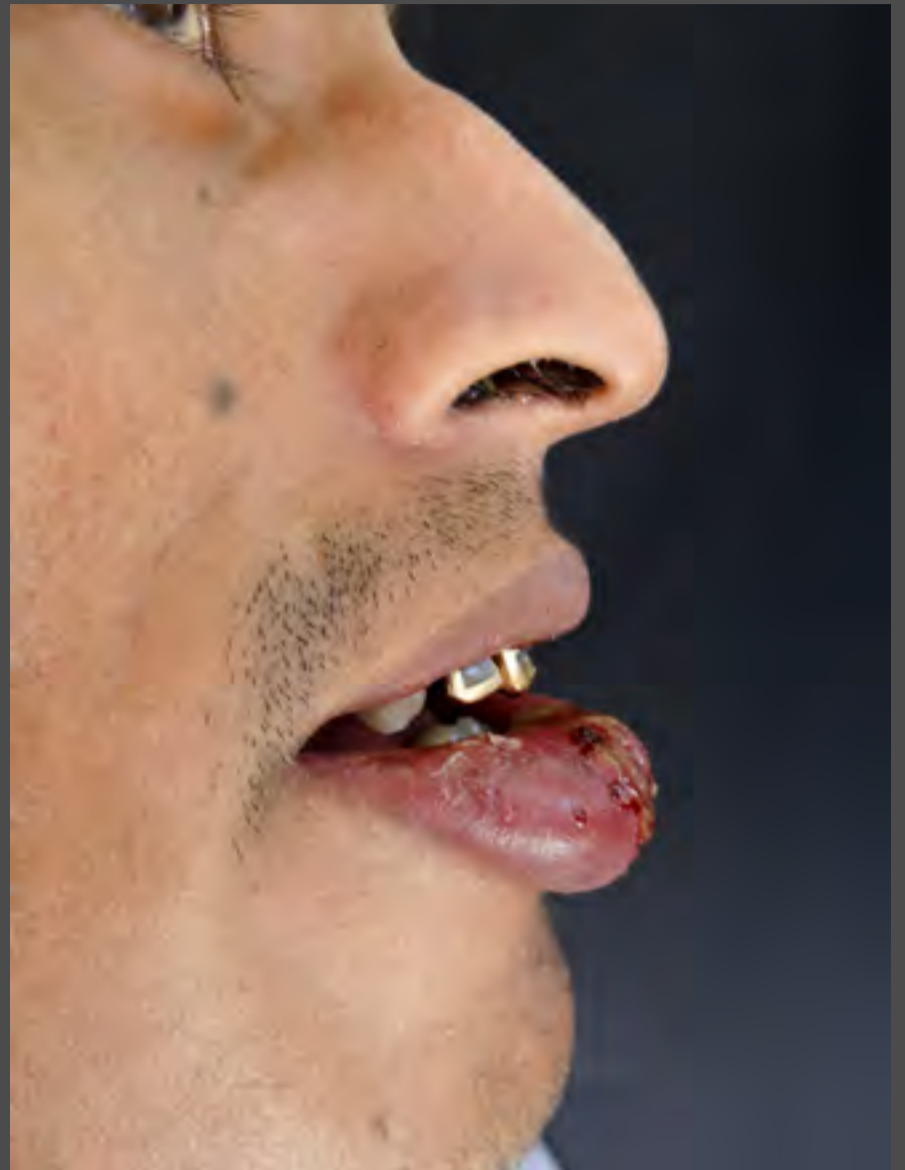
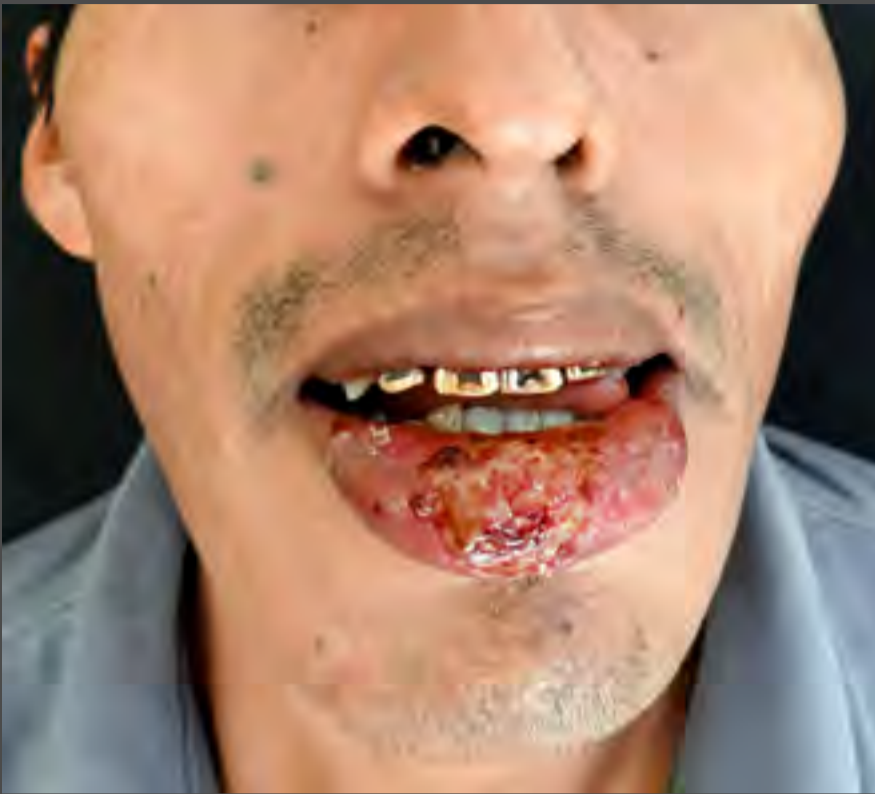Superficial ulcer 2 cm in diameter from direct inoculation of the upper lip. The entire lip has edema and significant infiltration, with no lesions in other areas.



**Figures 4.5A and B.**  
High-volume infiltrating lesion, with edema and superficial ulceration on lower lip

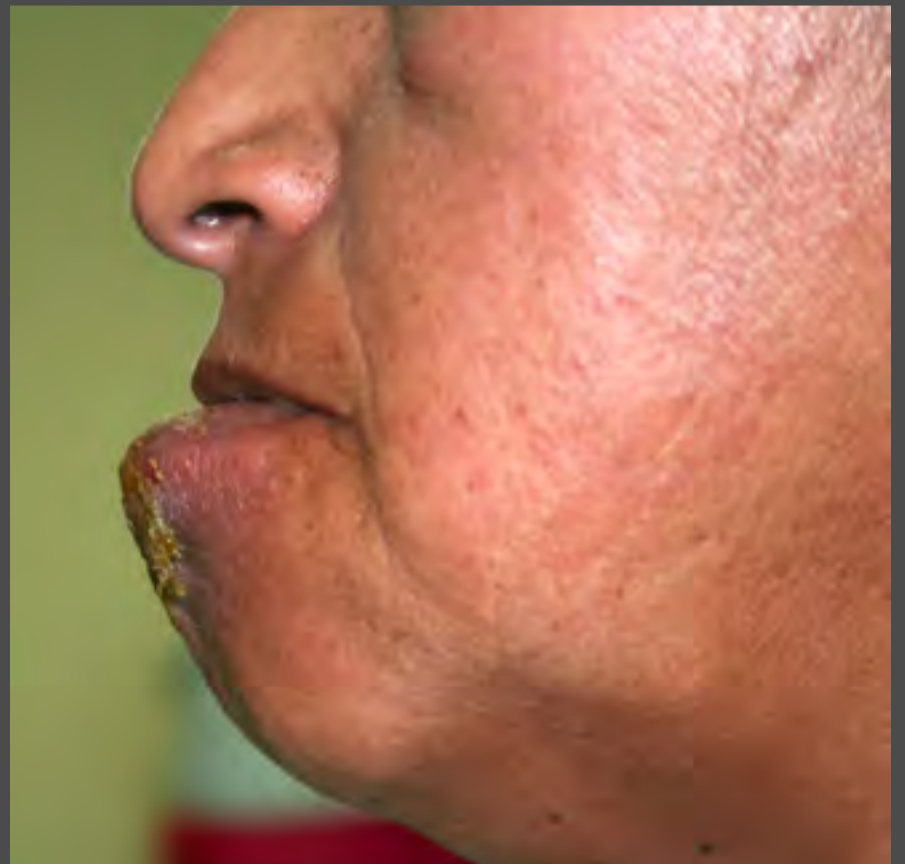
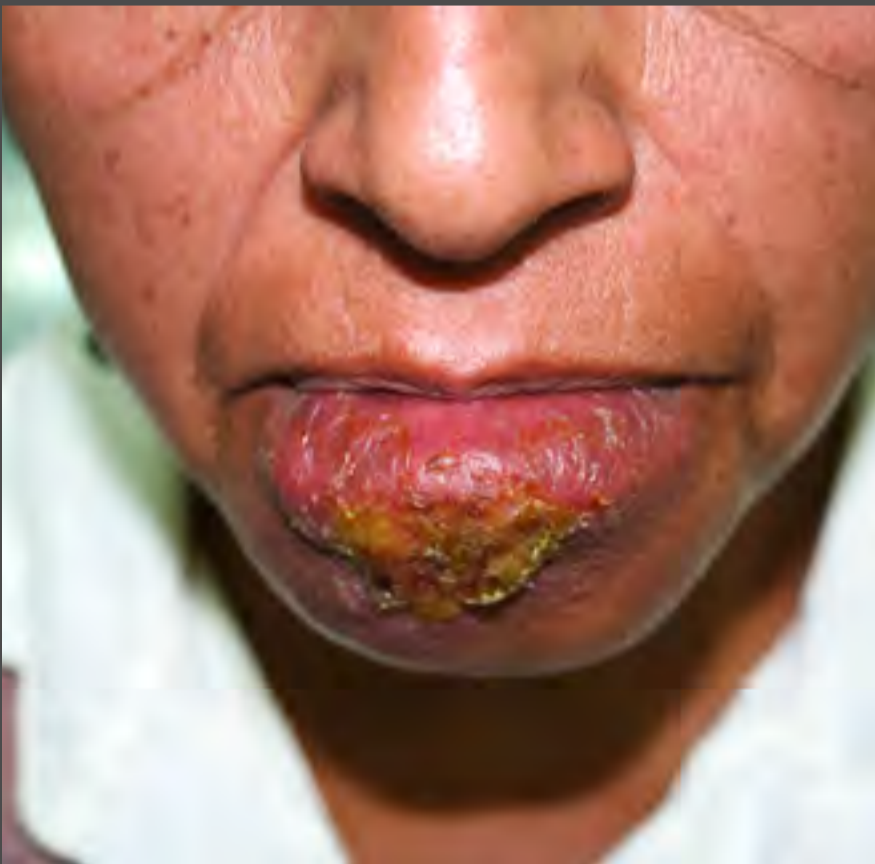
**Figures 4.6A and B.**  
Cutaneous leishmaniasis eight years earlier with irregular treatment, and with relapses on the soft palate four years ago. There is two-year-old macrocheilia, with edema and infiltration, especially on the upper lip, and granulomatous infiltration on the palate.



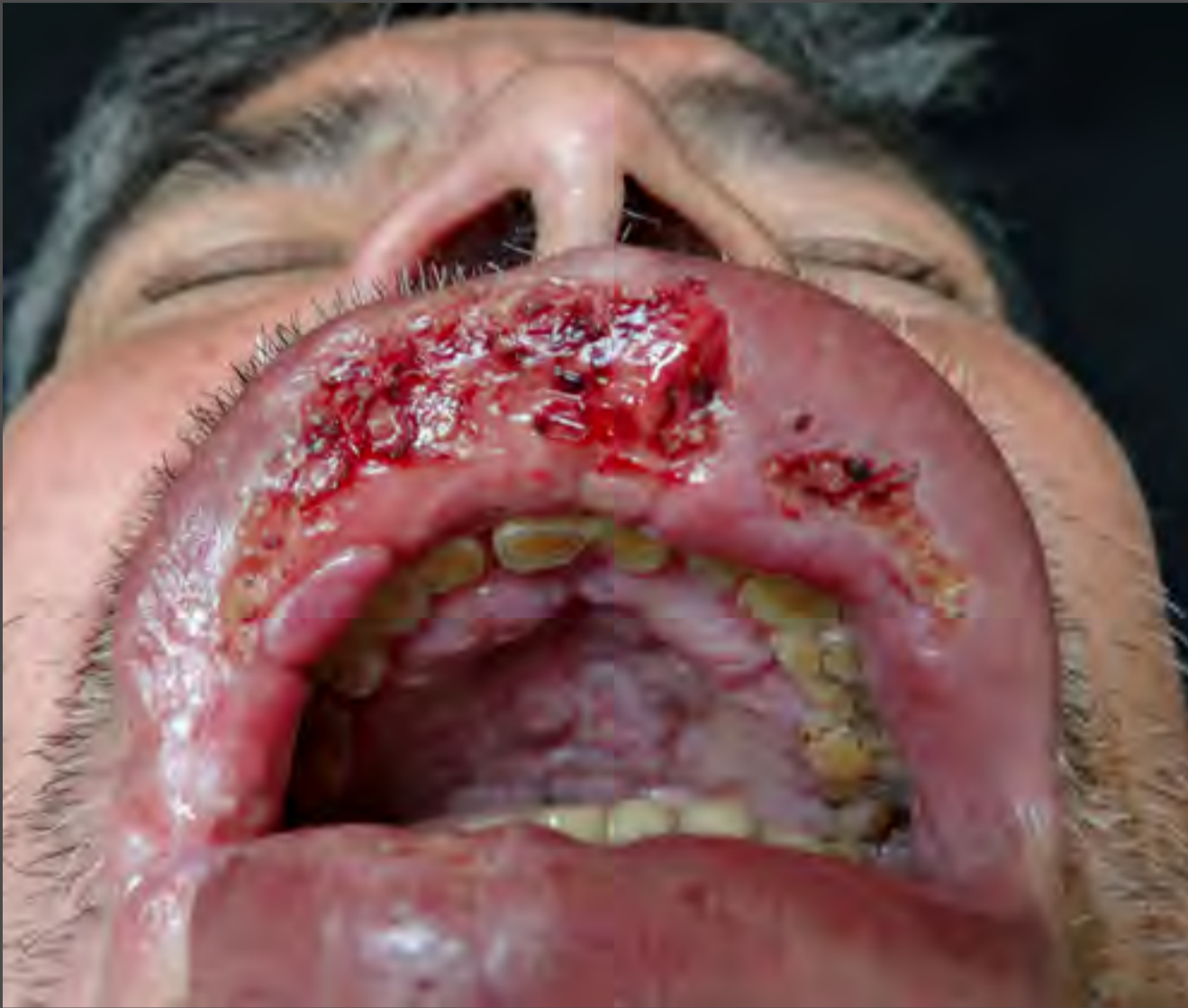**Figures 4.7A and B.**

Direct inoculation of the lower lip. Erythematous, edematous, eroded, crusted plaque, with secretion and significant soft edema. There are cervical adenopathies, with no history of previous skin lesions.



**Figures 4.7C and D.**

Initial lesion developed on the skin with spread to the lower lip, considerable edema, and abundant serosanguineous crusts.

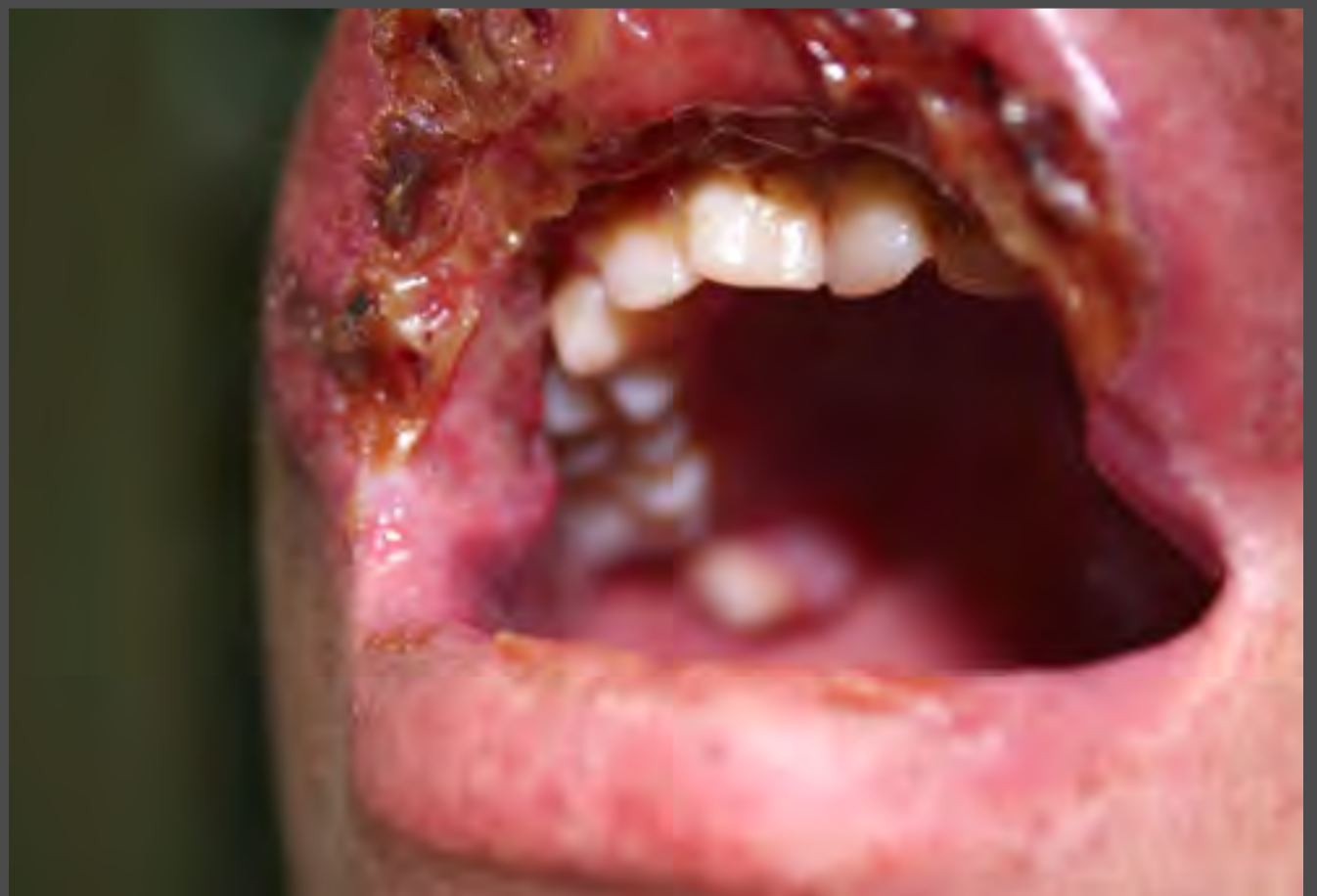

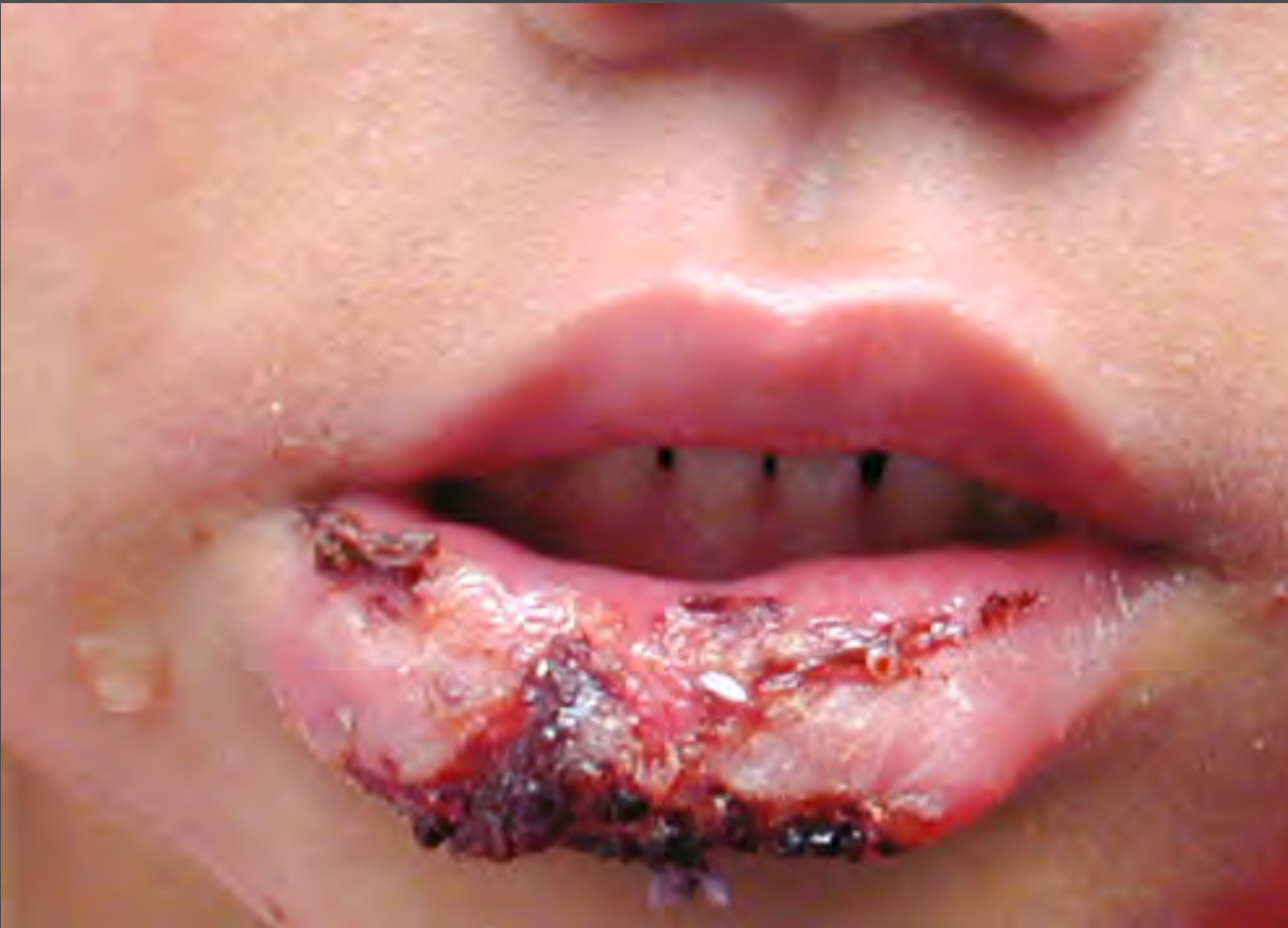**Figure 4.8.**

This person had the cutaneous form five years ago and received treatment; two years later, he presented nasal obstruction, rhinorrhea, and pain, and a year later, it affected the palate. It spread to the upper lip seven months ago, with large ulcerations, serous sanguineous crusts, and considerable edema and infiltration. Granulomatous infiltration of the palate is visible and there is a similar small lesion on the lower lip.

**Figure 4.9.**

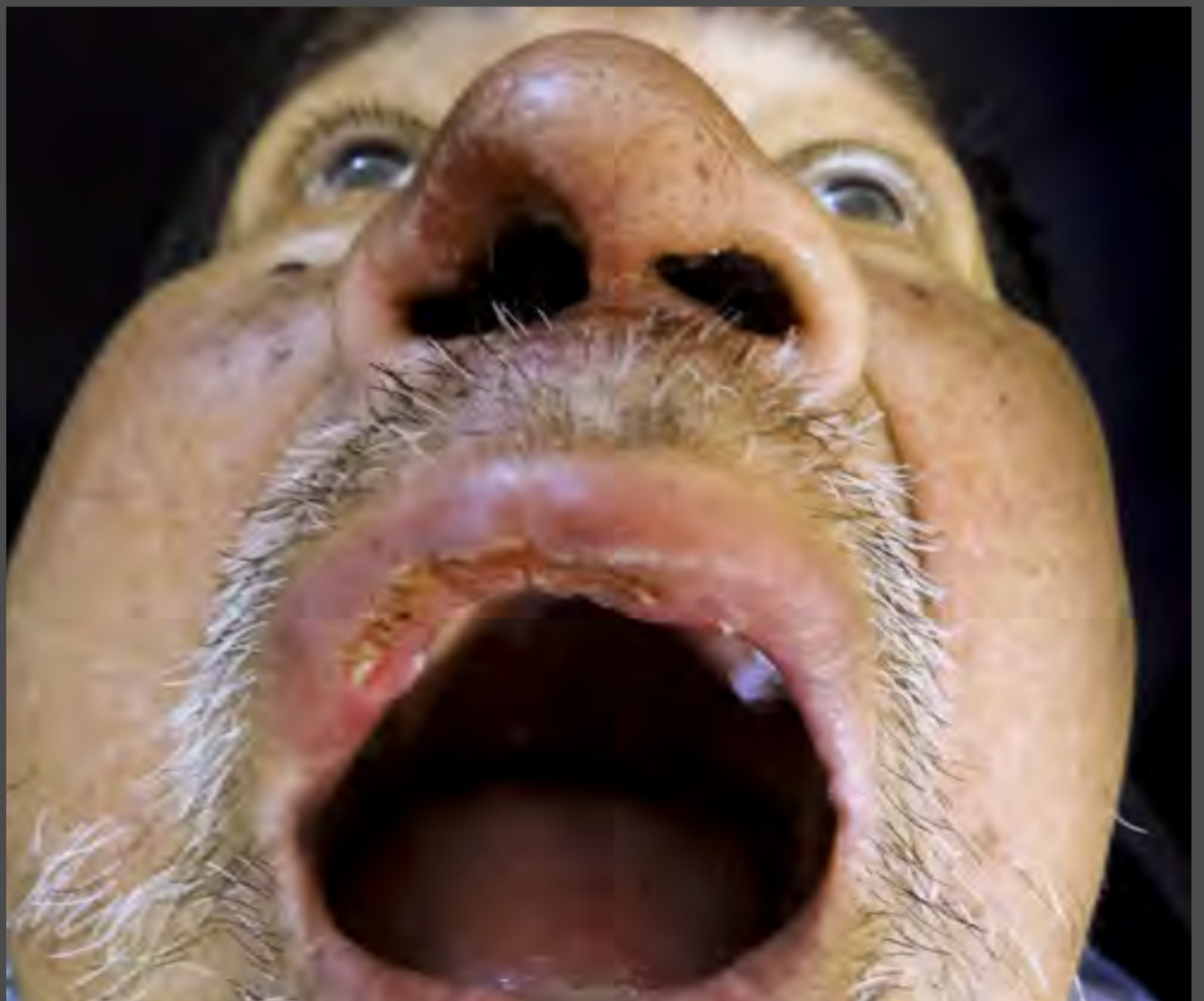Involvement by contiguity from the upper lip. There is a large superficial ulceration covered with serosanguineous crusts.

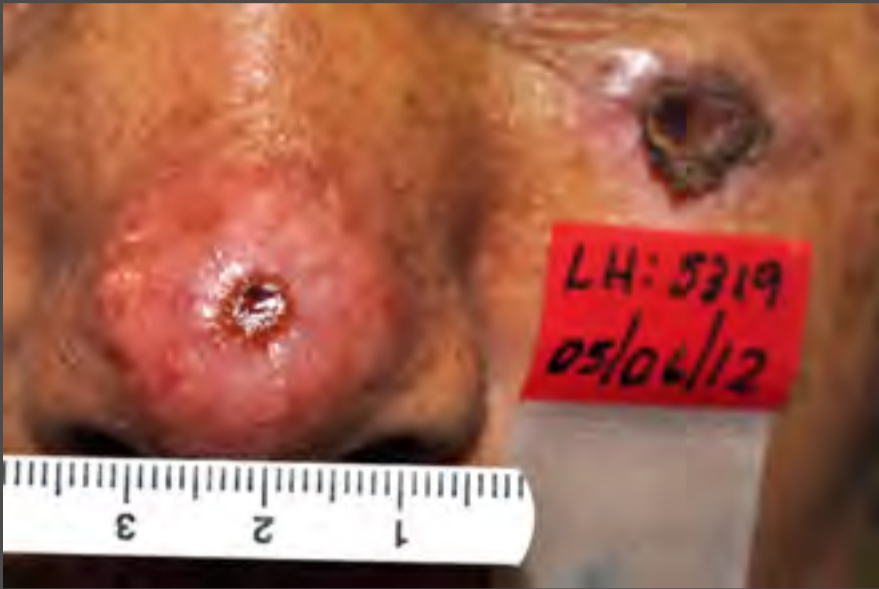



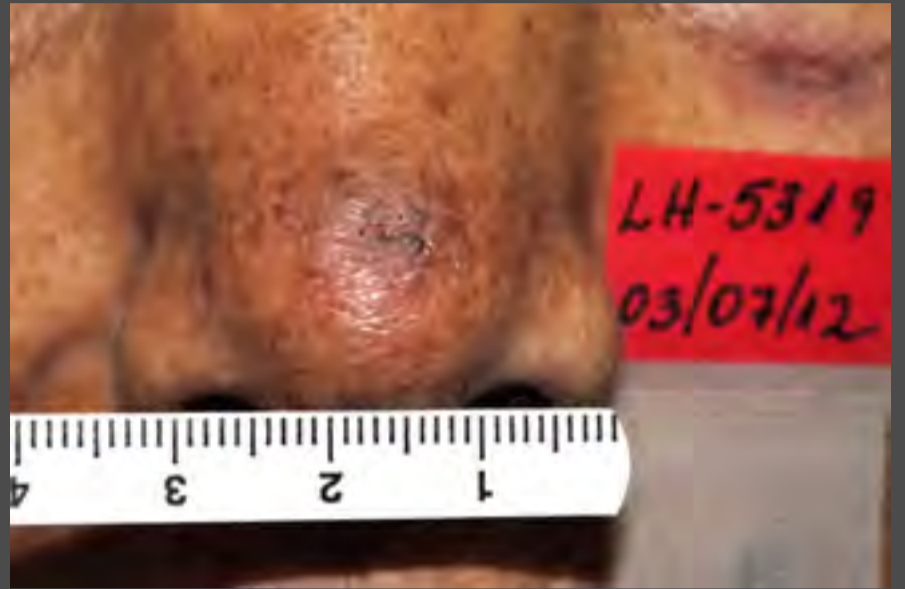**Figure 4.10.**  
Involvement of the lower lip, possibly due to the primary skin lesion by direct inoculation

**Figure 4.11.**  
Erythematous, infiltrated, ulcerated lesions in right nostril, with involvement of the columella. Ulcerated, infiltrated plaque on upper lip and granular infiltration of the soft and hard palate. It started two years ago in the nose, spread to the palate, and four months ago, to the lip. Patient has poorly controlled diabetes and denies a history of skin lesions.

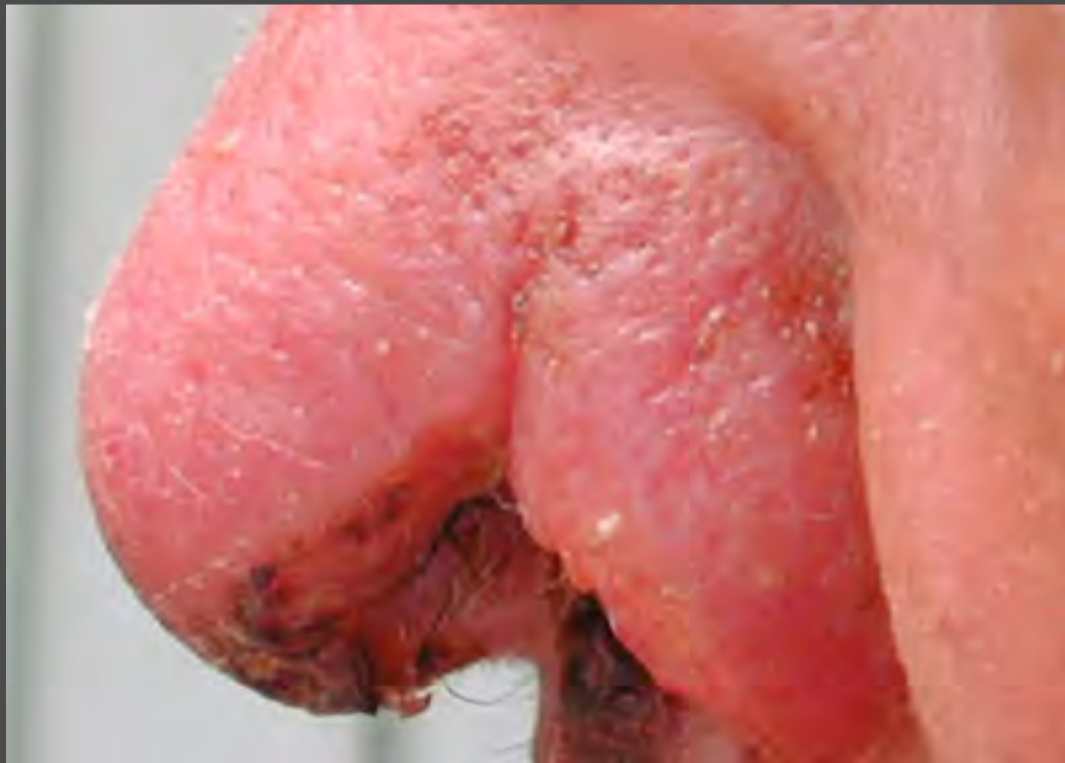



**Figure 4.12A.**  
Mucosal infiltration from contiguity to skin lesion

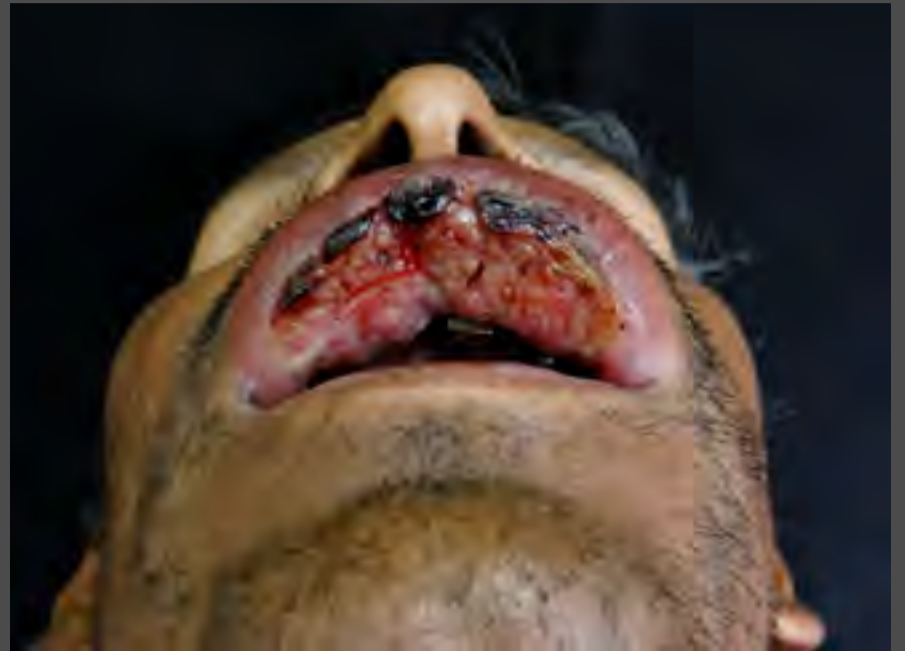
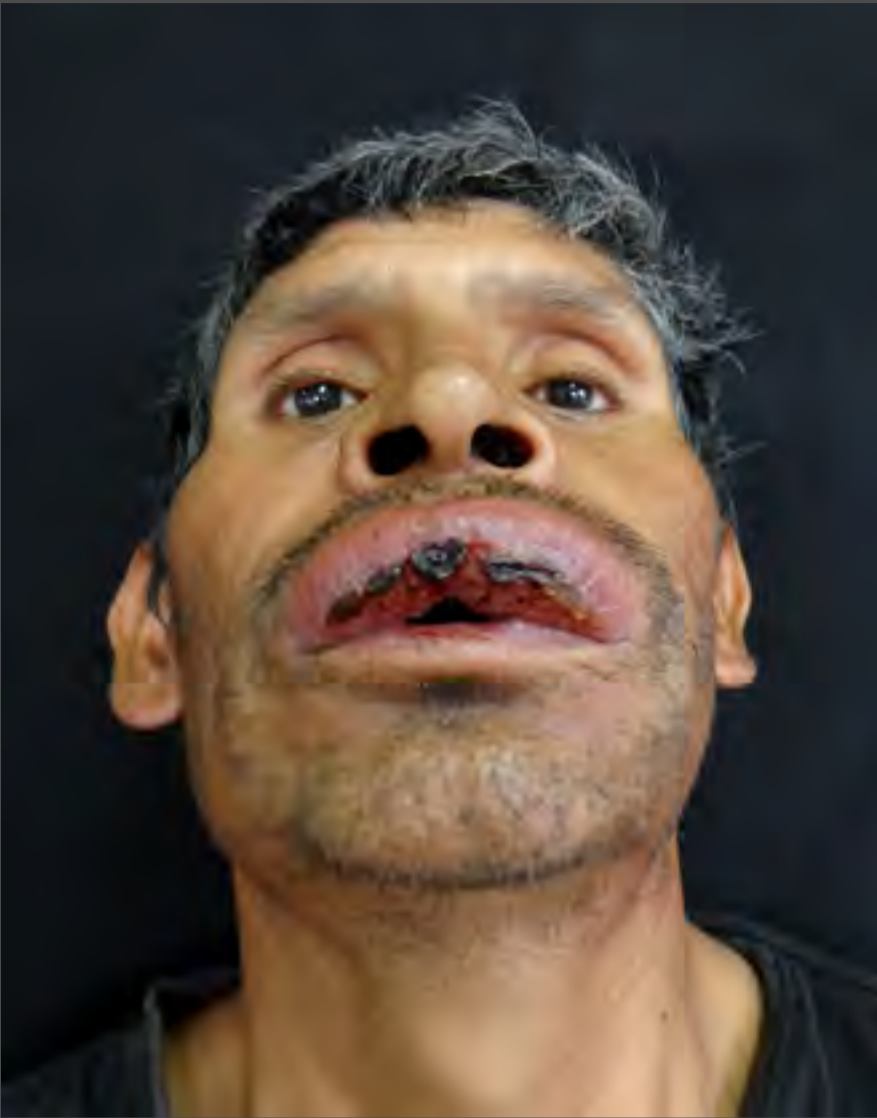
**Figure 4.12B.**  
A month later, at the conclusion of treatment, skin and mucosa have healed.



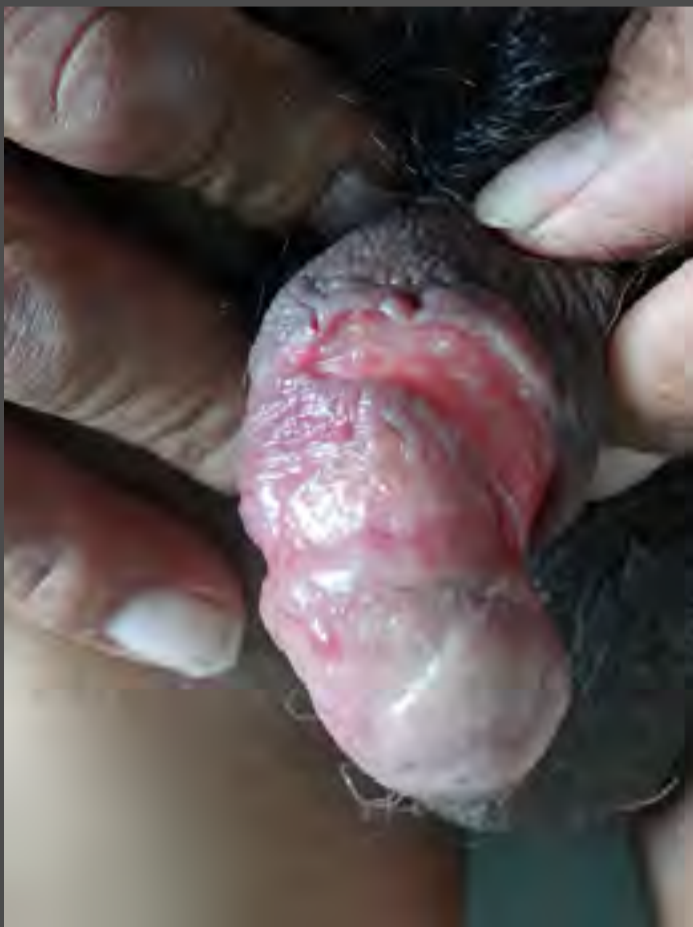**Figure 4.13.**  
Considerable inflammation and infiltration of the nose in which there is evident mucosal involvement and spread to the skin.





**Figures 4.14A and B.**

Six years earlier, cutaneous ulcer on forearm, which cured spontaneously. Three years later, nasal obstruction and bleeding, spread to the palate and, five months earlier, to the upper lip. Extensive erythematous, edematous, ulcerated plaque covered with serous sanguineous crusts. Involvement is discrete on the nasal mucosa and extensive on the palate.



**Figure 4.15.**

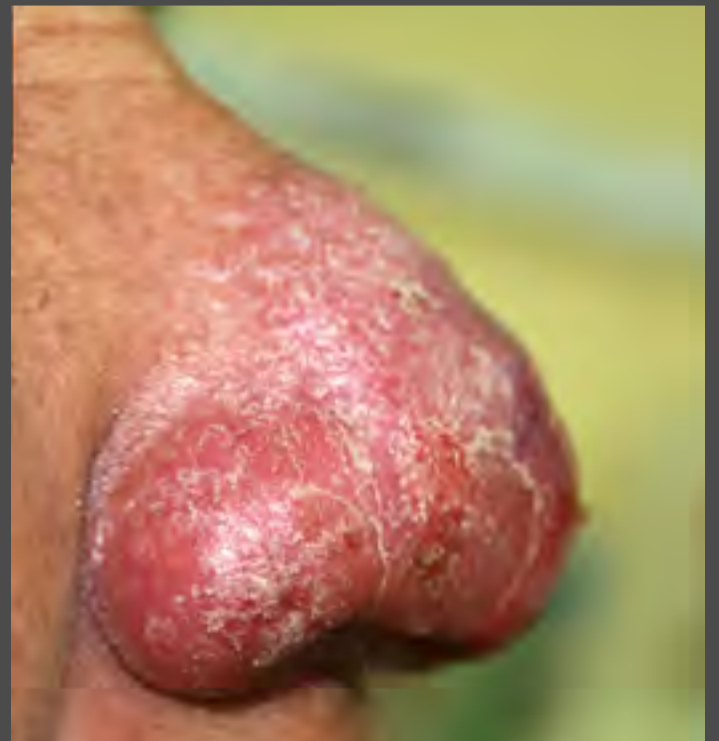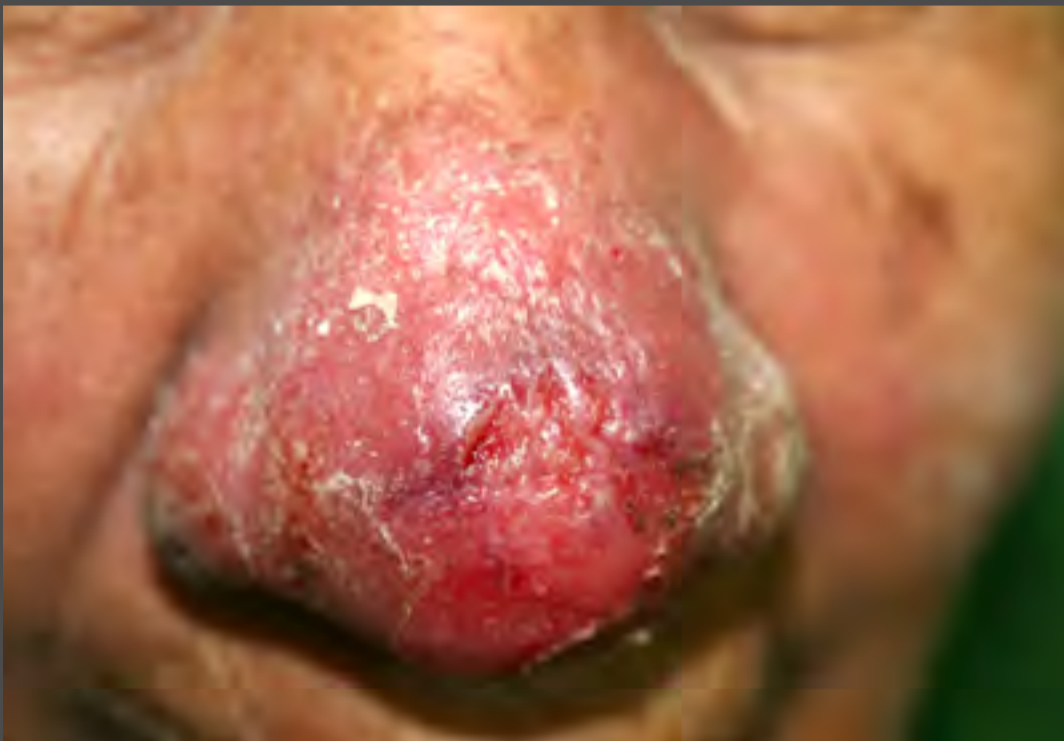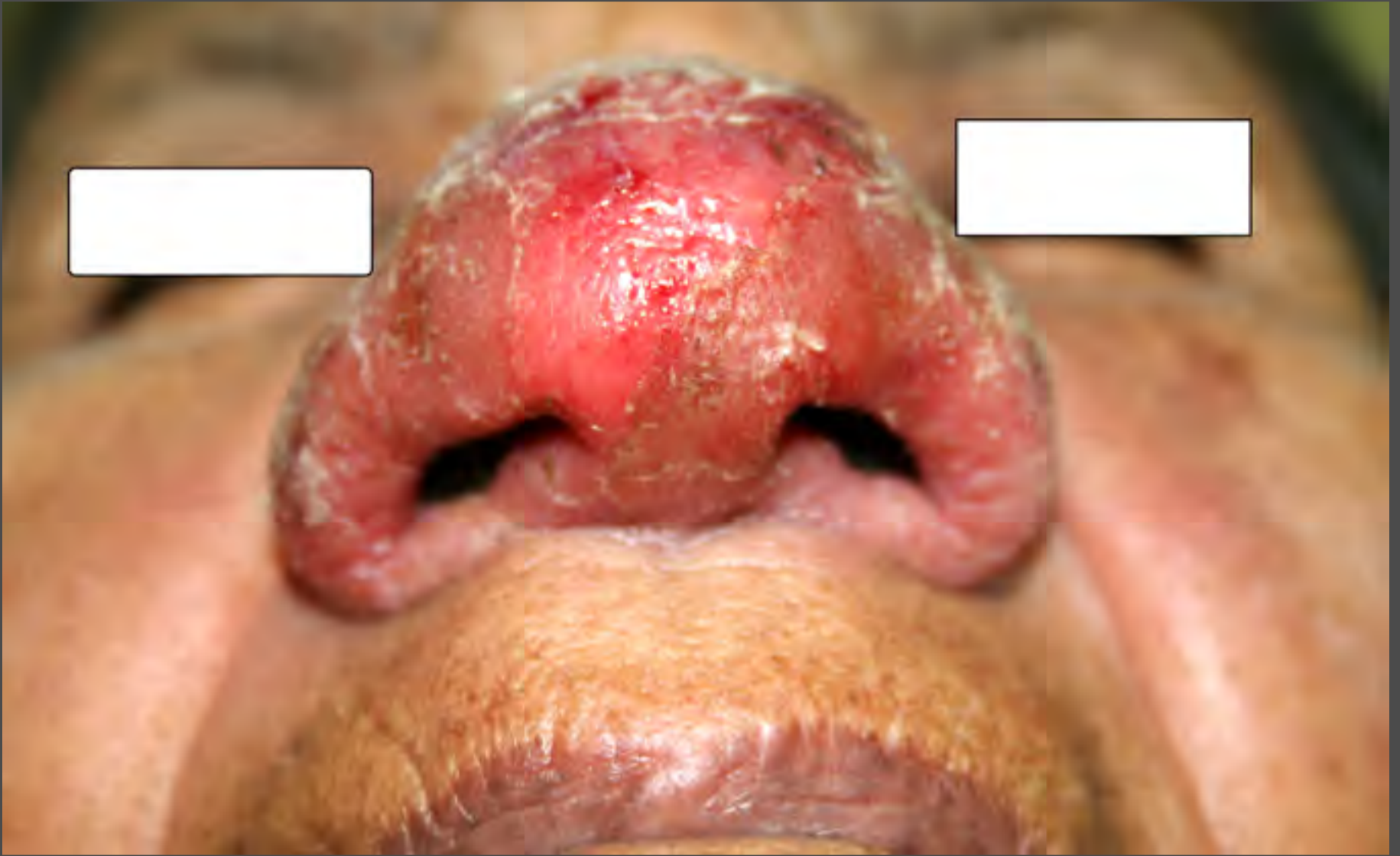
Primary mucosal form. *Leishmania (V.) braziliensis*. Ulcer on foreskin—infrequent location—that conserves the characteristics of corded edge and granular center, non-secreting, painless, slow-growing, and can last several months.

The risk that a mucosal lesion will develop has not been well specified but the evidence suggests that it ranges from 3% to 5% in the Region, although there are wide variations among countries, with an interval ranging from a few months to more than 50 years following cutaneous disease. The majority of cases (70-80%) occur in the first five years after the primary skin lesion.

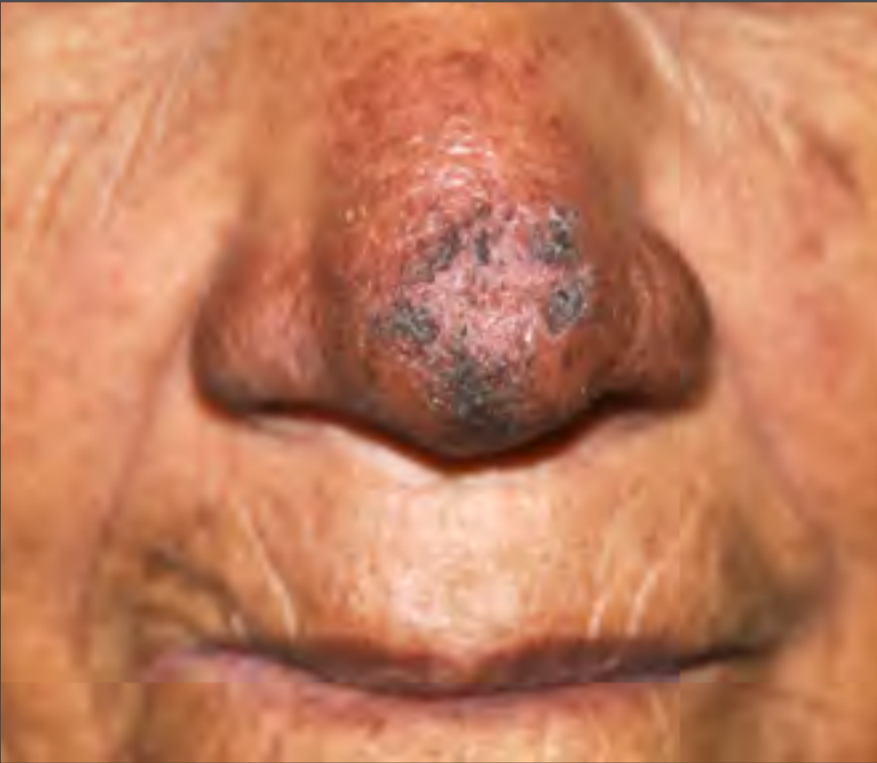The clinical stages of nasal mucosal leishmaniasis are described in *Table 4.1*, divided into five phases.

**Table 4.1.** Clinical stages of nasal involvement in mucosal leishmaniasis

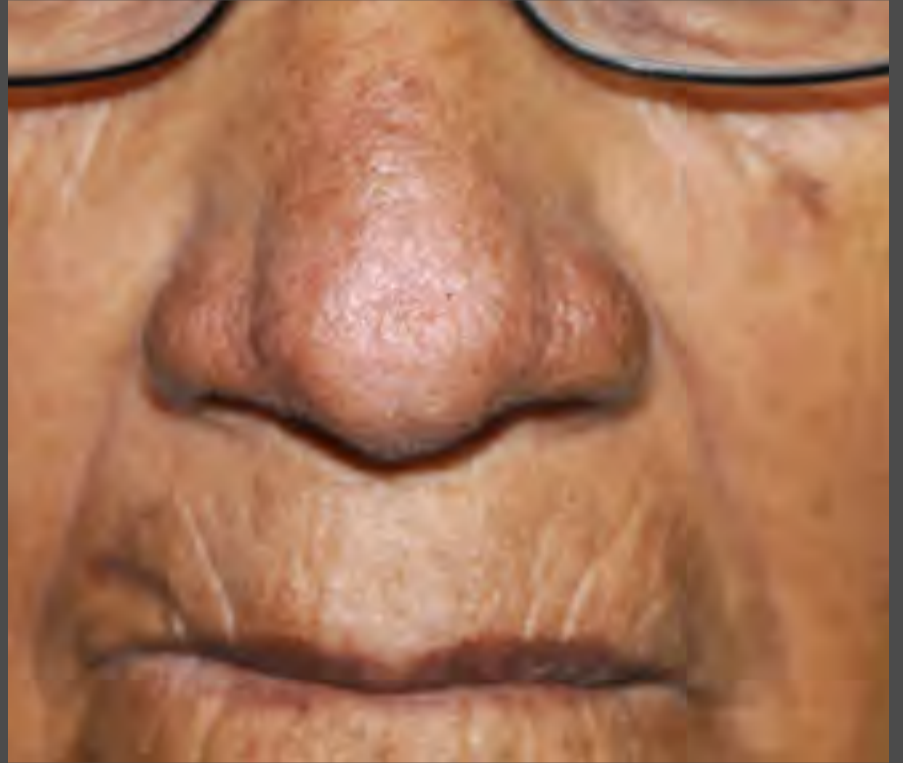I	Infiltration of mucous membranes, mild erythema and edema, no clinical symptoms. Detected during case finding for nasal disease in cutaneous leishmaniasis patients ( <i>Figures 4.16</i> ).
II	Superficial ulcers on area of moderate infiltration, with edema and erythema; patient may present pruritus, rhinorrhea, and nasal obstruction ( <i>Figures 4.17</i> ).
III	Deep ulcers with intense inflammatory reaction that involves the nasal septum. Occasional bleeding, pain, bloody rhinorrhea, crusts, and considerable nasal obstruction.
IV	Perforation of septum from necrosis of cartilage
V	Destruction of turbinates, loss of septum, collapse of nasal pyramid (also called <i>tapir nose</i> ) ( <i>Figures 4.18 and 4.19</i> ), and considerable functional impairment.



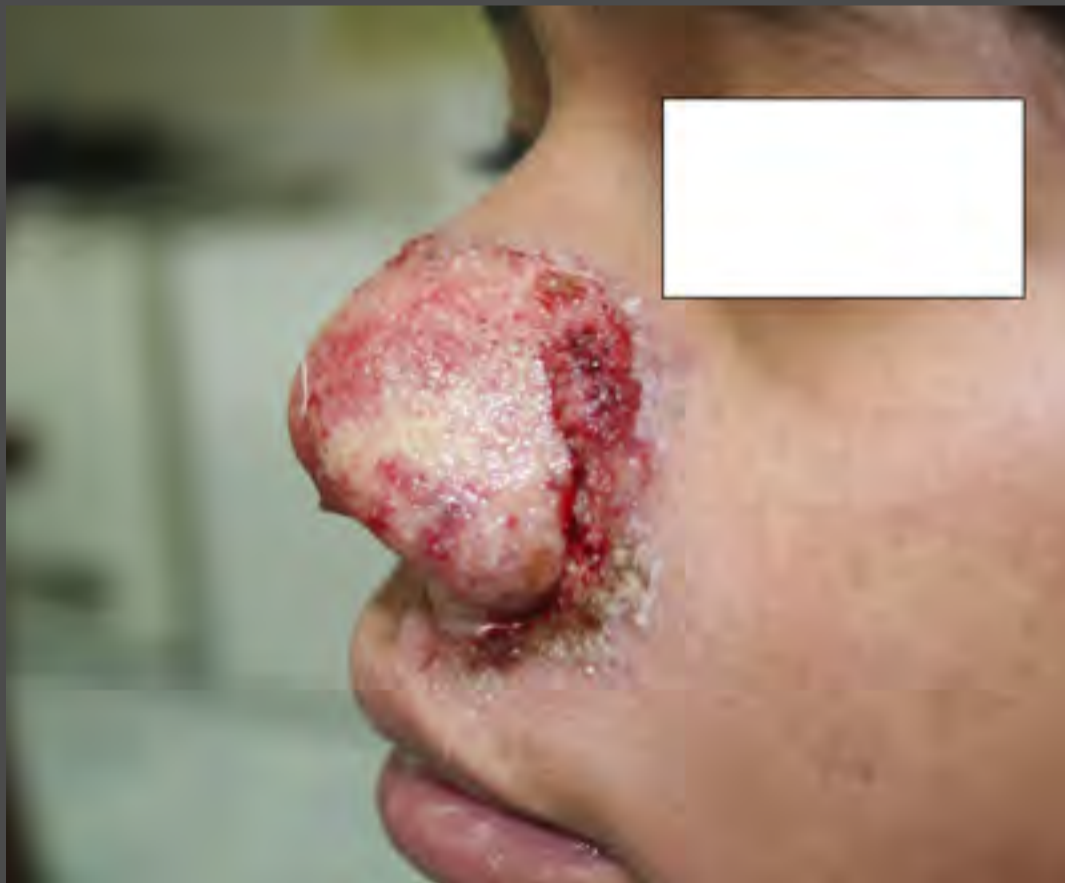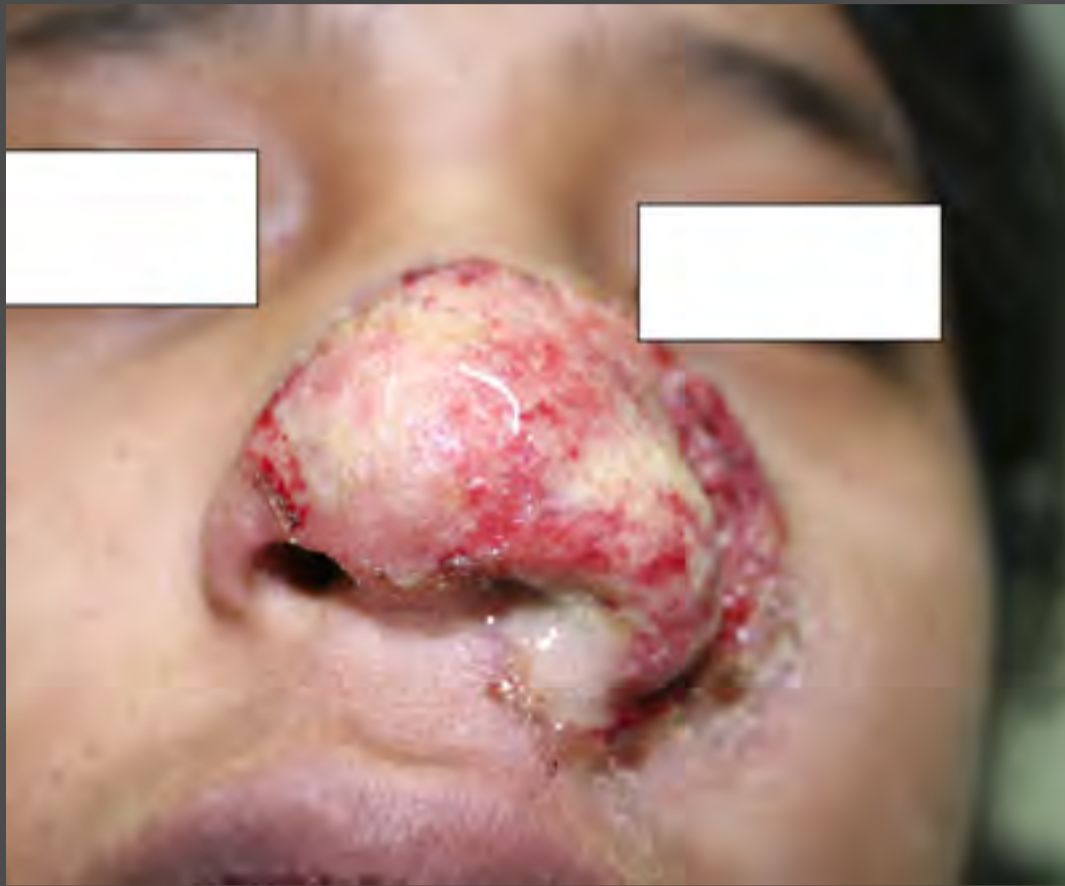Figures 4.16A, B and C.  
Cutaneous involvement with spread by contiguity to nasal mucosa



**Figure 4.16D.**  
At the conclusion of treatment, only mild hyperpigmentation persists.

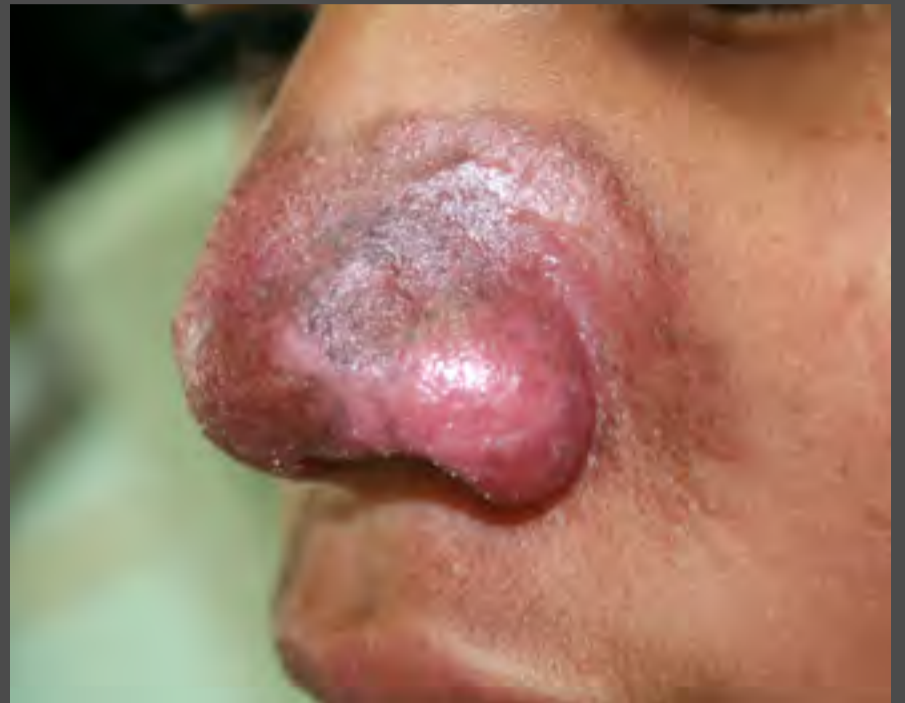
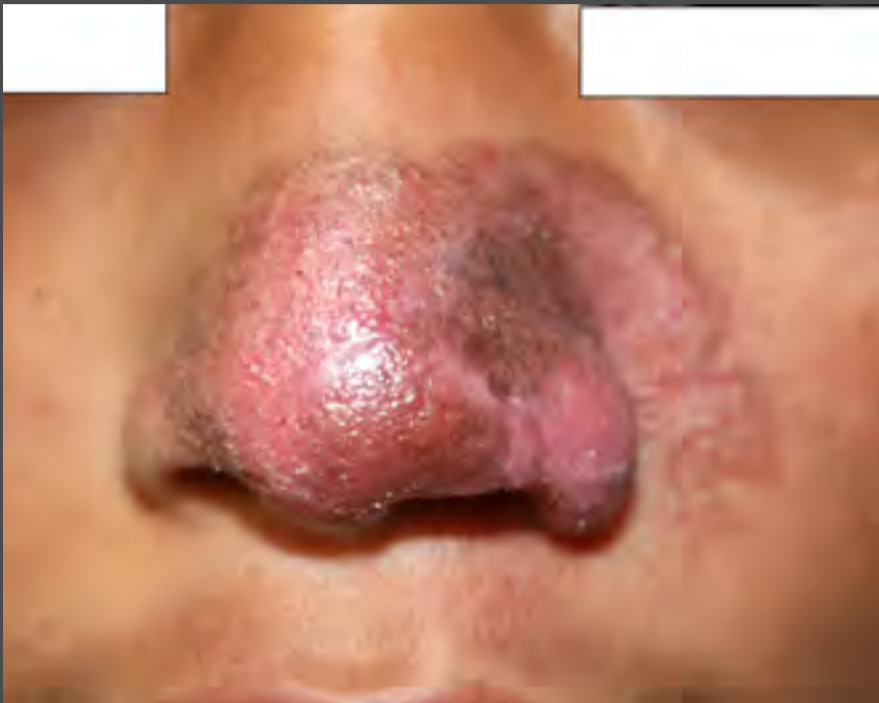
**Figure 4.16E.**  
Three and a half months after beginning treatment, there is healing without hyperpigmentation.



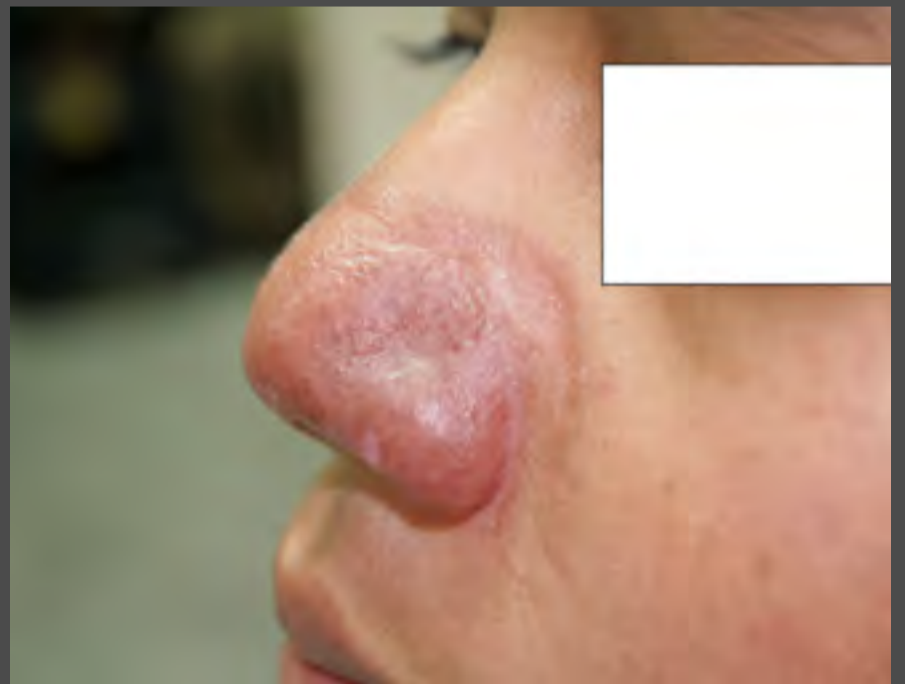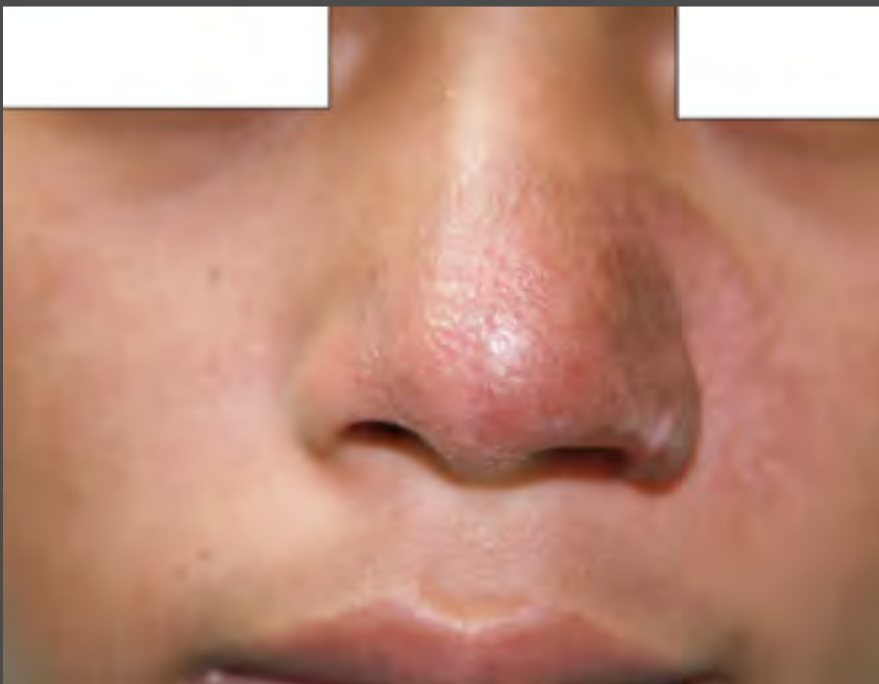**Figures 4.17A and B.**

Before beginning treatment, there is considerable infiltration of skin and nasal mucosa with severe acute inflammation.



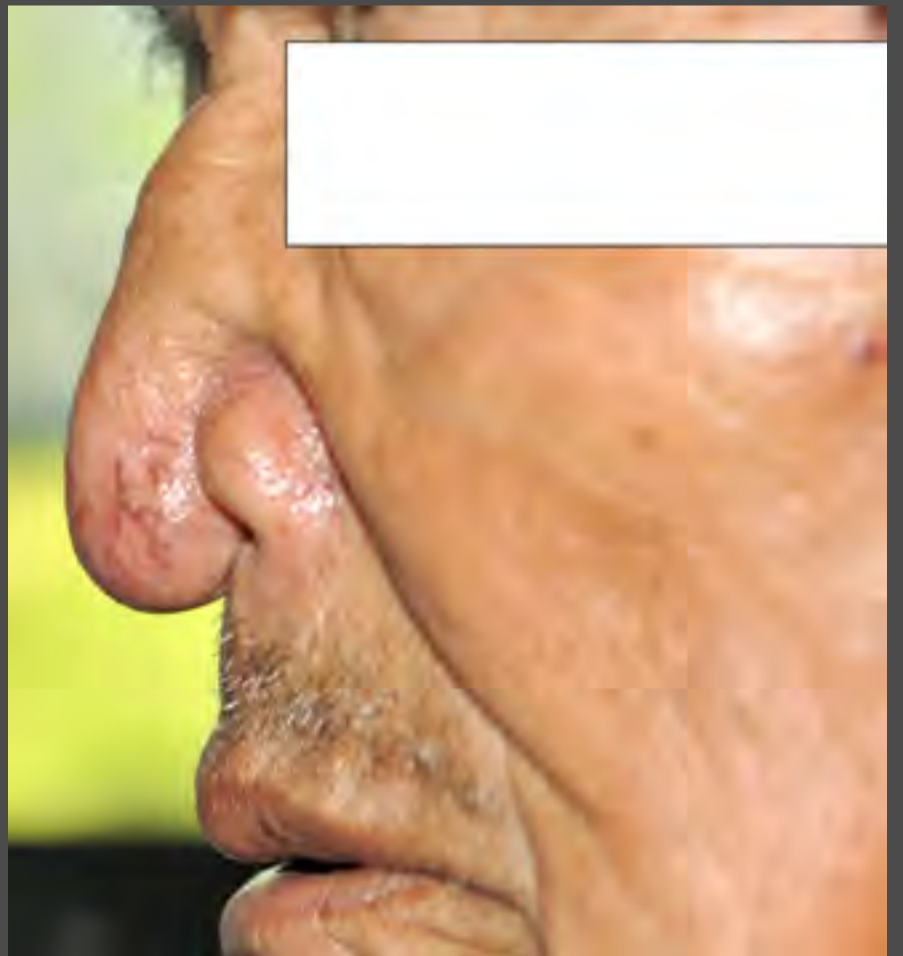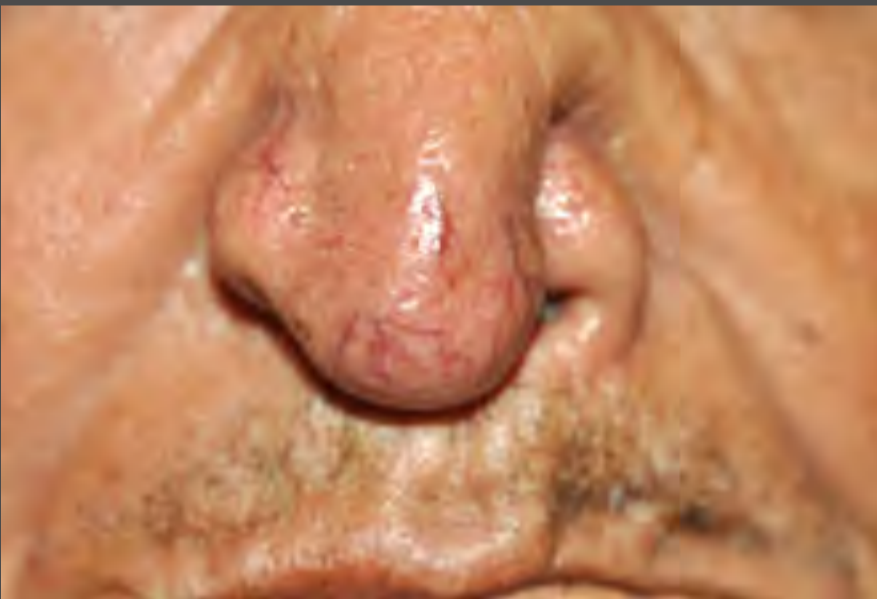
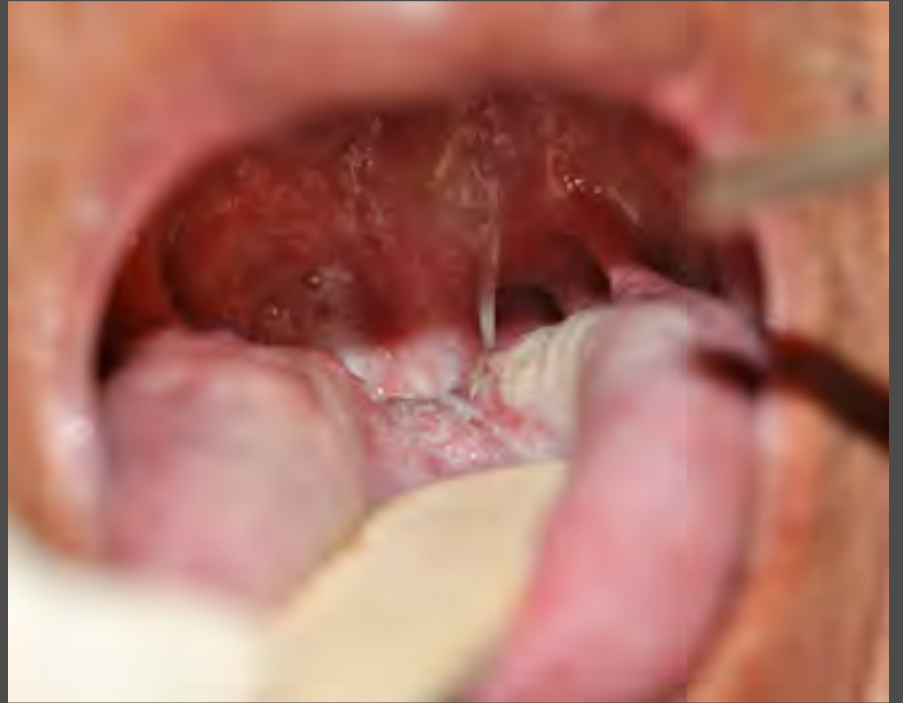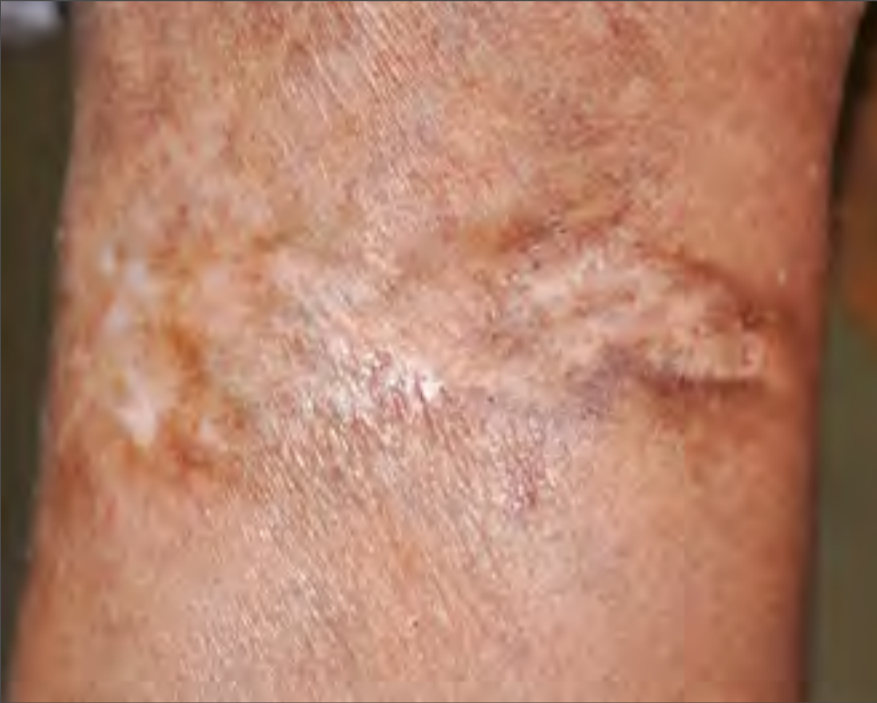**Figures 4.17C and D.**

At the end of treatment, clinical improvement is evident, with persistence of slight infiltration and hyperpigmentation.



**Figures 4.17E and F.**

One month after beginning treatment, there is no infiltration and limited hyperpigmentation persists.



**Figures 4.18A, B, C and D.**

The following are present at the beginning of treatment: A) scar from cutaneous ulcer cured 46 years earlier; B) granulomatous infiltration of soft palate; C) and D) nasal deformity from destruction of the septum.



Figure 4.19.

*Tapirus terrestris*, tapir; note the drooping end of the nose.





When it affects the soft palate, the lesions are inflammatory, erythematous, and edematous with a grainy, cobblestone appearance; they tend to be proliferative and, in the most severe cases, can give rise to a cross-like sign, known as “*Escomel’s cross*.” Involvement of the epiglottis, vocal cords, and trachea involves various degrees of voice loss (dysphonia or aphonia), pain with swallowing of food (dysphagia), and difficulty breathing. Patients with severe and chronic involvement are prone to intercurrent respiratory infections (aspiration pneumonia) with risk of death.

*Table 4.2* presents three patterns of mucosal leishmaniasis progression: slow, medium, and rapid.

**Table 4.2.** Patterns of mucosal disease progression

Slow	Medium	Rapid
Occurs in fewer than 10% of mucosal leishmaniasis cases; the lesion remains restricted to the nasal cavity (septum and turbinates) and remains almost stationary for up to 30 years.	Most cases follow this pattern. The disease has involved, at least, the nasal and oral cavity, in a period longer than two years after the primary skin lesion. Disease starts in the nasal septum and progressively involves the other mucous membranes, in the absence of specific treatment.	Occurs in fewer than 10% of cases; multiple mucous membranes are affected in fewer than six months and the skin lesion is frequently active.

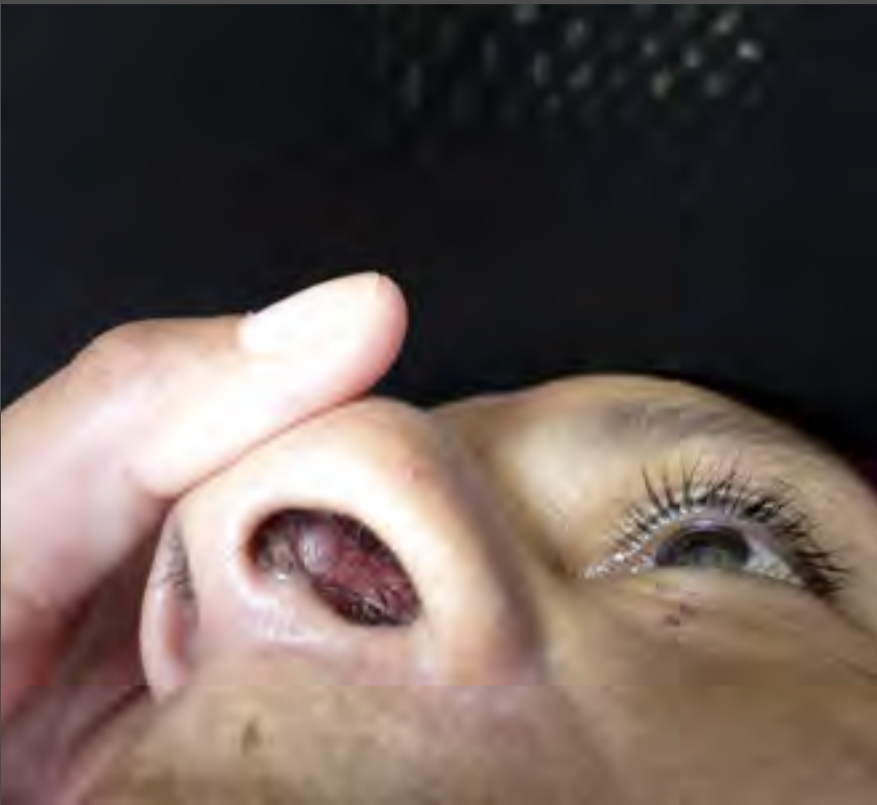These patterns are possibly correlated with the different genotypes of *L. (V.) braziliensis* strains, with infection by *Leishmania* with LRV1 virus, with differences in the immune response associated with individuals' genetics, as well as with improper treatments or insufficient dosages.

The clinical classification breaks down into three degrees: mild, moderate, and severe (*Table 4.3*). To determine the anatomical spread of lesions, assessment by an experienced otorhinolaryngologist or pneumologist is required; however, there is good correlation (approximately 80%) between clinical symptoms and anatomical spread of the disease.

The importance of this classification of disease severity is that it correlates well with therapeutic response.

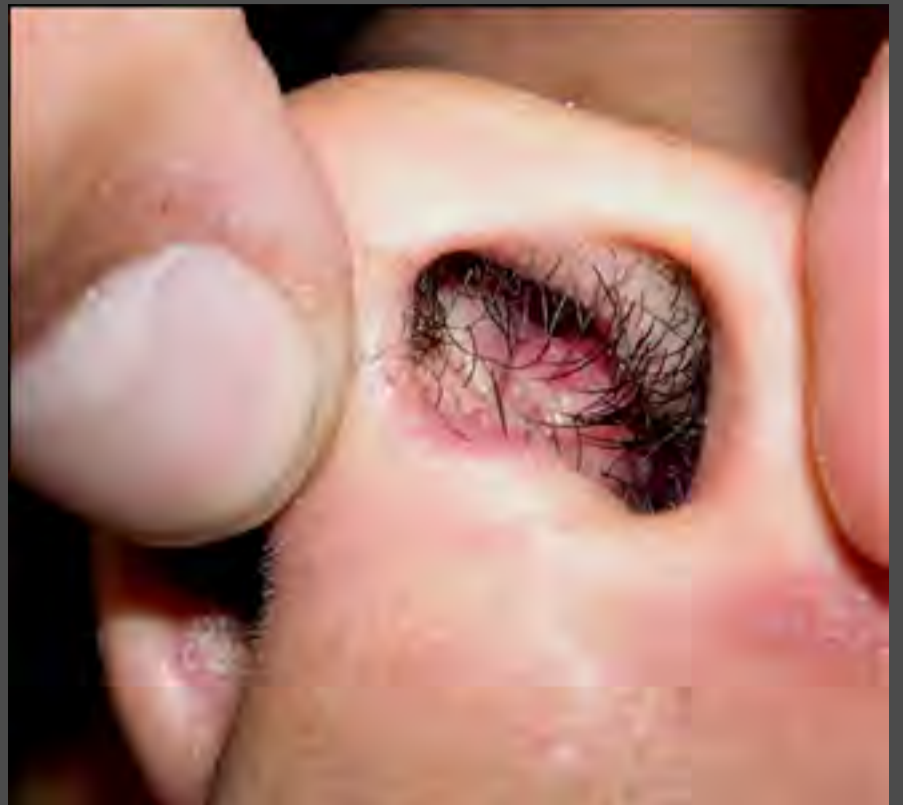Table 4.3. Levels of mucosal disease severity

Mild	Moderate	Severe
When it is limited to the nasal cavity, oropharynx, or both; usually manifested by nasal obstruction and bloody crusts ( <i>Figures 4.20 a 4.58</i> ).	When it also involves the oral cavity, supraglottis, and epiglottis; clinically, mild to moderate dysphonia and odynophagia occur ( <i>Figures 4.59 a 4.63</i> ).	When it also involves the vocal cords, subglottis, and 70% to 80% of the trachea. Clinical manifestations are significant dysphonia and odynophagia and moderate to severe difficulty breathing ( <i>Figures 4.64 a 4.74</i> ).



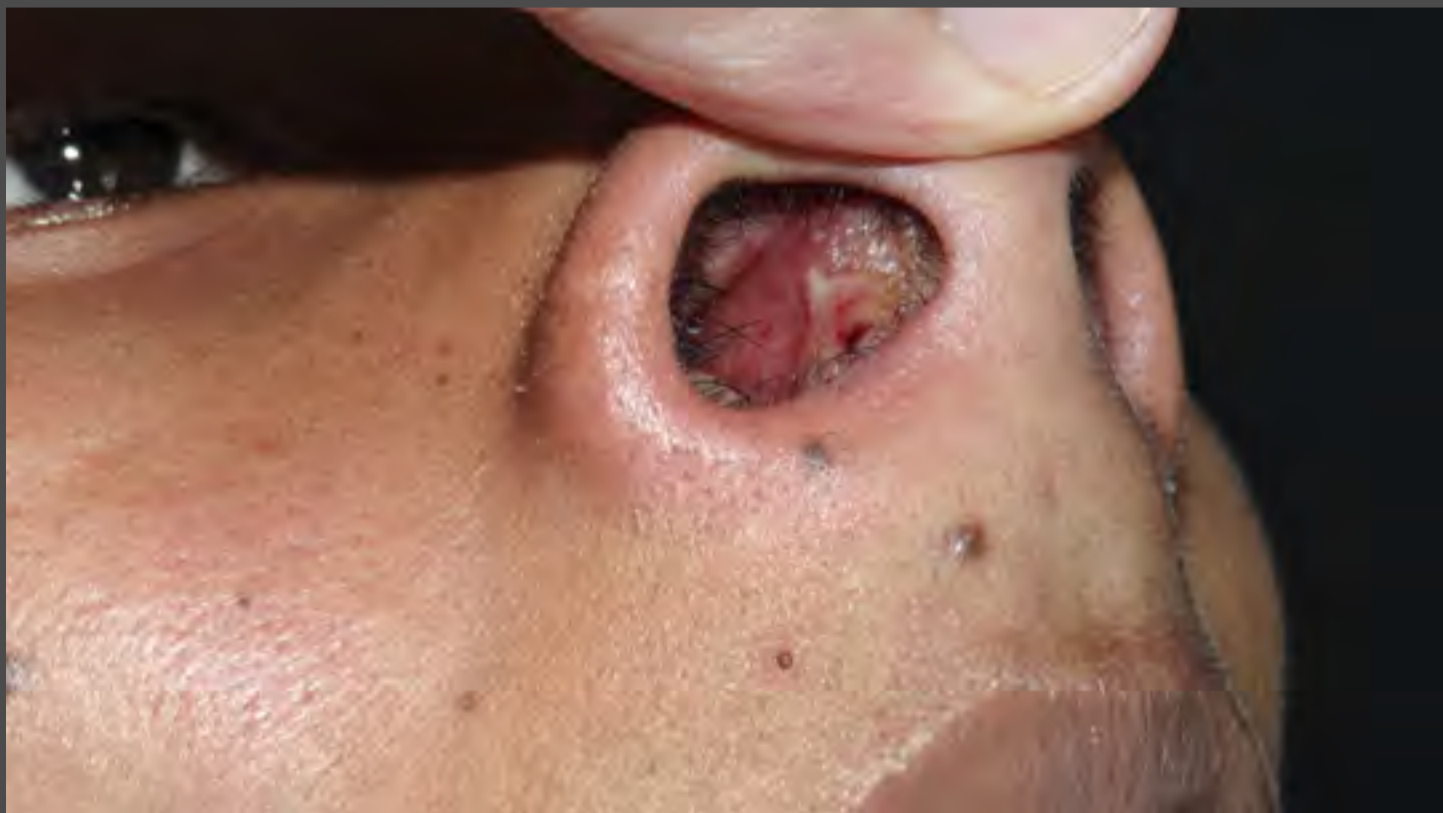**Figure 4.20A.**

Mucosal involvement starts with pruritus or mild intranasal pain and discrete serous discharge. Visible mild erythema of the mucous membrane covering the septum at its most anterior part.



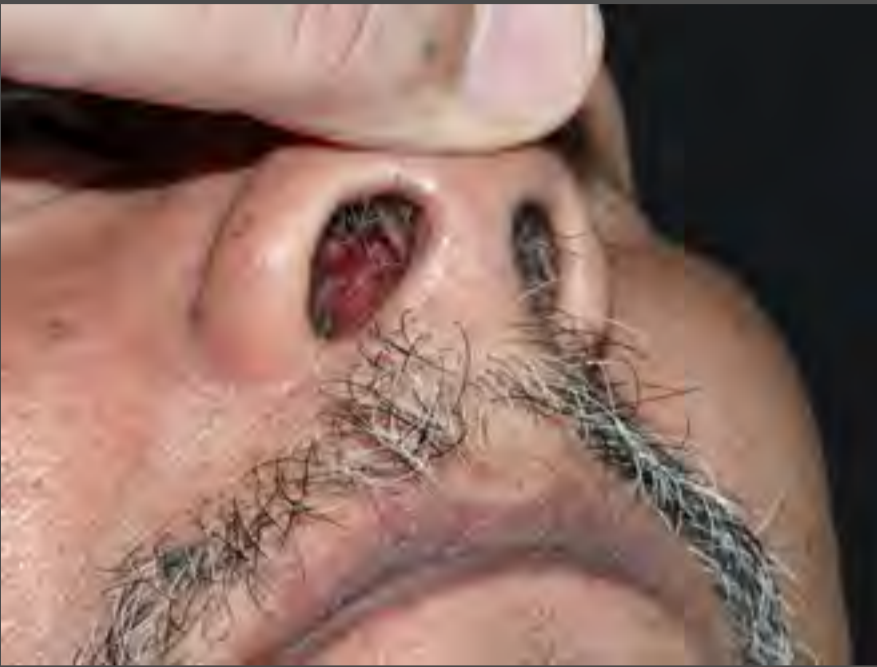**Figure 4.20B.**

Early involvement of nasal septum. Mucosal, infiltrative, proliferative lesion

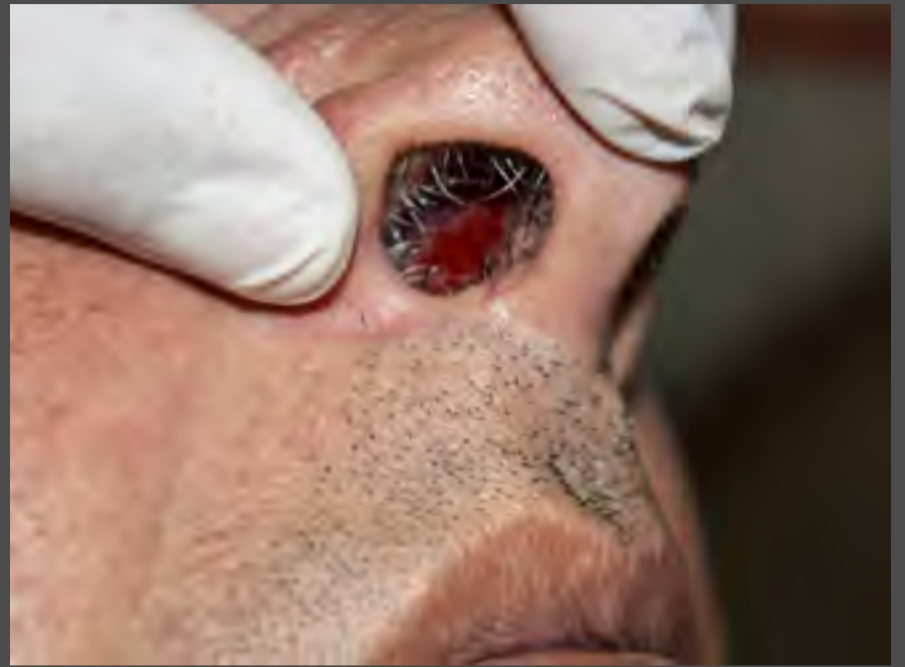

**Figure 4.21.**

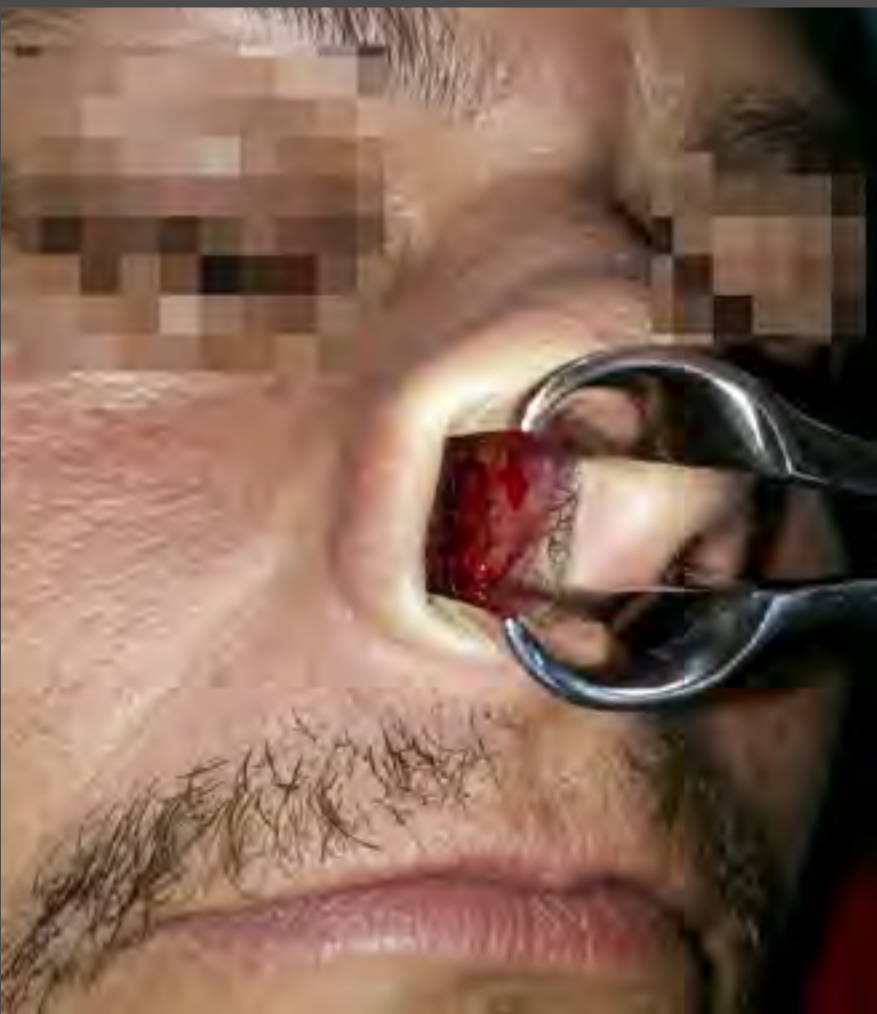As the disease progresses, there is greater discomfort, with obstruction and nasal bloody-mucus discharge. Increase in erythema, edema, and infiltration of the mucous membrane on the septum, and a small erosion from the advance of the disease or from scratching can be seen.



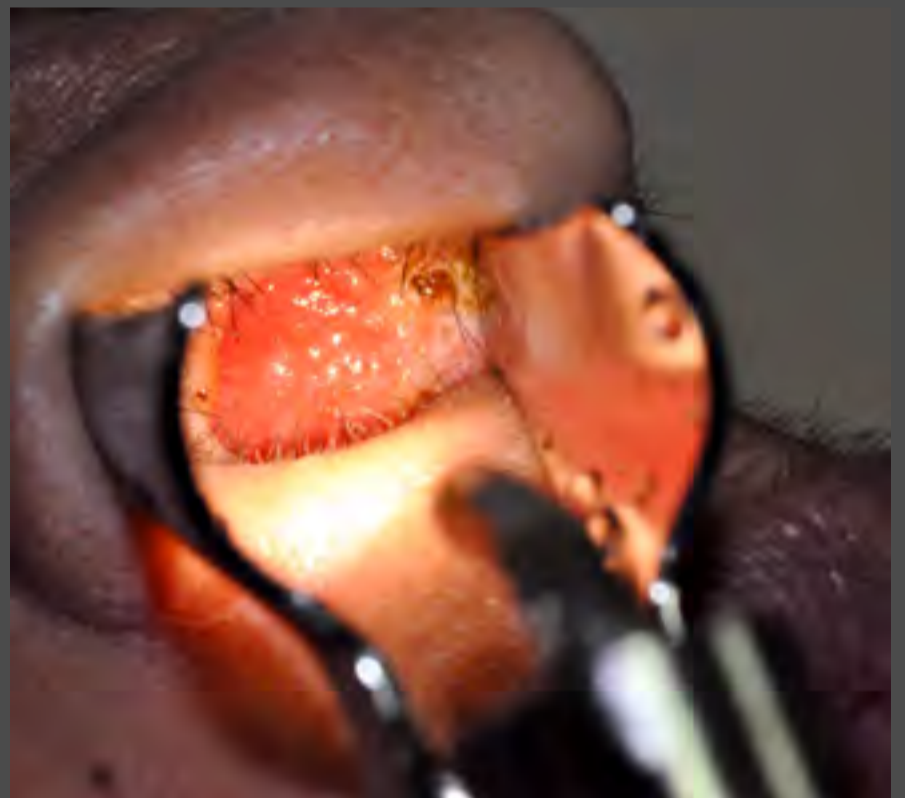**Figure 4.22.**  
Edema, infiltration, and serosanguineous crusts produce a greater sensation of nasal obstruction. Mucus tinged with fresh blood is frequent and sometimes there is little bleeding.



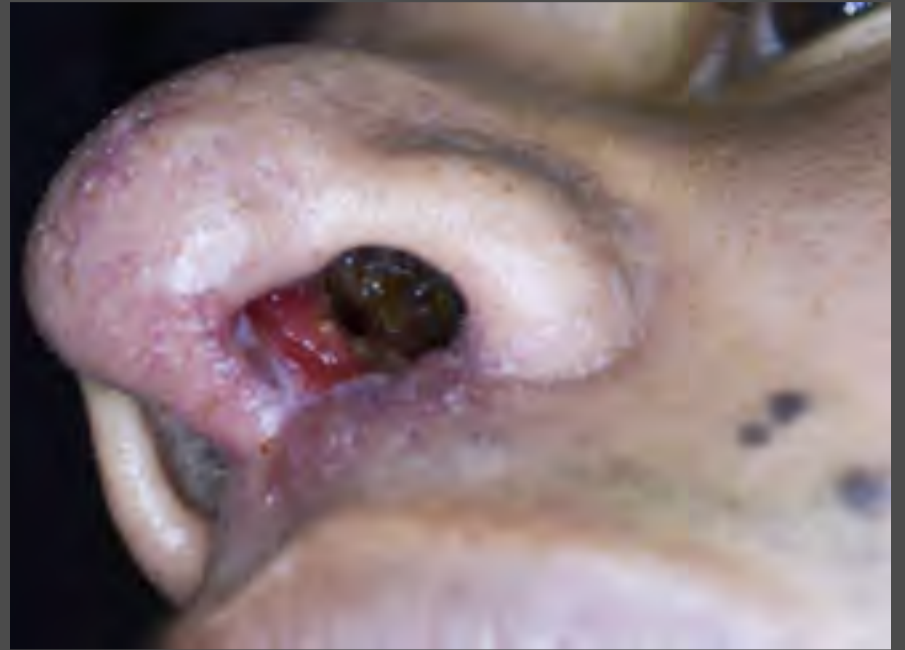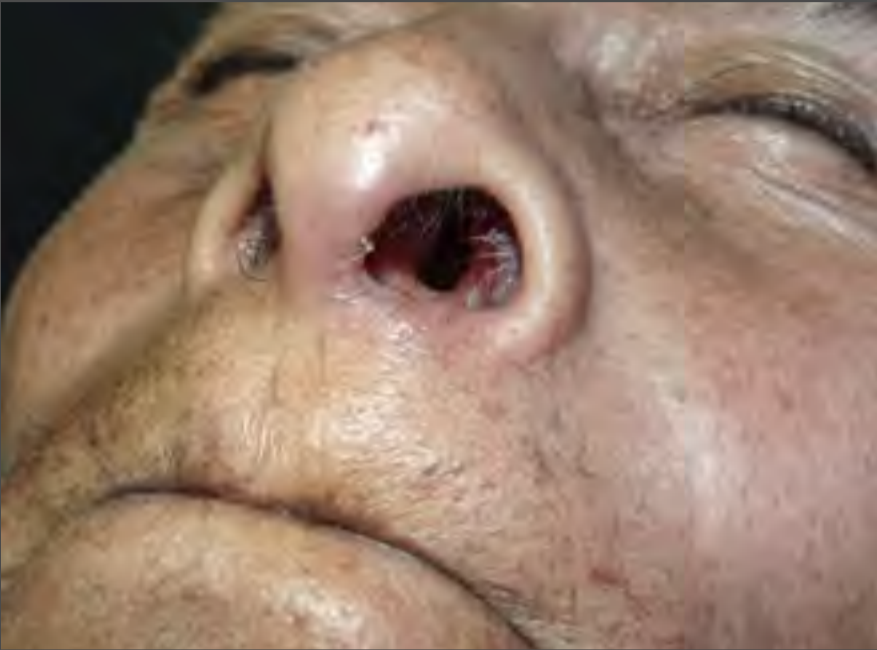**Figure 4.23.**  
Erythematous lesion on nasal septum mucosa (*Leishmania (V.) braziliensis* complex)



**Figure 4.24.**  
Erythematous lesion on nasal septum mucosa (*Leishmania (V.) braziliensis* complex)

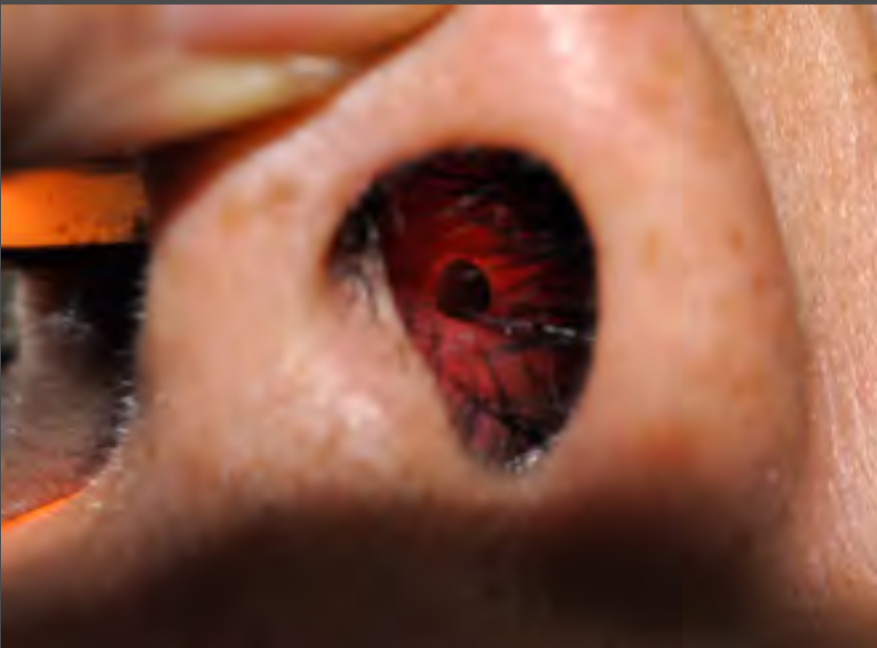

**Figure 4.25.**  
Granulomatous tissue on nasal septum



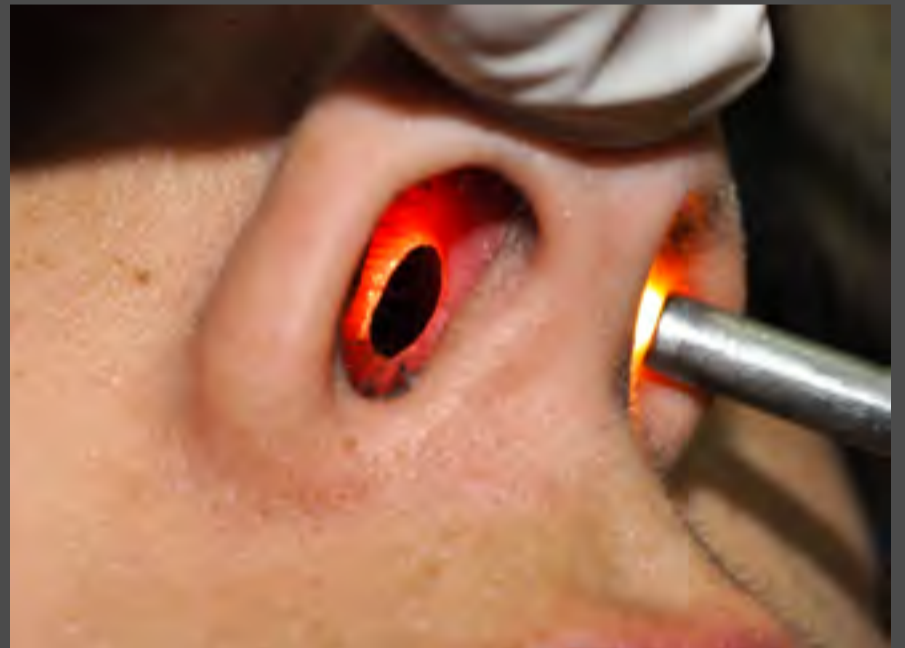**Figures 4.26A and B.**

Considerable inflammation erodes the mucous membrane and perforates the anterior third of the nasal septum. Perforations are small at first, but they can grow to two or more centimeters.



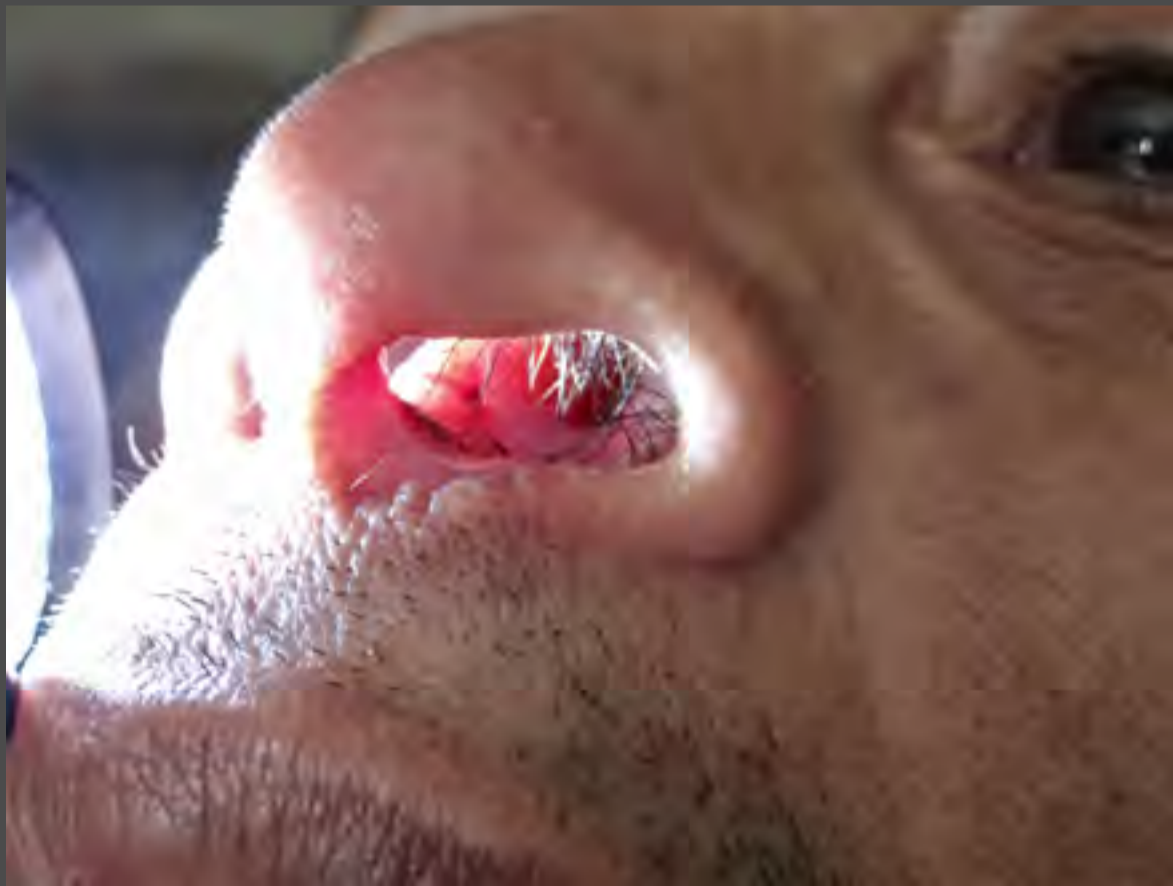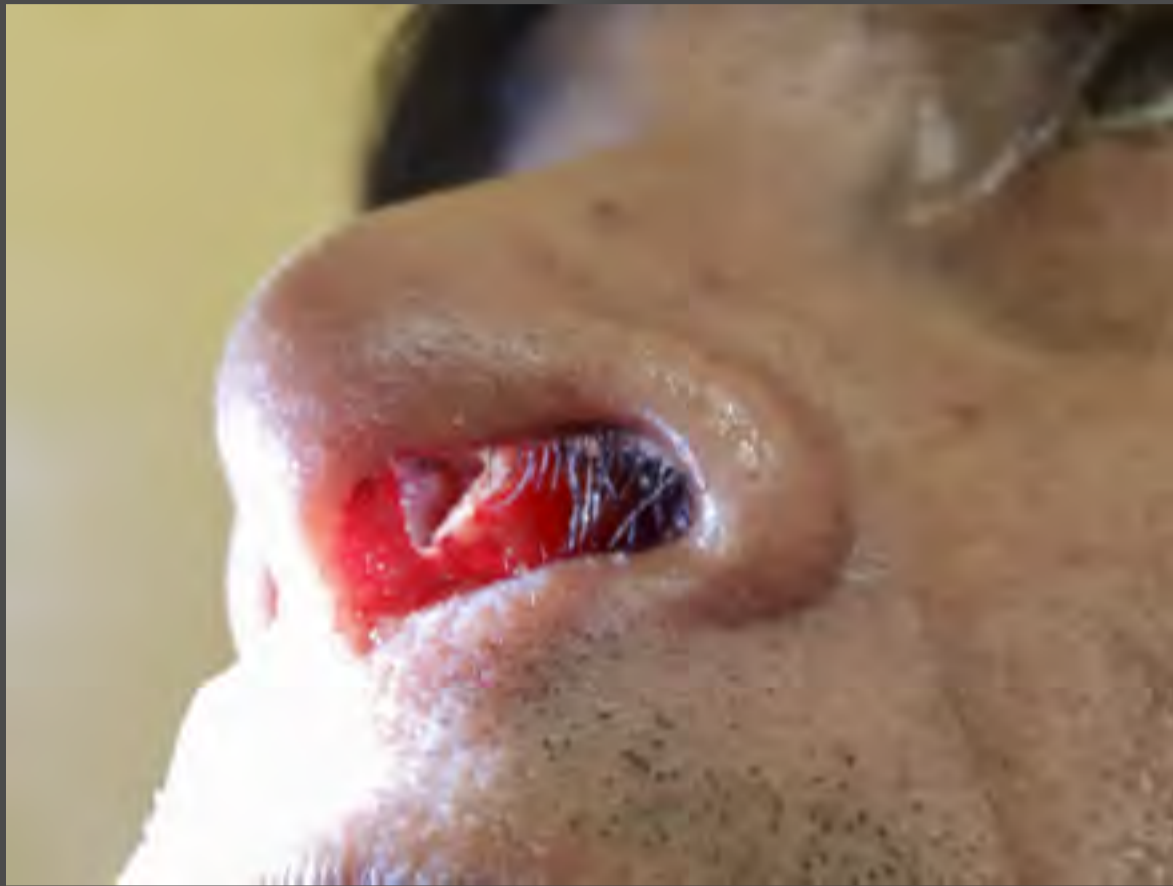**Figure 4.27A.**

Perforation of the nasal septum



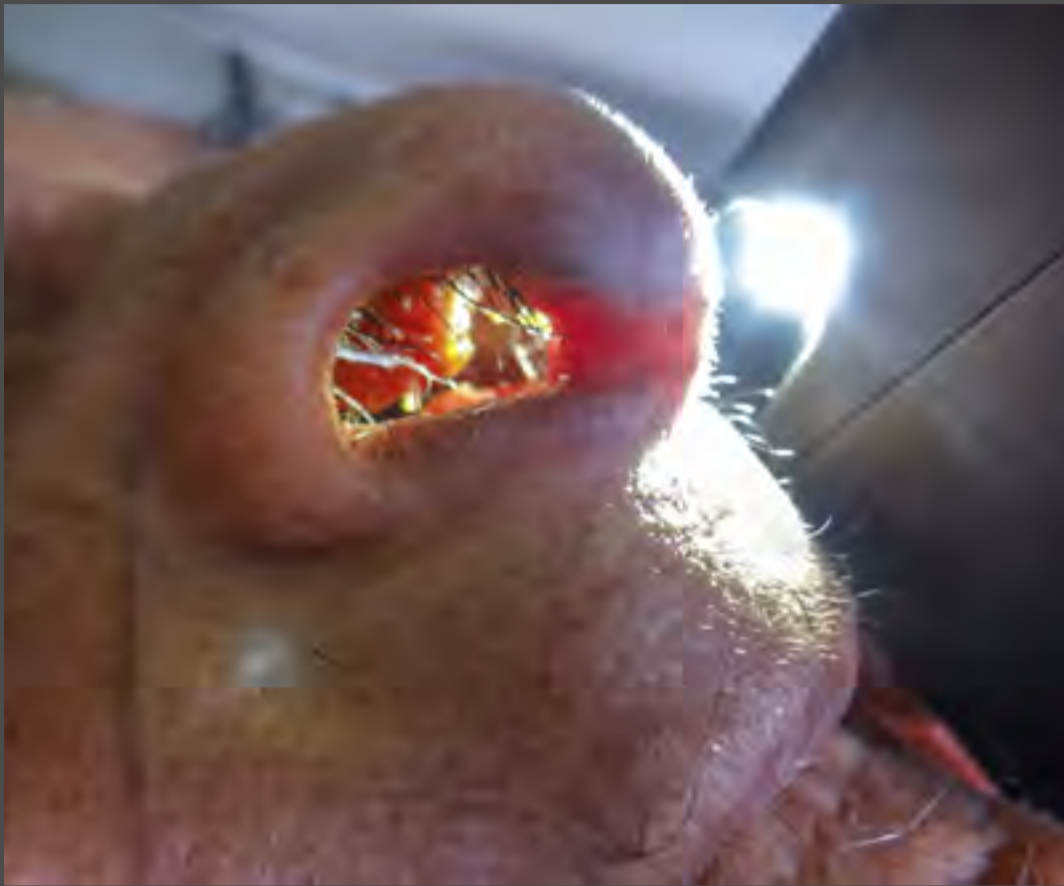**Figure 4.27B.**

After treatment, there are no signs of inflammation or infiltration, but the septum remains perforated. This is the most frequent sequela of mucosal involvement in the nose.

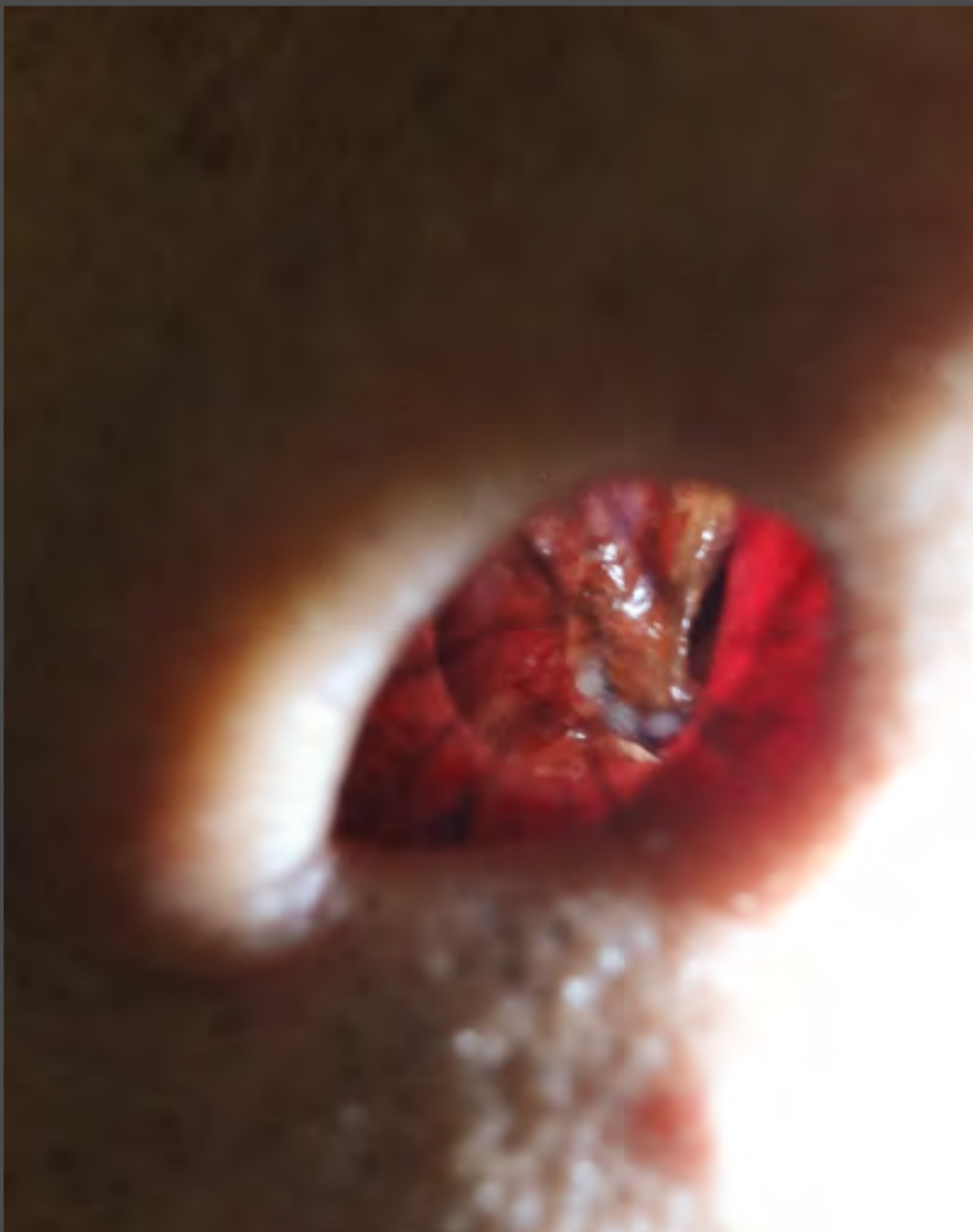

**Figures 4.28A and B.**

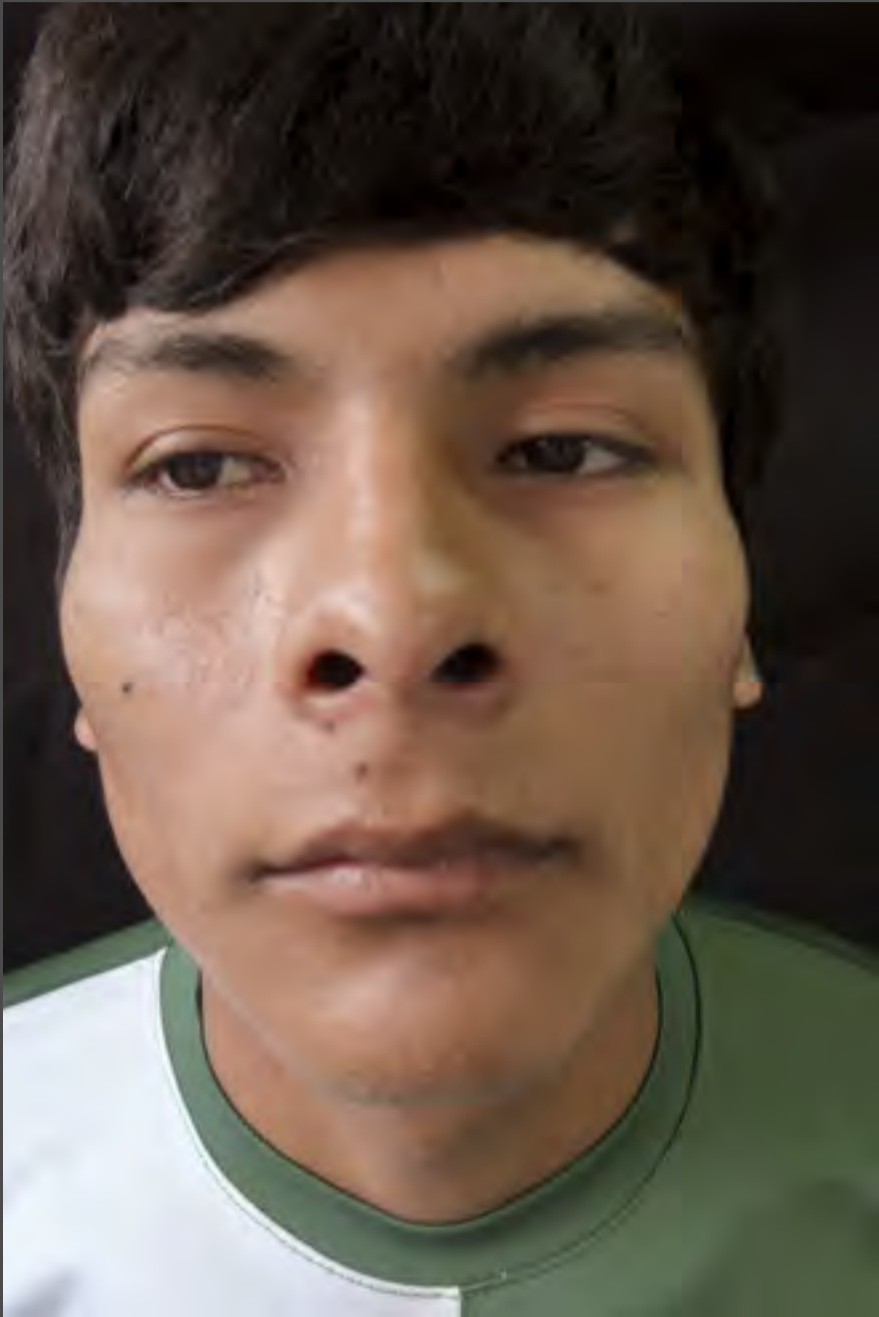As the disease progresses, perforation of the nasal septum enlarges, with loss of the osteocartilaginous support structure.



**Figure 4.29A.**  
With the help of lateral lighting, it is easy to observe the magnitude of the nasal septum's destruction.

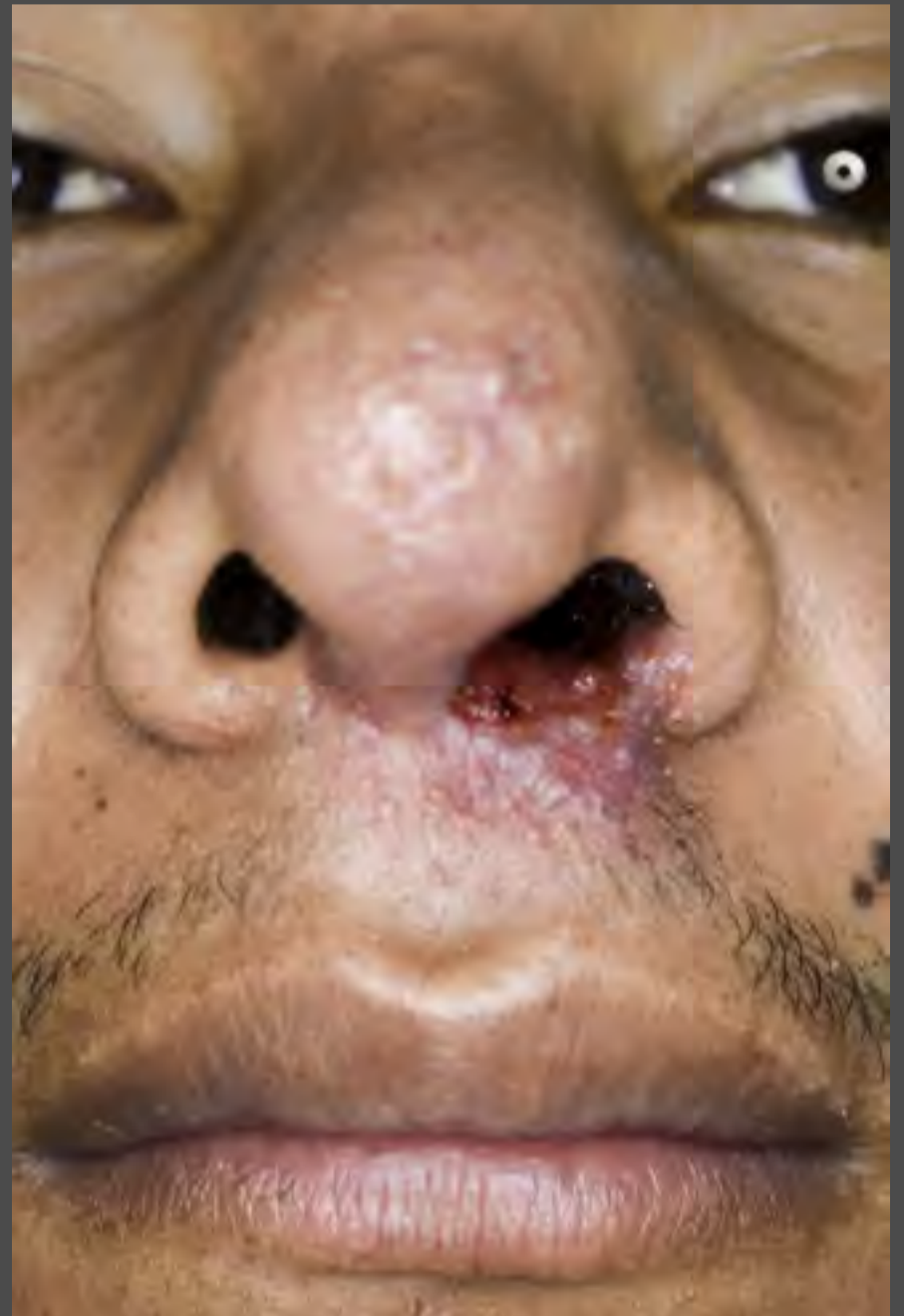
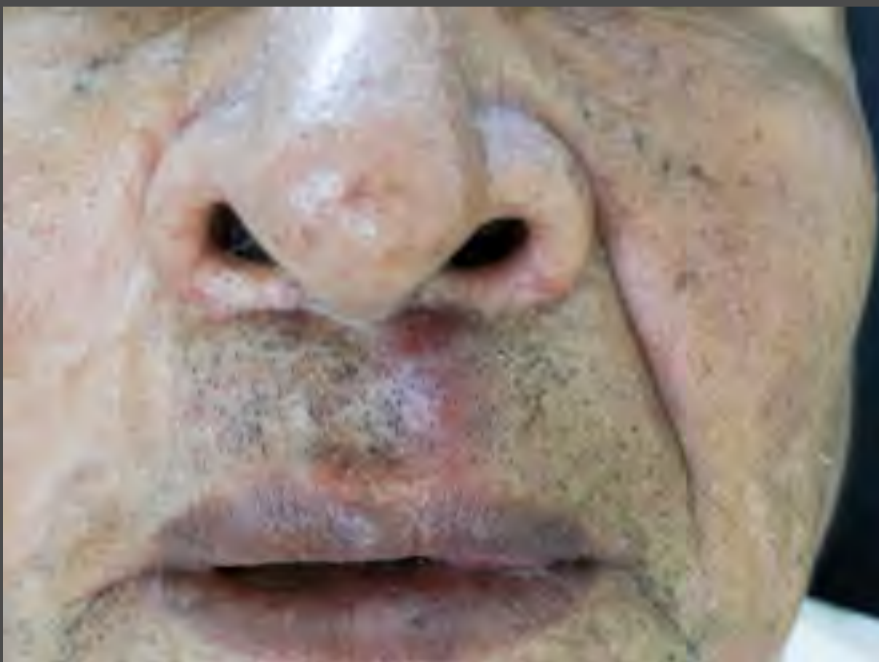
**Figure 4.29B.**  
Through the perforation, intense erythema and abundant serous and serosanguineous crusts are observed in the mucosa of the nasal ala.

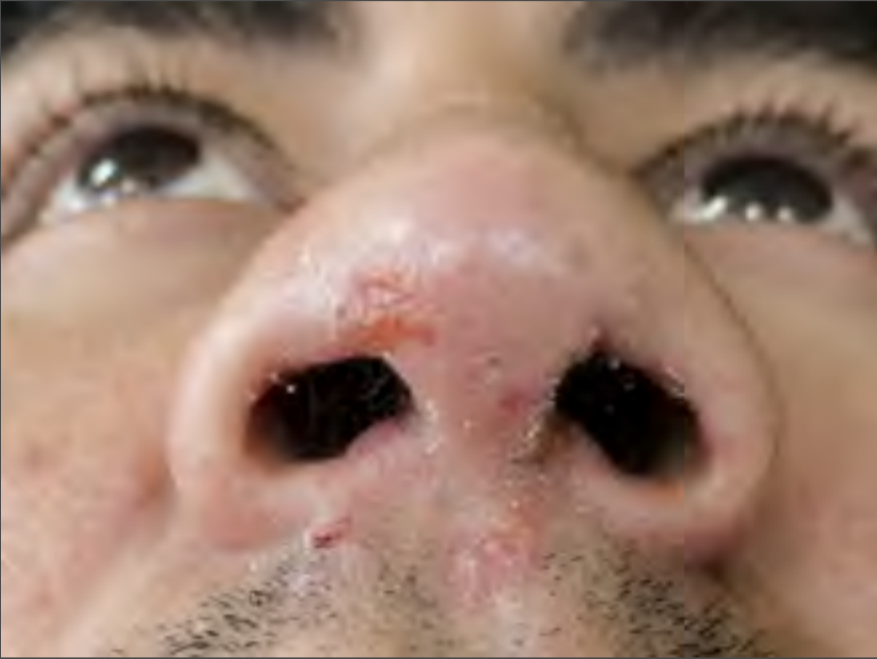

**Figures 4.30A, B and C.**

Regardless of the severity of the mucosal damage, the skin of the nose and the upper lip may look almost normal (Figure 4.30A), with light erythema (Figures 4.30B and C); with erythema, erosions, and crusts (Figure 4.30D); or with greater involvement due to erythema, edema, and infiltration (Figures 4.30E and F).

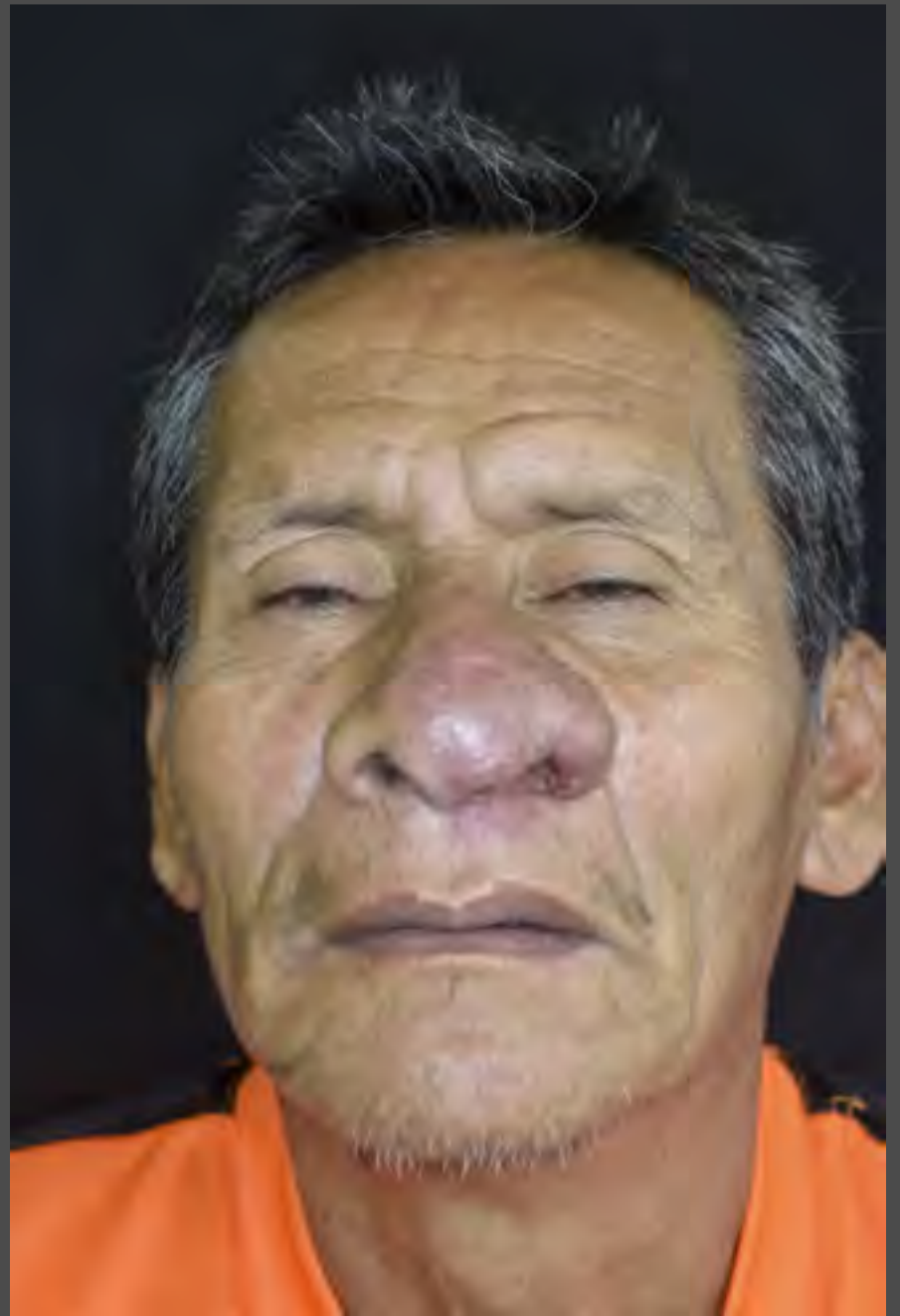
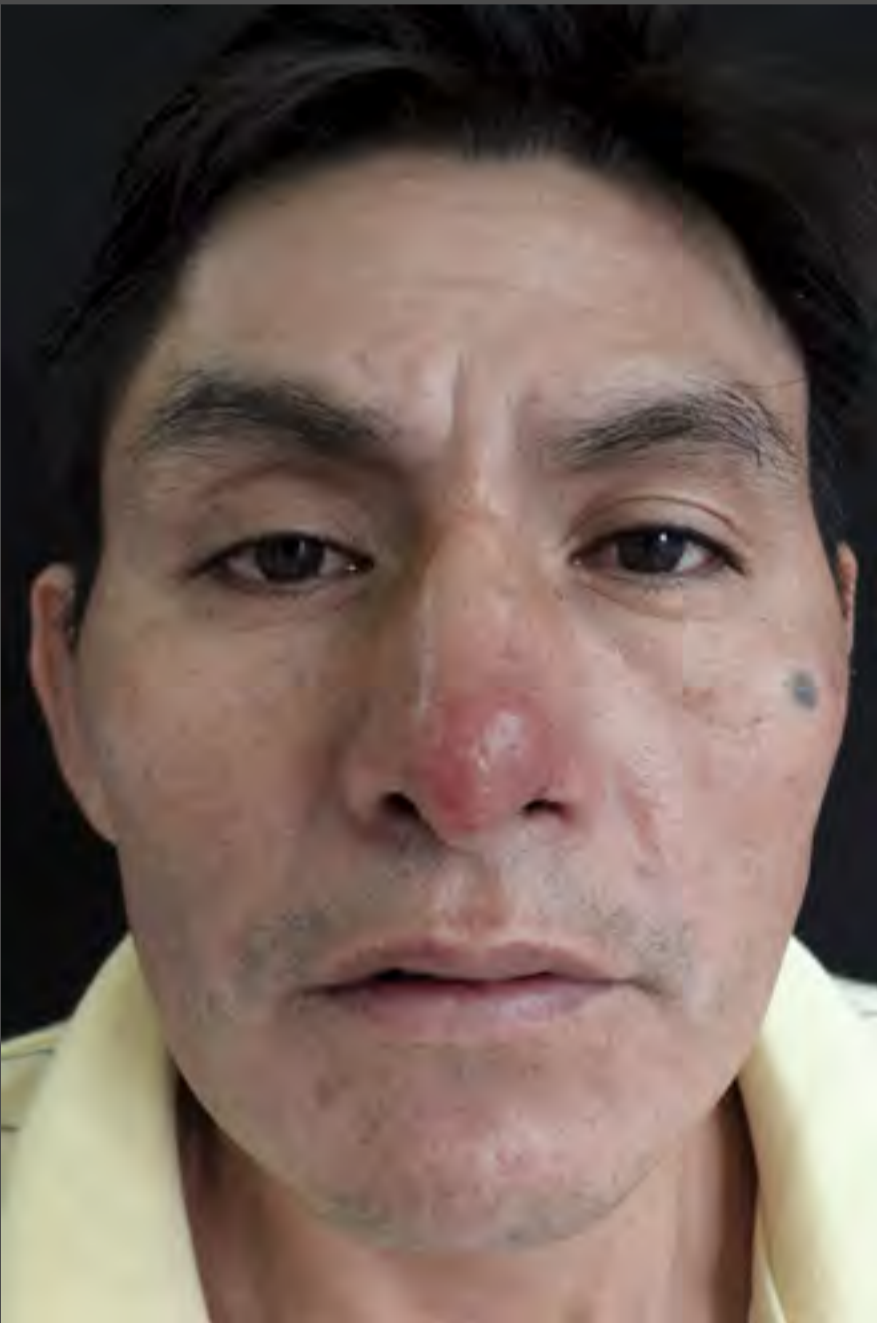


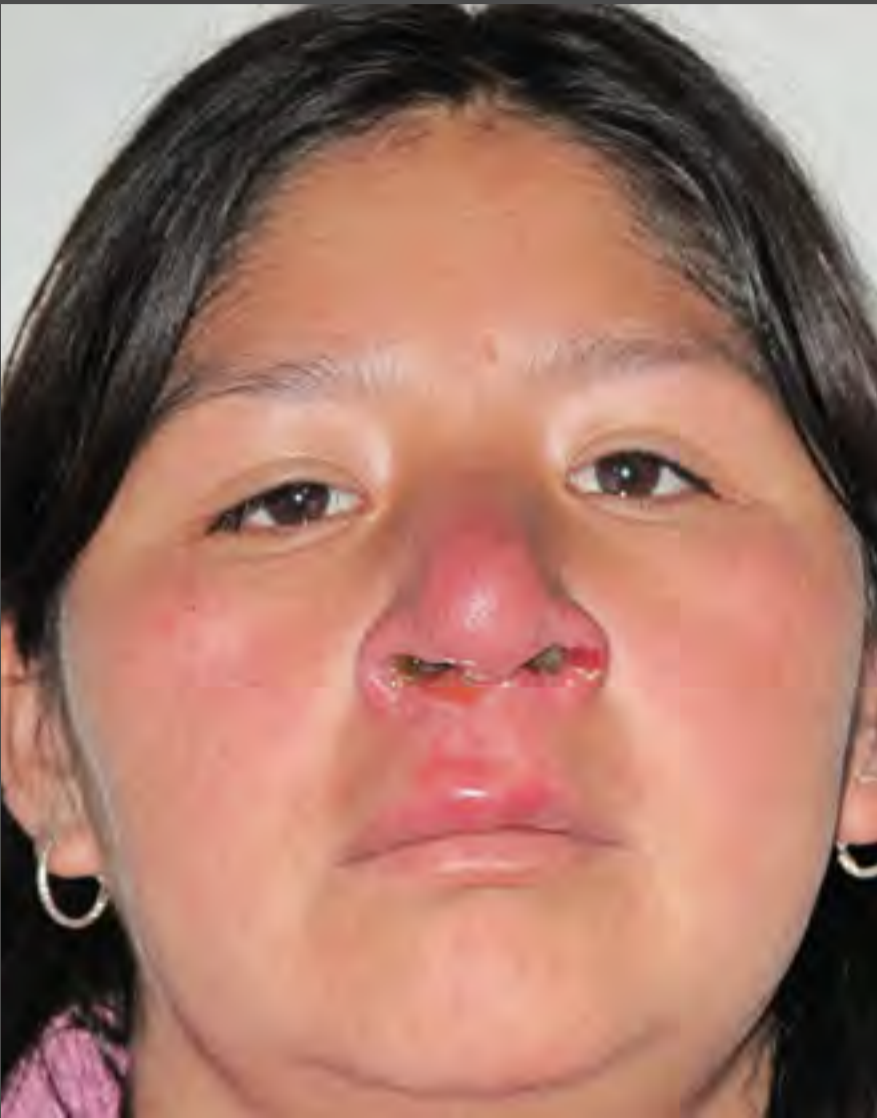

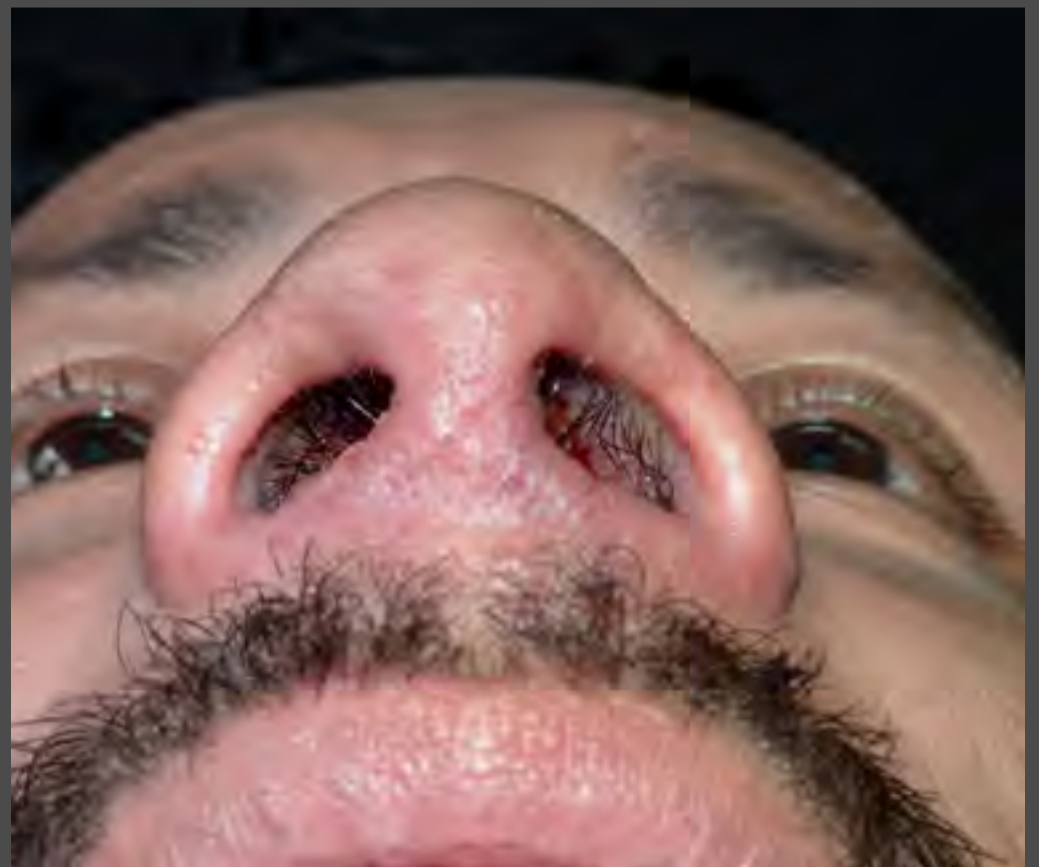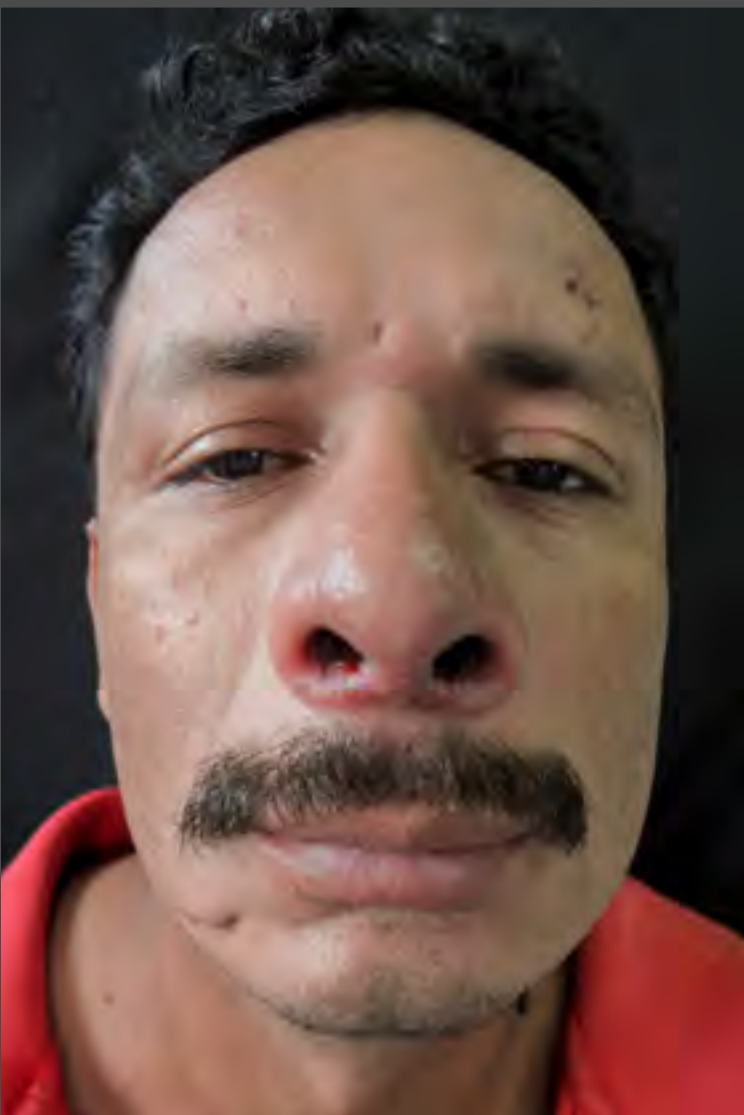**Figures 4.30D, E and F.**

Regardless of the severity of the mucosal damage, the skin of the nose and the upper lip may look almost normal (Figure 4.30A), with light erythema (Figures 4.30B and C); with erythema, erosions, and crusts (Figure 4.30D); or with greater involvement due to erythema, edema, and infiltration (Figures 4.30E and F).

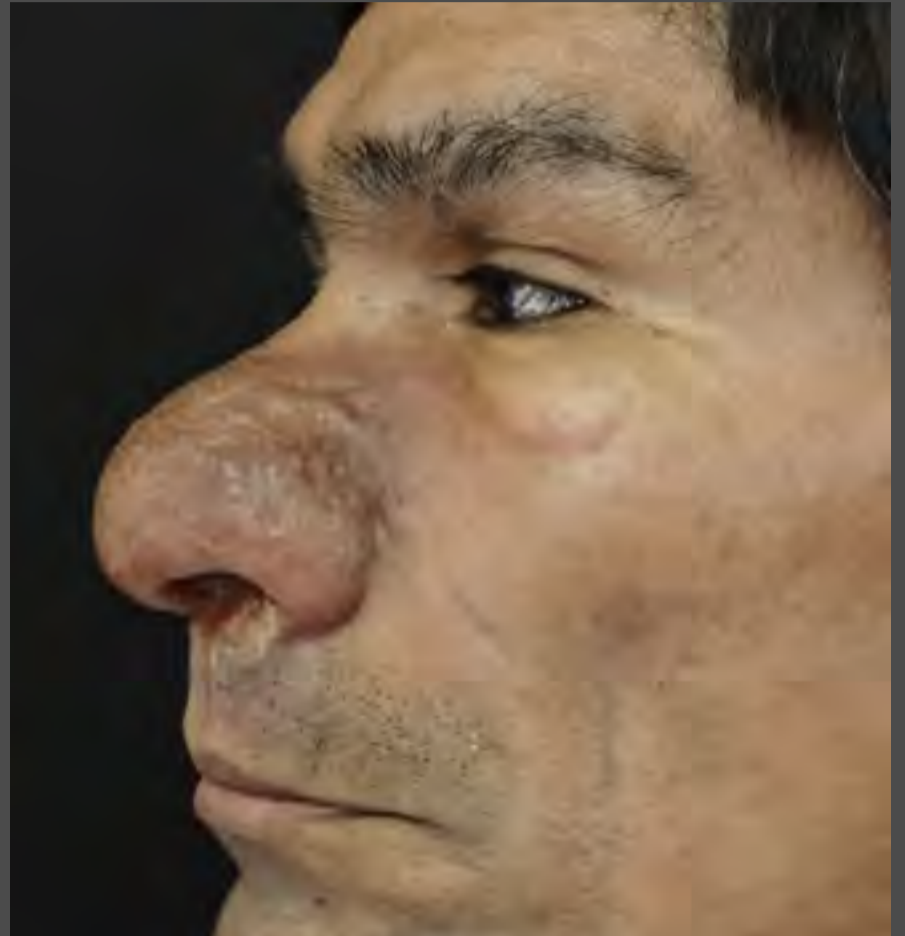
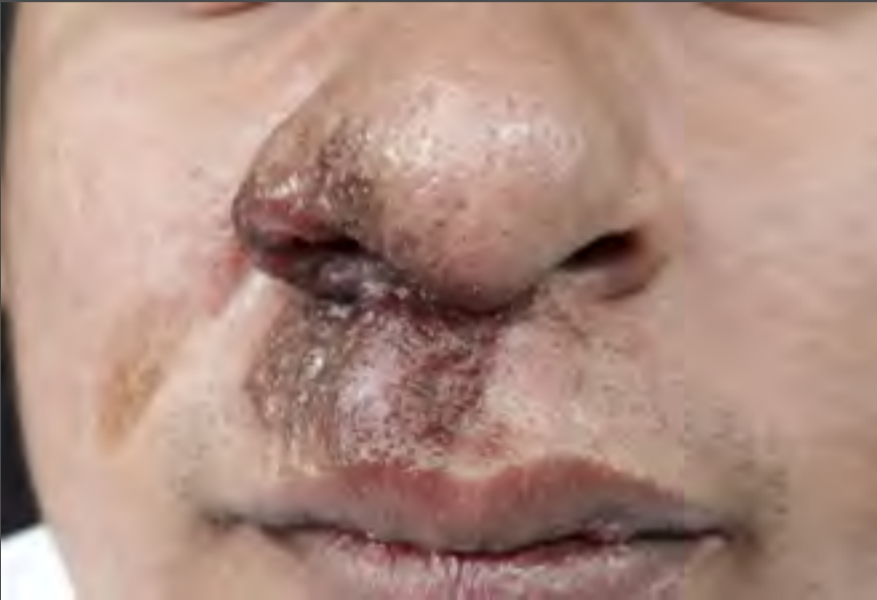


**Figure 4.31.**  
Considerable inflammation of the nose, with ulceration and exudation, and infiltration and inflammation of upper lip

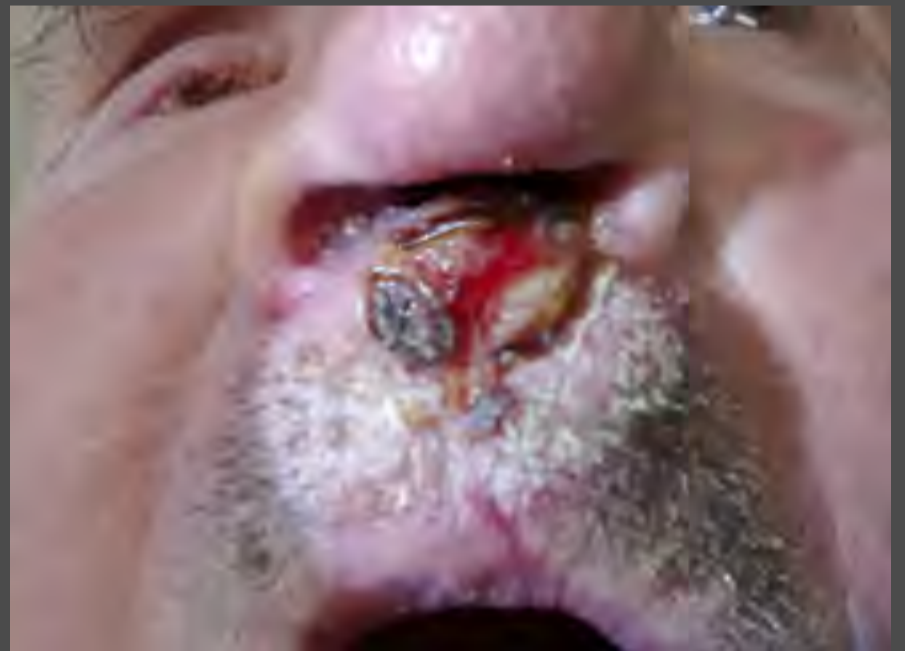
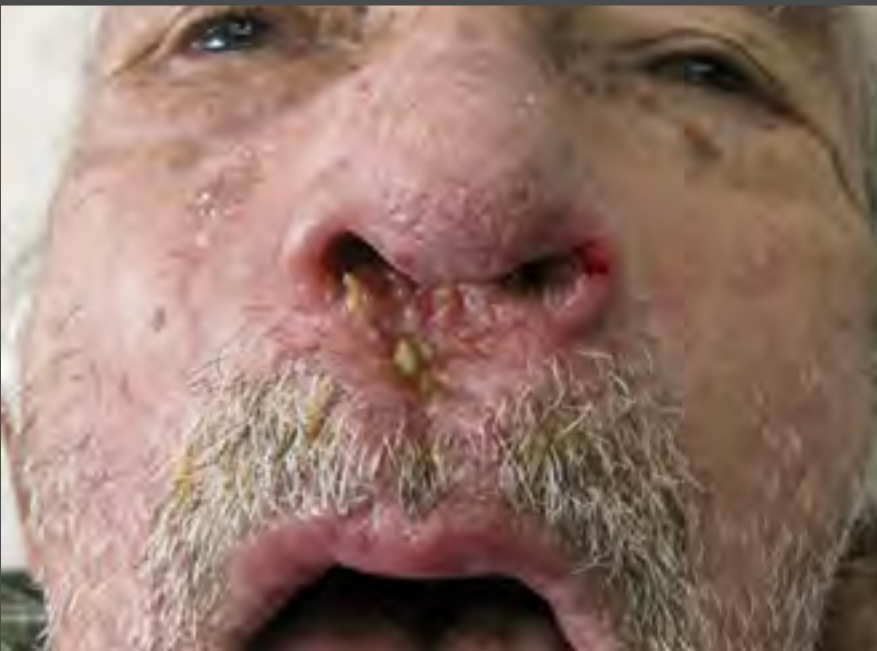
**Figures 4.32A and B.**  
Increase in volume of the nasal pyramid due to edema and infiltration of the mucosa and skin, with no spread to the upper lip



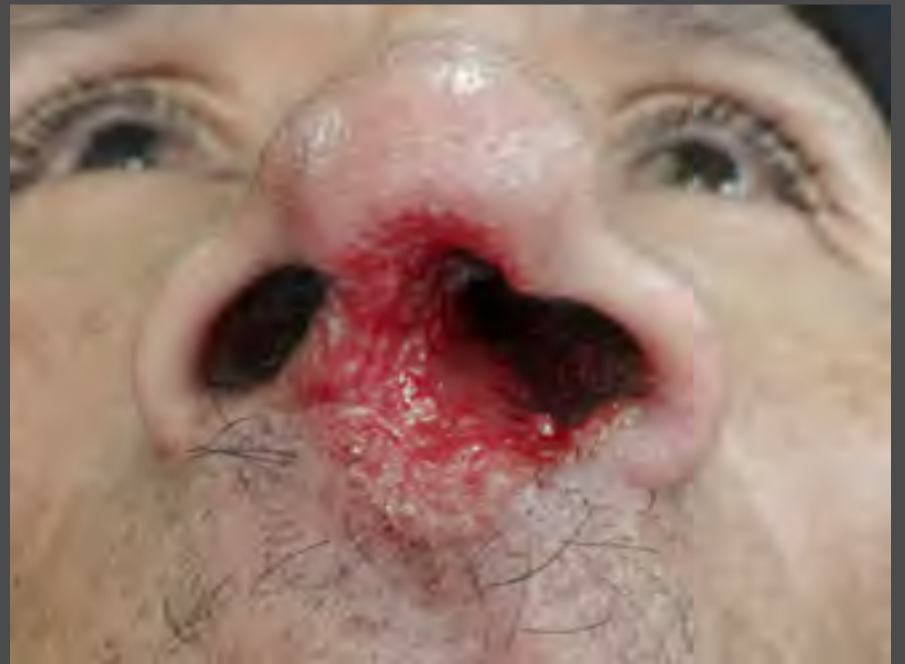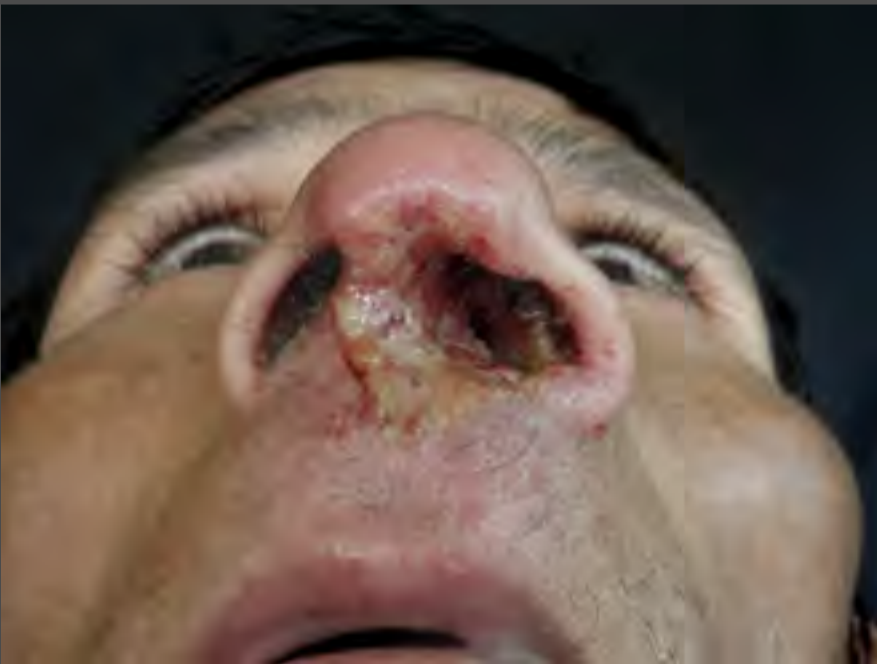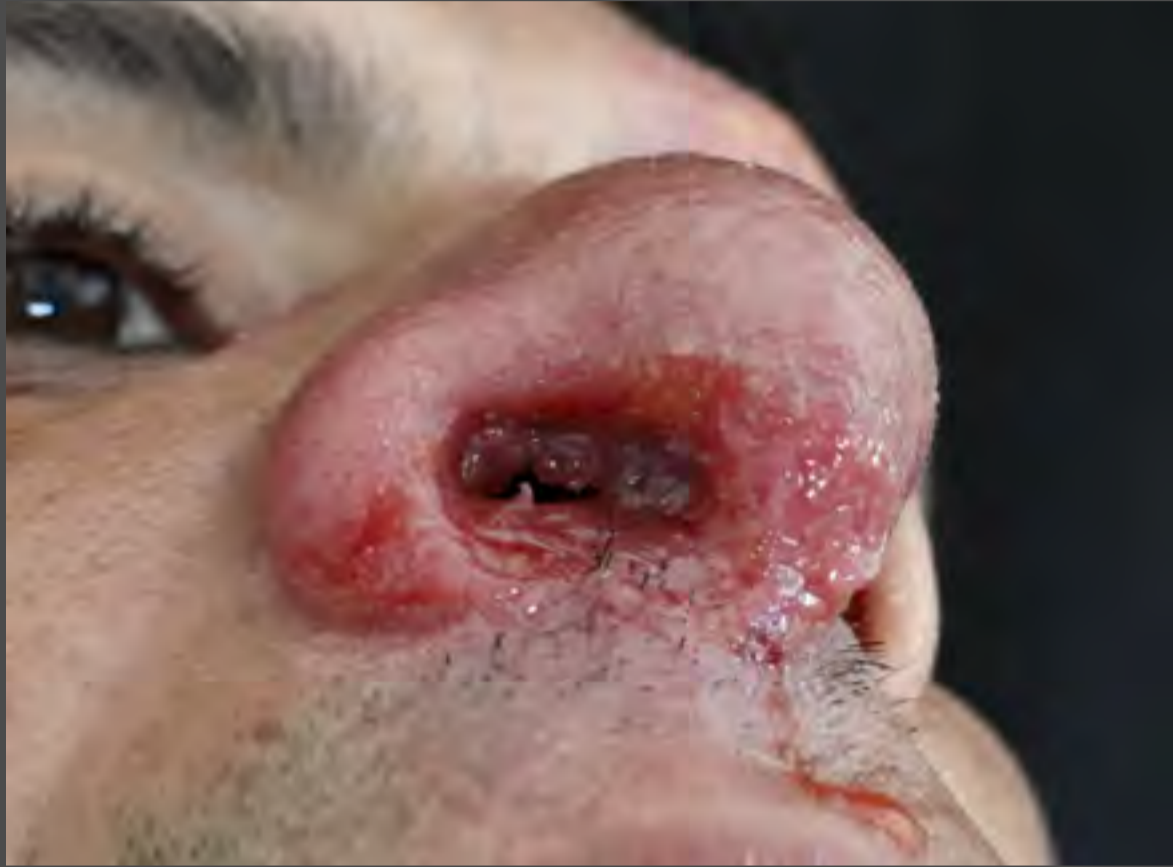**Figures 4.33A and B.**

In a recurrence of mucosal leishmaniasis, the lesions on the skin of the nose and lip may take on the warty, hyperpigmented appearance of cutaneous recurrences.



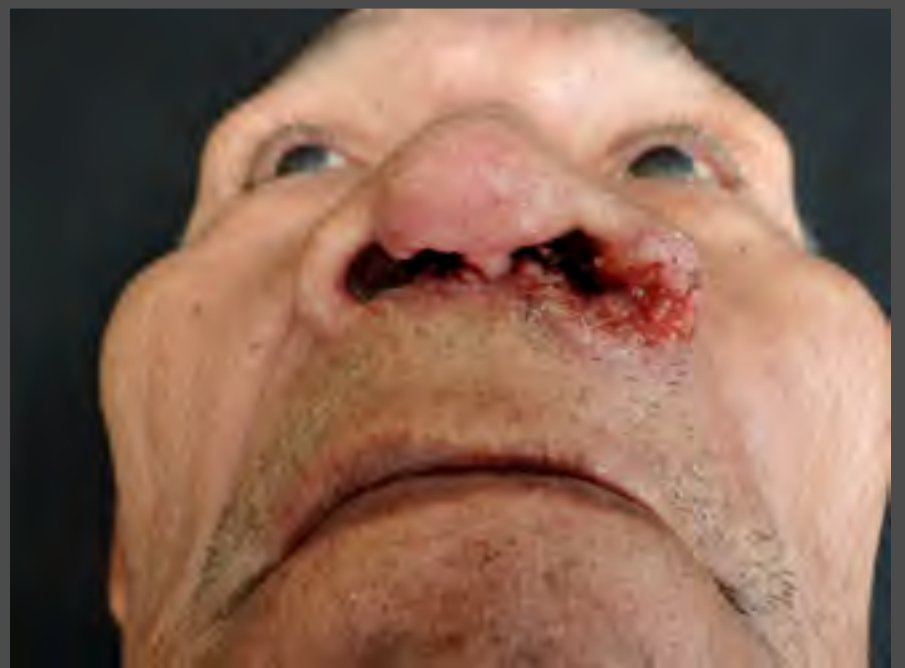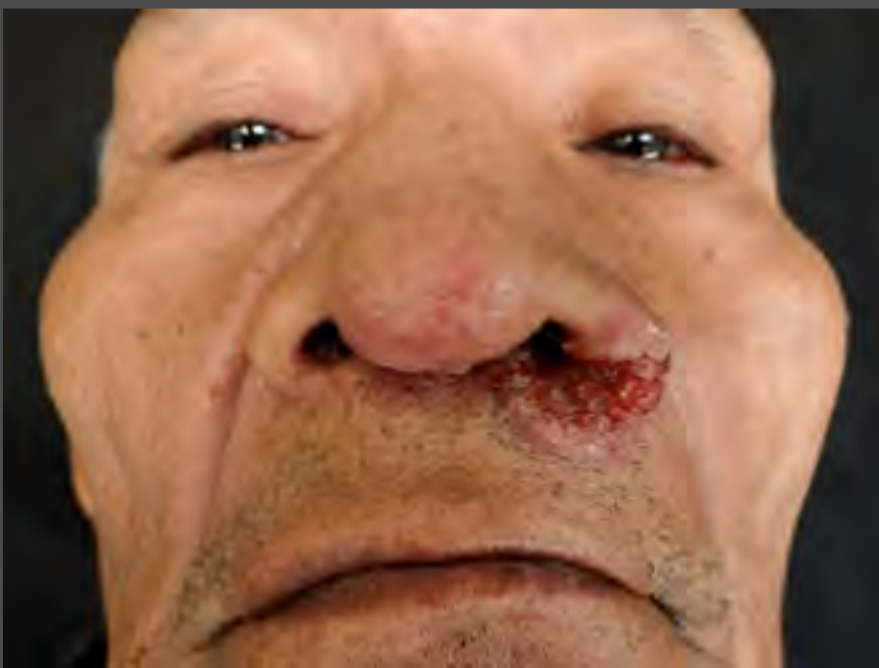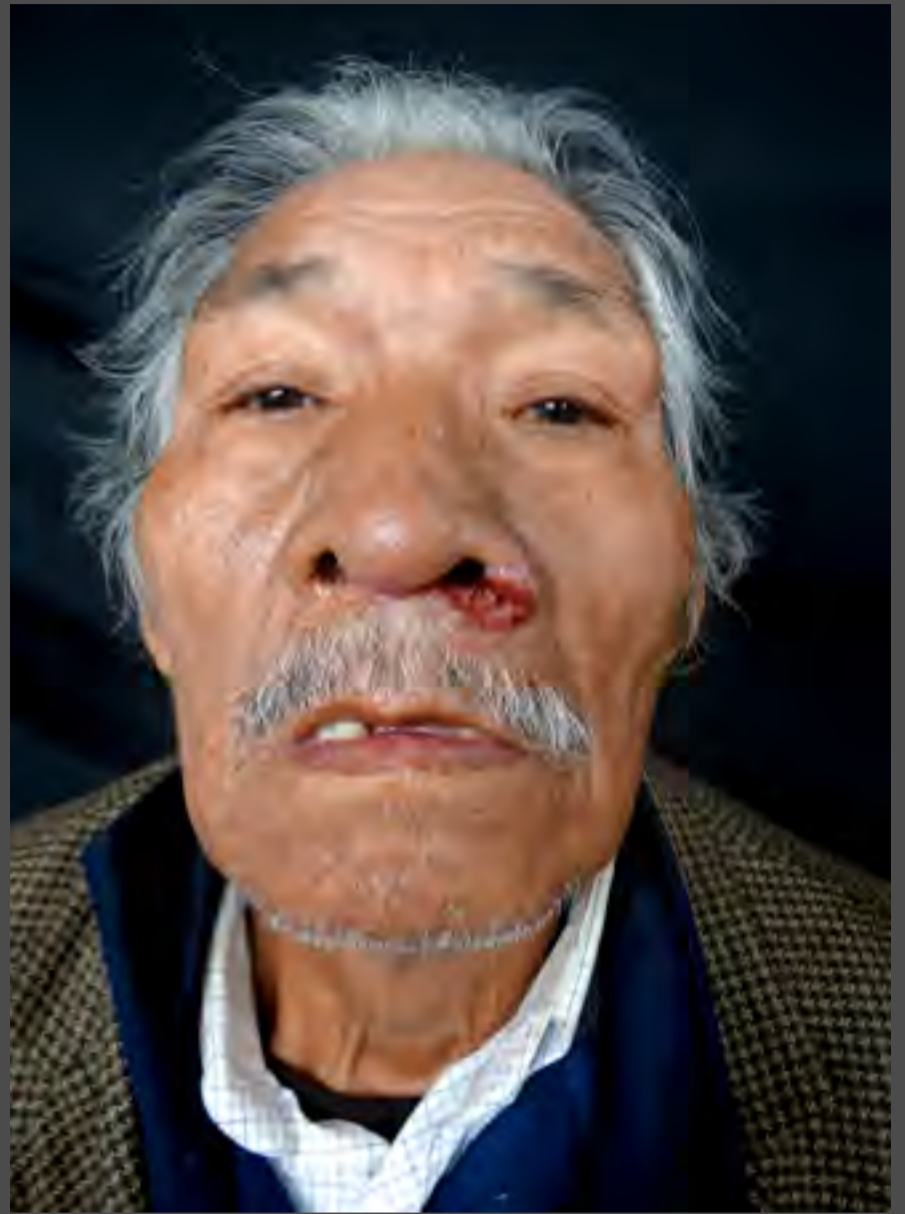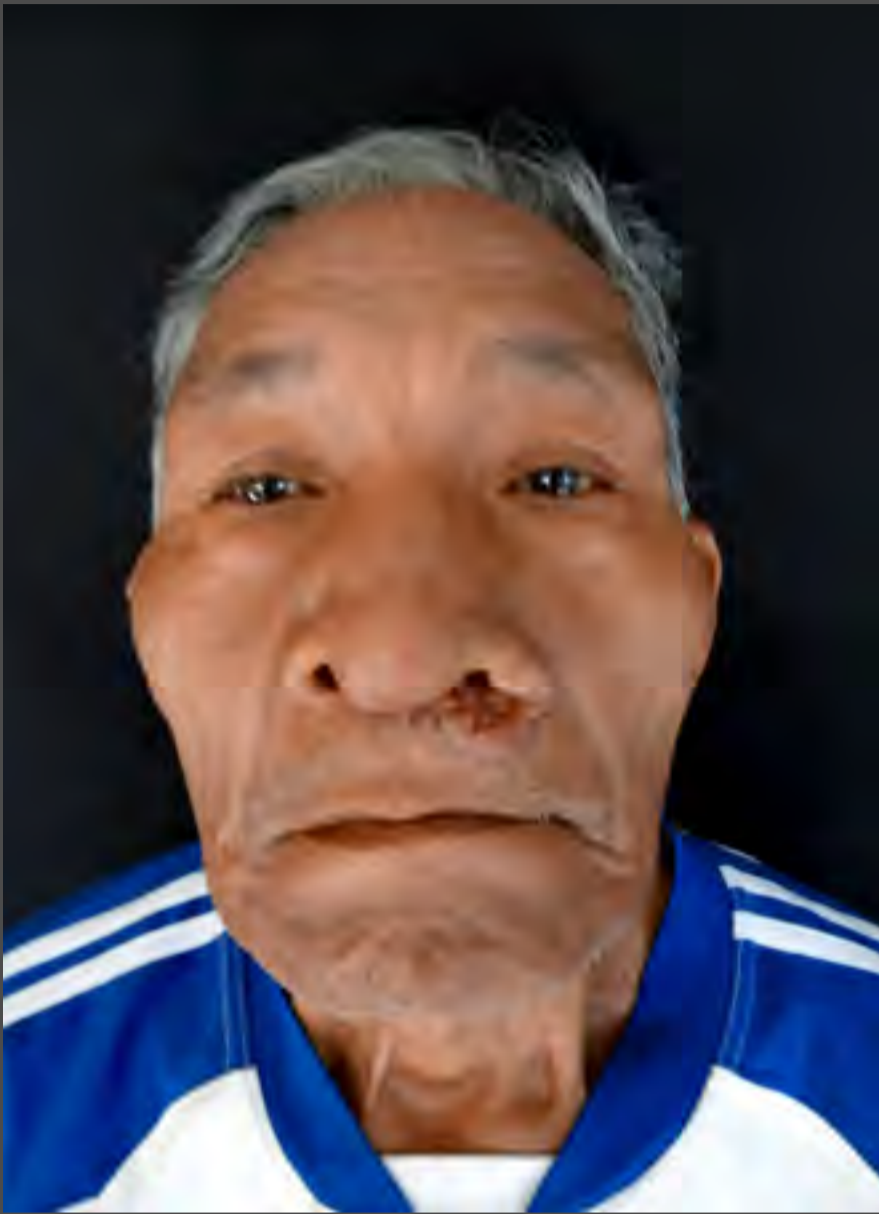**Figures 4.34A and B.**

Ulcerated lesion of the nasal mucosa, with crusts, exudation, and destruction of the septum. Involvement extends toward the upper lip.



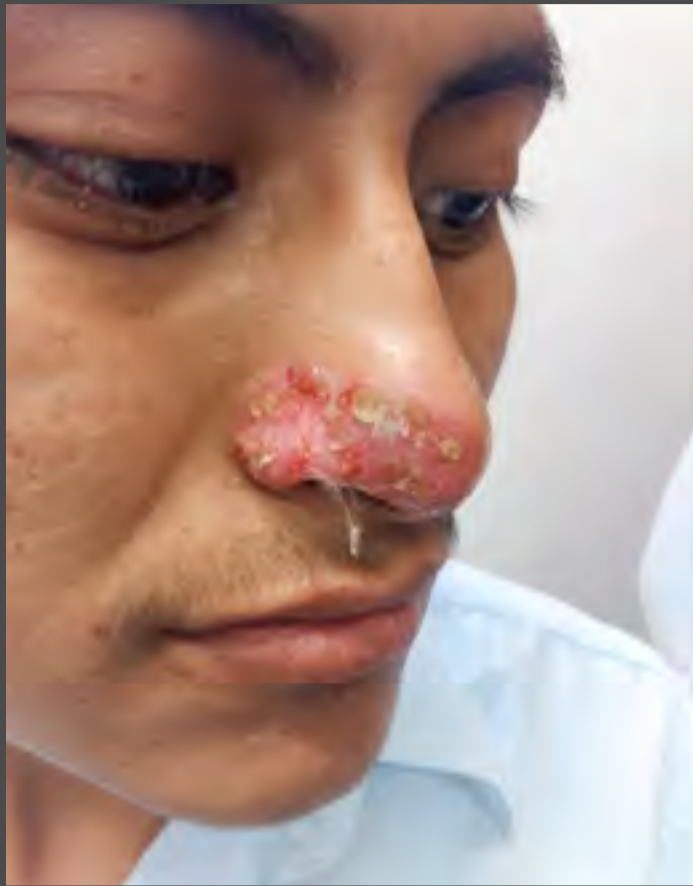**Figures 4.35A, B and C.**

Sometimes it only affects one side of the nose while the other side does not have apparent lesions. The affected side presents erythema, edema, infiltration, and considerable ulceration of the mucosa and skin.



**Figures 4.36A, B, C and D.**

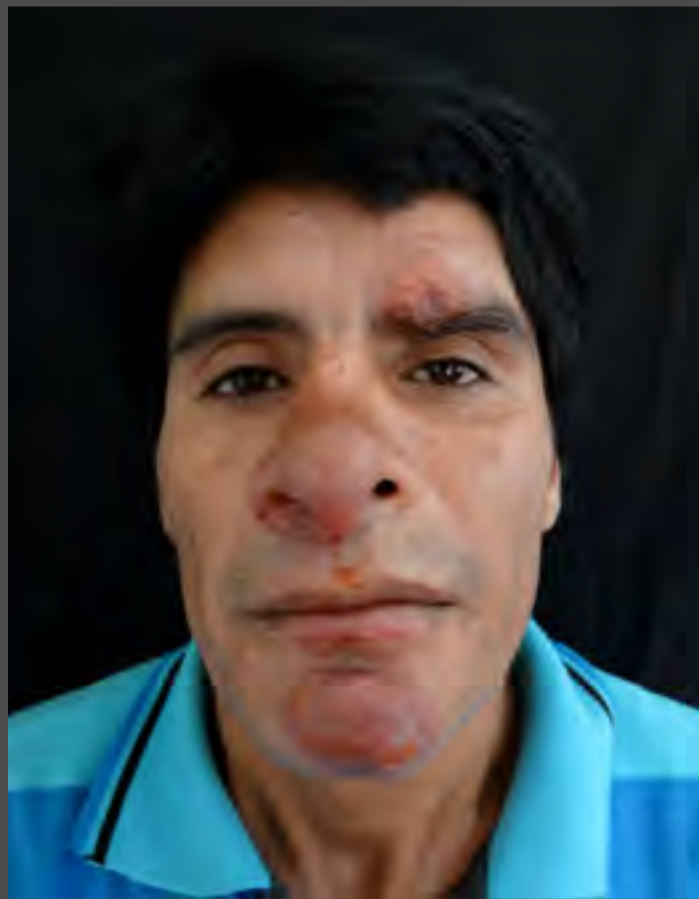The rapid development of destructive lesions is evident. This patient rejected treatment due to socioeconomic difficulties. At the initial consultation two years after nasal symptoms began (Figure 4.36A), a month and a half later (Figure 4.36B), and five months later (Figure 4.36C and D).



**Figure 4.37.**  
Nasal lesion with ulceration and exudation, on right half of the nose

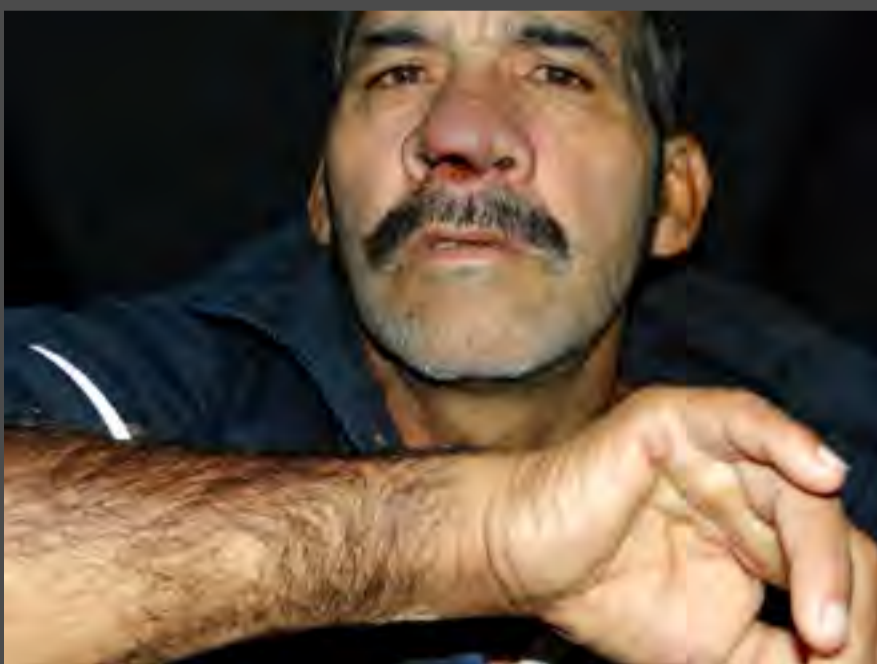
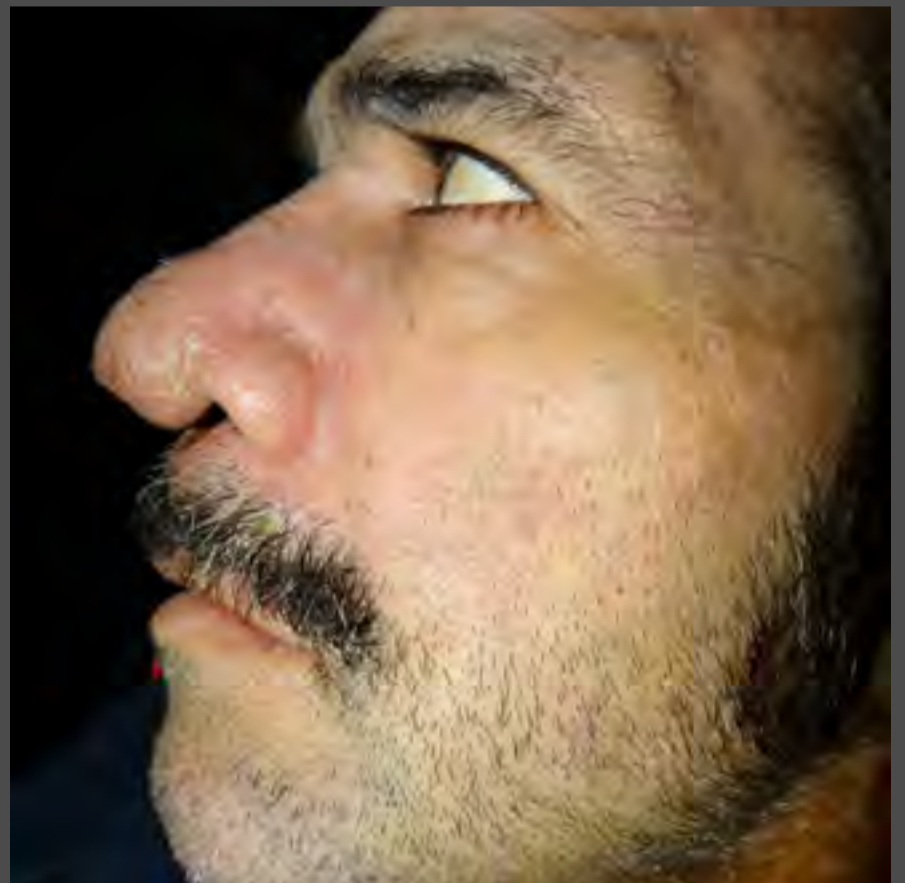
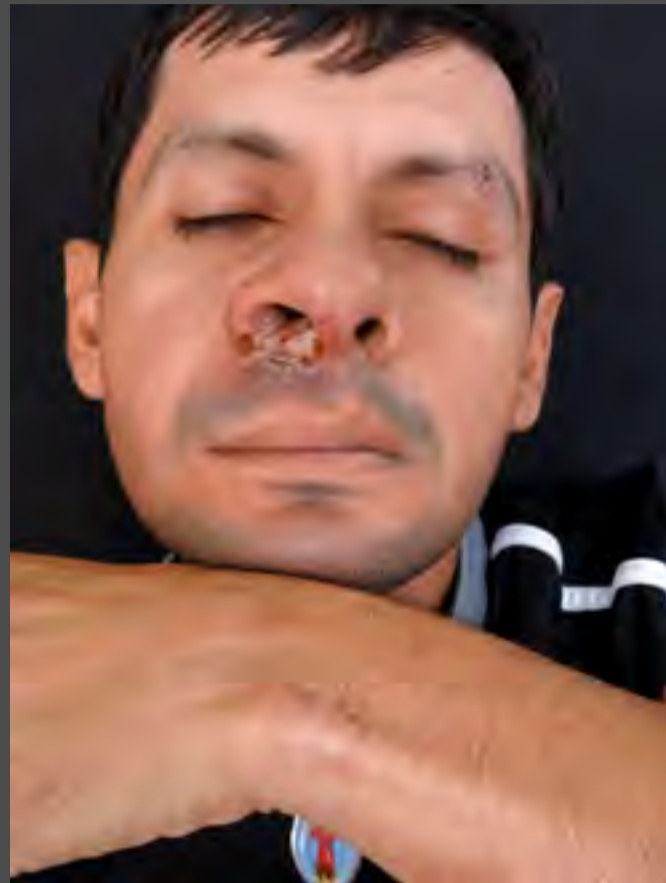**Figure 4.38.**  
Erythematous, edematous, infiltrated plaque on the nasal mucosa with evident spread to the cheek on the same side



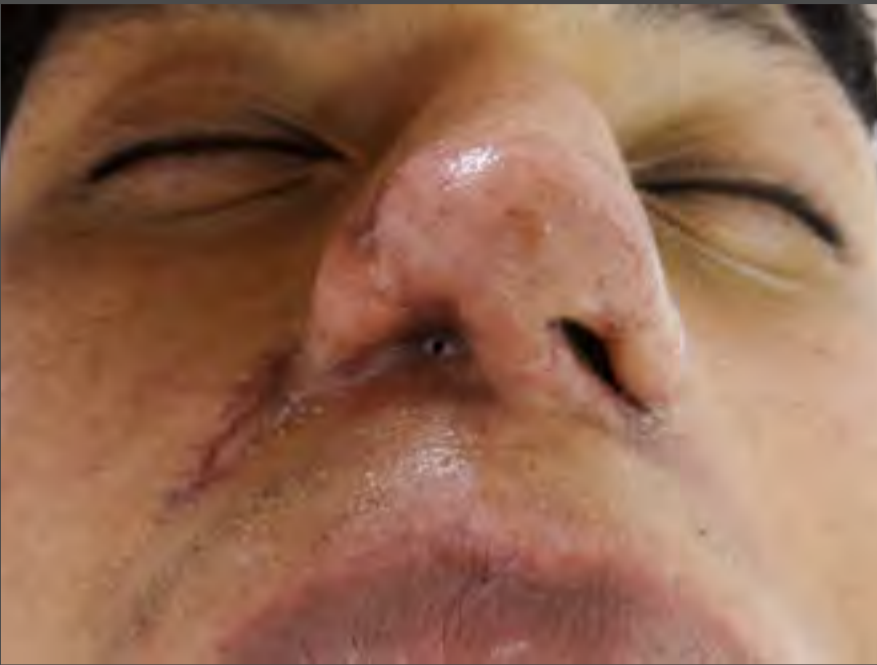**Figure 4.39.**  
Simultaneous six-month-old cutaneous and mucosal lesions

**Figure 4.40.**  
Severe nasal involvement due to mucosal leishmaniasis and scar on the forearm from the cutaneous form, partially treated 14 years ago



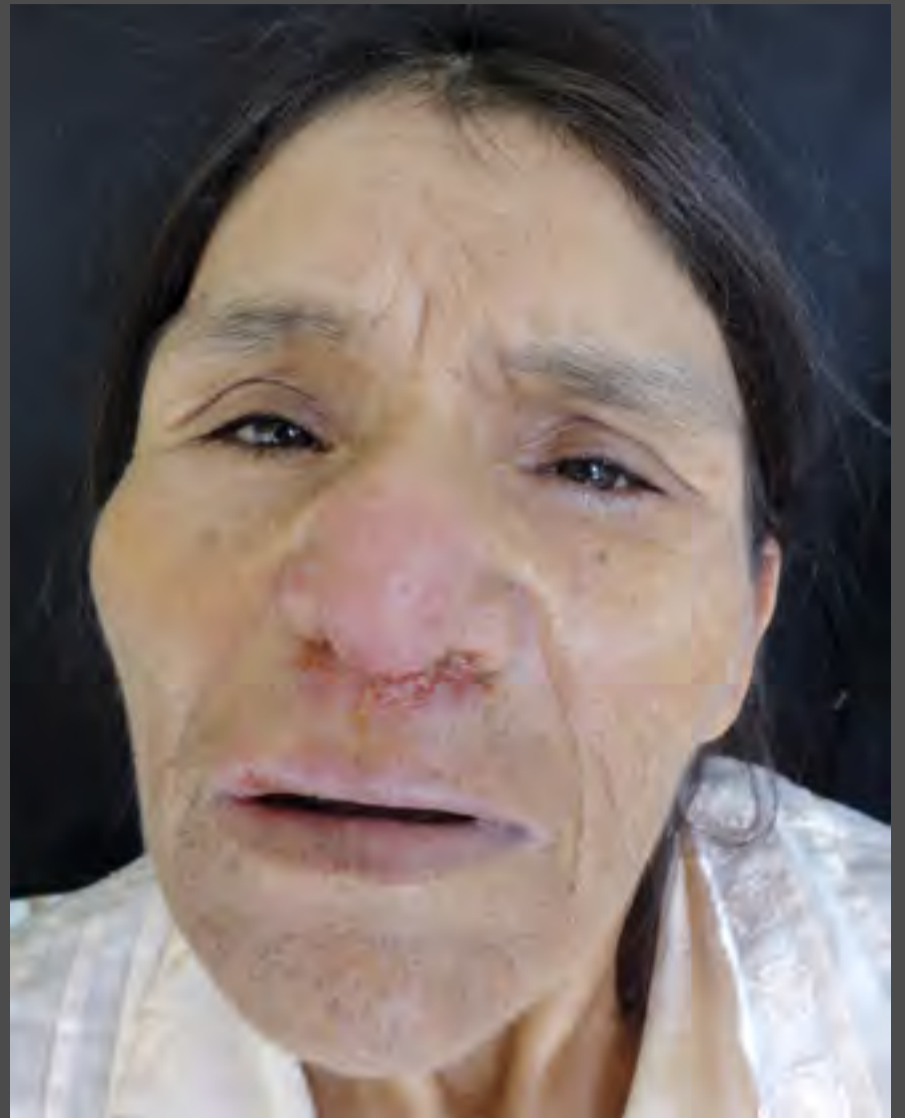**Figures 4.41A, B and C.**

Active mucosal leishmaniasis with scars from the old skin lesions. In the first patient (Figure 4.41A), scar on the forearm following spontaneous cure after seven months. The second patient (Figures 4.41B and C) was treated eight years earlier for the lesion on the forearm, it healed in three months, and three years later nasal symptoms appeared.



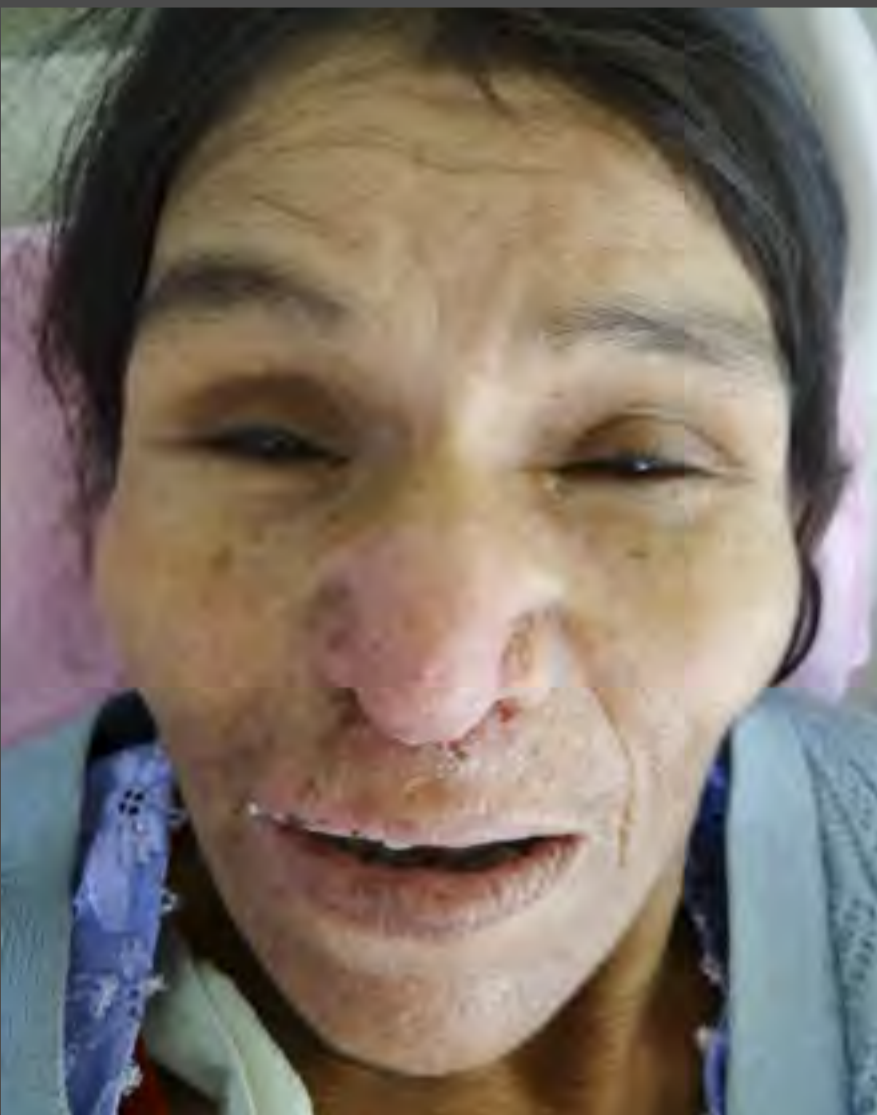**Figure 4.42.**

Cicatrization of the mucosal lesions can produce fibrosis and severe retractions, with obliteration of the nasal cavity and impairment of the respiratory function.

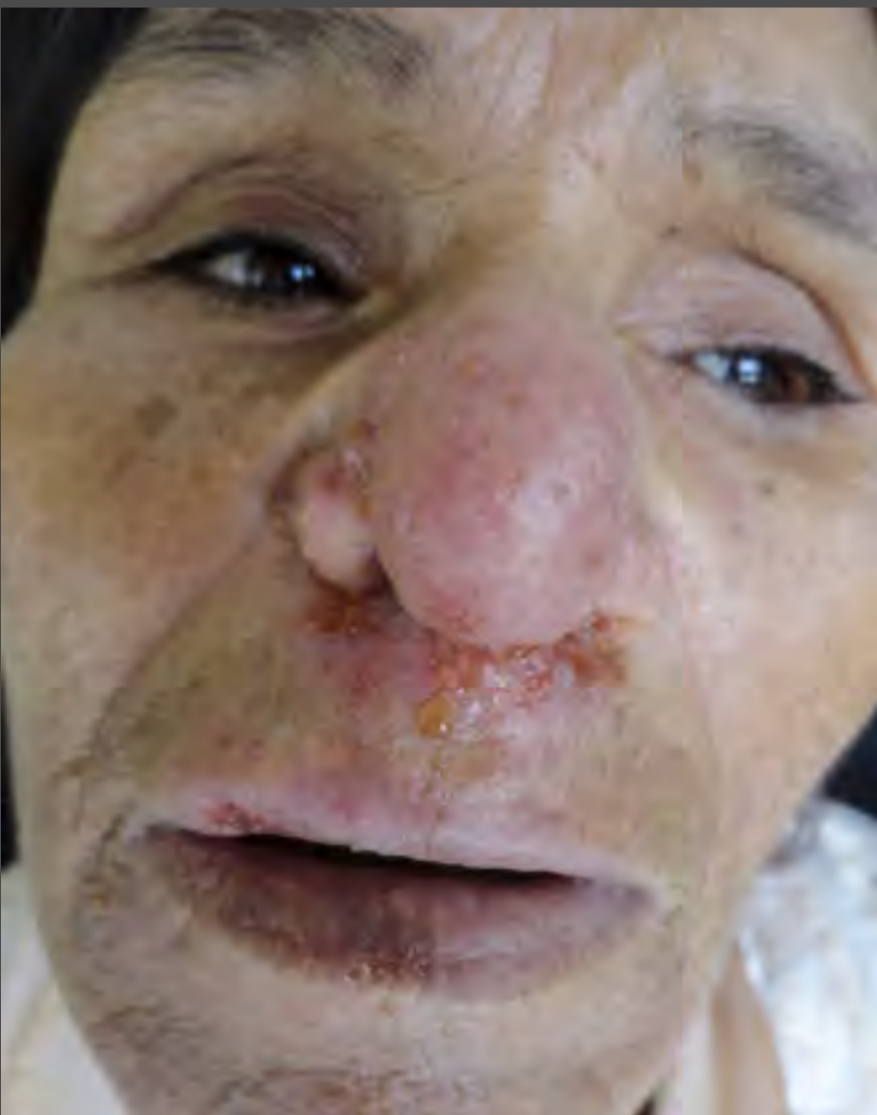
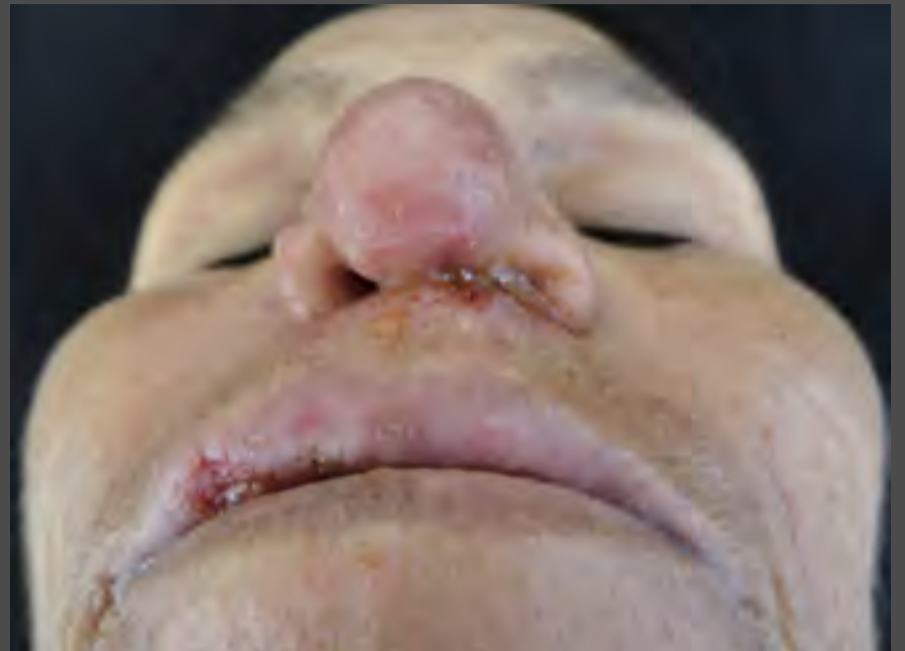
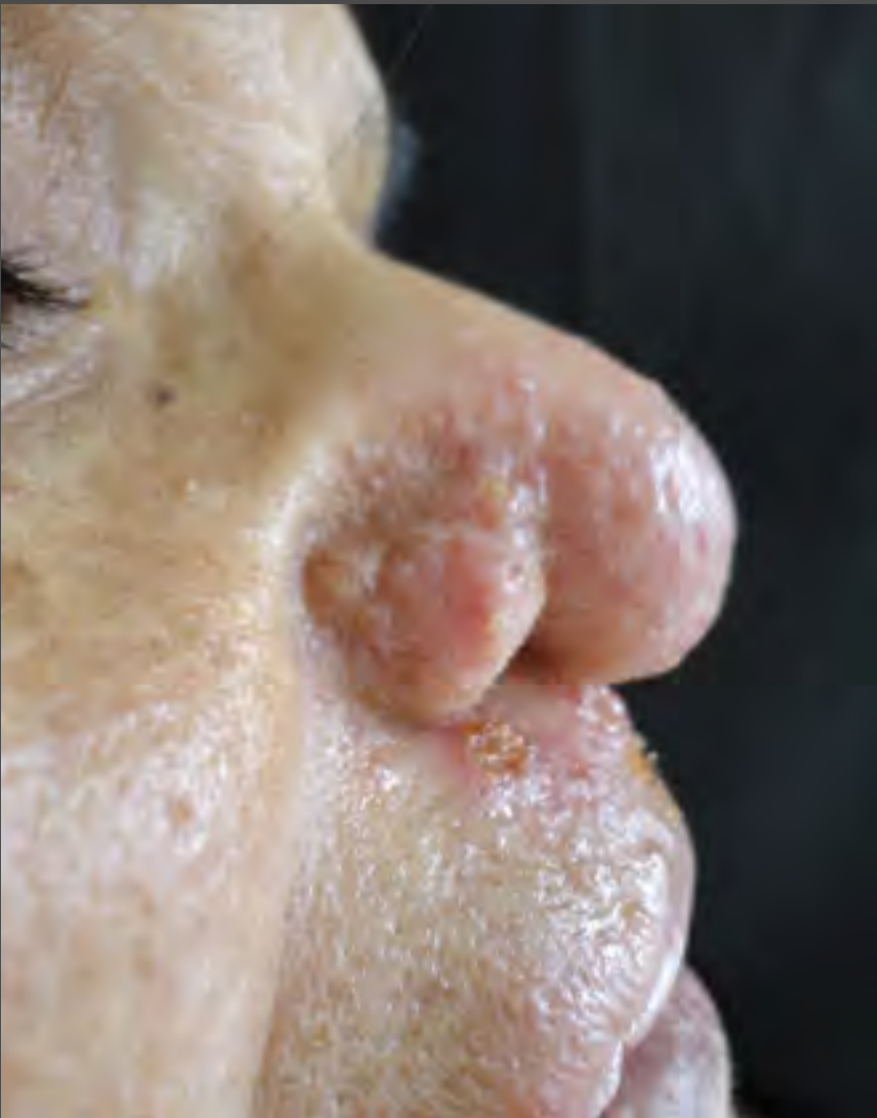**Figures 4.43A and B.**

Just as with cutaneous leishmaniasis, involvement of mucous membranes is also less frequent in women, but when it does occur, it adopts the same inflammatory, infiltrative, and destructive characteristics it has in men. This is a patient with a history of cutaneous leishmaniasis 22 years earlier that was treated with low-dose pentavalent antimonials and was cured. Eighteen years later, symptoms began in the nasal mucosa with pain, pruritus, and obstruction, accompanied by bloody mucus discharge and occasional frank bleeding. Spread of involvement due to contiguity to the upper lip without lesions on the palate is noteworthy. She received amphotericin B deoxycholate with improvement, but without complete resolution, and did not return for follow up. Partial obliteration of the nostrils is evident with the consequent impairment of respiratory function.

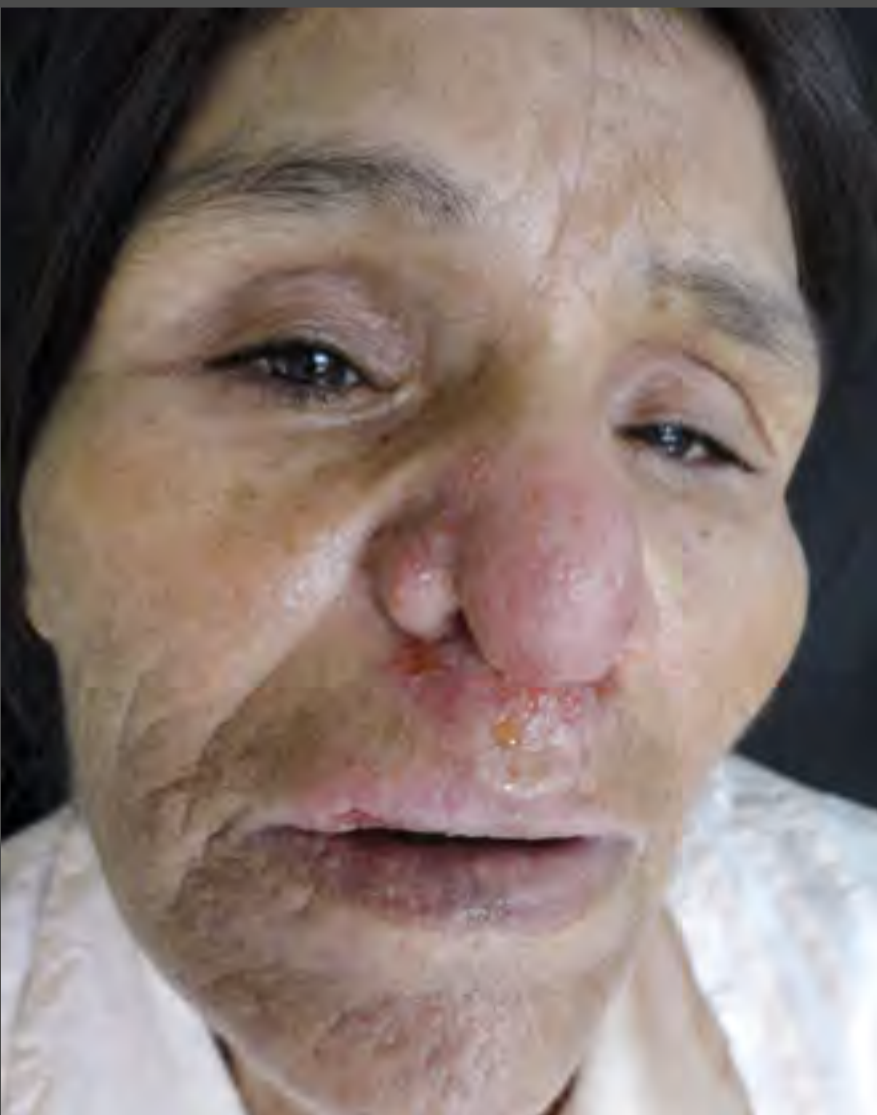
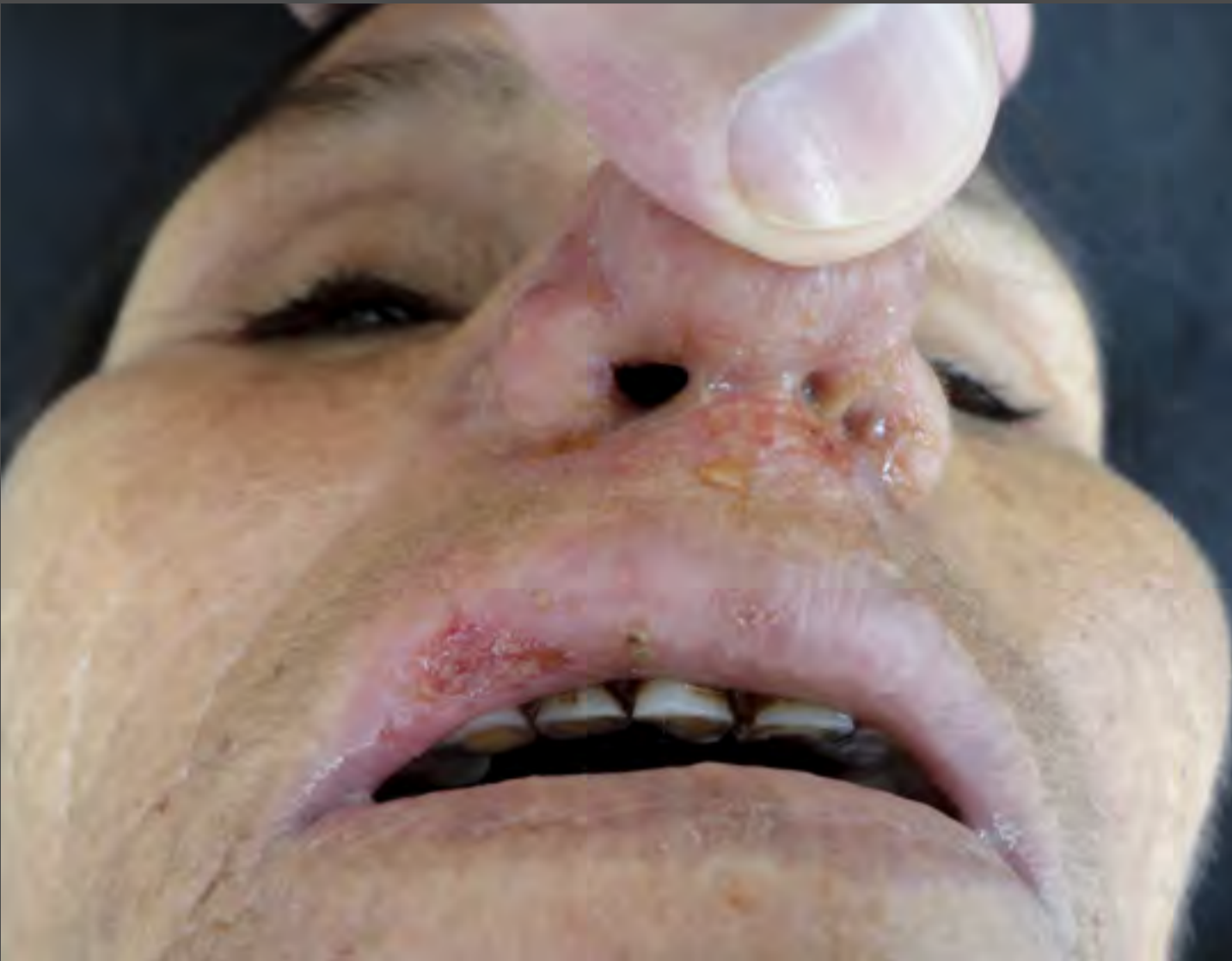




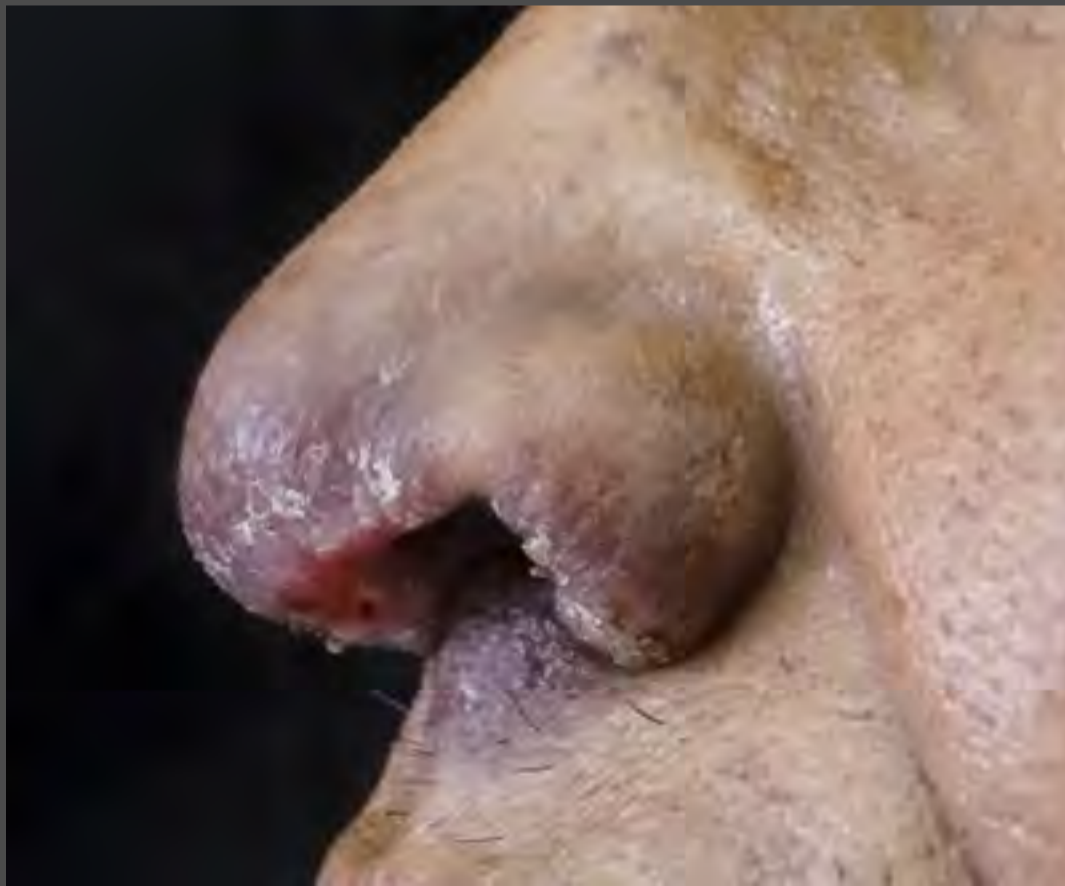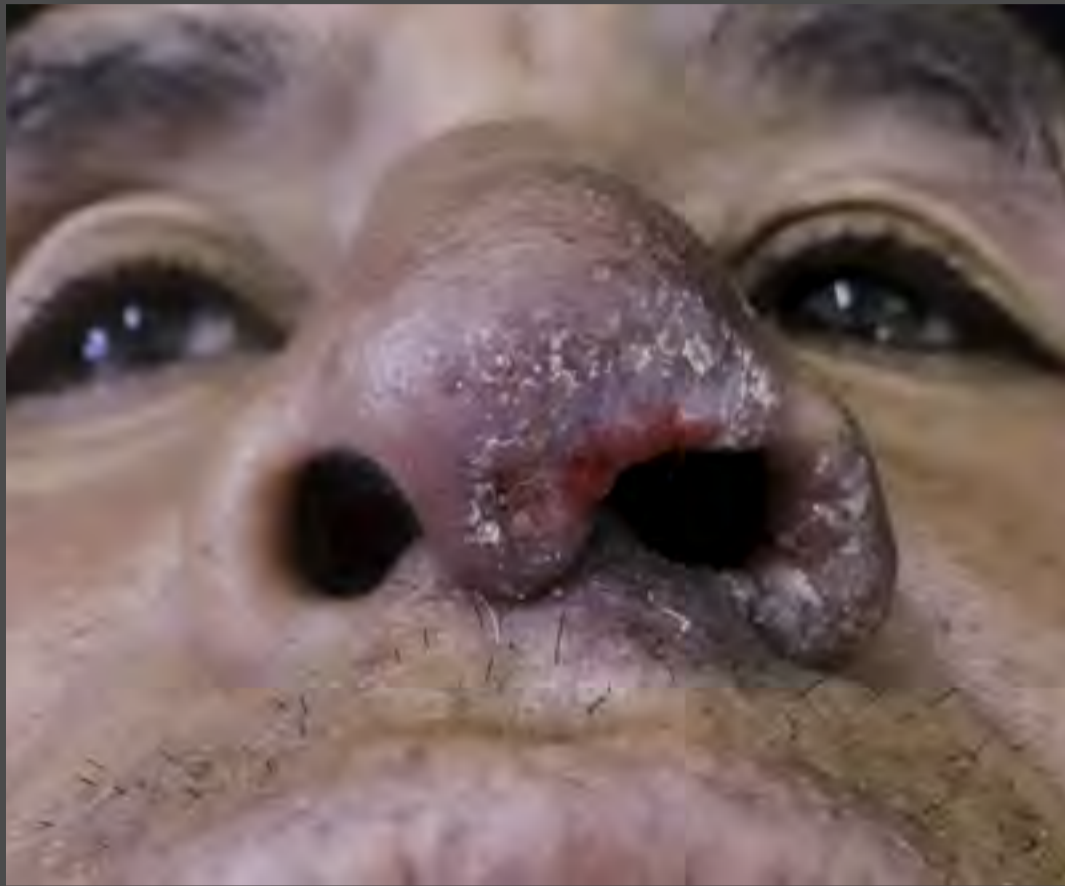**Figures 4.43C, D and E.**

Just as with cutaneous leishmaniasis, involvement of mucous membranes is also less frequent in women, but when it does occur, it adopts the same inflammatory, infiltrative, and destructive characteristics it has in men. This is a patient with a history of cutaneous leishmaniasis 22 years earlier that was treated with low-dose pentavalent antimonials and was cured. Eighteen years later, symptoms began in the nasal mucosa with pain, pruritus, and obstruction, accompanied by bloody mucus discharge and occasional frank bleeding. Spread of involvement due to contiguity to the upper lip without lesions on the palate is noteworthy. She received amphotericin B deoxycholate with improvement, but without complete resolution, and did not return for follow up. Partial obliteration of the nostrils is evident with the consequent impairment of respiratory function.



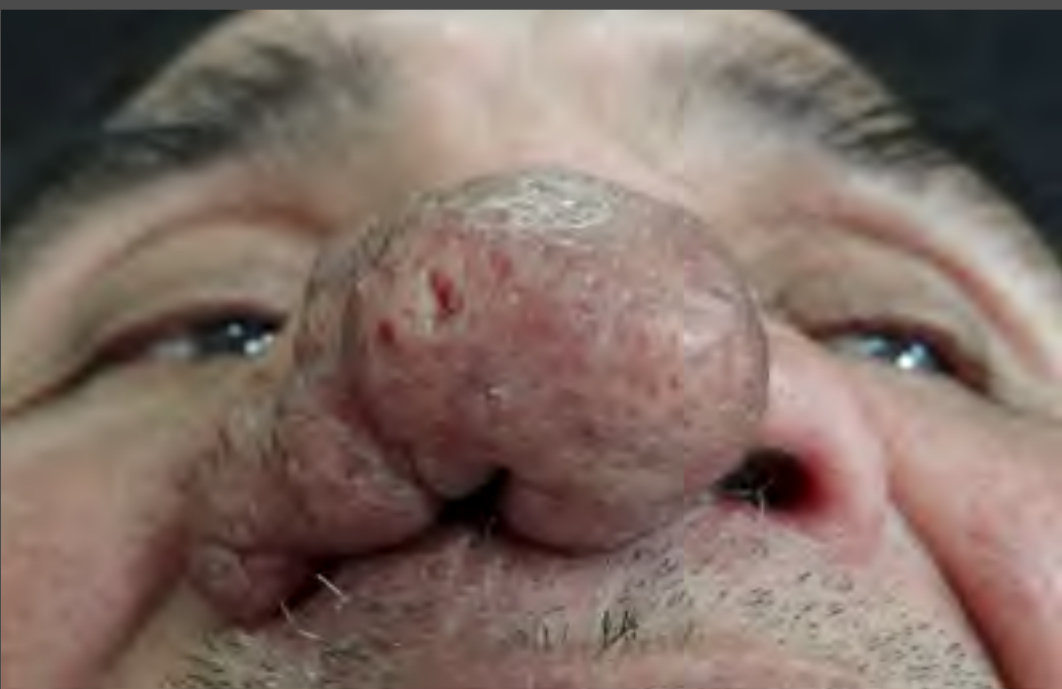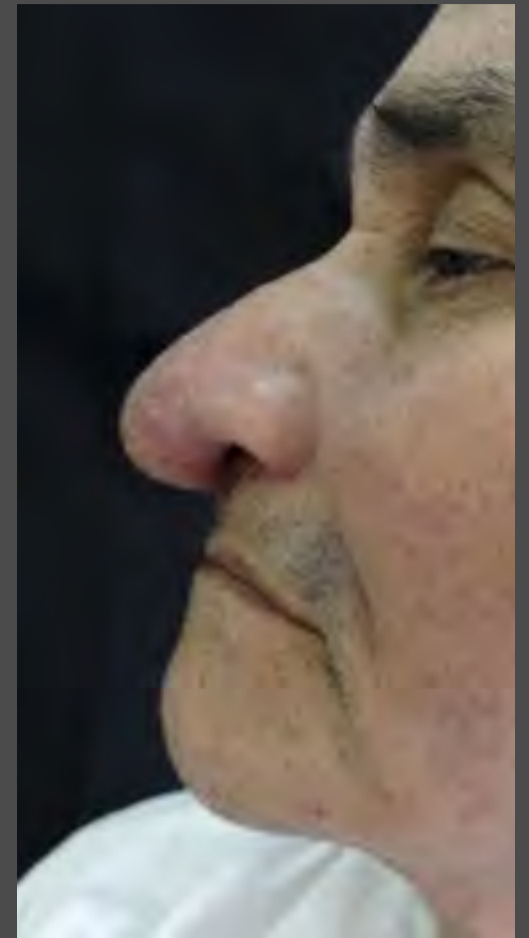
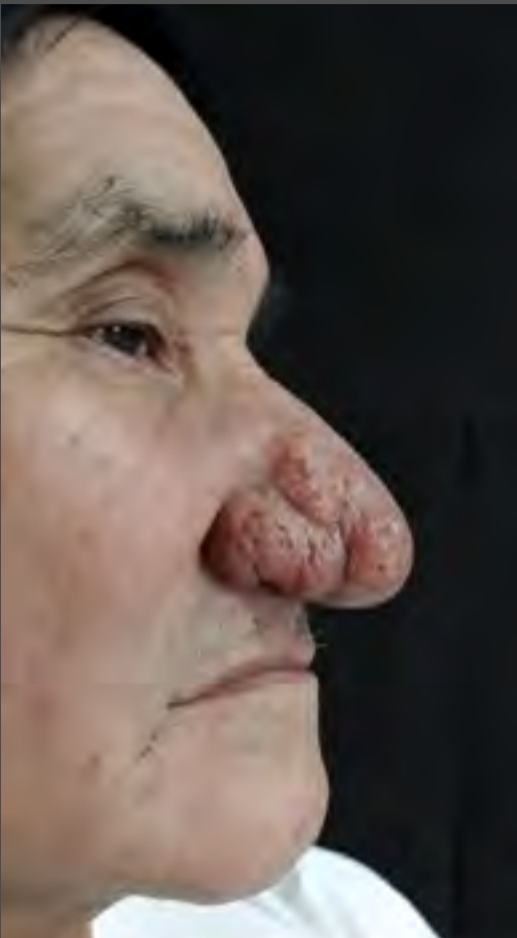#### Figures 4.43F and G.

Just as with cutaneous leishmaniasis, involvement of mucous membranes is also less frequent in women, but when it does occur, it adopts the same inflammatory, infiltrative, and destructive characteristics it has in men. This is a patient with a history of cutaneous leishmaniasis 22 years earlier that was treated with low-dose pentavalent antimonials and was cured. Eighteen years later, symptoms began in the nasal mucosa with pain, pruritus, and obstruction, accompanied by bloody mucus discharge and occasional frank bleeding. Spread of involvement due to contiguity to the upper lip without lesions on the palate is noteworthy. She received amphotericin B deoxycholate with improvement, but without complete resolution, and did not return for follow up. Partial obliteration of the nostrils is evident with the consequent impairment of respiratory function.



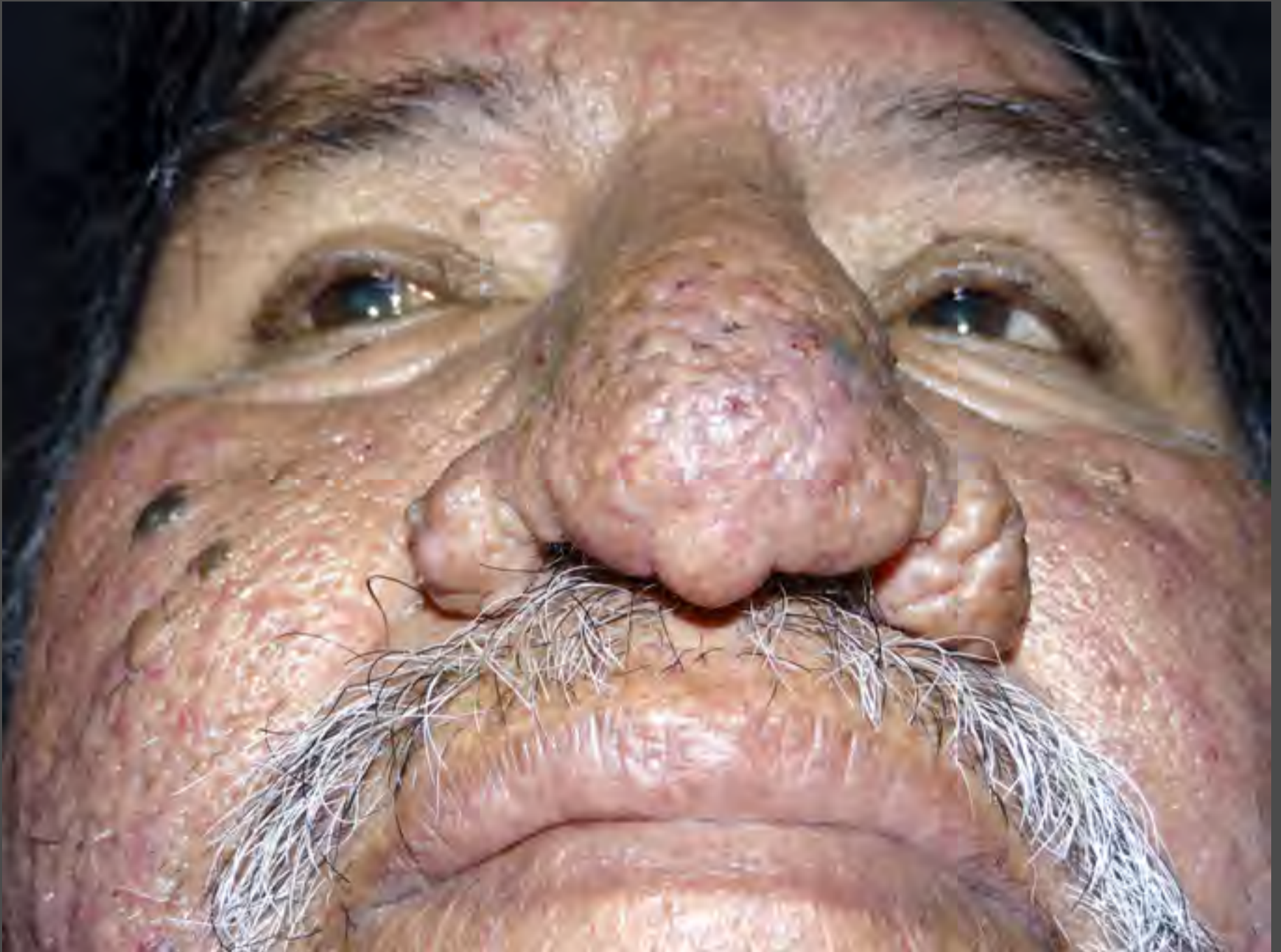**Figures 4.44A and B.**

In patients that experience recurrence of mucosal leishmaniasis, the lesions on the skin of nose and lip can take the hyperpigmented warty appearance of cutaneous recurrences.



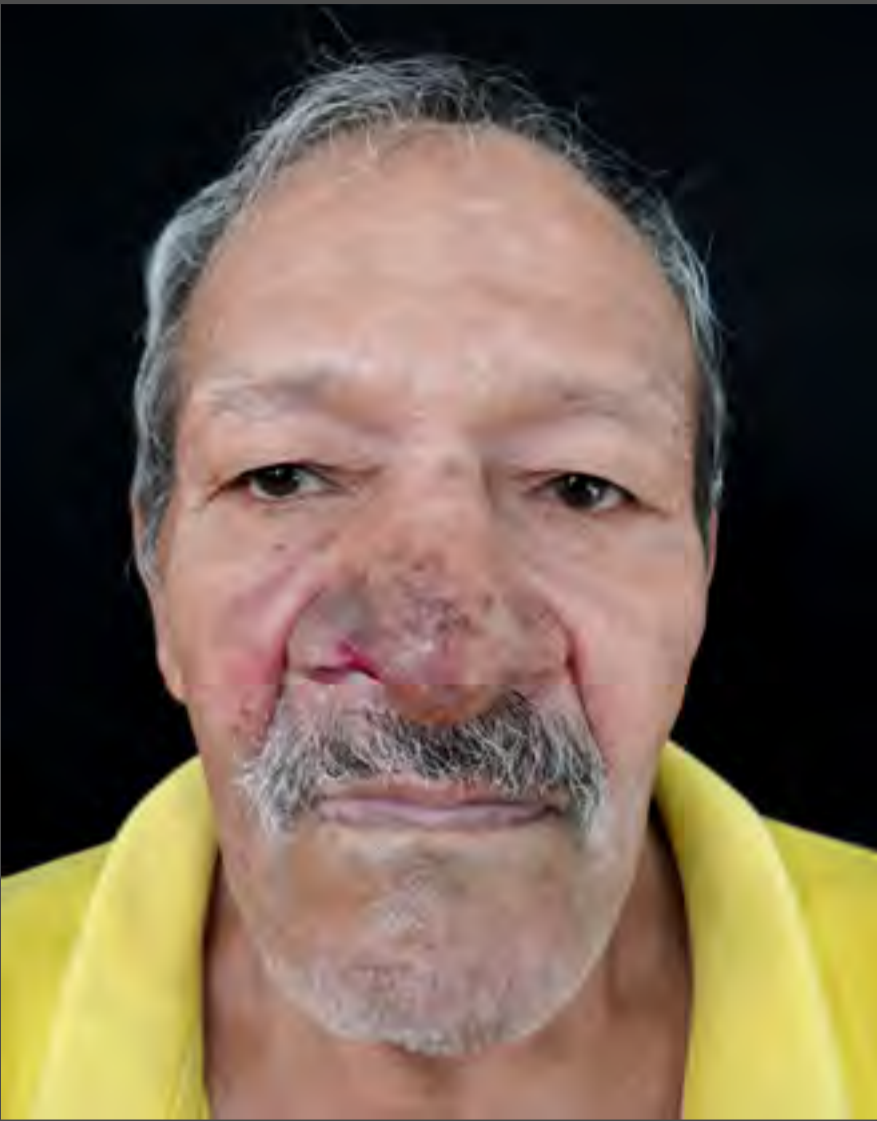**Figures 4.45A, B, C, D and E.**

Chronicity of nasal mucosal lesions leads to severe impairment of the nasal pyramid architecture, as in this case, in which the nose has become bulbous and lobed, with orange-peel skin and pronounced follicular orifices (*ostia*), which therefore take on an appearance similar to that of rhinophyma, with considerable involvement on the right side and almost none on the left side.



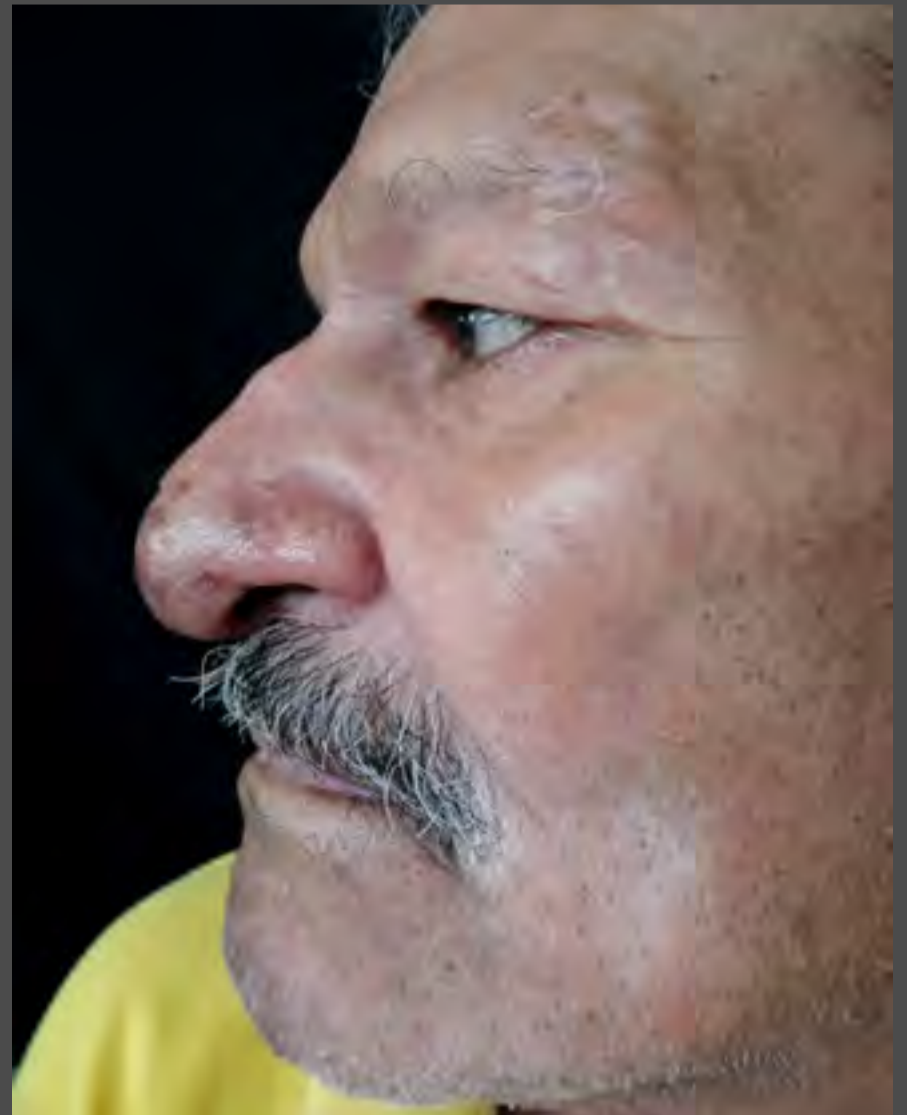
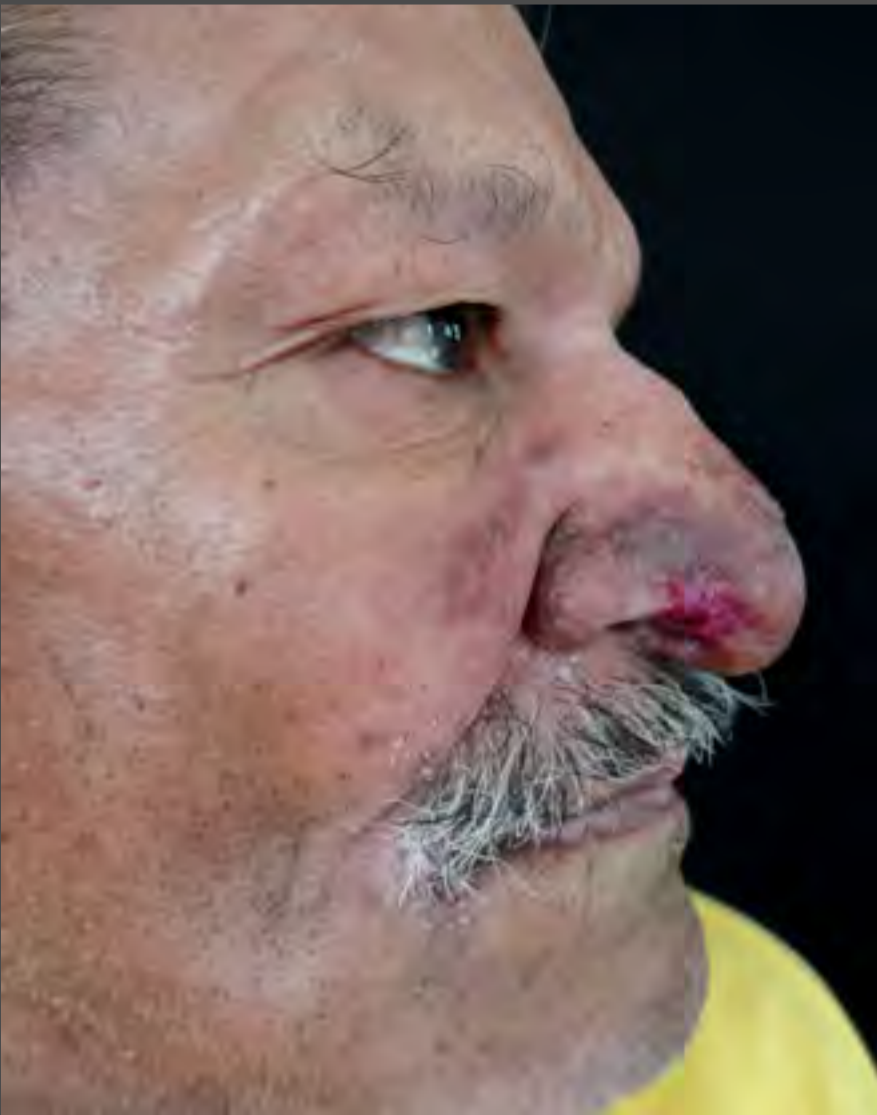**Figure 4.46.**

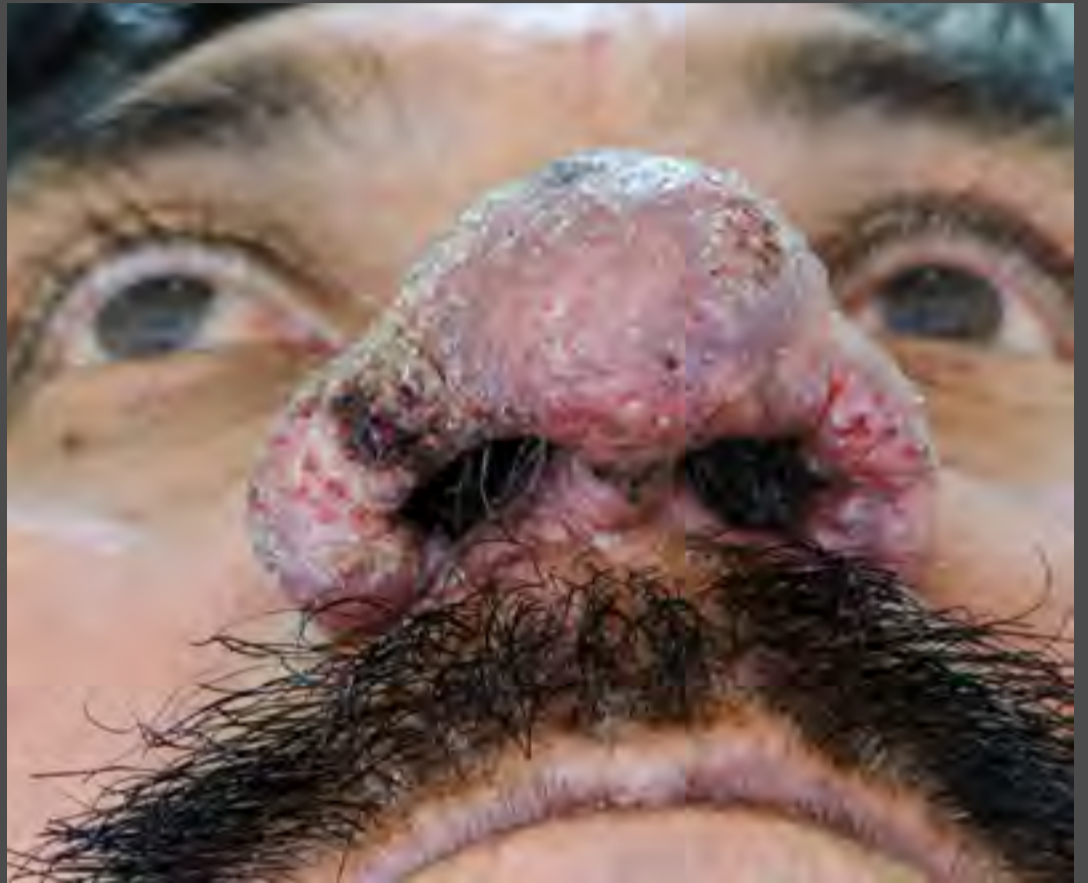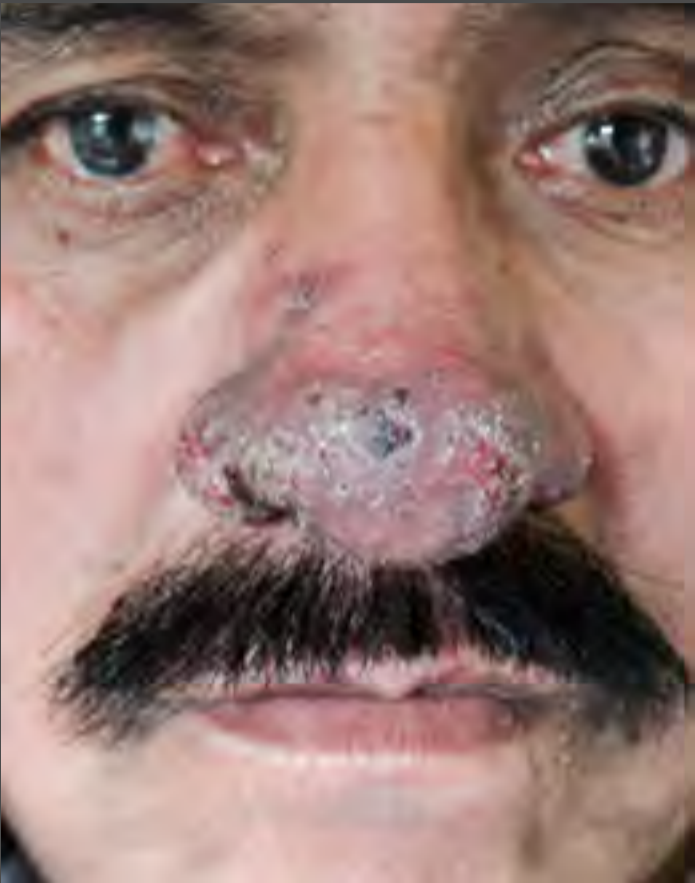Mucosal leishmaniasis that resembles rhinophyma due to the granular, exuberant, and micropapular appearance of the skin, but in which there is loss of the columella leading to drooping of the tip of the nose.



**Figures 4.47A, B and C.**

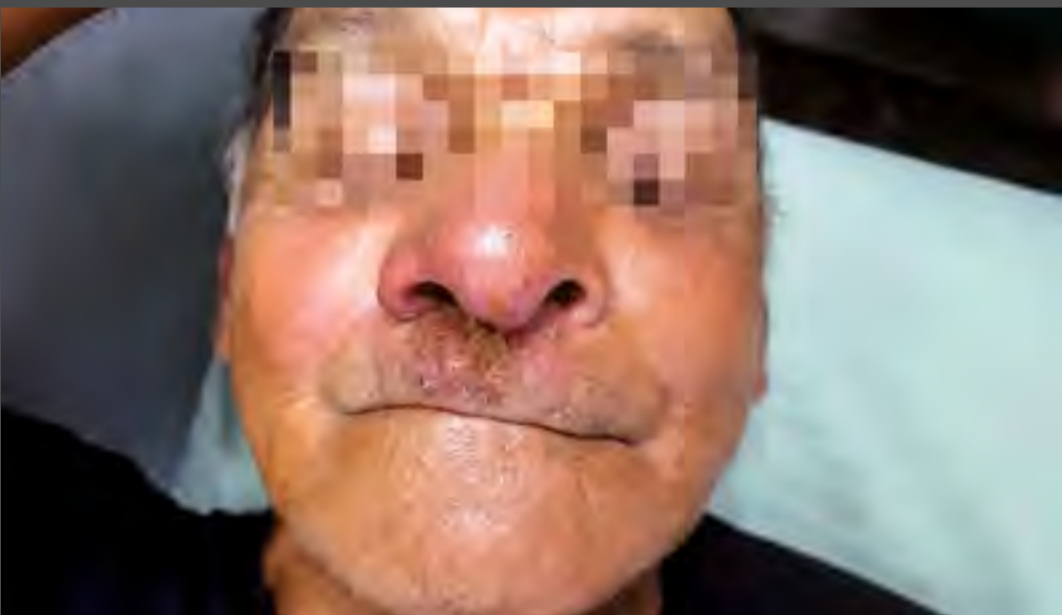Increased volume of the nasal pyramid secondary to edema and infiltration both of the mucous membrane and of the skin, and evident drooping of the tip of the nose, which is practically touching the upper lip, leading to the presumption that the septum has been destroyed.





**Figures 4.48A and B.**

The vegetative appearance of the nose in this patient corresponds to a hyperkeratotic, warty, and crusted response, similar to the warty lesions of cutaneous leishmaniasis.

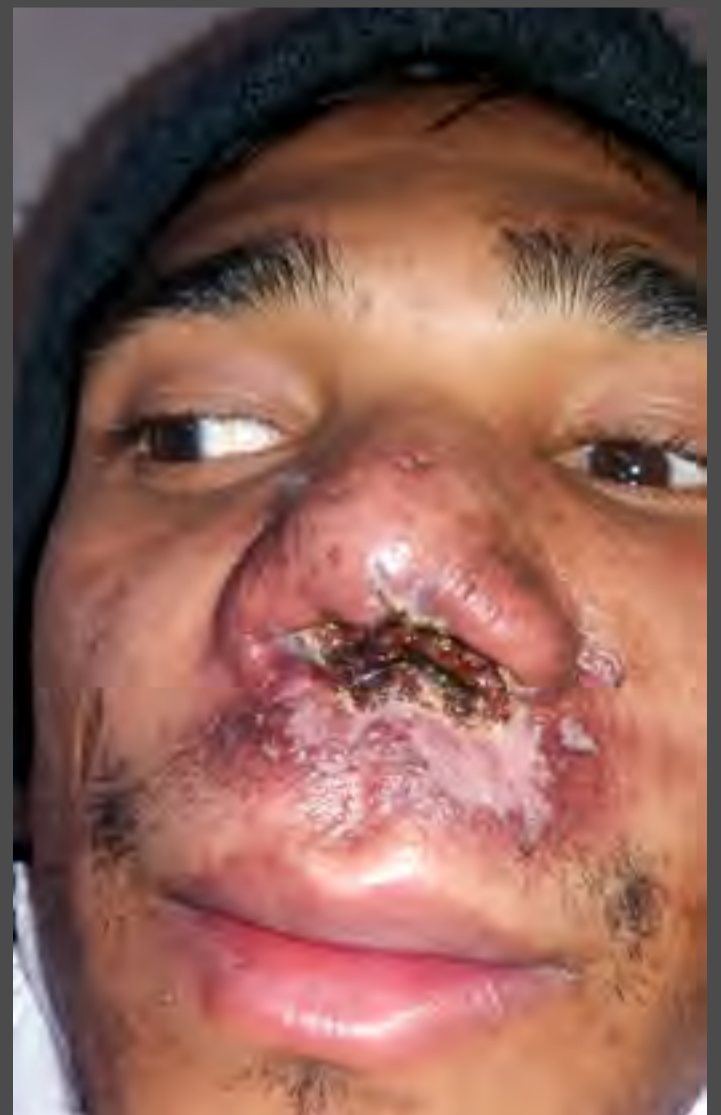

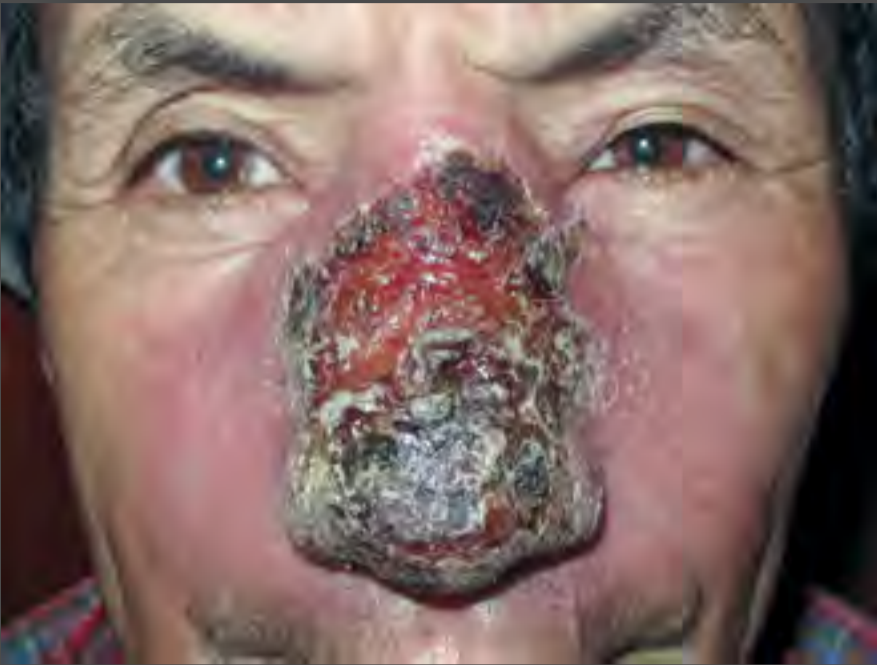**Figure 4.49.**

Involvement of the upper lip due to spread from the nasal mucosa. The right nostril and the tip of the nose are erythematous, edematous, and inflamed, as well as the lip, which, in addition, has abundant serous crusts.

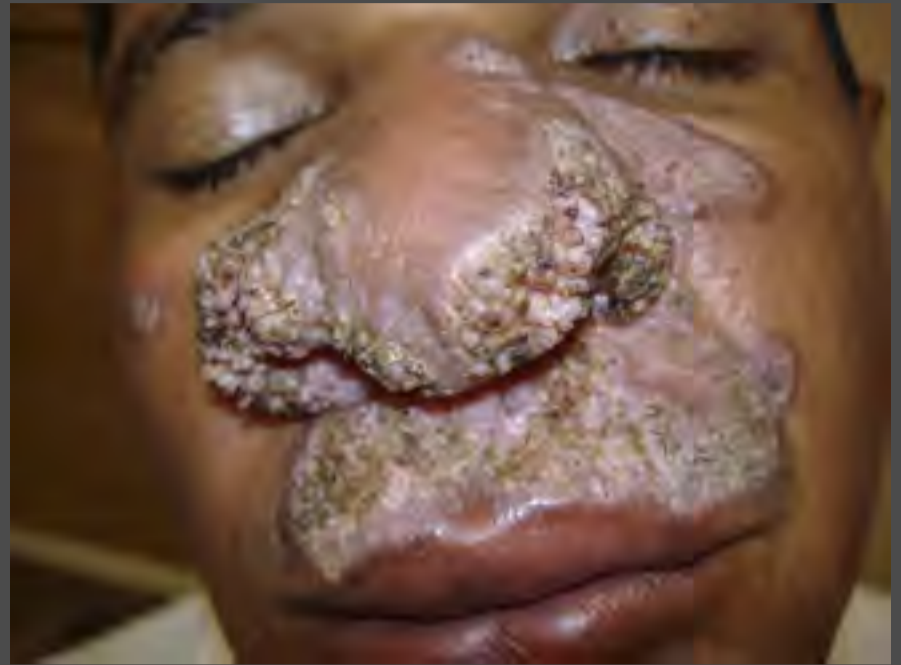**Figure 4.50.**

Ulceration of the nasal mucosa with destruction of the septum—*Leishmania (V.) braziliensis*

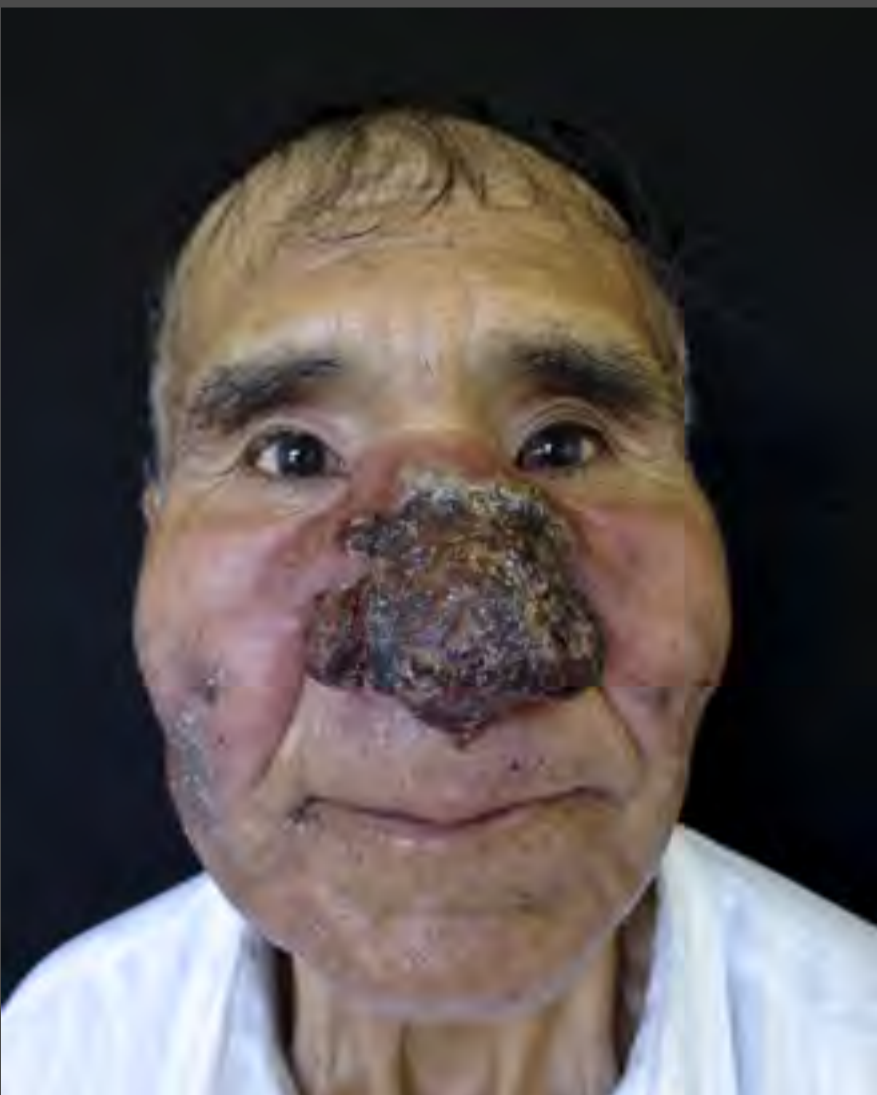



**Figure 4.51.**  
Mucocutaneous leishmaniasis. Ulcerative lesion, with erythematous crusty surface that involves the entire nose.

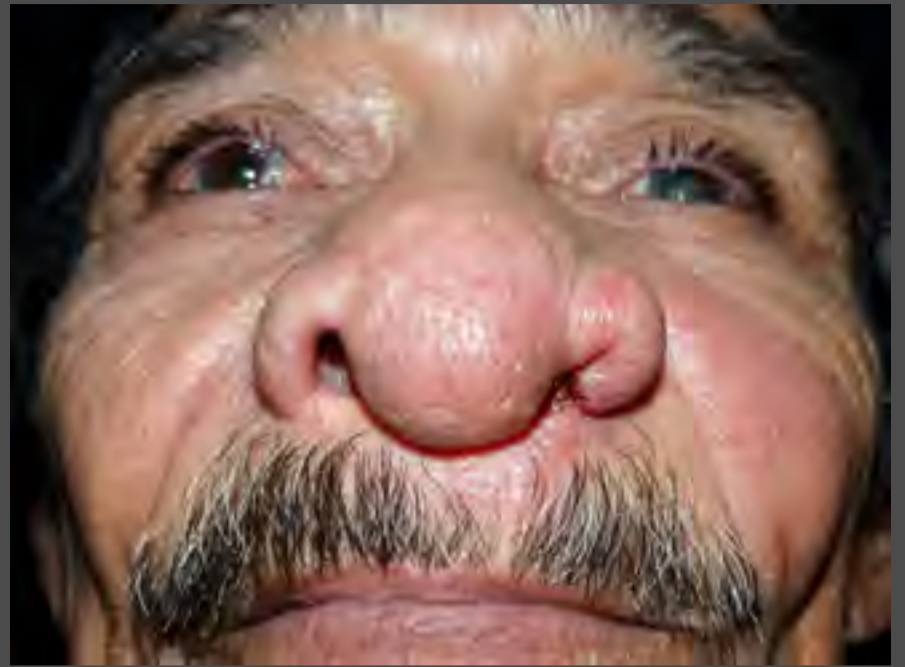
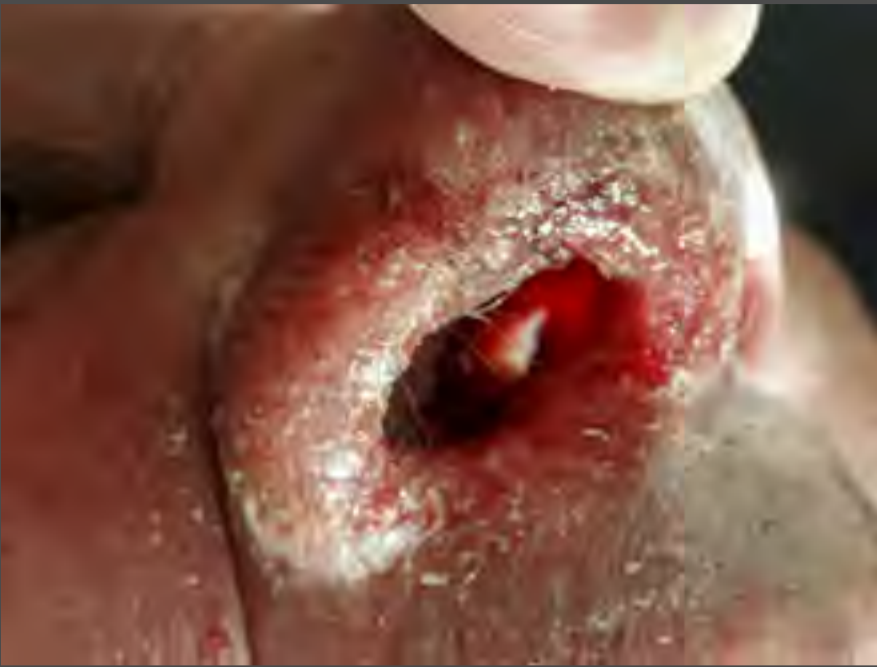
**Figure 4.52.**  
Vegetative lesions on the face, with extensive involvement of the nasal rim and mucosa, and of adjacent tissues



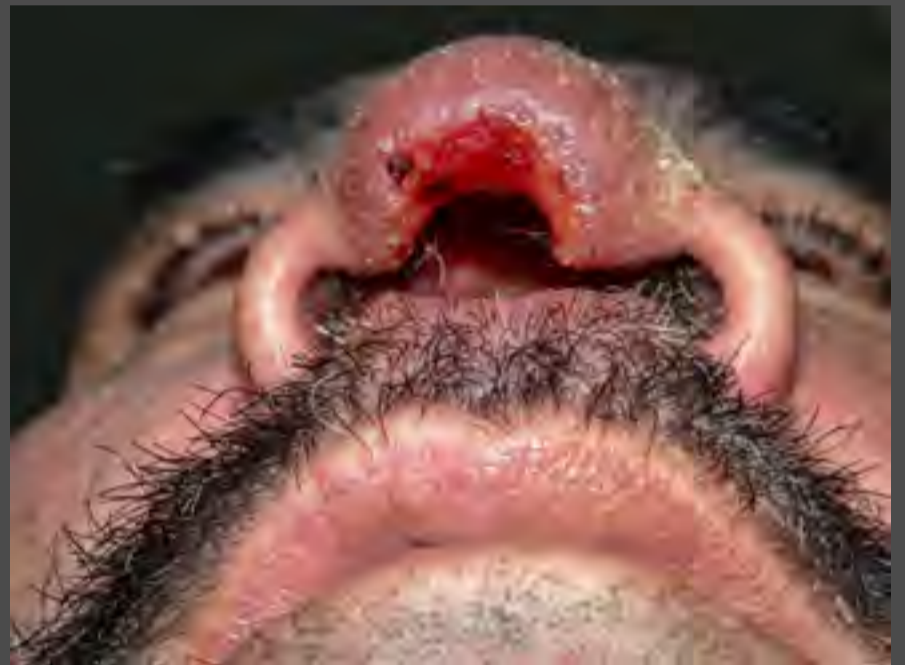**Figure 4.53.**  
Intense edema and inflammation of the nose and neighboring areas on the cheeks. Presence of abundant adherent crusts resulting from accumulation of secretions, cellular detritus, and treatments that the patient applies directly to the lesion. Many patients let the crusts accumulate for fear of pain when removing them or because they believe, erroneously, that removing them causes the lesion to spread or deepen.





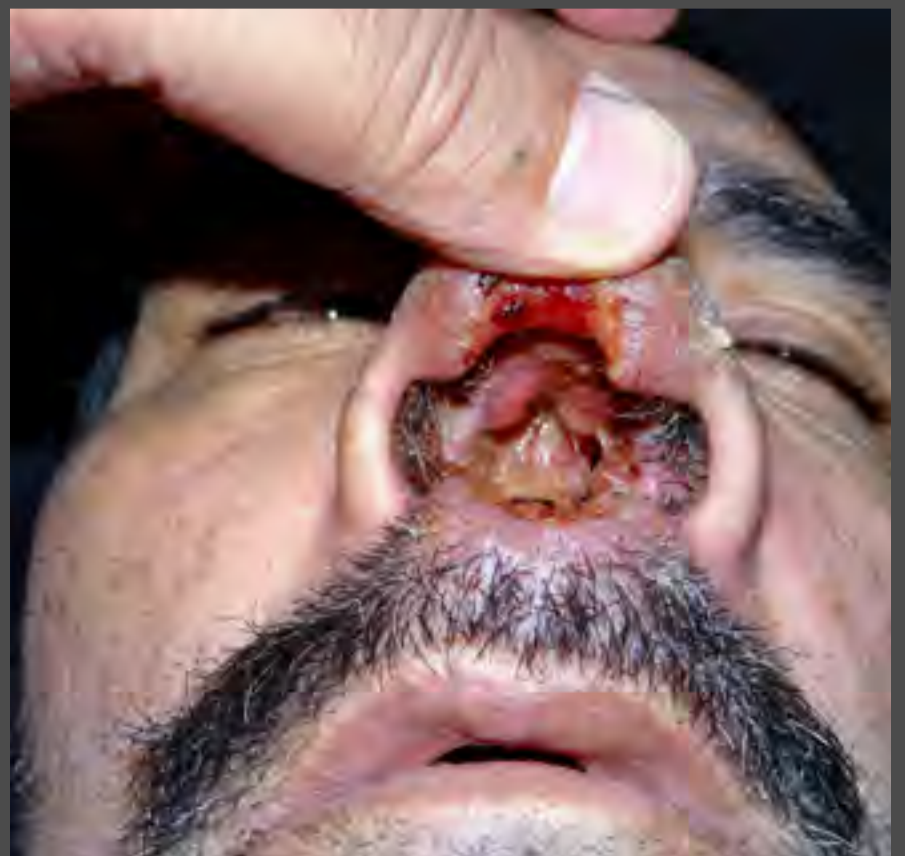**Figure 4.54.**

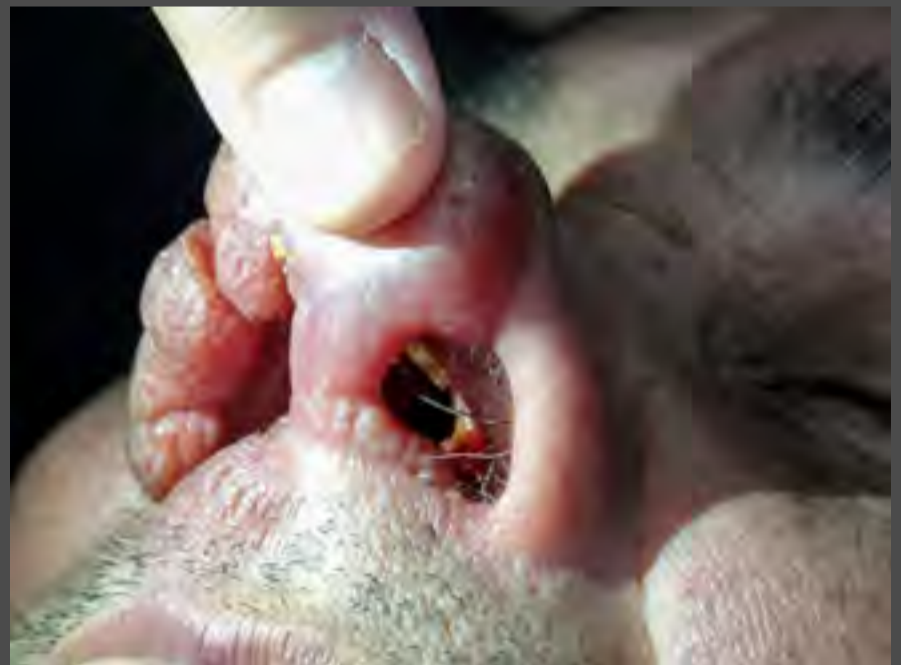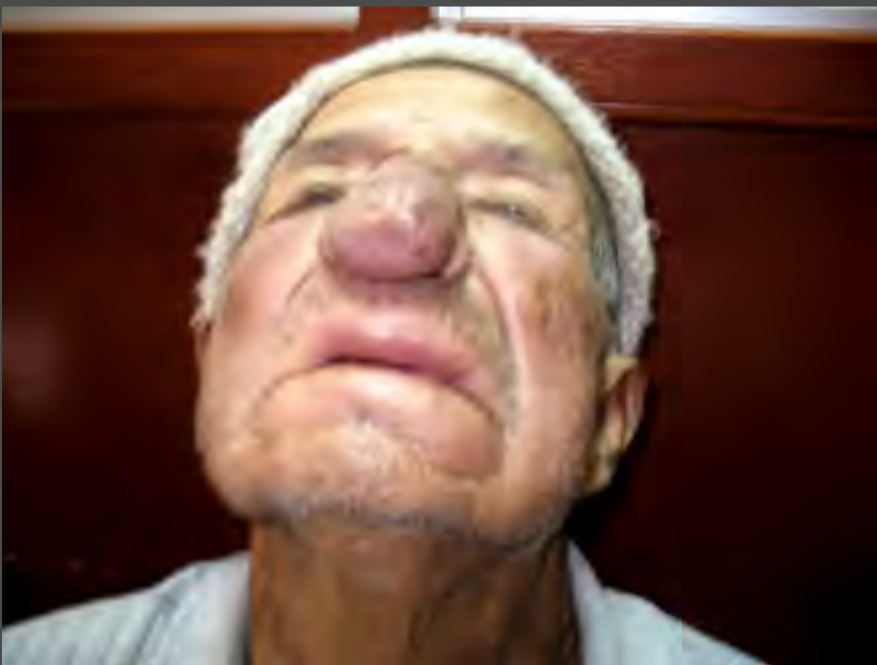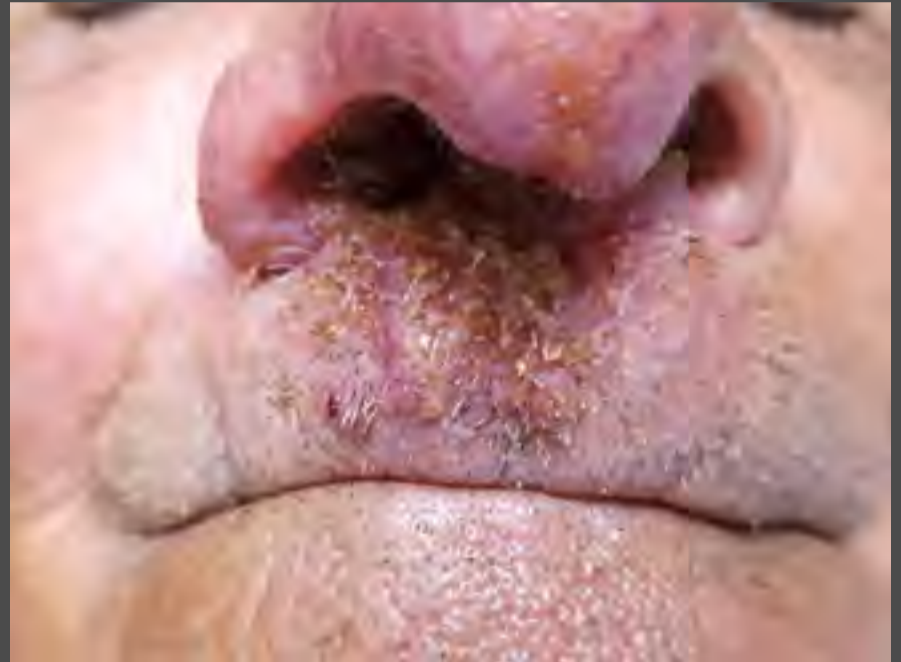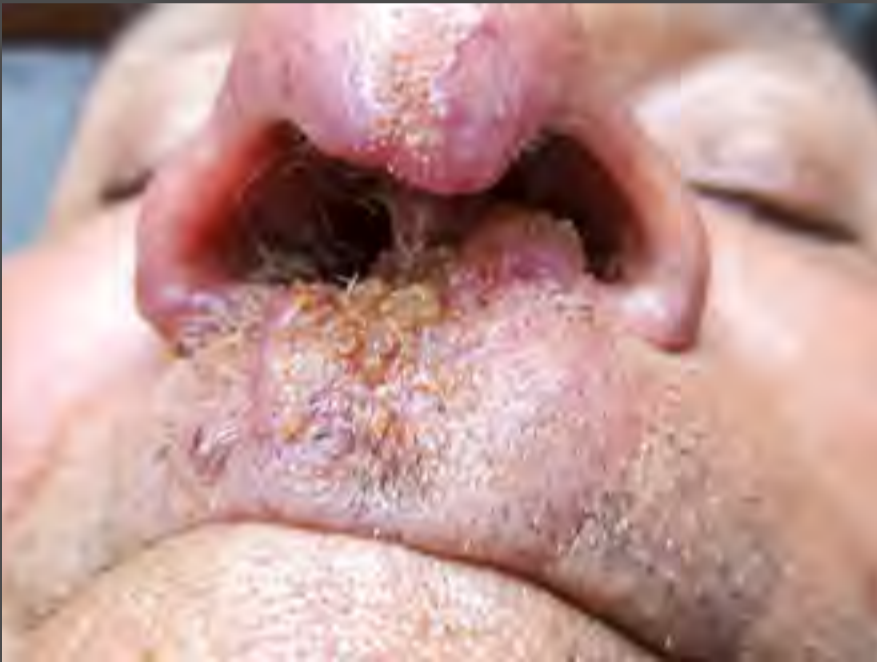Inflammation produces serous exudation that dries to form crusts that should be removed daily during cleaning and dressing as an important part of treatment of the disease.



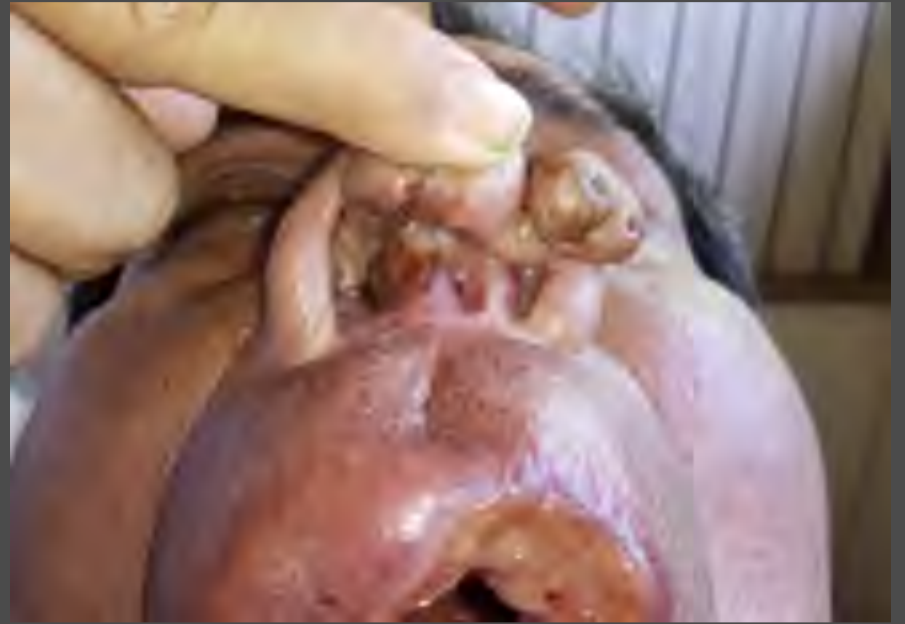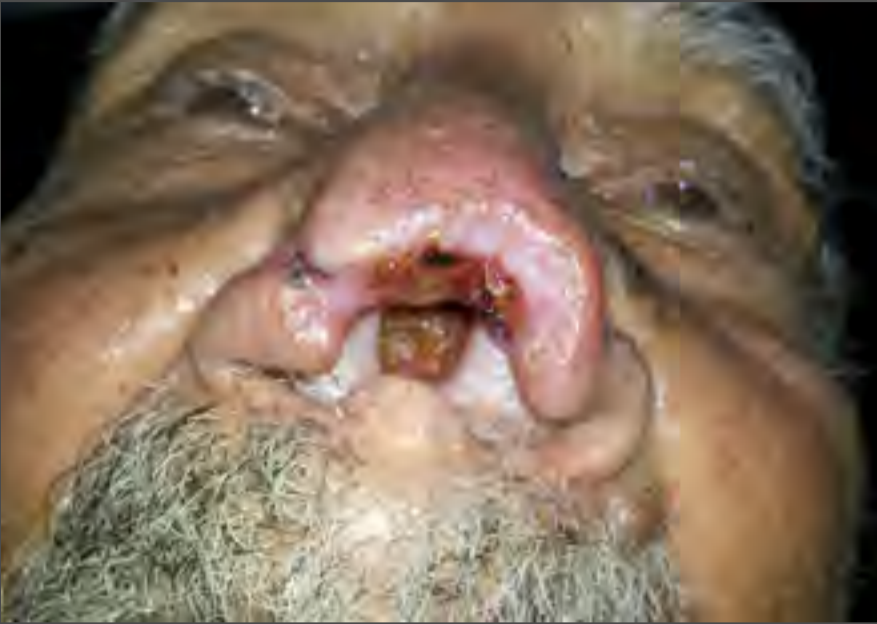**Figures 4.55A, B and C.**

Total loss of the nasal septum, leaving a single nonfunctional cavity that does not filter, humidify, or heat the air and that leaves the turbinates and the orifices into the paranasal sinuses exposed, thereby facilitating development of concomitant bacterial infections. With no septum, the tip of the nose drops taking on the tapir nose appearance described above. Early detection of mucosal involvement and complete proper treatment should be a priority to prevent such severe damage.



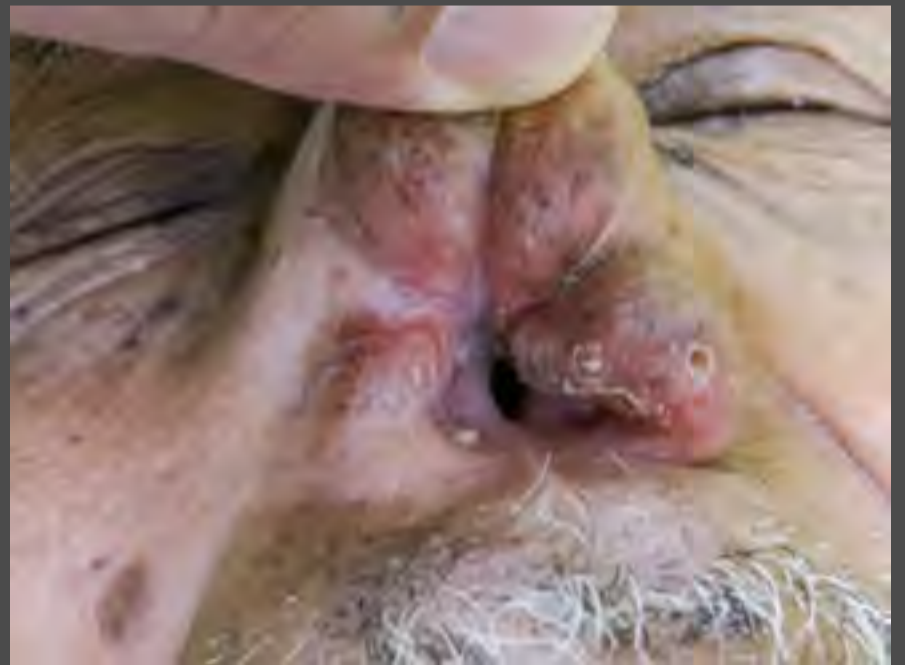
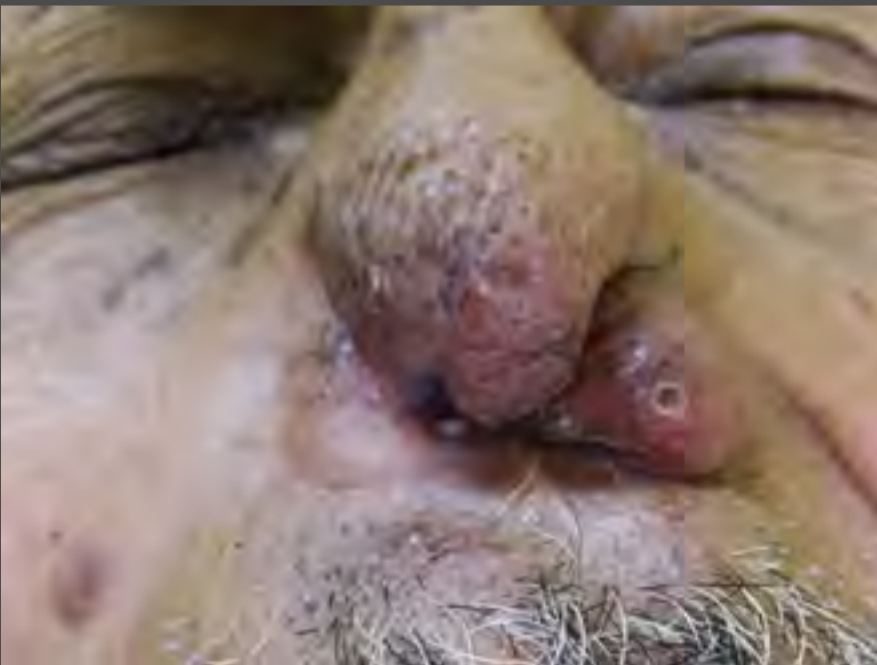
**Figures 4.56A, B, C and D.**  
Late nasal involvement, with nasal septum destruction and deformity in three patients



**Figures 4.57A and B.**

It is evident in these patients that scar tissue has replaced the nasal mucosa, therefore adding a functional disorder to the severe anatomical defect. In addition to leishmaniasis drugs, all patients with mucosal involvement should receive local management from the beginning that helps to limit damage and preserve function. All patients with mucosal leishmaniasis should be managed together with otorhinolaryngologists and with respiratory and speech-and-language therapists. Surgical reconstruction should be attempted once there is certainty that the leishmaniasis has been cured.



**Figures 4.58A and B.**

Significant sequelae from mucosal leishmaniasis with obliteration of the nostrils from extensive fibrosis secondary to the severe, persistent, and continuous inflammatory process, makes this a practically nonfunctional nose.



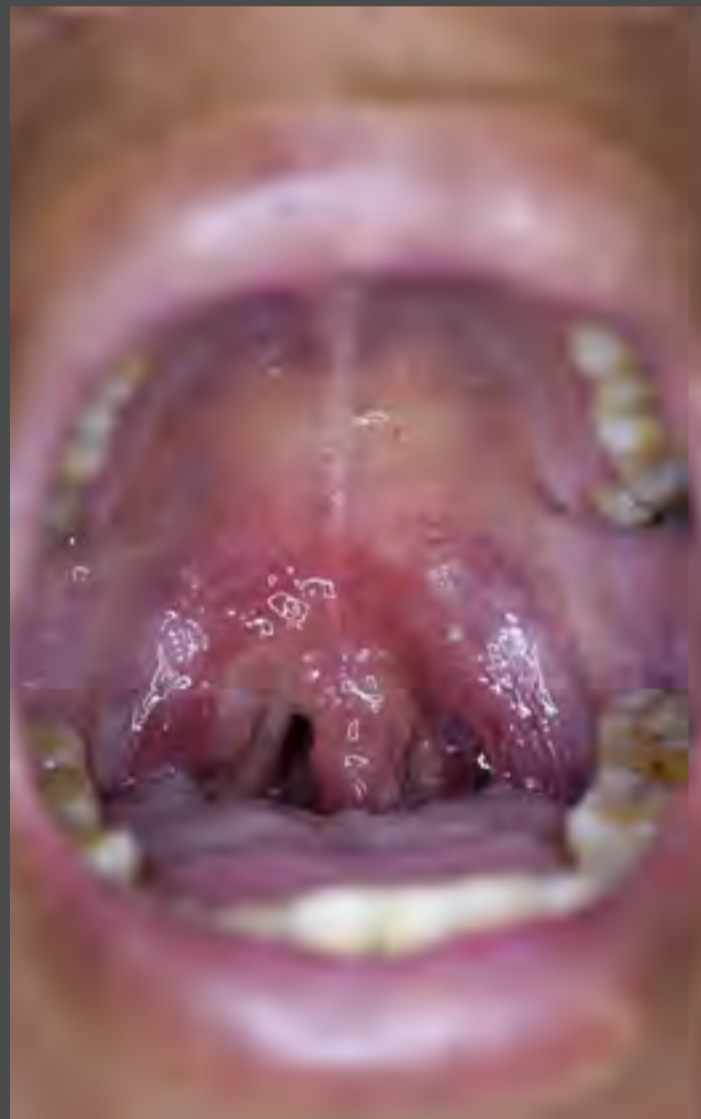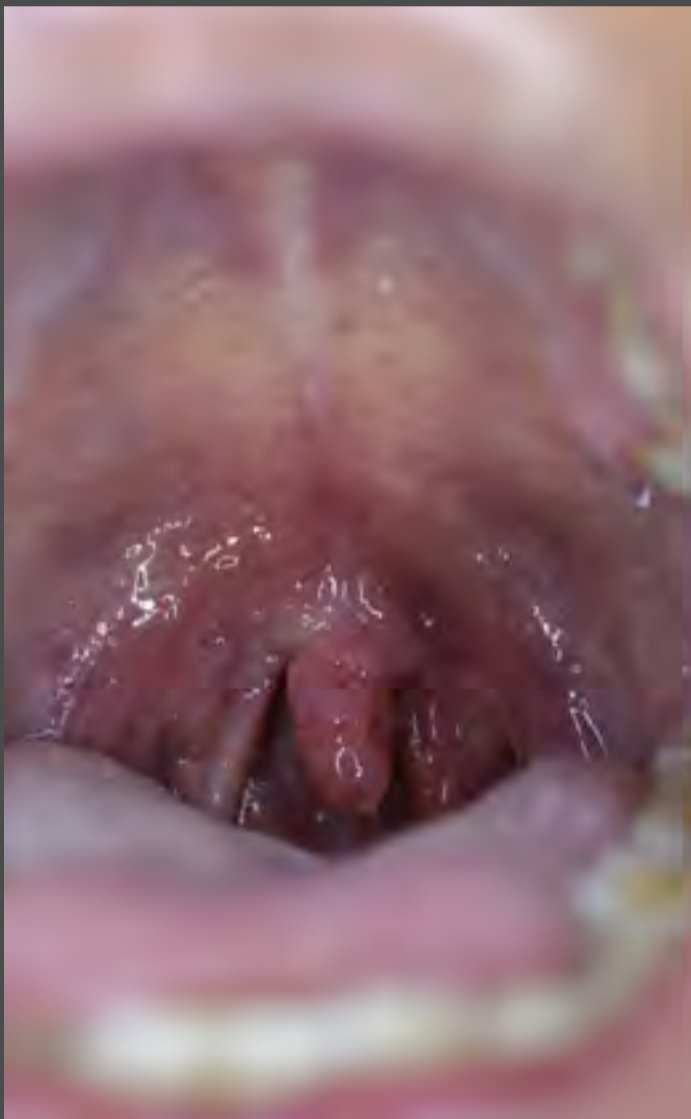Table 4.3. Levels of mucosal disease severity

Mild	Moderate	Severe
<p>When it is limited to the nasal cavity, oropharynx, or both; usually manifested by nasal obstruction and bloody crusts (<i>Figures 4.20 a 4.58</i>).</p>	<p>When it also involves the oral cavity, supraglottis, and epiglottis; clinically, mild to moderate dysphonia and odynophagia occur (<i>Figures 4.59 a 4.63</i>).</p>	<p>When it also involves the vocal cords, subglottis, and 70% to 80% of the trachea. Clinical manifestations are significant dysphonia and odynophagia and moderate to severe difficulty breathing (<i>Figures 4.64 a 4.74</i>).</p>



**Figures 4.59A and B.**

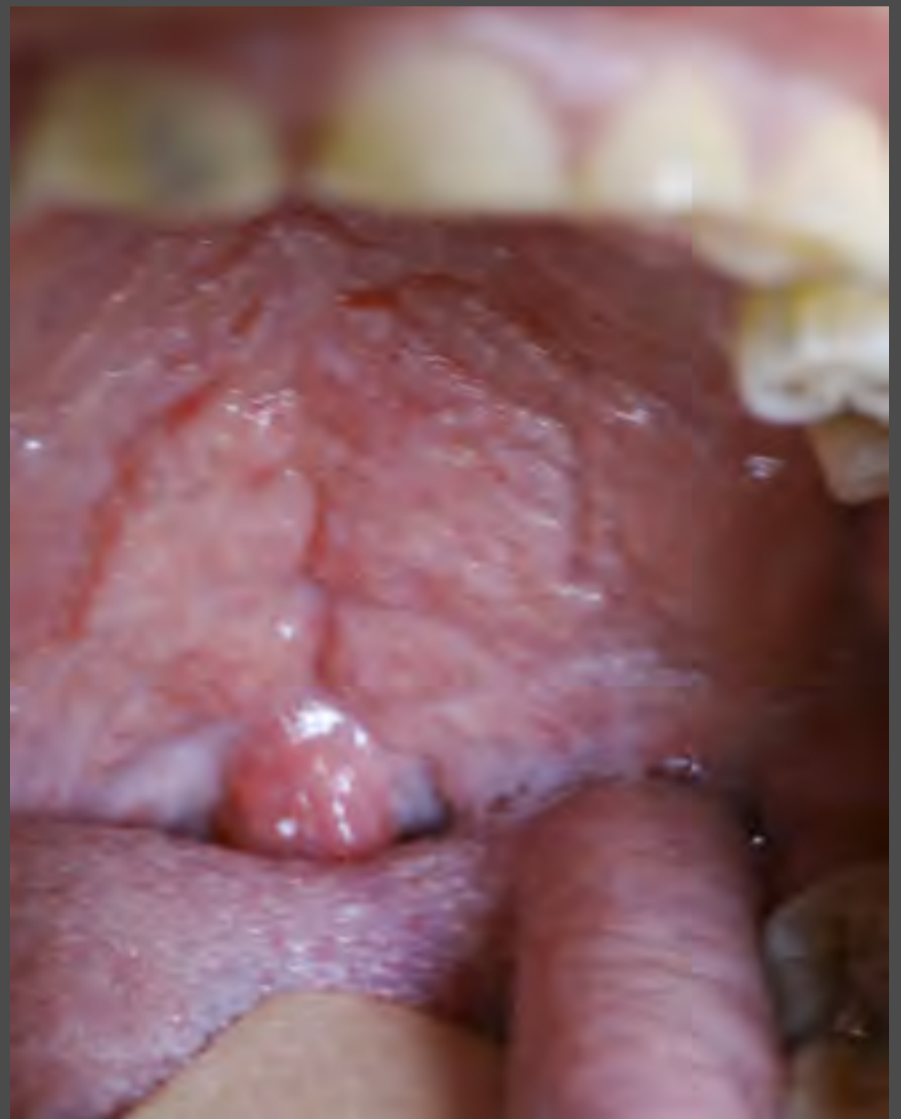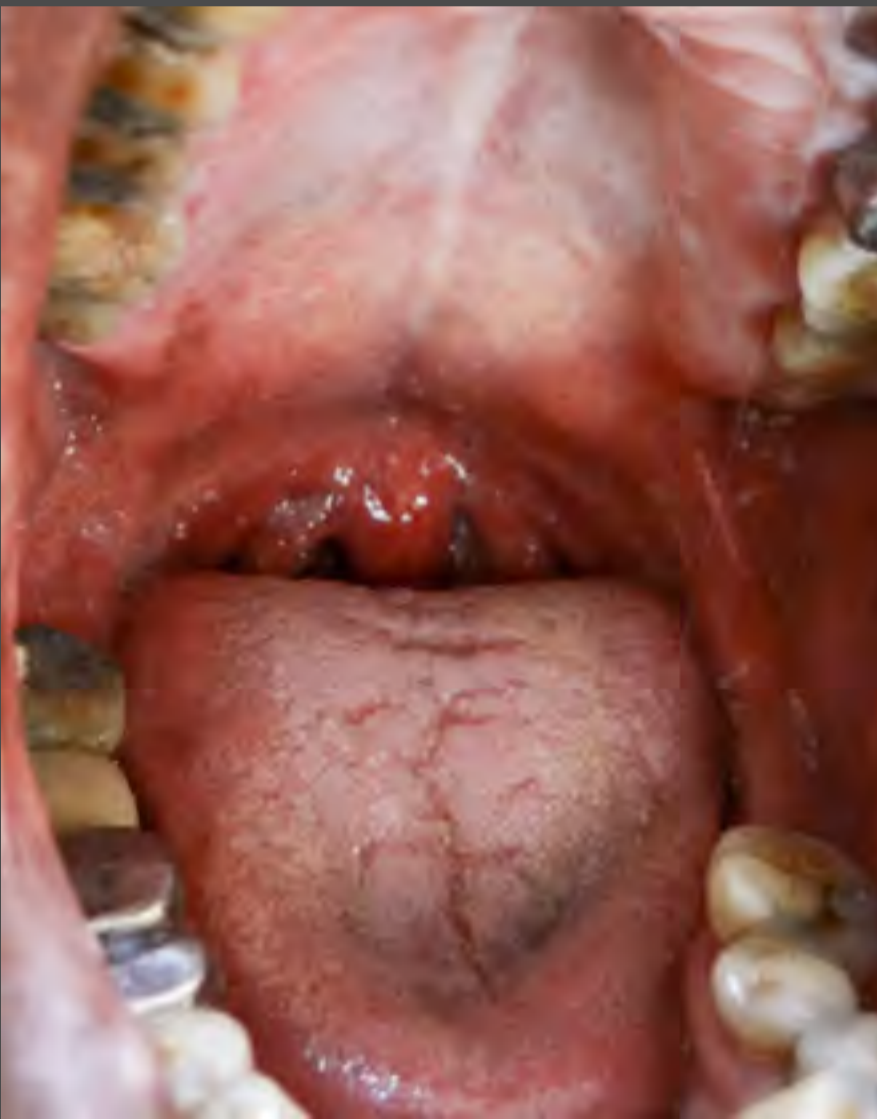The anterior pillars, soft palate, and uvula are affected in all mucosal leishmaniasis patients, although with different degrees of involvement.





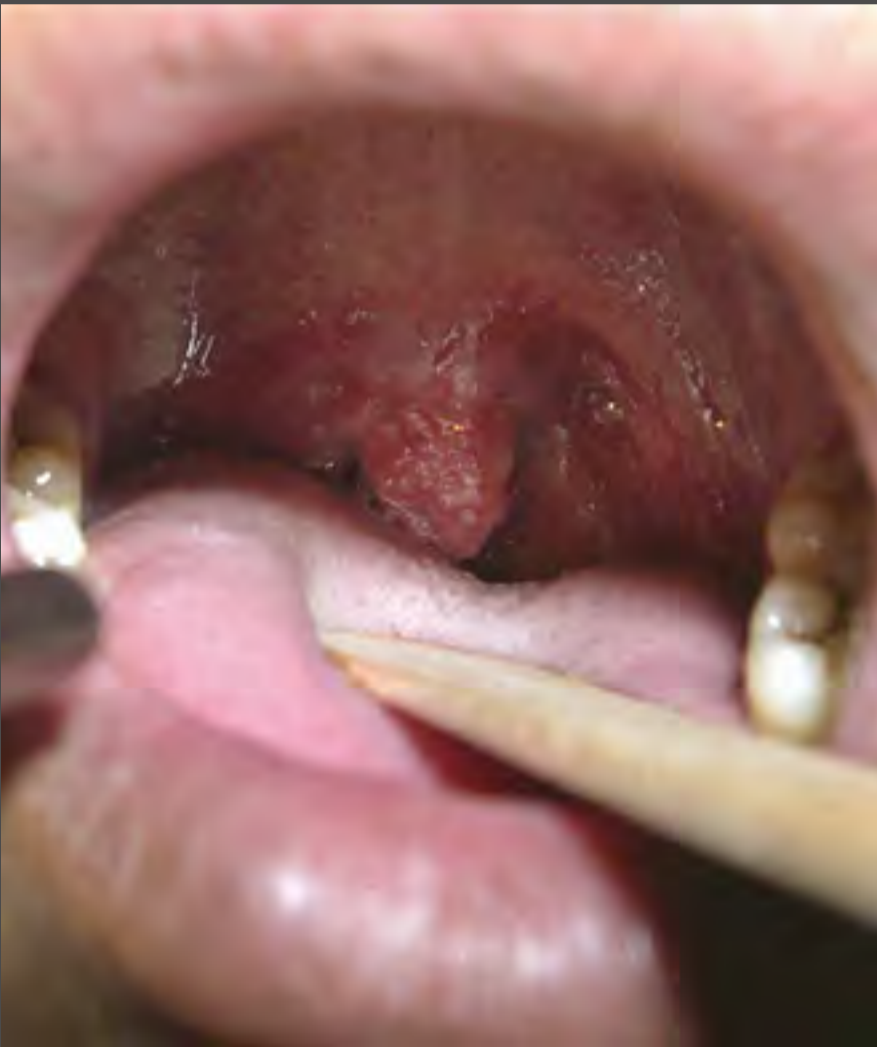**Figures 4.59C and D.**

The anterior pillars, soft palate, and uvula are affected in all mucosal leishmaniasis patients, although with different degrees of involvement.

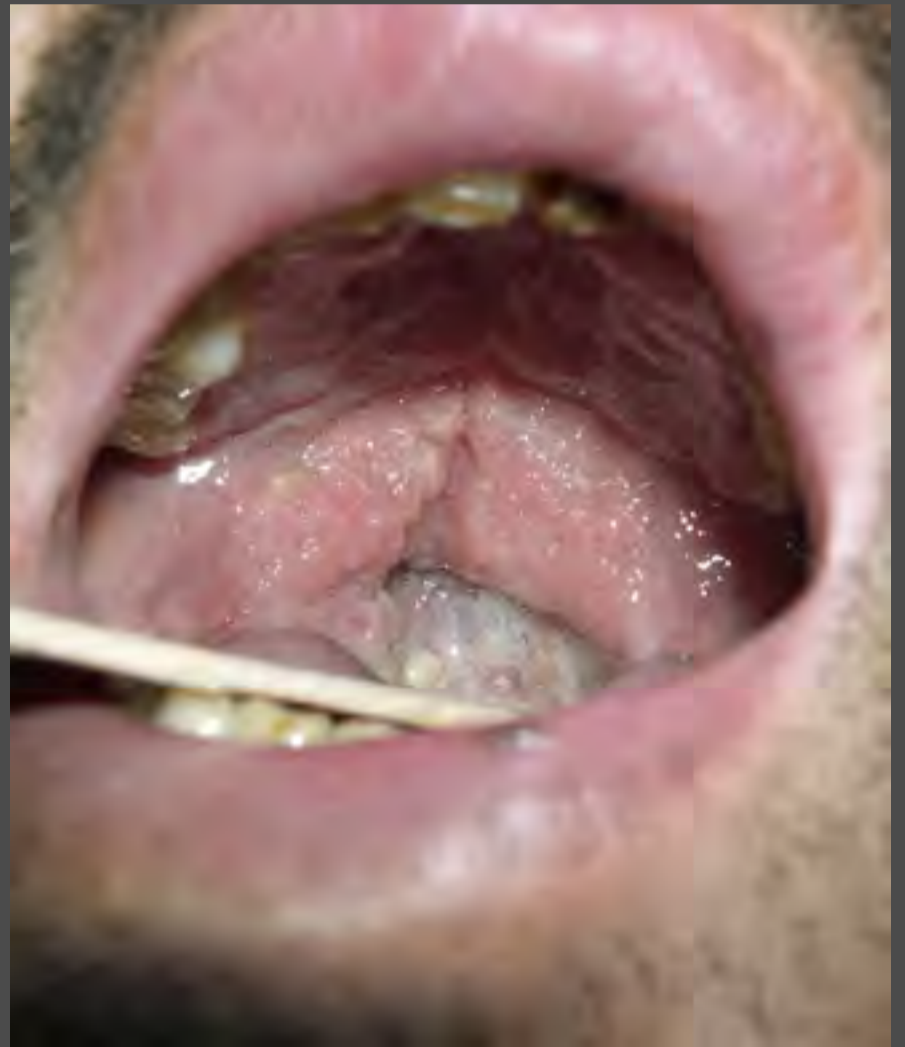

**Figures 4.59E and F.**

The anterior pillars, soft palate, and uvula are affected in all mucosal leishmaniasis patients, although with different degrees of involvement.

**Figure 4.59E.**

Granulomatous infiltration of the soft palate, especially the uvula

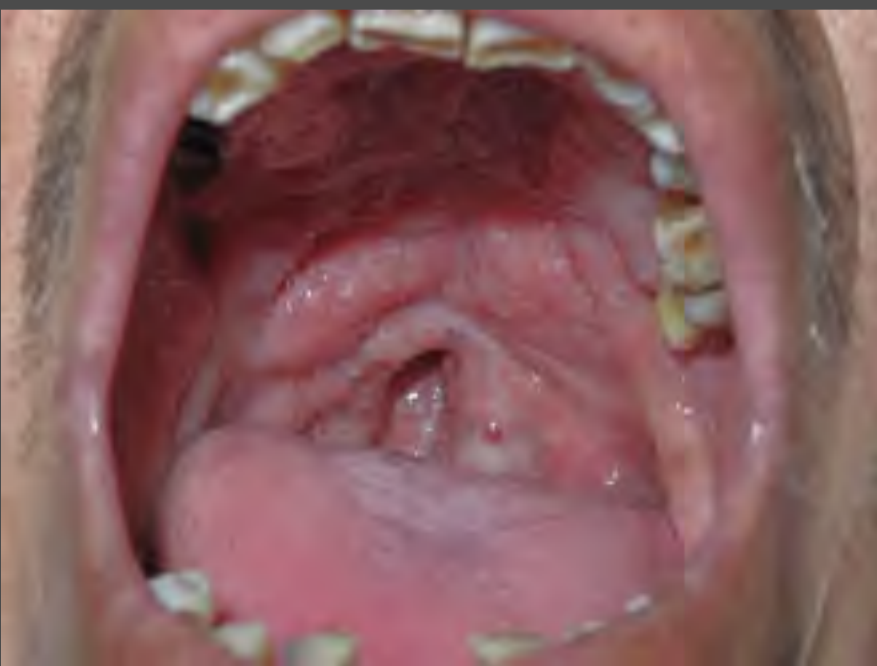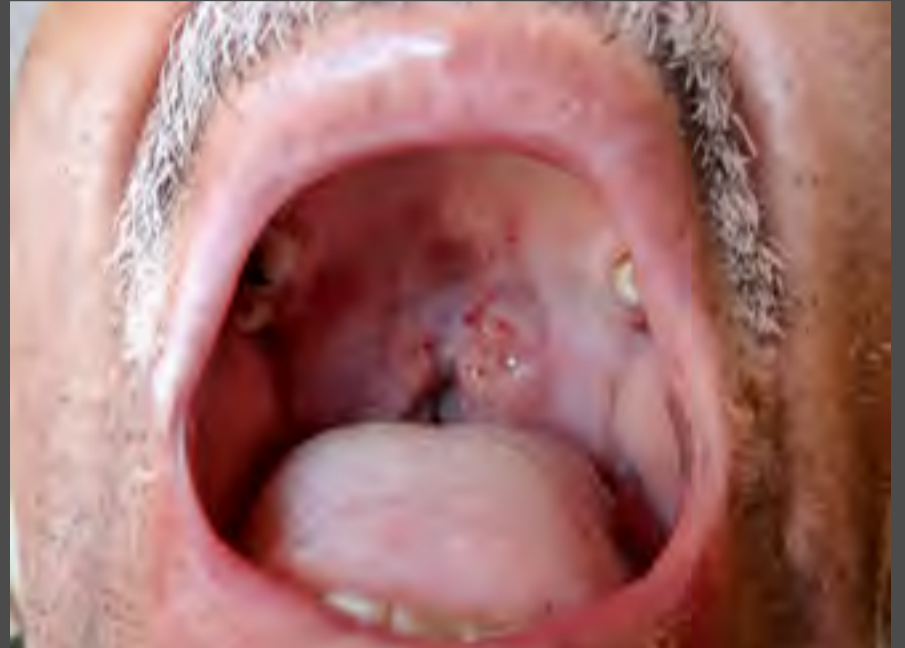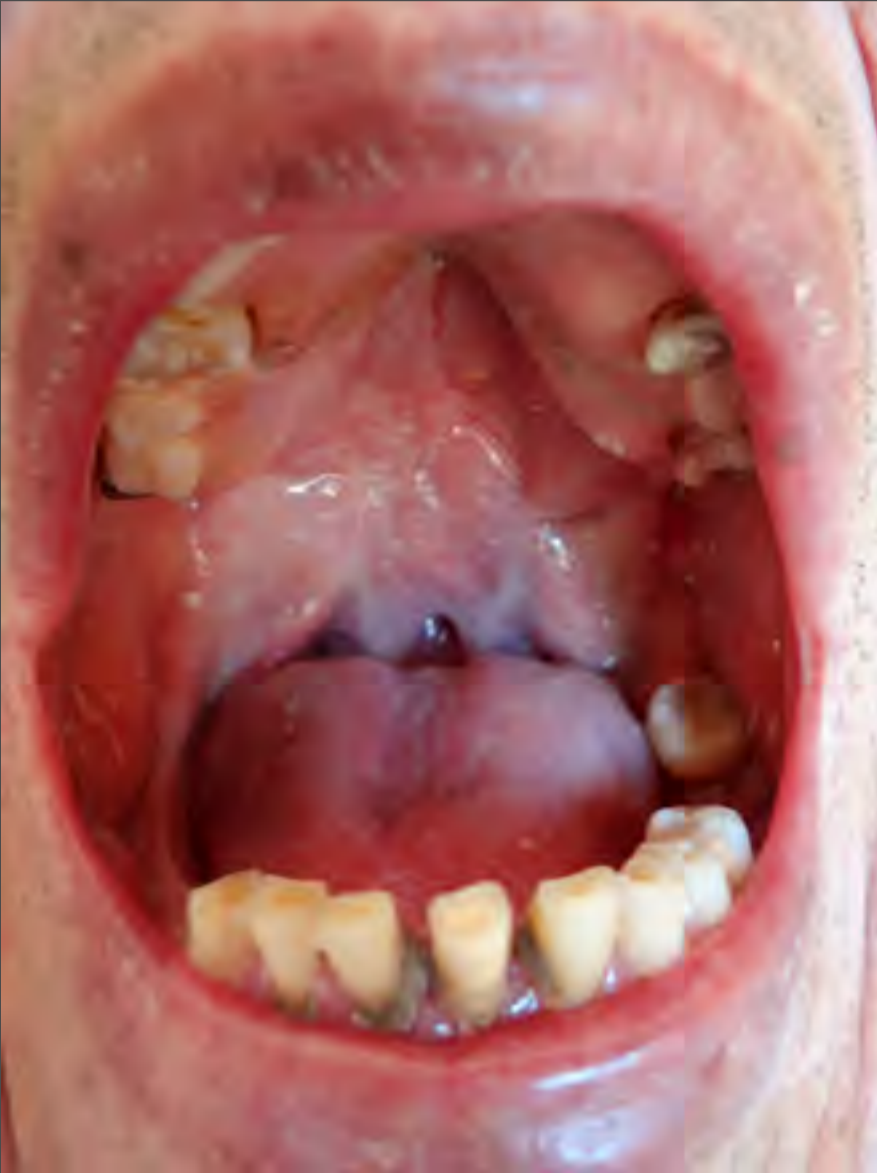**Figure 4.59F.**

Moderate granulomatous infiltration with loss of the uvula



**Figures 4.59G, H e I.**

The anterior pillars, soft palate, and uvula are affected in all mucosal leishmaniasis patients, although with differing degrees of involvement.



**Figures 4.59I.**

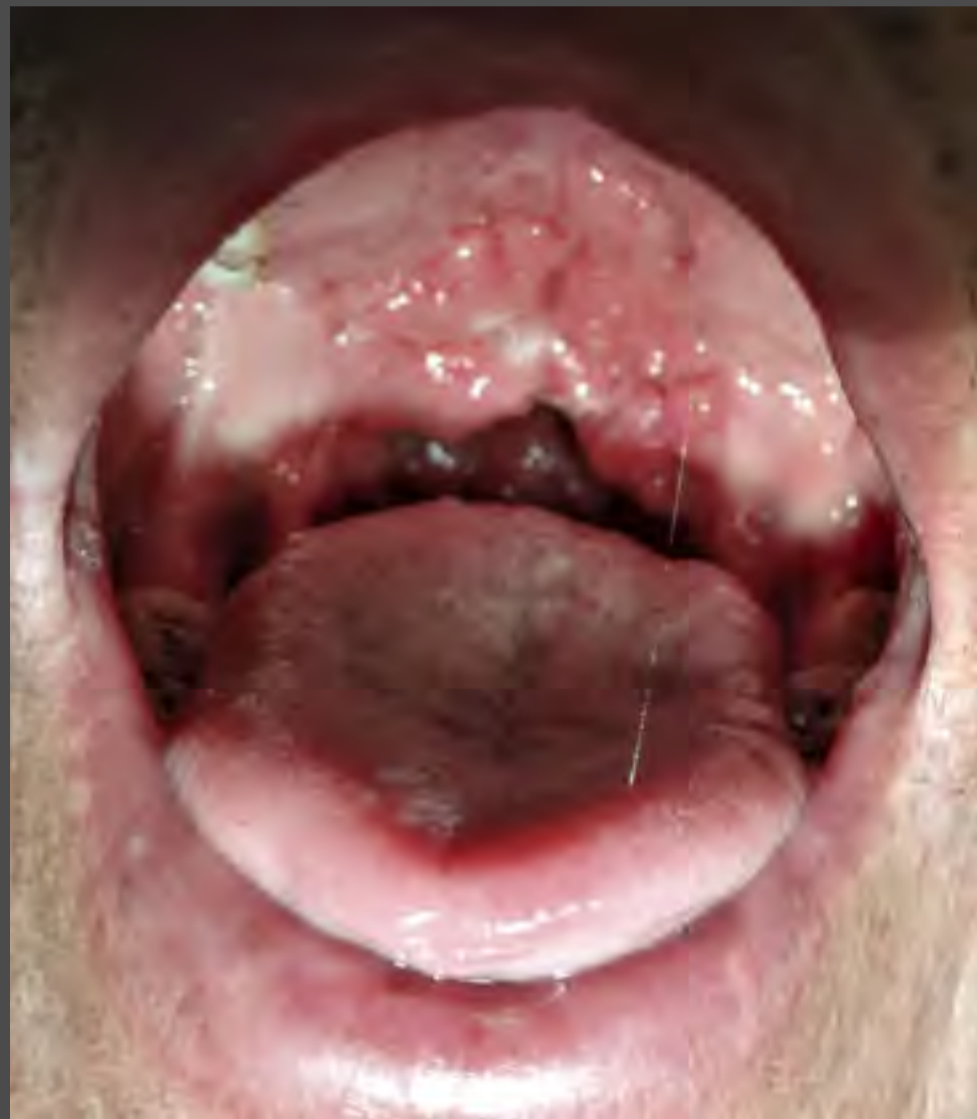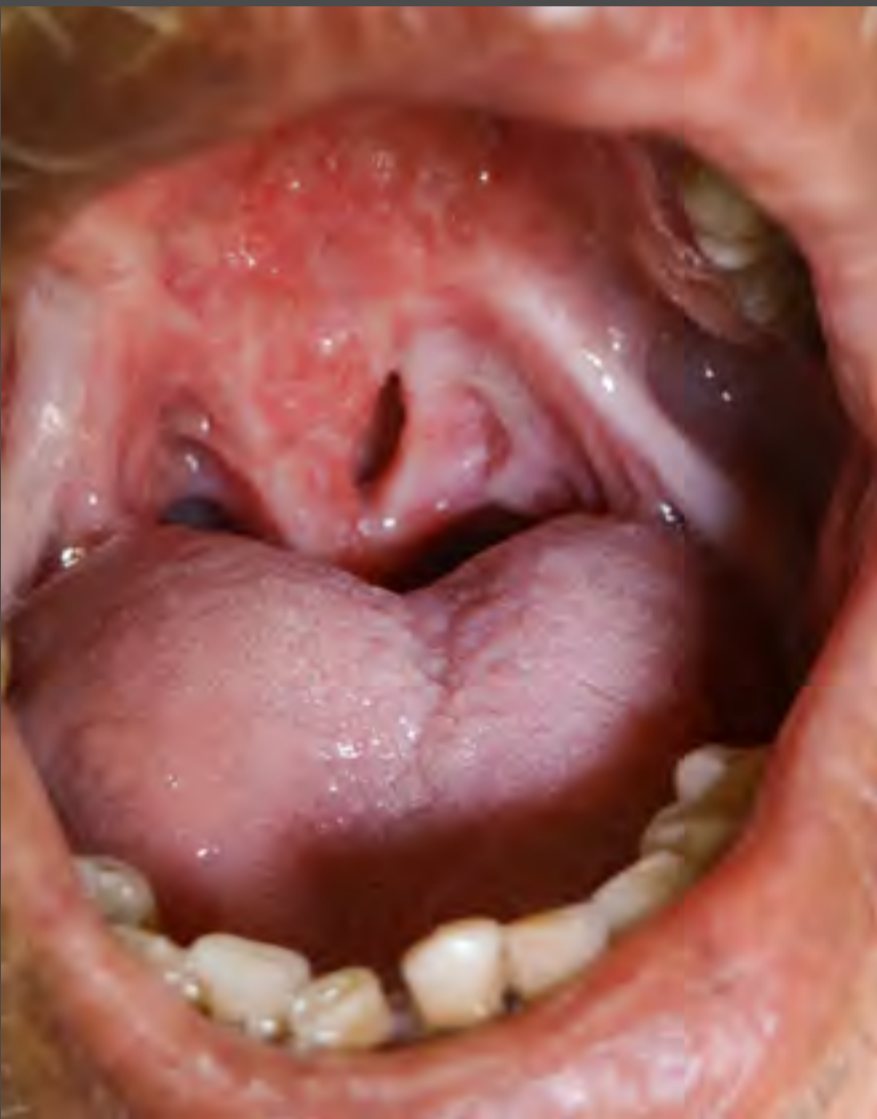Late mucosal leishmaniasis. Granulomatous lesions of the soft palate that involve the uvula.





### Figures 4.59J and K.

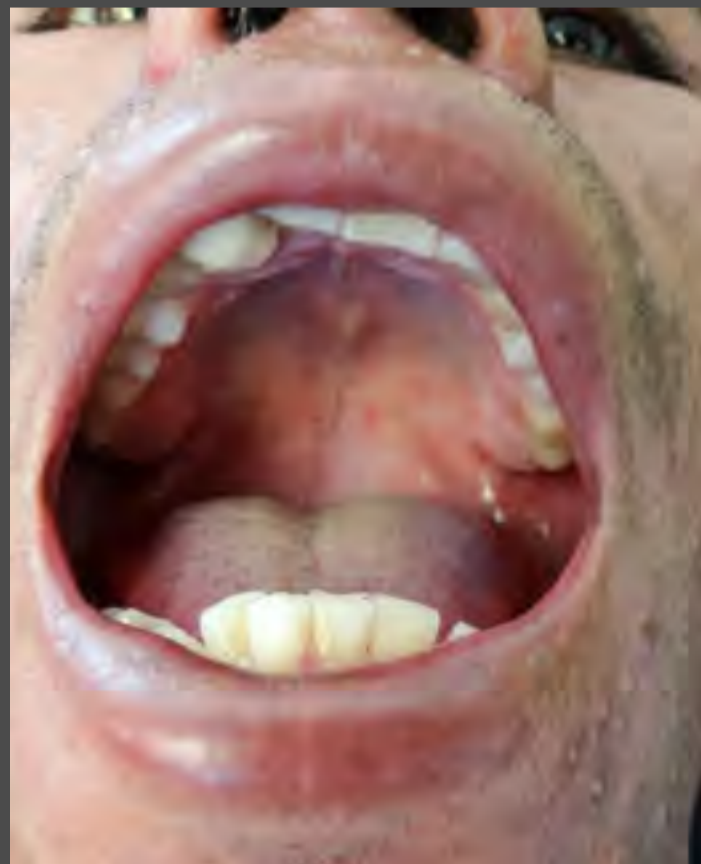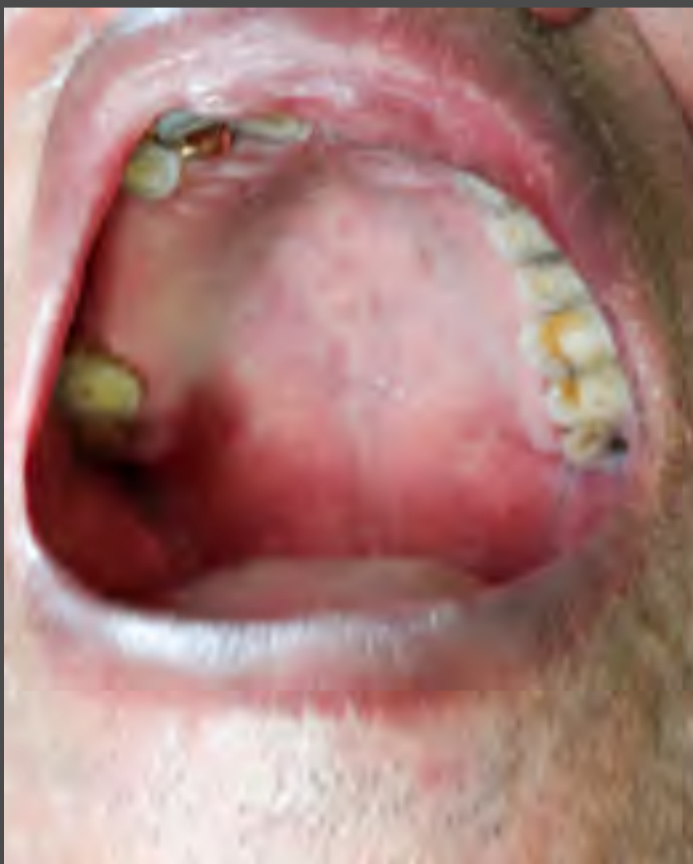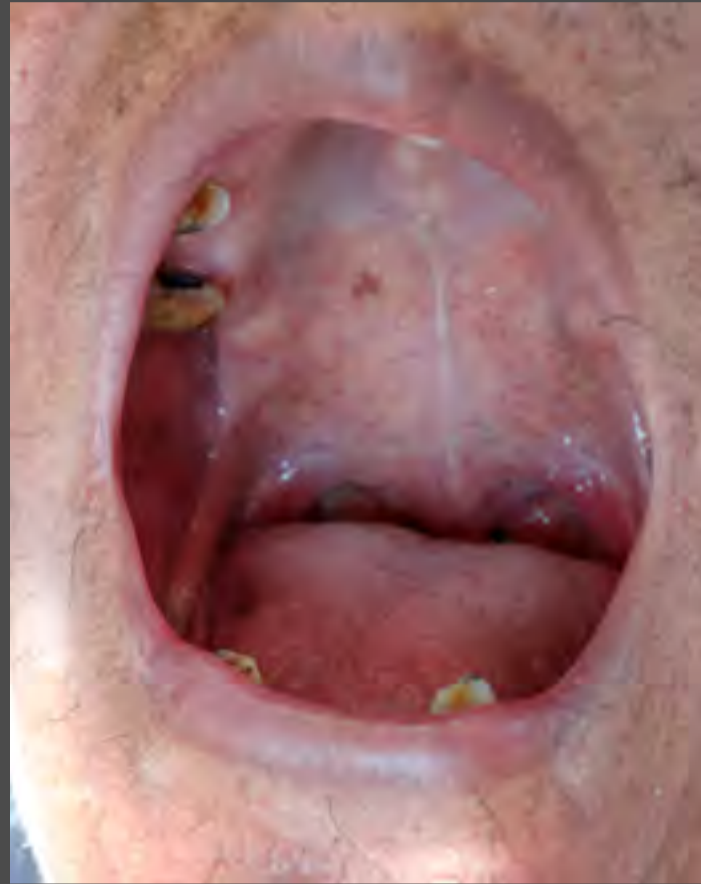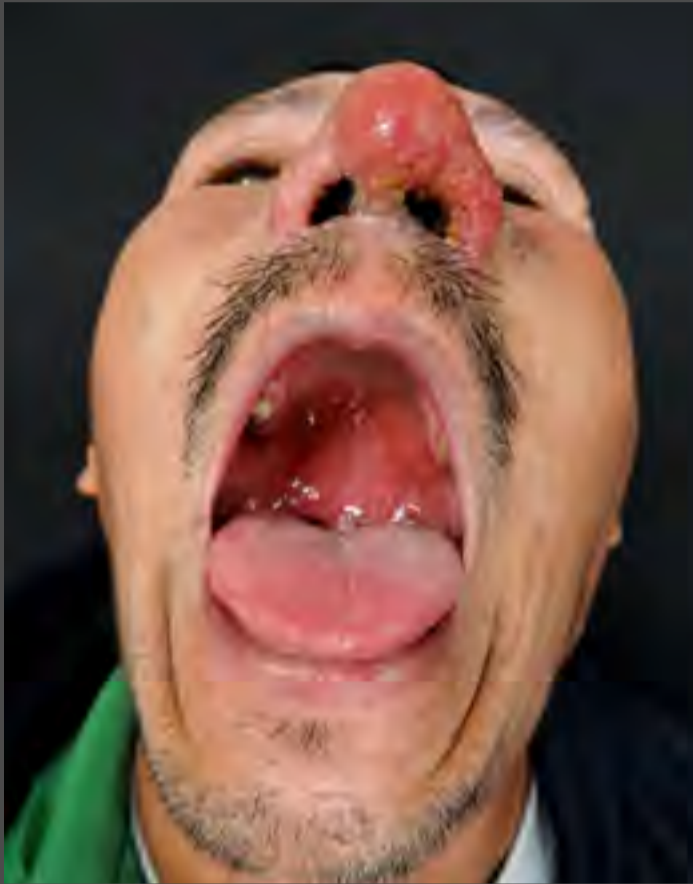The anterior pillars, soft palate, and uvula are affected in all mucosal leishmaniasis patients, although with differing degrees of involvement.





**Figures 4.59L, M, N and O.**

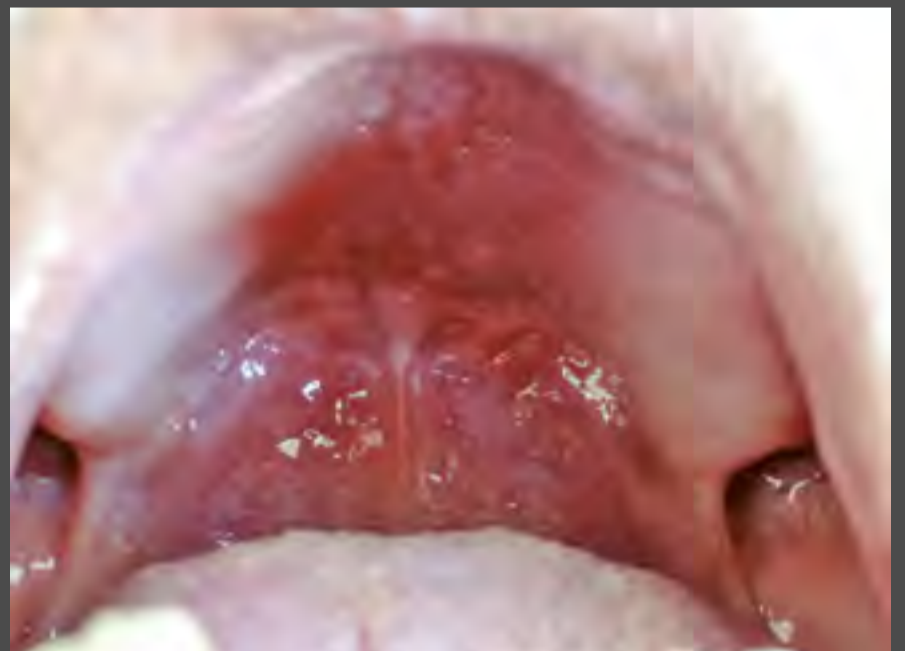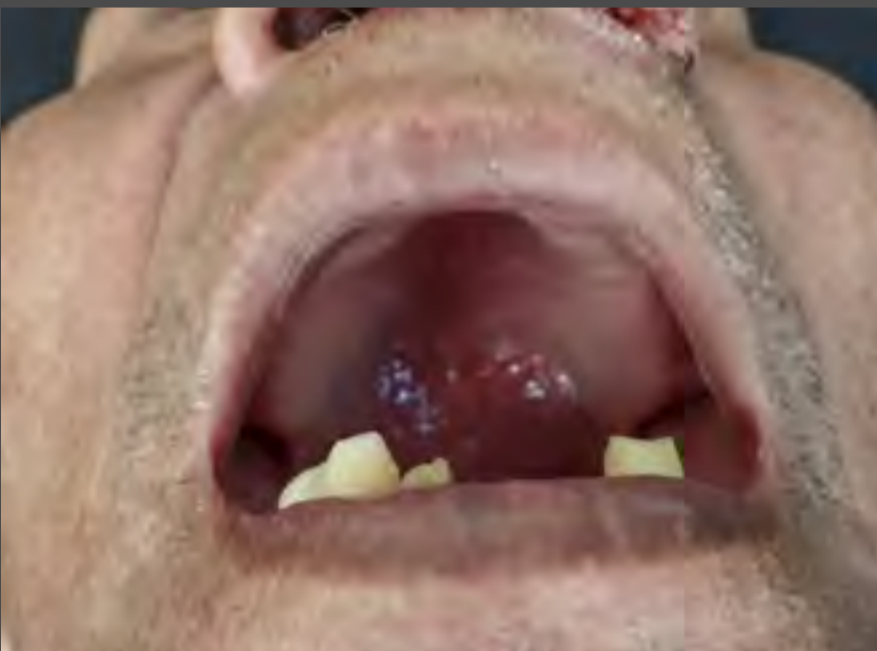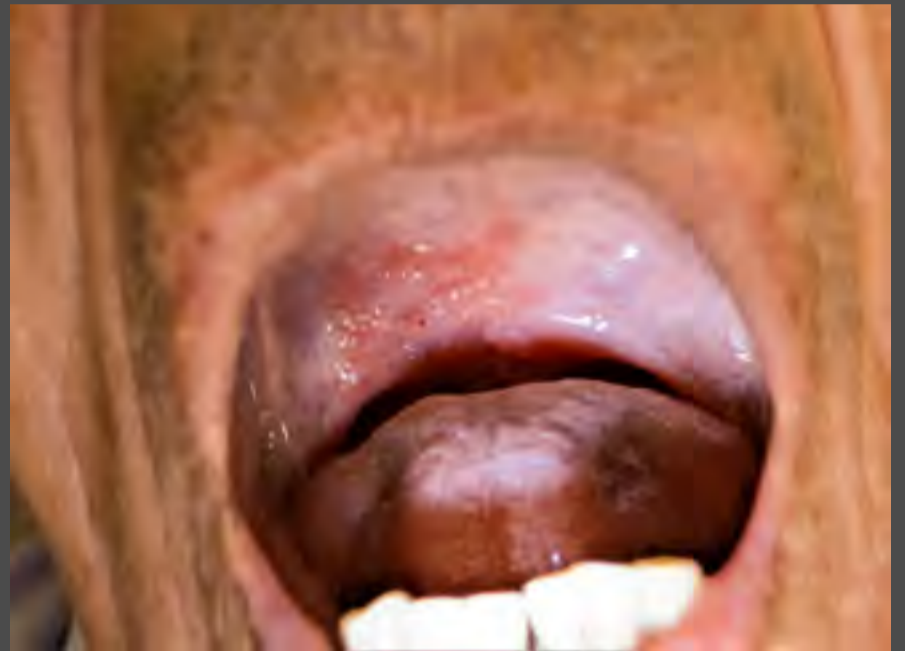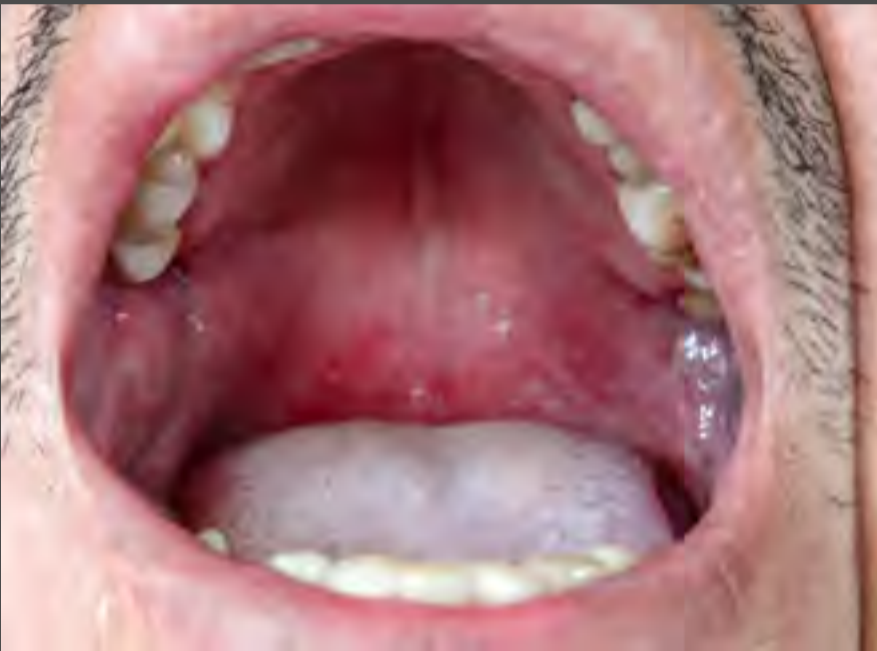Involvement of the oral mucosa usually begins in the oropharynx, where it has arrived due to spread from the nasopharynx and nasal mucosa; it then affects the palatine arches, uvula, and soft palate.





**Figures 4.59P, Q, R and S.**

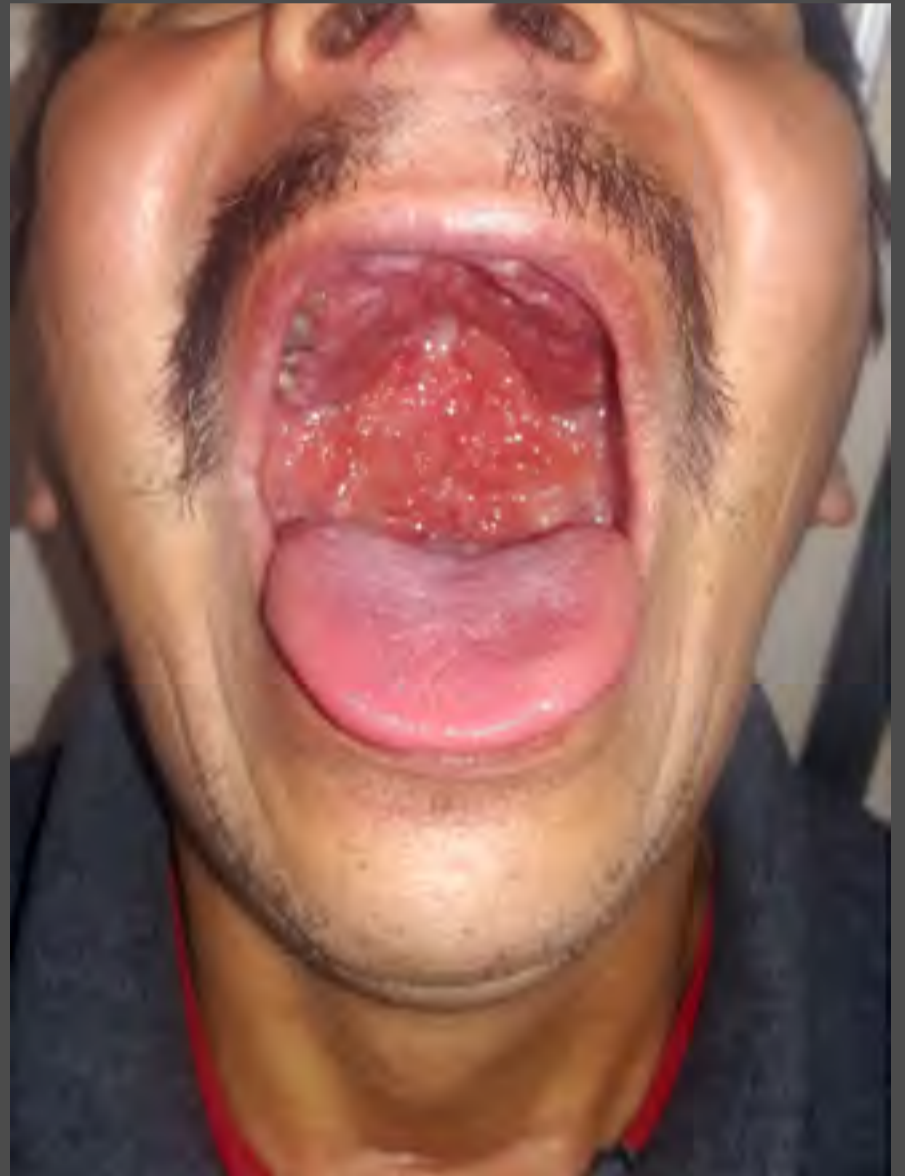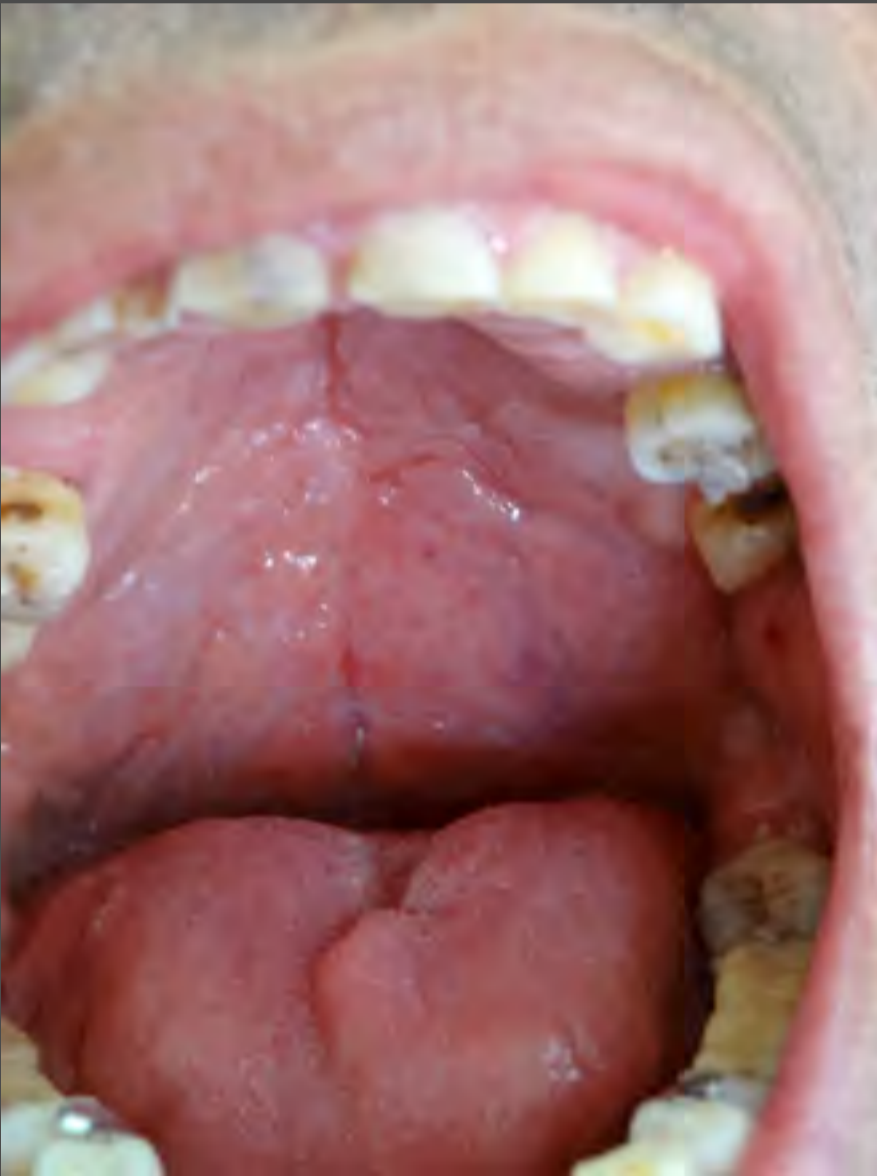Involvement of the oral mucosa usually begins in the oropharynx, where it has arrived due to spread from the nasopharynx and nasal mucosa; it then affects the palatine arches, uvula, and soft palate.





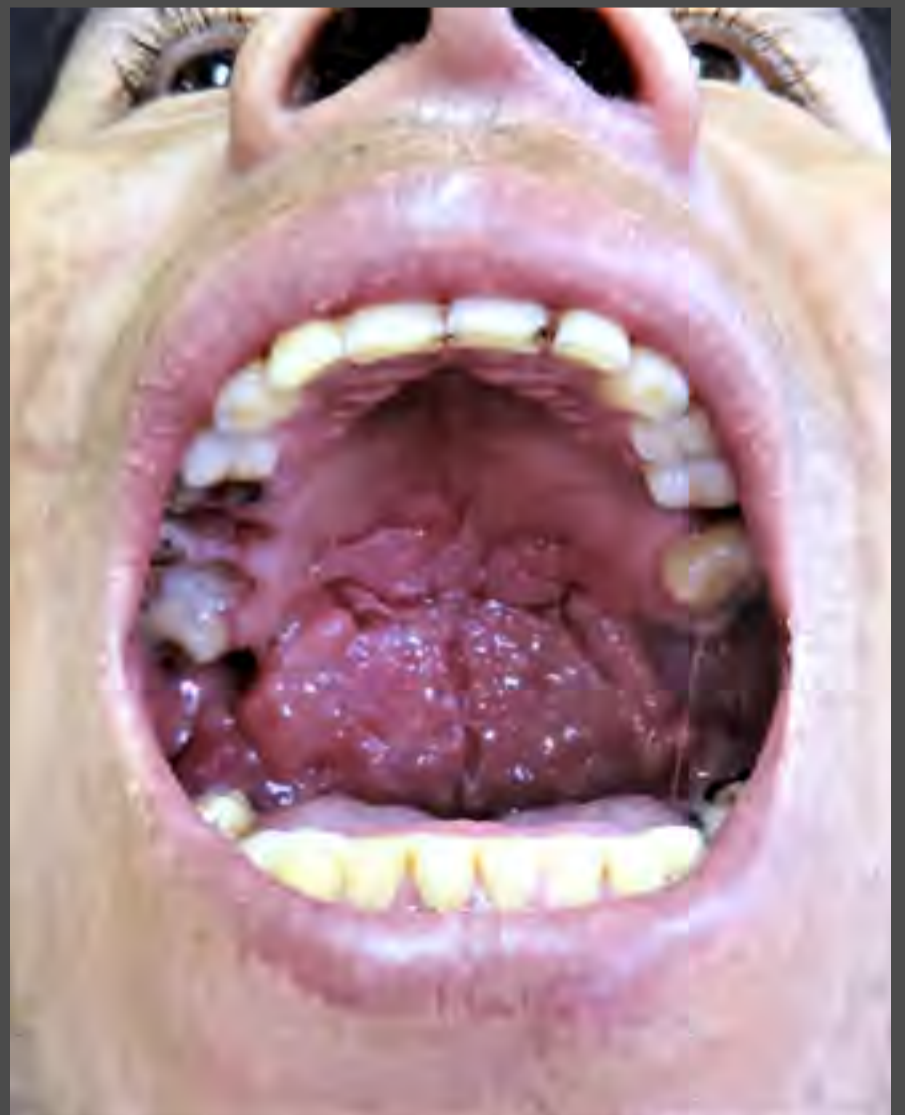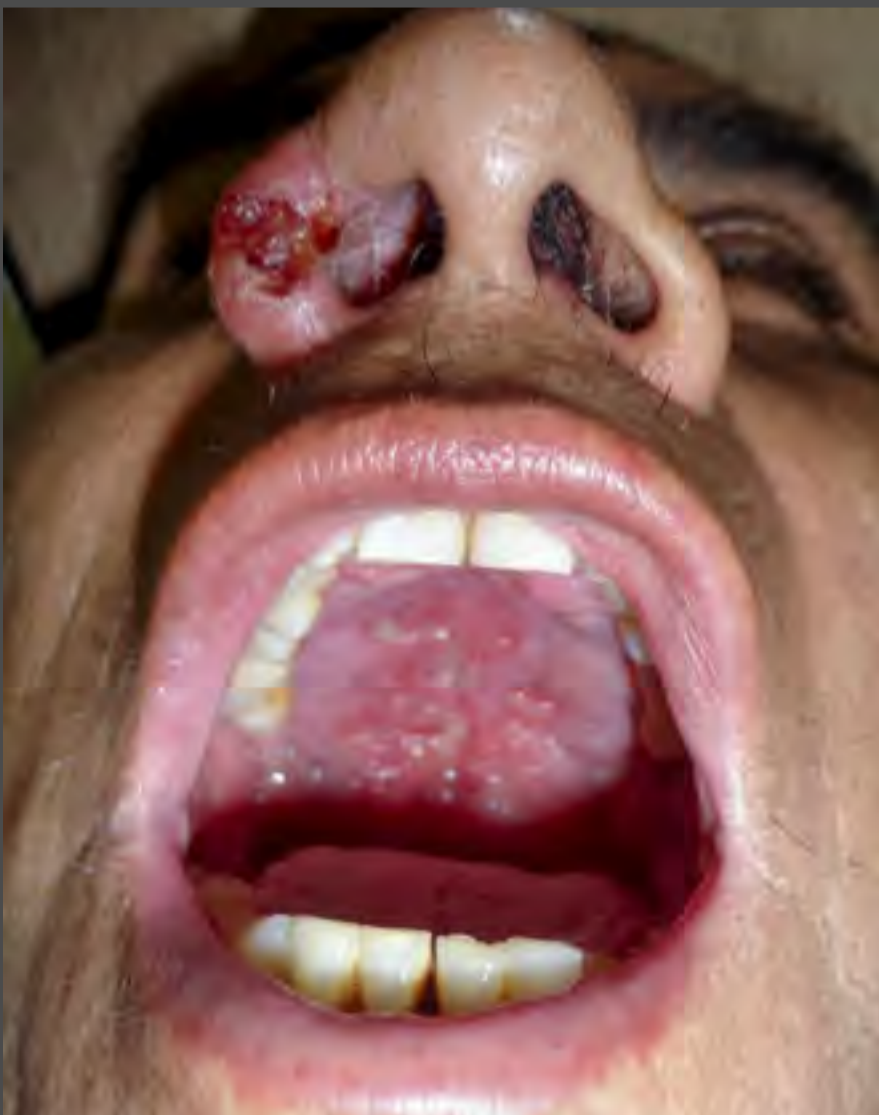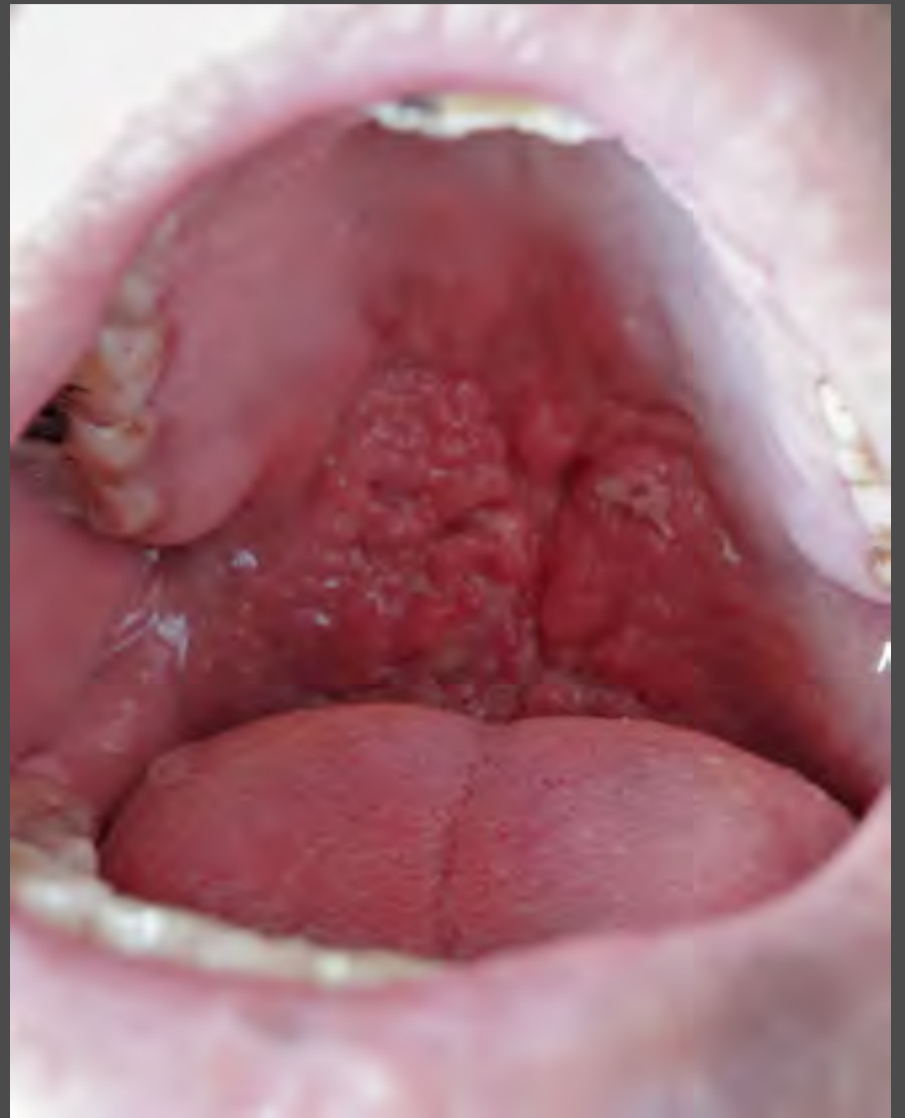**Figures 4.59T and U.**

Involvement of the oral mucosa usually begins in the oropharynx, where it has arrived due to spread from the nasopharynx and nasal mucosa; it then affects the palatine arches, uvula, and soft palate.



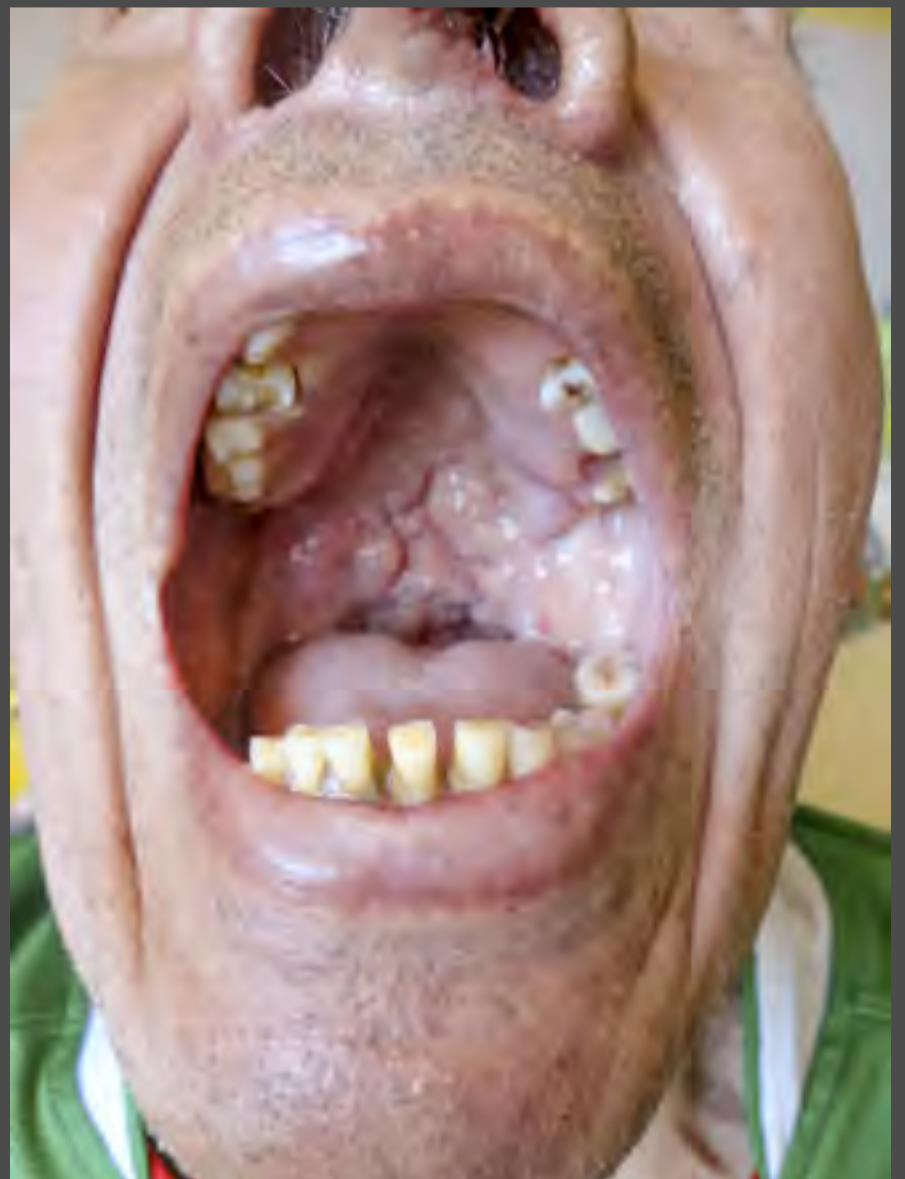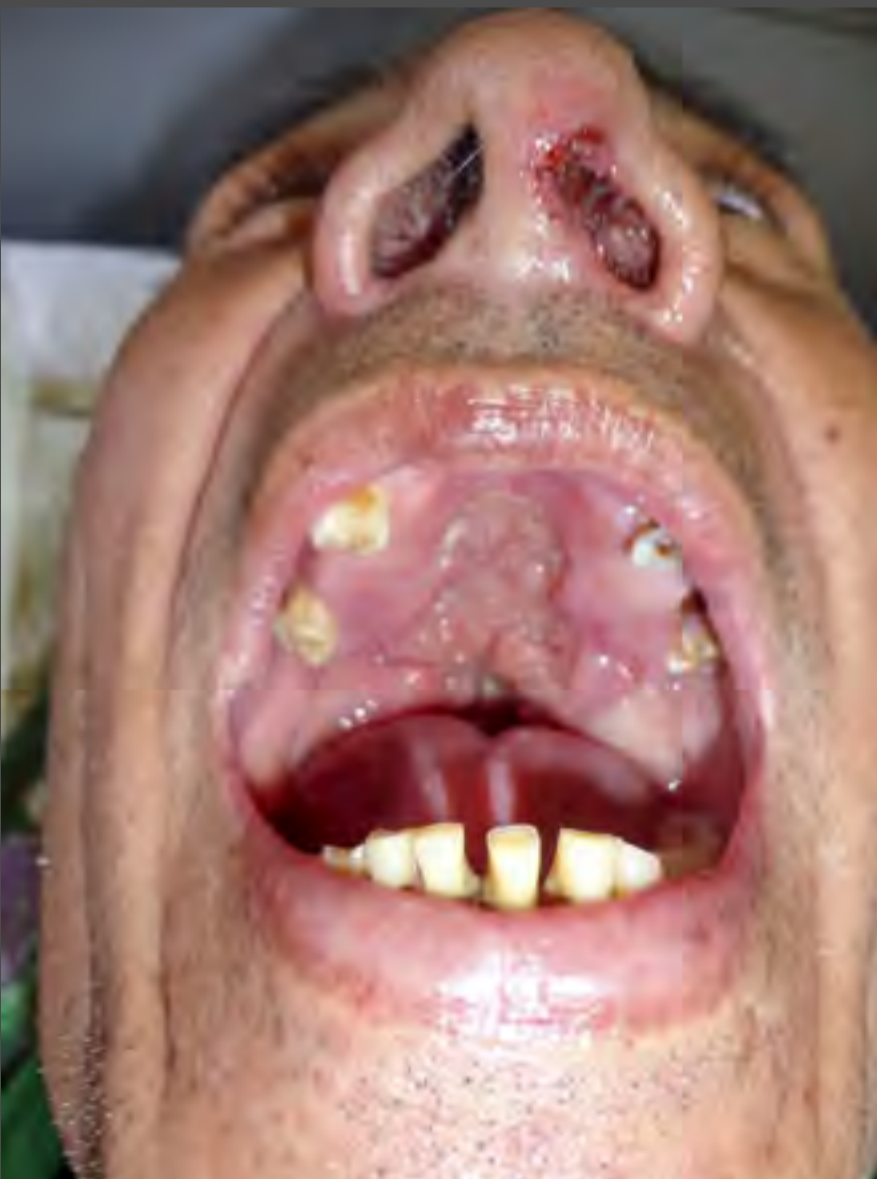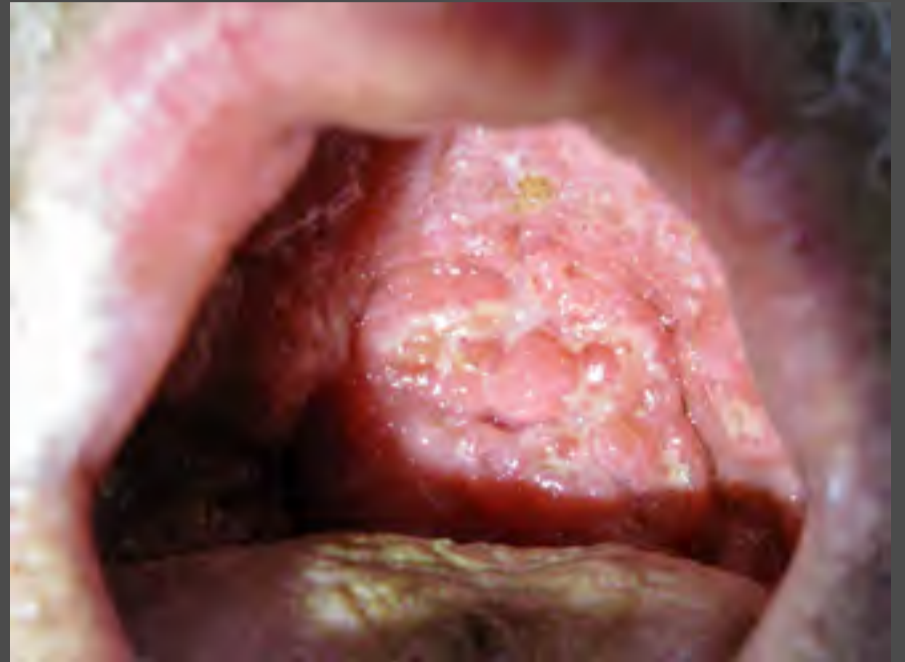**Figures 4.60A, B and C.**

Once the soft palate has been taken, the lesions expand and involve the hard palate, forming erythematous, granulomatous, exuberant nodulations, with a vegetative appearance, product of the infiltrative inflammatory process. The palate's fibrous raphes limit expansion and deep furrows form that are not pathognomonic nor exclusive of mucosal leishmaniasis but are quite characteristic.



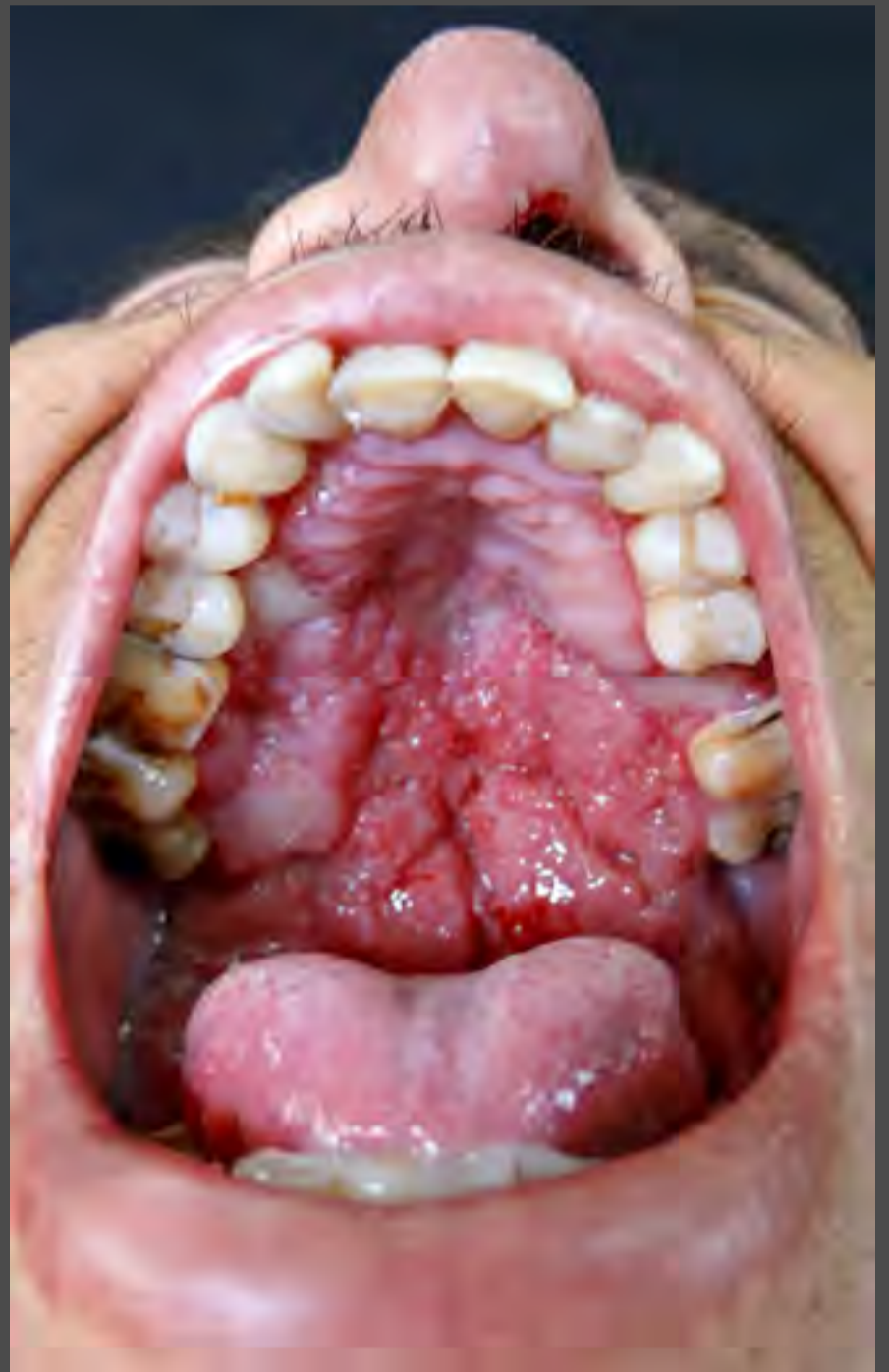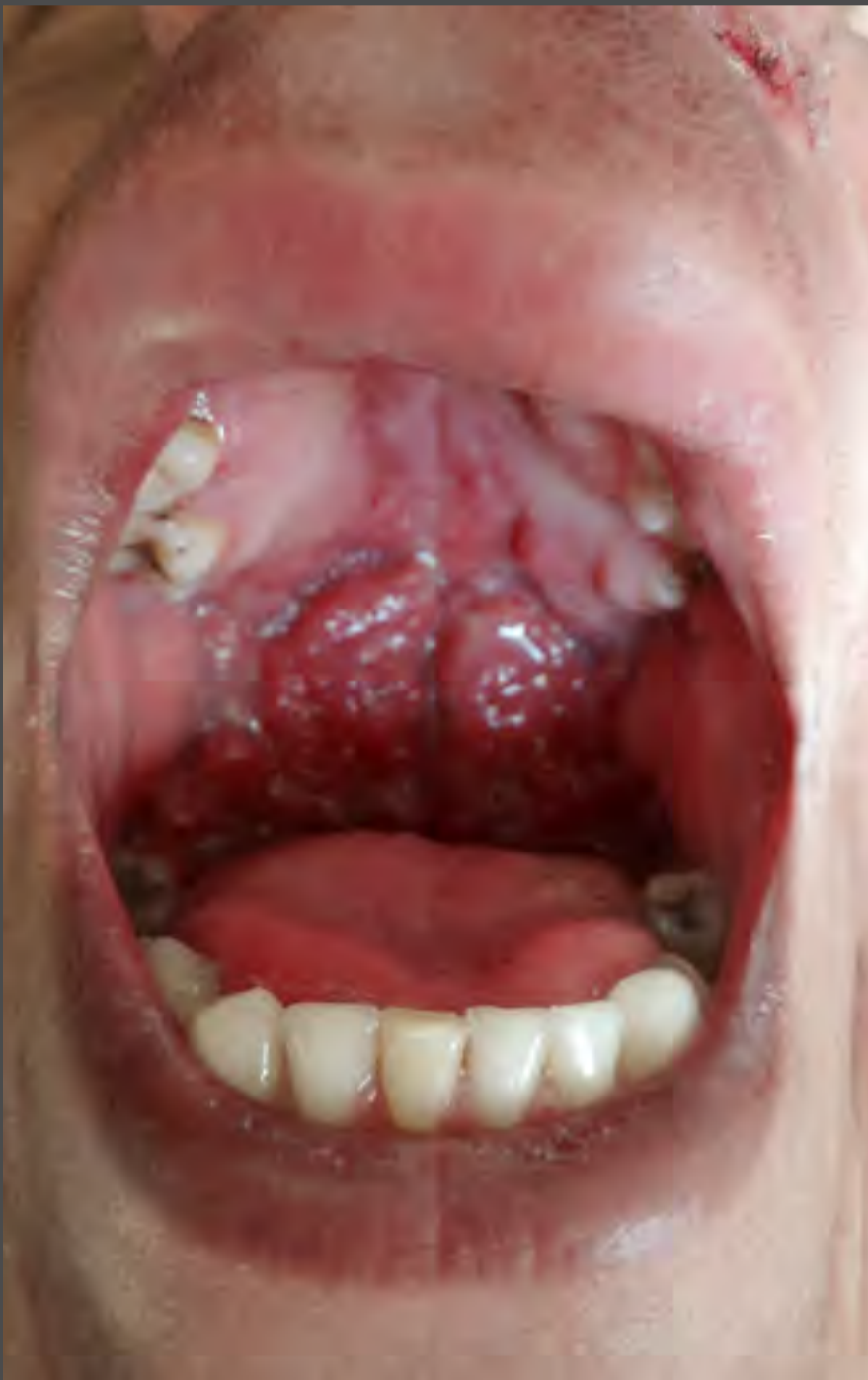**Figures 4.60D, E and F.**

Once the soft palate has been taken, the lesions expand and involve the hard palate, forming erythematous, granulomatous, exuberant nodulations, with a vegetative appearance, product of the infiltrative inflammatory process. The palate's fibrous raphes limit expansion and deep furrows form that are not pathognomonic nor exclusive of mucosal leishmaniasis but are quite characteristic.



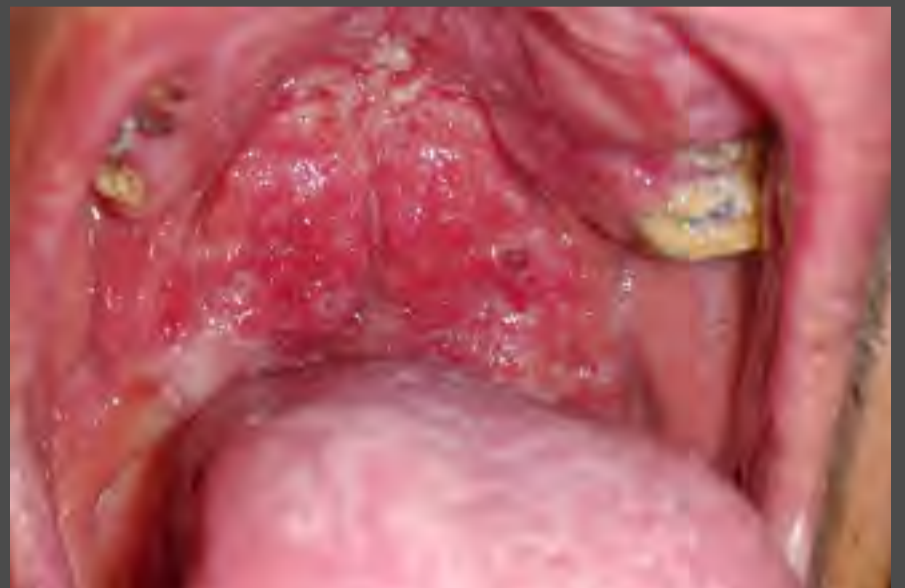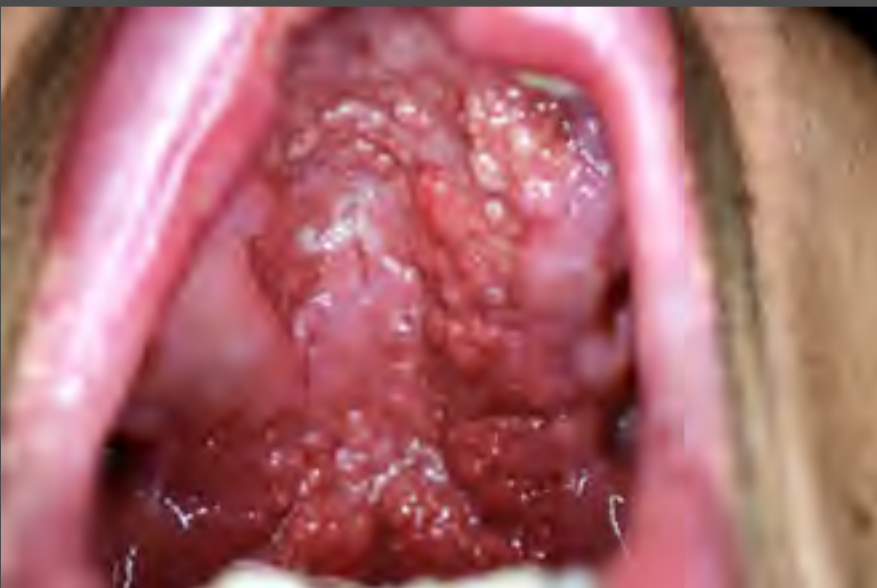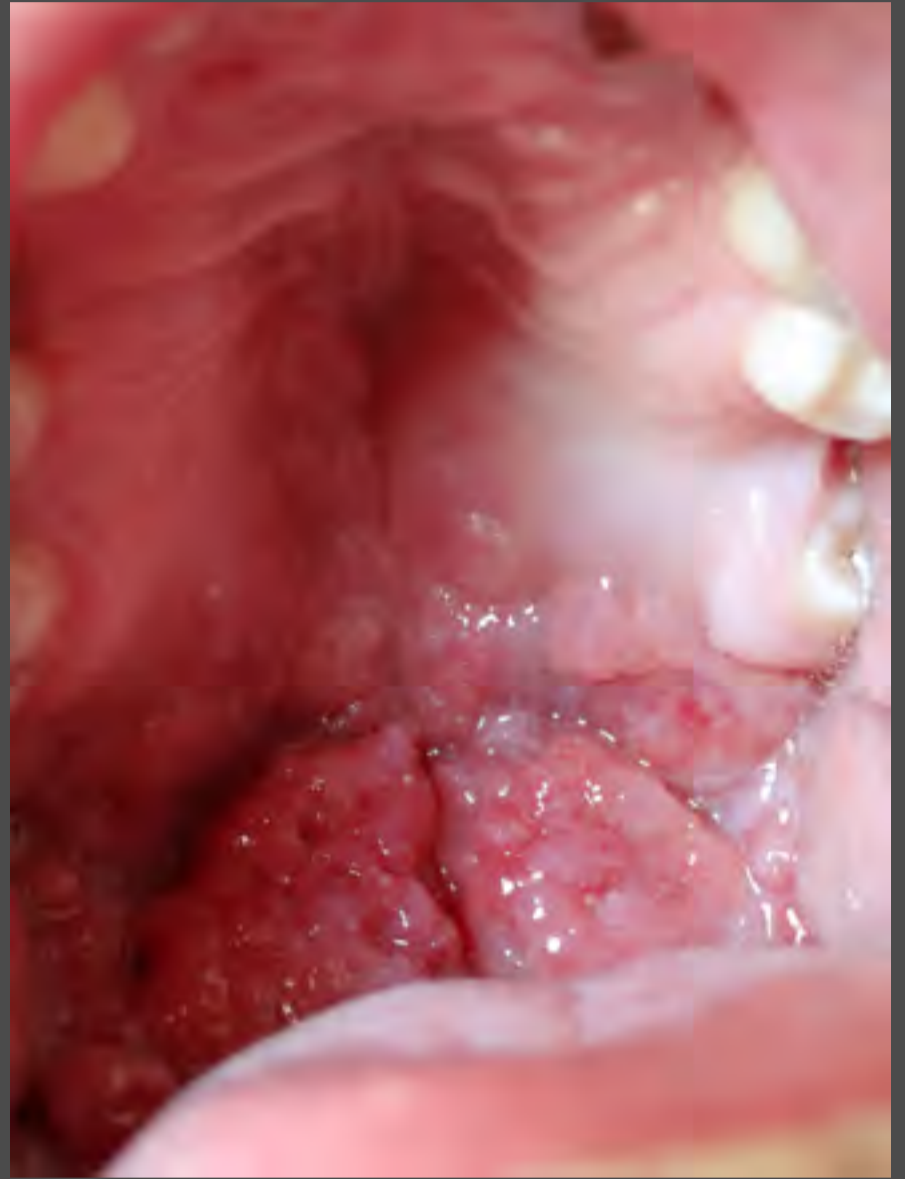**Figures 4.60G and H.**

Once the soft palate has been taken, the lesions expand and involve the hard palate, forming erythematous, granulomatous, exuberant nodulations, with a vegetative appearance, product of the infiltrative inflammatory process. The palate's fibrous raphes limit expansion and deep furrows form that are not pathognomonic nor exclusive of mucosal leishmaniasis but are quite characteristic.

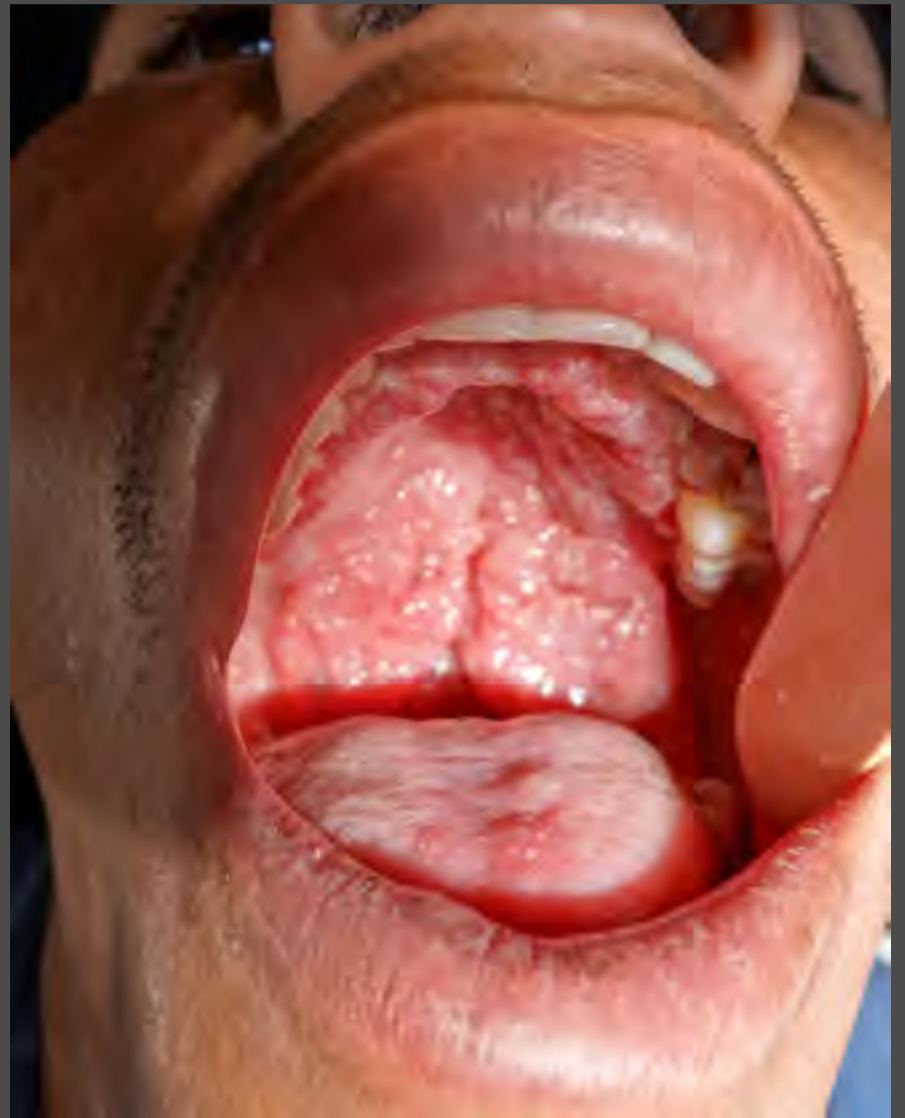
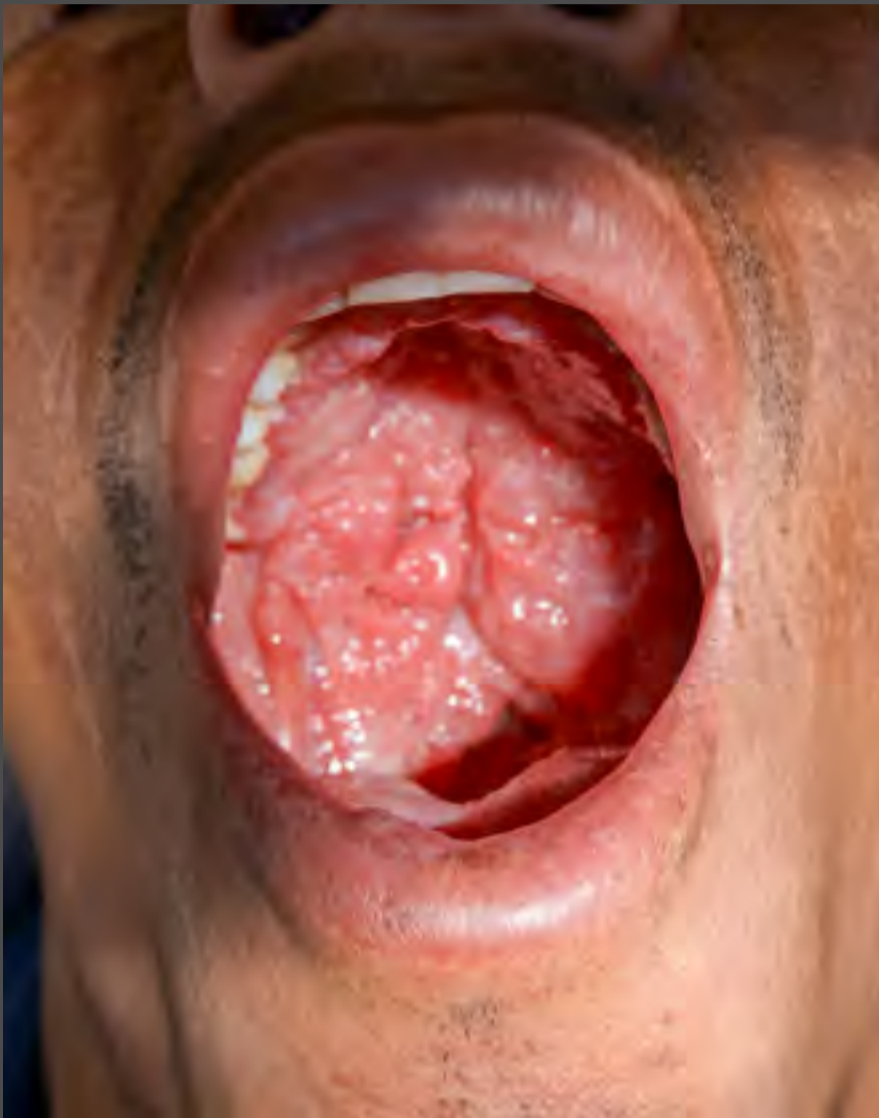
**Figures 4.60I, J and K.**

Once the soft palate has been taken, the lesions expand and involve the hard palate, forming erythematous, granulomatous, exuberant nodulations, with a vegetative appearance, product of the infiltrative inflammatory process. The palate's fibrous raphes limit expansion and deep furrows form that are not pathognomonic nor exclusive of mucosal leishmaniasis but are quite characteristic.

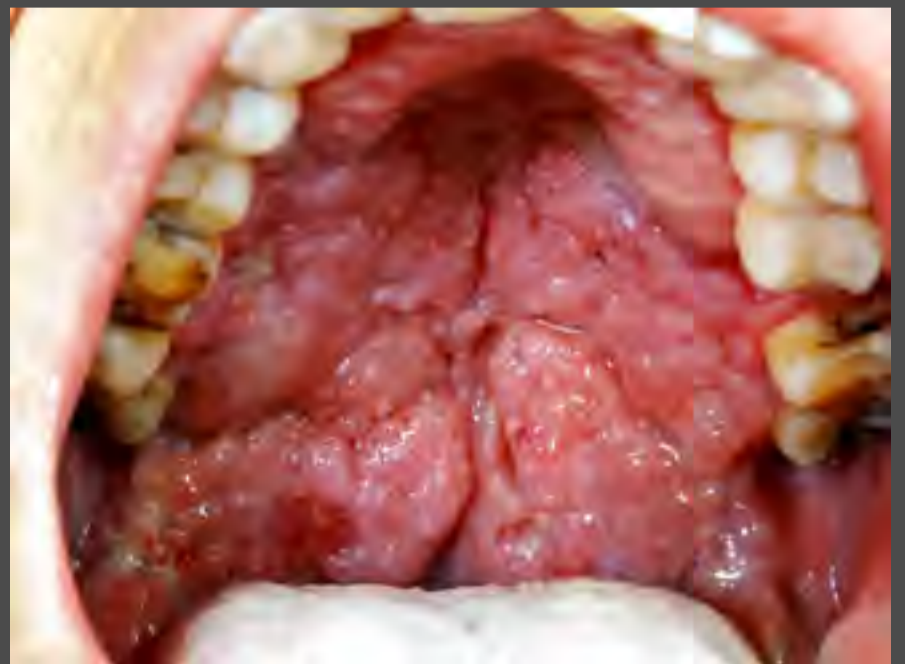


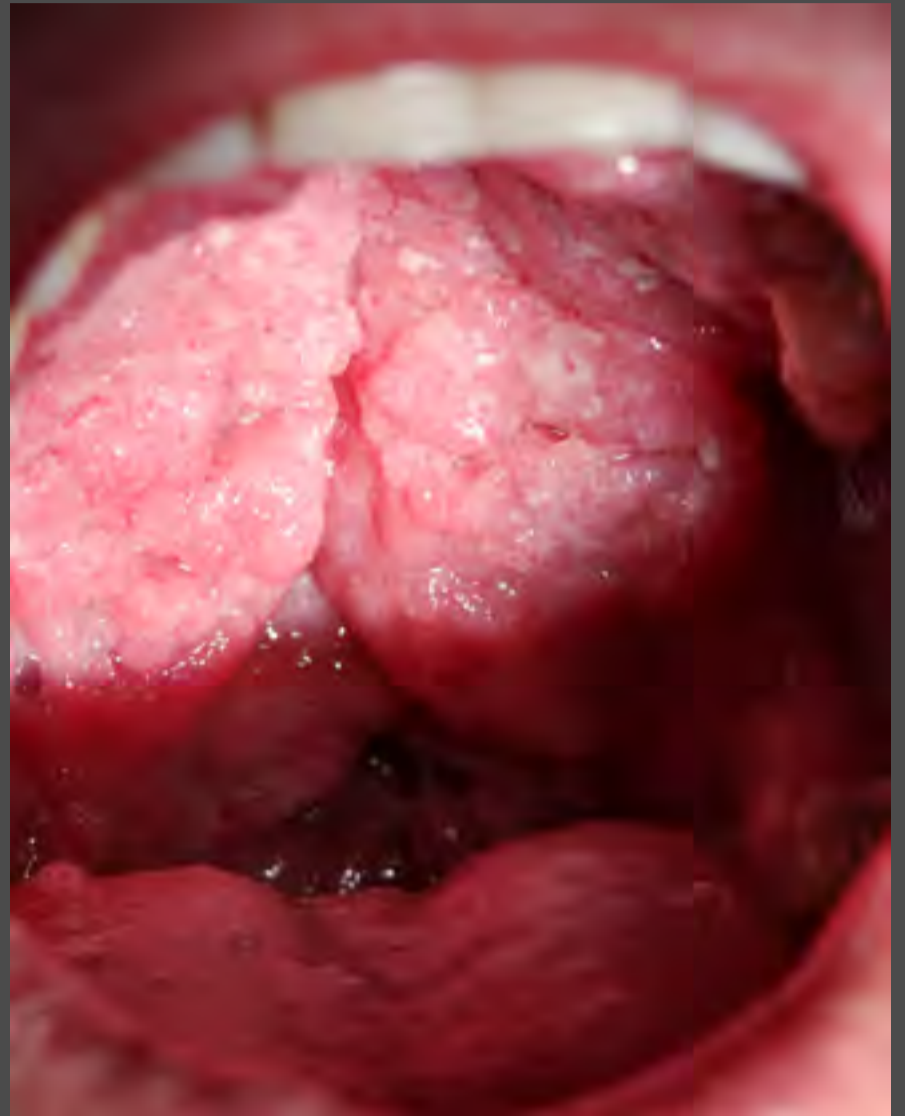
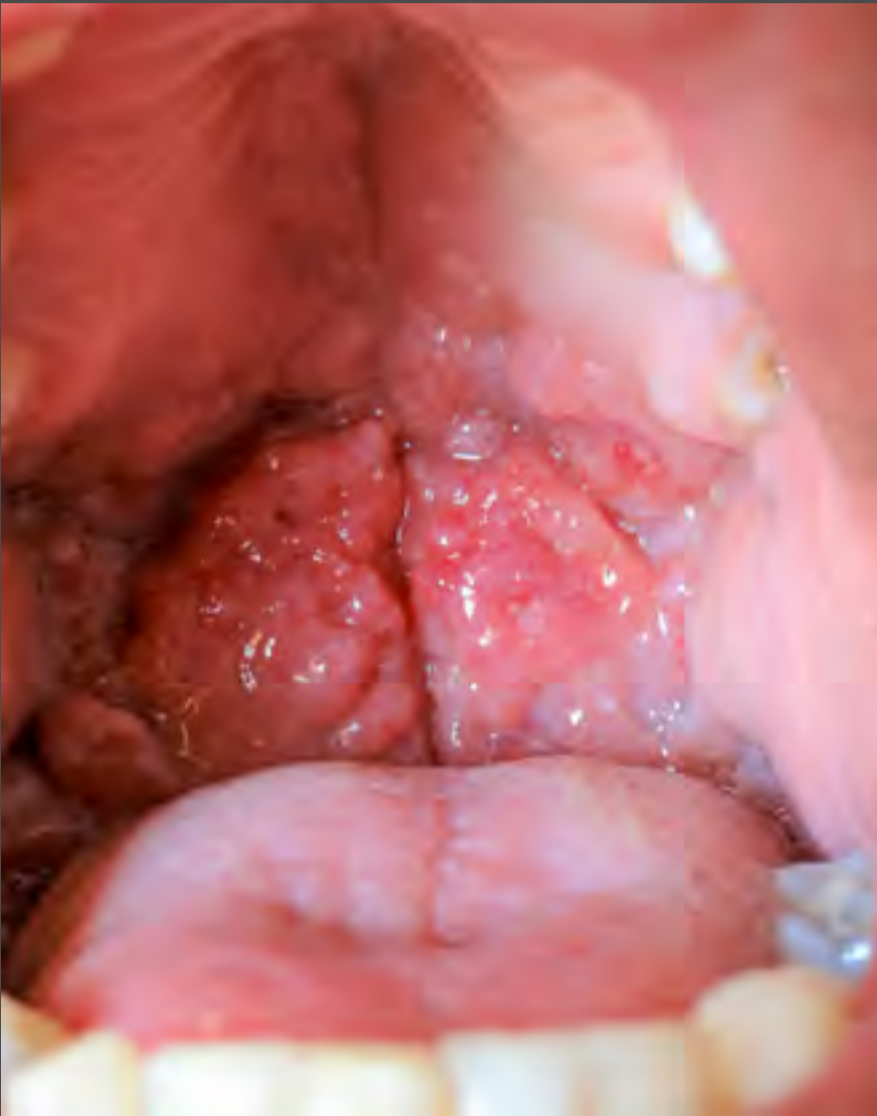

**Figures 4.60L, M and N.**

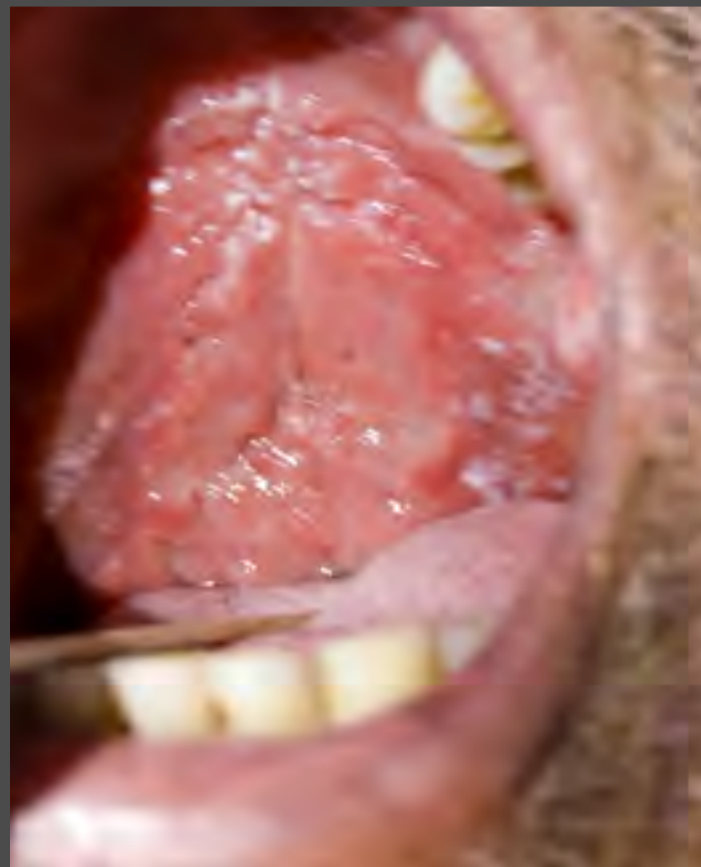Once the soft palate has been taken, the lesions expand and involve the hard palate, forming erythematous, granulomatous, exuberant nodulations, with a vegetative appearance, product of the infiltrative inflammatory process. The palate's fibrous raphes limit expansion and deep furrows form that are not pathognomonic nor exclusive of mucosal leishmaniasis but are quite characteristic.

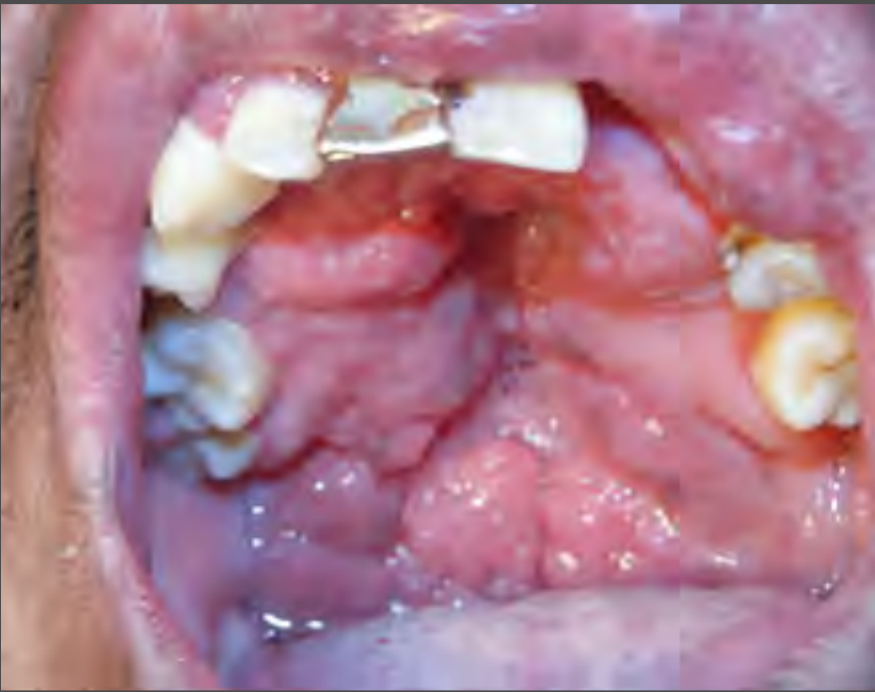



**Figures 4.600, P and Q.**

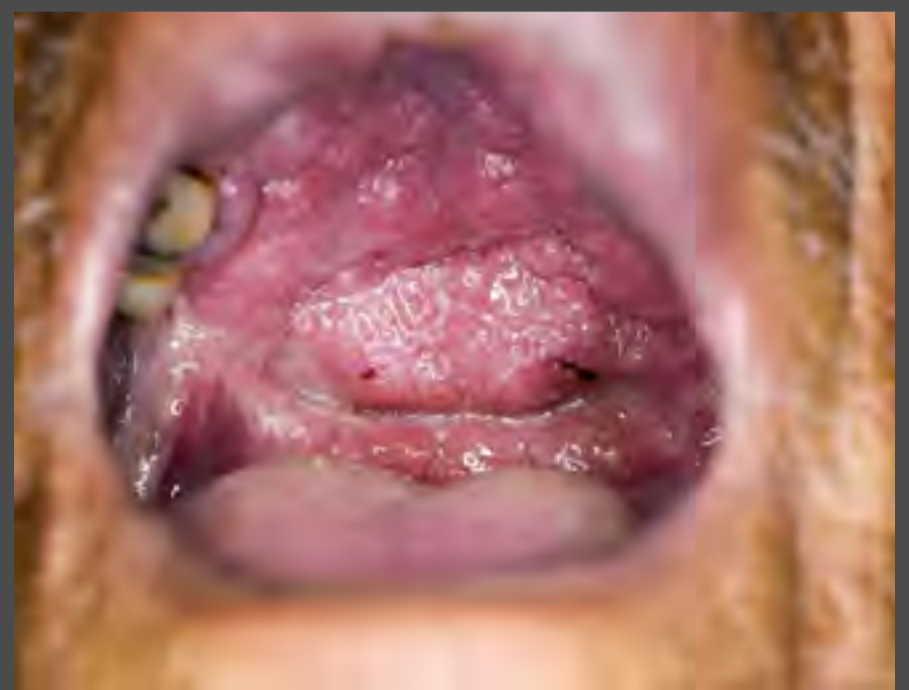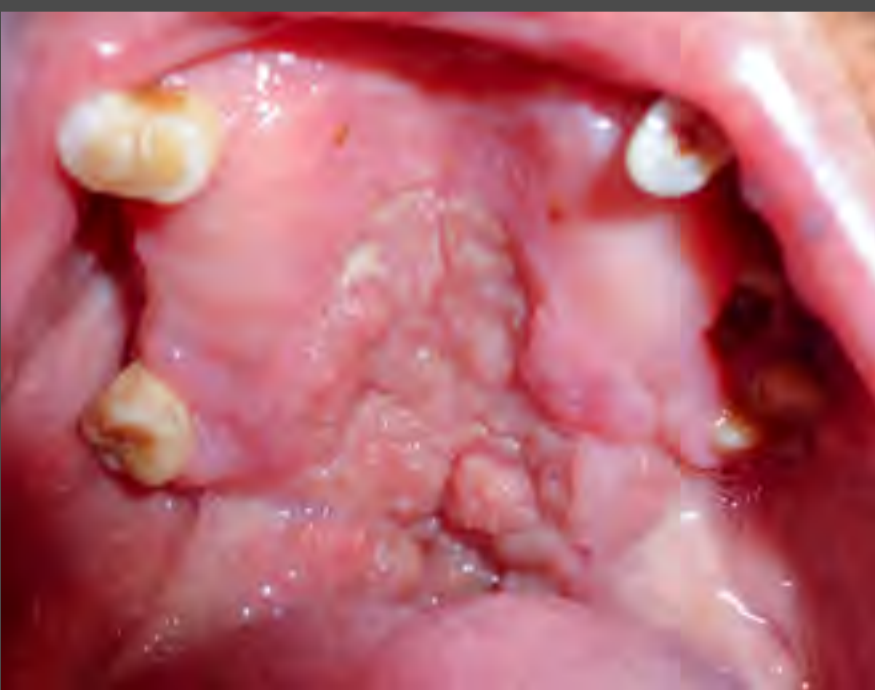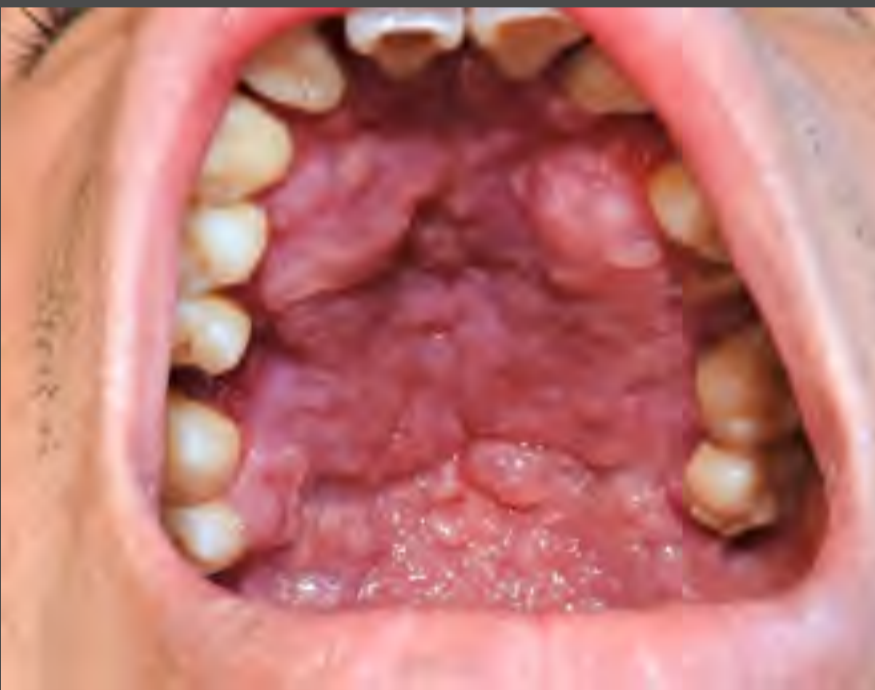Once the soft palate has been taken, the lesions expand and involve the hard palate, forming erythematous, granulomatous, exuberant nodulations, with a vegetative appearance, product of the infiltrative inflammatory process. The palate's fibrous raphes limit expansion and deep furrows form that are not pathognomonic nor exclusive of mucosal leishmaniasis but are quite characteristic.

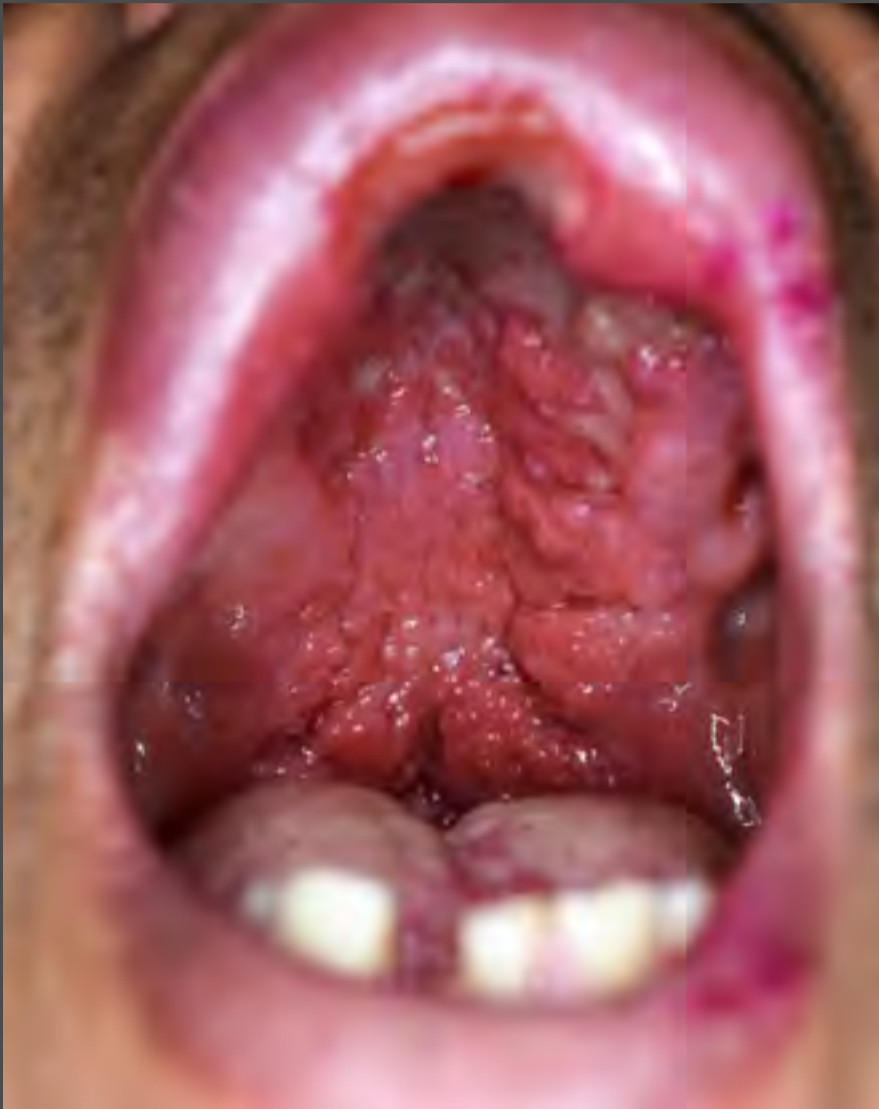



**Figures 4.61A, B, C and D.**

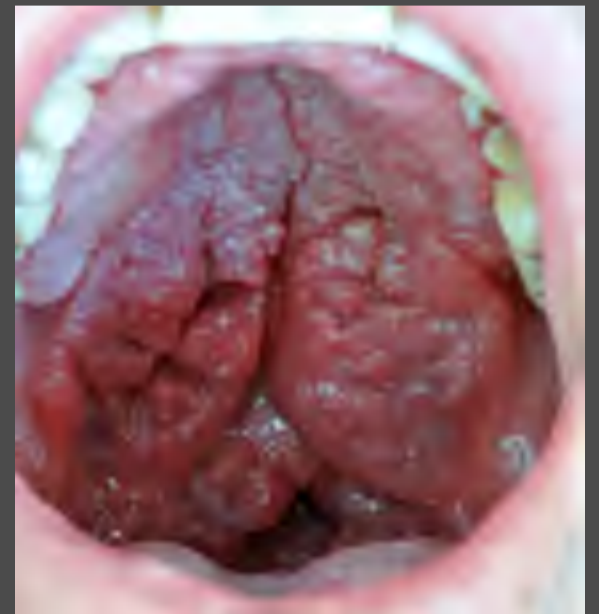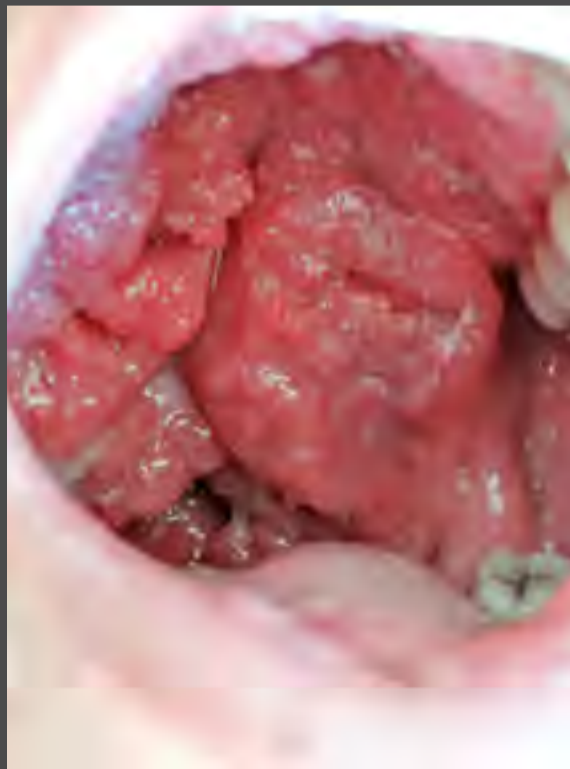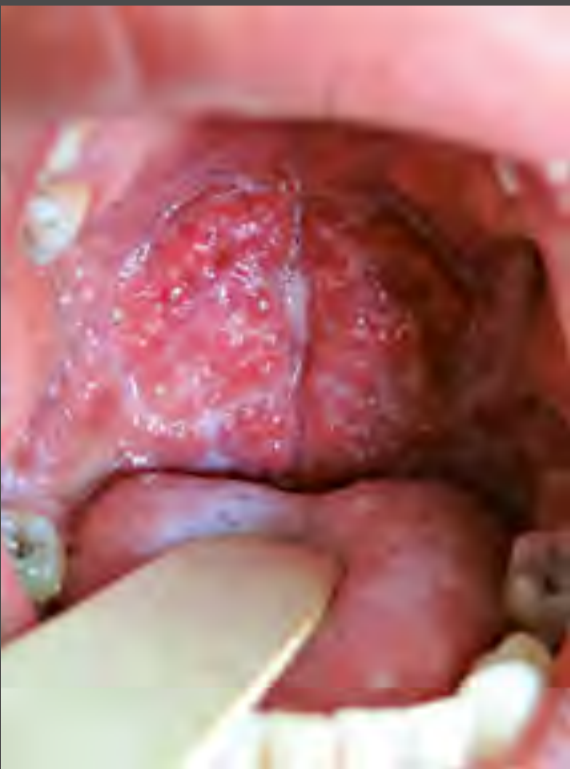The lesions increase in volume and take on a proliferative pseudoneoplastic appearance, although they remain limited to the palate, which is sometimes so significant that it makes swallowing difficult. Ulceration or perforation of the palate is exceptional in mucosal leishmaniasis, so much so that if it occurs it is imperative to rule out other infectious diseases (leprosy, paracoccidioidomycosis, and syphilis), tumors (carcinomas, angiocentric lymphomas [lymphomatoid granulomatosis], and cutaneous lymphomas), and autoimmune diseases (various vasculitises and systemic lupus erythematosus). In mucosal leishmaniasis, involvement of the gums, mucosa of the gums, the tongue, and the internal aspect of the lips is exceptional. When infiltration and edema of the lips occur, it is almost always due to spread due to contiguity from the skin or nasal mucosa in the case of the upper lip, or by direct inoculation in the case of the lower lip.

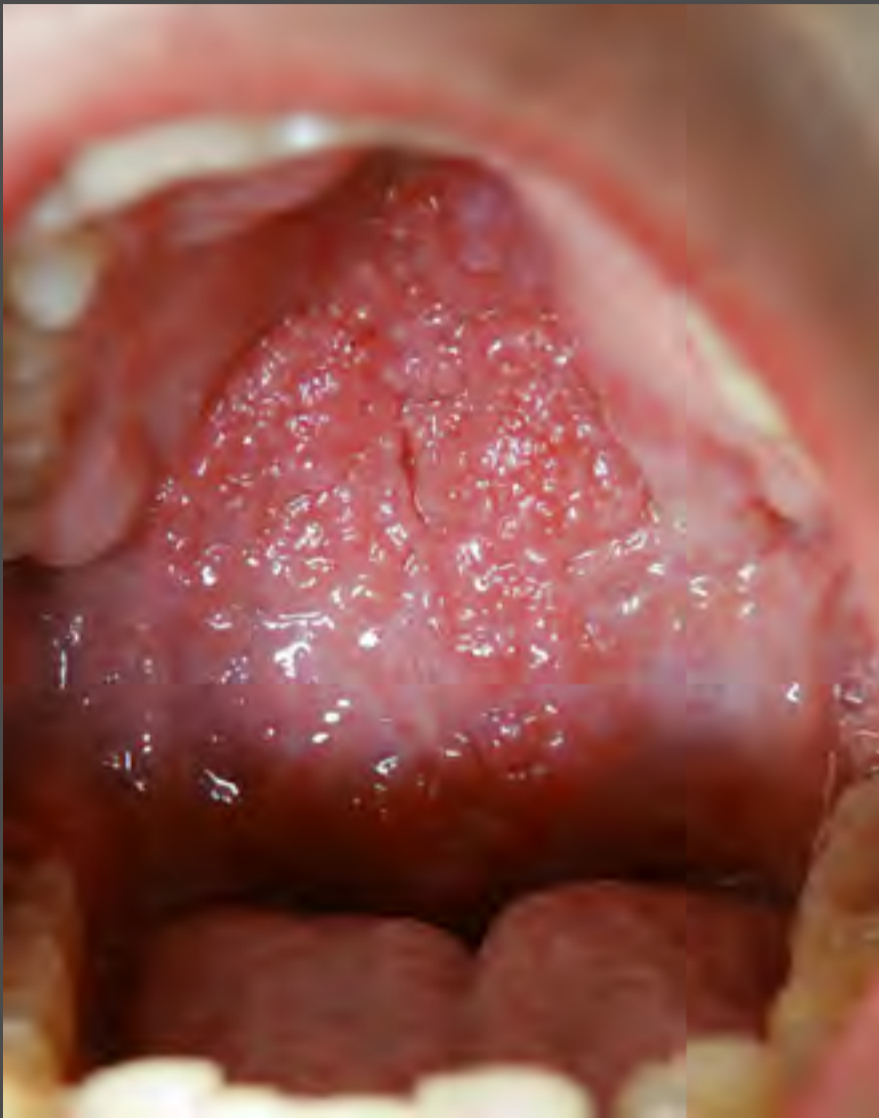



**Figures 4.61E, F, G and H.**

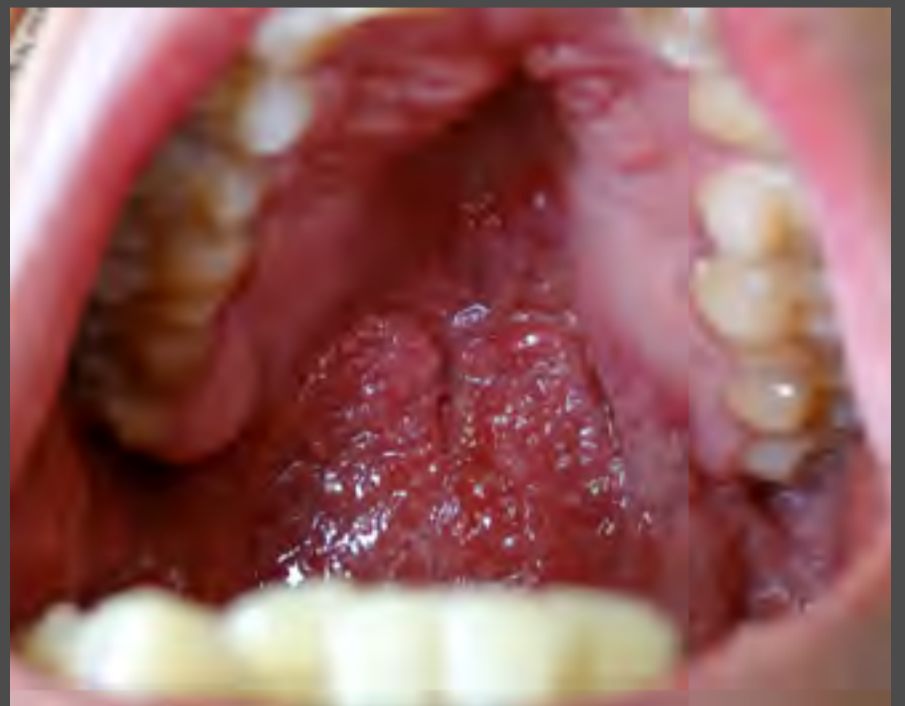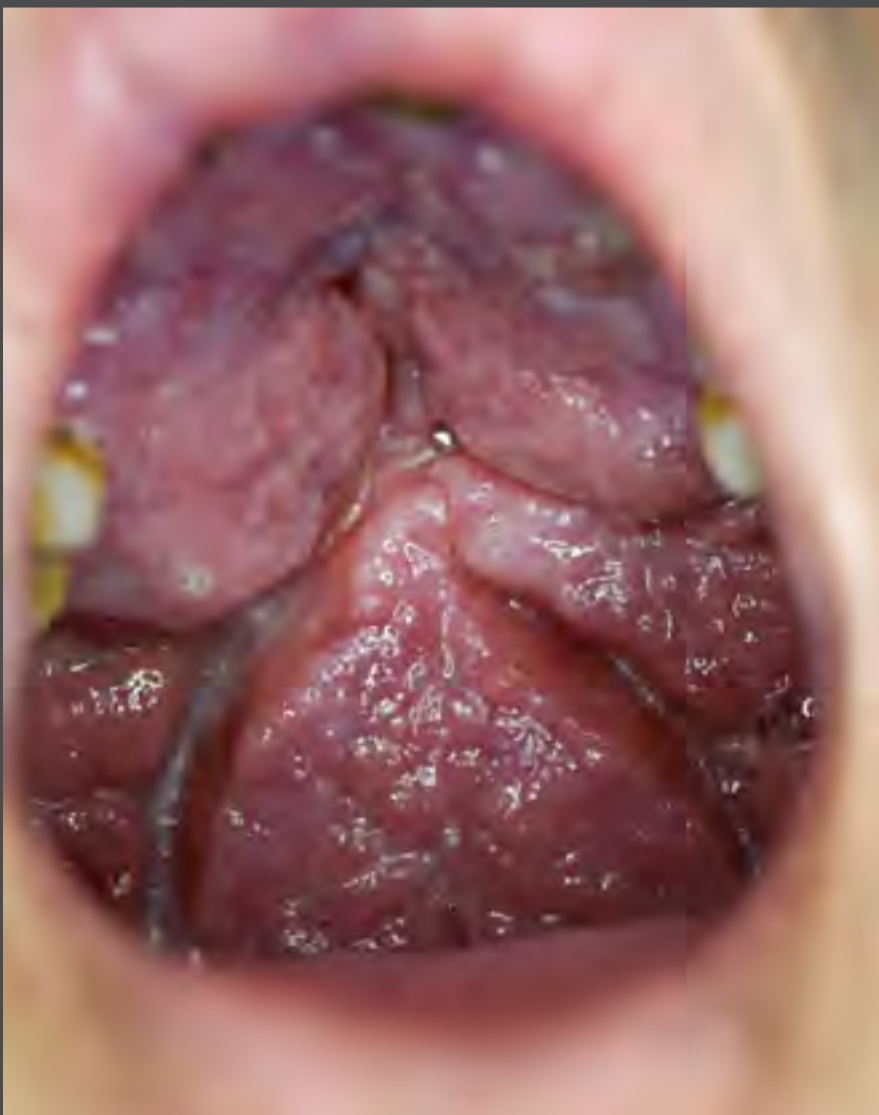The lesions increase in volume and take on a proliferative pseudoneoplastic appearance, although they remain limited to the palate, which is sometimes so significant that it makes swallowing difficult. Ulceration or perforation of the palate is exceptional in mucosal leishmaniasis, so much so that if it occurs it is imperative to rule out other infectious diseases (leprosy, paracoccidioidomycosis, and syphilis), tumors (carcinomas, angiocentric lymphomas [lymphomatoid granulomatosis], and cutaneous lymphomas), and autoimmune diseases (various vasculitises and systemic lupus erythematosus). In mucosal leishmaniasis, involvement of the gums, mucosa of the gums, the tongue, and the internal aspect of the lips is exceptional. When infiltration and edema of the lips occur, it is almost always due to spread due to contiguity from the skin or nasal mucosa in the case of the upper lip, or by direct inoculation in the case of the lower lip.

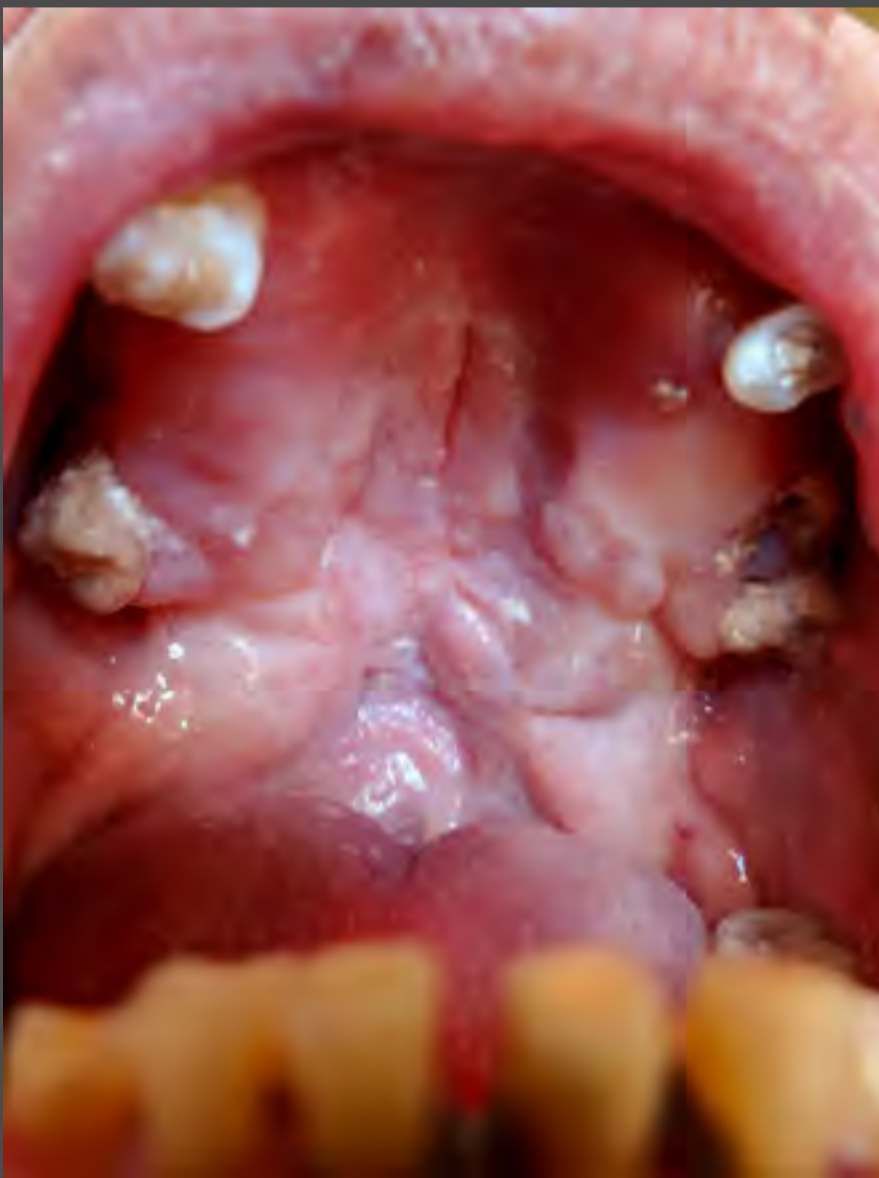
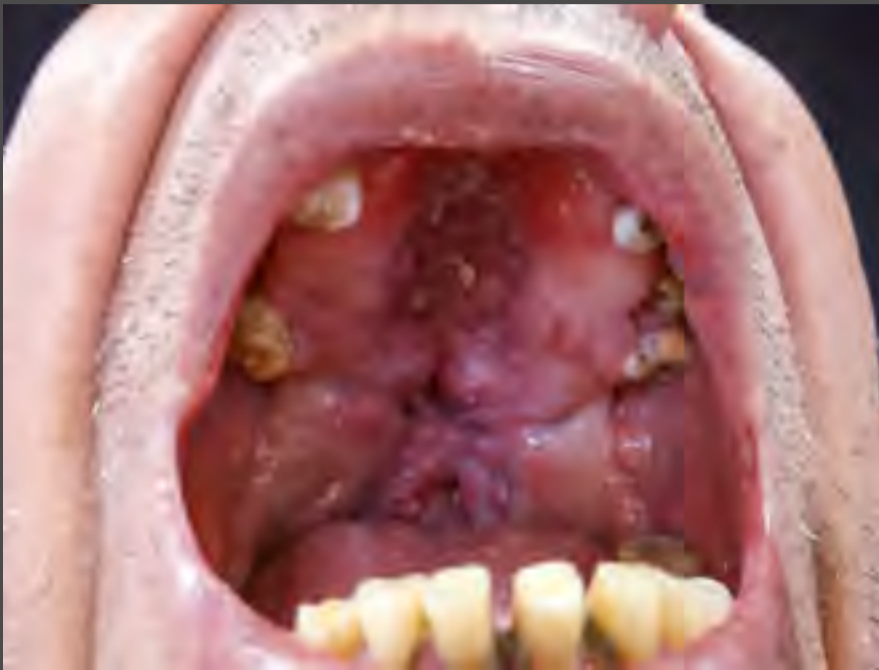


**Figures 4.61I, J and K.**

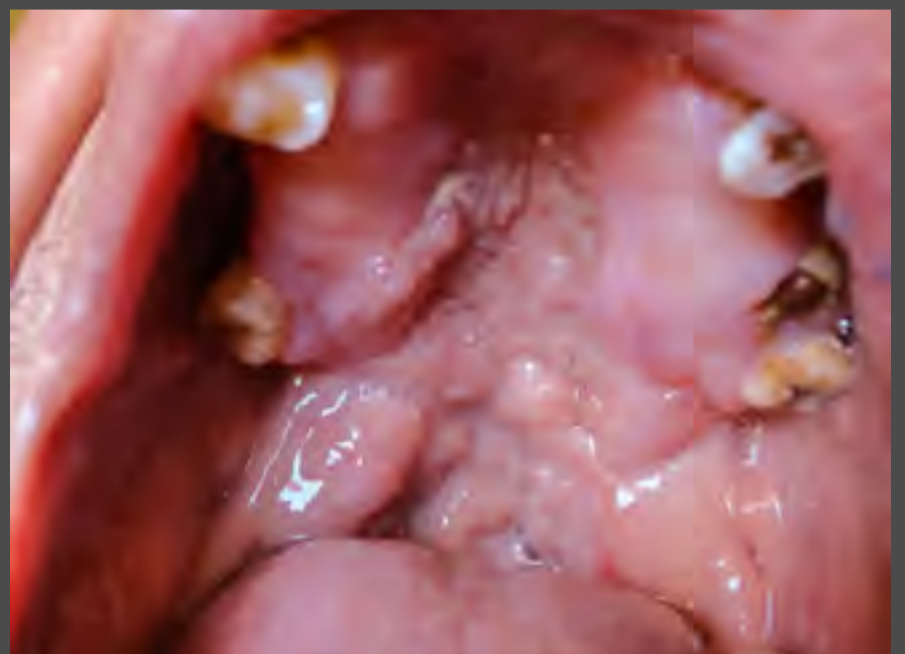The lesions increase in volume and take on a proliferative pseudoneoplastic appearance, although they remain limited to the palate, which is sometimes so significant that it makes swallowing difficult. Ulceration or perforation of the palate is exceptional in mucosal leishmaniasis, so much so that if it occurs it is imperative to rule out other infectious diseases (leprosy, paracoccidioidomycosis, and syphilis), tumors (carcinomas, angiocentric lymphomas [lymphomatoid granulomatosis], and cutaneous lymphomas), and autoimmune diseases (various vasculitises and systemic lupus erythematosus). In mucosal leishmaniasis, involvement of the gums, mucosa of the gums, the tongue, and the internal aspect of the lips is exceptional. When infiltration and edema of the lips occur, it is almost always due to spread due to contiguity from the skin or nasal mucosa in the case of the upper lip, or by direct inoculation in the case of the lower lip.





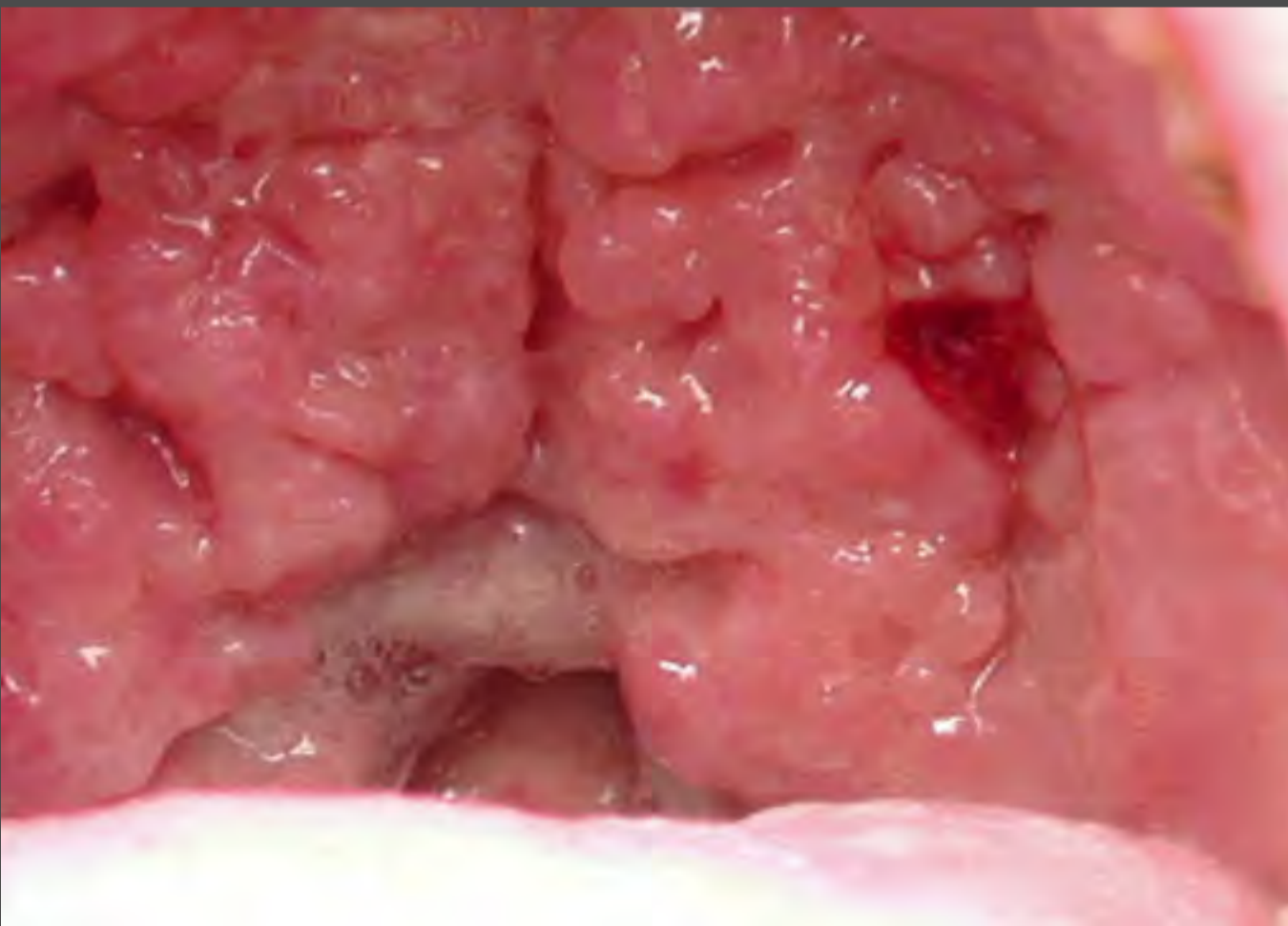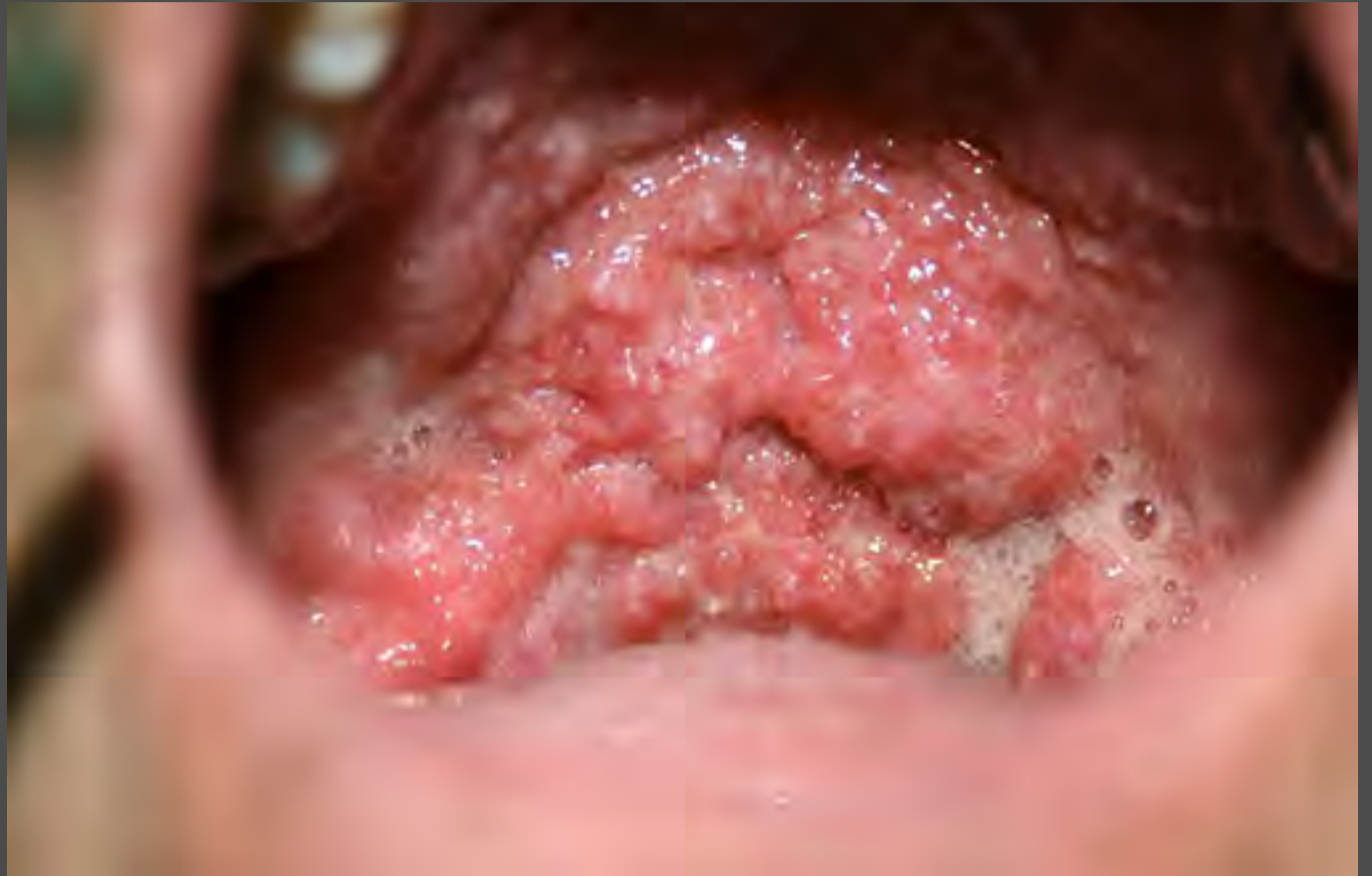**Figures 4.61L, M and N.**

The lesions increase in volume and take on a proliferative pseudoneoplastic appearance, although they remain limited to the palate, which is sometimes so significant that it makes swallowing difficult. Ulceration or perforation of the palate is exceptional in mucosal leishmaniasis, so much so that if it occurs it is imperative to rule out other infectious diseases (leprosy, paracoccidioidomycosis, and syphilis), tumors (carcinomas, angiocentric lymphomas [lymphomatoid granulomatosis], and cutaneous lymphomas), and autoimmune diseases (various vasculitises and systemic lupus erythematosus). In mucosal leishmaniasis, involvement of the gums, mucosa of the gums, the tongue, and the internal aspect of the lips is exceptional. When infiltration and edema of the lips occur, it is almost always due to spread due to contiguity from the skin or nasal mucosa in the case of the upper lip, or by direct inoculation in the case of the lower lip.





**Figure 4.62.**  
Pregnant woman with  
extensive involvement  
of the palate and no  
involvement of the  
vocal cords



**Figure 4.63.**  
Extensive and severe  
granulomatous  
infiltration of the  
soft palate, several  
years old

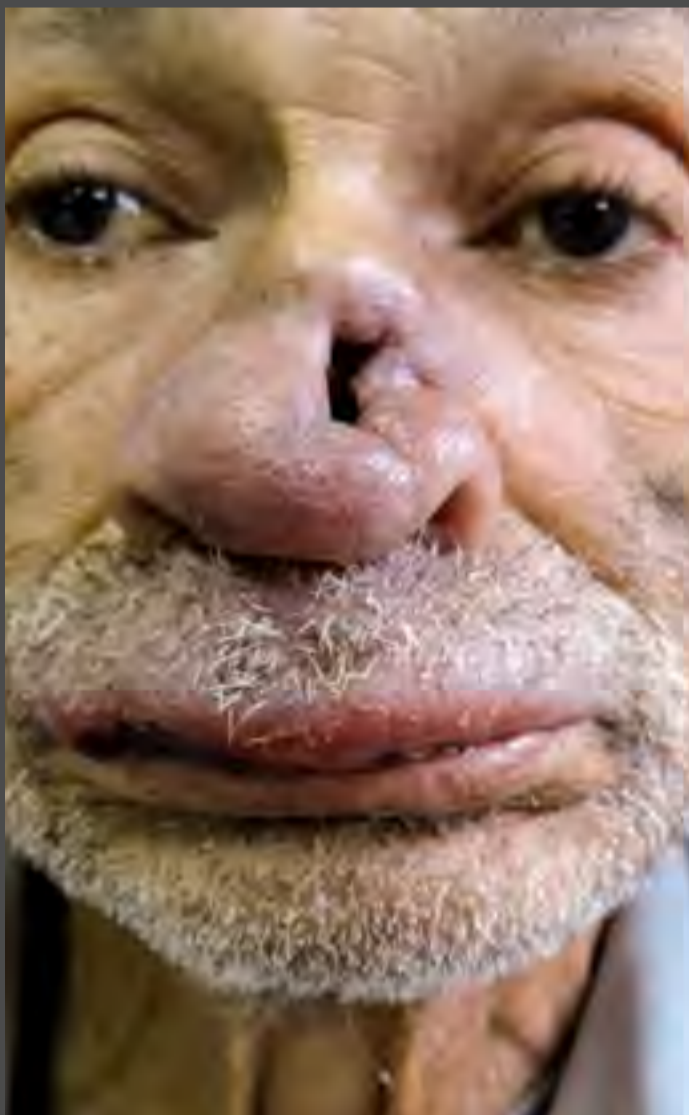
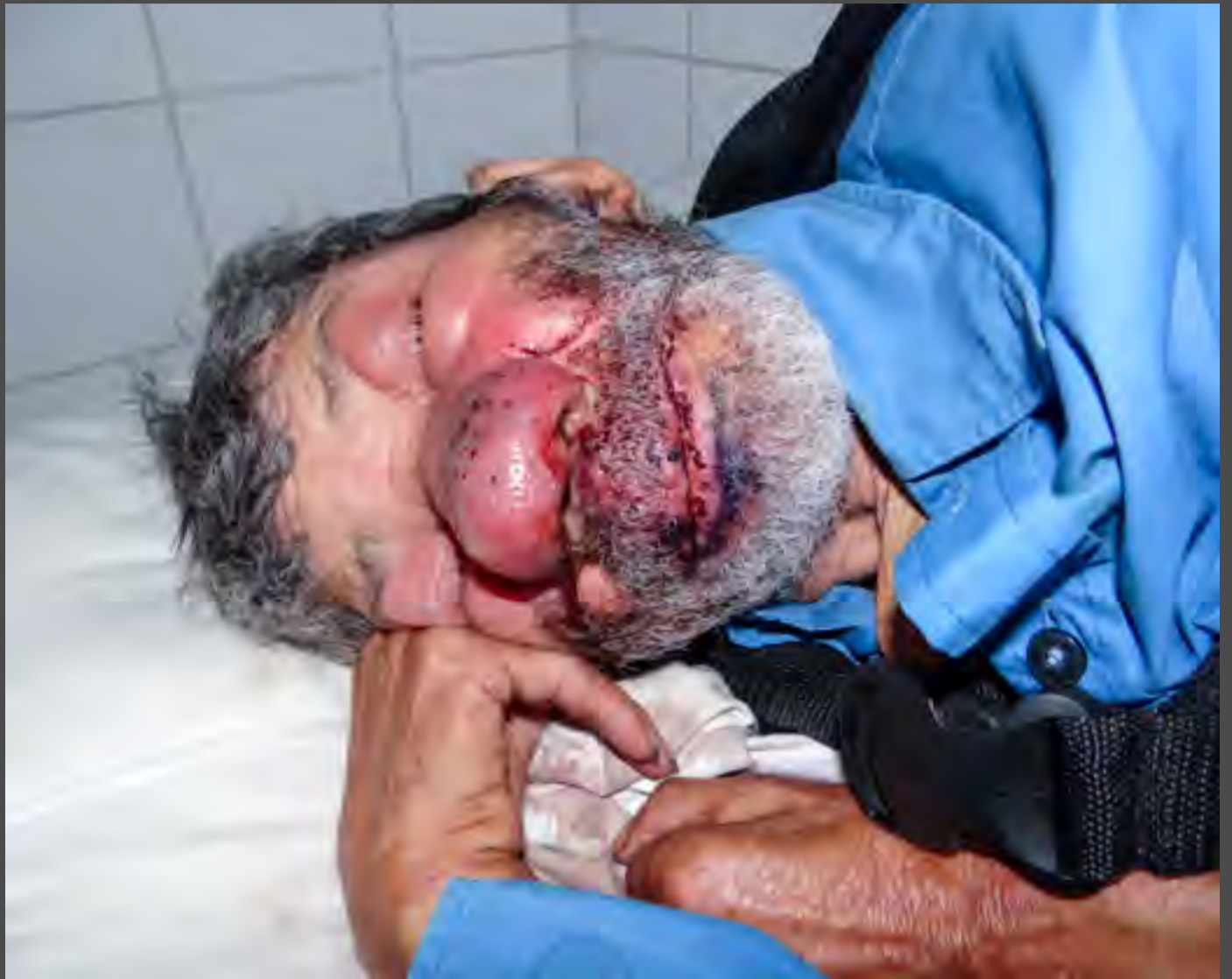
Table 4.3. Levels of mucosal disease severity

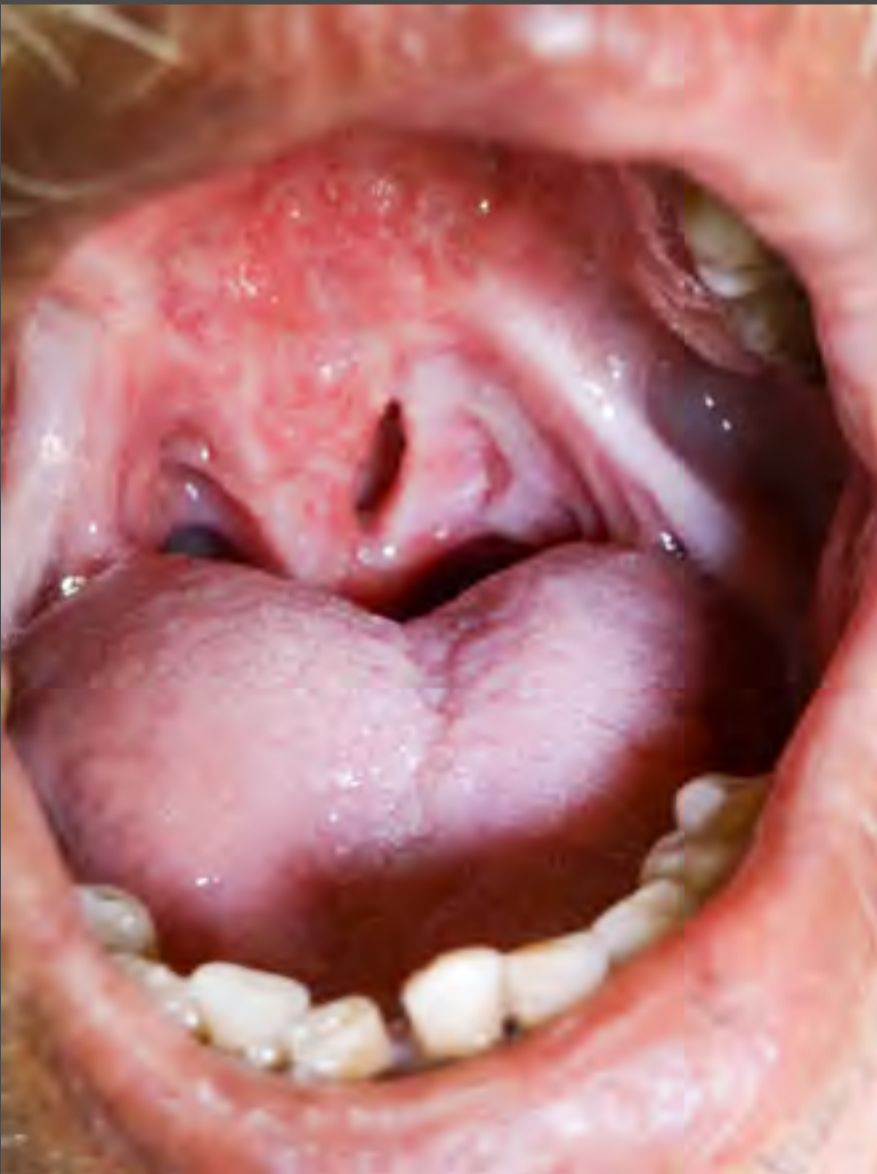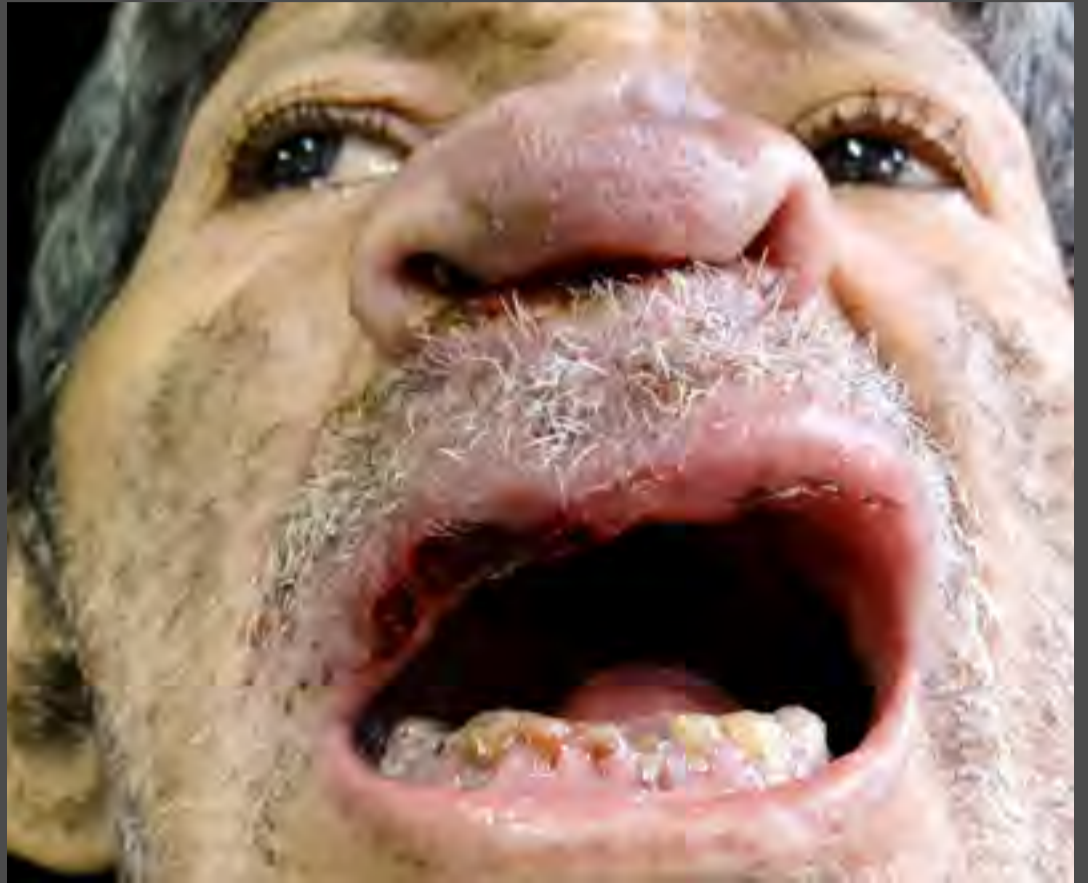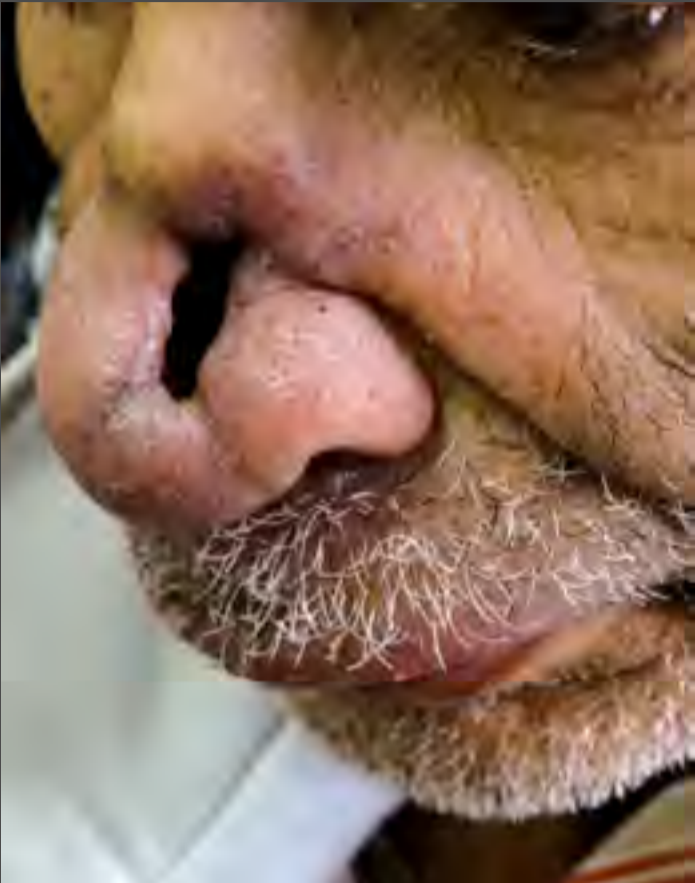Mild	Moderate	Severe
<p>When it is limited to the nasal cavity, oropharynx, or both; usually manifested by nasal obstruction and bloody crusts (<i>Figures 4.20 a 4.58</i>).</p>	<p>When it also involves the oral cavity, supraglottis, and epiglottis; clinically, mild to moderate dysphonia and odynophagia occur (<i>Figures 4.59 a 4.63</i>).</p>	<p>When it also involves the vocal cords, subglottis, and 70% to 80% of the trachea. Clinical manifestations are significant dysphonia and odynophagia and moderate to severe difficulty breathing (<i>Figures 4.64 a 4.74</i>).</p>



**Figure 4.64.**  
Patient with extensive nasal destruction with severe bacterial superinfection associated with secondary myiasis



**Figures 4.65A and B.**  
Severe involvement of the nasal mucosa and palate. Perforation of the skin of the nasal ridge is not common, and in this case, it was secondary to the superinfection process.



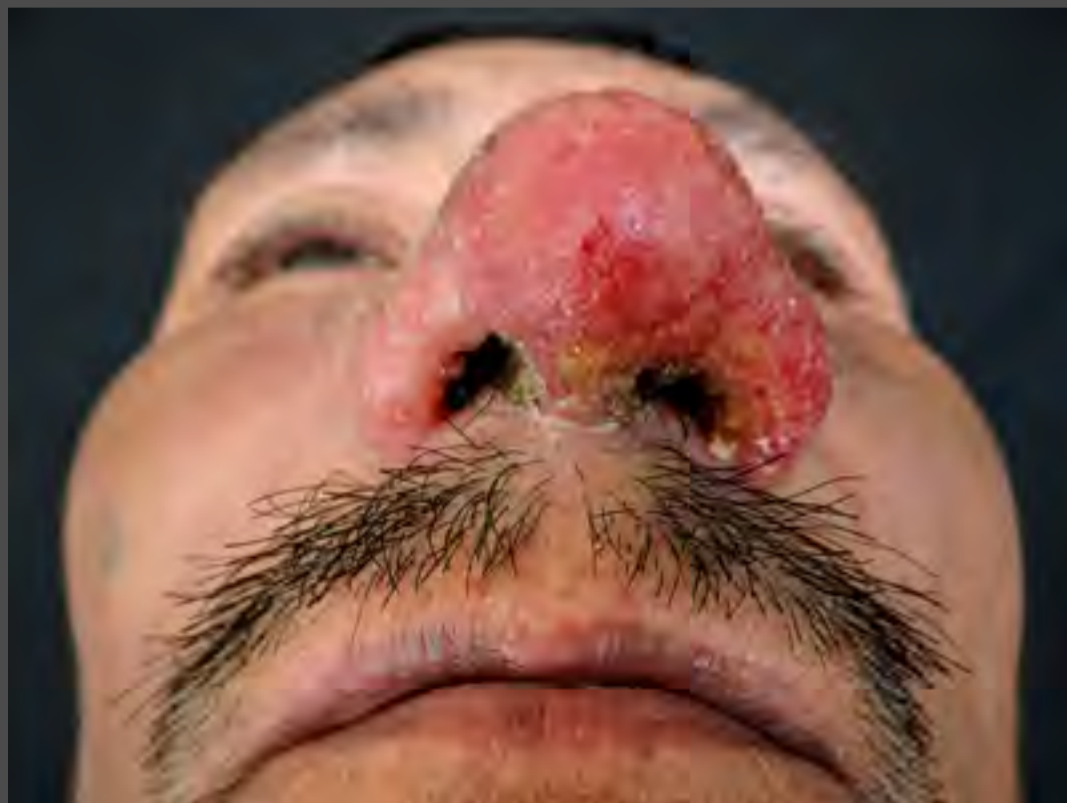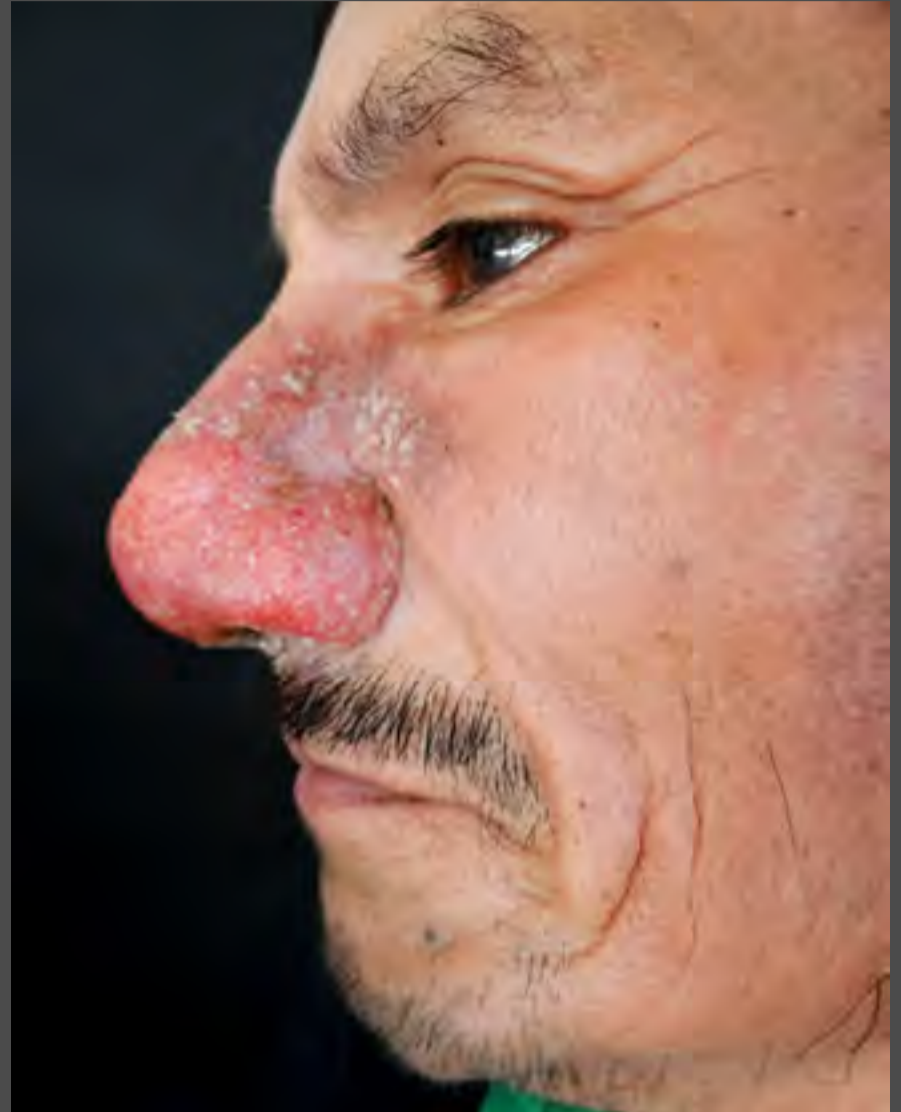
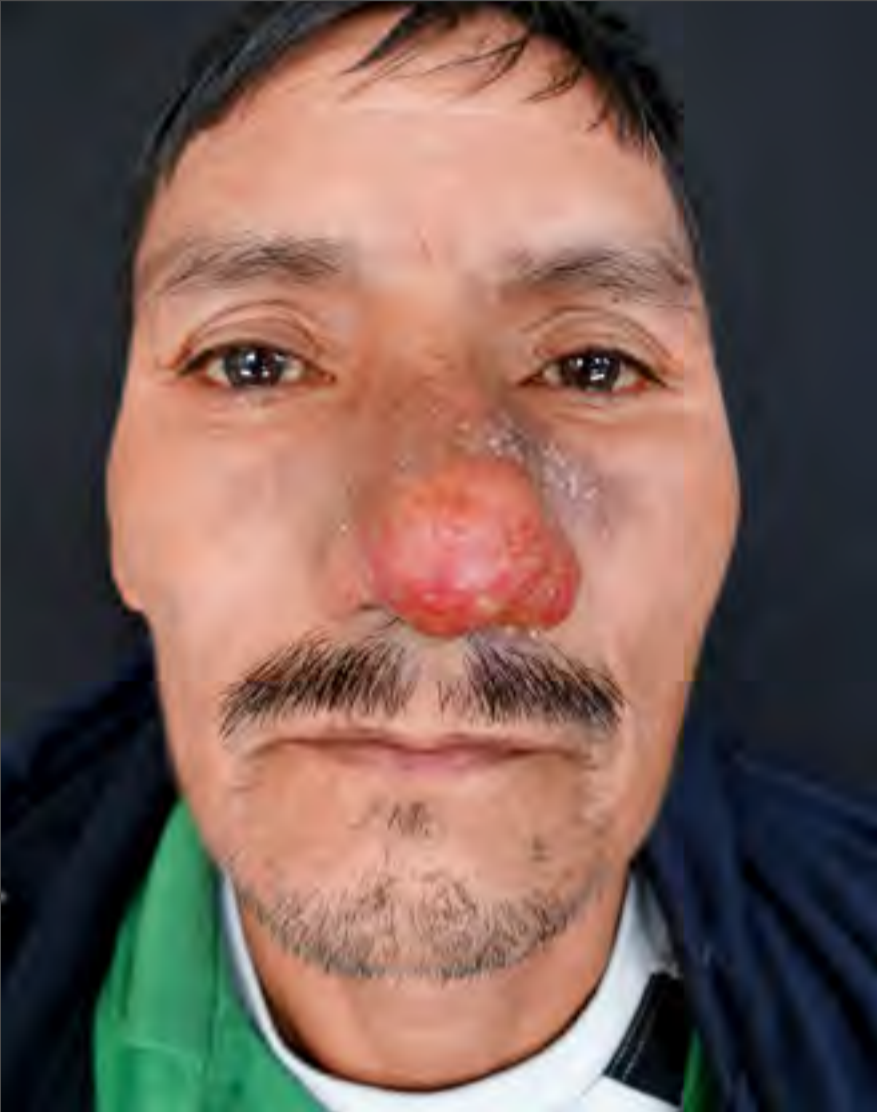**Figures 4.65C, D and E.**

Severe involvement of the nasal mucosa and palate. Perforation of the skin of the nasal ridge is not common, and in this case, it was secondary to the superinfection process.



**Figures 4.66A, B and C.**

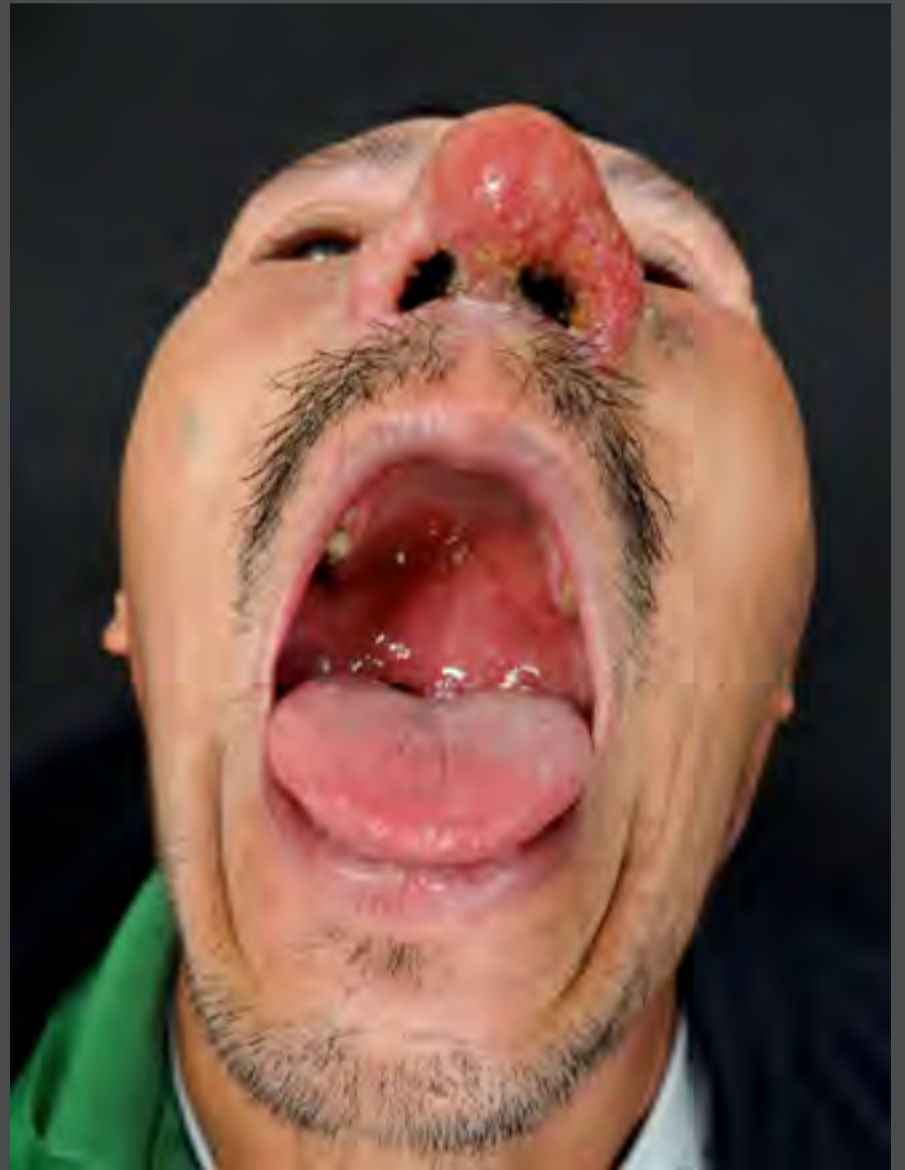
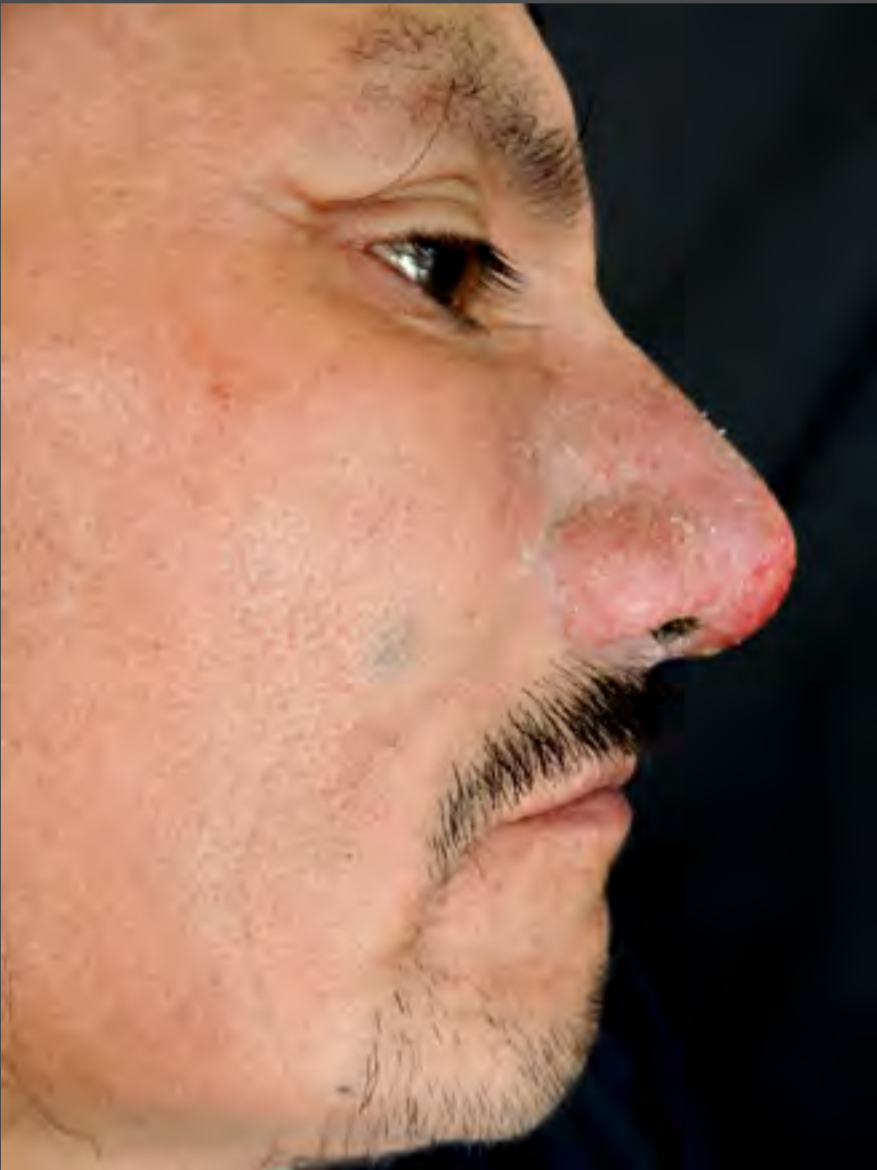Nasal involvement may be on one side only. When it spreads, pharyngeal and mouth lesions involve both sides.

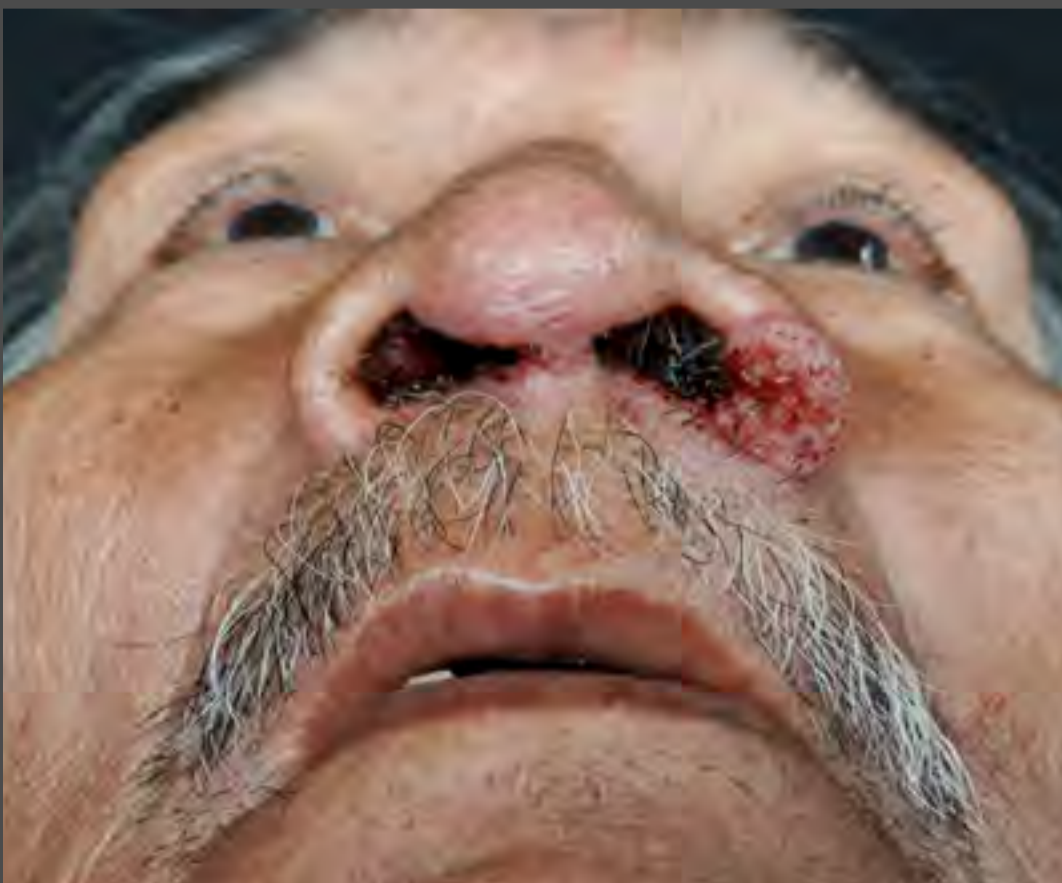
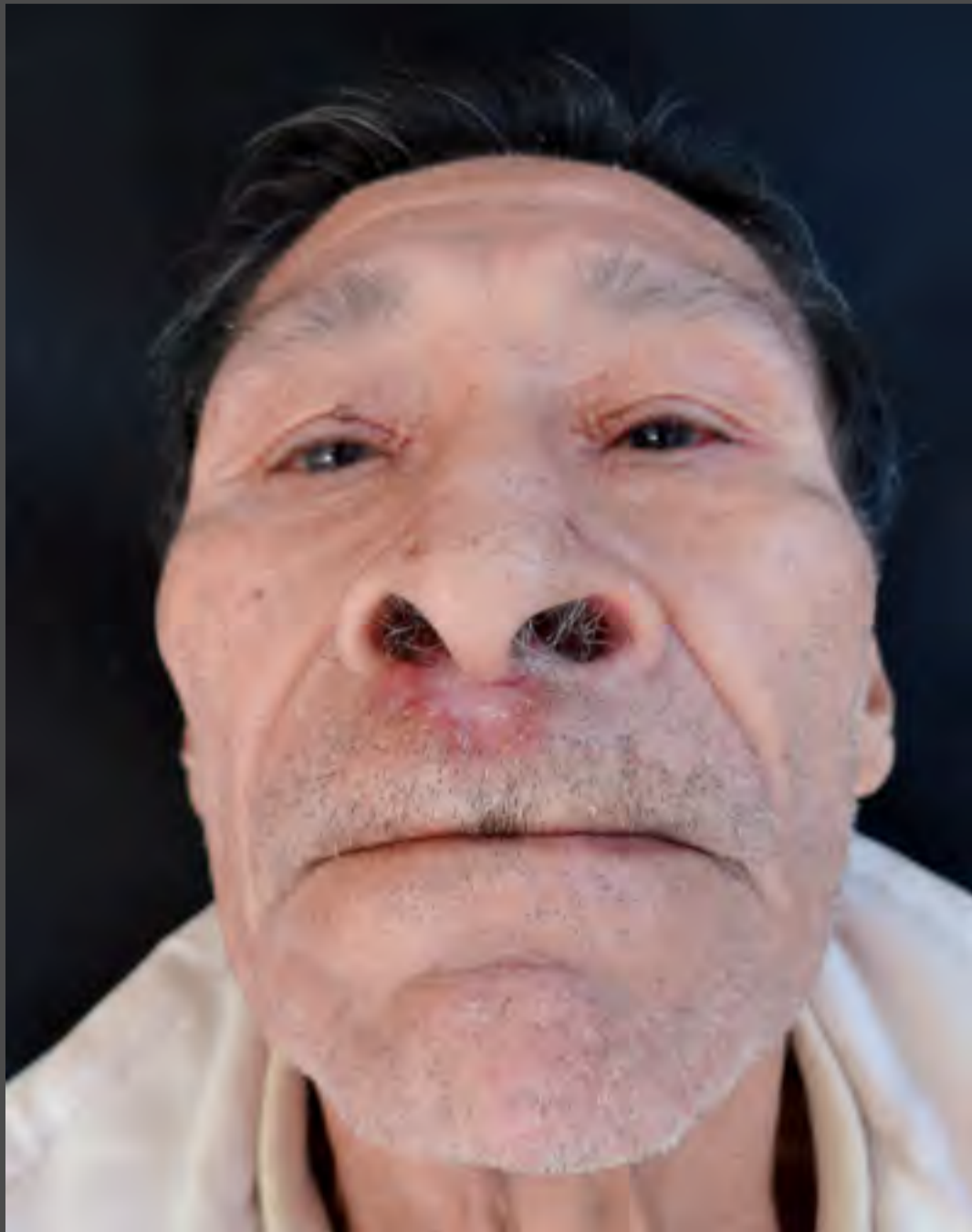


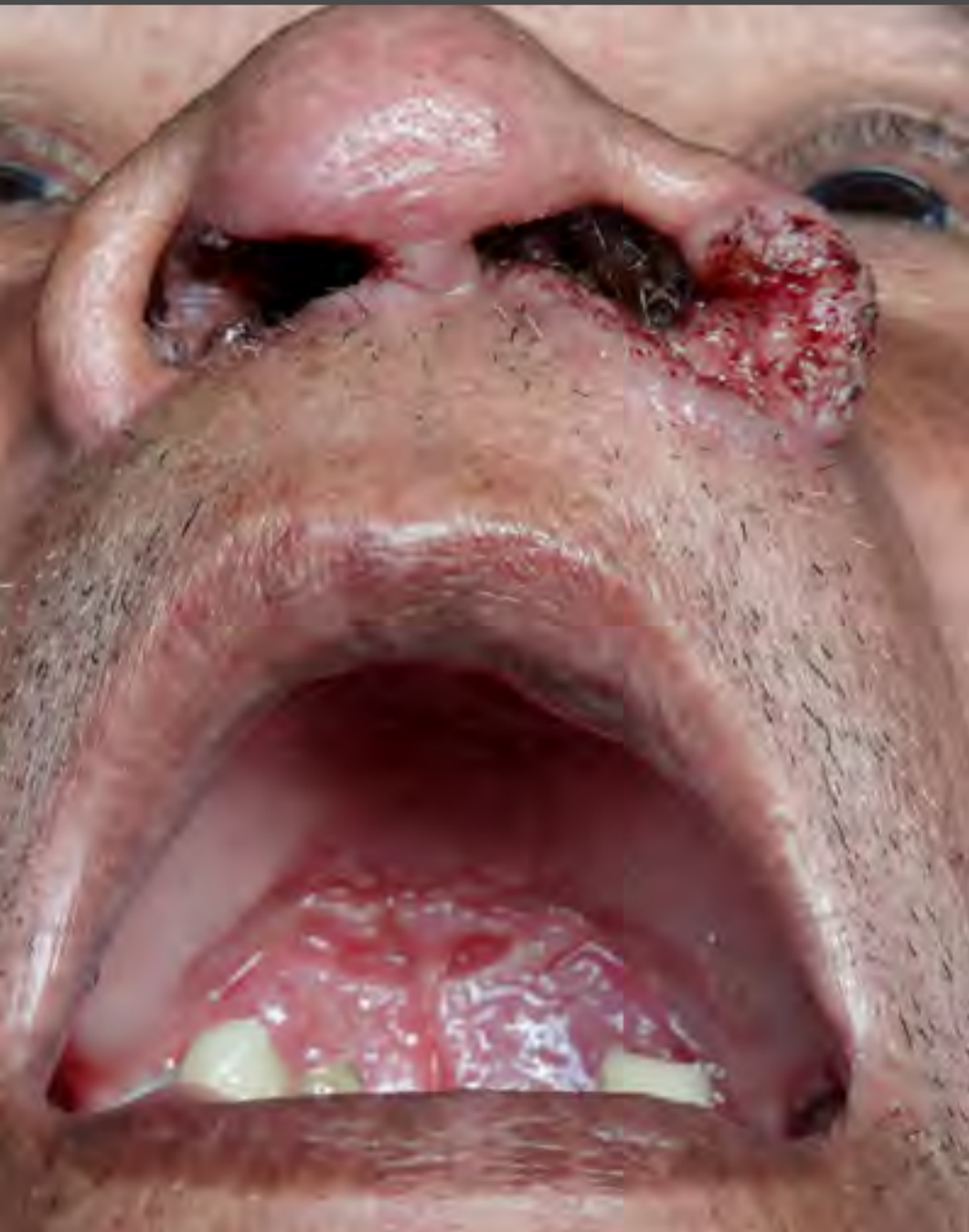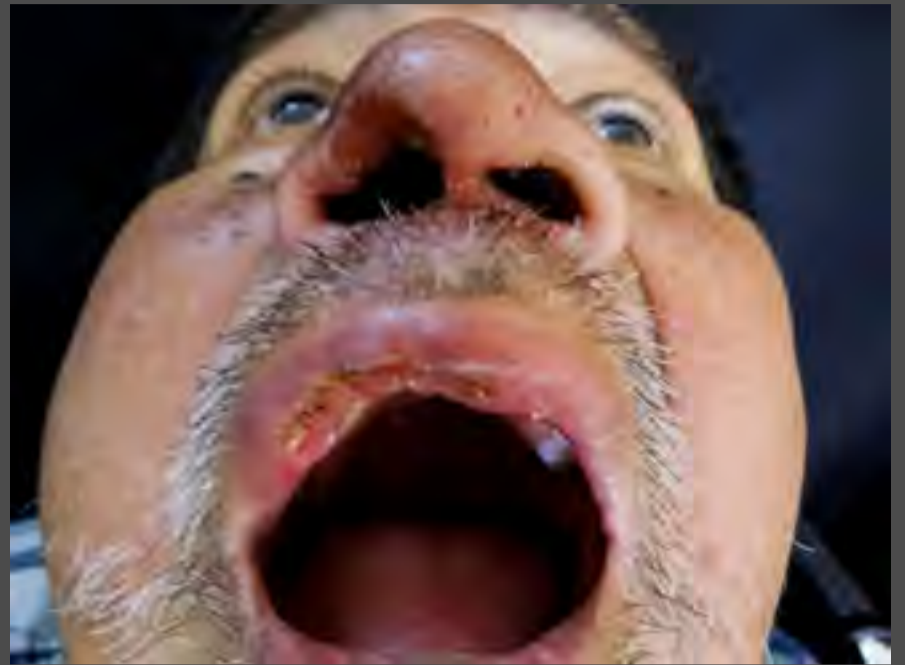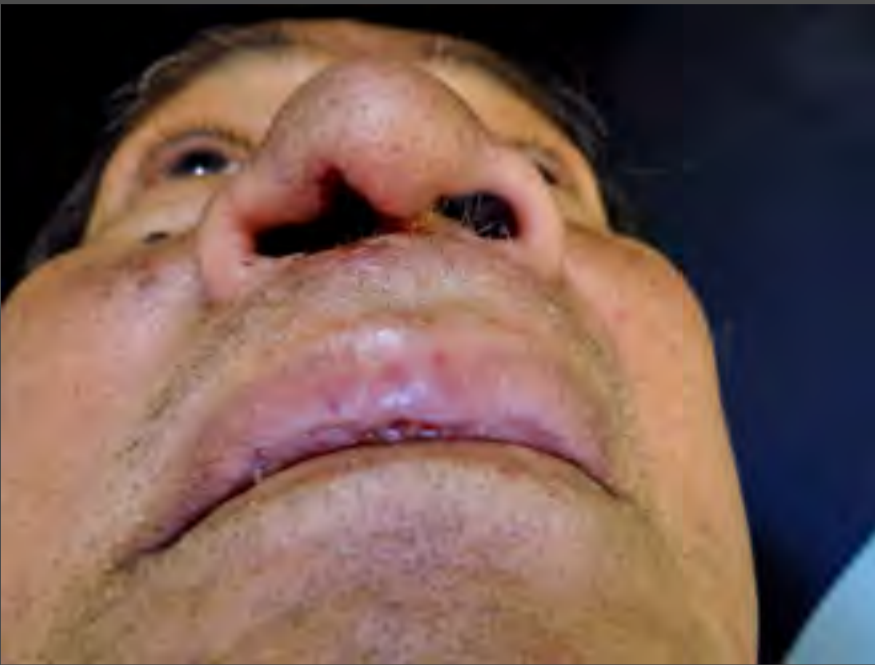**Figures 4.66D and E.**

Nasal involvement may be on one side only. When it spreads, pharyngeal and mouth lesions involve both sides.



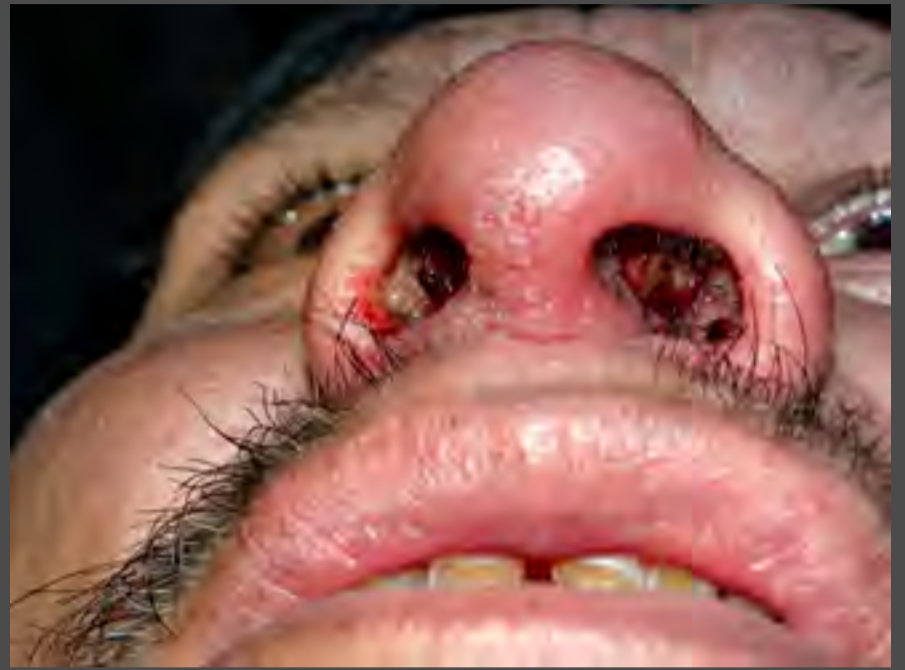
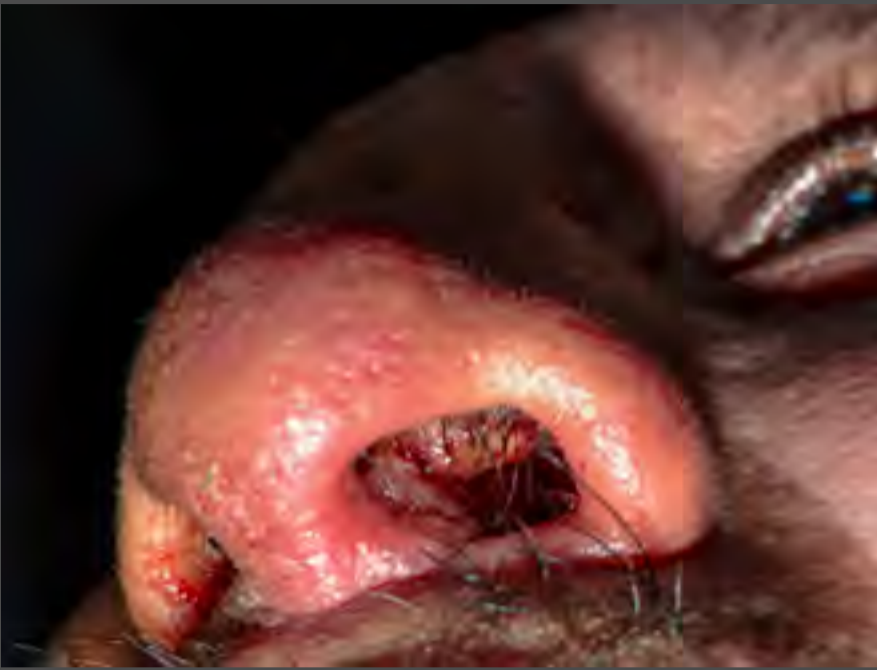
**Figures 4.67A and B.**  
Involvement of the nasal mucosa usually precedes that of the oral mucosa, and it may take months or even up to two years for them to fully develop.



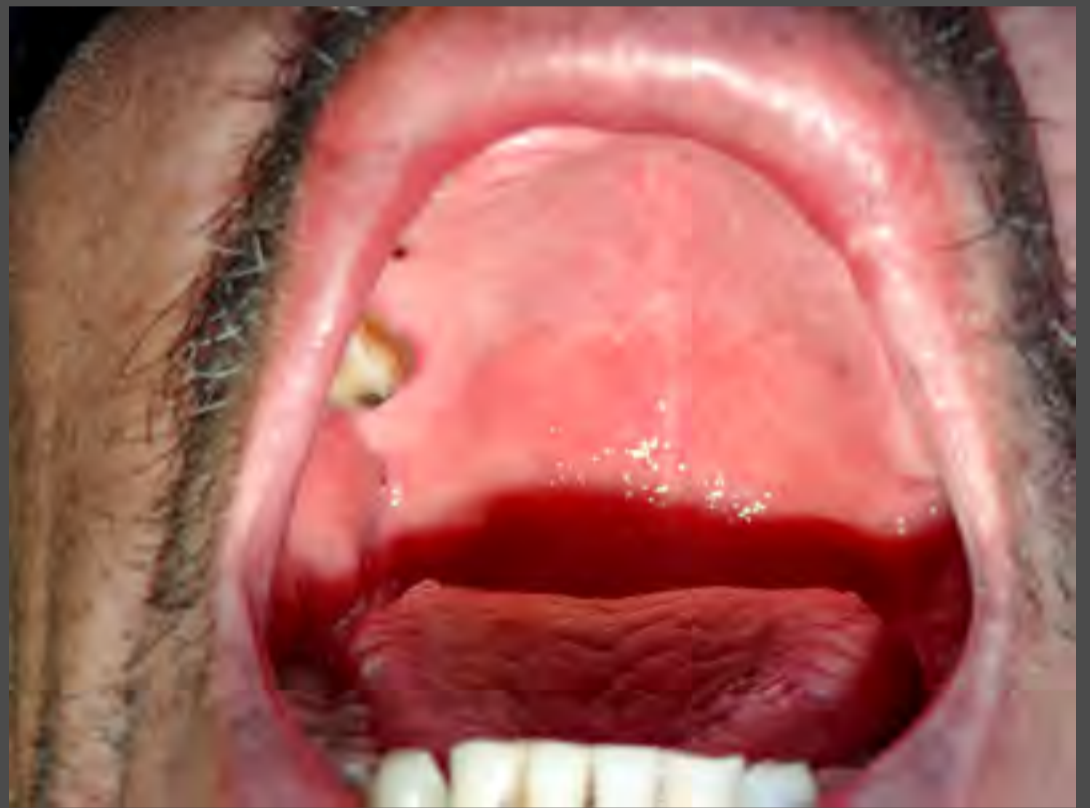**Figures 4.67C, D and E.**

Involvement of the nasal mucosa usually precedes that of the oral mucosa, and it may take months or even up to two years for them to fully develop.



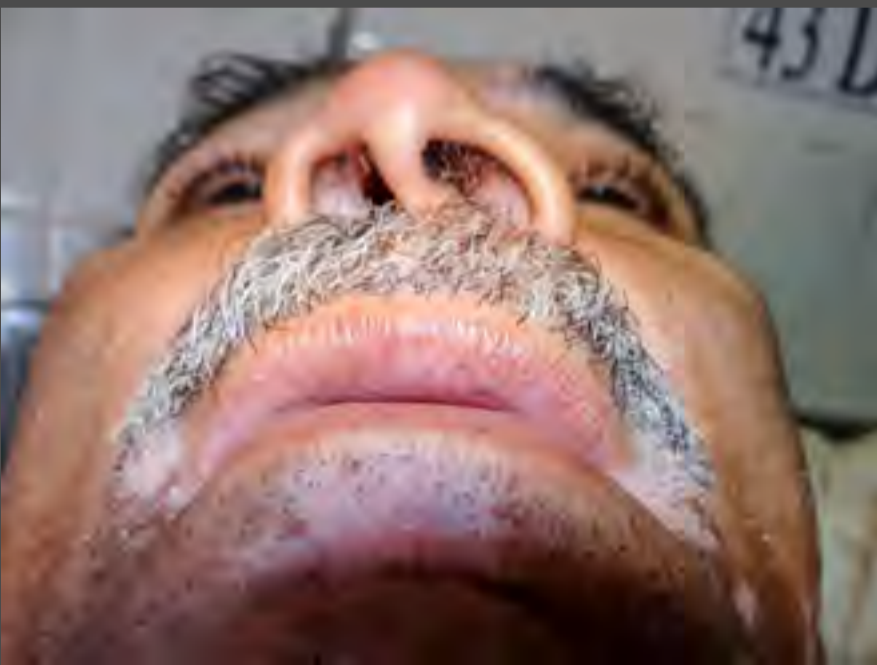**Figures 4.68A, B and C.**

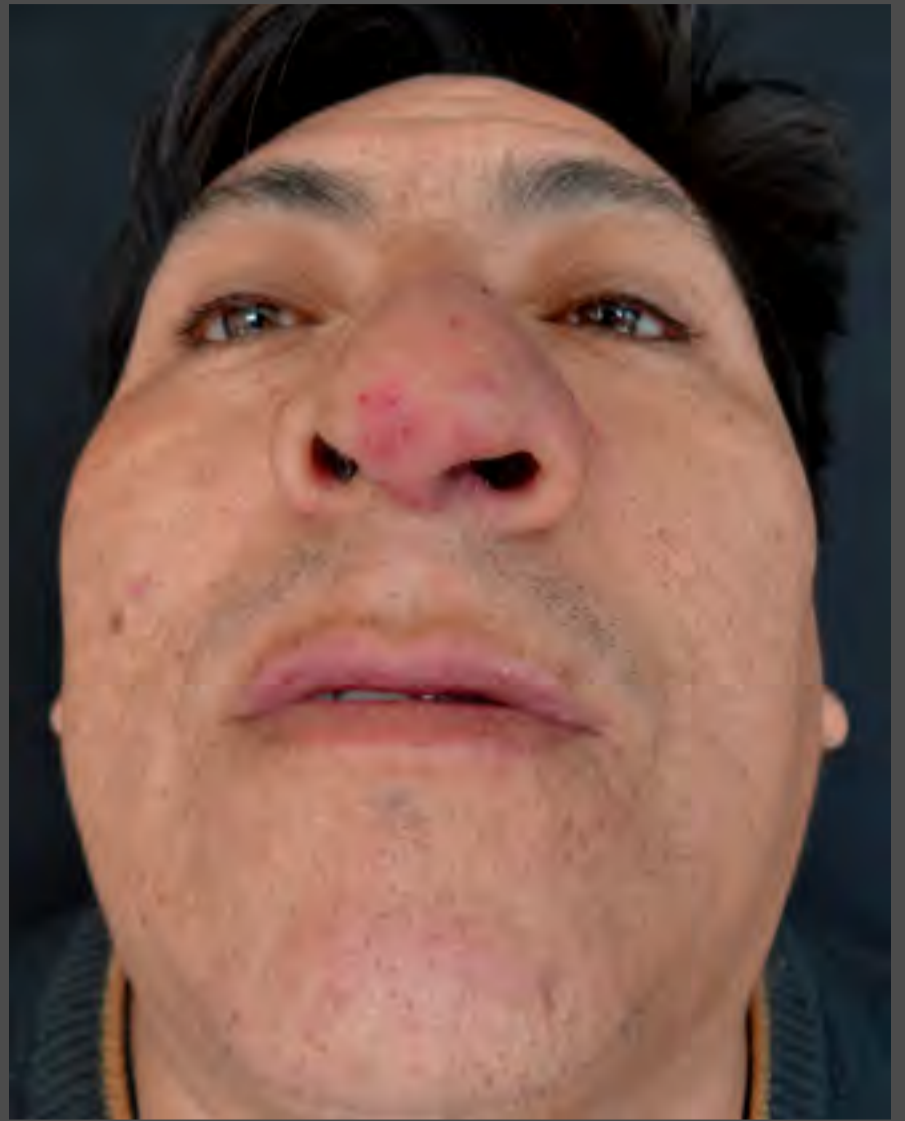Intense inflammation of the skin and nasal mucosa with only mild erythema that marks the beginning of palatine involvement due to spread of the lesions.



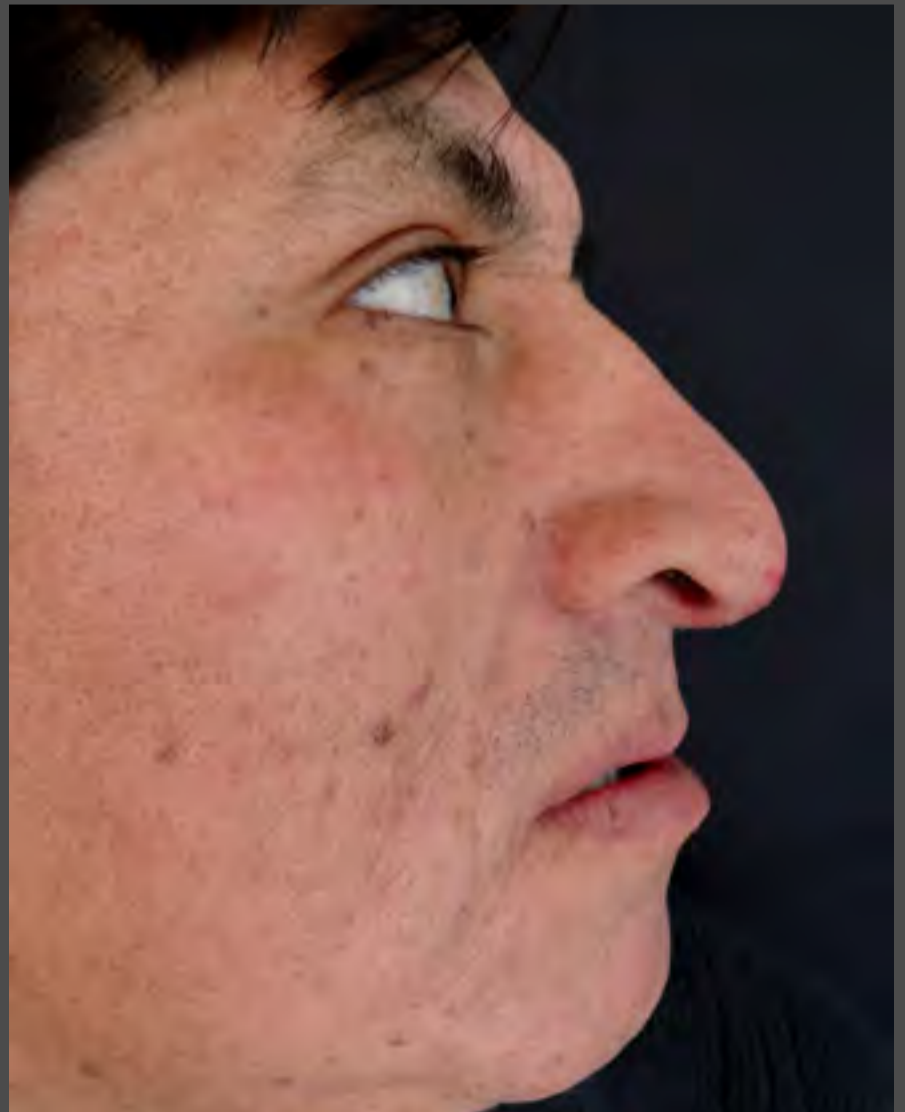**Figure 4.69.**

Considerable distortion of the nasal architecture due to loss of part of the septum with evident deviation of the columella

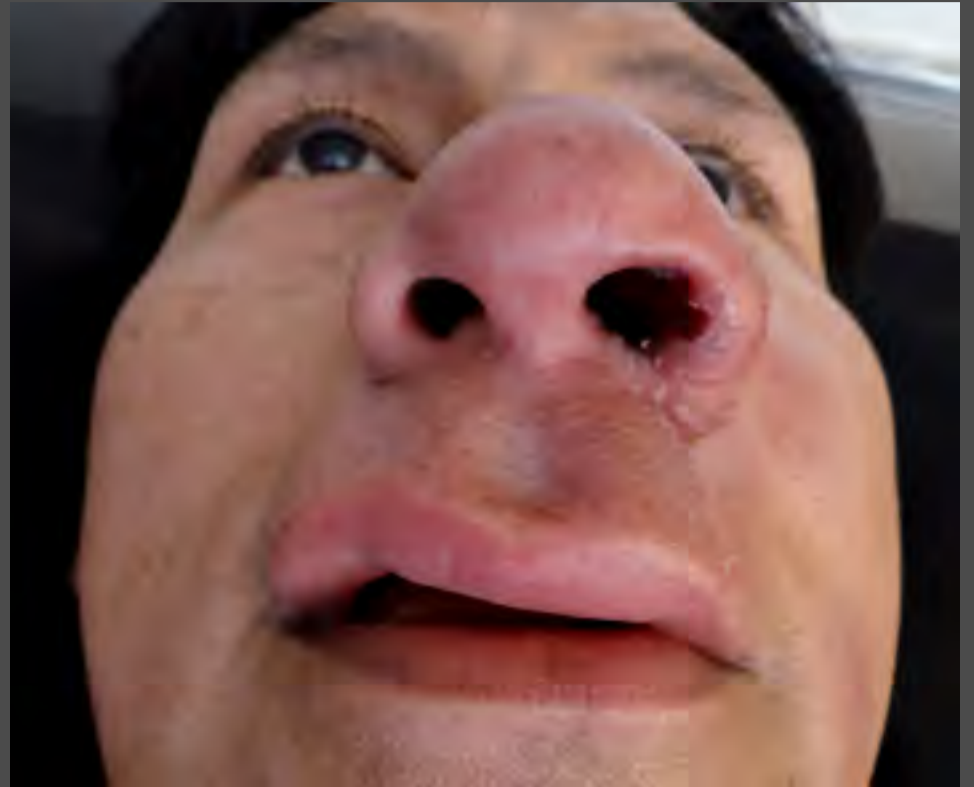
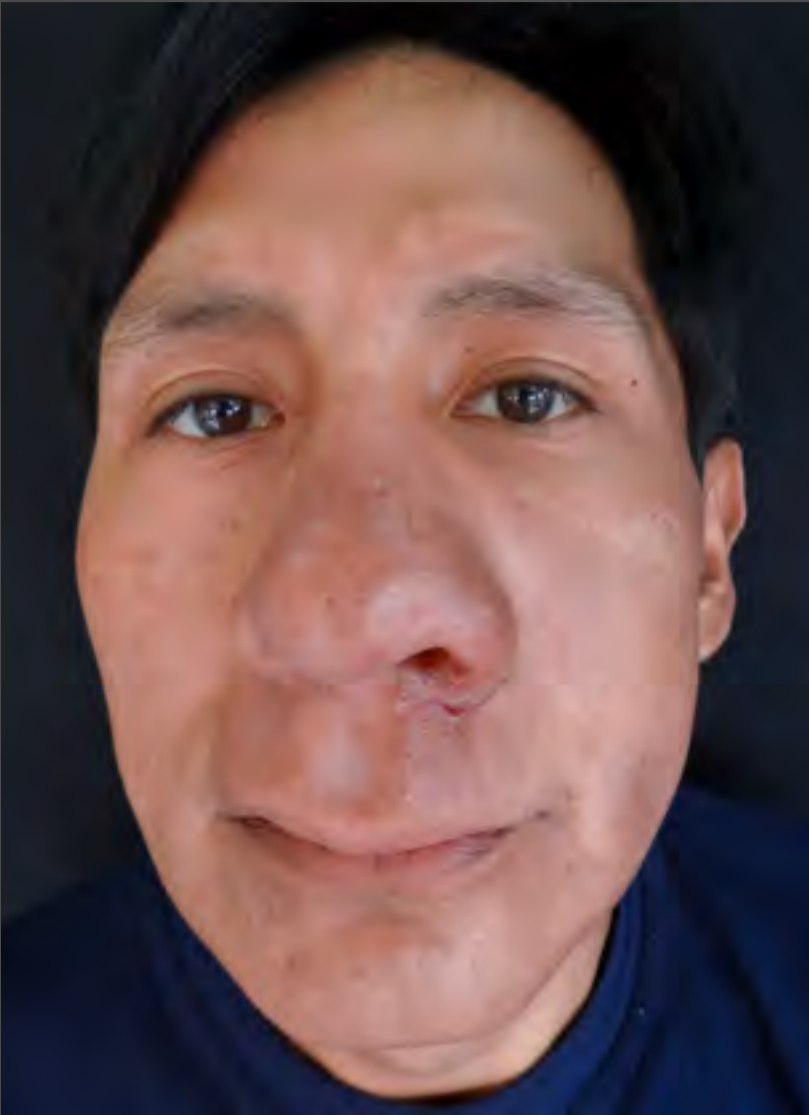


**Figures 4.70A, B and C.**  
Considerable increase in the volume of the nose  
giving it a bulbous appearance.

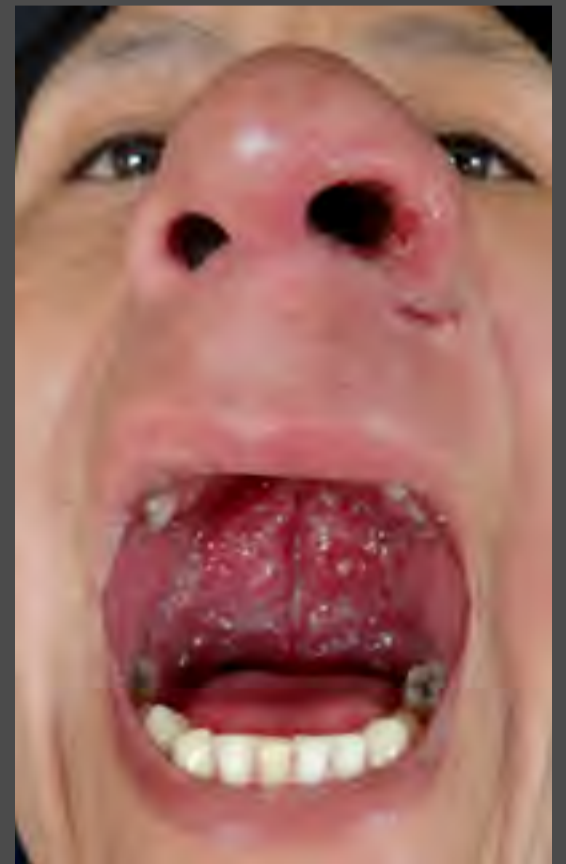
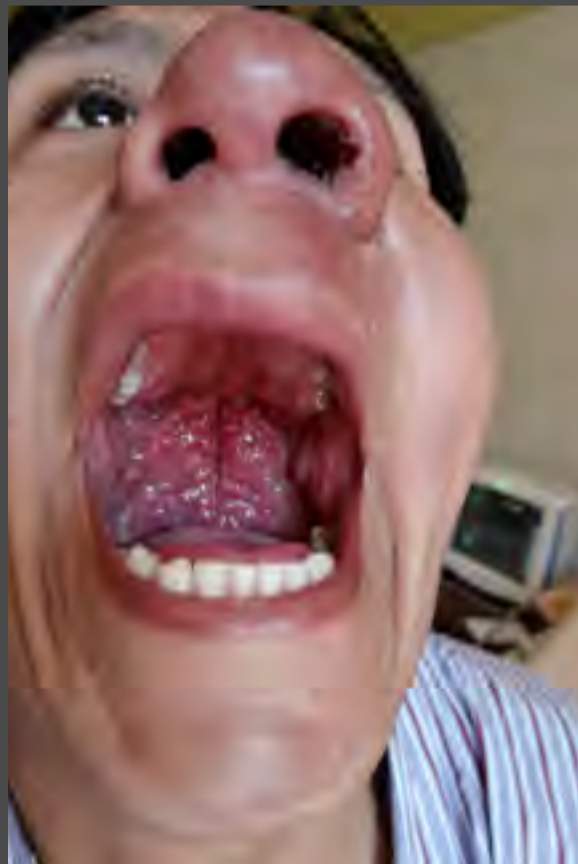
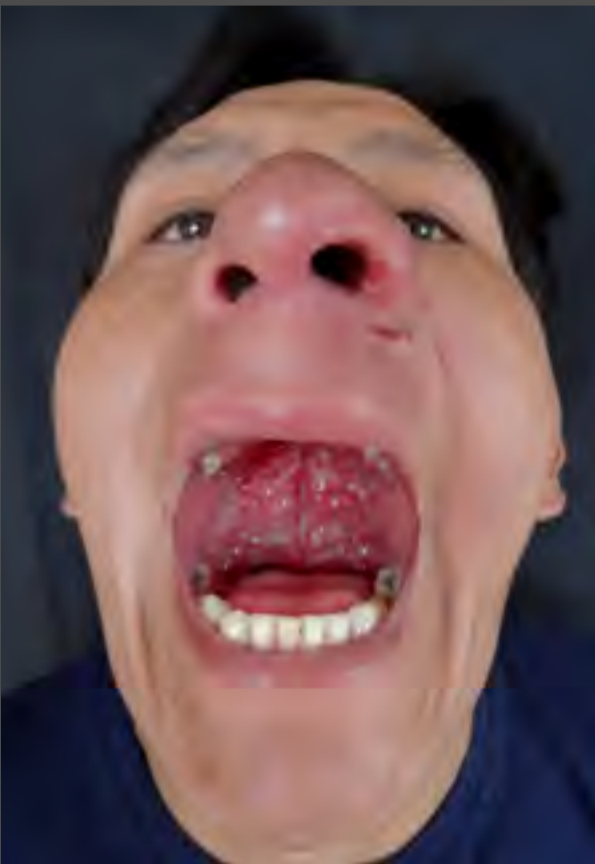


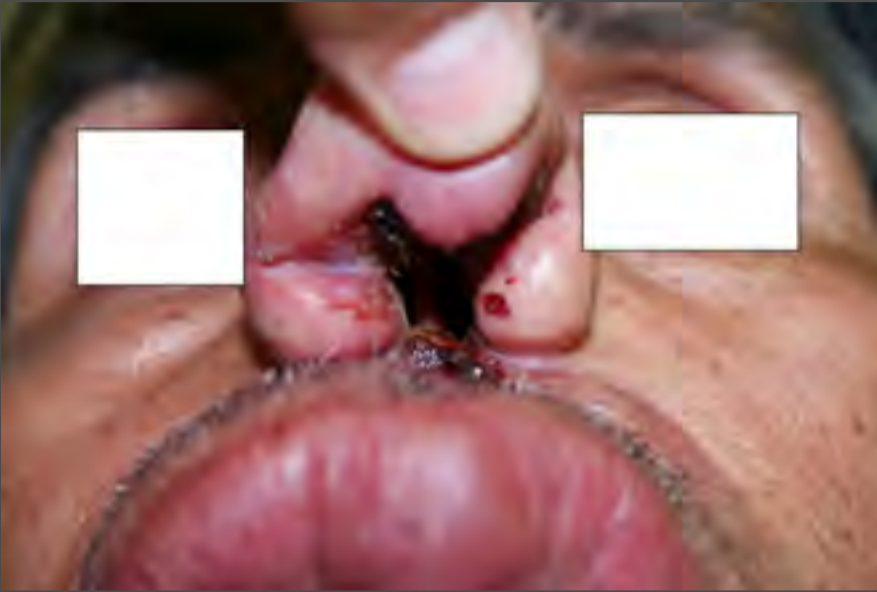

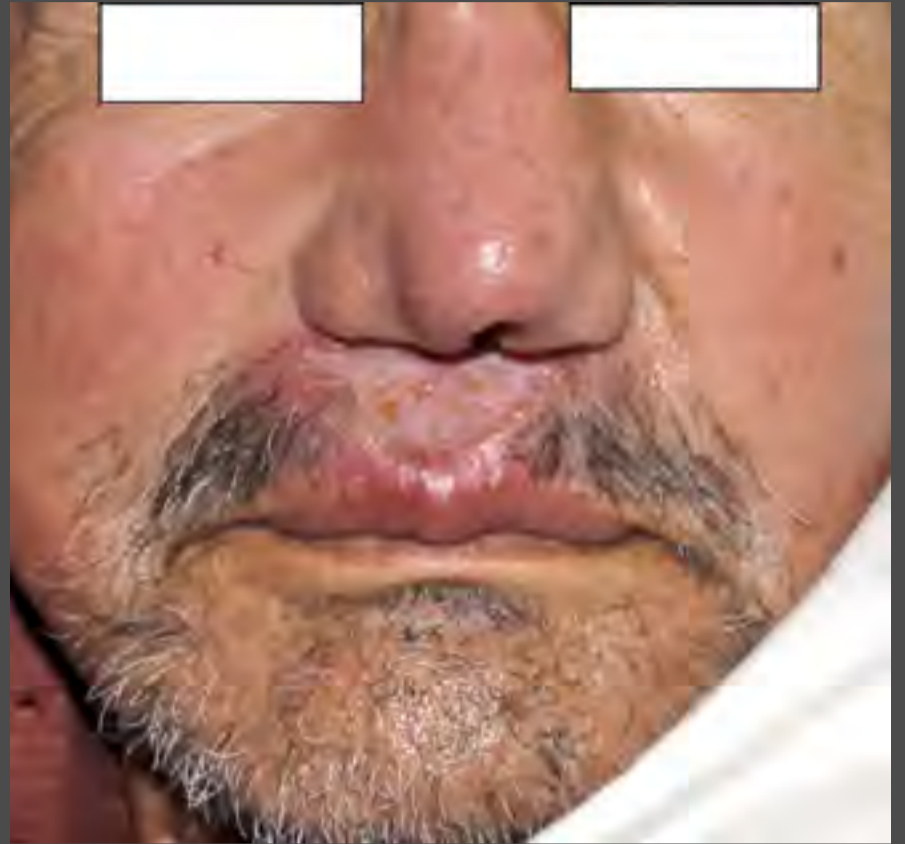Figures 4.71A, B, C, D and E.

In some patients, involvement of the oral mucosa is more extensive and more intense than involvement of the nasal mucosa. Figure 4.71D shows what is known as *Escomel's cross*.

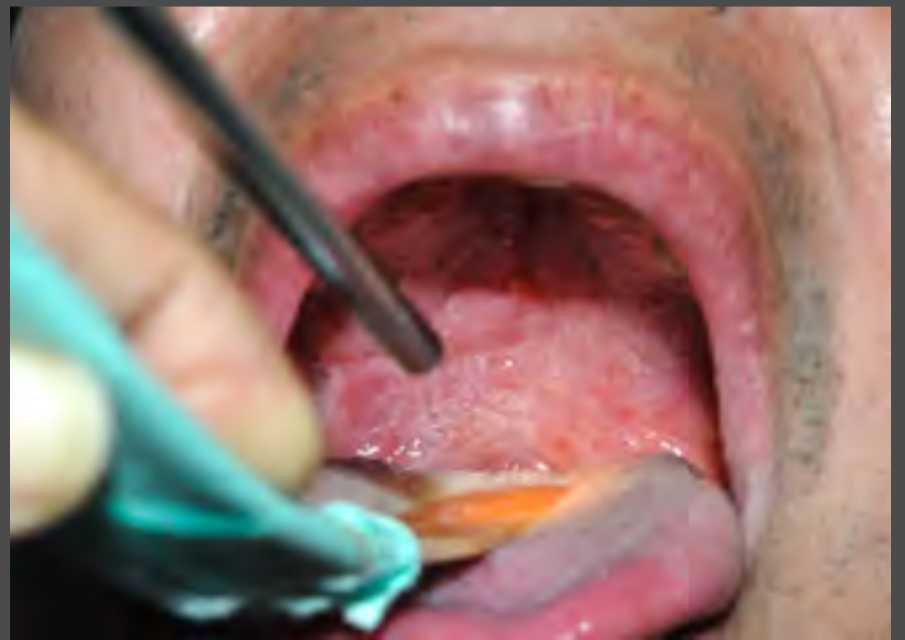
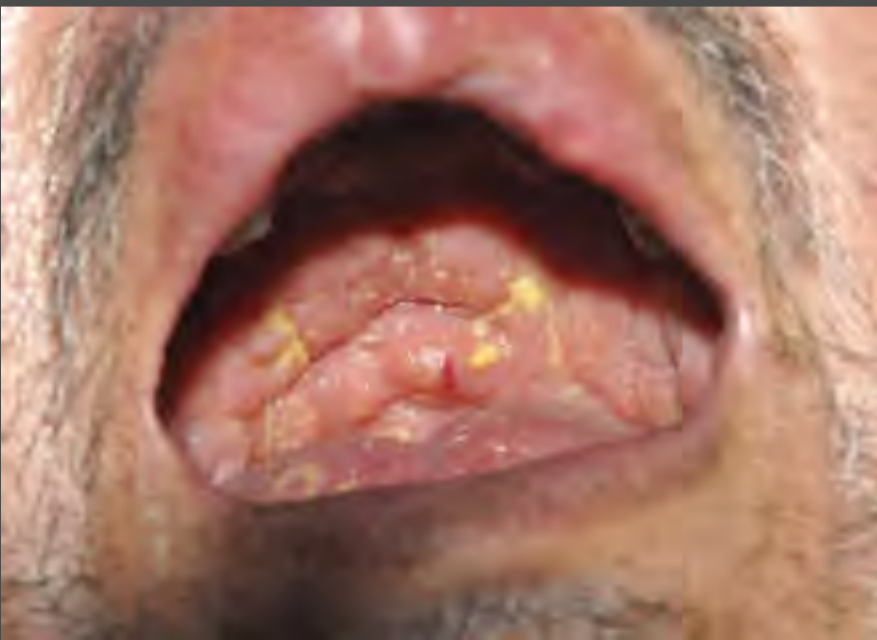


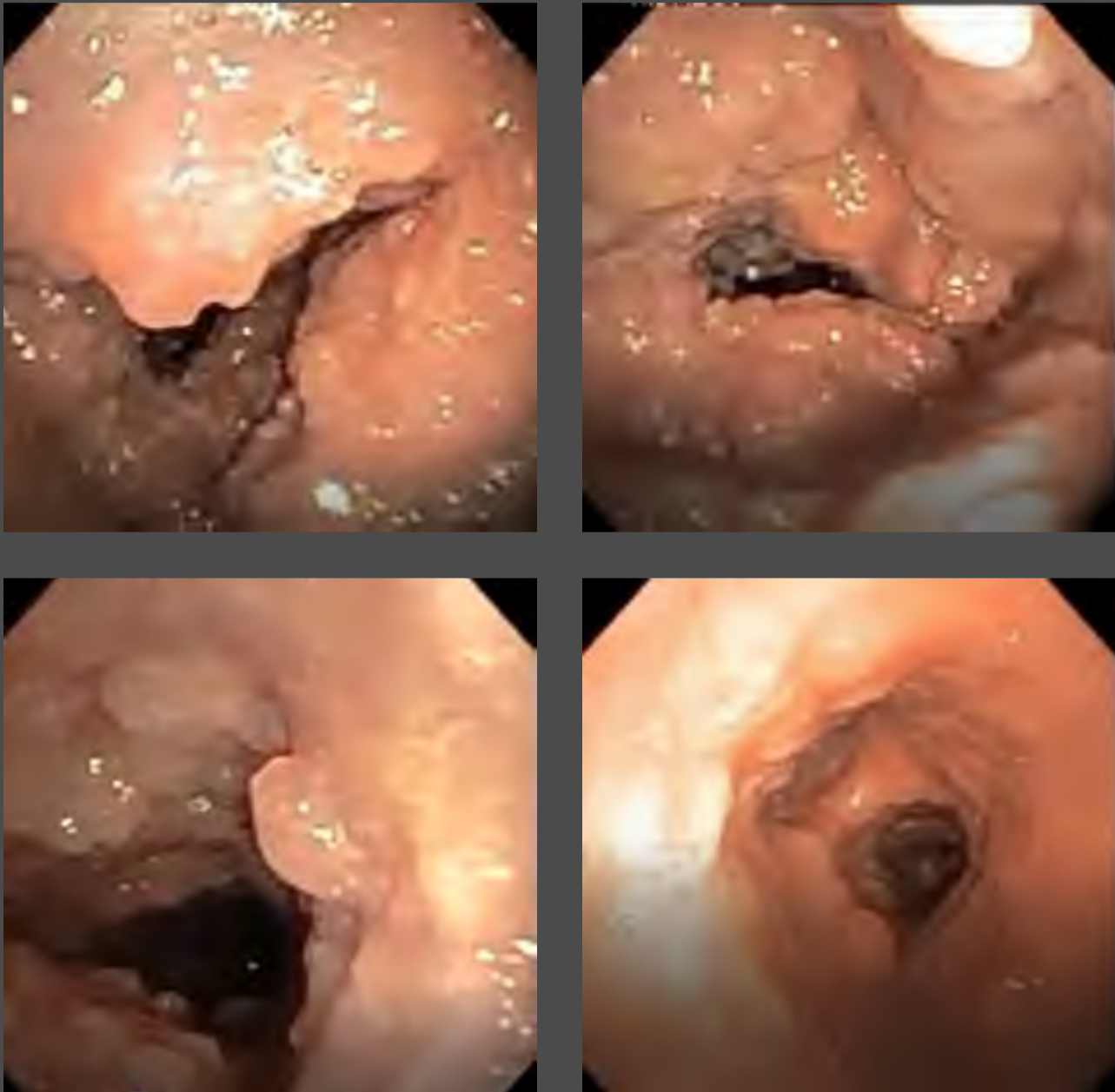
**Figures 4.72A.**  
Involvement of the upper lip and distortion of the nasal architecture from loss of the septum and columella.



**Figures 4.72B.**  
Treatment reduced inflammation and infiltration, but structural damage persists.

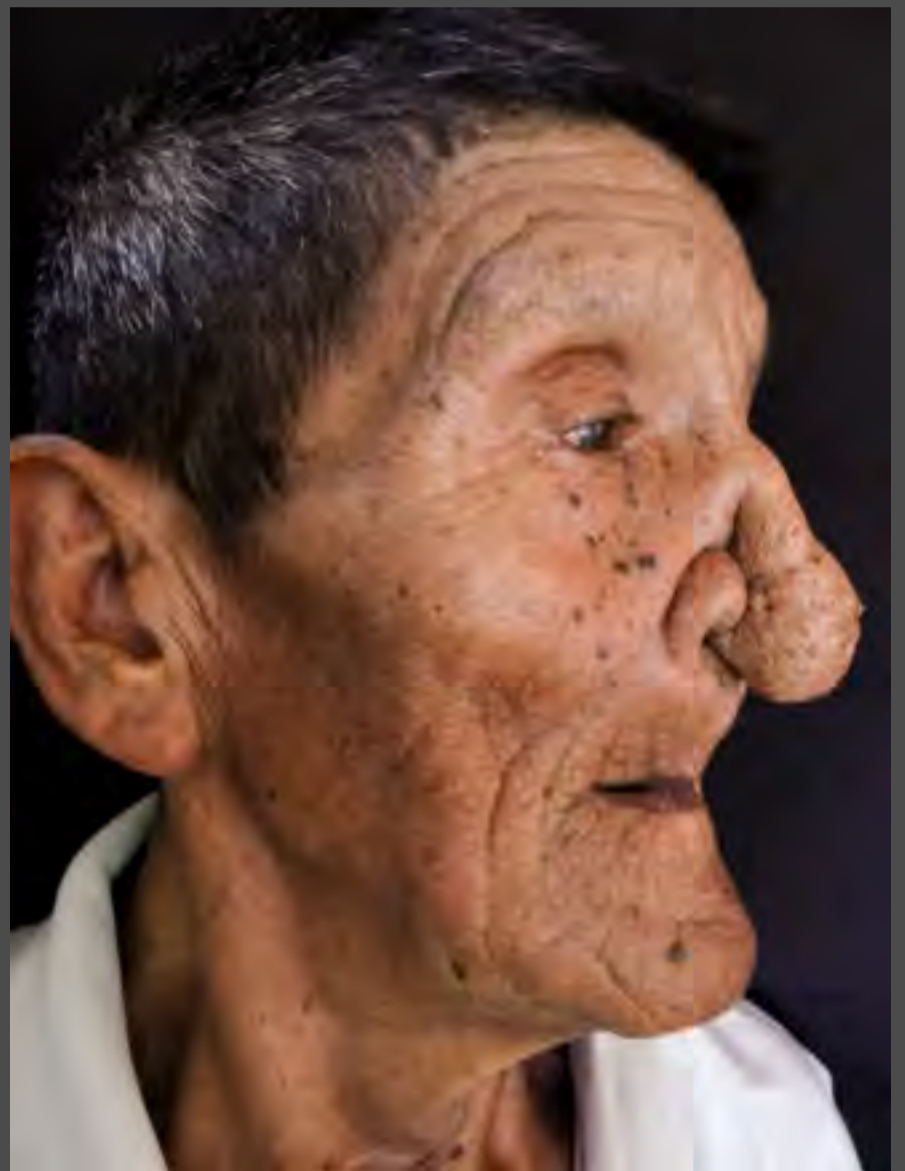
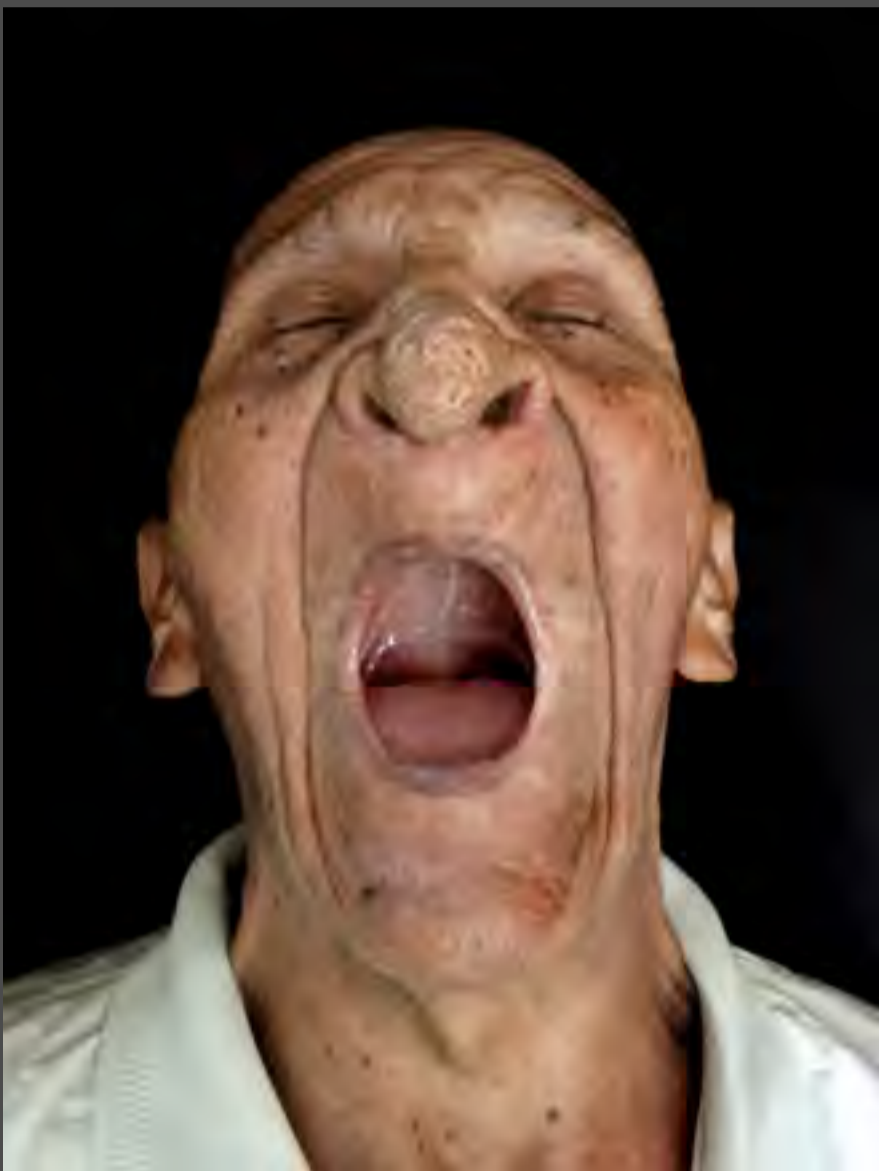
**Figures 4.72C and D.**  
Advanced granulomatous infiltration of the soft palate and improvement with treatment



**Figures 4.73A, B, C and D.**

Granulomatous infiltration with partial obstruction of the airway. A. Epiglottis. B. False vocal cords. C. Trachea. D. Involvement of the distal trachea and of the carina, continuing into the main bronchi.



**Figures 4.74A and B.**

Patient successfully treated with miltefosine; note the scarred, pink, fibrotic appearance of the palate and uninflamed nose, with a droopy tip and redundant skin as sequelae of the disease. The so-called *tapir nose* can be seen in the profile photo.

## Laboratory Diagnosis

Because identification of parasites on direct examination is possible in only 10% to 25% of cases, diagnosis of mucosal leishmaniasis should be done by histopathological study of nasal tissue, with observation of *Leishmania* spp. amastigotes, possible in fewer than 50% of cases, or of typical inflammatory infiltrate, or by demonstration of parasite DNA in mucosal lesion material.

Currently, non-invasive techniques with cytology brushes are used to obtain tissue samples, which are processed by reverse transcriptase polymerase chain reaction (RT-PCR), PCR, and RFLP (Restriction Fragment Length Polymorphism), or PCR and isothermal curves, methods with sensitivity and specificity above 95%.

Given that the disease occurs in rural areas where these specialized techniques are not available, most of the time the diagnosis is basically clinical, with a finding of ulcers, inflammatory signs, and presence of infiltrative granular lesions in the nasal or oral mucosa (palate or uvula), in a patient who has lived in areas of transmission and has a history of the skin disease or a lesion scar suggestive of cutaneous leishmaniasis. The intradermal skin testing does not confirm a diagnosis of active disease but does indicate an indirect proof of infection at some time in life. Serological examinations are not useful for diagnosing cutaneous or mucosal leishmaniasis and, as a result, they are not recommended.



## Treatment

In 2010, the World Health Organization (WHO) Expert Committee on the Control of Leishmaniasis concluded that no universal treatment exists for leishmaniasis, which means that the drug, dosage and length of treatment should be prescribed for each situation, based on the infective strain (if known), extent of the disease, and comorbidities.

The Pan American Health Organization (PAHO) published similar conclusions in 2013, as did the Infectious Diseases Society of America (IDSA) and the American Society of Tropical Medicine and Hygiene in 2016. Scientific evidence has demonstrated that it is not advisable to generalize treatment recommendations for mucosal leishmaniasis in countries in the Region of the Americas because:

1. There are variations in the response to strains from the same species depending on geographical region;
2. There is evidence of different cure rates with pentavalent antimonials according to the severity of mucosal disease; and
3. Frequency and severity of mucosal leishmaniasis may be greater in places where *L. (V.) panamensis* and *L. (V.) braziliensis* strains are infected by LRV1.

The objective of treatment is to reduce morbidity and prevent mortality. There is no spontaneous cure for mucosal leishmaniasis, which means that treatment must be required in all cases. Considering that spread of the mucosal disease usually depends on the passage of time, leishmaniasis treatment should be administered early on, because the likelihood of a cure will be greater.

The first-line treatment is still pentavalent antimonials ( $\text{Sb}^{5+}$ ), in daily doses of 20 mg of  $\text{Sb}^{5+}/\text{kg}$  for 30 consecutive days. Patients with mucosal leishmaniasis should be treated under direct medical supervision, preferably hospitalized and, if so, use of the complete dose can make the difference between cure and treatment failure and, if side effects do occur, they can be detected early and addressed early.

In the Region of the Americas, the average cure rate with pentavalent antimony ranges from 50% to 70%, depending on the severity of the disease and the *Leishmania* species. Frequency of treatment failure is greater in *L. (V.) braziliensis* cases. The exception for the use of pentavalent antimonials (meglumine antimoniate or sodium stibogluconate) are patients with severe mucosal leishmaniasis, since the cure rate with these drugs is less than 20%, or in patients coinfecting with human immunodeficiency virus (HIV). In these patients, the treatment of choice is amphotericin B deoxycholate or liposomal amphotericin B.

The second-line drugs for mucosal leishmaniasis are amphotericin B deoxycholate and liposomal amphotericin B.

The daily dose of amphotericin B deoxycholate is from 0.7 to 1.0 mg/kg. The total cumulative dosage by kilogram of weight has not been clearly established. In our experience, the majority of patients with mild mucosal leishmaniasis are cured with a cumulative dosage of 25 mg/kg (around 2 g of amphotericin B deoxycholate in 42 doses); however, patients with moderate to severe lesions with involvement of the trachea and bronchi require higher doses. Bronchoscopy makes it possible to evaluate the criteria for cure: absence of an active lesion and complete cicatrization.

Use of amphotericin B deoxycholate is limited due to frequent systemic toxicity (higher than 80%), especially renal (azotemia from glomerular damage and hypopotassemia from tubular damage) and cardiac (arrhythmia and auricular-ventricular blockages), which means that it should be administered in referral centers that have medical and clinical laboratory support (hematology; measurement of urea, creatinine, and serum electrolytes: sodium, potassium, chlorine, and magnesium) and electrocardiogram.

Administration of this drug usually requires hospitalization; however, outpatient treatment is possible, although it requires skilled medical and nursing personnel. Preventive alternatives have been developed that decrease glomerular (administration of a liter of 0.9% saline solution prior to infusion) and tubular (early magnesium and potassium replacement) damage, but there are no detailed guidelines to guide attending physicians in their management.

For liposomal amphotericin B, the proposed daily dose is 2 to 3 mg/kg until reaching a total cumulative dosage of 40 to 60 mg/kg; however, there is controversy about the daily dose and treatment time. Liposomal amphotericin B efficacy is similar to that of amphotericin B deoxycholate; what varies significantly is toxicity, which is lower with the liposomal form (increase in blood creatinine). Liposomal amphotericin B is expensive in the private sector; however, as a result of an agreement between WHO and the supplier, the countries of the Region can now acquire the drug at a subsidized price through the PAHO Strategic Fund to treat mucosal leishmaniasis cases in their public services.





Another therapeutic alternative is the combination of pentavalent antimonials (20 mg daily of Sb<sup>5+</sup>/kg, intravenously or intramuscularly for 30 consecutive days) and pentoxifylline (400 mg, oral, three times a day for 30 days). This therapeutic regimen increases the rate of remission by 10 to 12 points, reduces healing time, and cures resistant cases.

Miltefosine is an oral drug (daily dosage from 1.5 to 2.5 mg/kg for 28 days; maximum dosage of 150 mg per day) that proved to be effective for mucosal leishmaniasis in the Plurinational State of Bolivia, with a good safety profile; however, its recommendation for the Region is weak due to the lack of other studies in the Region of the Americas. The daily dosage of pentamidine isethionate is from 3-4 mg/kg for 7-10 doses on alternate days. Its effectiveness against *L. (V.) braziliensis* is over 50% and it is used when other therapeutic alternatives have failed.



## Follow-up

Clinical monitoring should be done on days 45, 90, and 180 to evaluate remission, persistence, relapse, or recurrence of lesions, and follow up should be done every six months for at least two years. At present, there are no useful laboratory tests for follow-up.

Mucosal leishmaniasis is a disease that is difficult to manage in comparison with cutaneous leishmaniasis and, in general, therapeutic response is variable; however, clinical cure is more effective when it is diagnosed early and treated appropriately.

The problem that has not still been solved is the sequelae (especially in severe cases) of fibrosis and tissue destruction in the upper and lower respiratory tract, which influence mortality.

Treatment of patients should include, in addition to leishmaniasis drugs, treatment of intercurrent infections, therapy and rehabilitation for lost function, reconstruction of physical defects, and psychological therapy and emotional support, since this is a disease that affects the patient physically, emotionally, socially, and also affects their families. Mucosal leishmaniasis mortality is lower than 1% but this has been studied very little and is usually underreported.

# Differential Diagnosis



Jaime Soto, Carlos Arturo Hernández, Ana  
Nilce Silveira Maia-Elkhoury, Gerzaín  
Rodríguez, Clemencia Ovalle-Bracho, Claudia  
Arenas and Carolina Camargo

As it is not easy to find the parasite in mucosal lesions and immunological tests are not specific, it is necessary to rely on epidemiological information (time spent in areas where there is transmission), make a careful search for scars suggestive of the skin lesion, and conduct a careful, directed case history. Patients frequently do not recall having had skin lesions. A thorough clinical examination is crucial to the diagnosis and to defining the severity of involvement or to finding signs that suggest other diseases.

The following is a brief description of diseases that should be regarded as differential diagnosis of mucosal leishmaniasis (*Table 4.4*).

Table 4.4. Differential diagnosis of mucosal leishmaniasis (in order of frequency)

Infections	Tumors	Miscellaneous
<ul style="list-style-type: none"> <li>• Paracoccidioidomycosis</li> <li>• Leprosy</li> <li>• Tuberculosis</li> <li>• Histoplasmosis</li> <li>• Syphilis</li> <li>• Rhinoscleroma</li> <li>• Rhinosporidiosis</li> <li>• Rhinoentomophthoromycosis</li> <li>• Mucormycosis</li> </ul>	<ul style="list-style-type: none"> <li>• Basal cell carcinoma</li> <li>• Squamous cell carcinoma</li> <li>• Epidermoid carcinoma</li> <li>• Cutaneous nasal T cell lymphoma</li> </ul>	<ul style="list-style-type: none"> <li>• Banal perforation of nasal septum</li> <li>• Rhinophyma</li> <li>• Sarcoidosis</li> <li>• Cocaine use</li> <li>• Granulomatosis with polyangiitis (previously known as Wegener's granulomatosis)</li> </ul>

## Infections

***Paracoccidioidomycosis.*** This is the most common differential diagnosis, since they share territory and both primarily affect middle-age men, with involvement of the upper respiratory tract, although paracoccidioidomycosis lesions develop faster—in weeks or months—in comparison with the years that leishmaniasis takes (*Figures 4.75 a 4.78*).

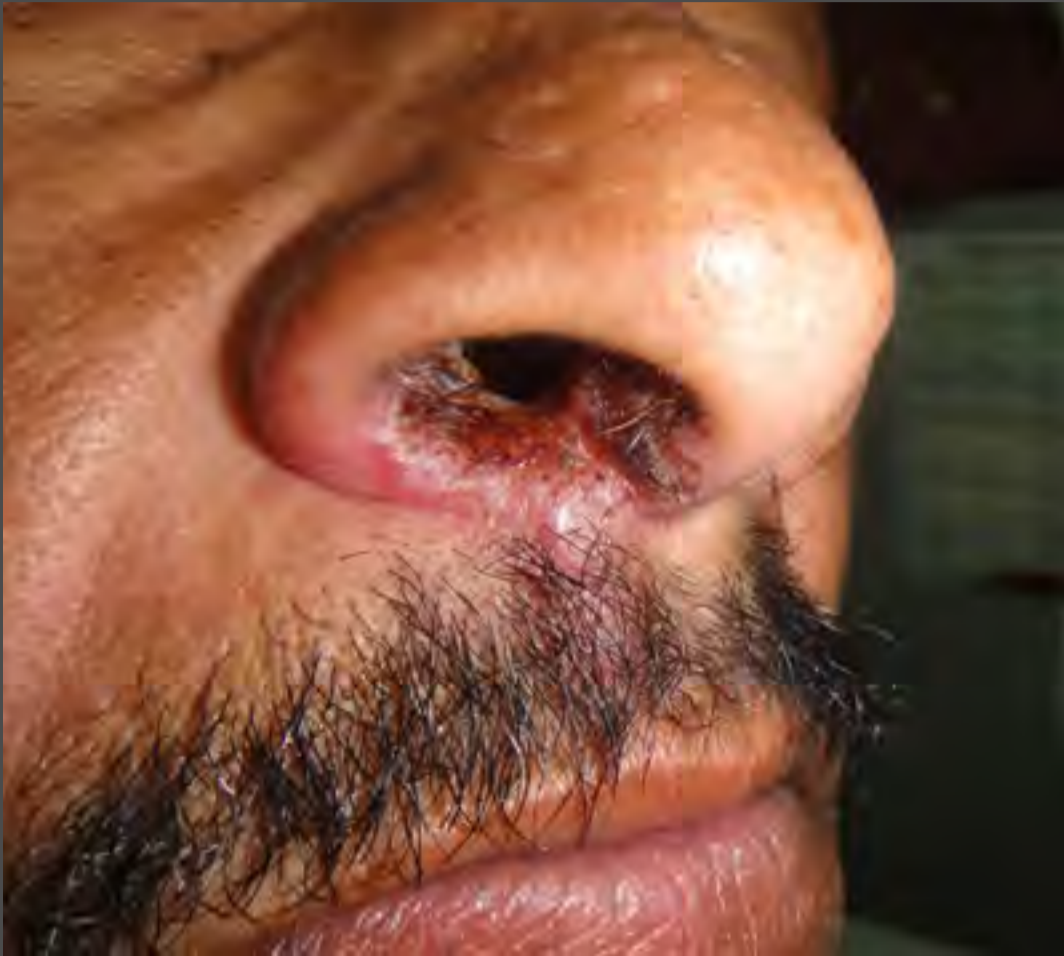*Table 4.5* presents a summary of the clinical differences.

Table 4.5. Clinical differences between paracoccidioidomycosis and mucosal leishmaniasis

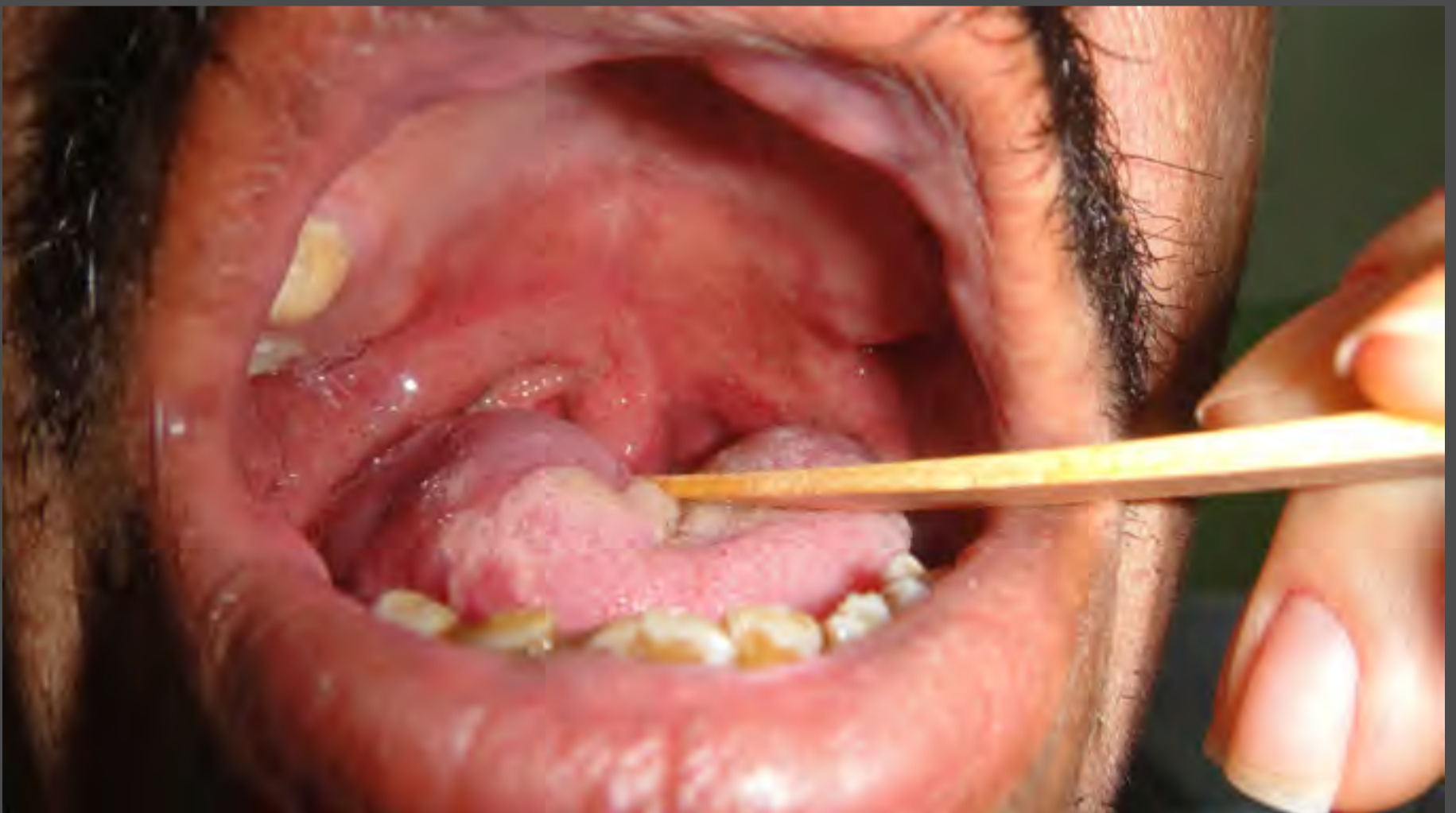	Paracoccidioidomycosis	Mucosal Leishmaniasis
Development	Rapid, weeks or months	Slow, months or years
Effect on overall health	Considerable and early	Occasional and late
Weight loss	Considerable and early	Moderate and late
Sex	9 men to 1 woman	6 men to 1 woman
Involvement of nasal mucosa	Rare	Very frequent
Nasal obstruction	Very rare	Very frequent
Involvement of skin on the nose	Very rare	Very frequent
Involvement of the uvula, soft palate pillars, and palate	Common	Common
Involvement of the gums and mucosa of the gums	Frequent	Very rare
Involvement of the tongue	Frequent	Very rare
Pain in the mouth	Very frequent	Very rare
Involvement of the larynx	Rare	Frequent
Dysphonia	Rare	Frequent



## Paracoccidioidomycosis



**Figures 4.75A and B.** Ulcerated, crusty, hyperkeratotic, and edematous plaques of the skin and mucosa of the upper lip, with spread to the rim of the choanas, tongue, and gums. There is infiltration of the oral cavity with mucosal inflammation at the edge between the soft and hard palate, ulcer at the base of the tongue, and infiltration of the nasal floor, with blood spots and crusts.





## Paracoccidioidomycosis

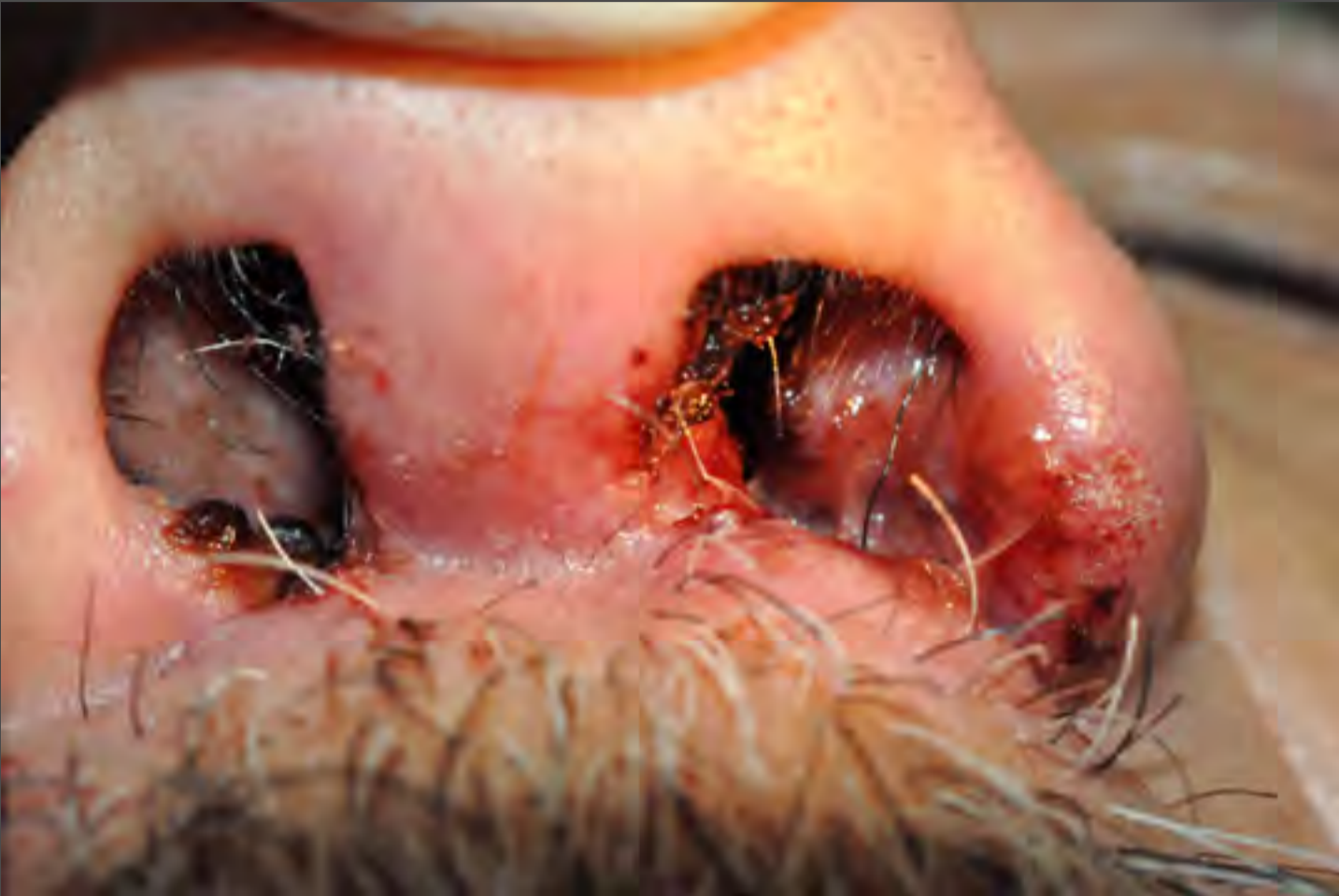
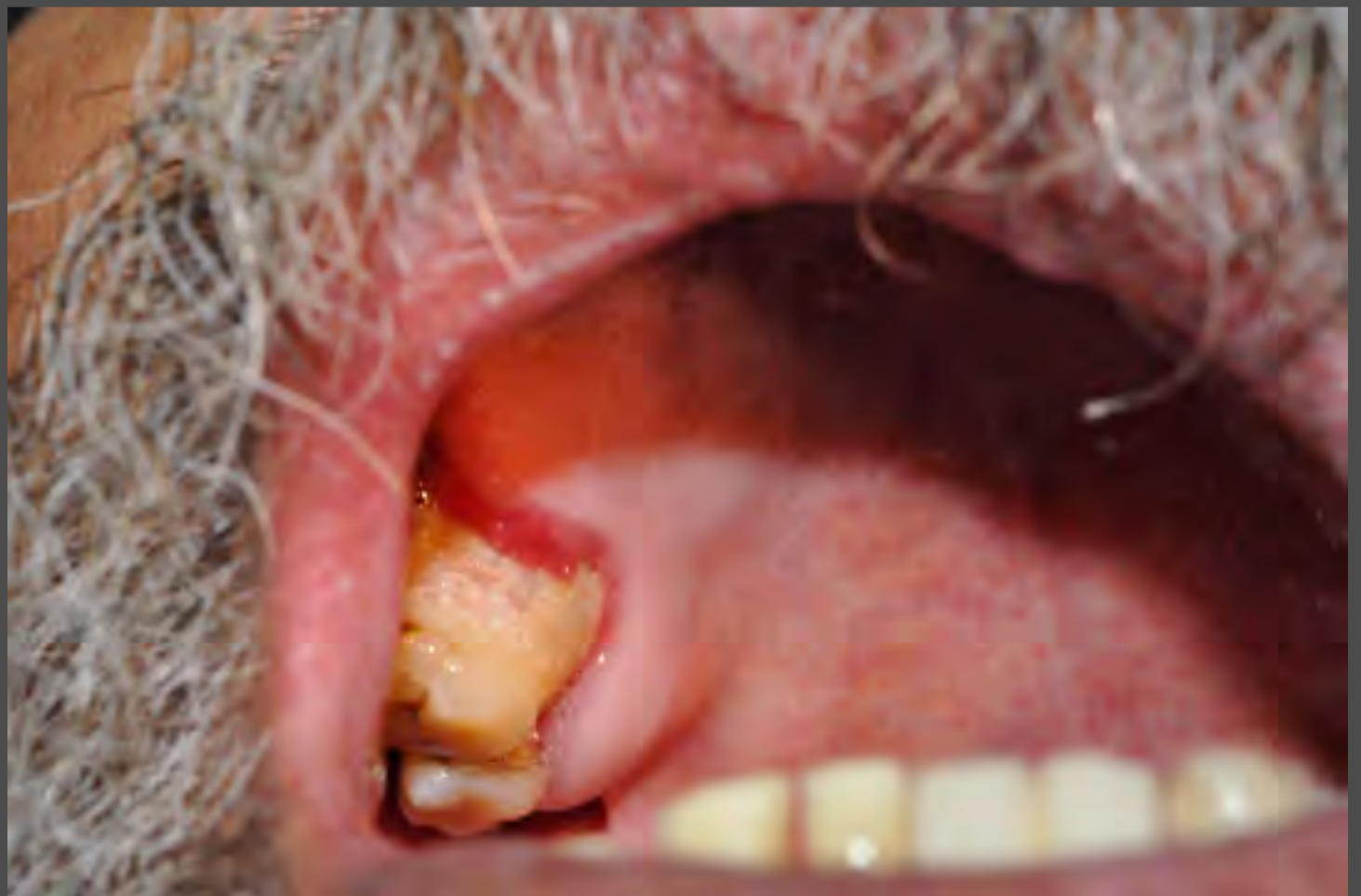
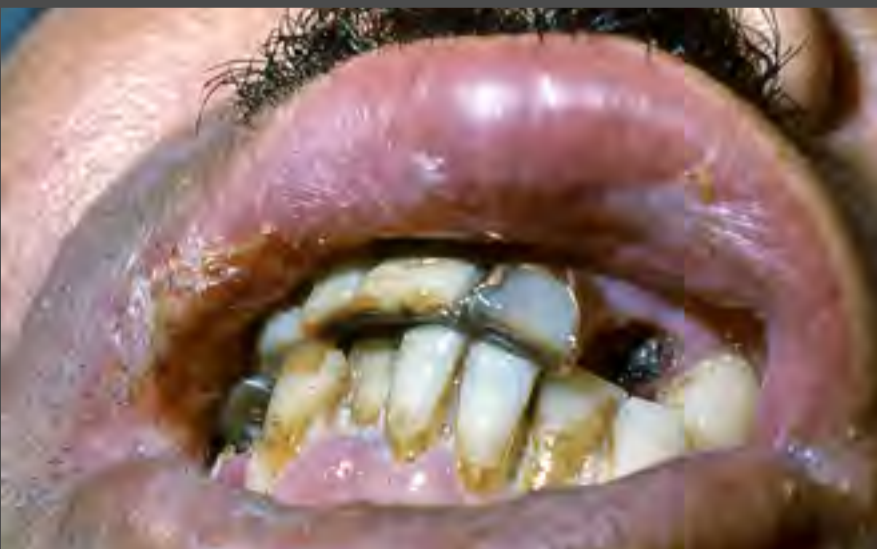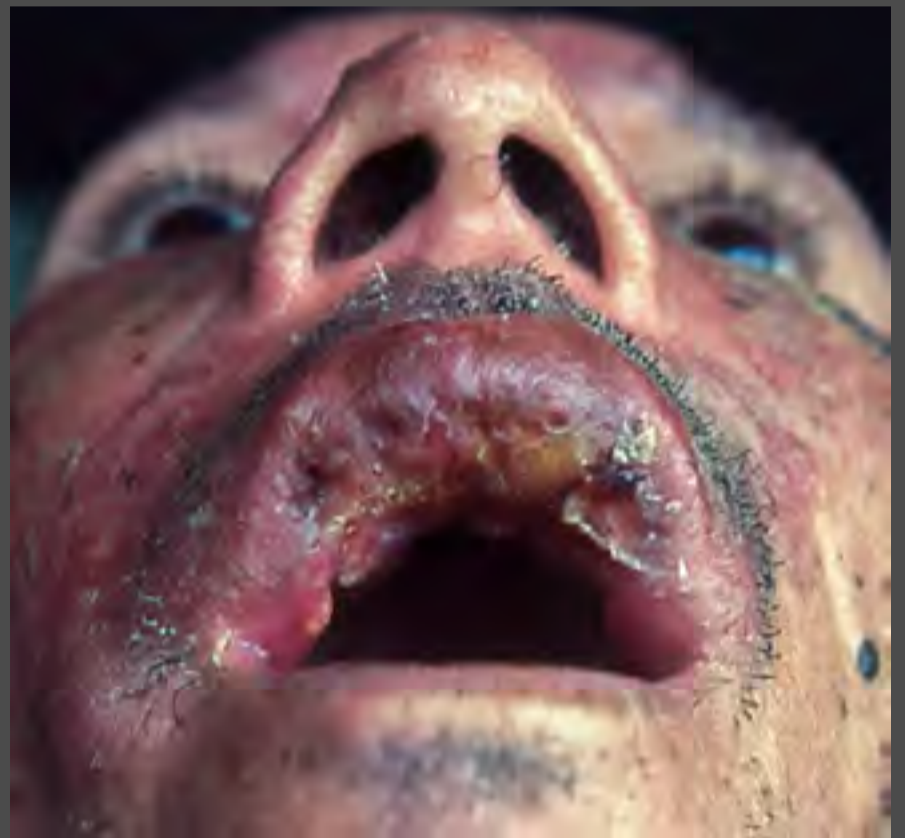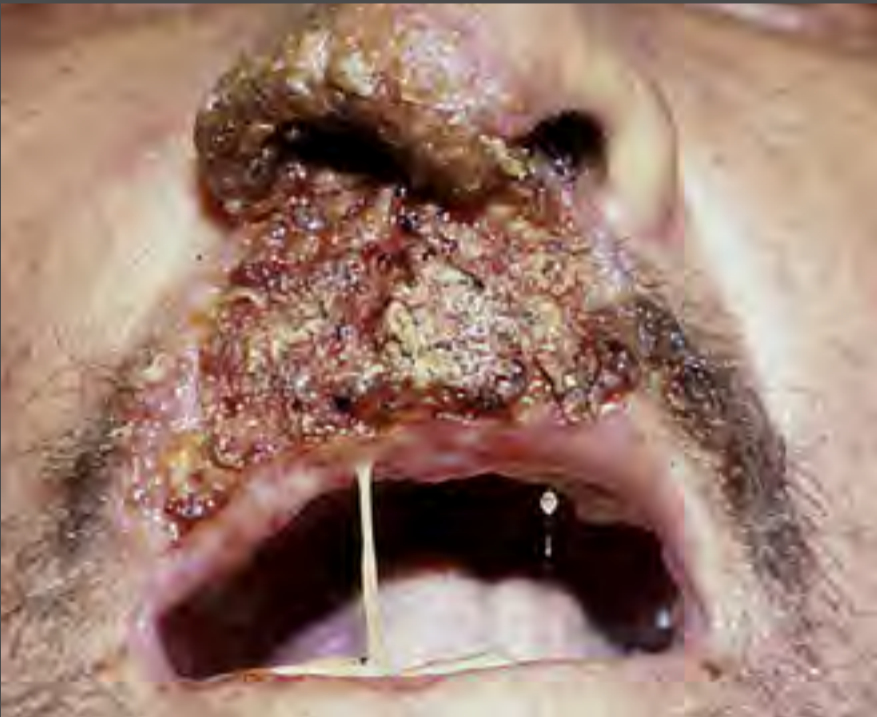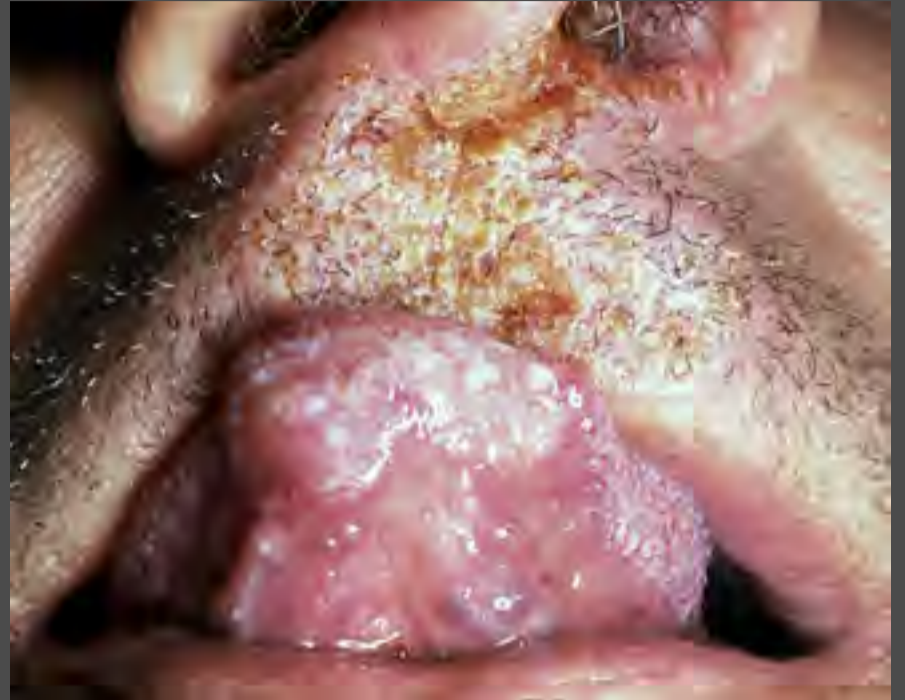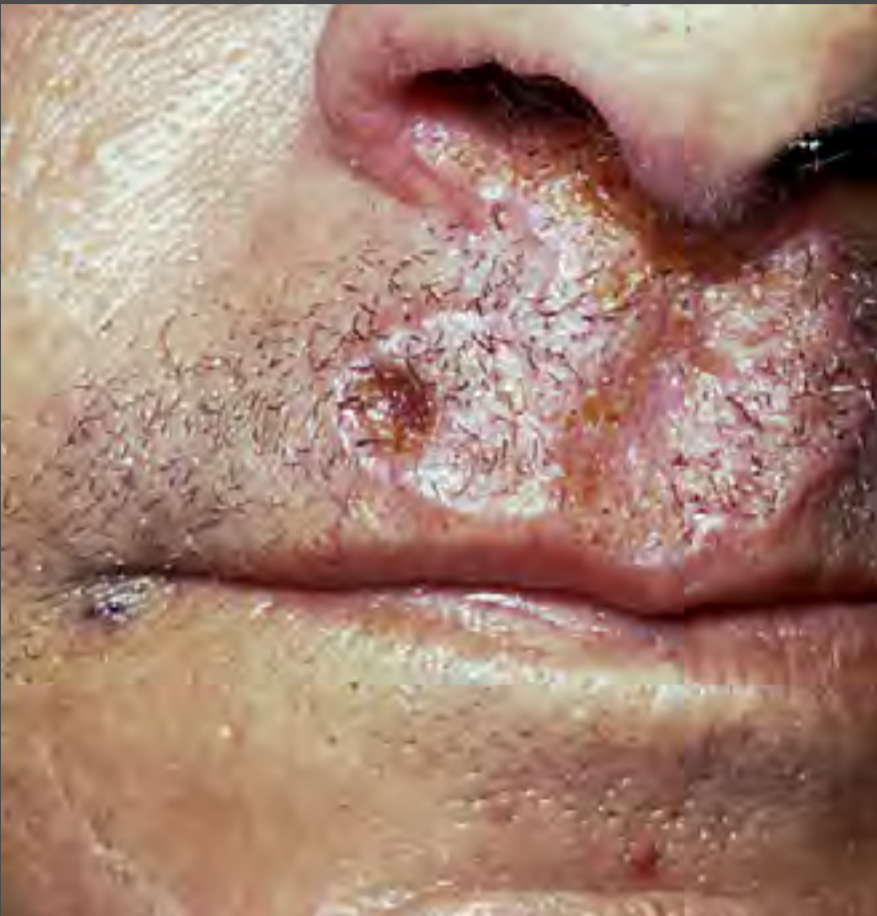Figure 4.75C.  
Involvement of  
the nasal mucosa

Figure 4.75D.  
Involvement of  
the hard palate  
and gums





## Paracoccidioidomycosis



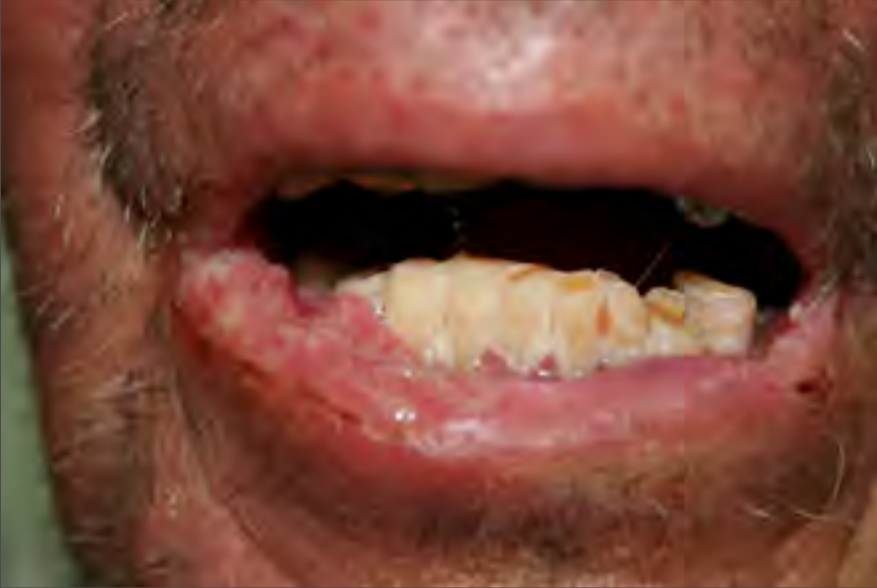Figures 4.75E, F, G, H e I.

Ulcerated, crusty, hyperkeratotic, and edematous plaques of the skin and mucosa of the upper lip, with spread to the rim of the choanas, tongue, and gums. There is infiltration of the oral cavity with mucosal inflammation at the edge between the soft and hard palate, ulcer at the base of the tongue, and infiltration of the nasal floor, with blood spots and crusts.

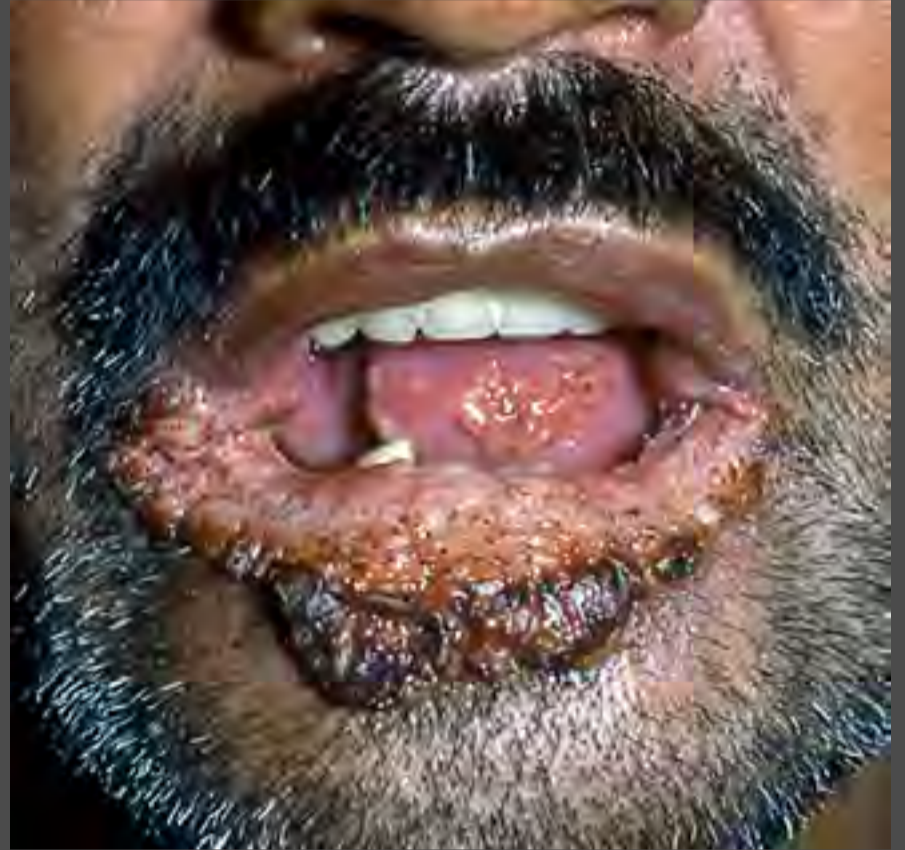



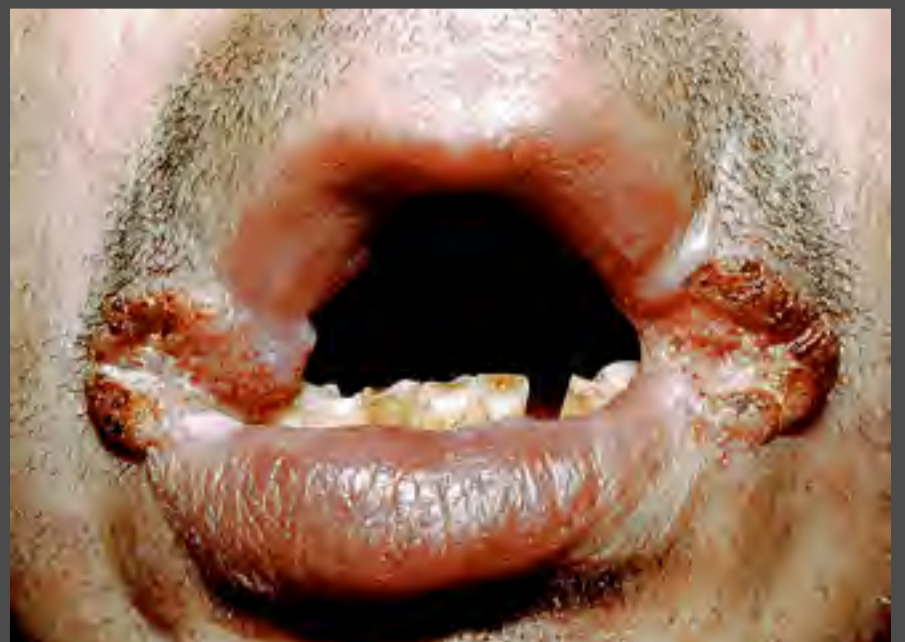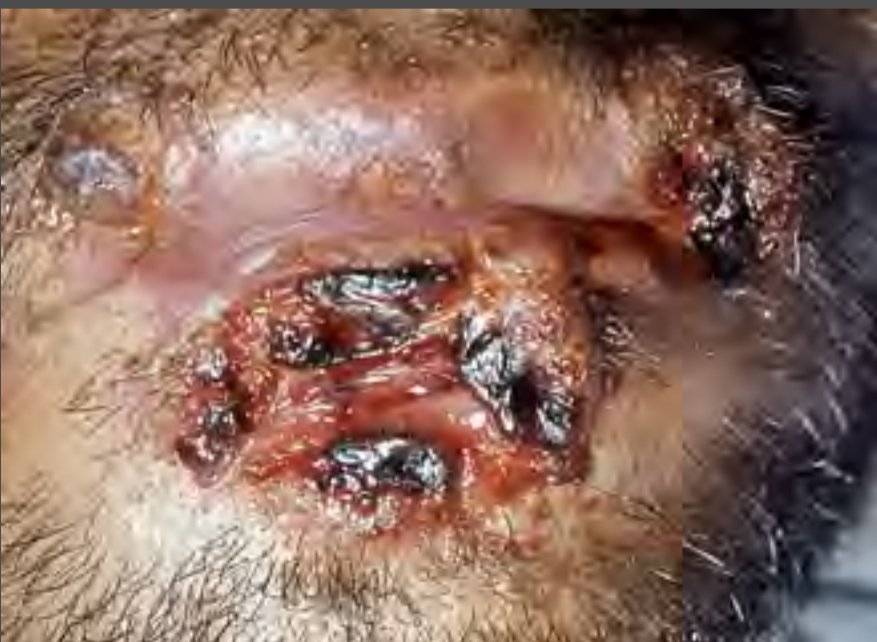## Paracoccidioidomycosis



**Figure 4.76A.**  
Infiltrated granular plaques on the lower lip

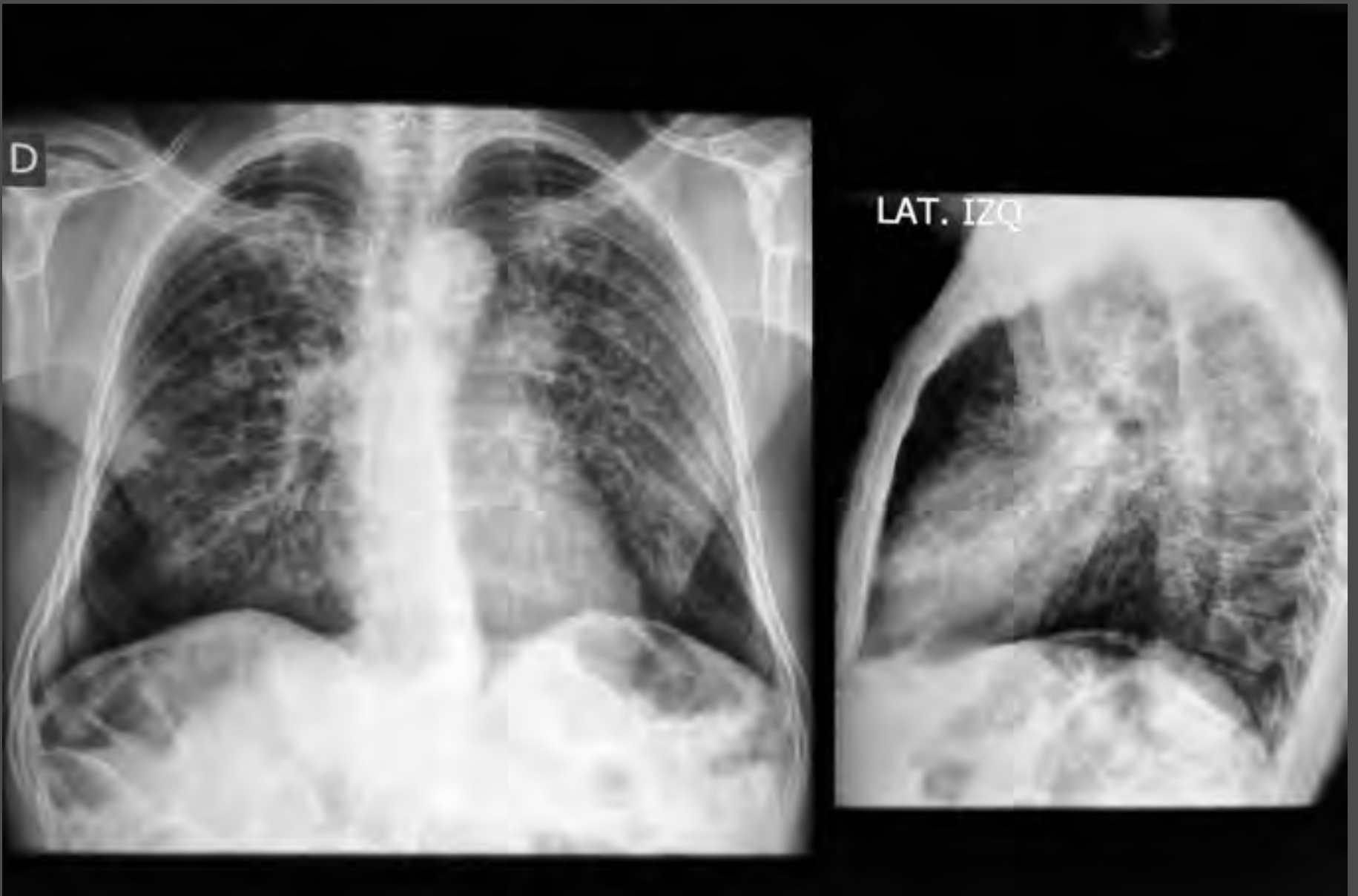


**Figures 4.77A, B and C.**  
Extensive ulcerated plaques involving the lower lip, tongue, and corners of the lips.



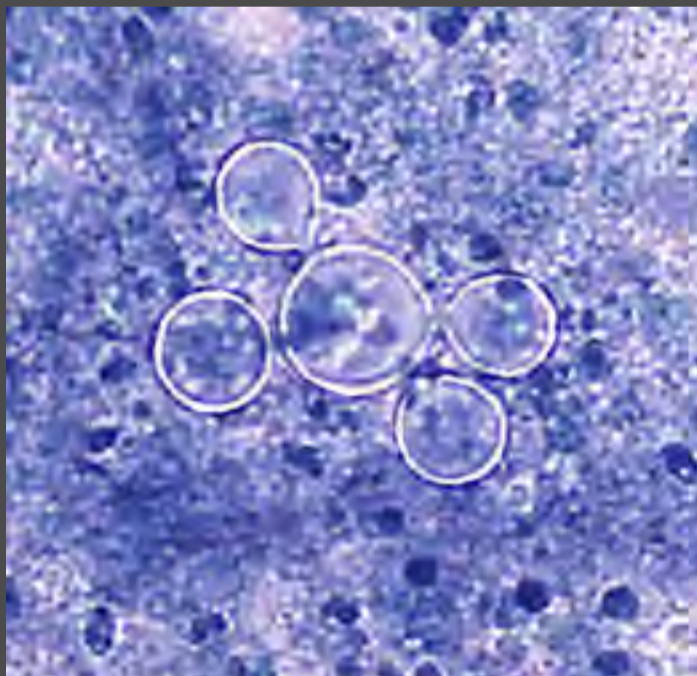


## Paracoccidioidomycosis



**Figure 4.78A.**

Chest x-ray. Bilateral and predominantly central reticulonodular infiltrate, with areas of greater confluence in the medial lobe



**Figure 4.78B.**

Direct smear of a lesion or sputum reveals yeasts (chlamydozoospores) with multiple buds attached by a small stalk to the central yeast, resembling a ship's wheel; Giemsa stain, 100X.

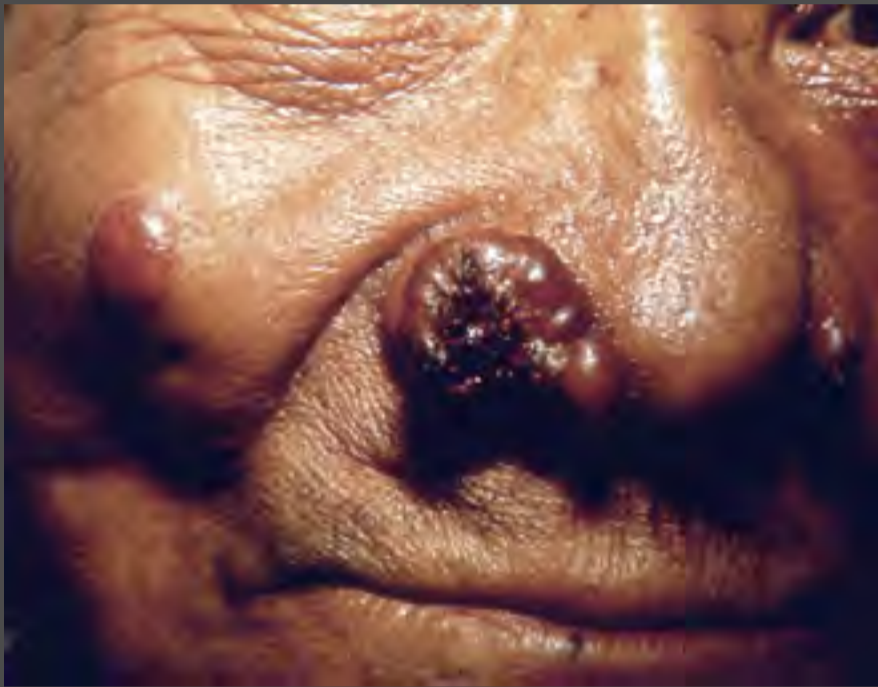

**Leprosy.** Leprosy patients may have nasal involvement with infiltrated plaques or nodules covered by pale mucosa in the anterior third of the septum and lower turbinate, which over time progress to destructive lesions with loss of the septum and considerable deformity. In the mouth, nodules (lepromas) or plaques and, exceptionally, ulcerations may occasionally be seen (*Figures 4.79 and 4.80*).

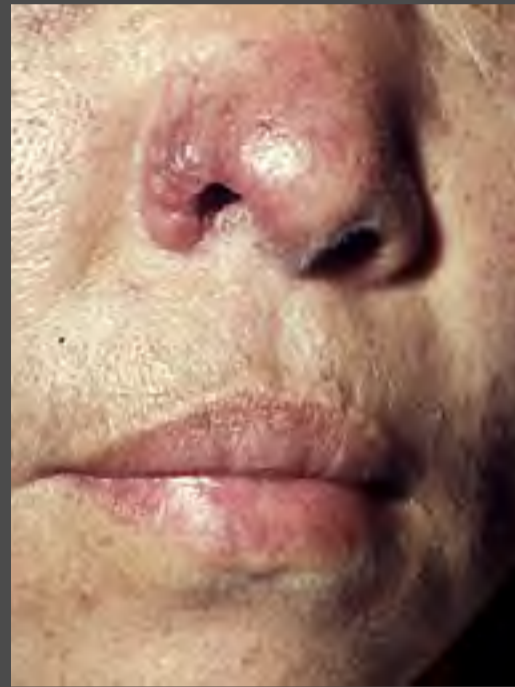Nevertheless, exclusive involvement of the mucous membranes is extraordinarily rare. The presence of other skin impairments helps make the differential diagnosis: diffuse infiltration of the face and ears, macules, nodules, tubercles, or hyperpigmented or erythematous plaques, loss of the tail of the eyebrows, sensitivity impairments, atrophy of some muscular groups, pigmented macules, and scars from previous episodes, and the presence of acid-fast bacilli in specimens of nasal mucus or lymph from skin lesions or the ears.



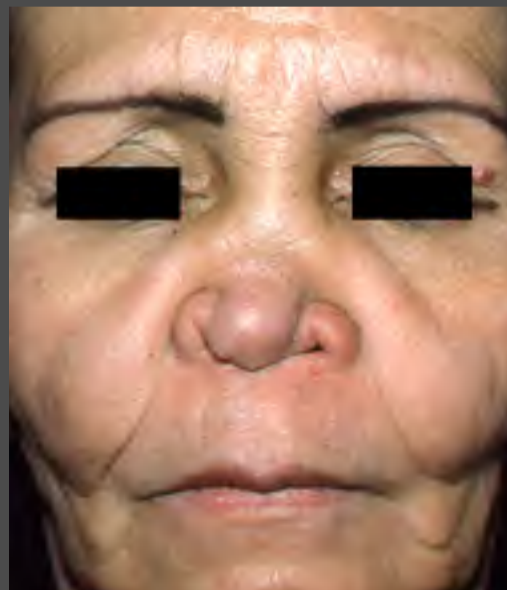## Lepromatous leprosy



**Figure 4.79A.**  
Woman with nasal tubercle and malar papule



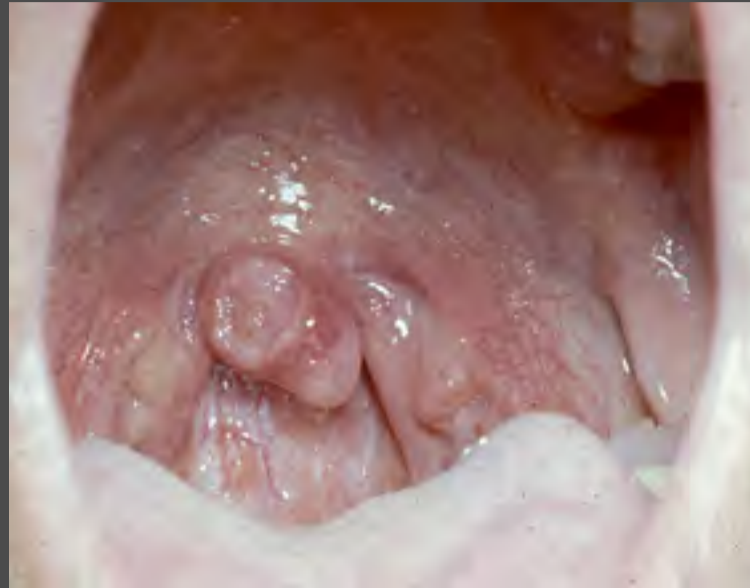**Figure 4.79B.**  
Woman with erythematous nasal plaque with infiltrated edges



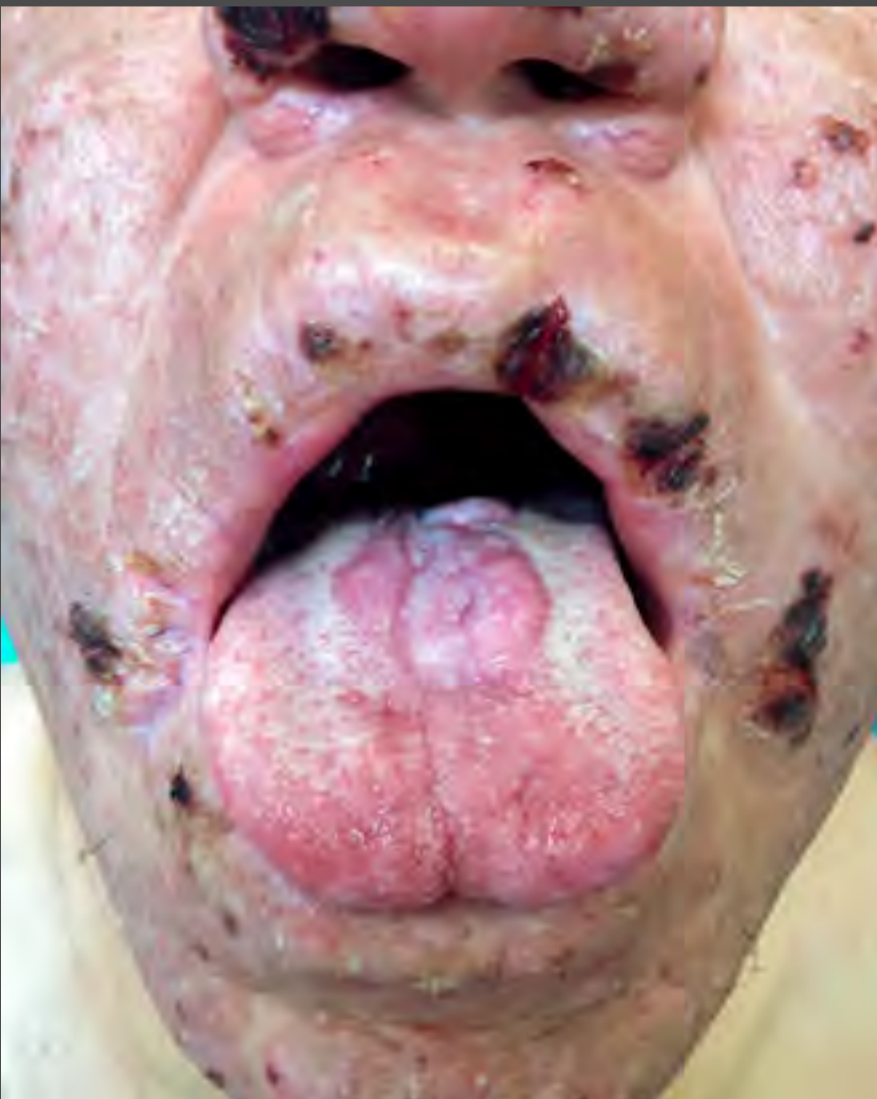**Figure 4.79C.**  
Saddle-shaped nose due to loss of the osteocartilaginous nasal structure



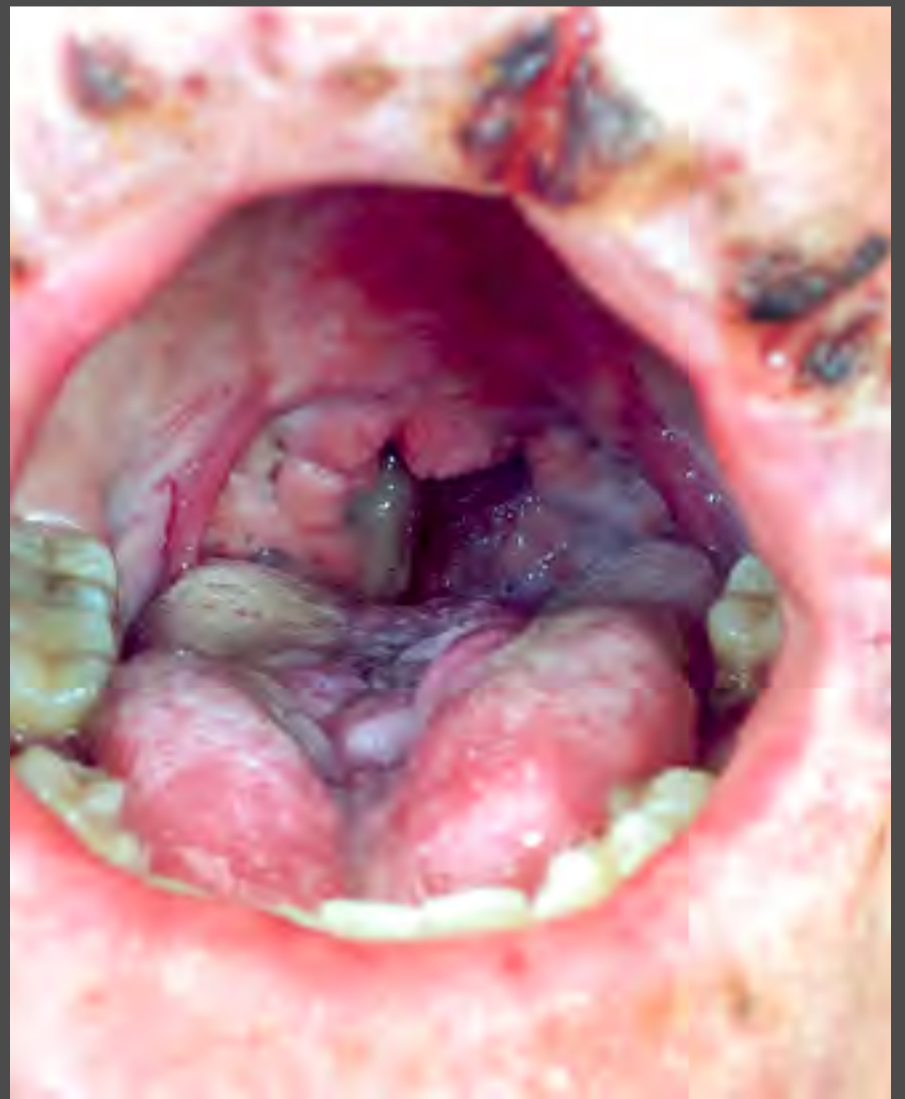## Lepromatous leprosy



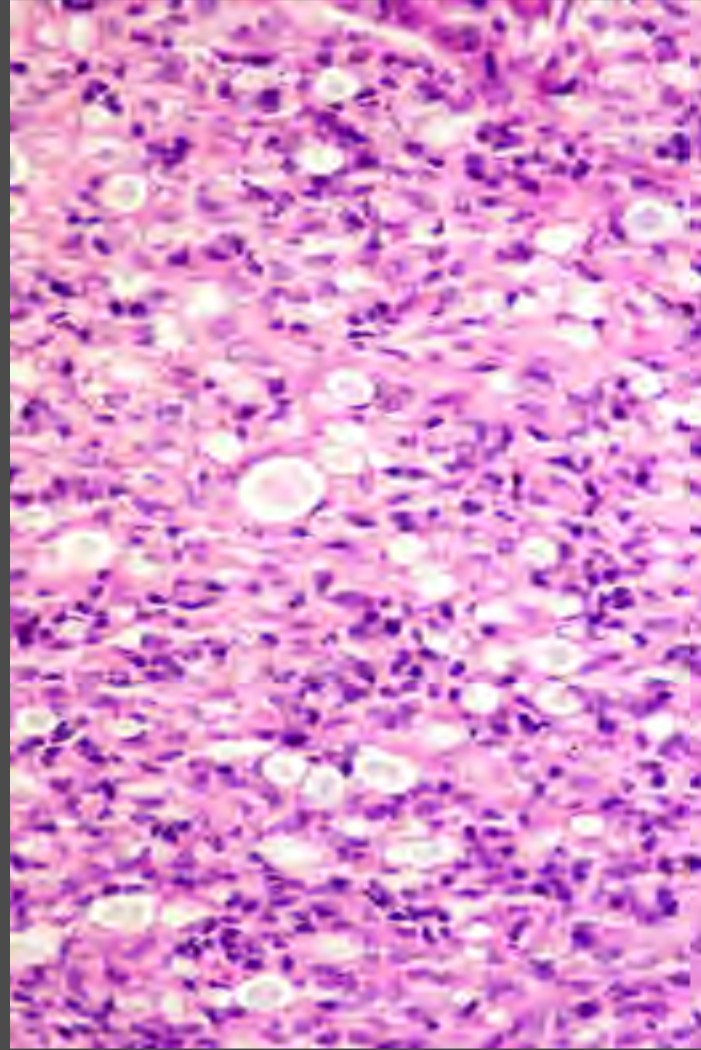
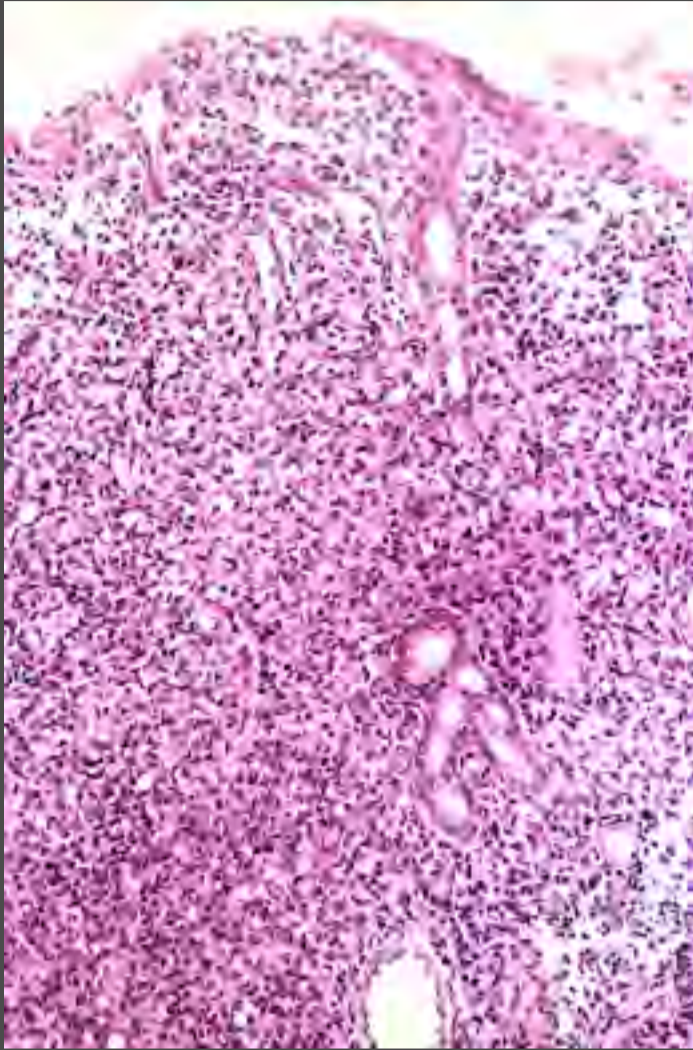
**Figure 4.79D.**  
Nodules and buccopharyngeal lepromas with amputation of the uvula



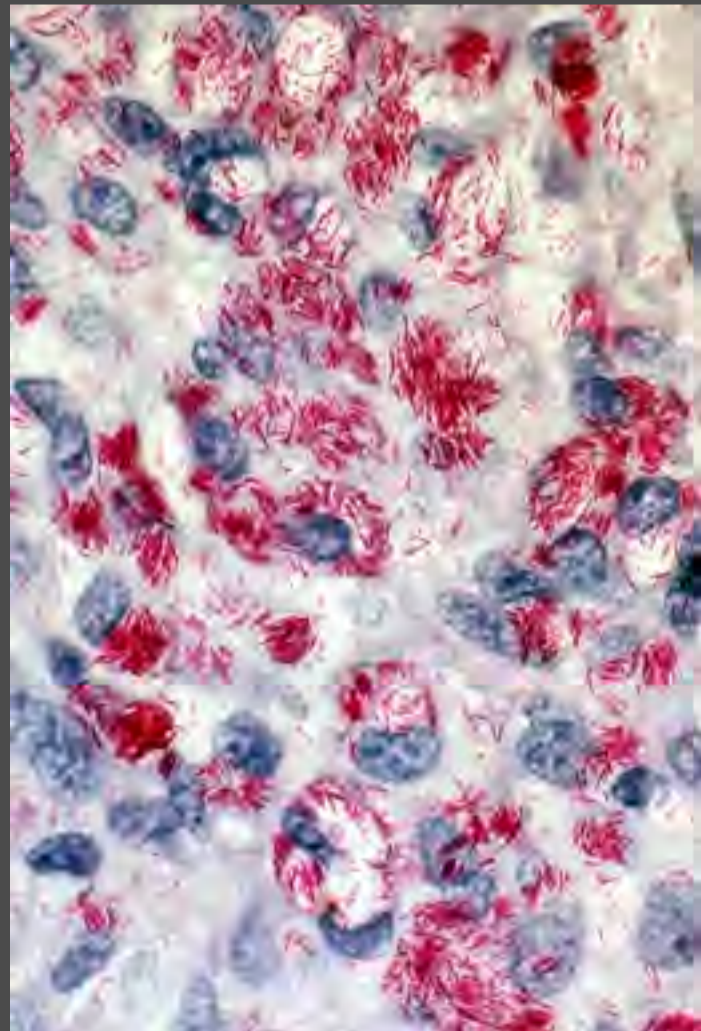
**Figure 4.79E.**  
Crusty, cracked plaques of the face, nose, and lips.  
The lingual nodule is a leproma.



**Figure 4.79F.**  
Lepromas of the pharyngeal tonsils with resorption of the uvula



**Figures 4.80A, B and C.**  
Nasal mucosa biopsies of suspected leishmaniasis. Findings: diffuse inflammation, rich in vacuolated macrophages (Virchow cells), containing abundant bacilli and globi. Hematoxylin and eosin, A, 16X, and B, 40X; C. Ziehl-Neelsen, 100X.



***Tuberculosis.*** The most frequent extrapulmonary location of tuberculosis is in the skin of the chest and neck, where it produces inflammatory adenopathies and suppurative areas (scrofuloderma), and in the upper respiratory tract, where it produces crusts and nasal discharge, oral ulcerations, or dysphonia (*Figures 4.81 and 4.82*).

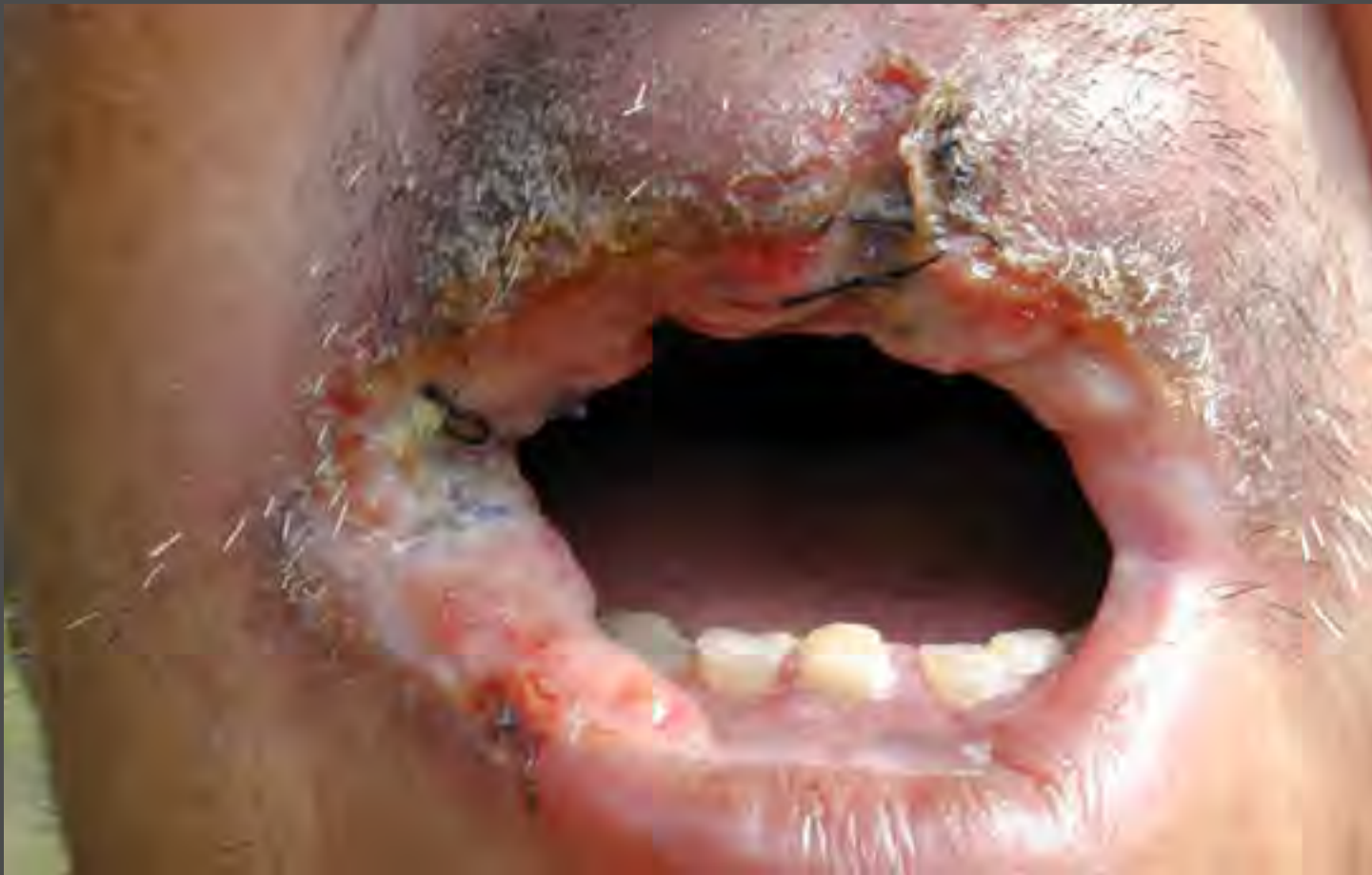A form of primary cutaneous tuberculosis is lupus vulgaris, which can affect the mid-facial area with papules and reddish-purplish plaques that are desquamative and crusty, infiltrative and destructive, leaving significant deformities and scars.

***Histoplasmosis.*** Usually associated with immunodeficiency, reactivation and spread of this deep mycosis occurs, which may be located in the nasal and oral mucosa causing inflammatory lesions that can be destructive. These patients present significant deterioration in their general condition and weight loss (*Figures 4.83 and 4.84*).

***Syphilis.*** Gummy infiltration of the nasal septum is a manifestation of tertiary syphilis and leads to loss of the septum, which is the reason why the nose takes on a characteristic saddle shape that can be confused with advanced, destructive lesions of mucosal leishmaniasis.

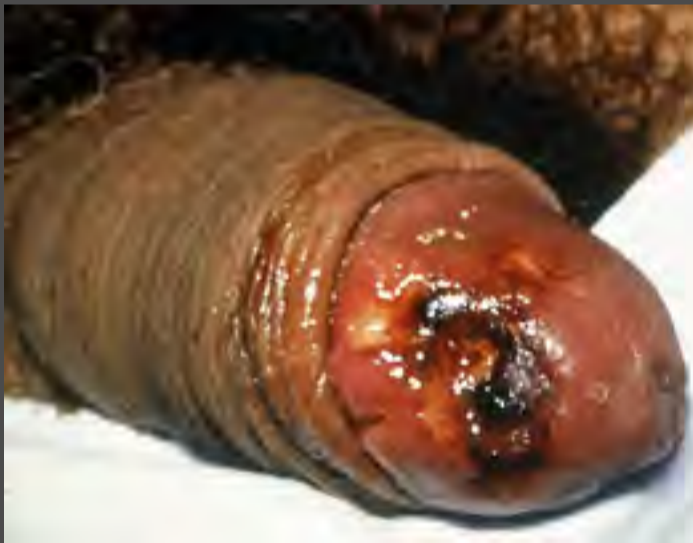

## Tuberculosis of the orifices



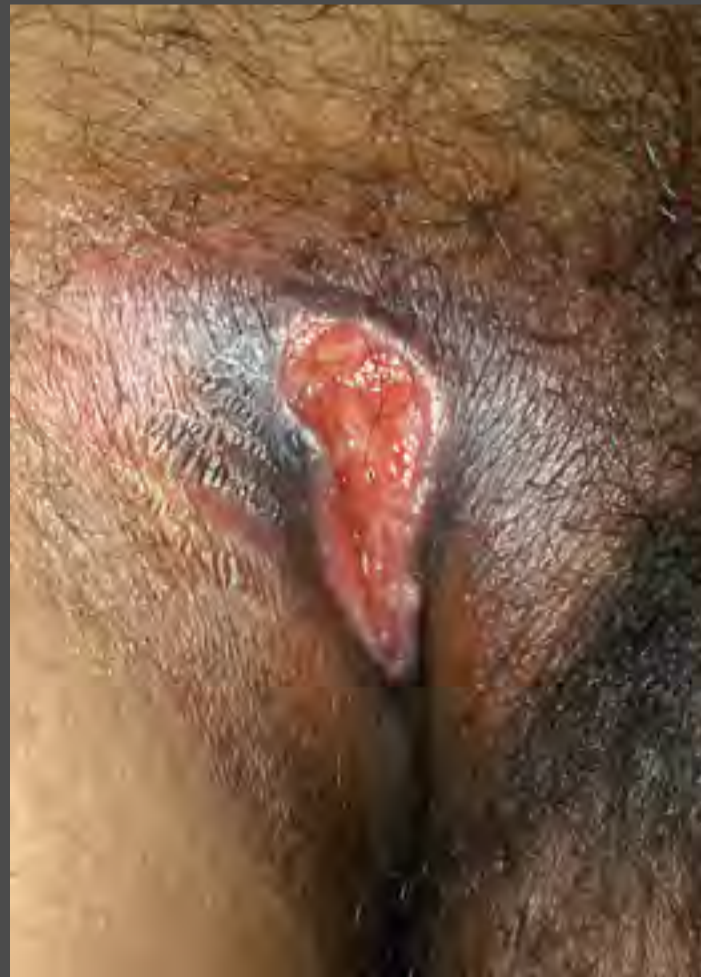**Figures 4.81A.**

Oral tuberculosis. Extensive lip damage, with ulceration, erosions, and crusts



**Figures 4.81B.**

Bacilli-rich tuberculous ulcer. Investigate tuberculous inoculation chancre or genitourinary tuberculosis.

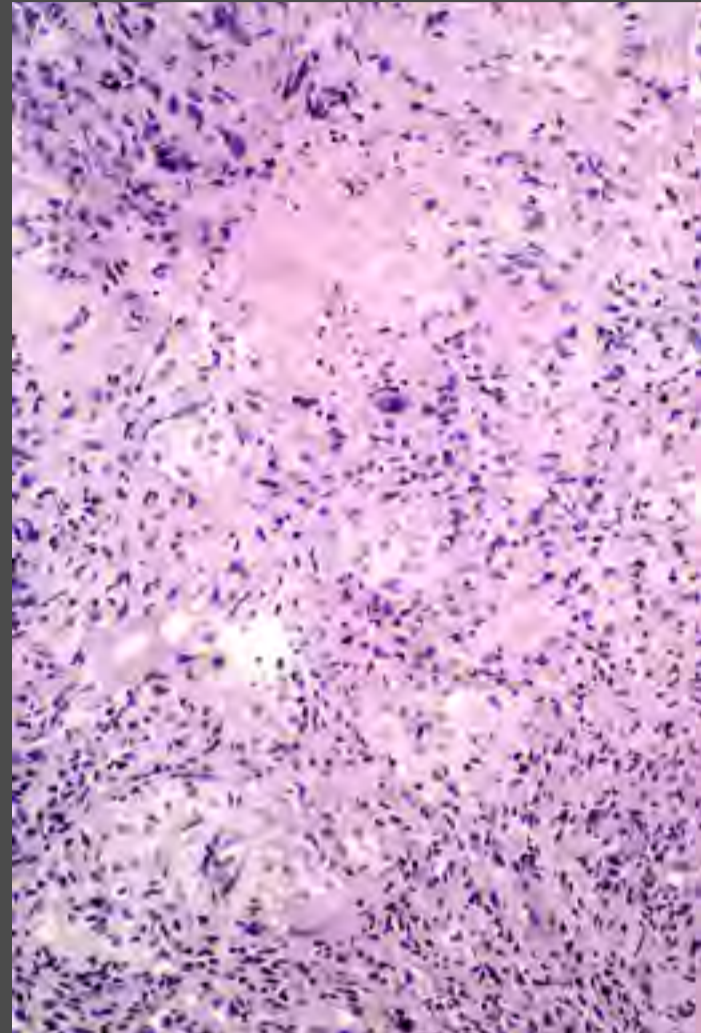
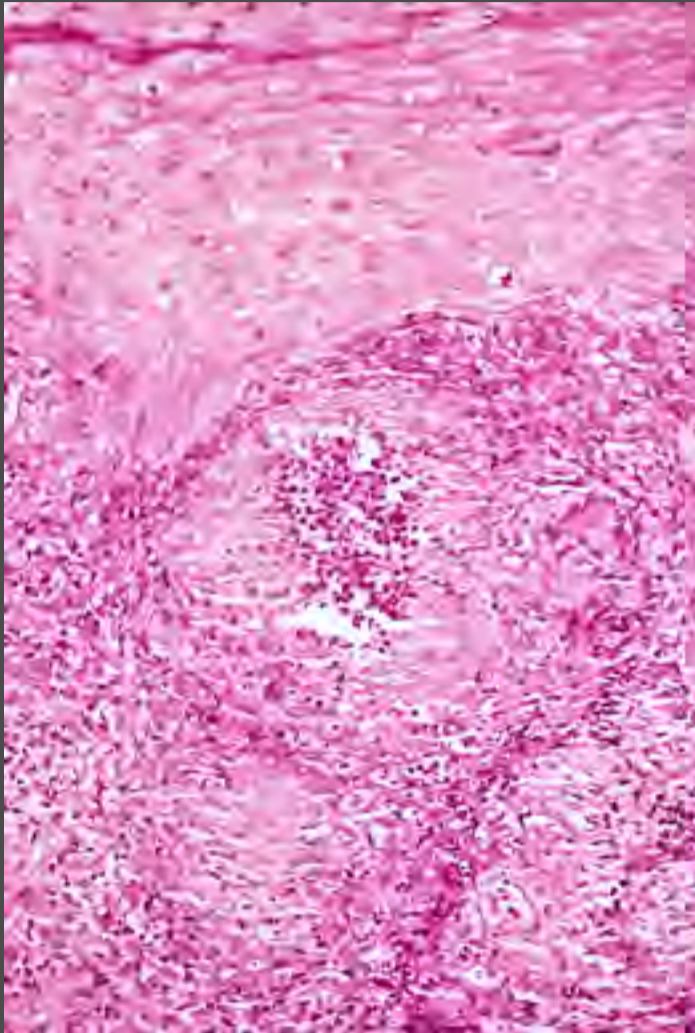


**Figures 4.81C.**

Perianal tuberculosis with concomitant intestinal and pulmonary involvement



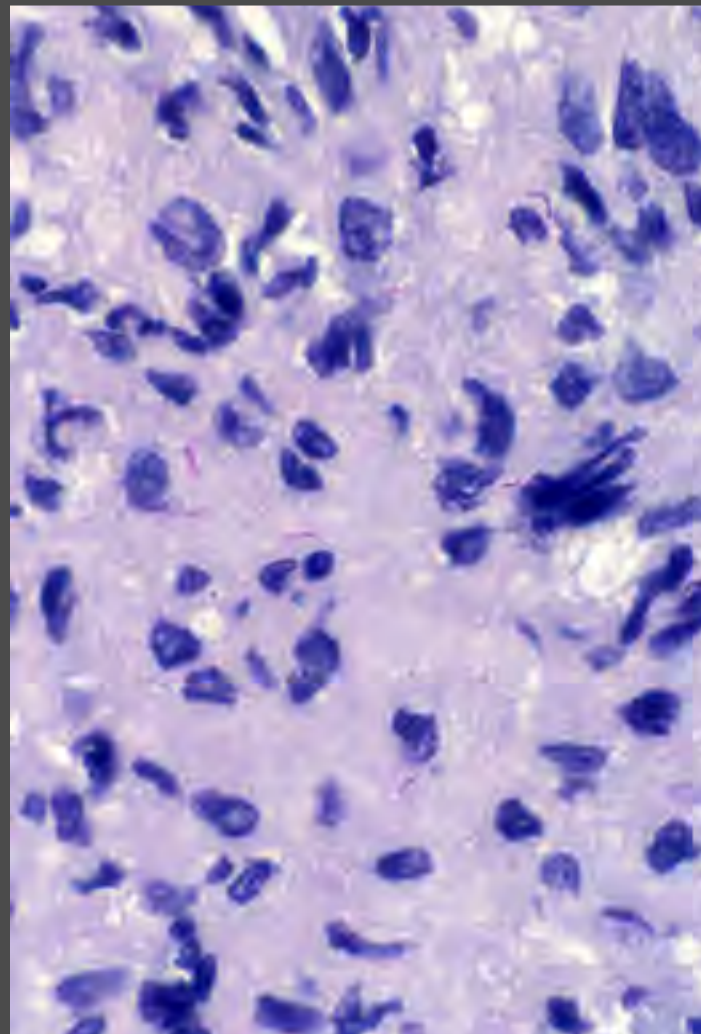
## Tuberculosis of the orifices



**Figures 4.82A.**  
Tongue. Note subepidermic tuberculoid granulomata, one with a central abscess; hematoxylin and eosin, 16X.

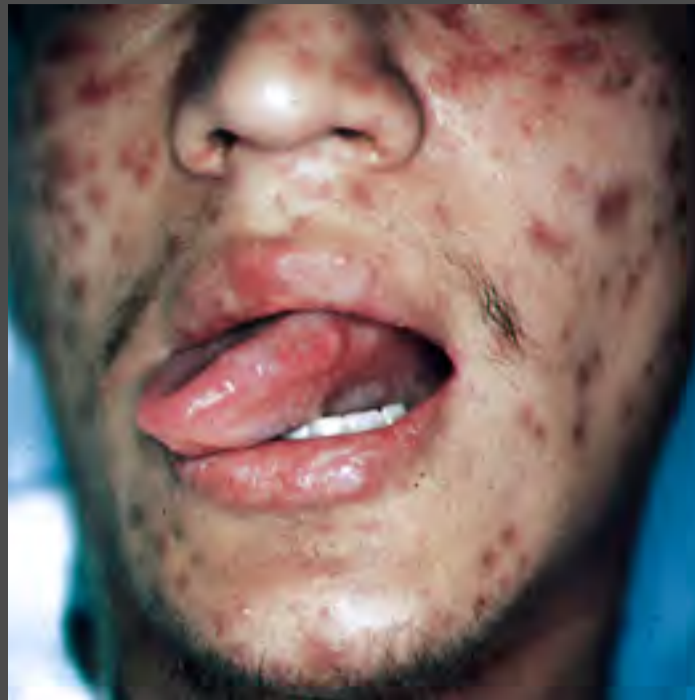**Figures 4.82B.**  
Tuberculoid granulomata with extensive central necrosis; hematoxylin and eosin, 16X.

**Figure 4.82C.**  
Abundant Koch's bacilli; Ziehl-Neelsen stain, 100X.

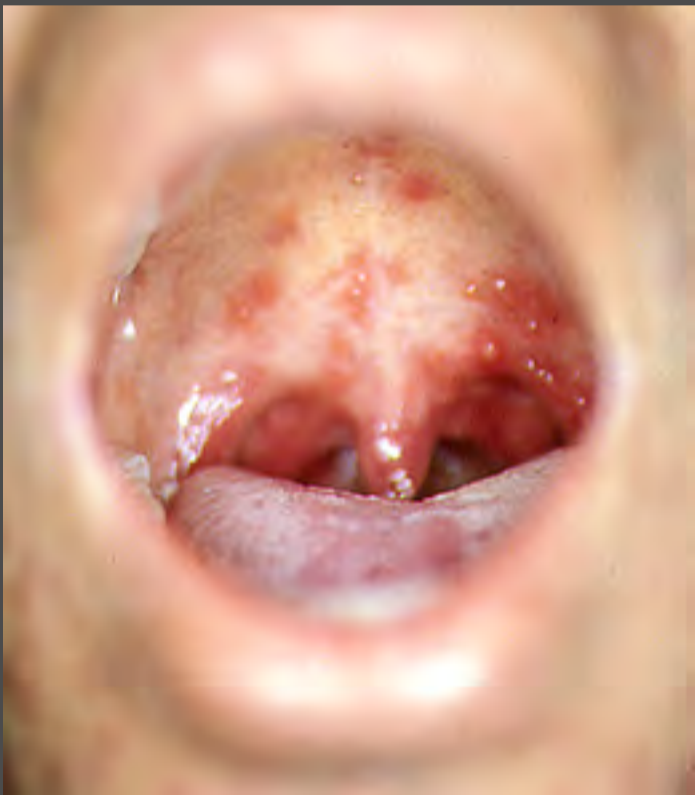
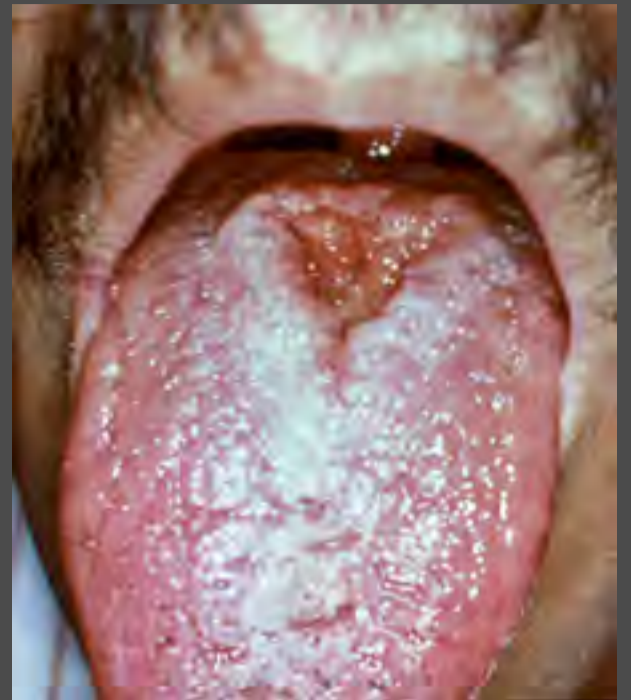
## AIDS-associated disseminated histoplasmosis

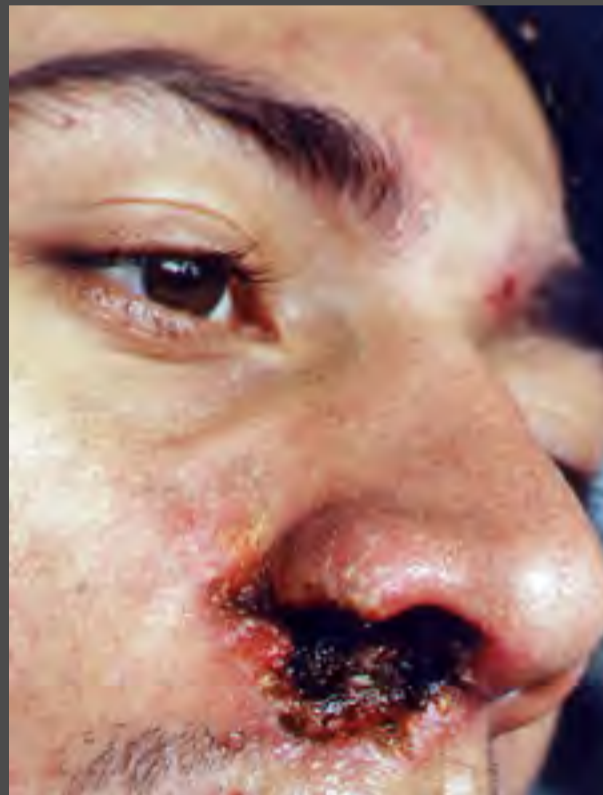**Figure 4.83A.**  
Papules on the face, lips,  
and tongue



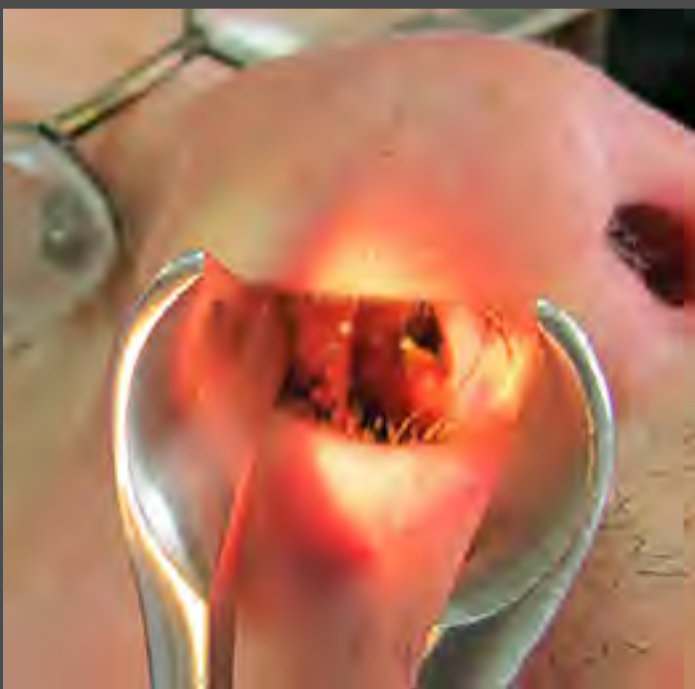**Figure 4.83B.**  
Lingual ulcer as only  
initial manifestation of  
this association



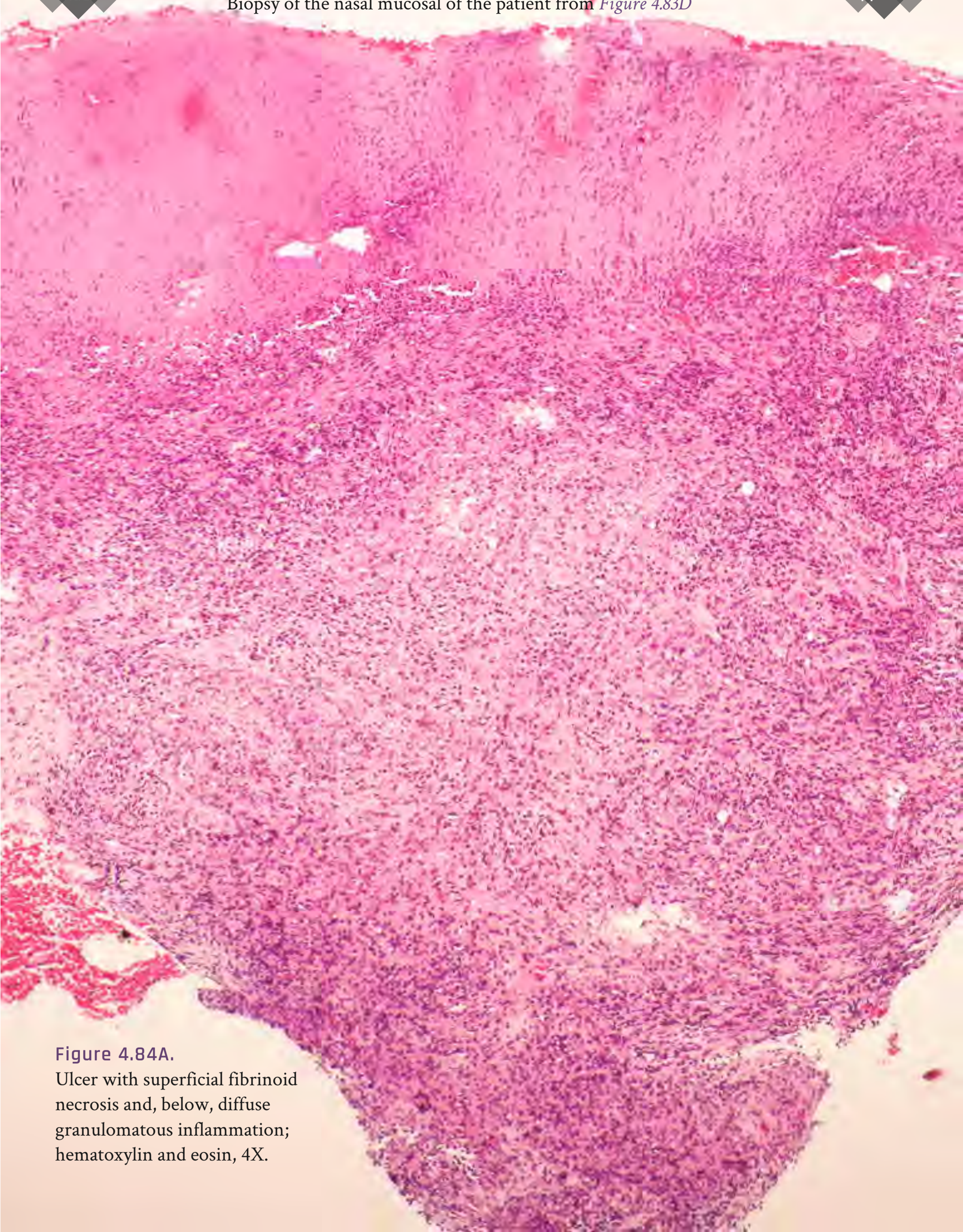
**Figure 4.83C.**  
Numerous papules of  
the palate and uvula



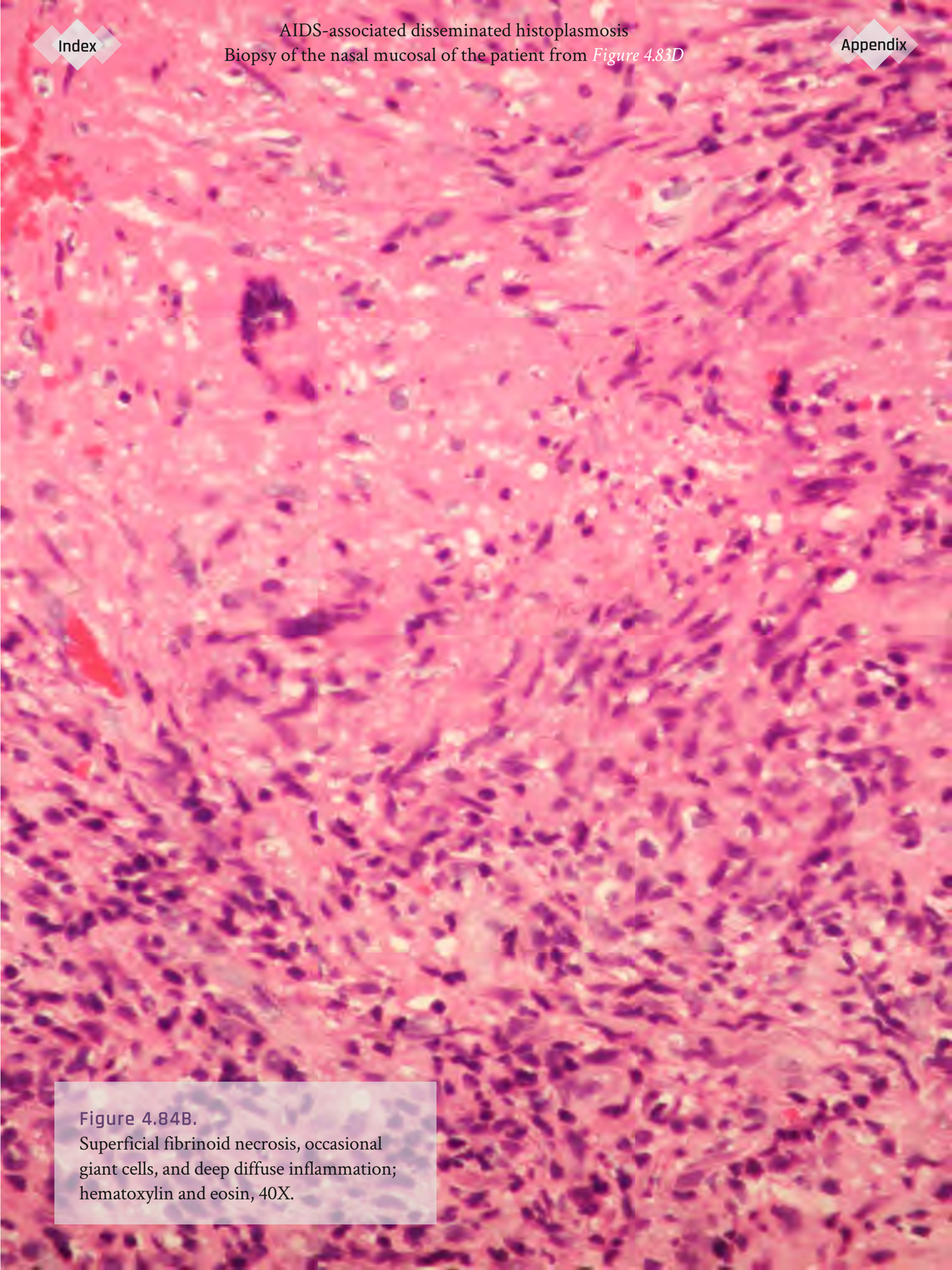
**Figure 4.83D.**  
Ulcer covered by  
sanguineous crust  
that involves the nasal  
ridge and lower part  
of the nasal mucosa.  
Erythematous papules  
of the eyebrows and  
forehead. The initial  
clinical diagnosis  
was mucocutaneous  
leishmaniasis.



**Figure 4.83E.**  
Nasal perforation as  
initial manifestation  
of AIDS-associated  
histoplasmosis



**Figure 4.84A.**  
Ulcer with superficial fibrinoid  
necrosis and, below, diffuse  
granulomatous inflammation;  
hematoxylin and eosin, 4X.

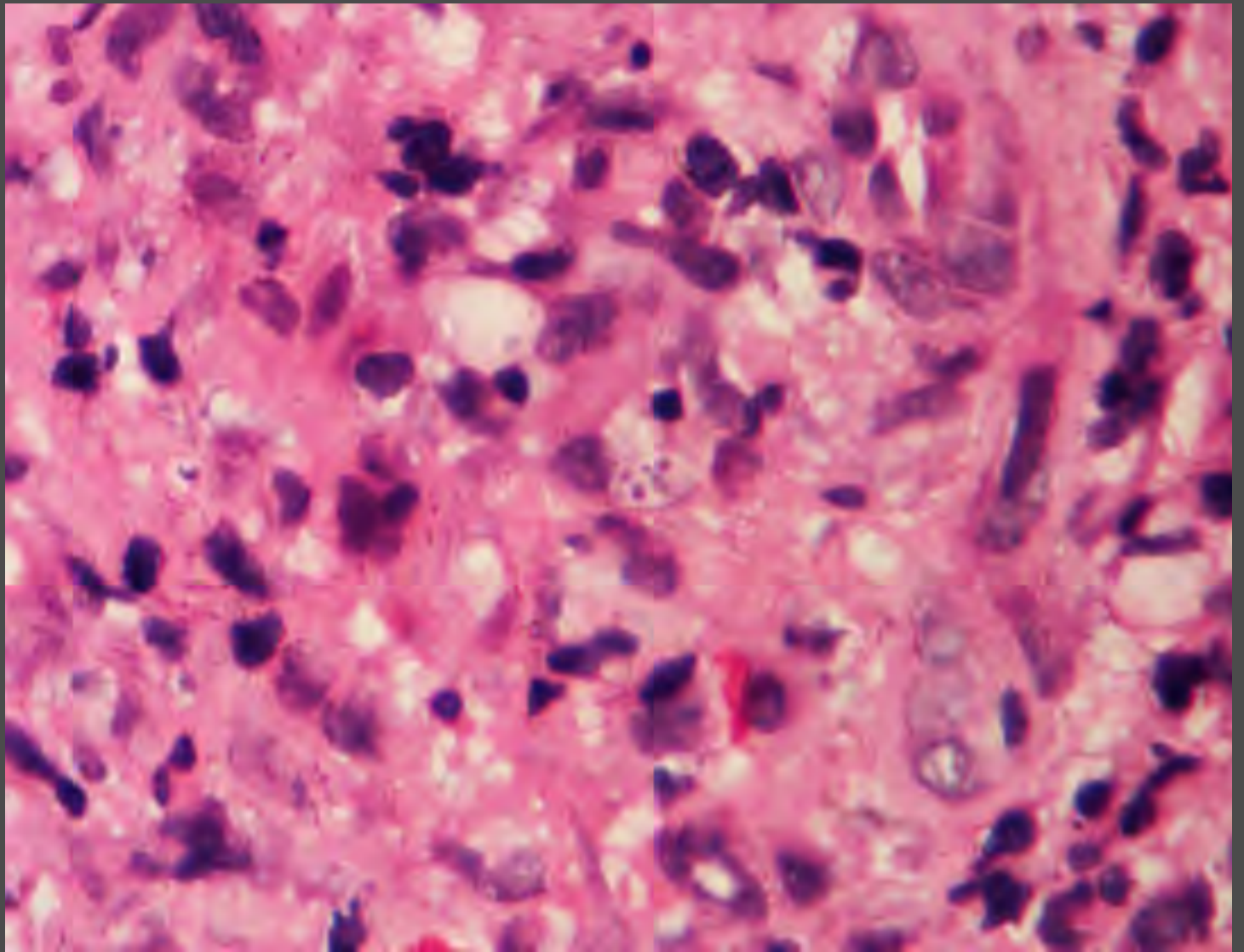


**Figure 4.84B.**  
Superficial fibrinoid necrosis, occasional  
giant cells, and deep diffuse inflammation;  
hematoxylin and eosin, 40X.

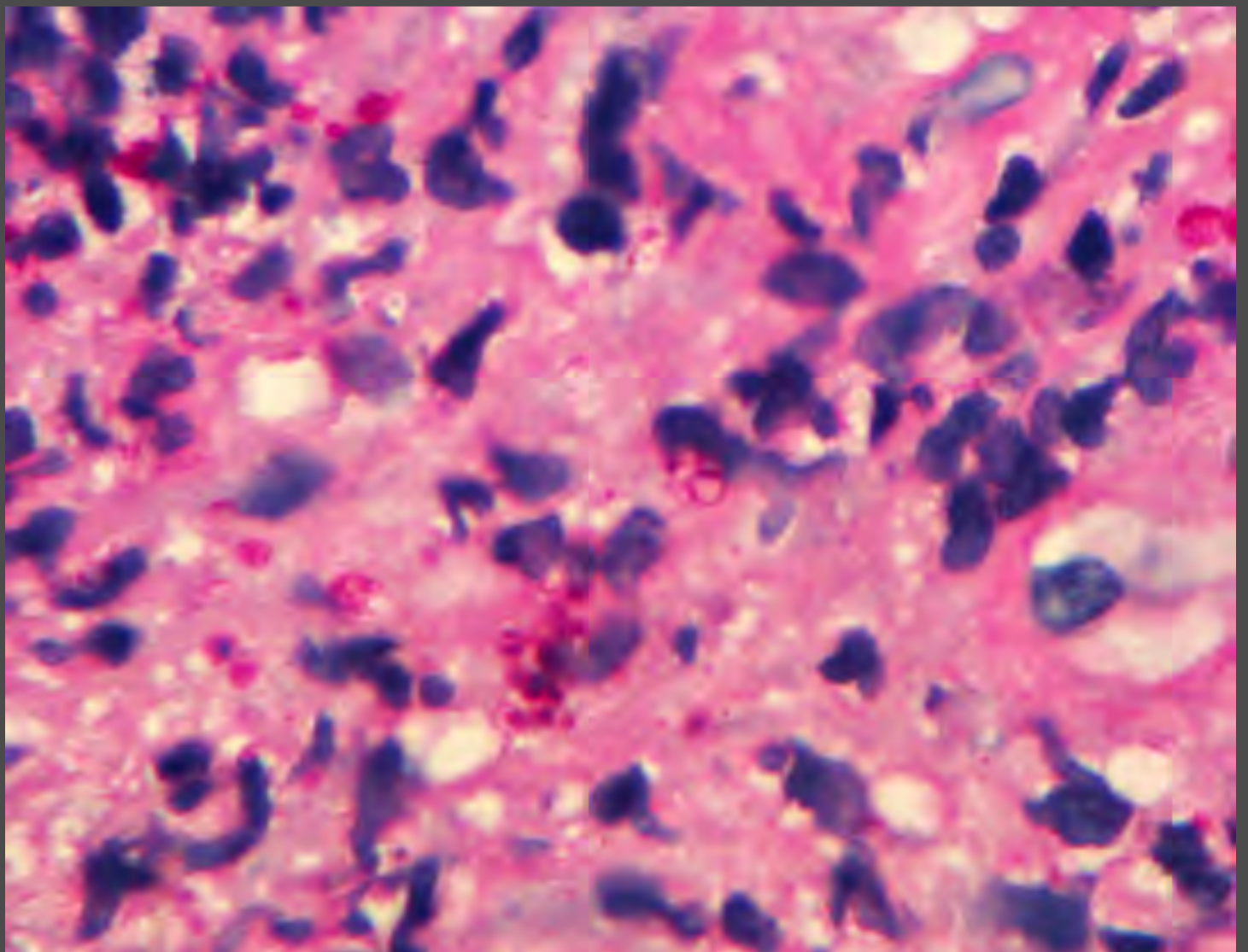


## AIDS-associated disseminated histoplasmosis

**Figure 4.84C.**  
Tiny phagocytized organisms  
are visible;  
hematoxylin and  
eosin, 100X.



**Figure 4.84D.**  
PAS stain (100X)  
reveals a great  
number of  
fungi identified  
as *Histoplasma*  
*capsulatum*.





## AIDS-associated disseminated histoplasmosis

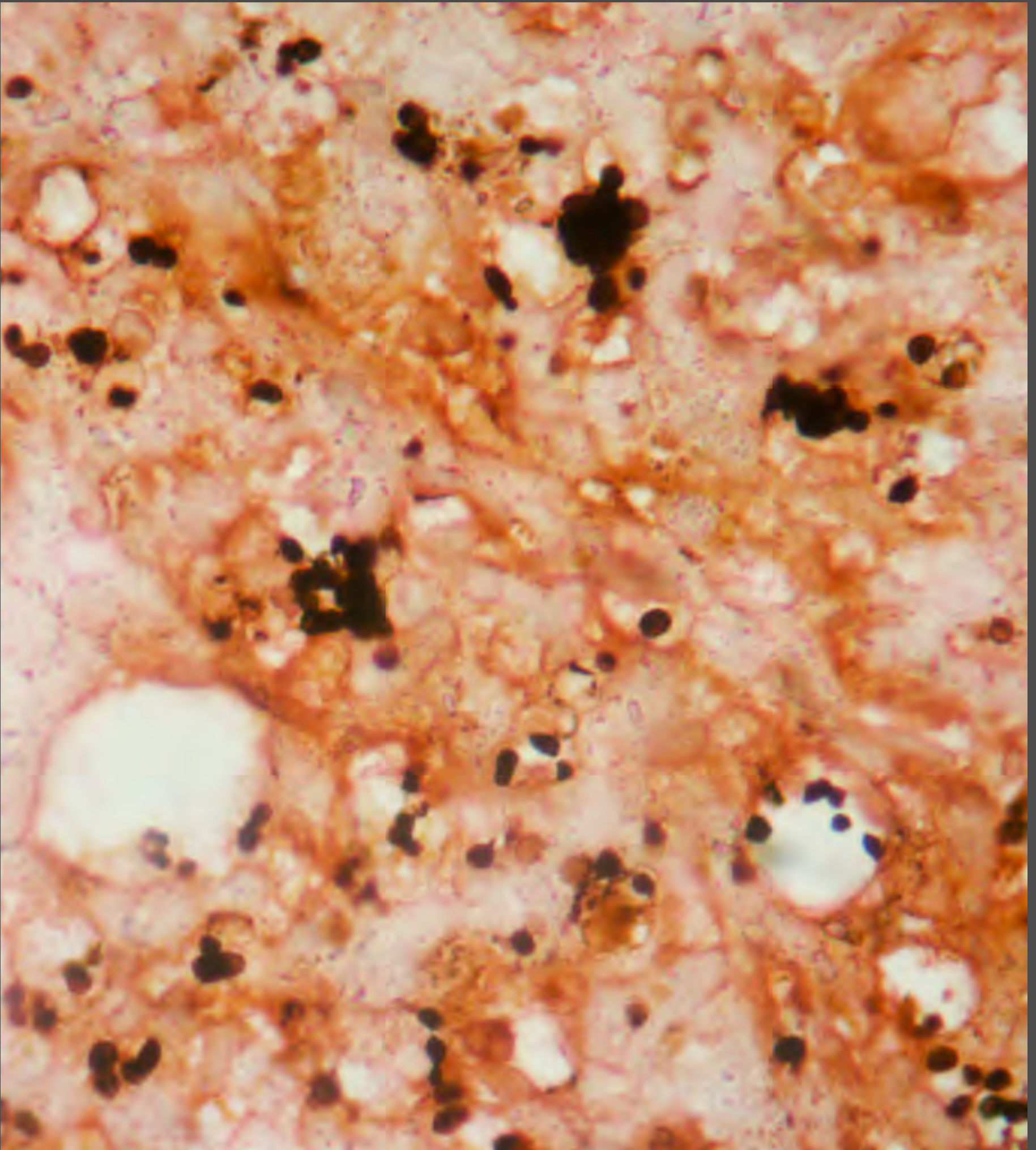


Figure 4.84E.  
Grocott stain (100X) reveals a great number of fungi  
identified as *Histoplasma capsulatum*.

**Rhinoscleroma.** This is a chronic granulomatous disease, caused by *Klebsiella rhinoscleromatis*, which affects the nose and can spread to the entire respiratory tract. Granulomatous masses form in the nostrils that produce obstruction and rhinorrhea, can be destructive, and leave scarring that affect function. Poor hygiene and nutritional conditions favor this infection, which is now more frequent with the presence of HIV/AIDS and other forms of immunosuppression (*Figures 4.85 and 4.86*).

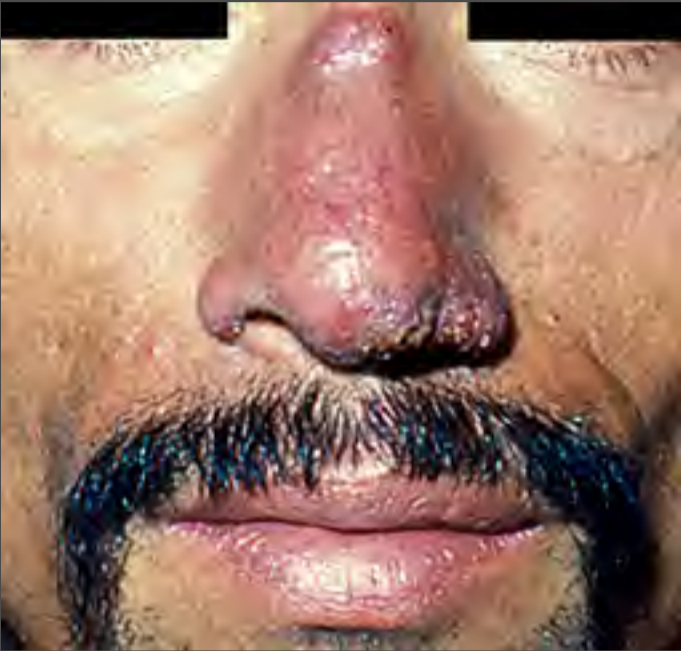**Rhinosporidiosis.** This infection is caused by *Rhinosporidium seeberi* and mainly affects young men, producing inflammatory, granular, polypoid, friable masses of the nasal septum mucosa that can sometimes ulcerate and cause nasal obstruction, rhinorrhea, and nosebleeds (*Figures 4.87 and 4.88*).

**Rhinoentomophthoromycosis.** This rare cutaneous and subcutaneous mycosis most frequently affects black men (*Figure 4.89*); it is produced by *Conidiobolus coronatus*, a saprophytic fungus (*Figure 4.90*).

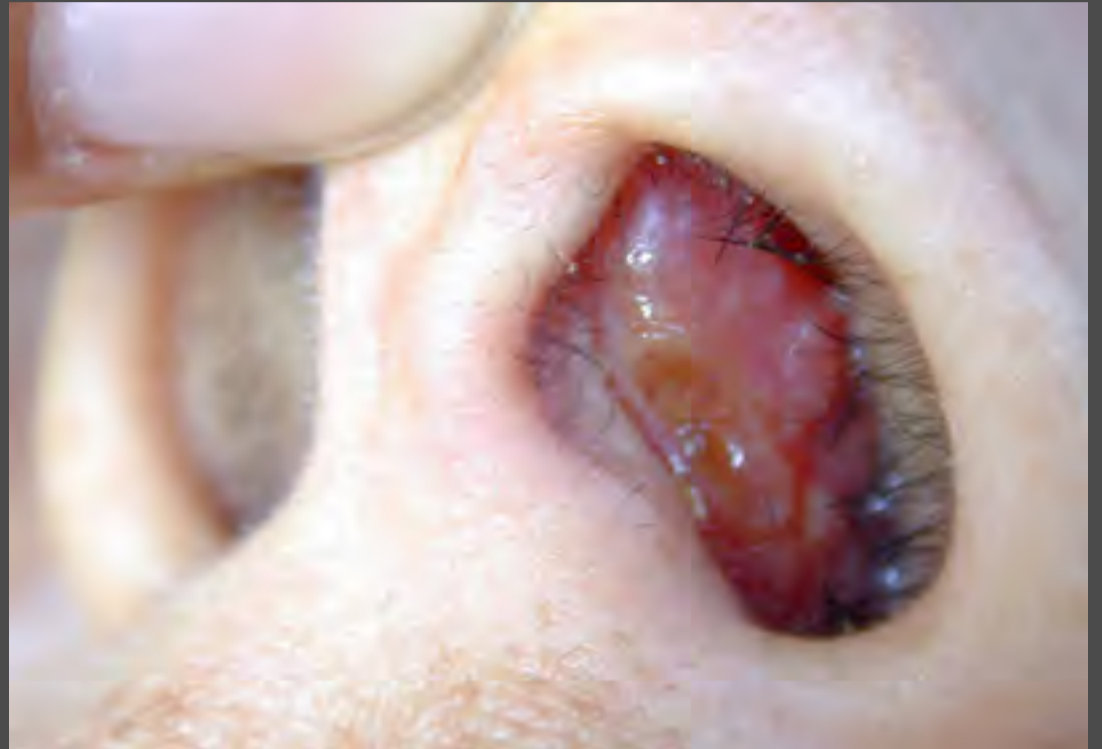**Mucormycosis.** This is an acute, severe opportunistic infection that affects the upper respiratory tract causing tissue necrosis with considerable destruction and invasion of deep tissues. In patients with a history of poor general health, and rapid development, this mycosis should be suspected, which even with treatment, it is frequently fatal.



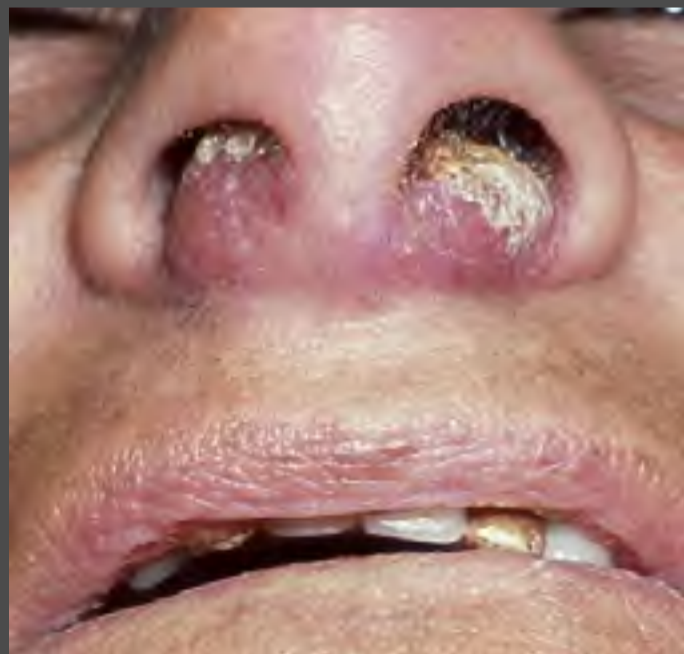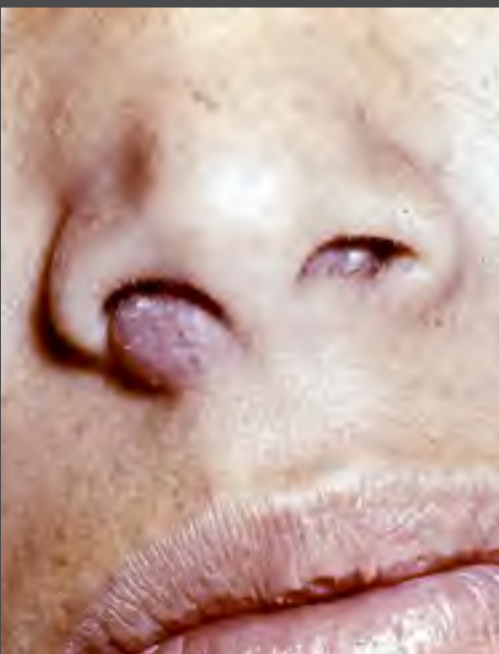## Rhinoscleroma



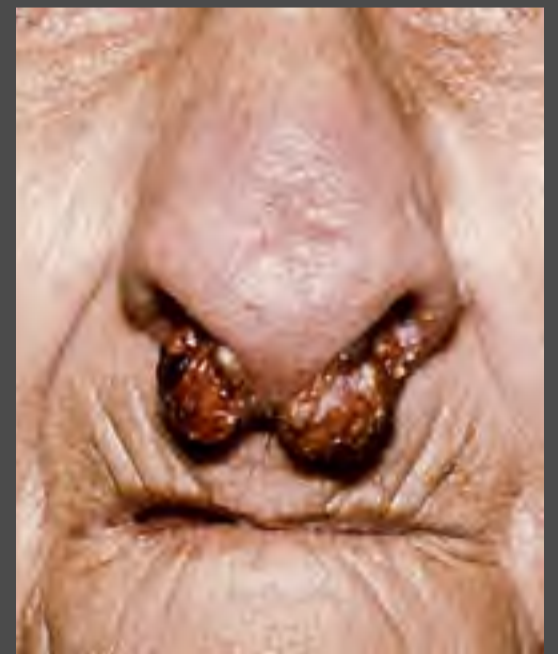**Figure 4.85A.**  
Chronic, firm, keloidal, and scarring  
plaques and nodules that deform the nose.



**Figure 4.85B.**  
Granulomatous mass partially obliterating the nasal cavity



**Figures 4.85C and D.**  
Firm infiltrated nodules in both nostrils



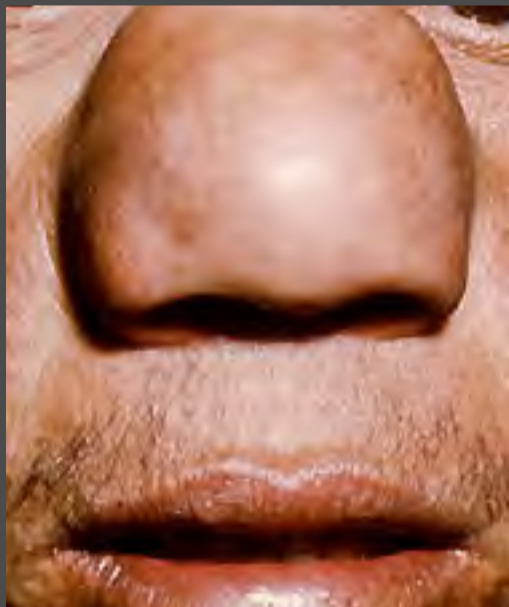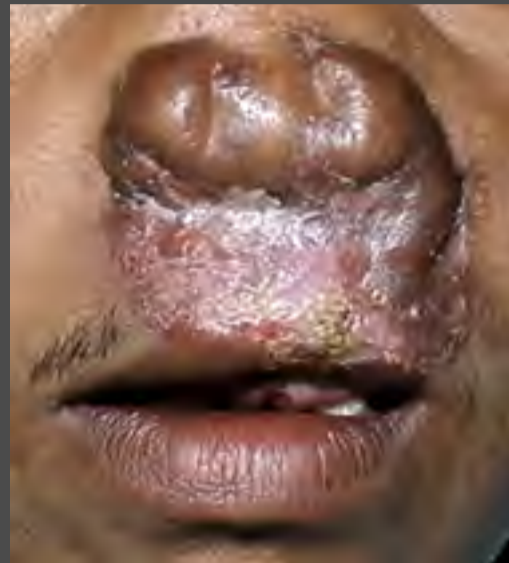**Figure 4.85E.**  
Polypoid, vegetative nasal  
nodules that deform and widen  
the nose.



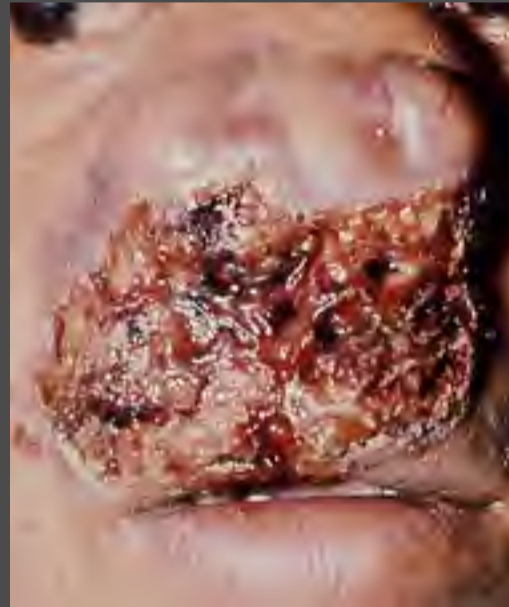

## Nasal scleroma

**Figure 4.85F.**  
Chronic, firm, keloidal,  
and scarring plaques and  
nodules that deform and  
occlude the nose.



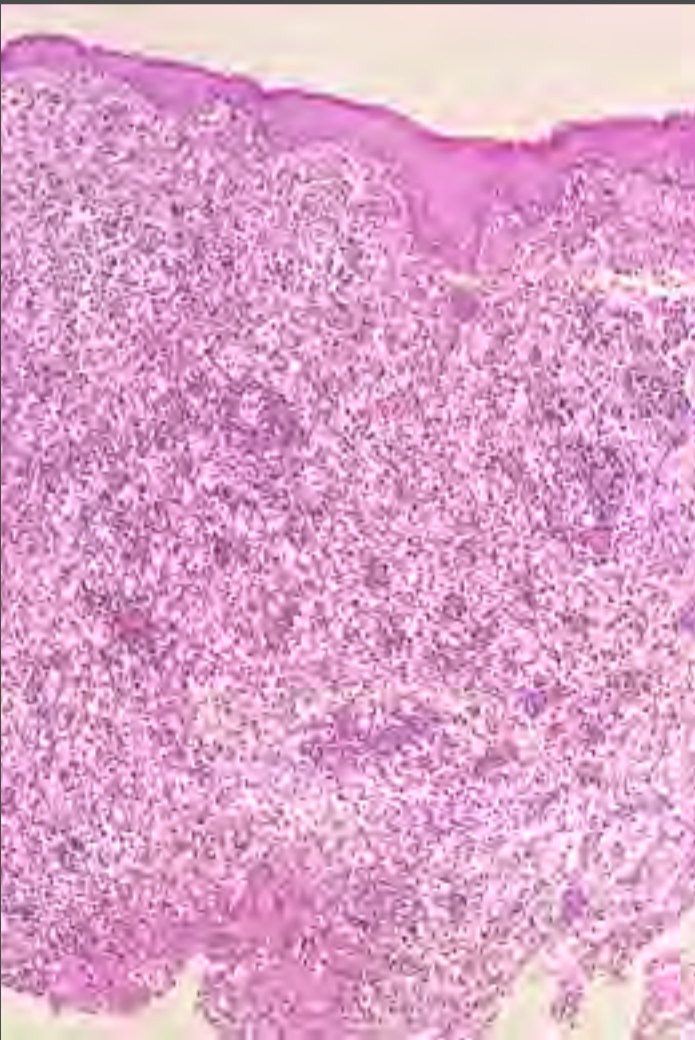
**Figure 4.85G.**  
Nasal deformation due  
to chronic inflammation  
and fibrosis



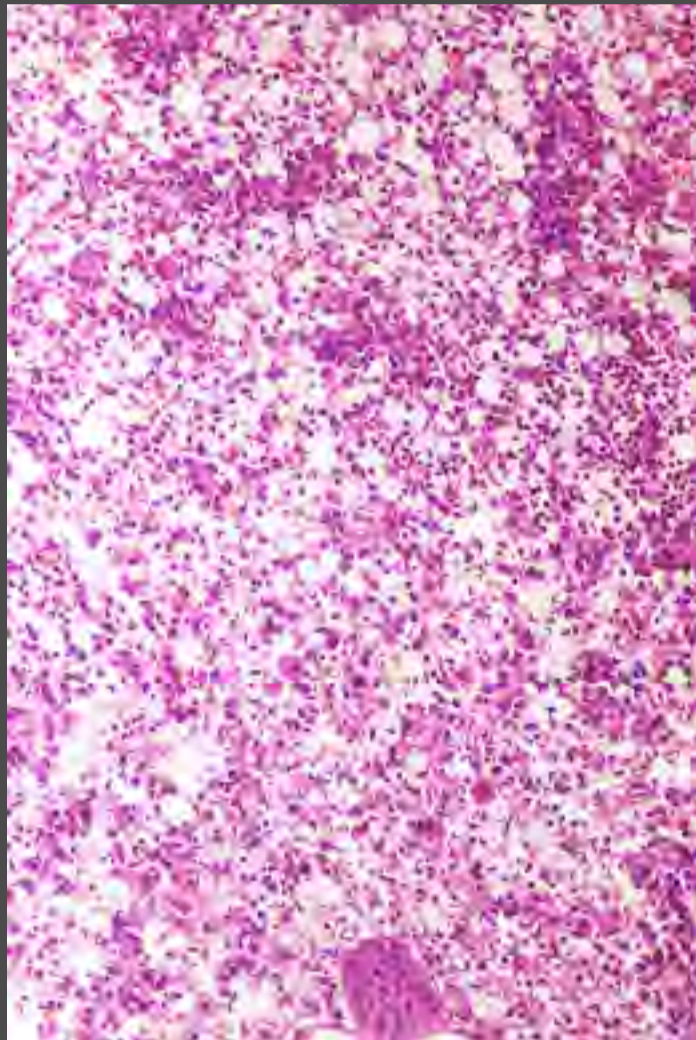
**Figure 4.85H.**  
Deformed, fibrous, keloidal  
nose, with occlusion of  
the nostrils and extensive  
ulceration extending to the  
upper lip.



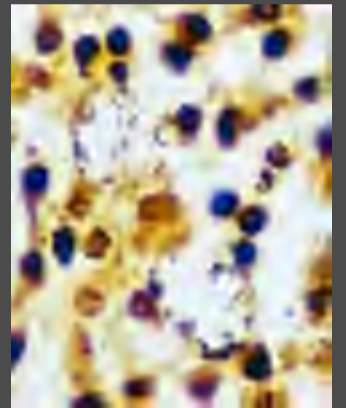
## Rhinoscleroma. Biopsy of recent nasal lesion



**Figure 4.86A.**  
Normal epidermis and corium or lamina propria of the mucosa with diffuse inflammation and abundant vacuolated macrophages; hematoxylin and eosin, 4X.



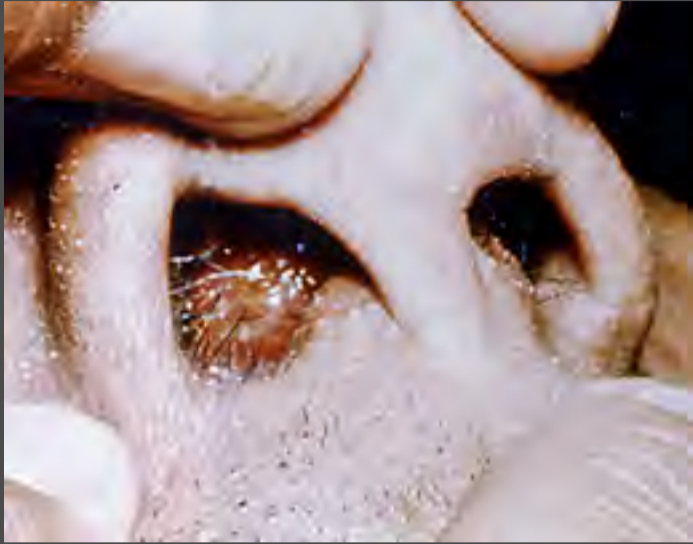**Figure 4.86B.**  
Numerous vacuolated macrophages, plasmacytes, and Russell bodies; hematoxylin and eosin, 16X.



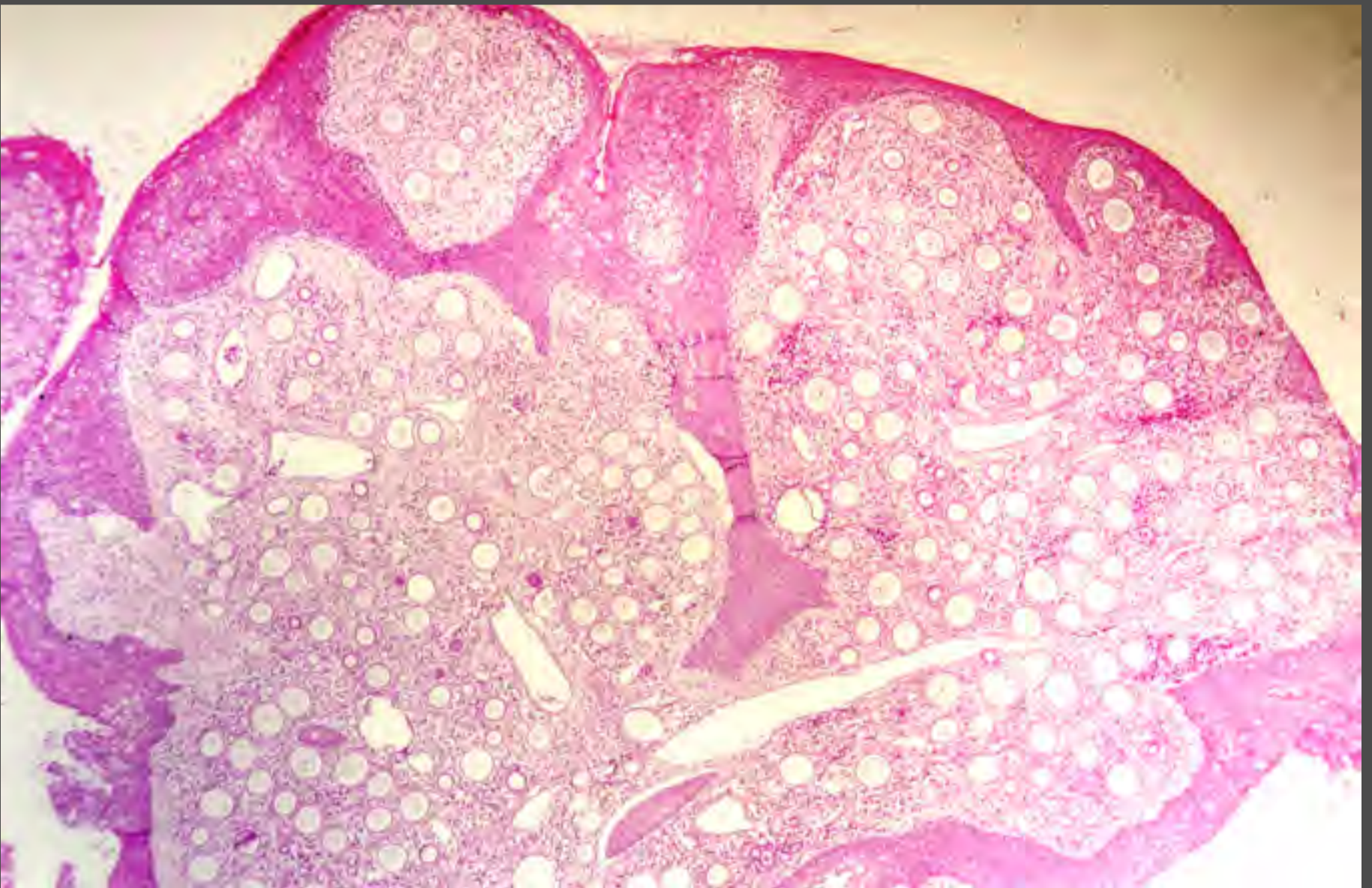
**Figure 4.86C.**  
Silver salts stain *Klebsiella* species phagocytized by macrophages; Warthin-Starry stain, 100X.



## Rhinosporidiosis



**Figure 4.87.**  
Nasal nodule in an  
adult man



**Figure 4.88A.**  
The wide-angle photograph shows discrete  
epidermal hyperplasia and corium with numerous  
cysts surrounded by chronic inflammation;  
hematoxylin and eosin, 2X.



## Rhinosporidiosis

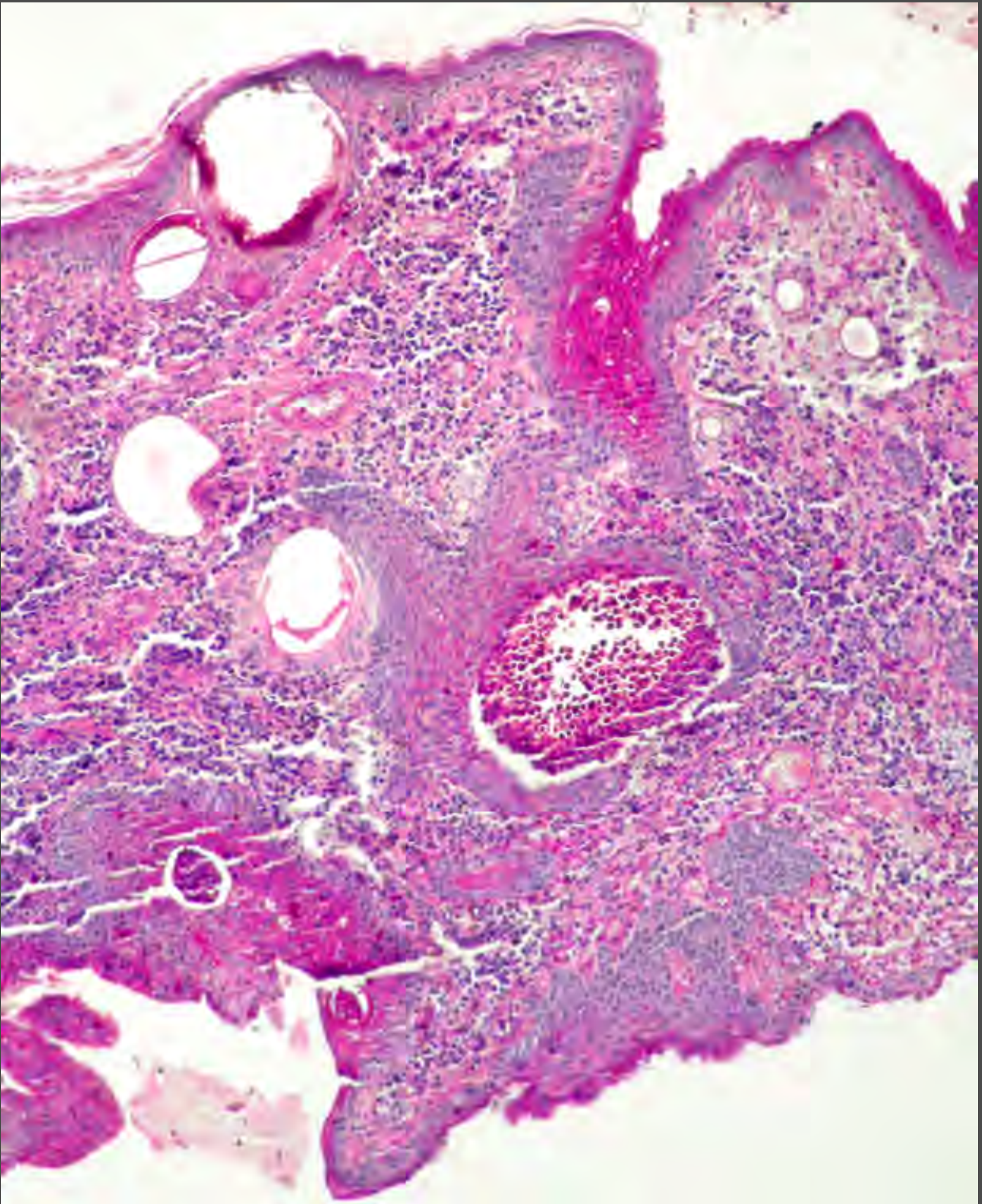


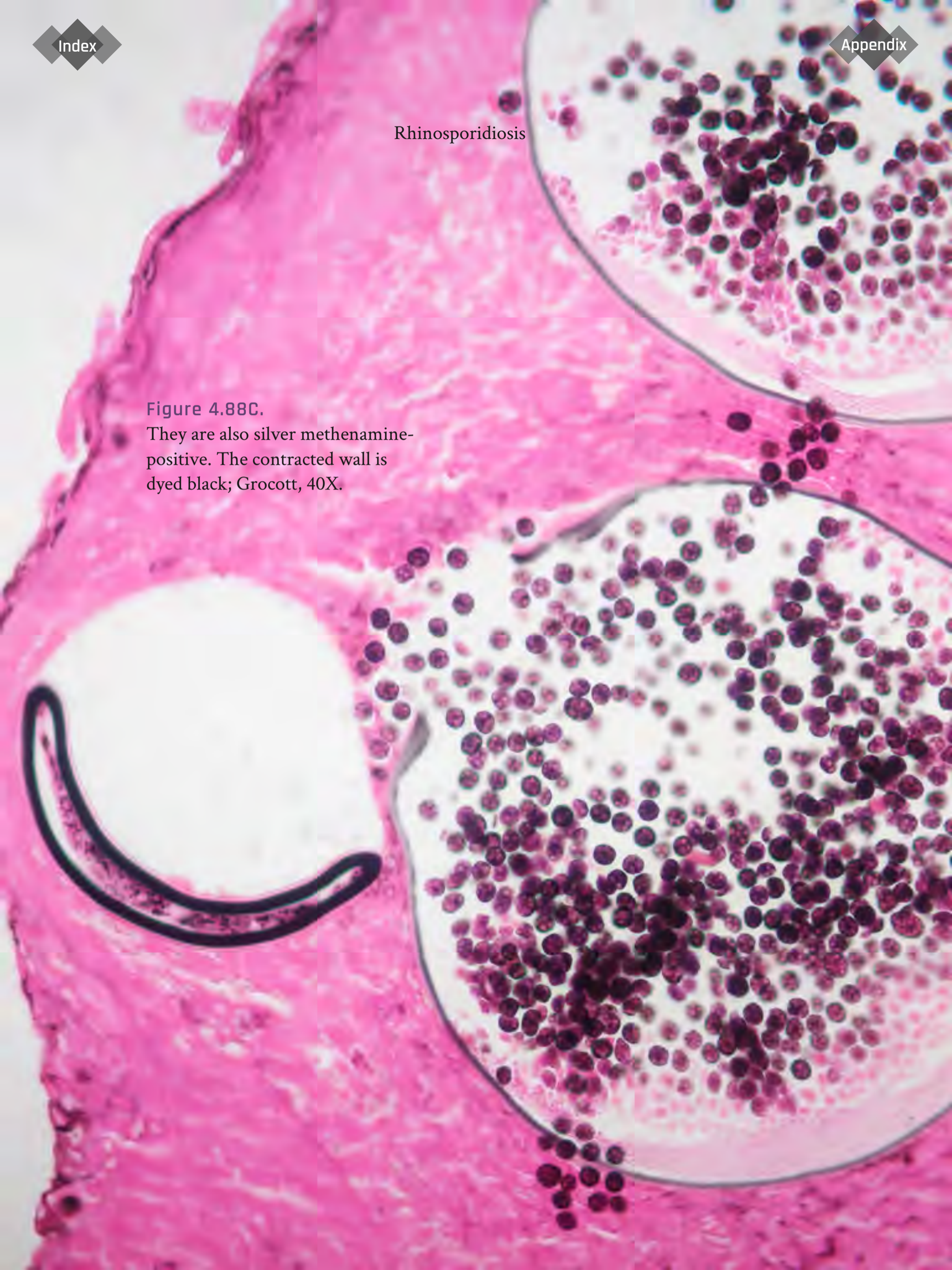
Figure 4.88B.

Cysts or sporangia have a thin wall and some are full of PAS-positive endospores; PAS, 6.3X.

## Rhinosporidiosis

Figure 4.88C.

They are also silver methenamine-positive. The contracted wall is dyed black; Grocott, 40X.



## Rhinosporidiosis

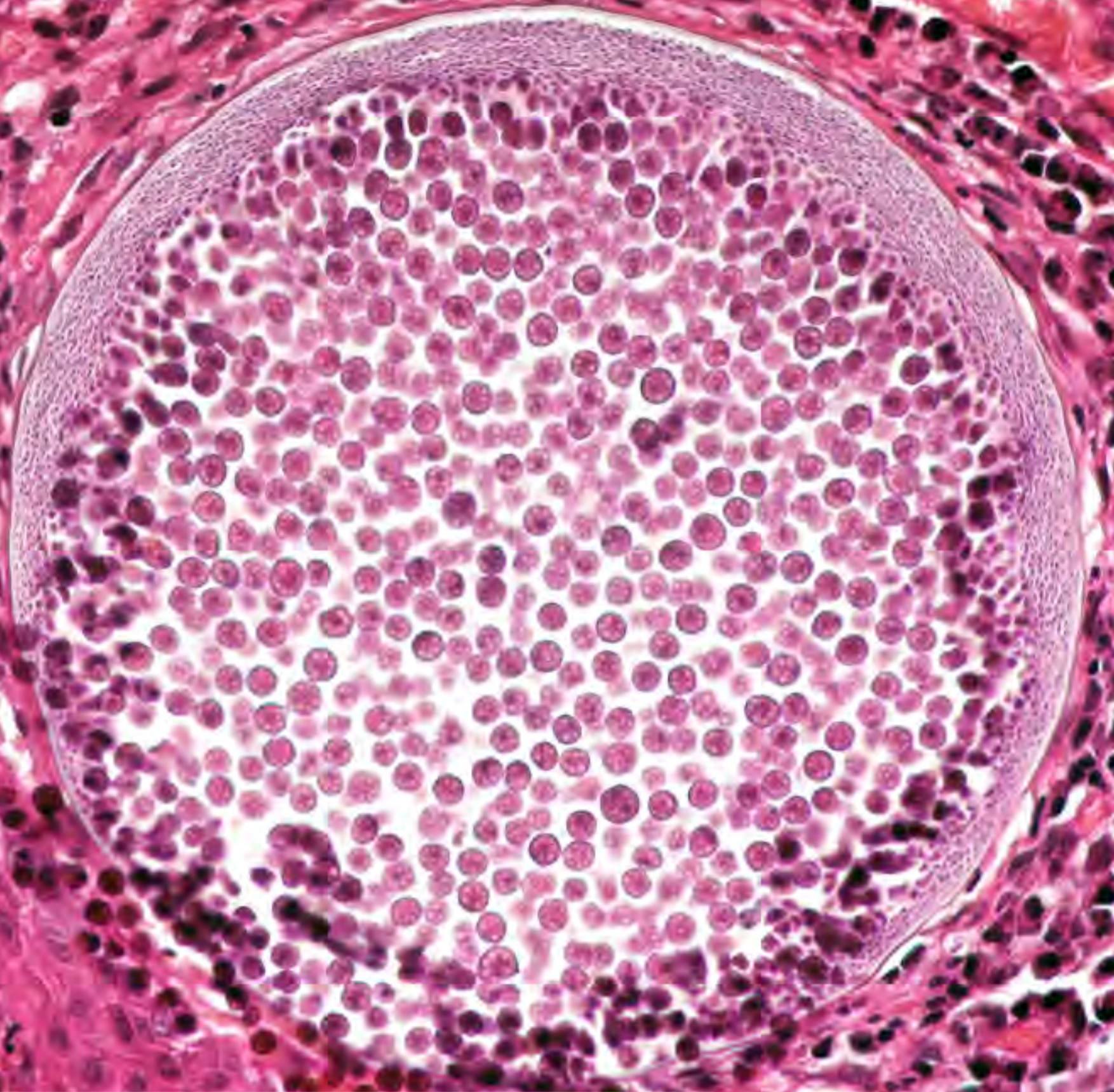


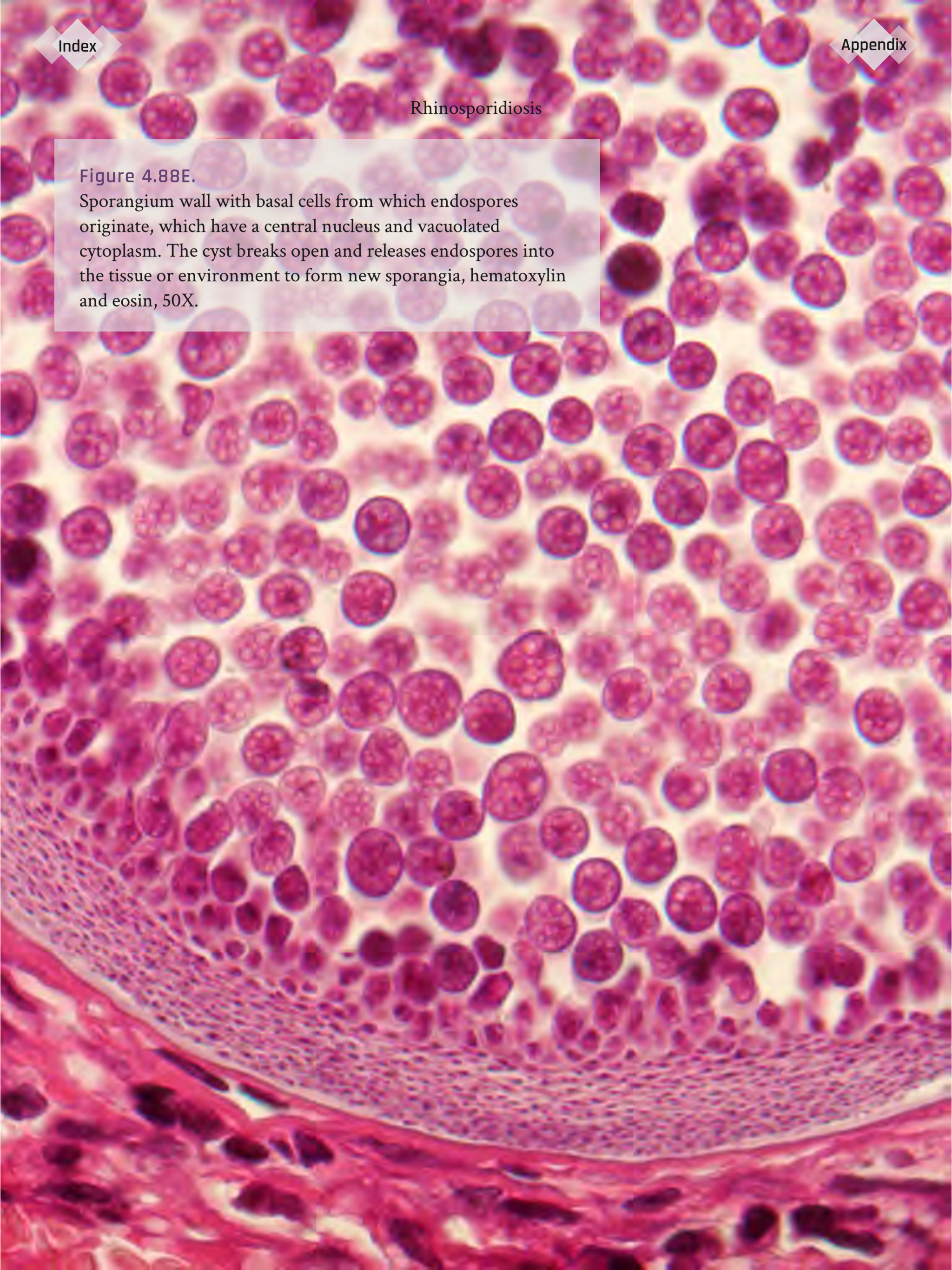
Figure 4.88D.

Sporangium wall with basal cells from which endospores originate, which have a central nucleus and vacuolated cytoplasm. The cyst breaks open and releases endospores into the tissue or environment to form new sporangia; hematoxylin and eosin, 50X.

## Rhinosporidiosis

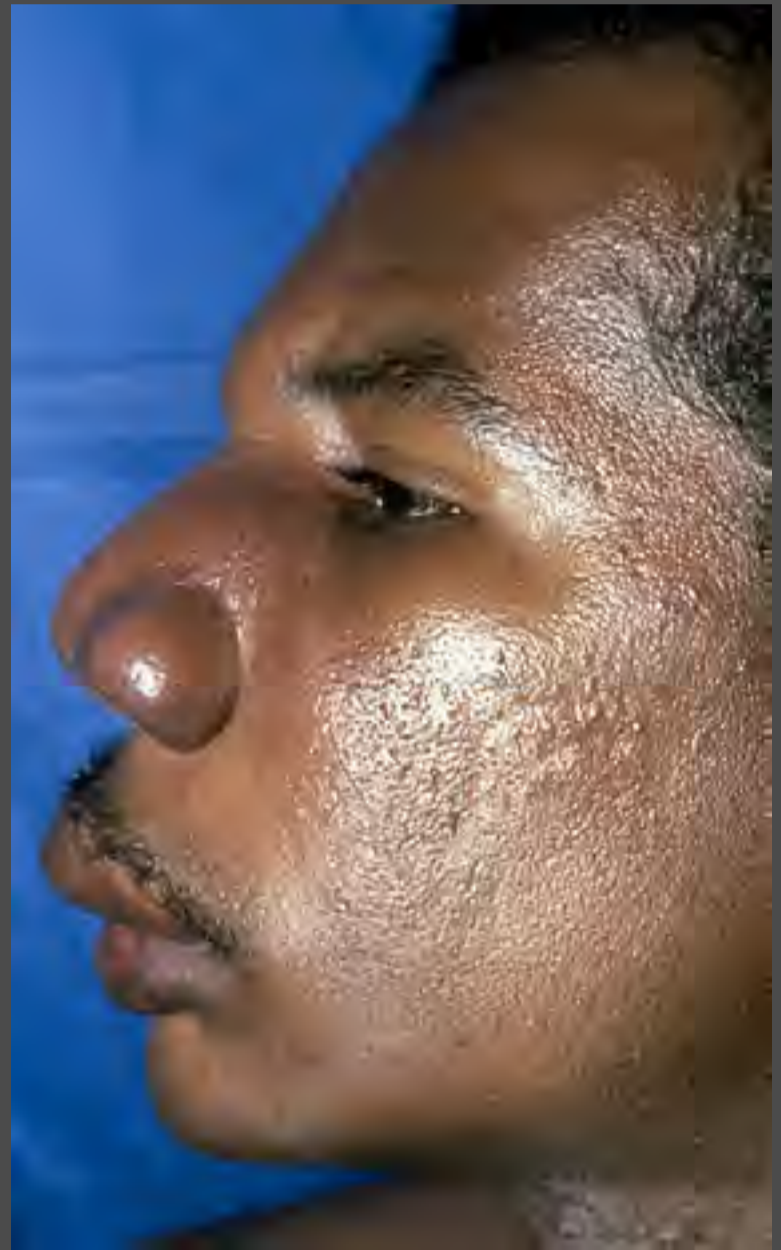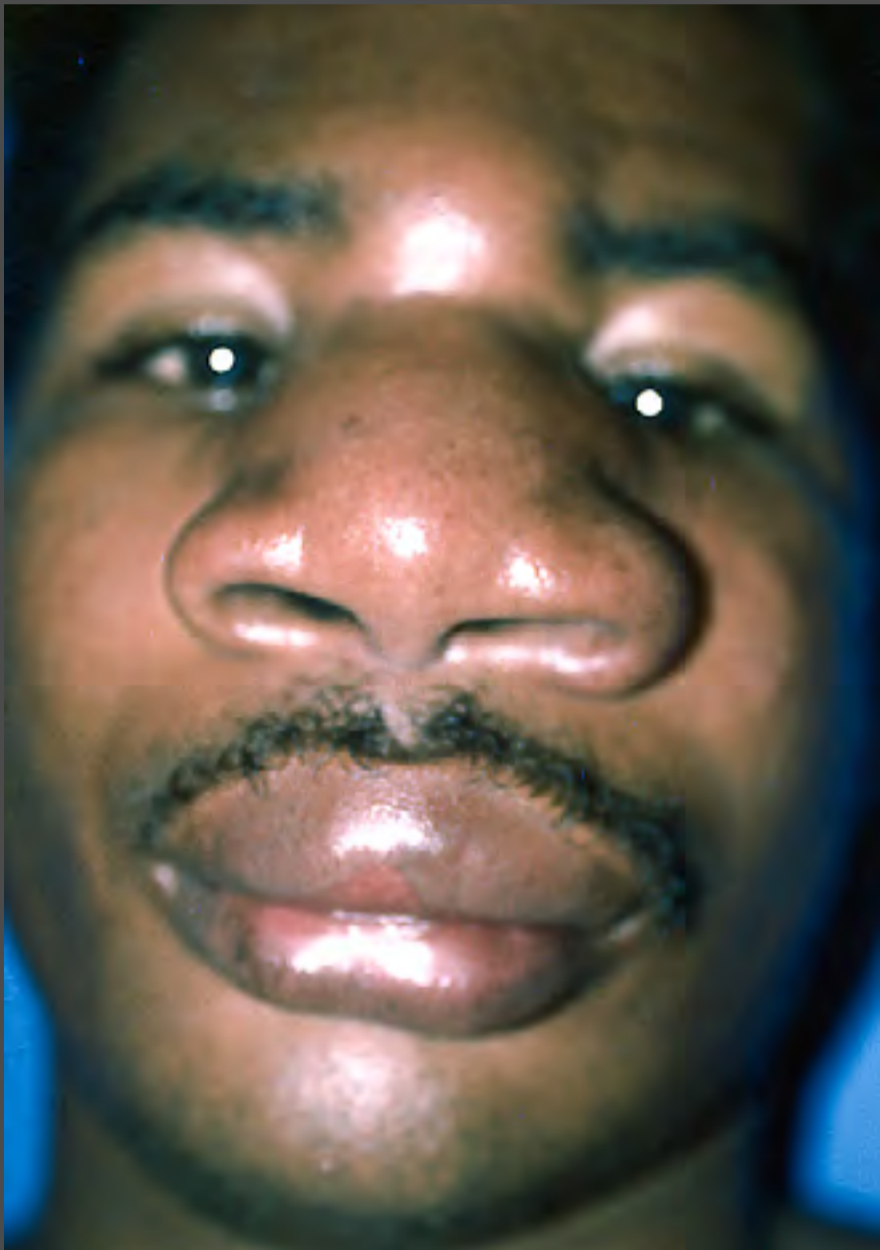Figure 4.88E.

Sporangium wall with basal cells from which endospores originate, which have a central nucleus and vacuolated cytoplasm. The cyst breaks open and releases endospores into the tissue or environment to form new sporangia, hematoxylin and eosin, 50X.





## Rhinoentomophthoromycosis

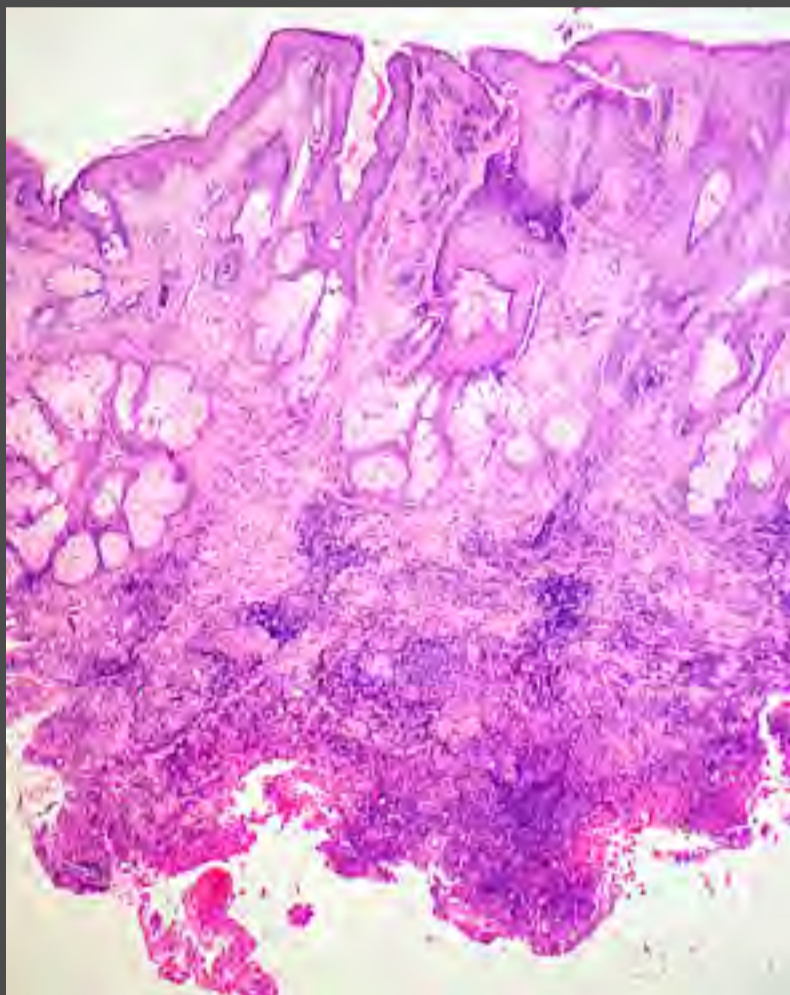


**Figures 4.89A and B.**  
Young man with hard, infiltrated nasal deformation that extends to the forehead.



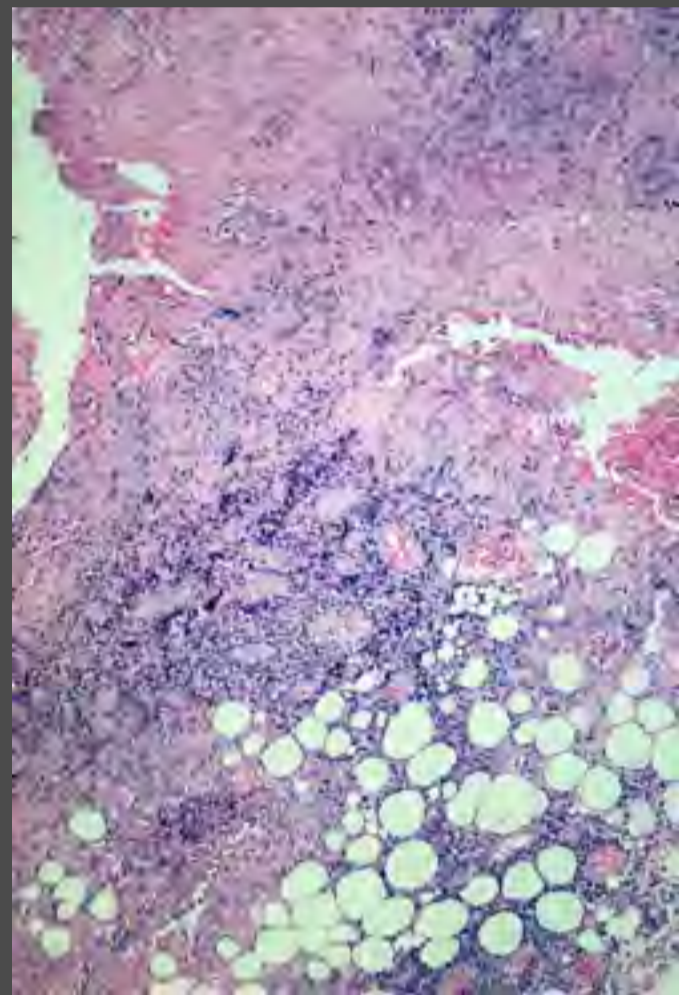


## Nasal biopsy of the previous patient



**Figure 4.90A.**

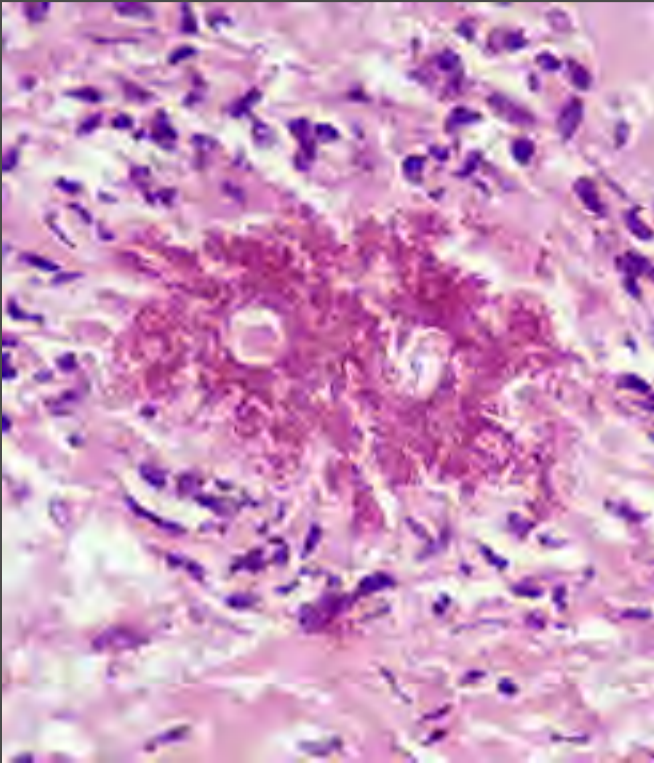
The wide-angle photo shows normal superficial hair follicles and inflammation in the deep dermis and hypoderm; hematoxylin and eosin, 2,5X.



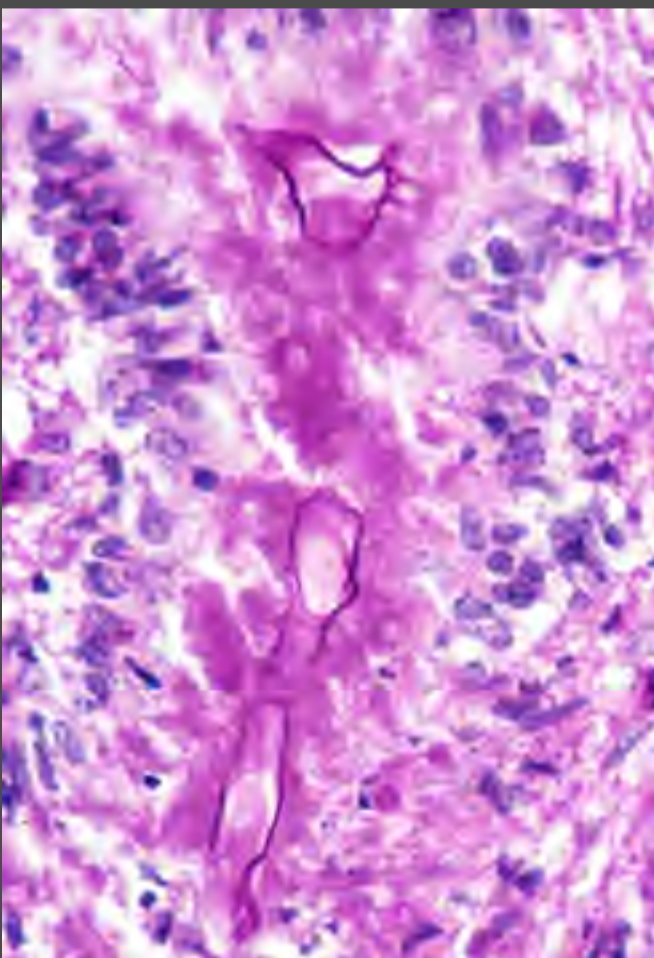
**Figure 4.90B.**

Hypodermic inflammation and an eosinophilic area surrounding clear spaces in the deep dermis; hematoxylin and eosin, 10X.

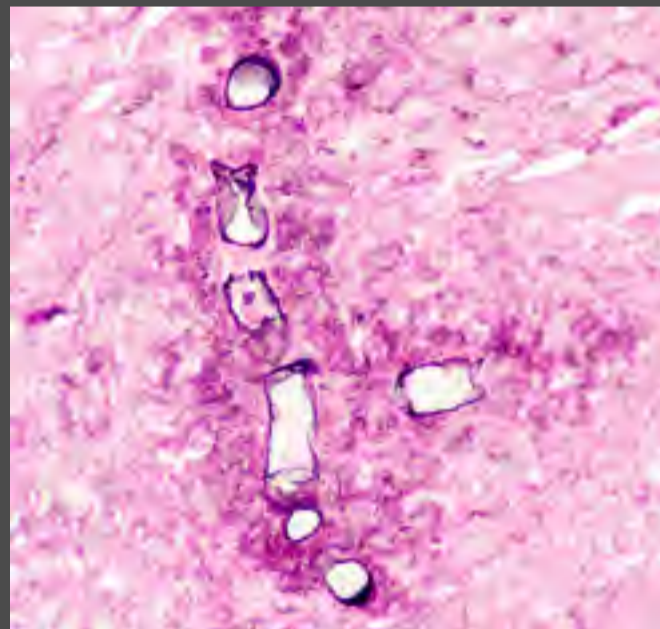
## Nasal biopsy of the previous patient

**Figure 4.90C.**

At greater magnification, eosinophilic granulations surrounding these clear quadrilateral hyphae are visible, as an expression of the Splendore-Hoeppli phenomenon; hematoxylin and eosin, 40X.

**Figure 4.90D.**

PAS staining shows broad, thick-walled hyphae surrounded by eosinophilic granulations and granulomatous inflammation; PAS, 40X.

**Figure 4.90E.**

Silver-methenamine stains the hyphae black; Grocott, 64X.

## Tumors

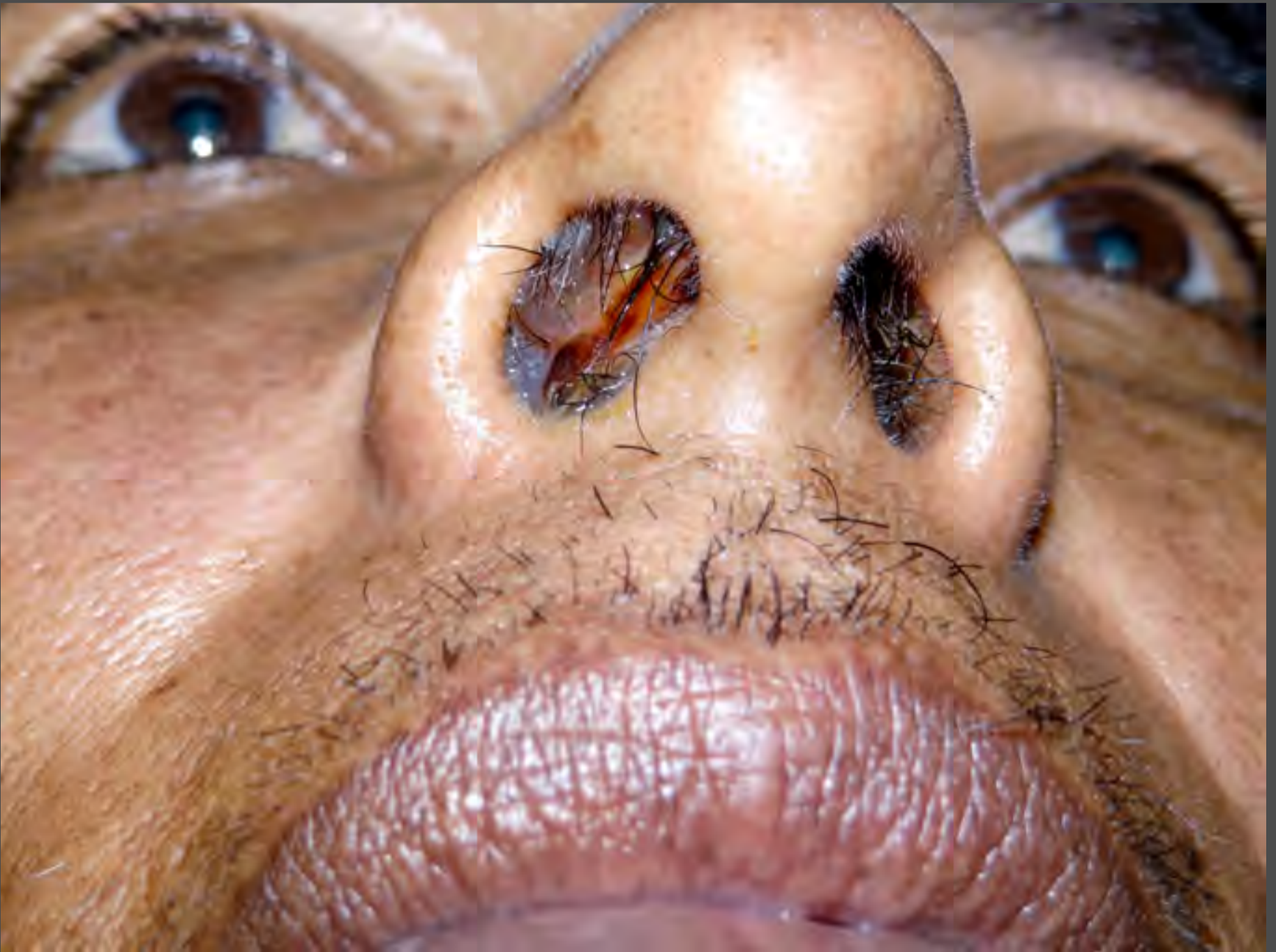**Adenoma.** This is a pleomorphic tumor of the nasal mucosa located on the septum. It is fast-growing, with obstruction. Usually there is no edema, infiltration, or ulceration, but rather a tumor mass (*Figure 4.91*).

Table 4.4. Differential diagnosis of mucosal leishmaniasis (in order of frequency)

Infections	Tumors	Miscellaneous
<ul style="list-style-type: none"> <li>• Paracoccidioidomycosis</li> <li>• Leprosy</li> <li>• Tuberculosis</li> <li>• Histoplasmosis</li> <li>• Syphilis</li> <li>• Rhinoscleroma</li> <li>• Rhinosporidiosis</li> <li>• Rhinoentomophthoromycosis</li> <li>• Mucormycosis</li> </ul>	<ul style="list-style-type: none"> <li>• Basal cell carcinoma</li> <li>• Squamous cell carcinoma</li> <li>• Epidermoid carcinoma</li> <li>• Cutaneous nasal T cell lymphoma</li> </ul>	<ul style="list-style-type: none"> <li>• Banal perforation of nasal septum</li> <li>• Rhinophyma</li> <li>• Sarcoidosis</li> <li>• Cocaine use</li> <li>• Granulomatosis with polyangiitis (previously known as Wegener's granulomatosis)</li> </ul>



## Adenoma



**Figure 4.91.**  
Pleomorphic tumor of the nasal mucosa, confirmed by biopsy

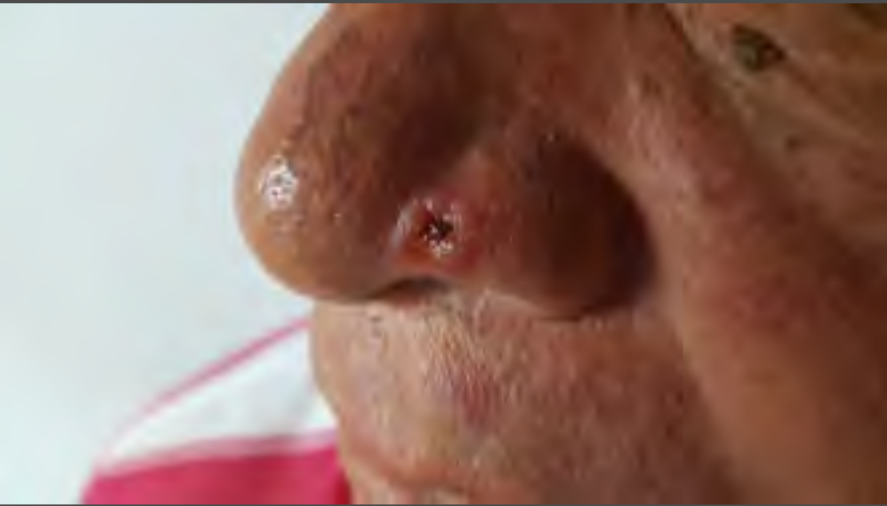

***Basal cell carcinoma.*** The skin of the nose is one of the most frequent locations for basal cell carcinoma, and both the papular or nodular lesions and plaques and the usual ulcerations of this type of cancer can be confused with leishmaniasis. They are distinguished by taking years to develop, the frequent presence of pigmentation on the edges of the lesion, their slow growth, and sun damage on the facial skin. When the lesion is aggressive, it can produce destruction of the nasal pyramid that usually starts with the skin of the alae or the ridge, possibly eventually involving the septum, causing lesions that can be confused with mucosal leishmaniasis (*Figures 4.92*).

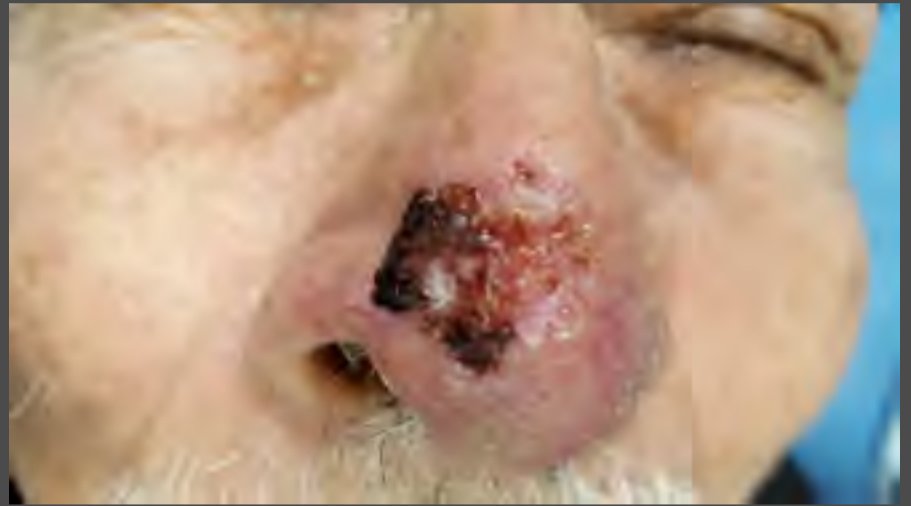***Squamous cell carcinoma.*** As with basal cell carcinoma, this is a lesion associated with severe sun damage, which means that facial and other exposed skin present actinic melanosis and actinic keratosis. The lesion is usually an ulcerated, erythematous, and irregular plaque with crusts. When it is located on the bridge of the nose or in the vicinity of the nose, it grows and ulcerates, destroying neighboring tissues and deeply invading them, which leads to changes that can be disfiguring and deforming. It can also be located inside the nose and it is common to see lesions on the lower lip. It progresses more rapidly and can invade regional nodes or produce remote metastases (*Figures 4.93*).



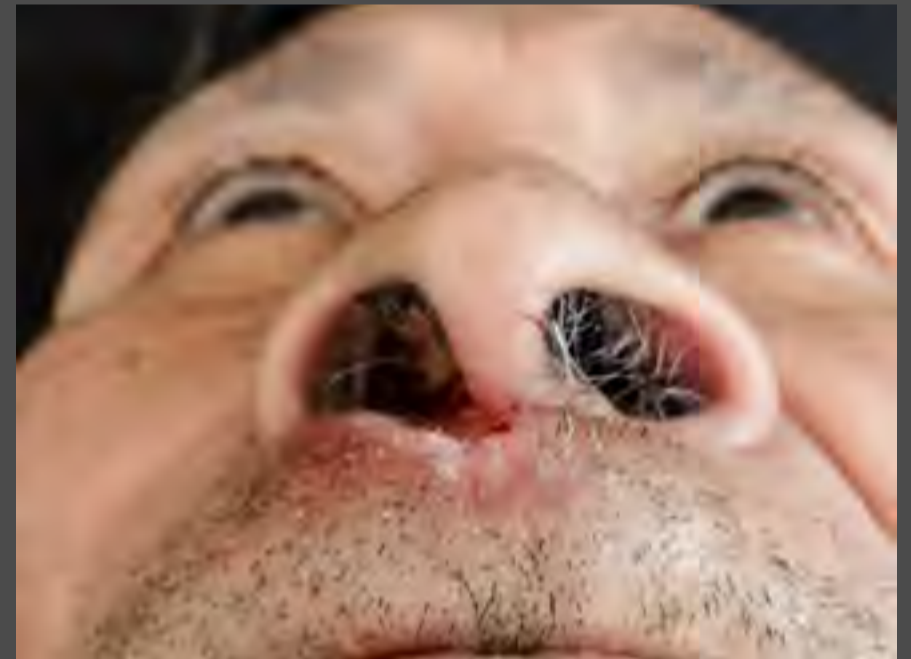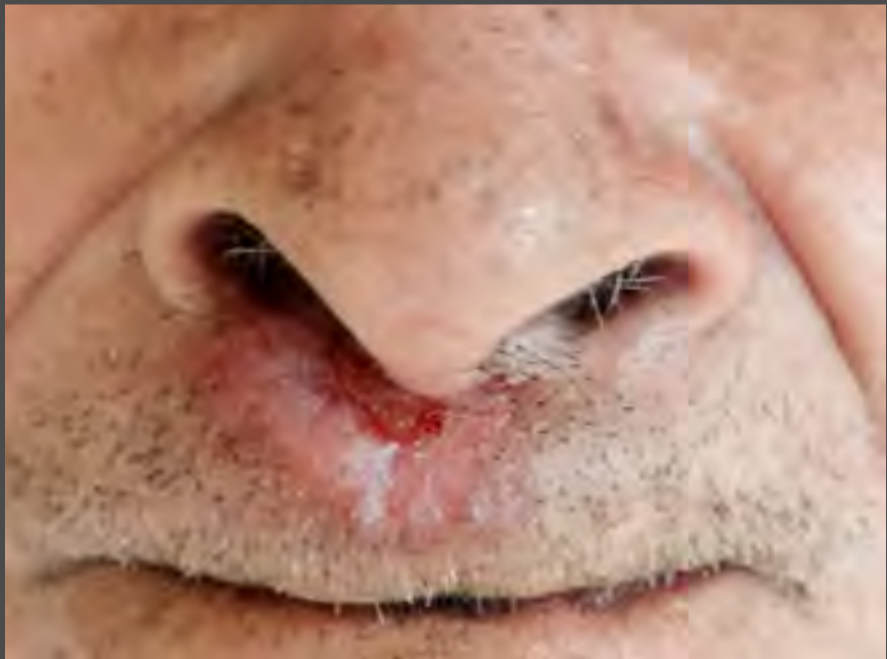## Basal cell carcinoma



**Figure 4.92A.**  
Incipient tumor, confirmed by biopsy



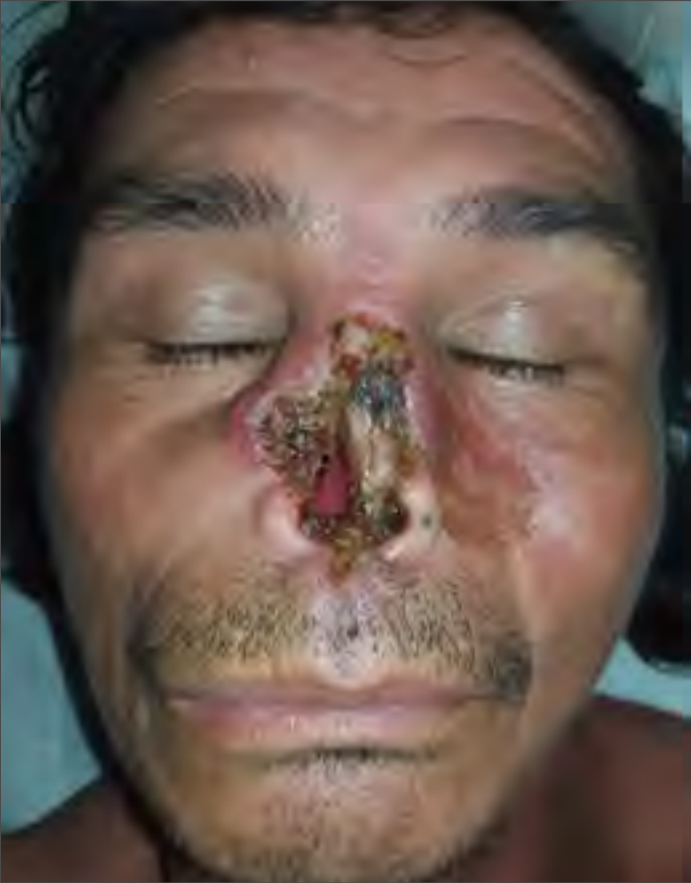**Figure 4.92B.**  
Crusty, infiltrated plaque with telangiectasias



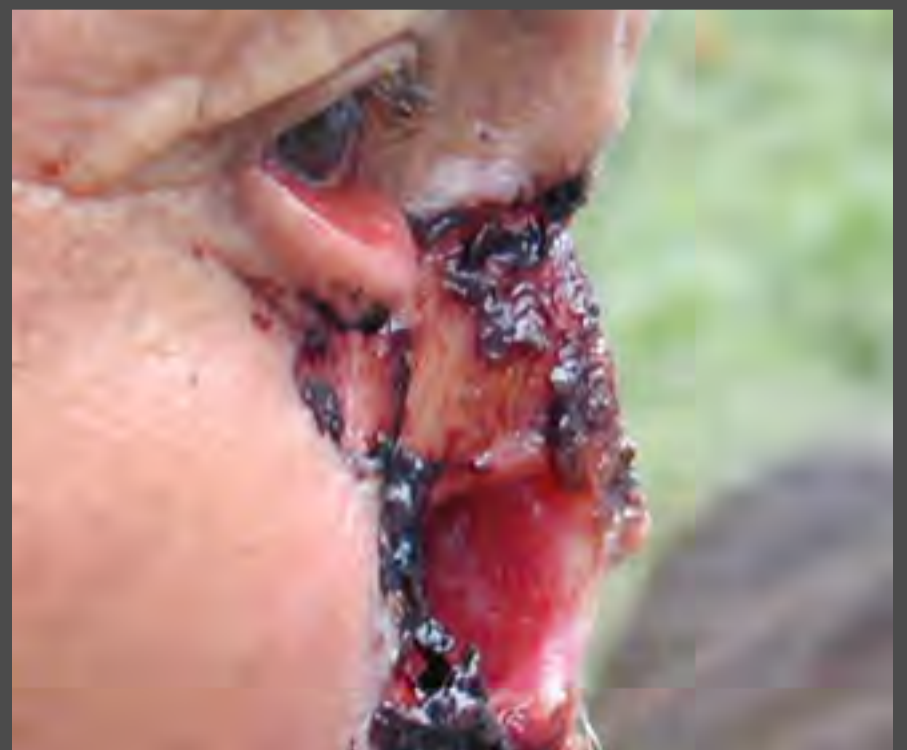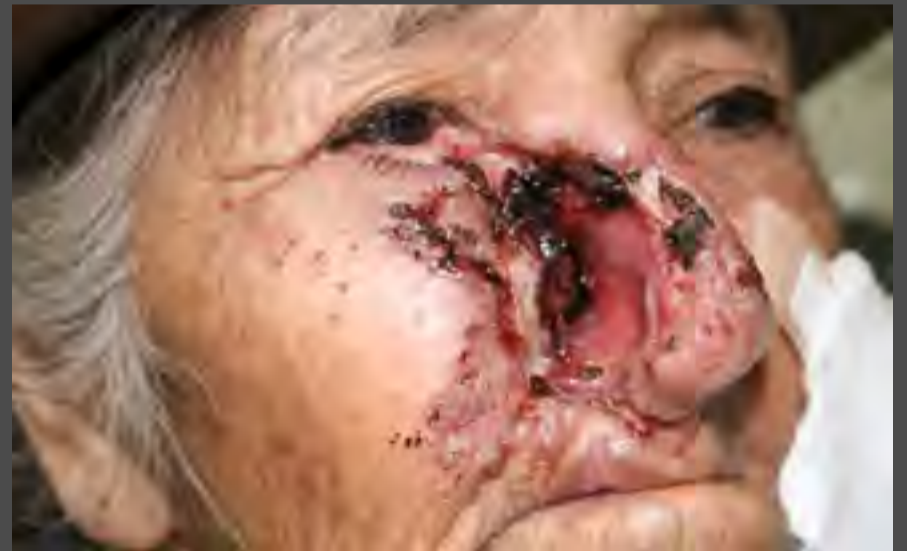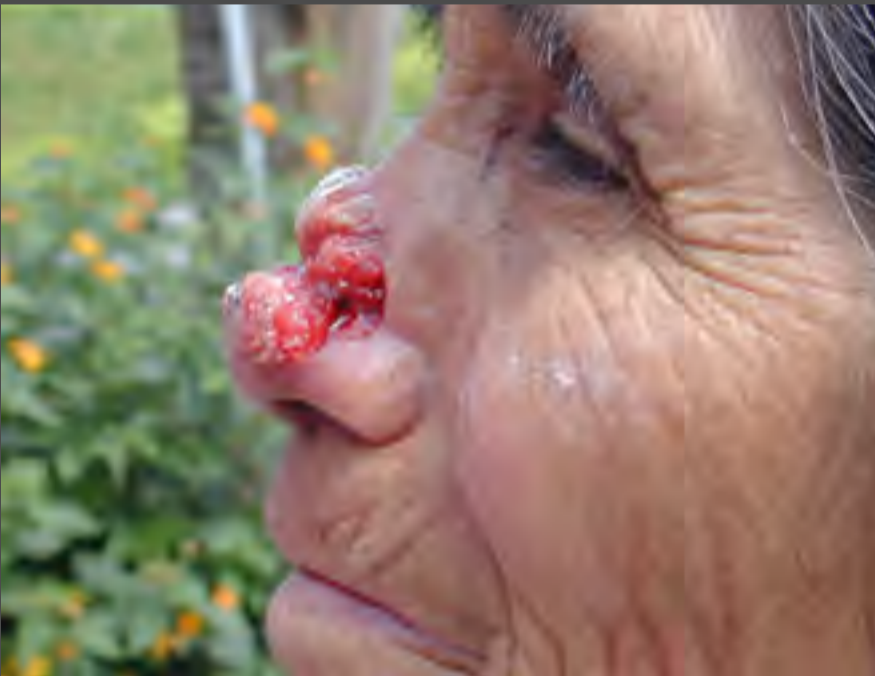**Figure 4.92C and D.**  
Tumor confirmed by biopsy. Examination of the mucosa did not find intranasal lesions.



## Basal cell carcinoma

**Figure 4.92E.**

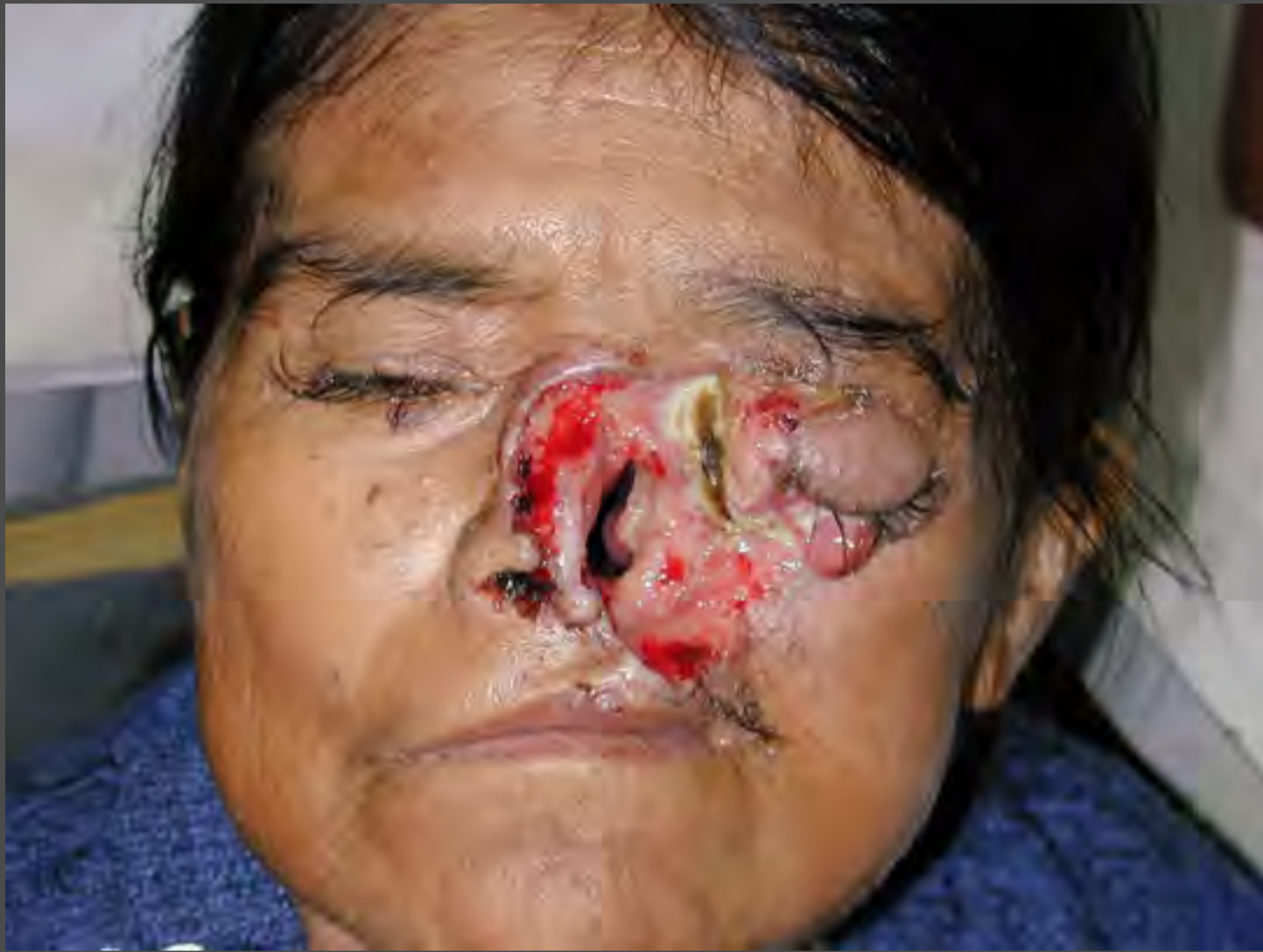Crusty ulcer with involvement of the nasal septum

**Figures 4.92F, G and H.**

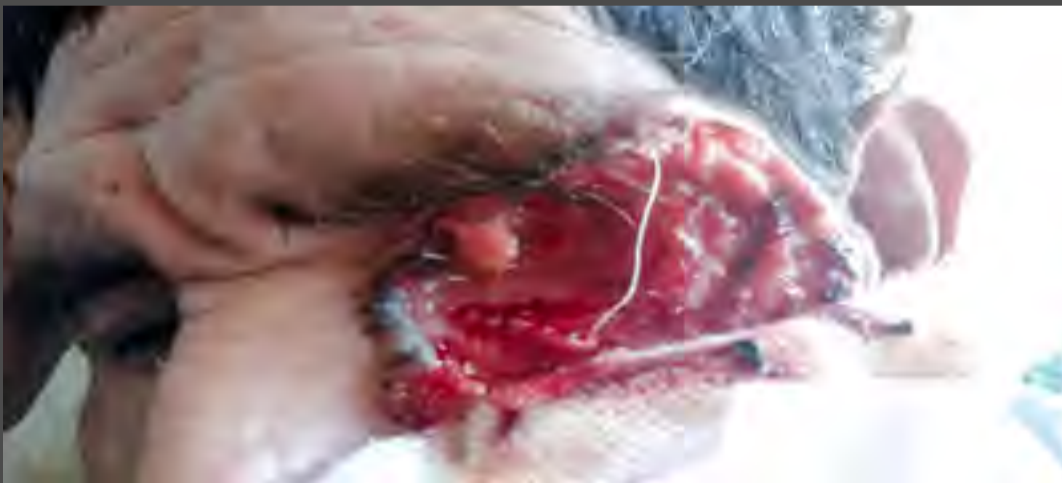Patients with varying degrees of nasal destruction. This is a mildly aggressive tumor that can last for years in its localized form of superficial skin involvement, but over time it can become locally invasive and cause considerable destruction of bone, extending to deep structures.



## Basal cell carcinoma



**Figure 4.92I.**  
Tumor that became invasive, with considerable destruction of the nose and eyeball

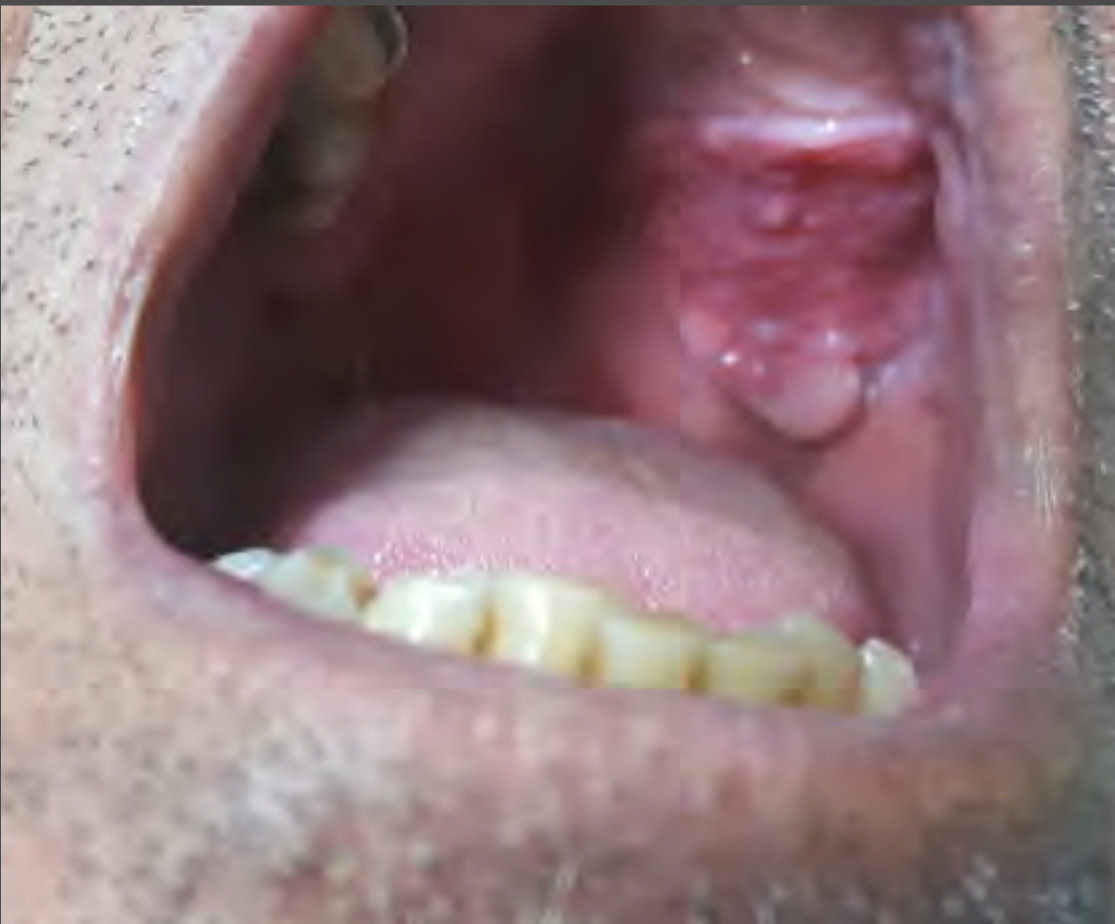
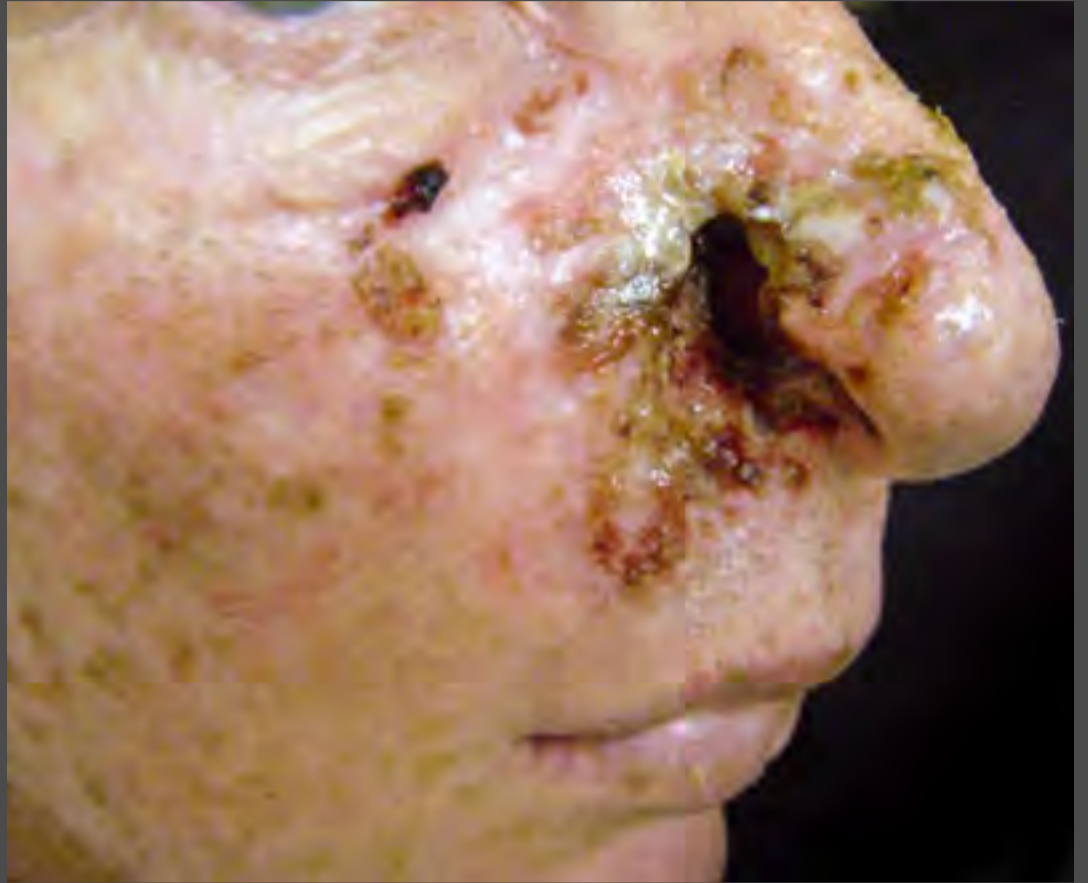
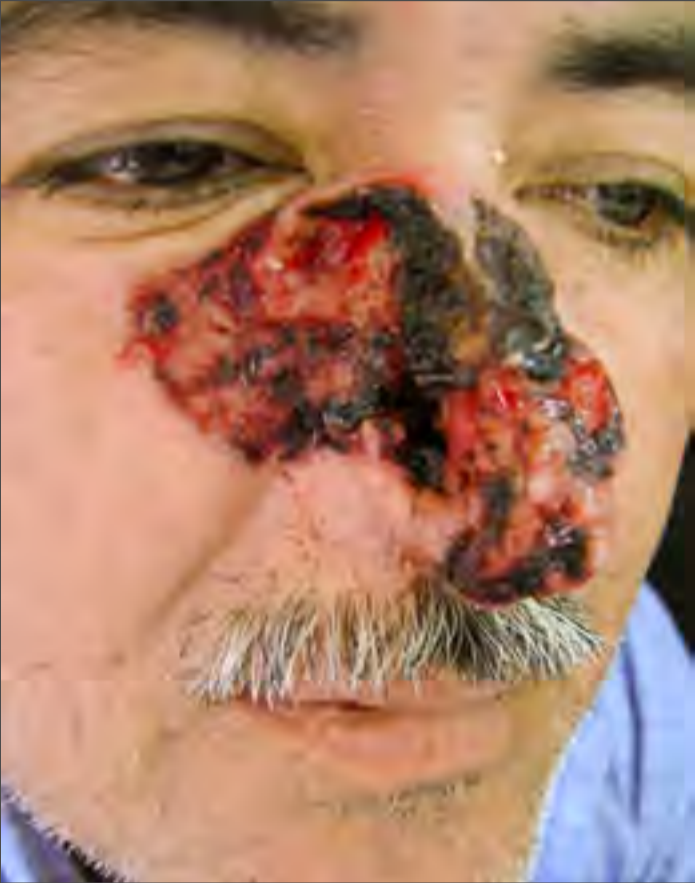**Figures 4.92J and K.**  
Advanced tumors with ocular involvement





## Squamous cell carcinoma



**Figures 4.93A and B.**  
Tumor confirmed by biopsy

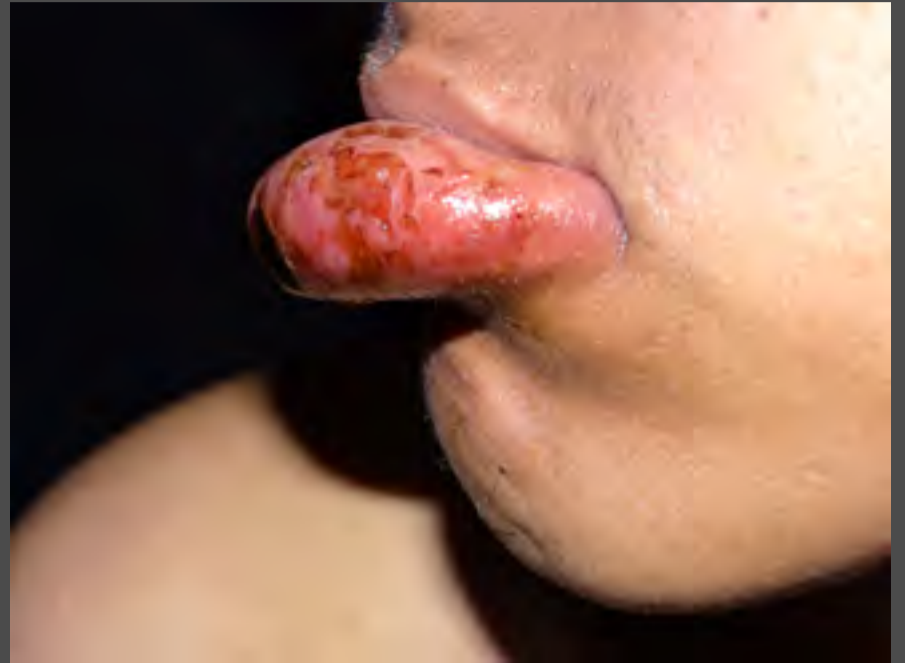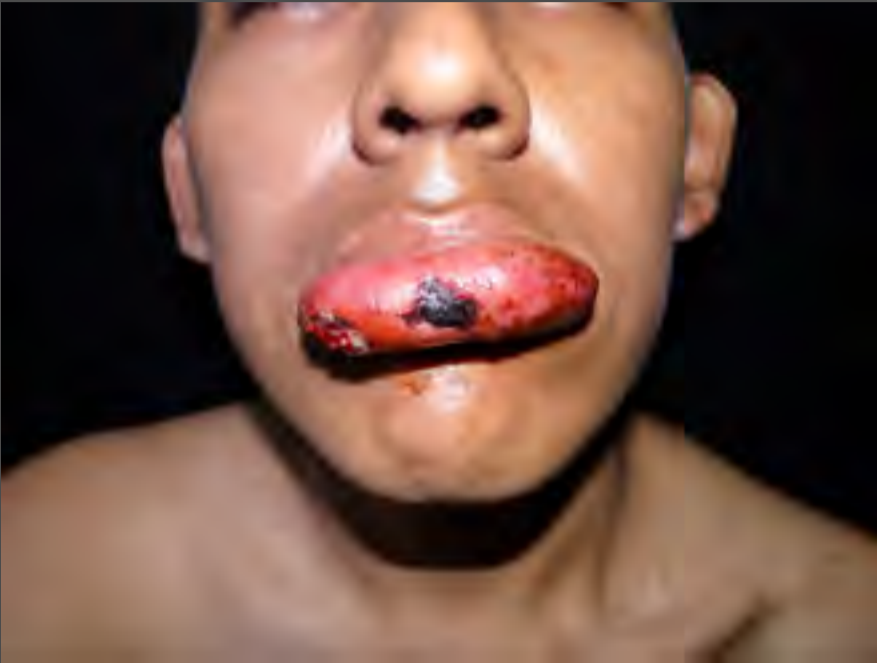**Figure 4.93C.**  
Incipient tumor on hard palate,  
confirmed by biopsy



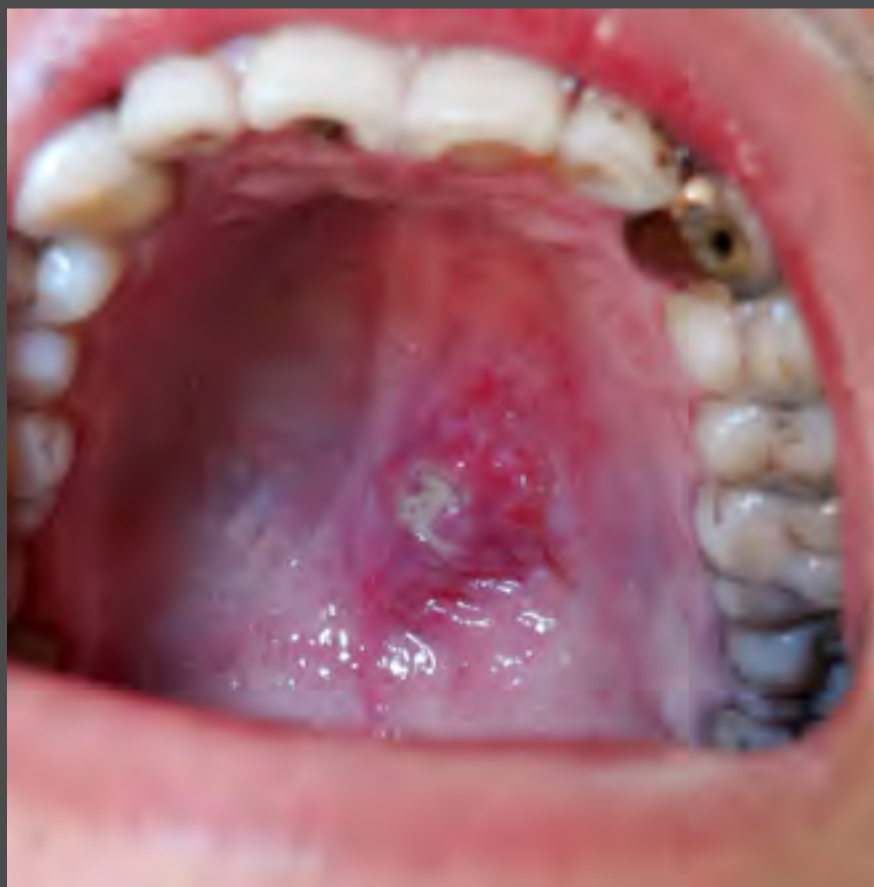*Epidermoid carcinoma.* Tumors of the nasal cavity initially display symptoms similar to those of mucosal leishmaniasis, with obstruction, epistaxis, and pain being the most common. These symptoms do not improve with treatment and lesions grow and can produce destruction, which begins inside the nose and spreads rapidly.

*Cutaneous nasal T cell lymphoma.* This is a very destructive malignant tumor of the midfacial area that can get confused with other tumor or infectious processes and that manifests with rapidly-progressing ulcerated tumor plaques, accompanied by deterioration in general condition and systemic symptoms. It is related to the Epstein-Barr virus and was previously called lethal midline granuloma (*Figures 4.94 a 4.96*).

## Lymphoma



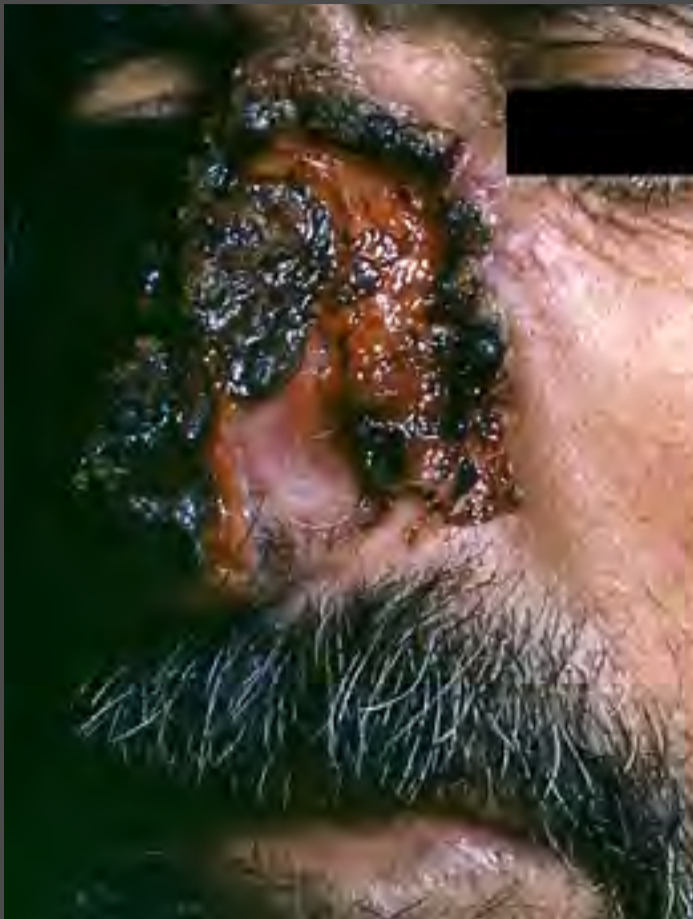**Figures 4.94A and B.**  
Lymphoma confirmed by biopsy,  
rapidly-developing macrochelia



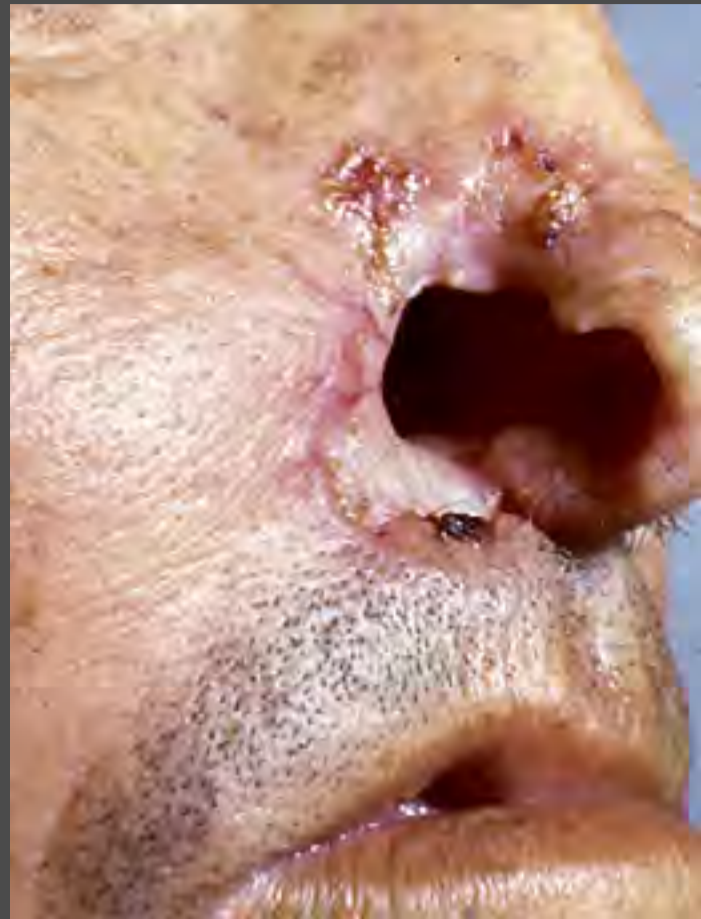**Figure 4.94C.**  
Ulcerated lesion of patient with cutaneous lymphoma



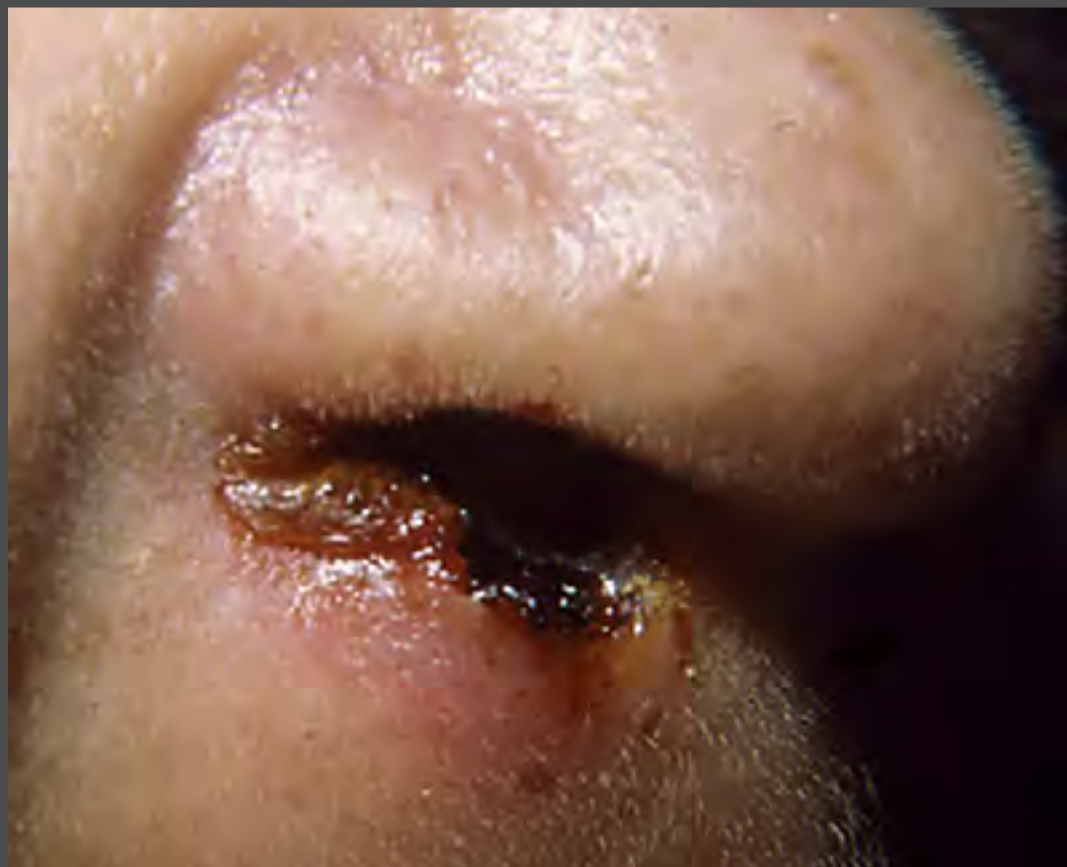## Midline lymphoma



**Figure 4.95A.**  
Extensive nasal destruction. Ulcer and edema of the choana



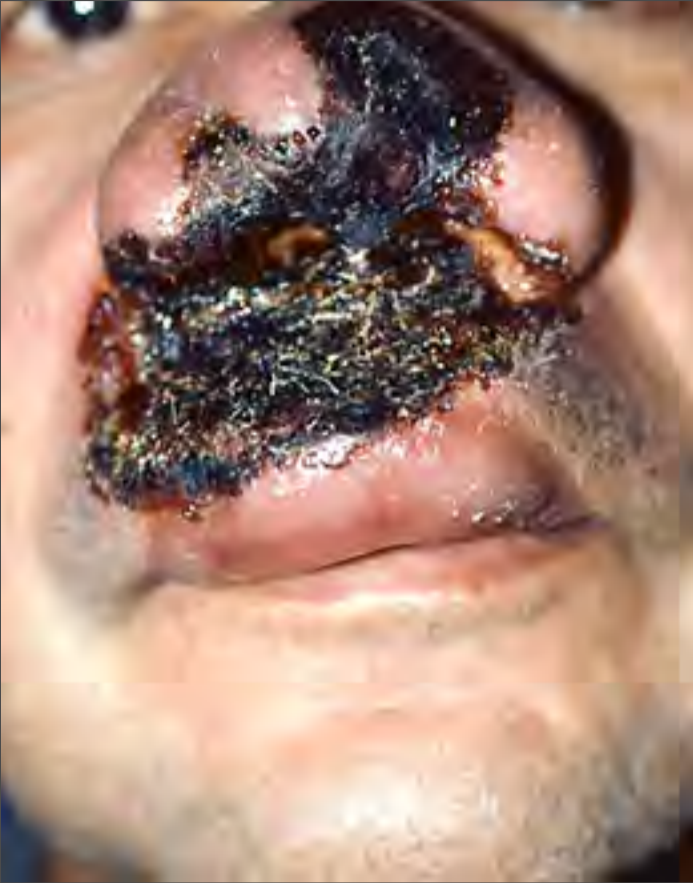**Figure 4.95B.**  
Extensive nasal destruction



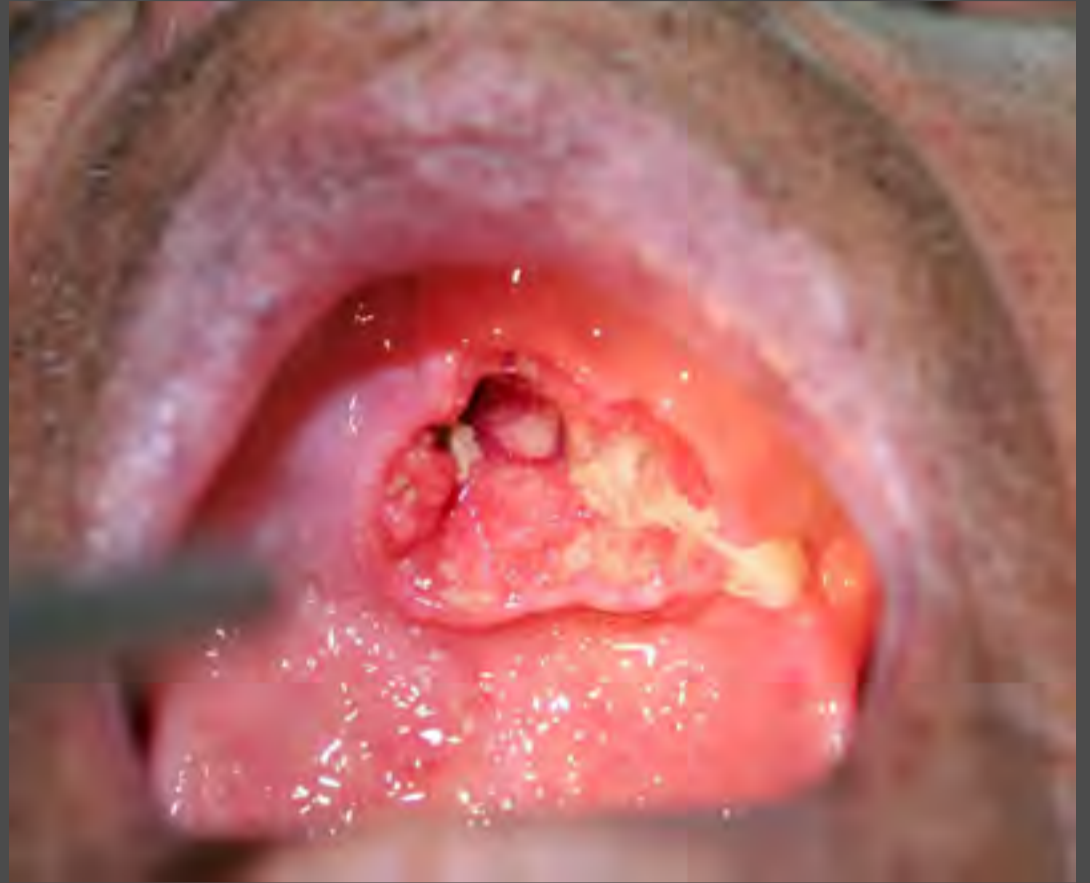**Figure 4.95C.**  
Advanced, ulcerated, and hemorrhagic lymphoid tumor



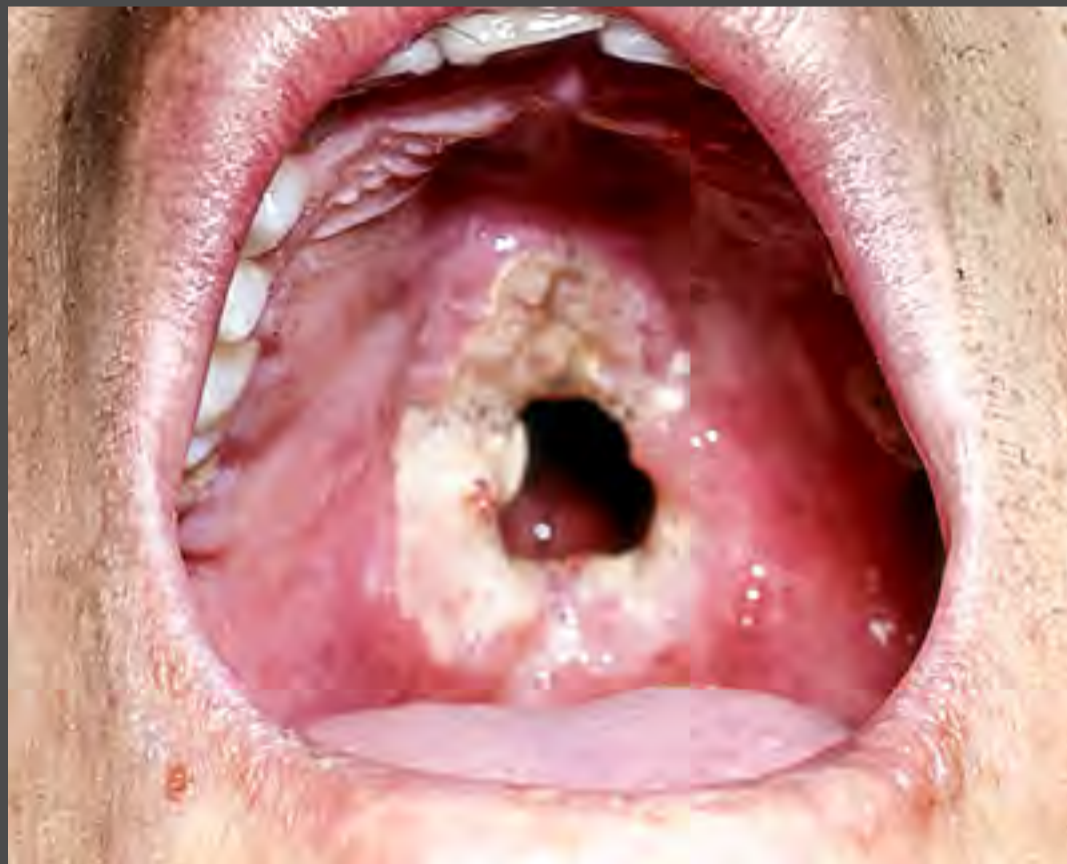## Lymphoid tumor



**Figure 4.95D.**  
Advanced, ulcerated, and hemorrhagic  
lymphoid tumor

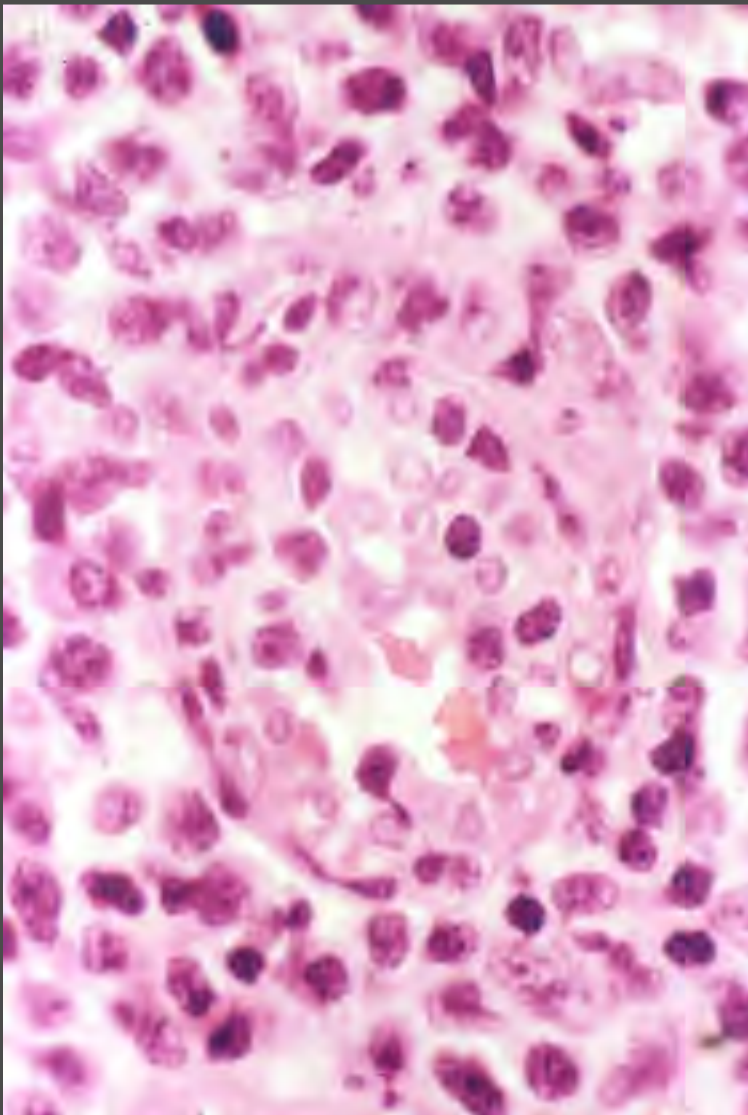
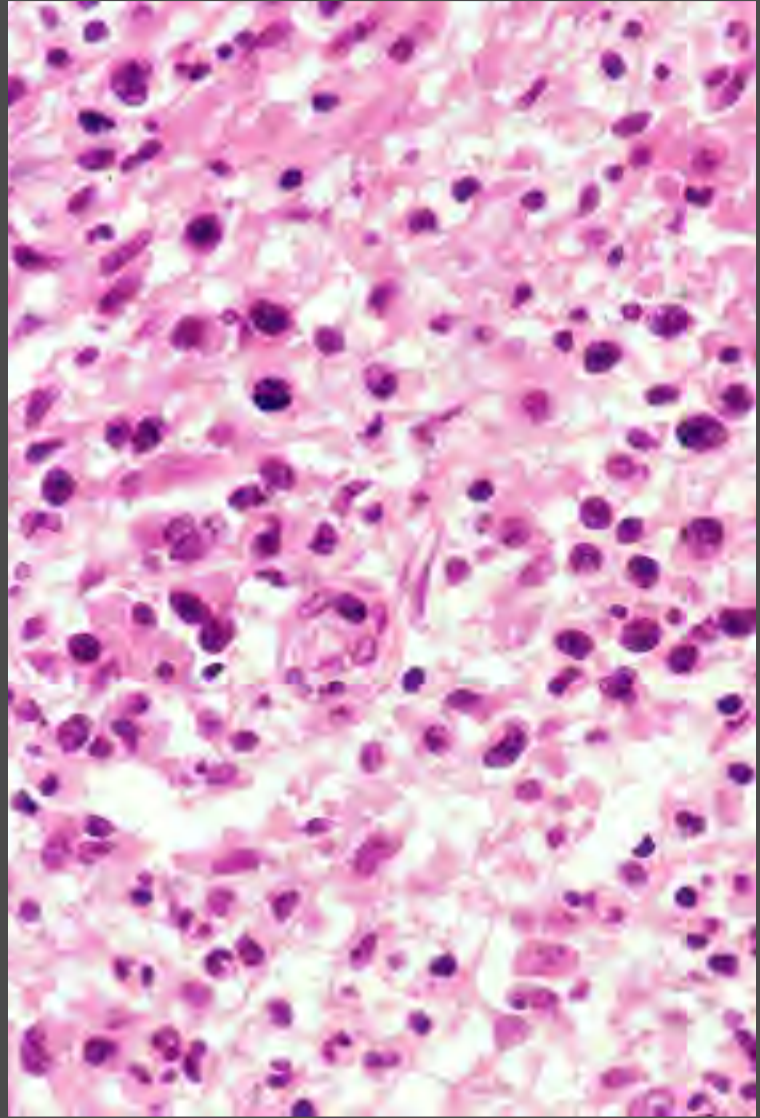
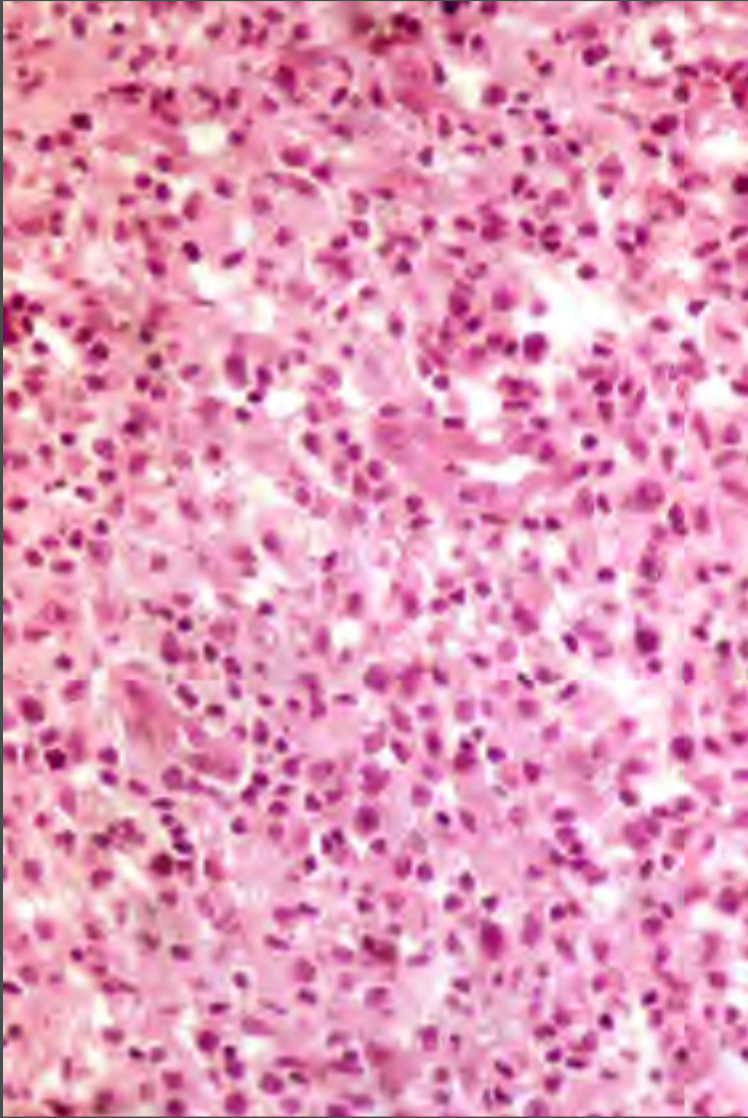


**Figure 4.95E.**  
Lymphoma



**Figure 4.95F.**  
Perforation of the palate is not typical of mucous leishmaniasis.  
This lesion primarily suggests an angiocentric lymphoma.

## Angiocentric lymphoma



**Figures 4.96A and B.**  
Diffuse infiltration of lymphoid cells;  
hematoxylin and eosin, 40X

**Figure 4.96C.**  
Diffuse infiltration with atypia and  
mitosis that tend to surround the vessels;  
hematoxylin and eosin, 100X.

## Miscellaneous

***Banal perforation of the nasal septum.*** This is mucosal ulceration and rupture of the septum that can result from repeated mild trauma, like nose picking, atrophic rhinitis, prior surgeries, repeated exposure to strong vapors, use of vasoconstrictors, or snorting cocaine. There is rhinorrhea, epistaxis, dryness and, sometimes, noisy breathing. The diagnosis is based on a good case history and on ruling out other possibilities.

Table 4.4. Differential diagnosis of mucosal leishmaniasis (in order of frequency)

Infections	Tumors	Miscellaneous
<ul style="list-style-type: none"> <li>• Paracoccidioidomycosis</li> <li>• Leprosy</li> <li>• Tuberculosis</li> <li>• Histoplasmosis</li> <li>• Syphilis</li> <li>• Rhinoscleroma</li> <li>• Rhinosporidiosis</li> <li>• Rhinoentomophthoromycosis</li> <li>• Mucormycosis</li> </ul>	<ul style="list-style-type: none"> <li>• Basal cell carcinoma</li> <li>• Squamous cell carcinoma</li> <li>• Epidermoid carcinoma</li> <li>• Cutaneous nasal T cell lymphoma</li> </ul>	<ul style="list-style-type: none"> <li>• Banal perforation of nasal septum</li> <li>• Rhinophyma</li> <li>• Sarcoidosis</li> <li>• Cocaine use</li> <li>• Granulomatosis with polyangiitis (previously known as Wegener's granulomatosis)</li> </ul>

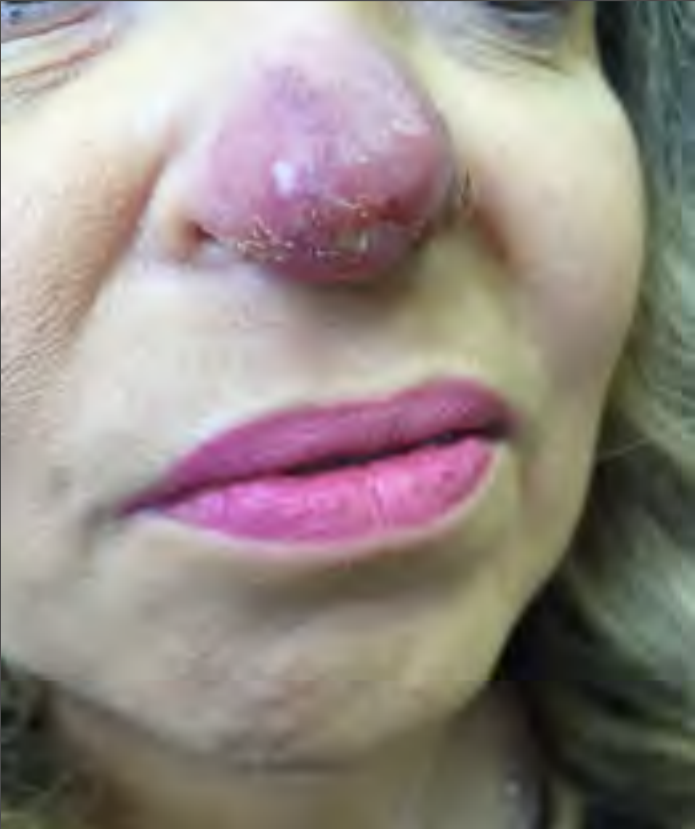**Rhinophyma.** This is a deformity of the skin of the nose as a result of hypertrophy of the local sebaceous glands, chronic inflammation, and increase in the blood vessels that cause the tip and nasal alae to become bulbous, lobed, and granular, increasing greatly in volume and deforming it. It is not very symptomatic and there is always a history related to rosacea, alcohol consumption, or chronic exposure to sources of heat.

**Sarcoidosis.** Lupus pernio is a form of sarcoidosis that affects the nose and surrounding skin with groups of reddish-purple infiltrated, granular plaques that may occasionally ulcerate and destroy the bone and cartilage. It frequently involves other organs, has a chronic course, and poor response to treatment (*Figure 4.97*).

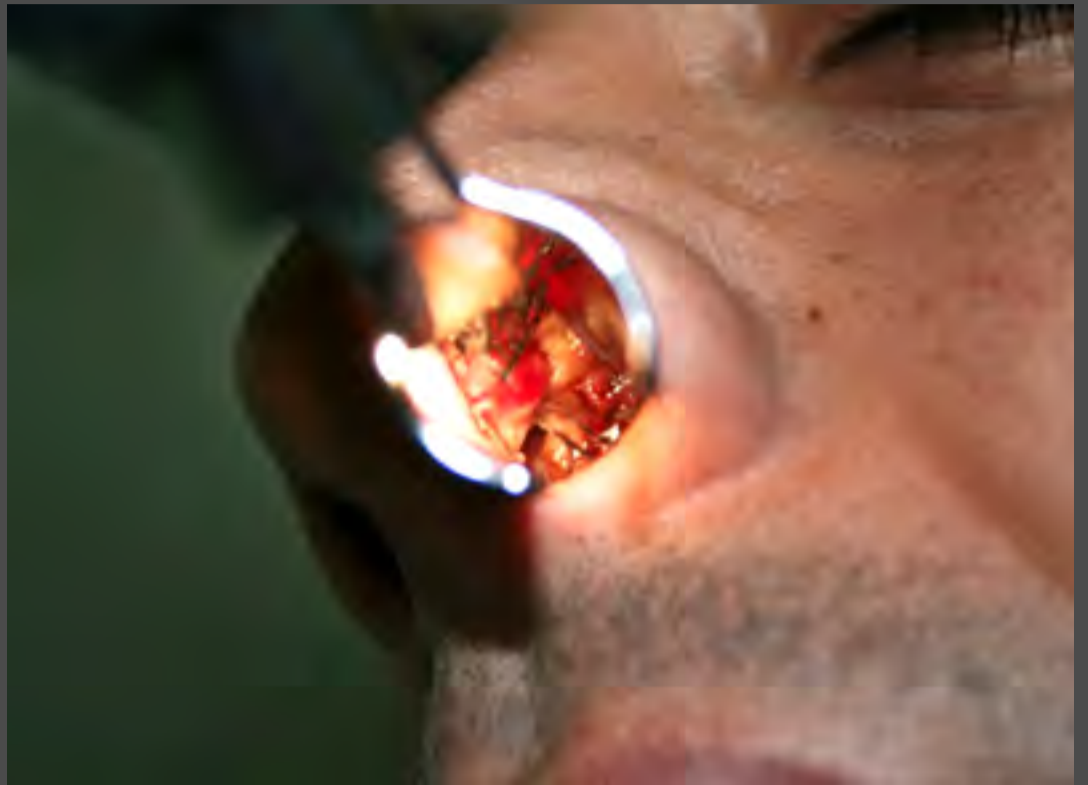**Cocaine use.** Chronic and repeated consumption of cocaine by nasal inhalation can cause destructive lesions of the septum and of the palate as a consequence of extreme vasoconstriction, the presence of contaminants (levamisole, mannitol, lactose) and microtraumas from inhaling its particles at high speed. There are no specific diagnostic characteristics and the clinical history can lead to suspecting this cause, once other possible causes are ruled out (*Figure 4.98*).

**Granulomatosis with polyangiitis (previously known as Wegener's granulomatosis).** Involvement of the upper respiratory tract is frequent in this severe systemic granulomatous vasculitis; it manifests with nasal obstruction, pain, bleeding, and perforation of the septum. There are usually manifestations of the involvement of other organs, such as the lung and kidney, and papules, nodules, plaques, and ulcers on other areas of the skin (*Figures 4.99 and 4.100*).

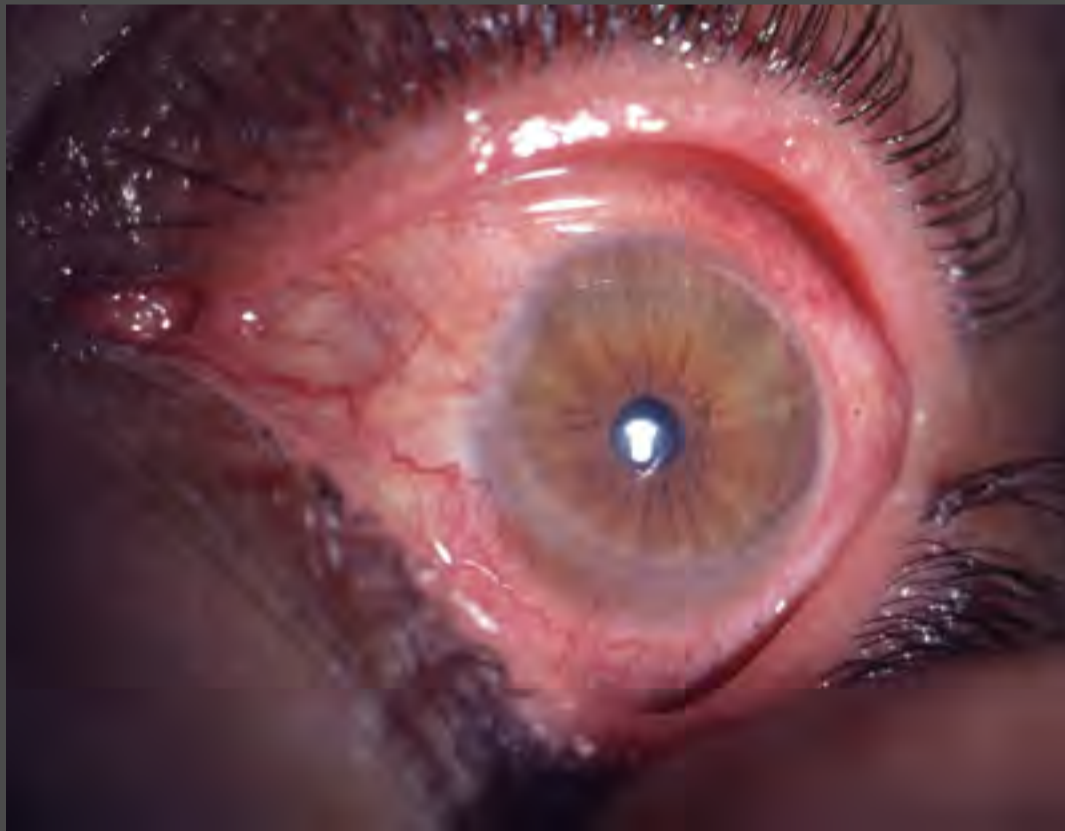



**Figure 4.97.**  
Sarcoidosis. Infiltrative lesion in the external nasal area



**Figure 4.98.**  
Destruction of the nasal septum from chronic cocaine snorting

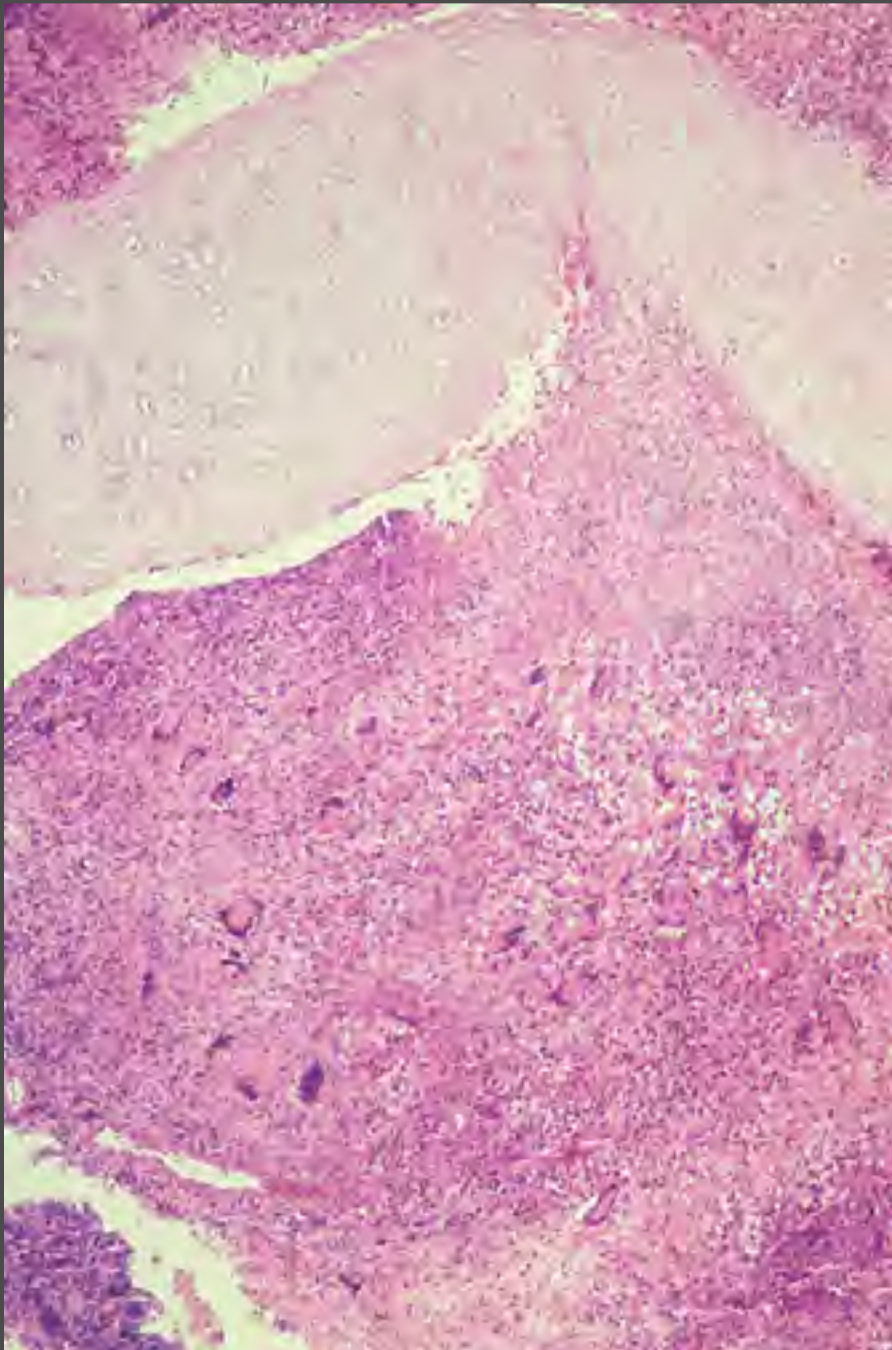
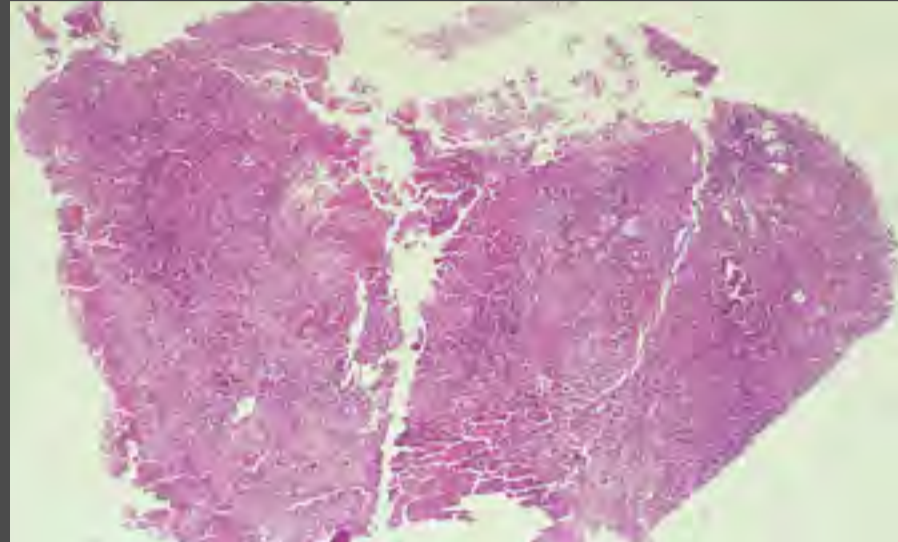


**Figure 4.99.**  
Granulomatosis with polyangiitis (previously known as Wegener's granulomatosis). Ocular lesion

## Granulomatosis with polyangiitis. Biopsy of the nasal mucosa

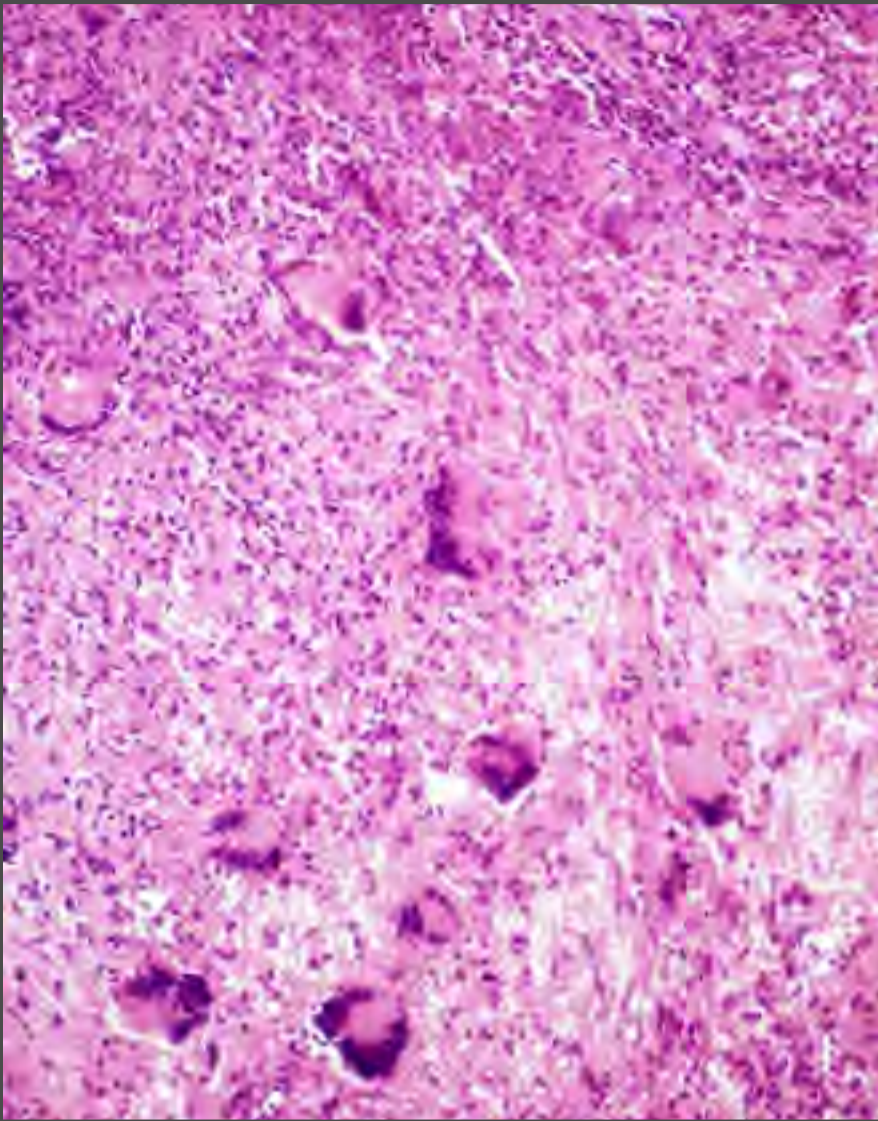
**Figure 4.100A.**

Ulcerated lesion with diffuse inflammation of the corium or lamina propria of the mucosa; hematoxylin and eosin, 2.5X

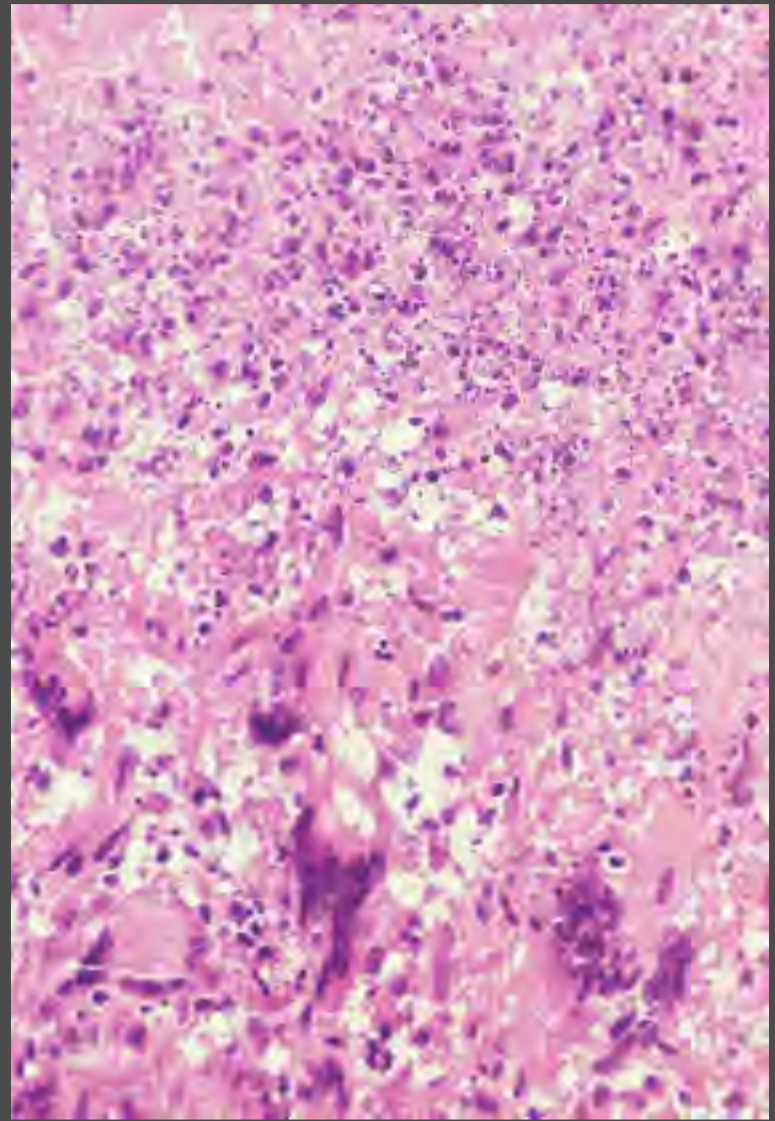
**Figure 4.100B.**

Inflammation compresses the cartilage and is rich in giant cells, a characteristic absent in mucosal leishmaniasis; hematoxylin and eosin, 6.3X.

## Granulomatosis with polyangiitis. Biopsy of the nasal mucosa

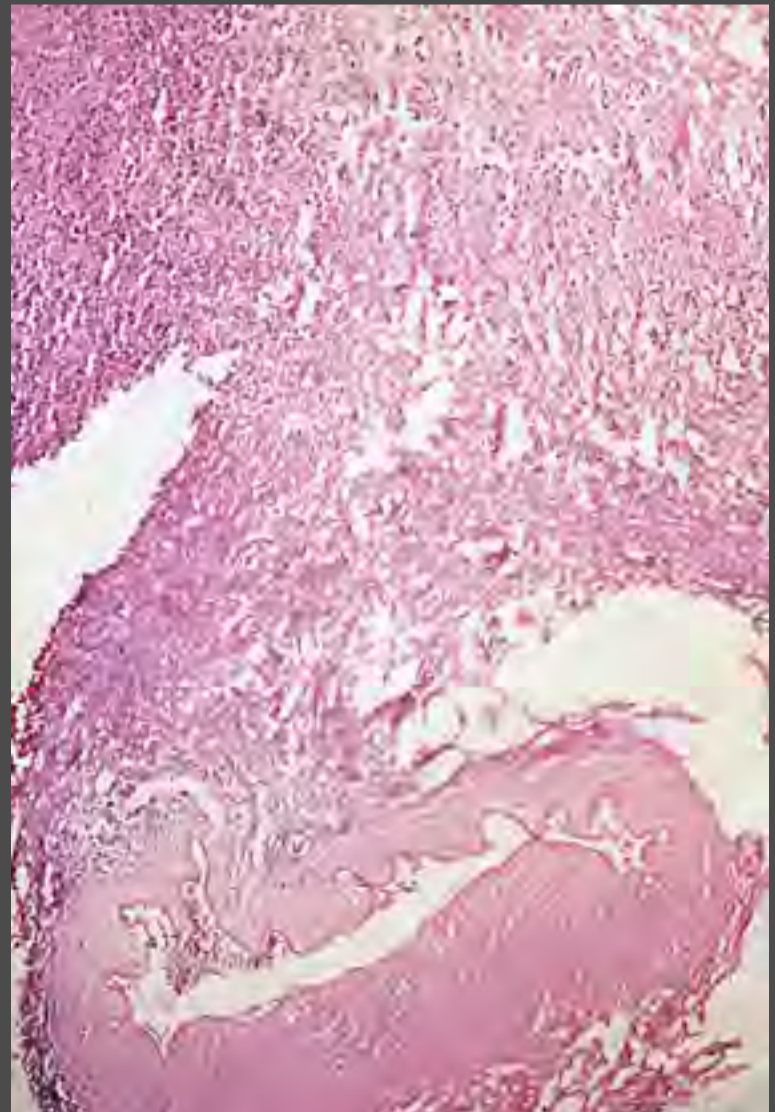


**Figure 4.100C.**  
Granuloma rich in giant cells; hematoxylin and eosin, 10X



**Figure 4.100D.**  
Area of lymphocyte apoptosis with numerous giant cells; hematoxylin and eosin, 20X.

**Figure 4.100E.**  
The artery (below) has fibrinoid necrosis of its wall. Some of the internal elastic lamina persists. Above, the necrosis is extensive; hematoxylin and eosin, 6.3X.



## Recommended Reading

- Amato VS, Tuon FF, Siqueira AM, Nicodemo AC, Amato V. Treatment of mucosal leishmaniasis in Latin America: Systematic review. *Am J Trop Med Hyg.* 2007;77:266-74.
- Boggild AK, Valencia BM, Veland N, Ramos AP, Calderón F, Arévalo J, *et al.* Non-invasive cytology brush PCR diagnosis testing in mucosal leishmaniasis: Superior performance to conventional biopsy with histopathology. *PLoS One.* 2011;6:e26395. doi: 10.1371/journal.pone.00226395.
- Carvalho LP, Passos S, Bacellar O, Lessa M, Almeida RP, Magalhaes A, *et al.* Differential immune regulation of activated T cells between cutaneous and mucosal leishmaniasis as a model for pathogenesis. *Parasite Immunol.* 2007;29:251-8.
- Giudice A, Vendrame C, Bezerra C, Carvalho LP, Delavechia T, Carvalho EM, *et al.* Macrophages participate in host protection and the disease pathology associated with *Leishmania braziliensis* infection. *BMC Infect Dis.* 2012;12:75. doi: org/10.1186/14712334-12-75.
- Jara M, Valencia BM, Adauí V, Alba M, Arévalo J, Llanos-Cuentas A, *et al.* Quantitative kineplast DNA assessment during treatment of mucosal leishmaniasis as a potential biomarker of outcome: A pilot study. *Am J Trop Med Hyg.* 2016;94:107-13. doi: 10.4269/ajtmh.15-0514.
- Llanos-Cuentas EA, Echevarría J, Cruz M, La Rosa A, Campos P, Campos M, *et al.* Efficacy of pentostam alone and in combination with allopurinol in the treatment of mucocutaneous leishmaniasis. *Clin Infect Dis.* 1997;25:677-84.
- Machado RL, Lessa H, Lessa M, Guimarães LH, Bang H, Ho JL, *et al.* Oral pentoxifylline combined with pentavalent antimony: A randomized trial for mucosal leishmaniasis. *Clin Infect Dis.* 2007;44:788-93. doi: 10.1086/511643.
- Marsden PD. Mucosal leishmaniasis due to *Leishmania (Viannia) braziliensis* in Três Braços, Bahia, Brazil. *Rev Soc Bras Med Trop.* 1994;27:93-101.
- Pan American Health Organization. Leishmaniasis in the Americas: Treatment recommendations. Washington, D.C.: PAHO; 2018.
- World Health Organization. Control of the leishmaniasis: Report of a Meeting of the WHO Expert Committee on the Control of Leishmaniasis. Technical Report Series, No. 949. Geneva: WHO; 2010.

# CHAPTER 5

Visceral Leishmaniasis,  
Post-Kala-Azar and  
Para-Kala-Azar  
Dermal Leishmaniasis



# Visceral Leishmaniasis



Dorcas Lamounier Costa and Carlos  
Henrique Nery Costa



## Definition, Agent, Vectors, and Reservoirs

Visceral leishmaniasis is the most serious presentation of the leishmaniasis, primarily affecting the poorest populations in 75 countries of Asia, East Africa, South America, and the Mediterranean region.

The two main species that cause visceral leishmaniasis (also known as kala-azar in India) belong to the *Leishmania donovani* complex—*L. donovani* (syn. *L. archibaldi*) of the Old World and *L. (L.) infantum* (syn. *L. (L.) chagasi*) of the New World—and are transmitted by various Phlebotominae species.

Visceral leishmaniasis is the most severe form; it is the second most lethal parasitic disease in the world, surpassed only by malaria. Mortality can reach 100% in two years if it is not treated. The disease caused by *L. donovani* in India and eastern Africa is anthroponotic; in the other endemic regions, the disease is a zoonosis that affects many mammal species. In the New World, it is transmitted by the bite of a phlebotomine sand fly of the genus *Lutzomyia*. On rare occasions, transmission can occur directly by intravenous drug use, accidents with contaminated needles, blood transfusion, or placentally.

*Leishmania (L.) infantum*, the species that causes visceral leishmaniasis in the Region of the Americas, are digenetic organisms; i.e., they have an invertebrate host, the phlebotomine, and a vertebrate host, a mammal. In the invertebrate hosts, the parasite has a flagellate form, and in the vertebrate hosts, it has the amastigote form, with no apparent flagellum.

The phlebotomine vector that transmits visceral leishmaniasis belongs to the order Diptera, family Psychodidae, and subfamily Phlebotominae. The insects that transmit the leishmaniasis in the Americas belong to the genus *Lutzomyia*, whose principal species are *Lutzomyia longipalpis* (Figure 5.1), *Lu. cruzi*, and *Lu. evansi*. The larval stage of the phlebotomine develops in a solid substratum, shady and rich in organic matter, as well as in the hollows of trees, caverns, stables, gardens, etc.

In general, wild canids have been identified as the wild reservoirs of *L. (L.) infantum*, and the most abundant species in the Americas are *Cerdocyon thous* and *Speothos venaticus*. Furthermore, *Didelphis marsupialis* and *D. albiventris* are also potential reservoirs of *L. infantum*. Domestic dogs are the principal reservoirs of *L. (L.) infantum* in urban environments; they are infectious for the vector and responsible for maintaining transmission (Figure 5.2).



**Figure 5.1.**  
*Lutzomyia longipalpis*, principal vector of *Leishmania infantum*



**Figure 5.2.**  
Visceral leishmaniasis in a dog. Note thinness, long nails, and alopecia.





## Clinical Manifestations

Clinical manifestations of visceral leishmaniasis range from inapparent or oligosymptomatic infections (*Figures 5.3*) to progressive and potentially fatal infections (*Figure 5.4*). The majority of individuals infected by *Leishmania* spp. do not present signs or symptoms of the disease, and it is estimated that 20% develop the classical form of visceral leishmaniasis; for this reason, it is important to do a detailed clinical examination when the disease is suspected (*Figures 5.5*). Factors that determine the severity of clinical manifestations can be related to environmental conditions, age, nutritional status, and the individual's initial immune reaction.

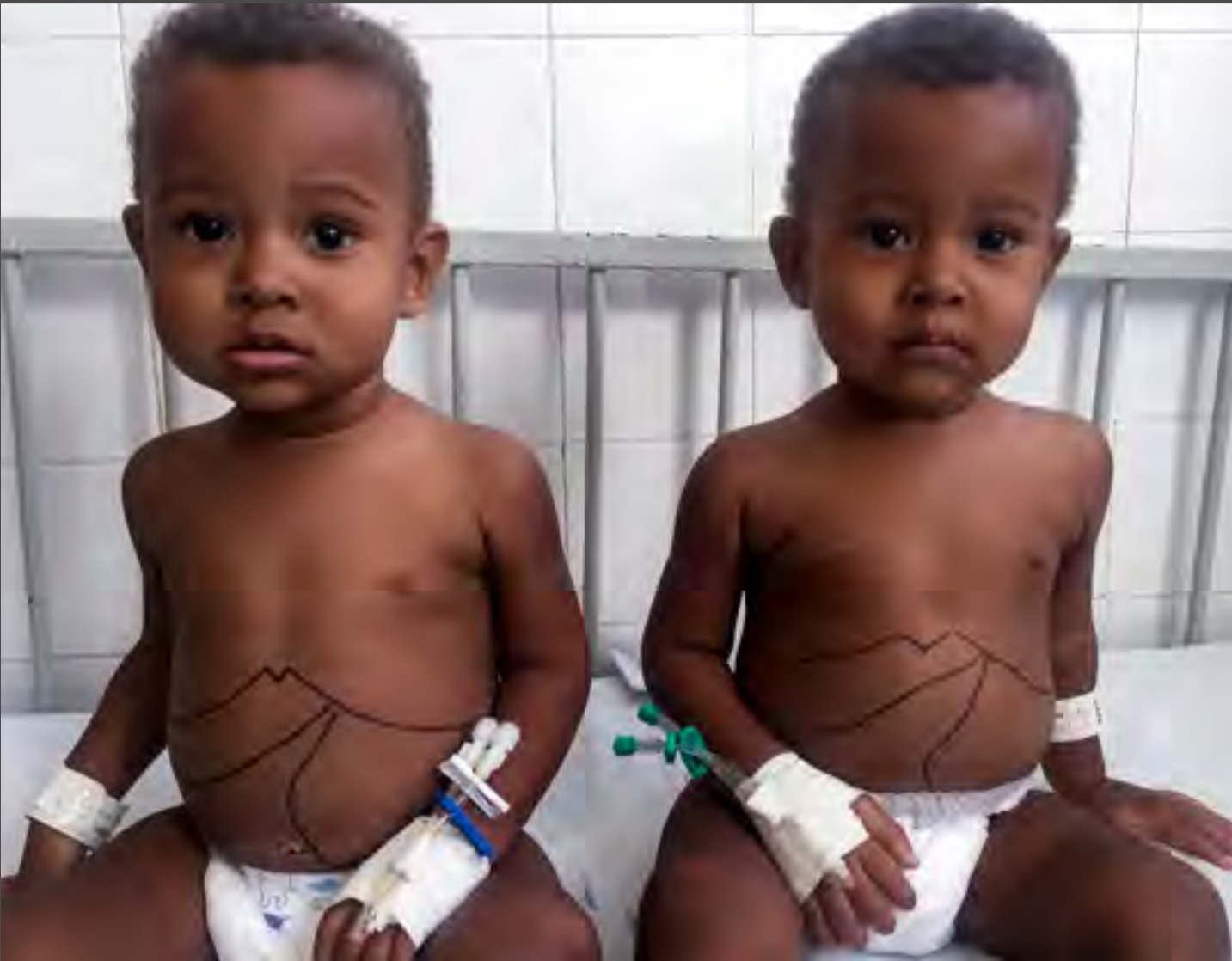The incubation period for visceral leishmaniasis is variable; however, in general, it lasts from three to eight months. Usually, the beginning and the course of the disease are subacute or chronic, although they can be acute. The disease is particularly more severe in children (*Figures 5.6*), the elderly, and patients with some type of immunodeficiency (*Figures 5.7*).

As inapparent or asymptomatic infections have no clinical manifestations, infection is verified through epidemiological studies, serological testing, or the Leishmanin test. Antibody titers in peripheral blood are usually low and may remain positive over a prolonged period.

In the oligosymptomatic form, the clinical condition is discrete, has a short duration, and frequently progresses to spontaneous remission.



## Visceral leishmaniasis



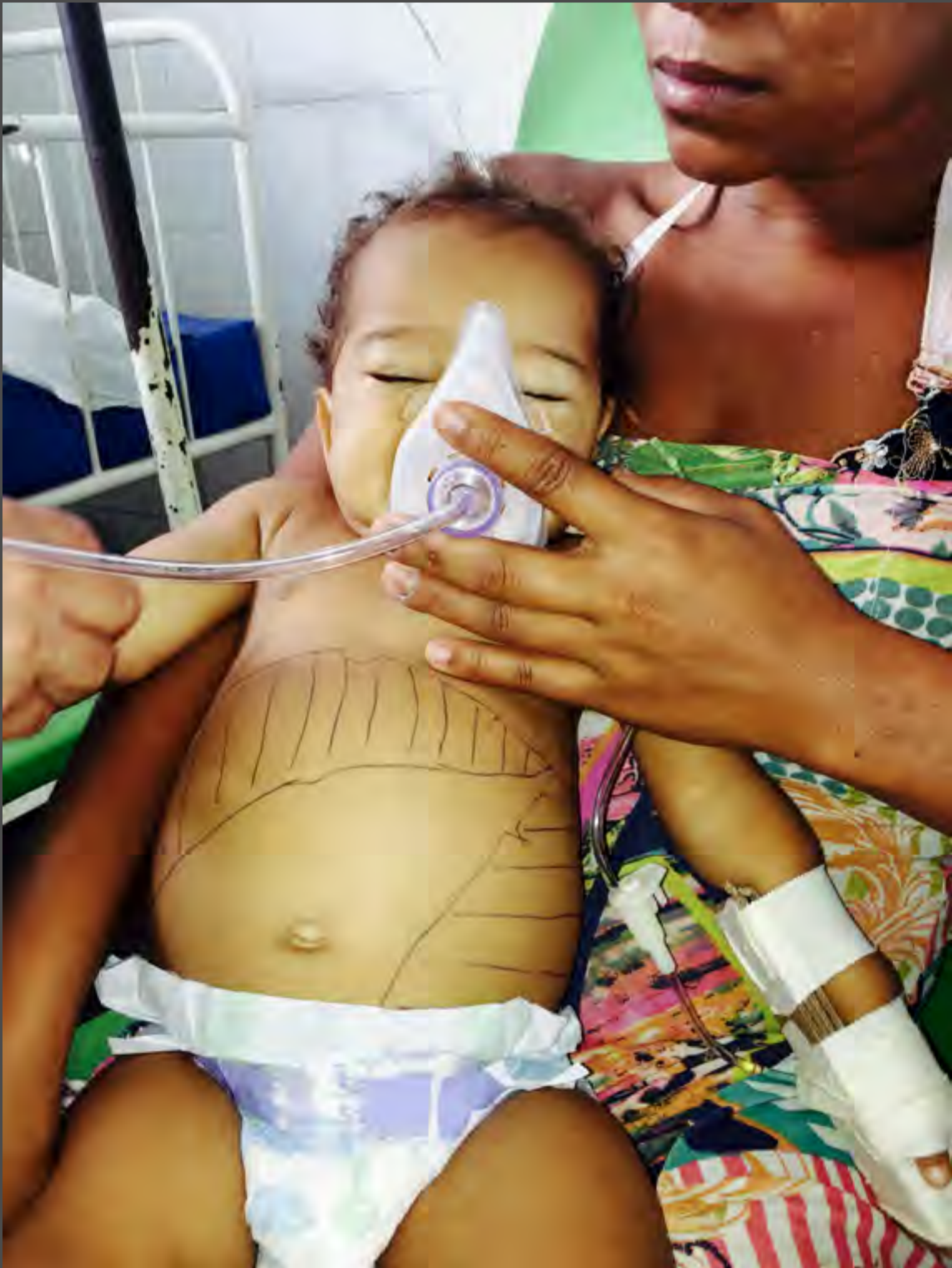**Figure 5.3A.**  
Infant twins, with  
concomitant signs  
and symptoms



**Figure 5.3B.**  
Infant twins on  
their fifth day  
of treatment  
with liposomal  
amphotericin  
B, with notable  
improvement  
in their general  
condition



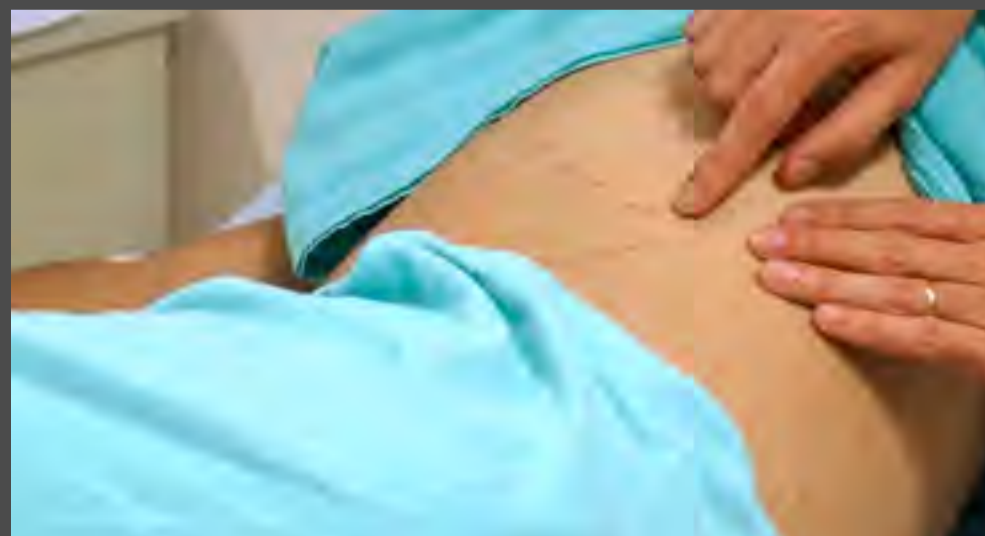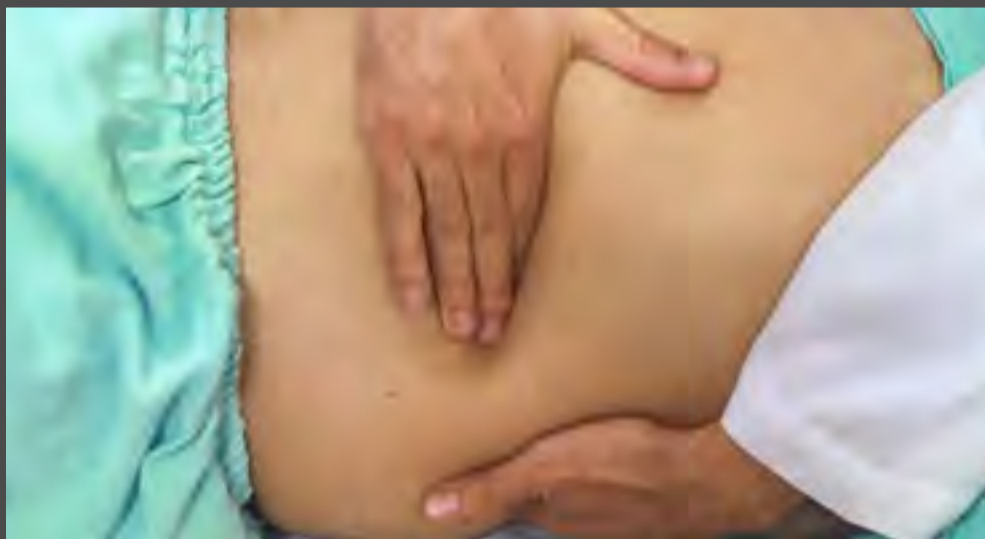## Visceral leishmaniasis



**Figure 5.4.**  
Severe visceral leishmaniasis. Infant with edema and respiratory failure



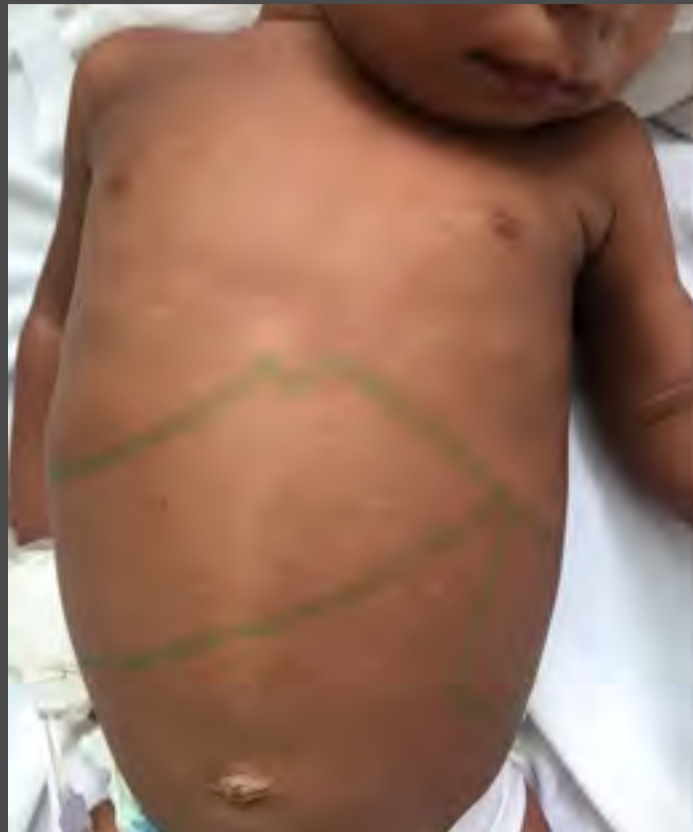## Visceral leishmaniasis



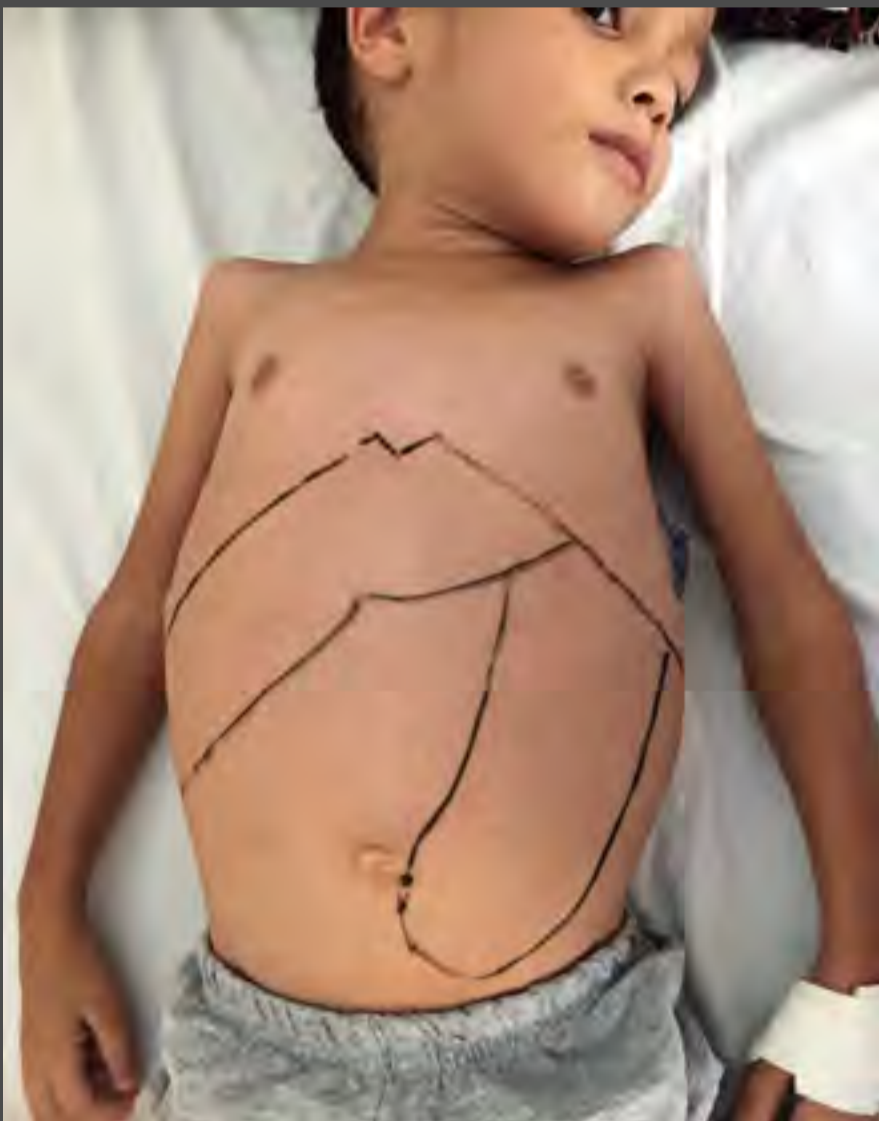Figures 5.5A, B, C and D.  
Clinical examination. Palpation of liver and spleen in patients with clinical suspicion of visceral leishmaniasis



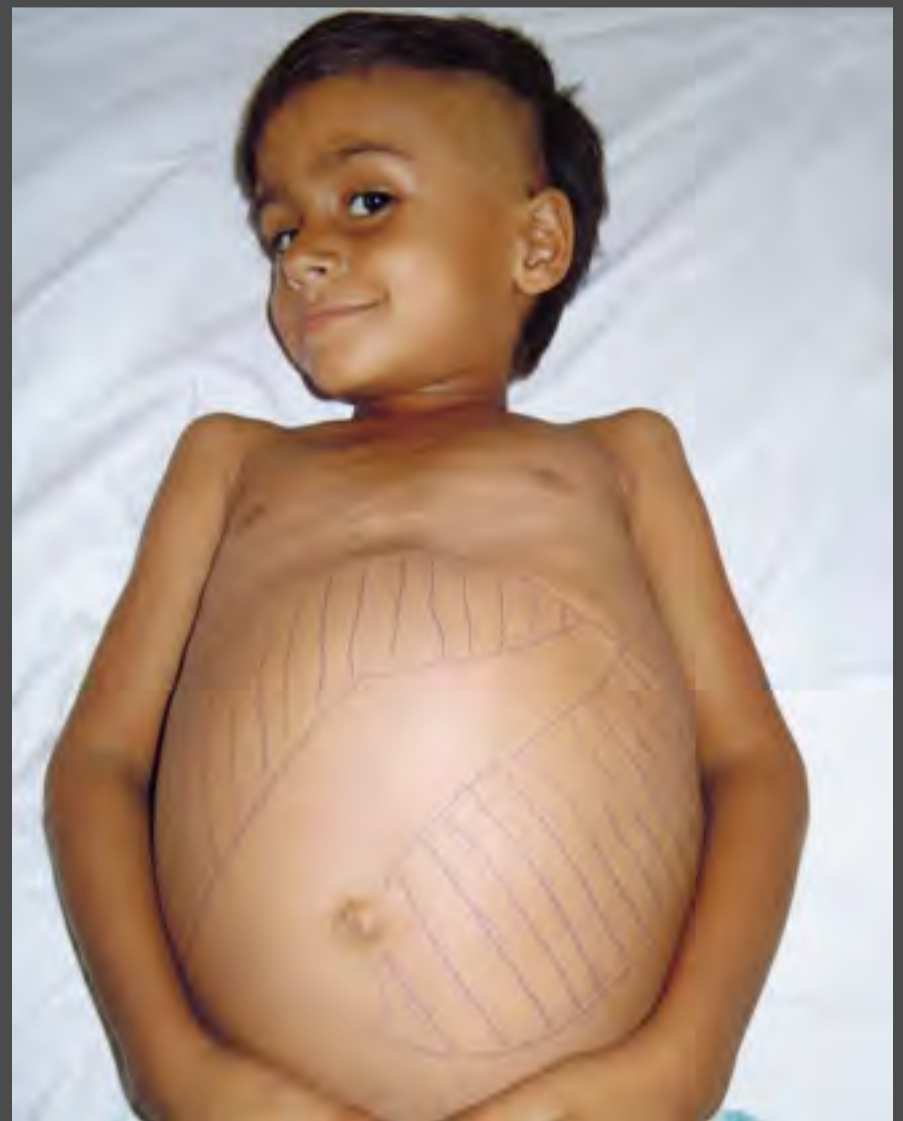## Visceral leishmaniasis



**Figure 5.6A.**  
Infant with hepatosplenomegaly, before treatment



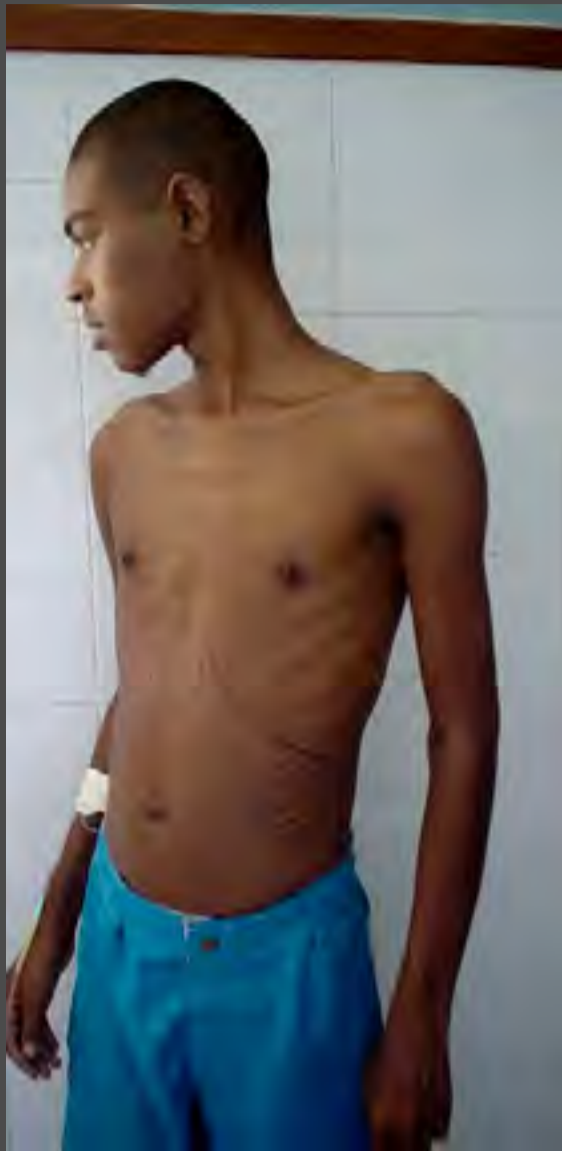**Figure 5.6B.**  
Child with hepatosplenomegaly and cutaneous pallor



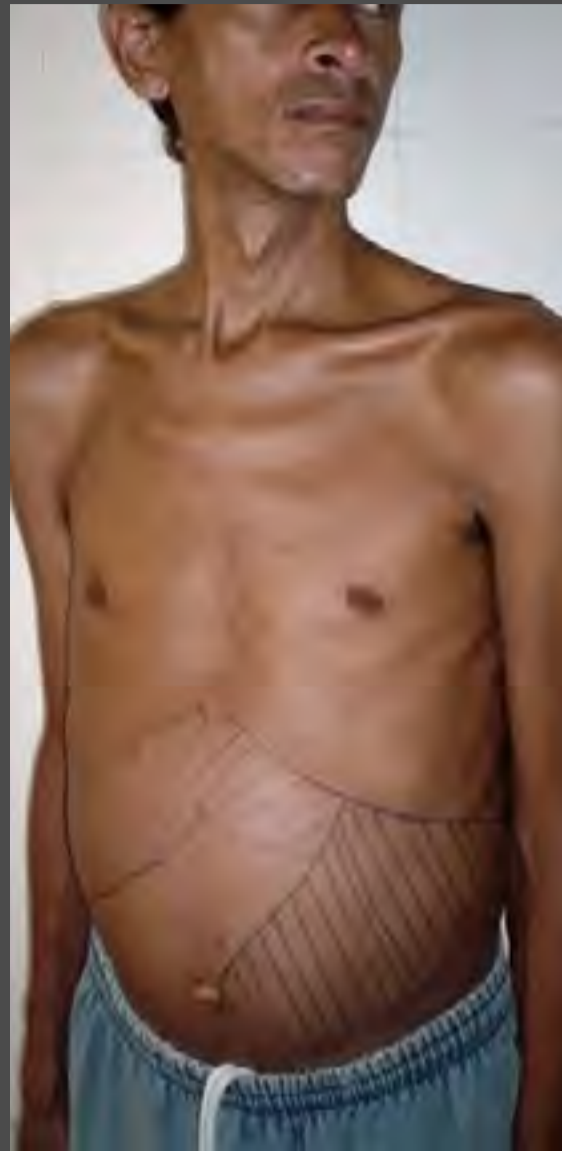**Figure 5.6C.**  
Schoolchild with significant hepatosplenomegaly and weight loss, despite good general condition, three months after onset



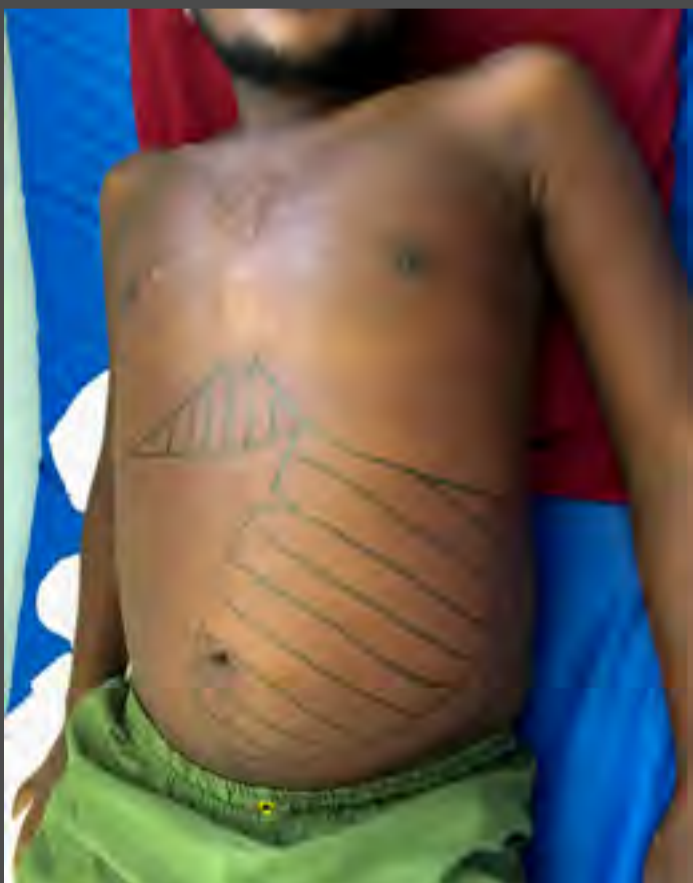## Visceral leishmaniasis



**Figure 5.7A.**  
Young person with  
hepatosplenomegaly and weight loss



**Figure 5.7B.**  
Adult with malnutrition and  
significant splenomegaly



**Figure 5.7C.**  
Adult with hepatosplenomegaly;  
spleen much more involved  
than liver



Viscerotropic oligoparasitic syndrome, observed in United States soldiers who served in the Persian Gulf War, has nonspecific manifestations caused by *L. tropica*, a species circulating in the Old World.

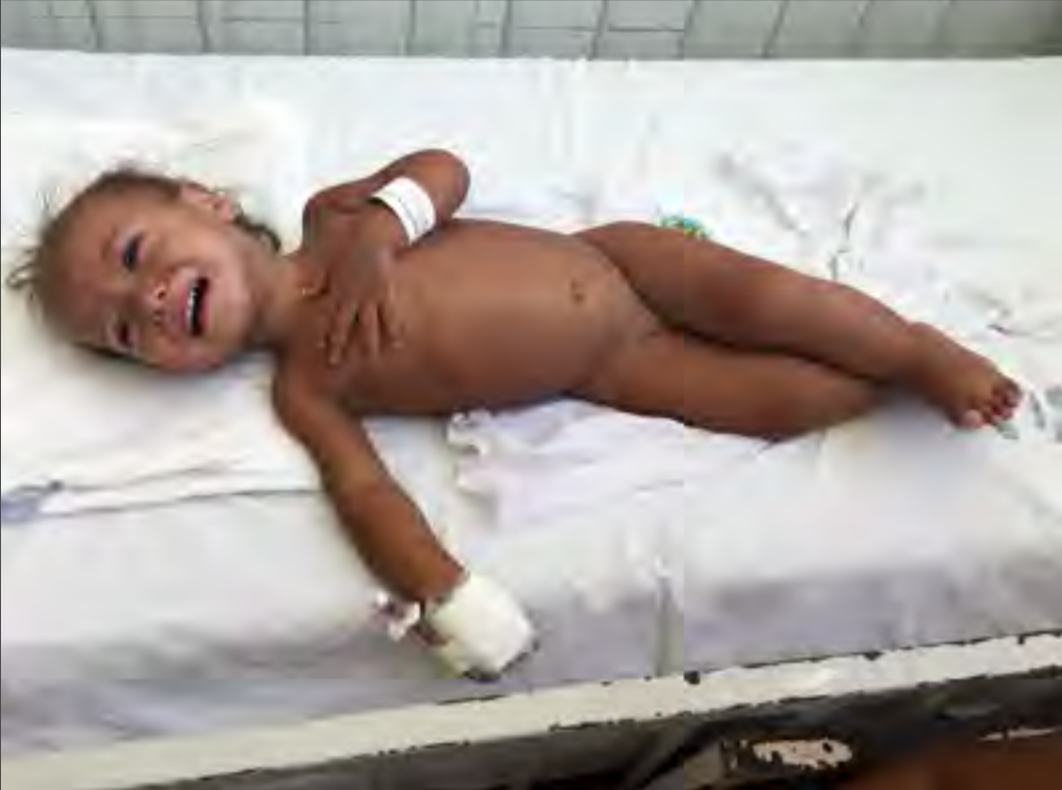The classic form of the disease is characterized by prolonged fever, pallor, loss of appetite, weight loss (*Figures 5.8*), and hepatosplenomegaly (*Figures 5.9*). Increase in spleen size is almost always more evident than increase in liver size. Lymphadenopathy is frequent in patients from India and Sudan, although less common in New World visceral leishmaniasis.

Disease severity varies greatly, and atypical presentations are common, especially in immunocompromised individuals. Symptoms can persist for weeks or months and patients can be debilitated and incapacitated from carrying out their usual activities at the time of diagnosis. Children may become apathetic or irritable (*Figures 5.10*) and report restless sleep. Fever can be intermittent or remittent, although it is usually tolerable, which can delay seeking medical care. Chills may occur, causing diagnostic confusion with malaria or bacteremia.

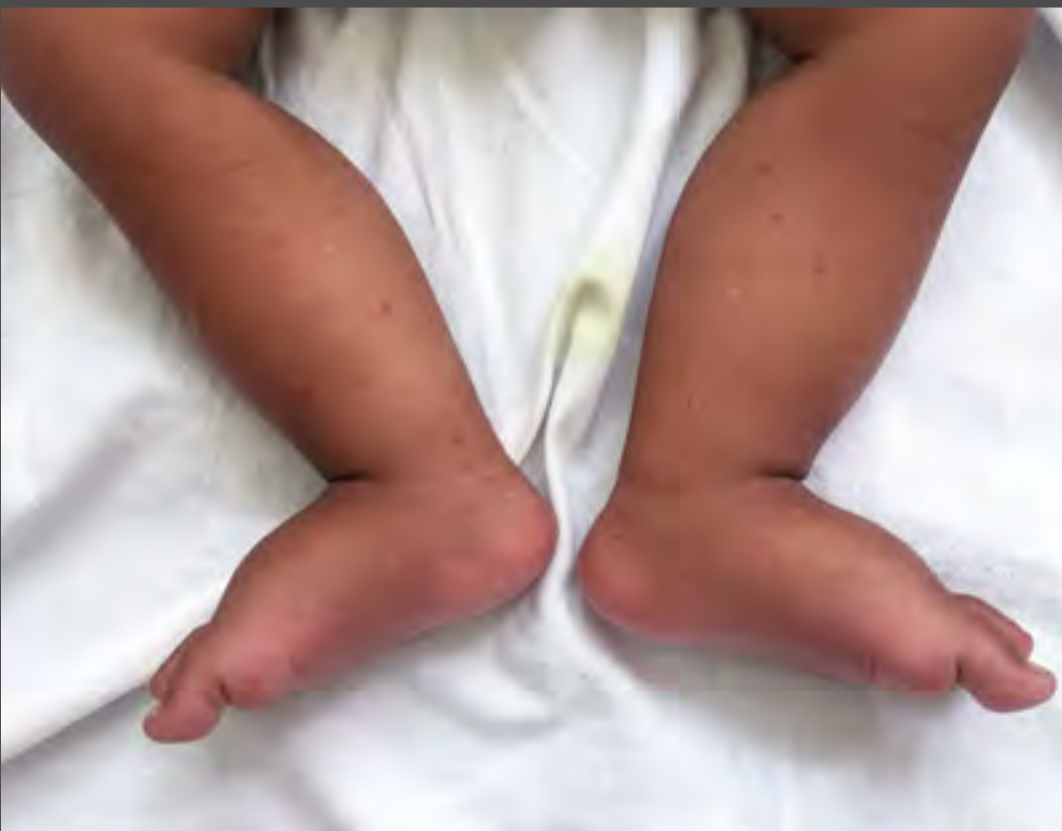
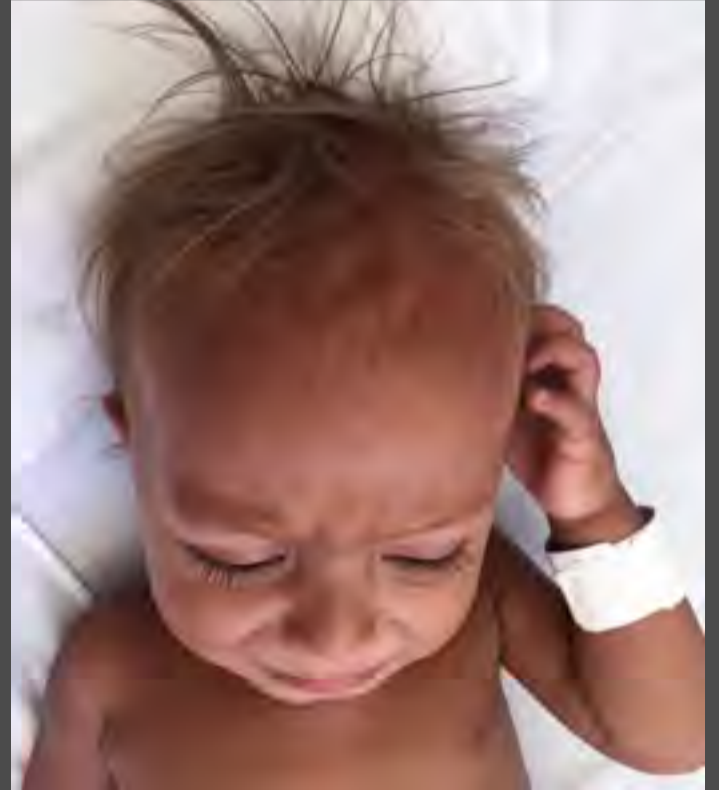
## Visceral leishmaniasis

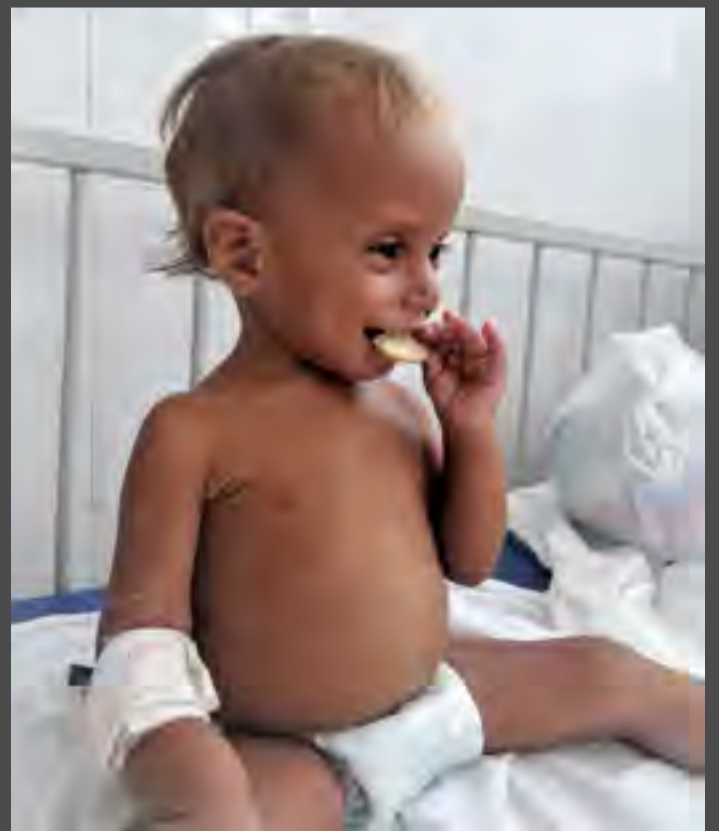**Figure 5.8A.**  
Malnourished irritable infant, before treatment



**Figure 5.8B.**  
Malnourished infant with alopecia and lengthening of eyelashes, before treatment



**Figure 5.8C.**  
Edema of the feet, before treatment



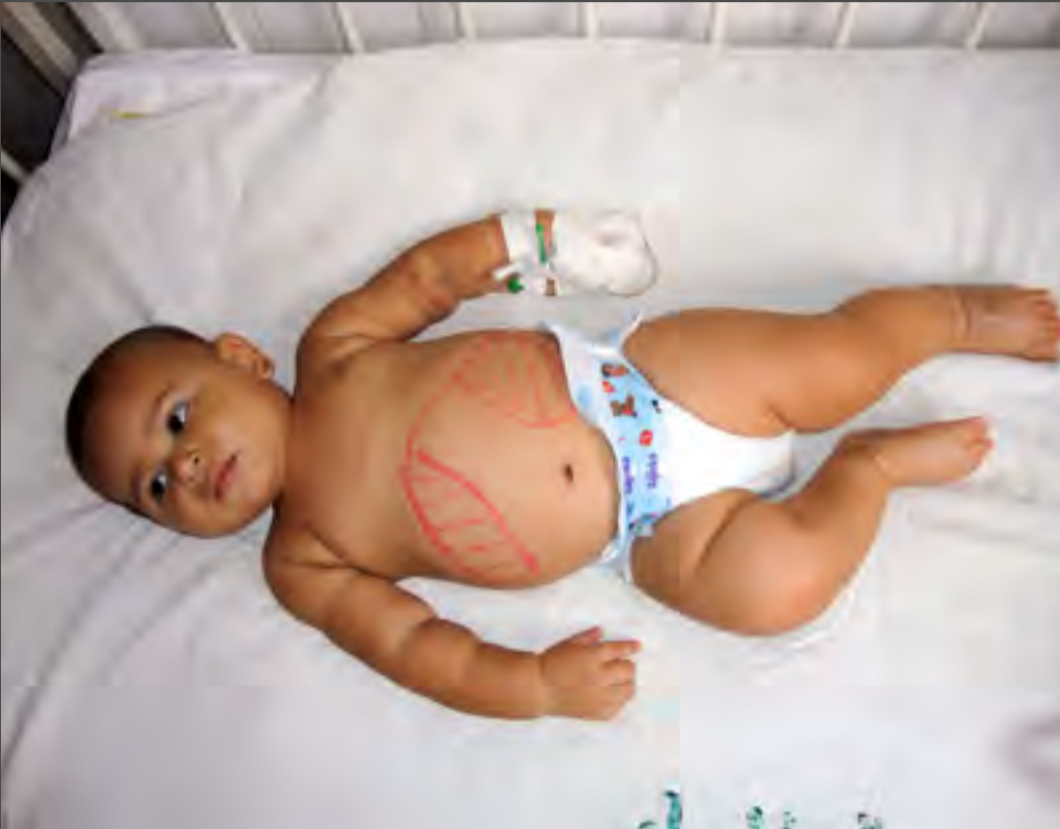**Figure 5.8D.**  
Improvement of an infant's general condition, on the seventh day of treatment



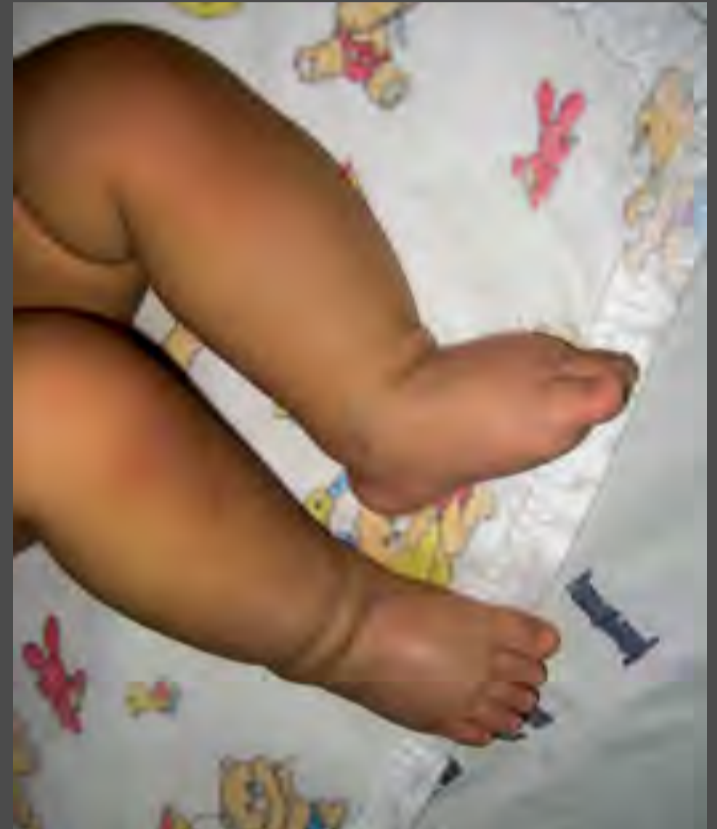

## Visceral leishmaniasis

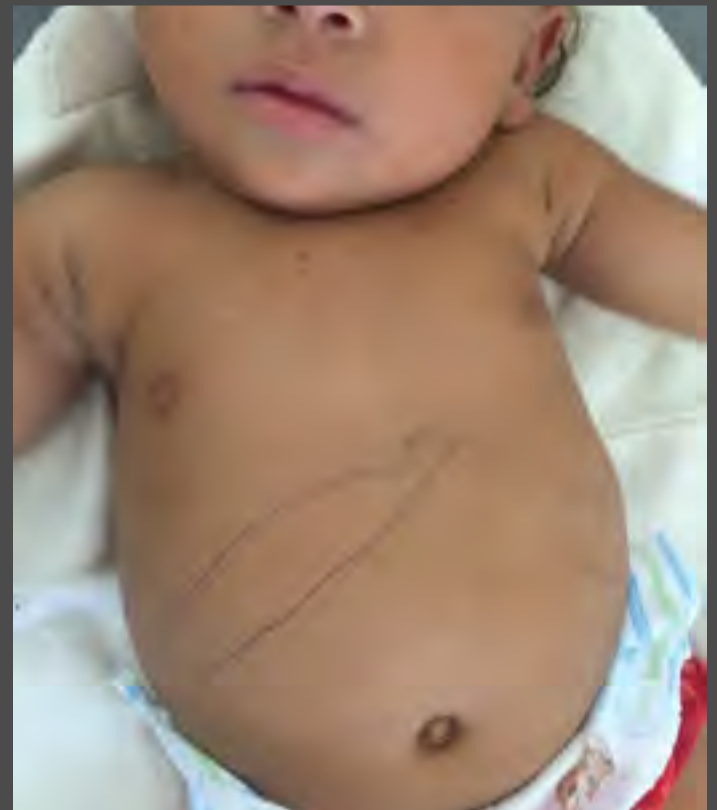**Figure 5.9A.**  
Infant with hepatosplenomegaly and leg edema



**Figure 5.9B.**  
Infant with foot edema



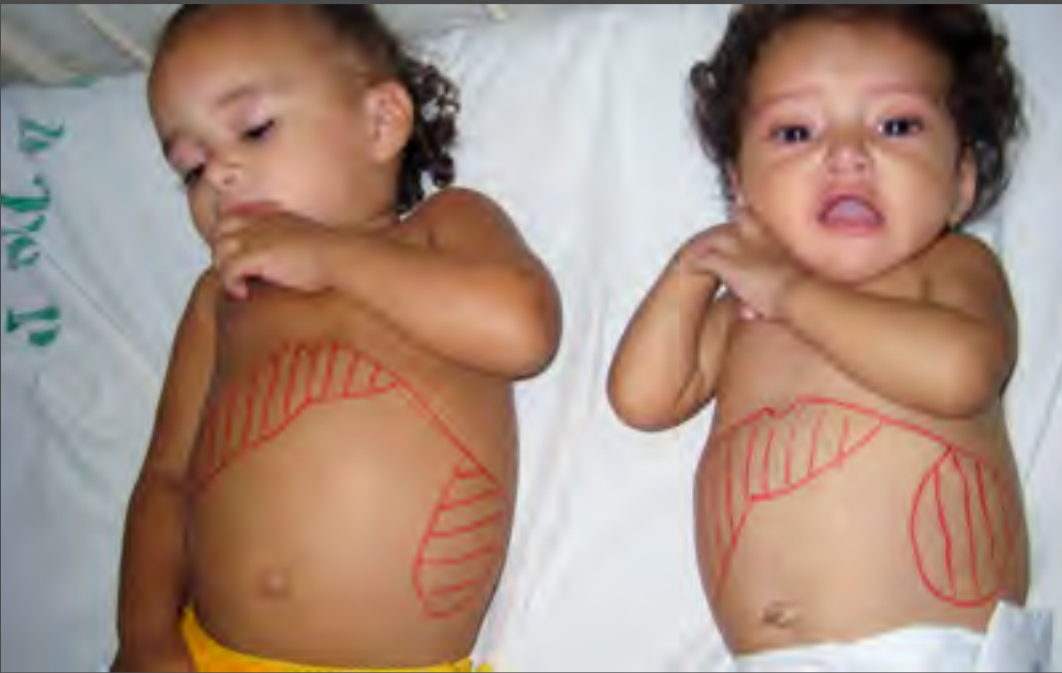**Figure 5.9C.**  
Infant with petechiae on the face and ascites



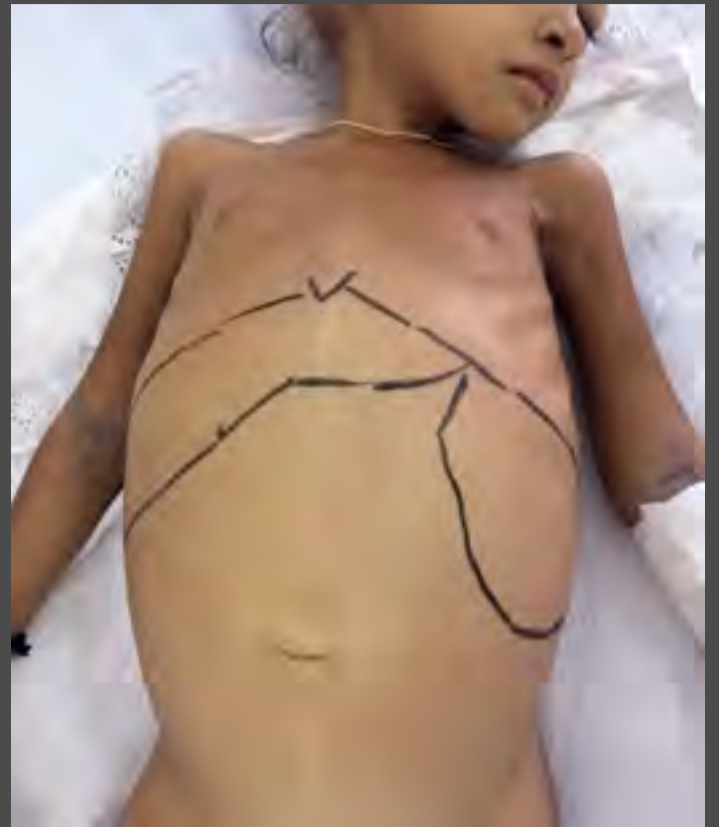**Figure 5.9D.**  
Infant after a month of treatment, with persistent discrete hepatosplenomegaly and multiple petechiae from phlebotomines bites



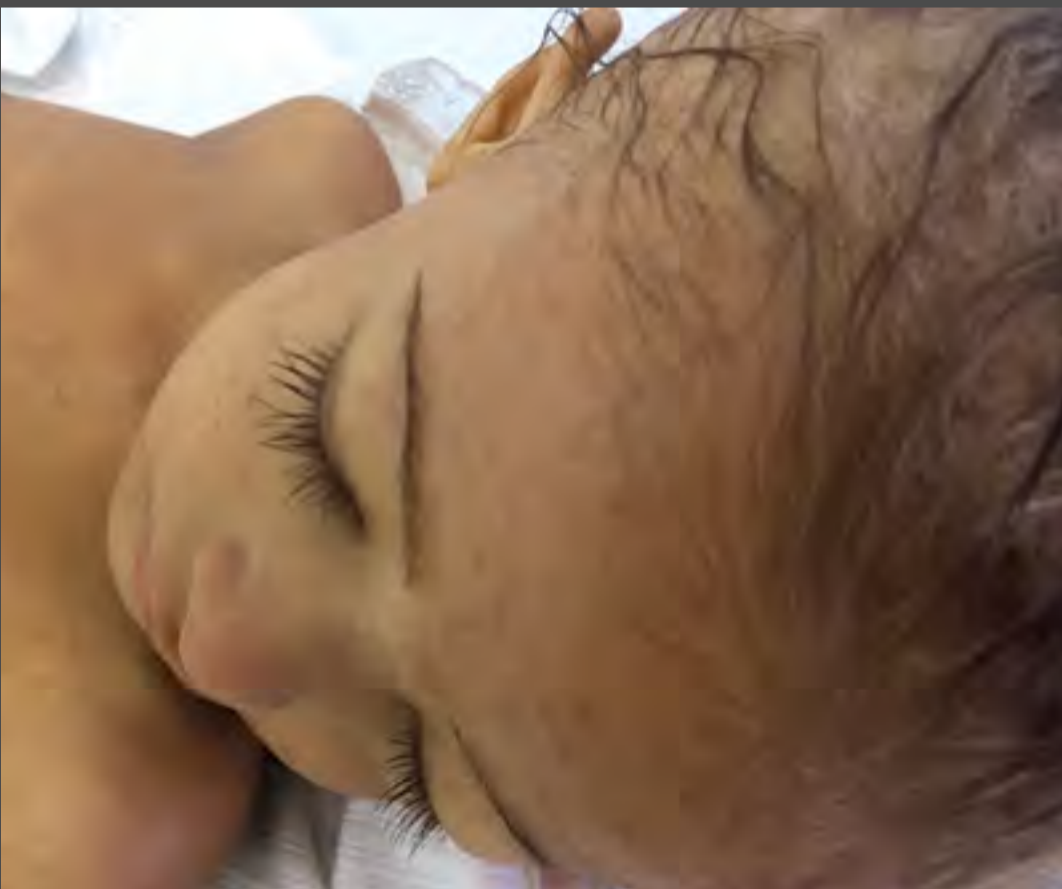## Visceral leishmaniasis



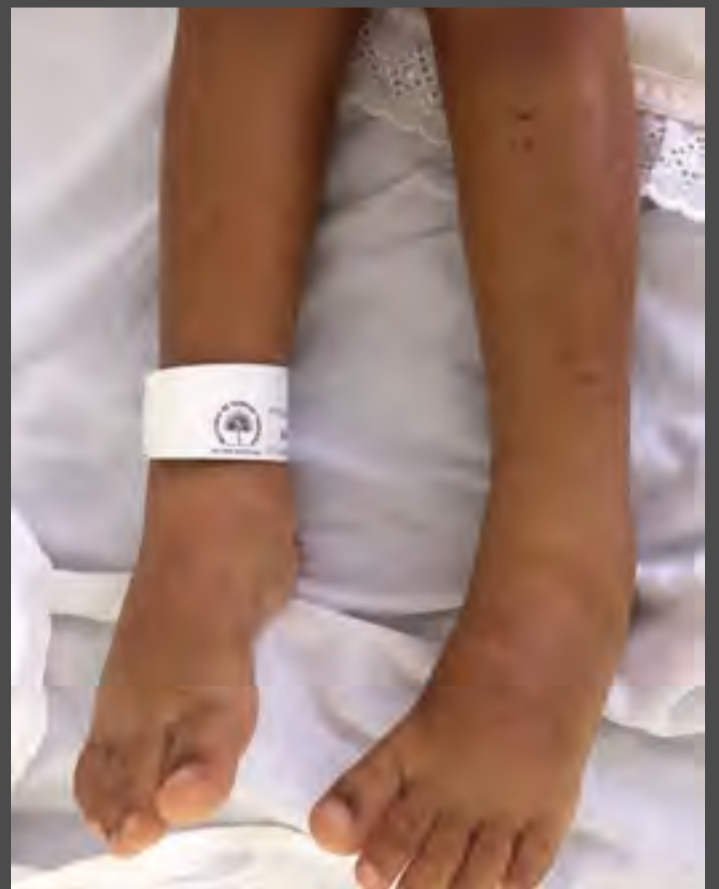**Figure 5.9E.**  
Sisters aged 9 months and 2 years, patients at the same time



**Figure 5.9F.**  
Severe visceral leishmaniasis. Child aged 3 years with weight loss, edema, and hepatosplenomegaly



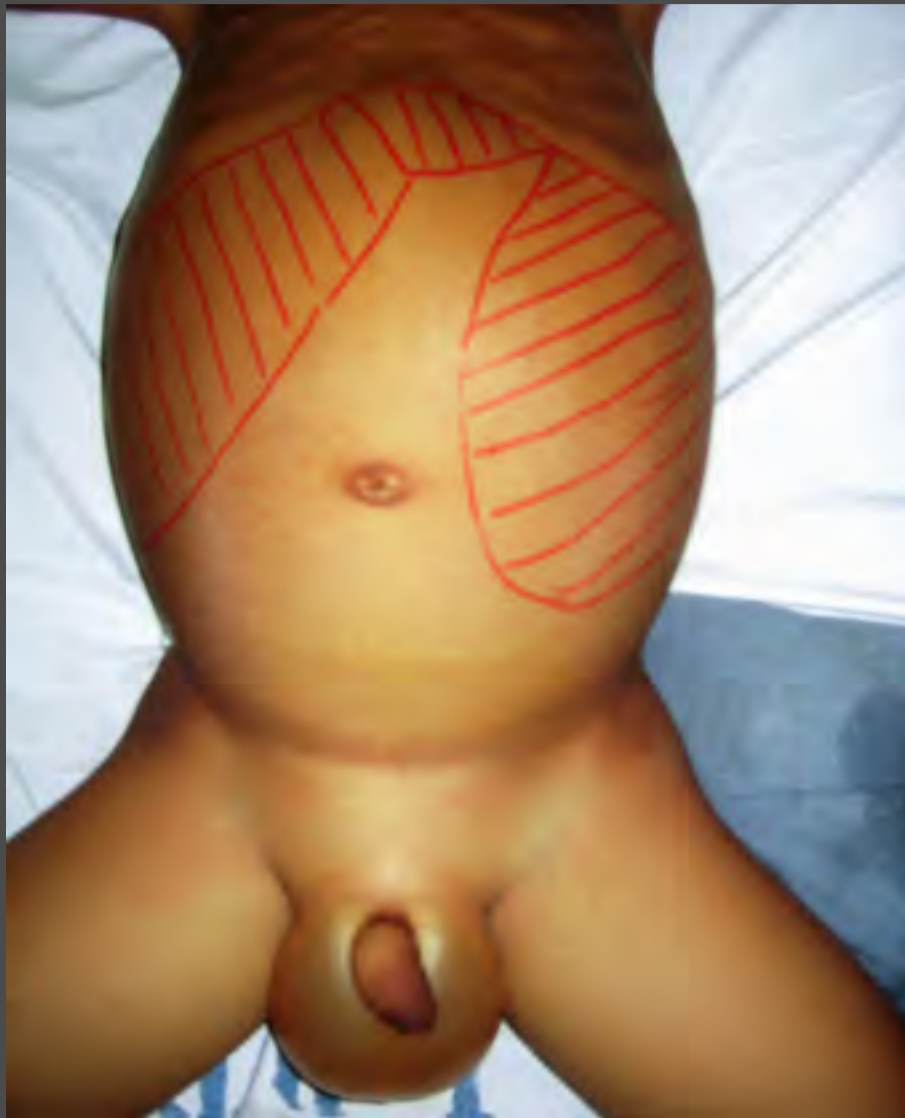**Figure 5.9G.**  
Child aged 3 years, with malnutrition, long eyebrows and sparse hair



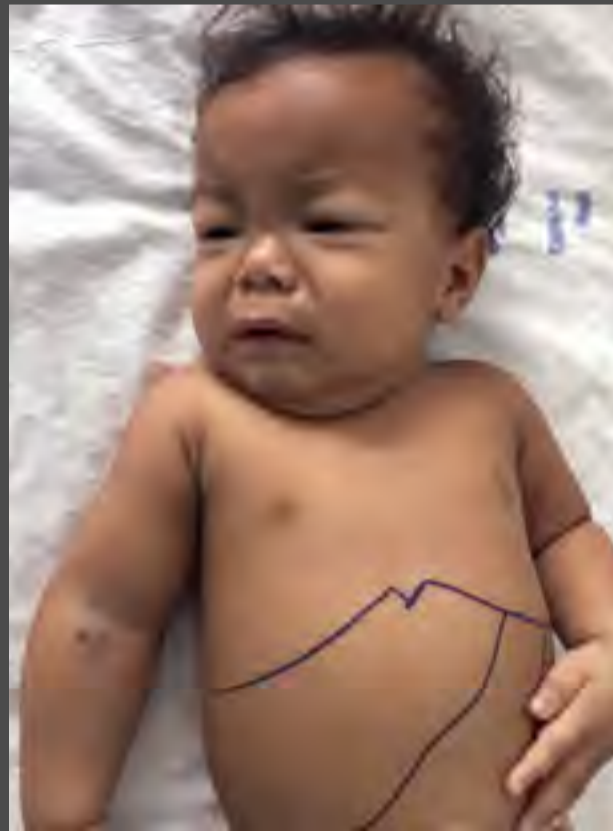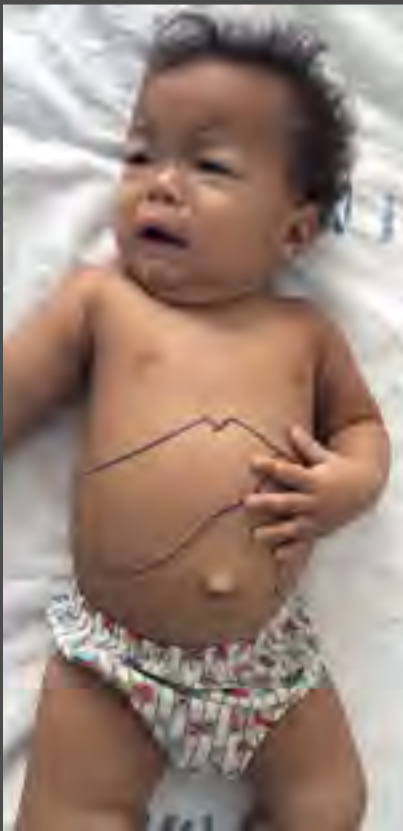**Figure 5.9H.**  
Severe visceral leishmaniasis. Child with petechiae and ecchymoses on the legs



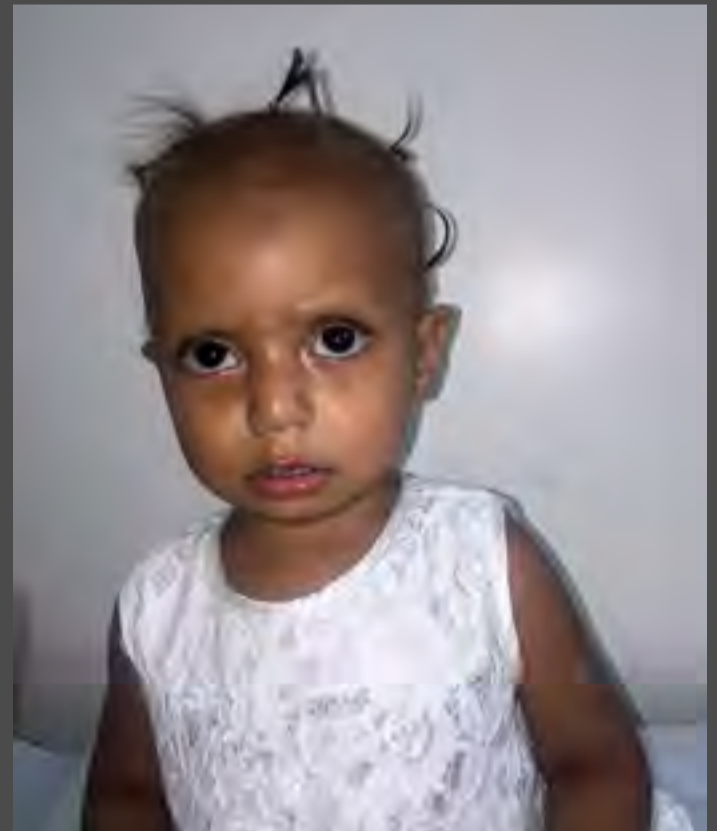## Visceral leishmaniasis



**Figure 5.10A.**  
Preschool child with  
anasarca, weight loss, and  
hepatosplenomegaly



**Figures 5.10B and C.**  
Irritable infant with hepatosplenomegaly



**Figure 5.10D.**  
Improvement of an infant's general condition  
after a month of treatment

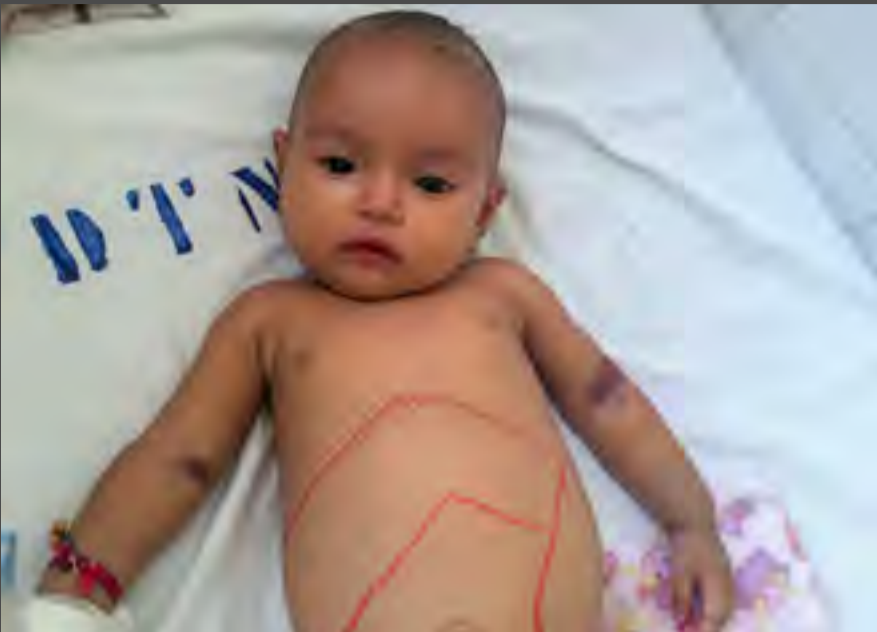

Hemorrhages (*Figures 5.11*) and bacterial infections are frequent and constitute the most important risk factors for death in patients with visceral leishmaniasis. In addition to impaired blood clotting, other risk factors for death include jaundice (*Figures 5.12*), thrombocytopenia, coinfection with human immunodeficiency virus (HIV), diarrhea, extreme ages, neutropenia, and dyspnea.

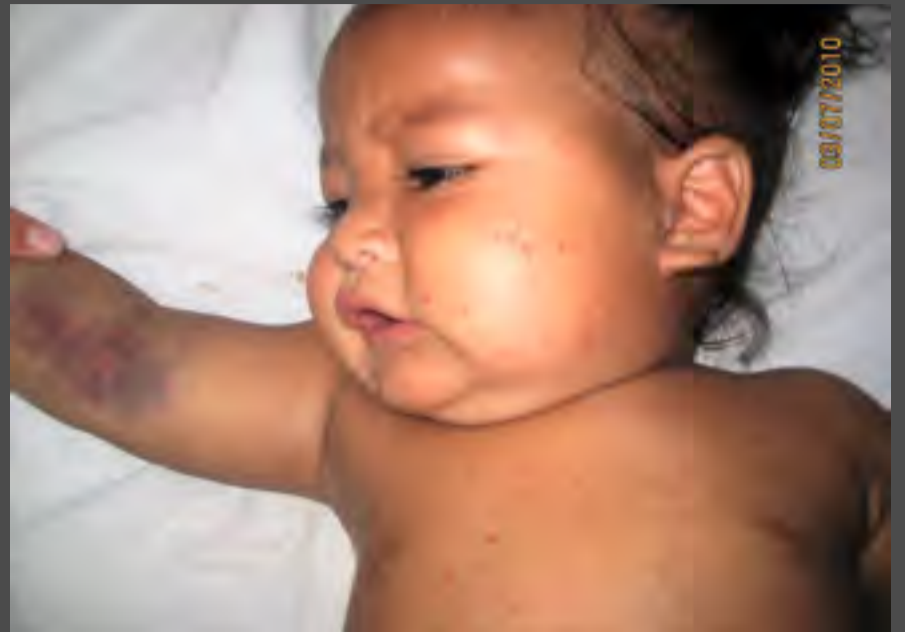Transmission of *Leishmania* spp. from mother to fetus is rarely described and can result in placental infection or fetal death. Congenital disease can manifest with early symptoms, such as low weight-for-gestational age, fever, bleeding, jaundice, and neonatal death, or the child may present signs and symptoms of visceral leishmaniasis many months after birth, making it harder to distinguish from vector-acquired disease.



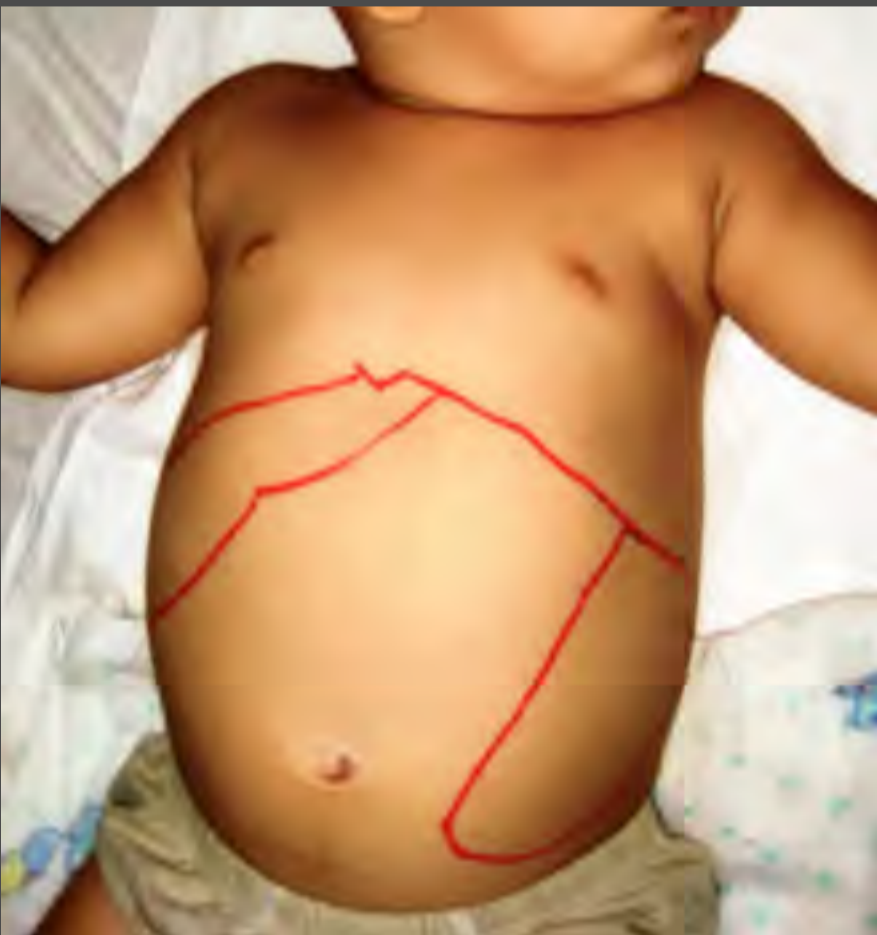## Visceral leishmaniasis



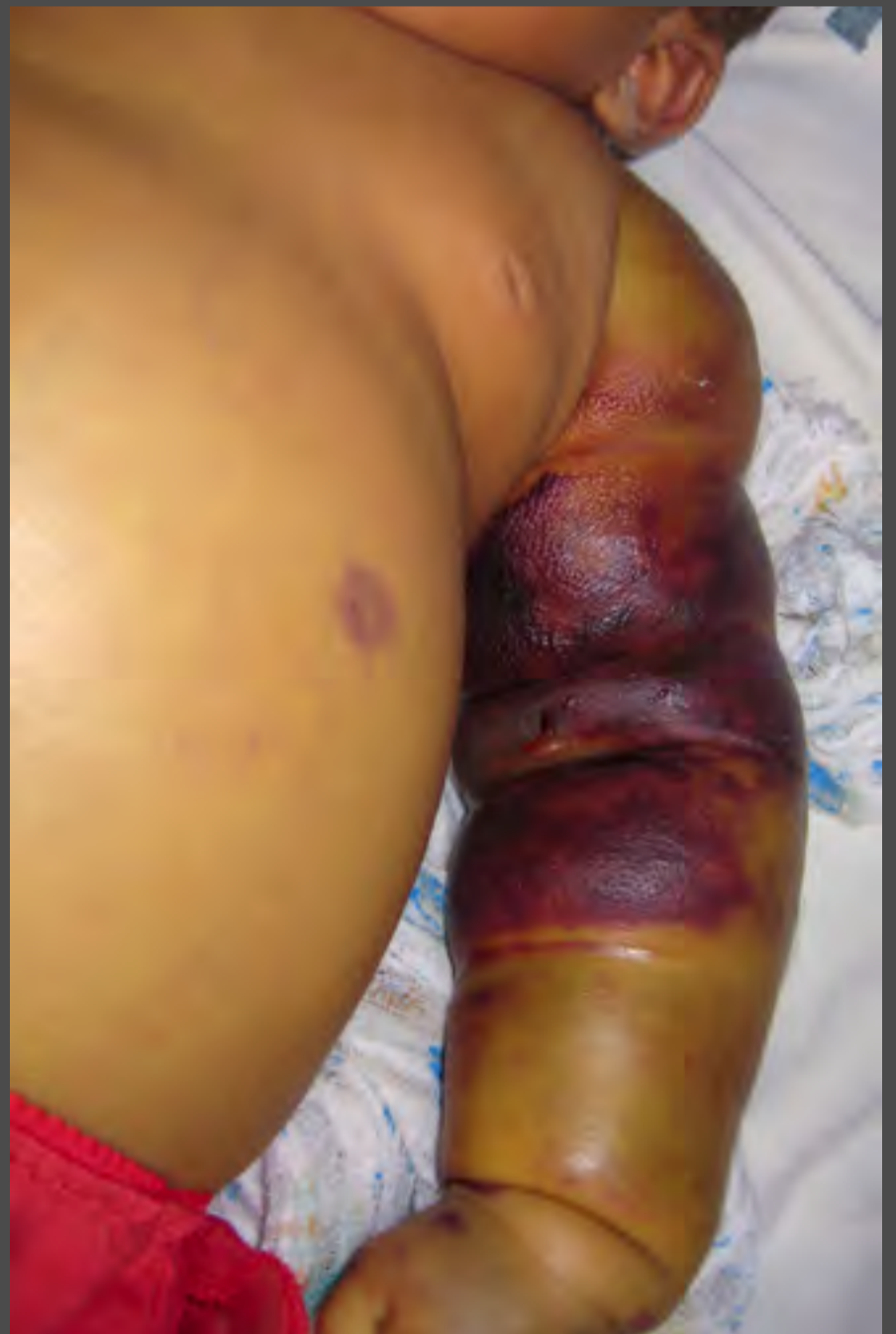**Figure 5.11A.**  
Visceral leishmaniasis and coagulopathy. With  
ecchymoses at venipuncture sites



**Figure 5.11B.**  
Infant with petechiae and ecchymoses



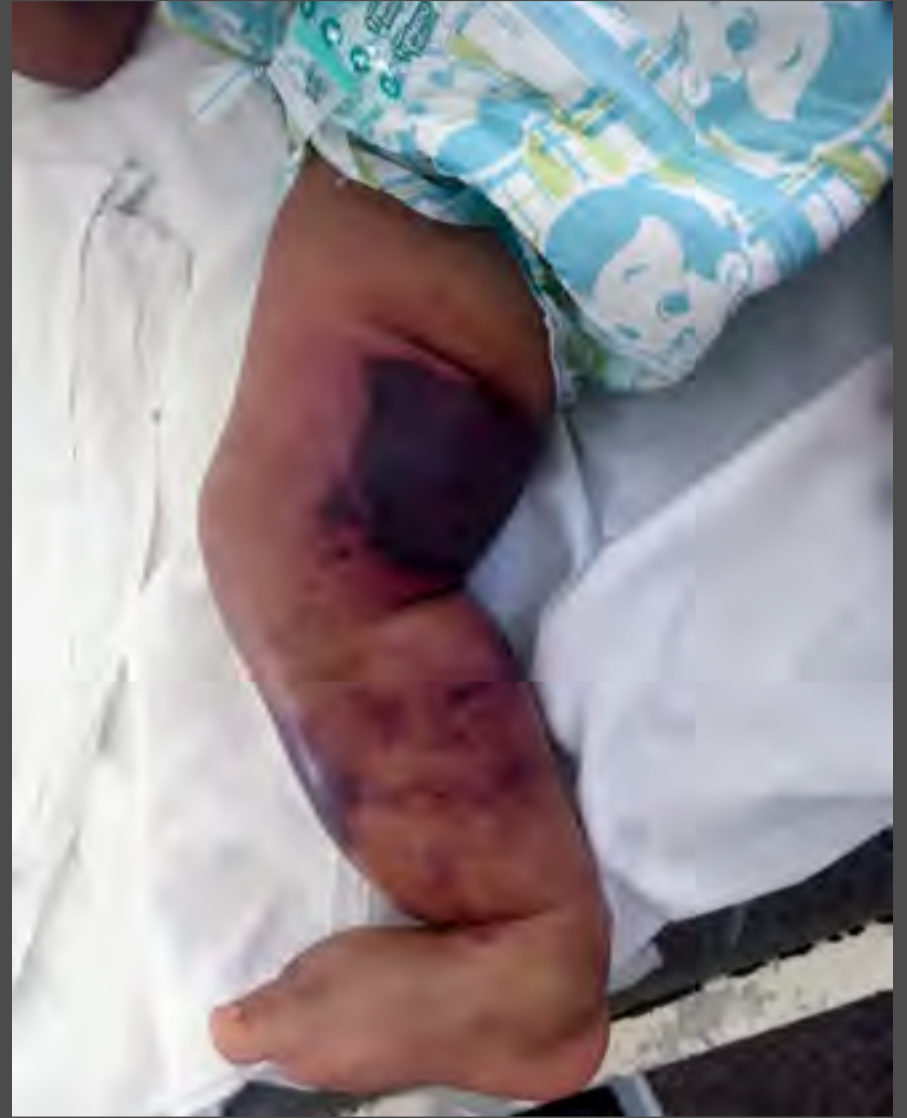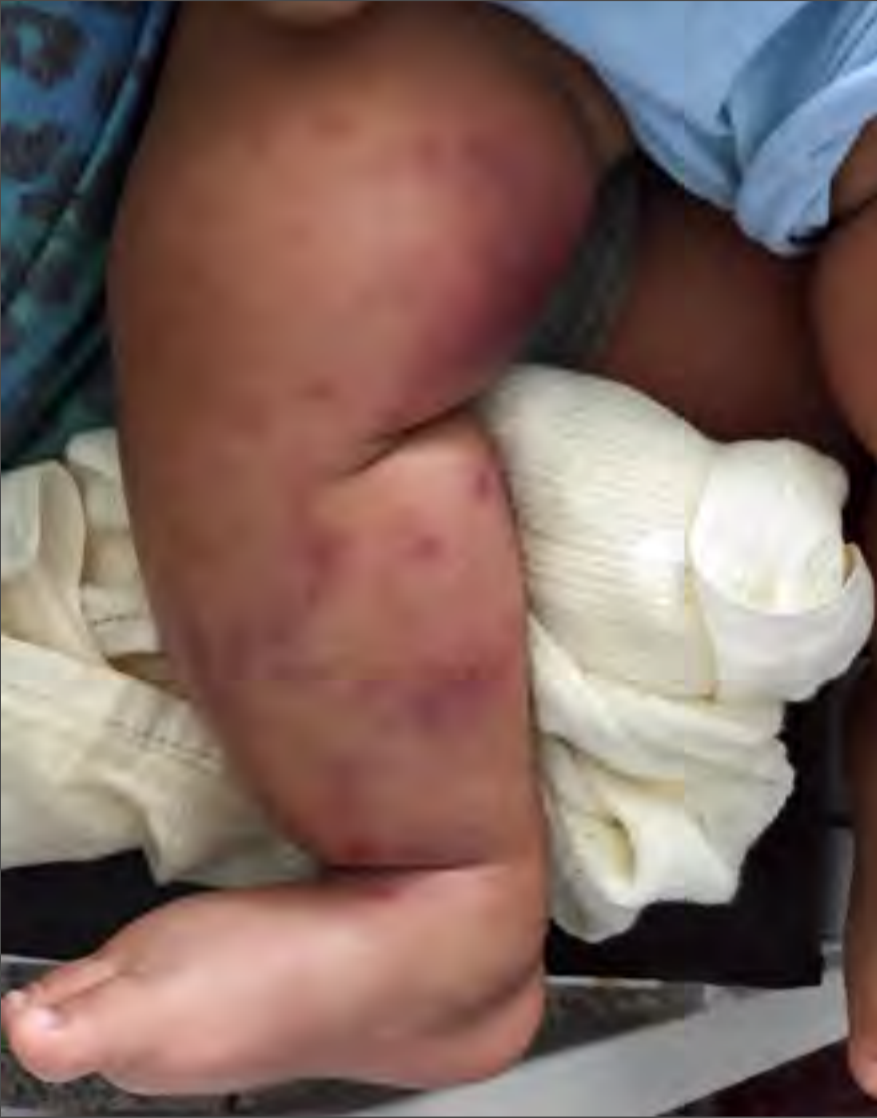**Figure 5.11C.**  
Infant with hepatosplenomegaly



**Figure 5.11D.**  
Extensive ecchymoses on the forearm of an infant  
with visceral leishmaniasis

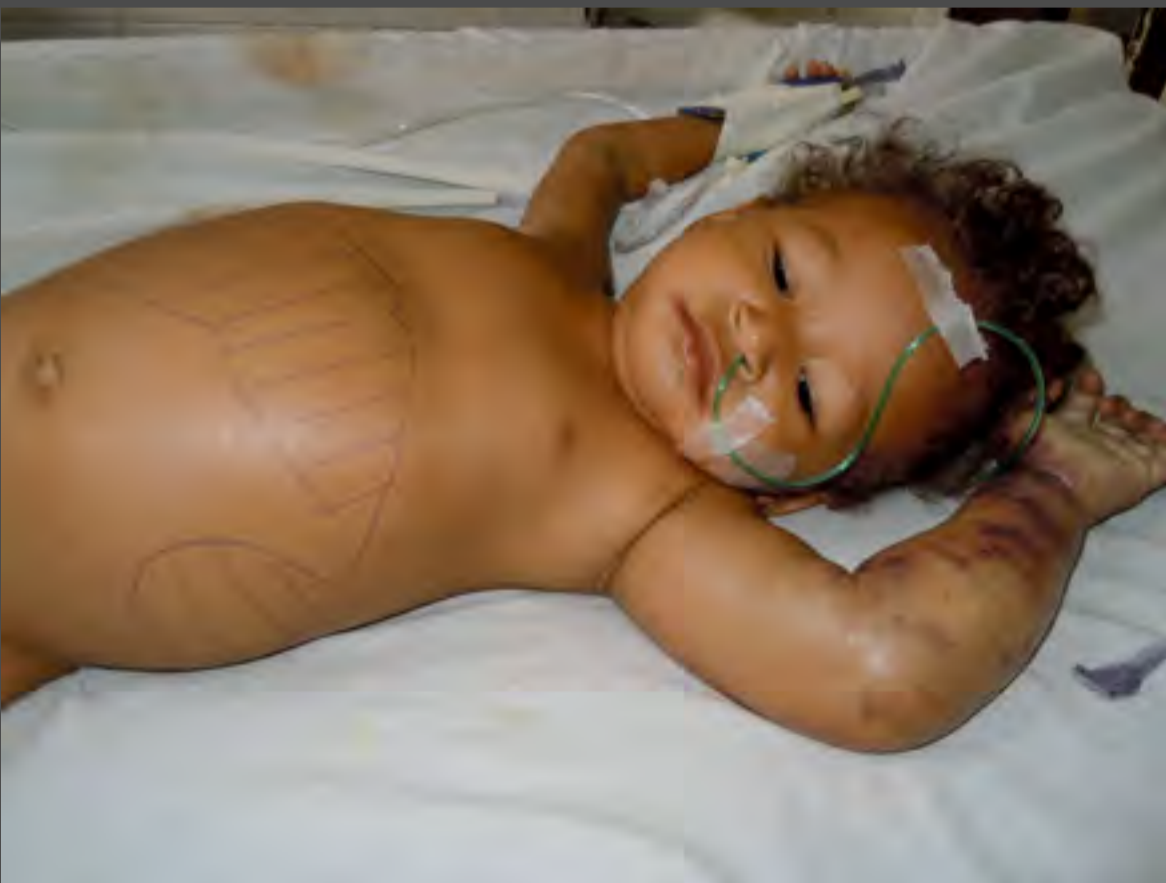

## Visceral leishmaniasis



**Figure 5.11E.**  
Extensive ecchymoses on the leg of an infant (day 1)

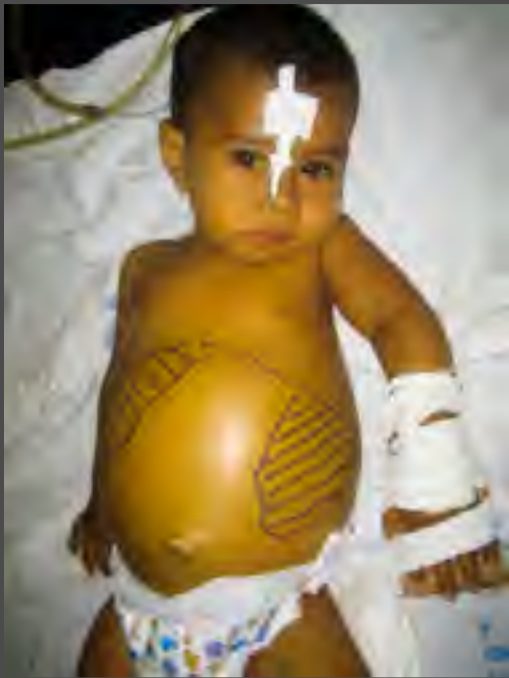**Figure 5.11F.**  
Extensive ecchymoses on the leg of an infant (day 3)



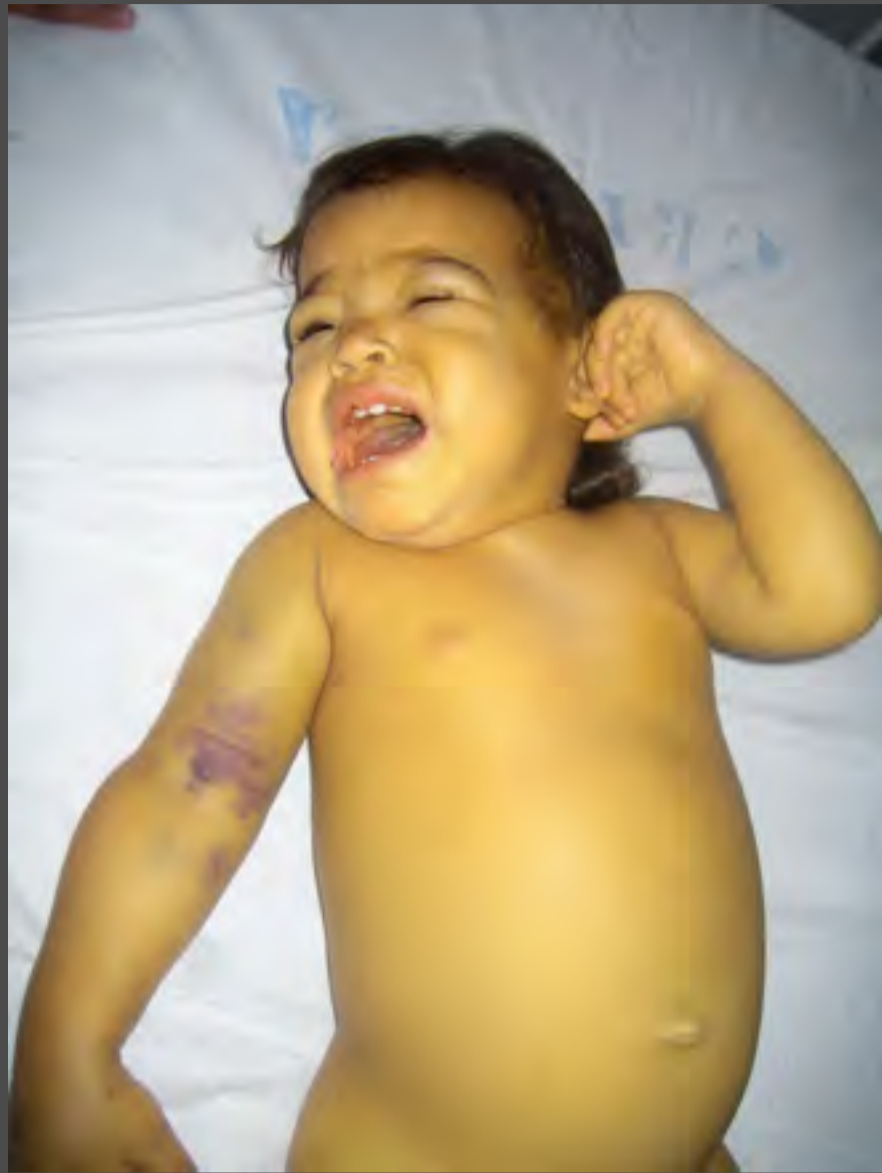**Figure 5.11G.**  
Infant with edema and  
coagulopathy



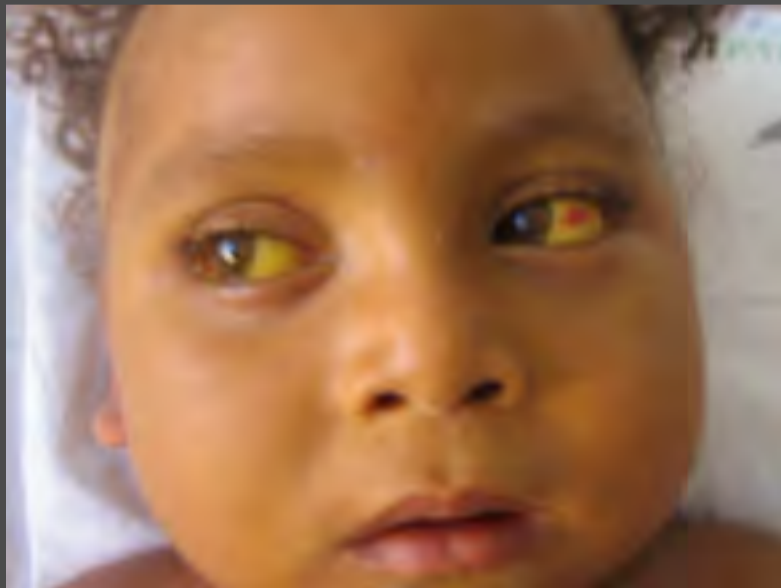## Visceral leishmaniasis



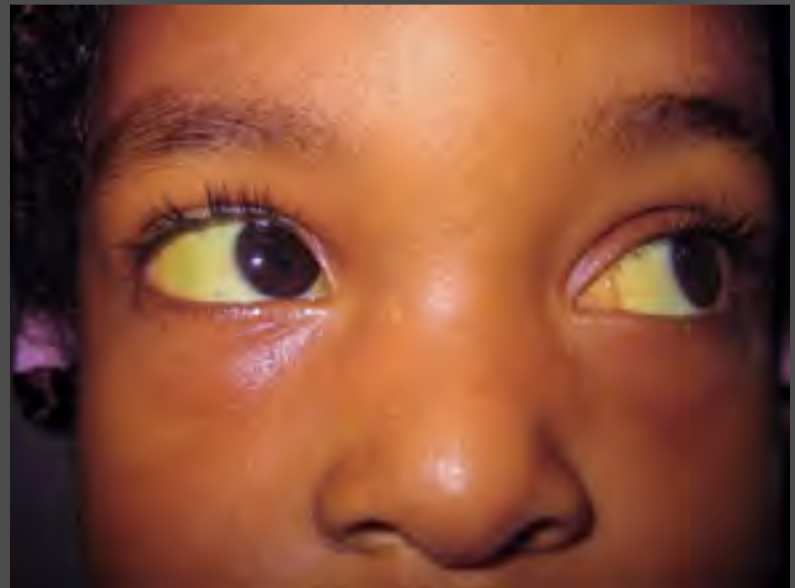**Figure 5.12A.**  
Severe visceral leishmaniasis.  
Child with ascites,  
hepatosplenomegaly, and  
jaundice



**Figure 5.12B.**  
Severe visceral leishmaniasis. Infant with jaundice,  
bleeding, edema, and irritability



**Figure 5.12C.**  
Preschool child with jaundice and  
subconjunctival hemorrhage



**Figure 5.12D.**  
Child with jaundice



### In immunosuppressed patients

Clinical manifestations of visceral leishmaniasis in immunocompromised individuals can be easily confused with those of other opportunistic diseases or the immunodeficiency syndrome, which frequently delays diagnosis.

Visceral leishmaniasis may be the first opportunistic infection in people with AIDS or it may appear in the more advanced stages of HIV infection. Clinical manifestations in people with HIV infection are usually similar to those in uninfected people, although some manifestations, such as splenomegaly and fever, may be more subtle or even absent.

Atypical presentations are common, and the parasites may also be found in many organs without producing clinical manifestations.

Post-kala-azar dermal leishmaniasis (PKDL) may also develop in immunosuppressed persons after treatment of visceral leishmaniasis caused by *L. (L.) infantum*.

Relapses are frequent. Many patients present chronic anemia, splenomegaly, and malnutrition, with little immune recovery. Visceral leishmaniasis can also occur as an opportunistic disease in people who receive corticoids, or in those with lymphoma, leukemia, chronic hepatitis, sarcoidosis, Crohn's disease, systemic lupus erythematosus, or ulcerative colitis, or who are organ transplant recipients.





## Differential Diagnosis

The clinical manifestations of visceral leishmaniasis are not specific and the differential diagnosis is broad. Frequently, the early signs and symptoms of the disease are nonspecific and can be confused with those of other diseases, such as upper respiratory tract infections, diarrhea, or primary protein-calorie malnutrition.

The differential diagnosis for the acute form of visceral leishmaniasis includes malaria, typhoid fever, arbovirus diseases (chikungunya, Zika, and dengue fever), acute Chagas disease, acute schistosomiasis, amoebic liver abscess, mononucleosis, and the hepatitis. In subacute or chronic cases, the differential diagnosis includes tuberculosis, enterobacteriasis, subacute bacterial endocarditis, histoplasmosis, disseminated fungal diseases, malaria, schistosomiasis, and brucellosis, among others. Noninfectious differential diagnosis include sickle cell anemia, lymphomas, leukemias, aplastic anemia, rheumatoid arthritis with Felty syndrome, and systemic lupus erythematosus.

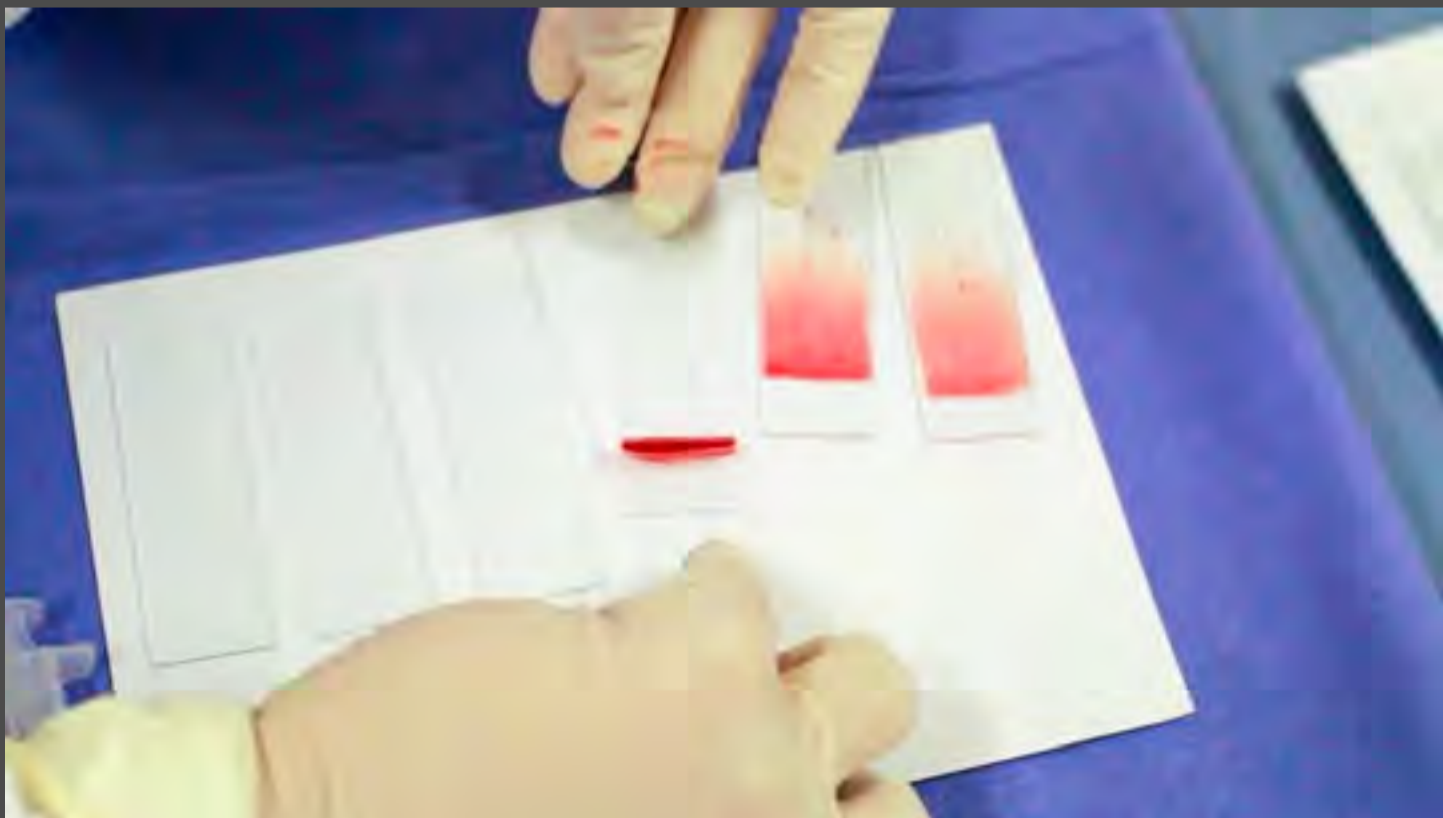
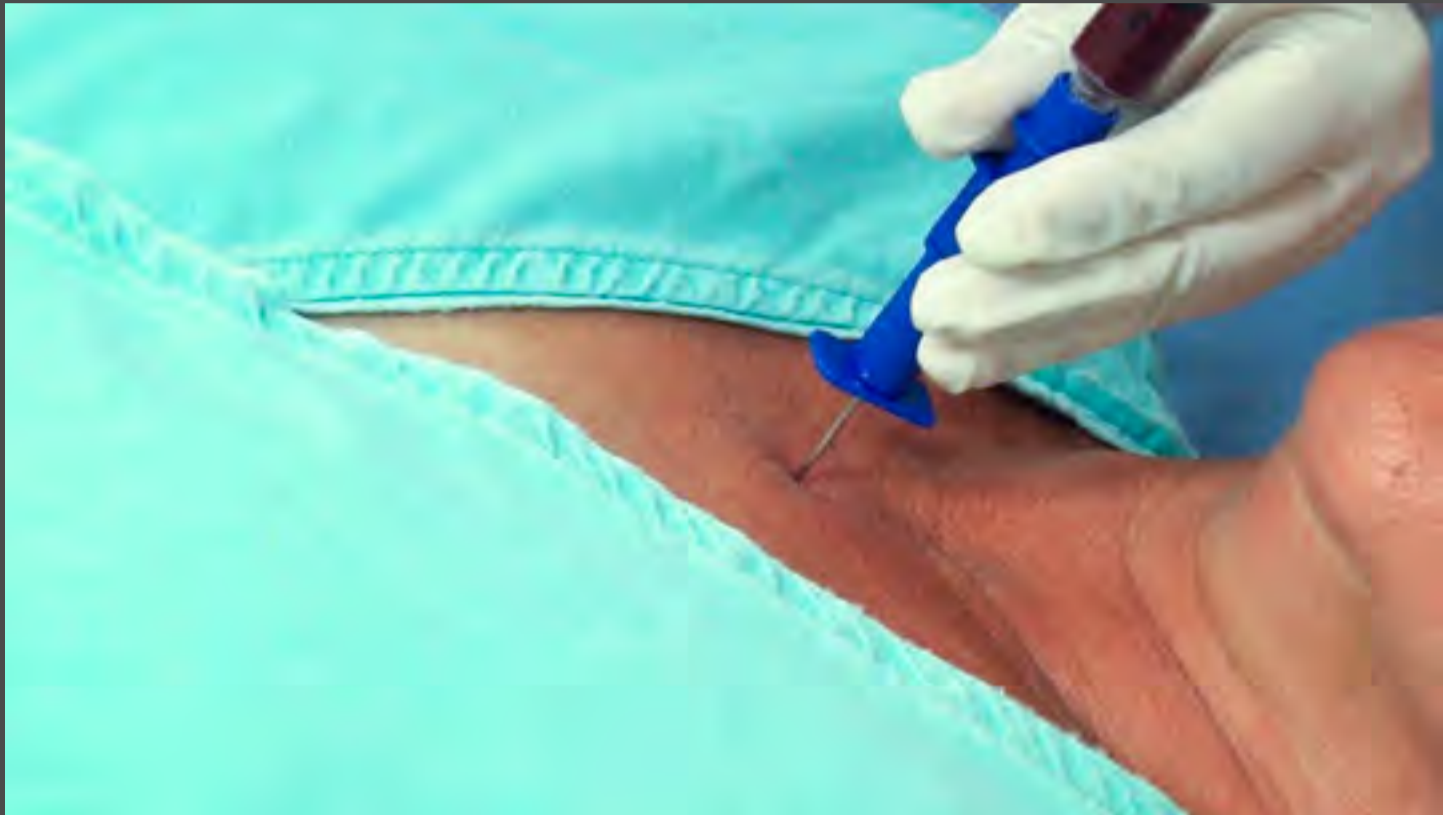
## Laboratory Diagnosis

Laboratory confirmation of the disease before treatment is important and requires a balance of test sensitivity and specificity, as well as of costs and risks of procedures.

Nonspecific laboratory findings include anemia, leukopenia with neutropenia, marked eosinopenia, relative monocytosis and lymphocytosis, thrombocytopenia, hypoalbuminemia and hypergammaglobulinemia, and coagulation disorders.

Two or more diagnostic techniques should be used to ensure maximum precision of the specific diagnosis. The most commonly used techniques are visualization of amastigotes in tissue, parasite isolation via *in vitro* or *in vivo* culture, and serological tests (*Figures 5.13*). Detailed technical procedures for collection, processing, conservation, and shipment of samples for diagnosis of cutaneous leishmaniasis can be consulted in the *Manual of procedures for leishmaniases surveillance and control in the Americas*, Chapter 4 and Annexes 6 and 7 (available at: <https://iris.paho.org/handle/10665.2/51838>).



**Figures 5.13A and B.**  
Bone marrow puncture and smear for parasitology diagnosis in patient with clinical suspicion of visceral leishmaniasis



Detection of parasitic DNA through conventional polymerase chain reaction (PCR) in blood samples, bone marrow, or biopsy is highly sensitive.

The direct agglutination test (direct antiglobulin test, DAT) is simple and economical, and has proven to be useful as a first line of diagnosis in endemic areas. Immunochromatographic tests are easy to carry out and interpret, and are highly sensitive and specific.

Serological tests should not be used to evaluate response to treatment because *Leishmania* spp. antibodies can persist for several years following treatment. The Montenegro skin test is not recommended for confirming a diagnosis of visceral leishmaniasis.



## Treatment

It is recommended that people with visceral leishmaniasis signs or symptoms and positive laboratory tests be treated with drugs against *Leishmania* spp. and auxiliary support measures, which include nutritional support, blood transfusions, and treatment of concomitant diseases; e.g., AIDS, tuberculosis, and bacterial or parasitic diseases.

People with an asymptomatic infection should be monitored clinically and investigated for possible association with HIV infection or other causes of suppression of cell-mediated immunity.

Drugs against *Leishmania* spp. available for human treatment in the Americas are N-methyl-glucamine antimonate and amphotericin B in its various presentations. When choosing one, consider age, comorbidities, pregnancy, and drug availability. Other drugs used in other transmission areas, such as Africa and Asia, include paromomycin, pentamidine, and miltefosine; the latter is the only oral agent with proven efficacy for visceral leishmaniasis, though treatment failure rates have been increasing.

Treatment with several visceral leishmaniasis drugs has been recommended as an alternative, to increase drug efficacy and tolerance, reduce treatment duration, limit relapses, and prevent resistance.



## In immunosuppressed patients

Most studies of visceral leishmaniasis associated with immunodeficiency involve patients with HIV infection, with information on immunocompromised patients without HIV coming from a small number of case reports. Patients coinfecting with HIV frequently respond poorly to conventional visceral leishmaniasis treatment, and liposomal amphotericin continues to be the treatment of choice in the Americas and the Mediterranean region.

Several drugs with properties against *Leishmania* spp. are in the preclinical phase and require further development to achieve an effective treatment and secondary prophylaxis for visceral leishmaniasis and HIV coinfection.

Secondary prophylaxis in immunosuppressed patients significantly reduces rates of visceral leishmaniasis reactivation and should be continued until the patient's immune status has been minimally reconstituted. The choice between pentavalent antimonial and amphotericin B should consider the toxicity profile and interactions with other drugs the patient is taking.

Antiretroviral therapy should be initiated during treatment for *Leishmania* spp. or shortly afterwards to reduce the possibility of immune reconstitution inflammatory syndrome. People with AIDS who present visceral leishmaniasis as part of this syndrome should be treated immediately.



## Follow-up and Criteria for Cure

There are no laboratory parameters to indicate that visceral leishmaniasis has been cured and follow-up of the treated patient should be essentially clinical. The first signs of recovery tend to be nonspecific, such as improved appetite, reduced irritability, and feeling well.

The fever goes down between the second and fifth day of treatment. Nutritional recovery and reduction in spleen and liver volume are observed in the first weeks. Blood count starts to improve in the second week, although complete recovery can require months.

Clinical follow up for six months after treatment is recommended and the patient is considered to be cured if they remain free from signs of disease activity. People with immunodeficiency should be followed for many years, since they might relapse.

## Recommended Reading

- Belo VS, Struchiner CJ, Barbosa DS, Nascimento BW, Horta MA, da Silva ES, *et al.* Risk factors for adverse prognosis and death in American visceral leishmaniasis: A meta-analysis. *PLoS Negl Trop Dis.* 2014;8:e2982. doi: 10.1371/journal.pntd.0002982.
- Bush JT, Wasunna M, Alves F, Alvar J, Olliaro PL, Otieno M, *et al.* Systematic review of clinical trials assessing the therapeutic efficacy of visceral leishmaniasis treatments: A first step to assess the feasibility of establishing an individual patient data sharing platform. *PLoS Negl Trop Dis.* 2017;11:e0005781. doi: 10.1371/journal.pntd.0005781.
- Costa DL, Rocha RL, Chaves EB, Batista VG, Costa HL, Costa CH. Predicting death from kala-azar: Construction, development, and validation of a score set and accompanying software. *Rev Soc Bras Med Trop.* 2016;49:728-40. doi: 10.1590/0037-86820258-2016.
- Crescente JA, Silveira FT, Lainson R, Gomes CM, Laurenti MD, Corbett CE. A cross-sectional study on the clinical and immunological spectrum of human *Leishmania (L.) infantum chagasi* infection in the Brazilian Amazon region. *Trans R Soc Trop Med Hyg.* 2009;103:1250-6. doi: 10.1016/j.trstmh.2009.06.010.
- Lukes J, Mauricio IL, Schonian G, Dujardin JC, Soteriadou K, Dedet JP, *et al.* Evolutionary and geographical history of the *Leishmania donovani* complex with a revision of current taxonomy. *Proc Natl Acad Sci U S A.* 2007;104:9375-80.
- Pagliano P, Ascione T, Di Flumeri G, Boccia G, De Caro F. Visceral leishmaniasis in immunocompromised: Diagnostic and therapeutic approach and evaluation of the recently released IDSA guidelines. *Infez Med.* 2016;24:265-71.
- Pigott DM, Bhatt S, Golding N, Duda KA, Battle KE, Brady OJ, *et al.* Global distribution maps of the leishmaniasis. *Elife.* 2014 Jun 27;3. doi: 10.7554/eLife.02851.
- Uliana SRB, Trinconi CT, Coelho AC. Chemotherapy of leishmaniasis: Present challenges. *Parasitology.* 2018;145:464-80. doi: 10.1017/S0031182016002523.
- Wilson ME, Jeronimo SM, Pearson RD. Immunopathogenesis of infection with the visceralizing *Leishmania* species. *Microb Pathog.* 2005;38:147-60.
- World Health Organization. Control of the leishmaniasis. WHO technical report series. Geneva: WHO; 2010. pp. 1-186.



# Post-Kala-Azar and Para-Kala-Azar Dermal Leishmaniasis



José Angelo Lauletta Lindoso



## Post-Kala-Azar Dermal Leishmaniasis

Post-kala-azar dermal leishmaniasis (PKDL) is a clinical manifestation that appears six months to three years after the visceral manifestation. It has been very well described in some areas of visceral leishmaniasis or kala-azar incidence, mainly in Asia and Africa.

It is described as a complication of visceral leishmaniasis caused by *Leishmania donovani* and is involved in maintaining anthroponotic transmission, particularly in India and Sudan.

The lesion is characterized mainly by a maculopapular skin rash after an episode of visceral leishmaniasis, and occurs mainly on the face, chest, and arms. Other clinical presentations are hypopigmented macules, erythematous plaques, papular or nodular lesions, ulcers, or warty lesions.

It is important to point out that in India, PKDL primarily manifests with macular, papular, and nodular lesions, with lesion polymorphism, while in Sudan, nodules and papules are the most characteristic lesions.

Mucous membrane involvement is uncommon, although it may occur in some cases and the lesion may be ulcerated.

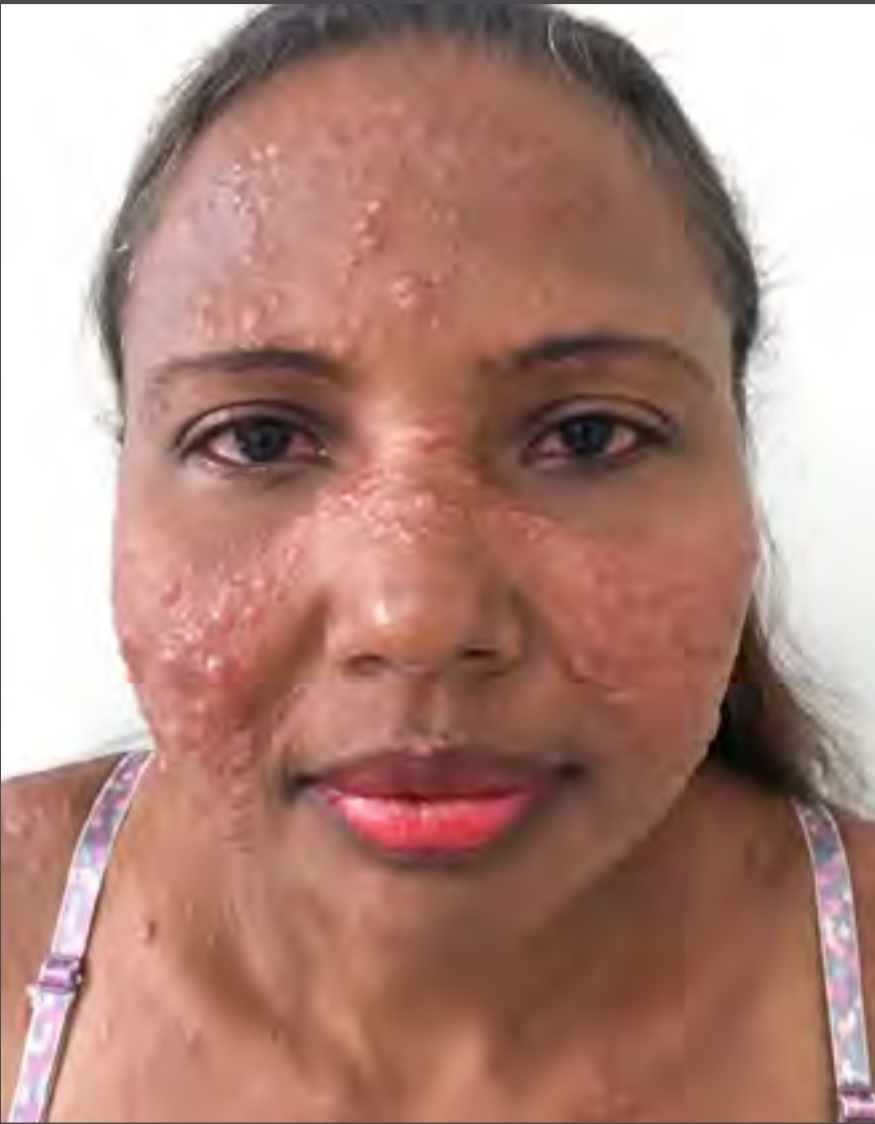

There have been very few reports of PKDL caused by *L. (L.) infantum*. Some authors describe cutaneous manifestations caused by this species, together with visceral involvement, in patients with HIV or another cause of immunosuppression; in addition, immune reconstitution inflammatory syndrome may occur in patients with HIV who receive antiretroviral therapy.

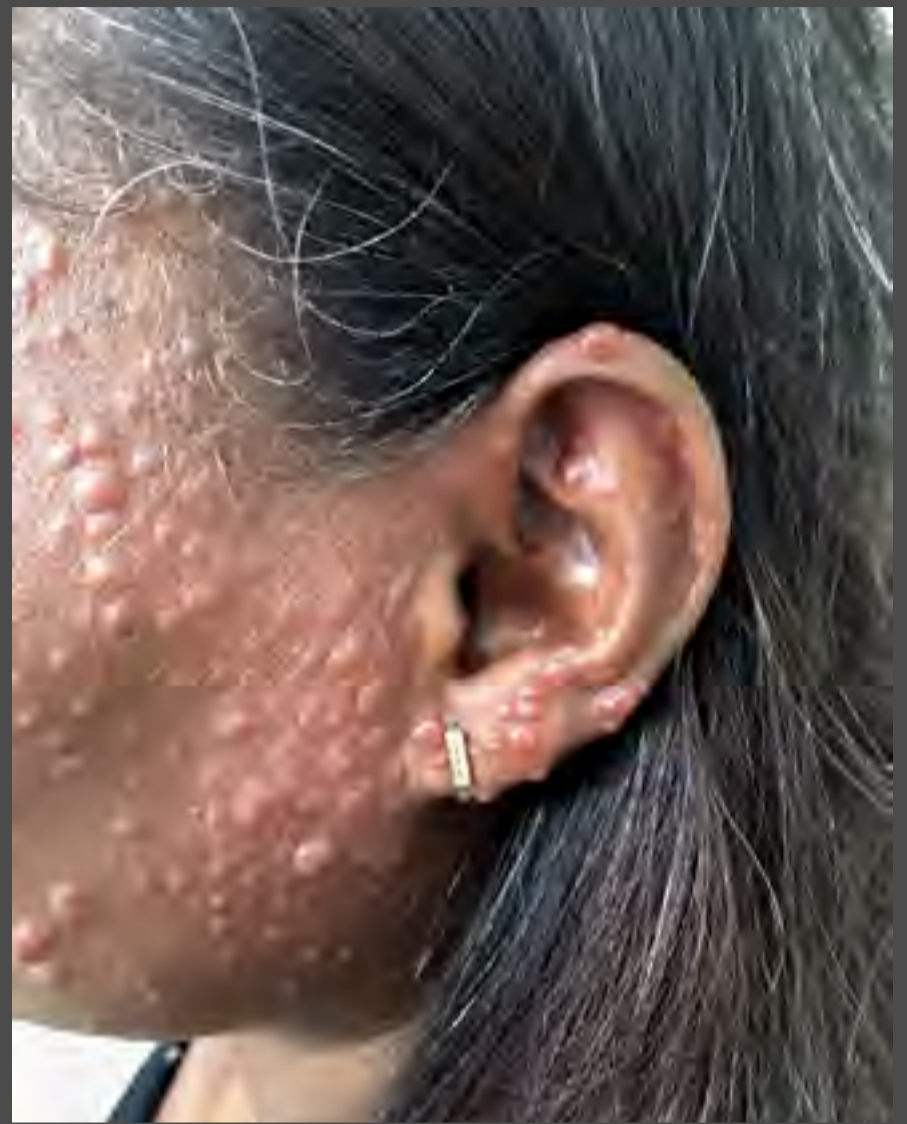The characteristic skin lesion of PKDL is primarily described as an atypical skin rash.

In cases of immunosuppression, abundant parasites are found in lesions of PKDL from *L. (L.) infantum*, contrary to *L. donovani* cases, in which few parasites are found. In the Americas, PKDL is rare; nevertheless, in patients with HIV, as well as in a patient with leprosy, skin lesions associated with visceral leishmaniasis have been described (*Figures 5.14*).

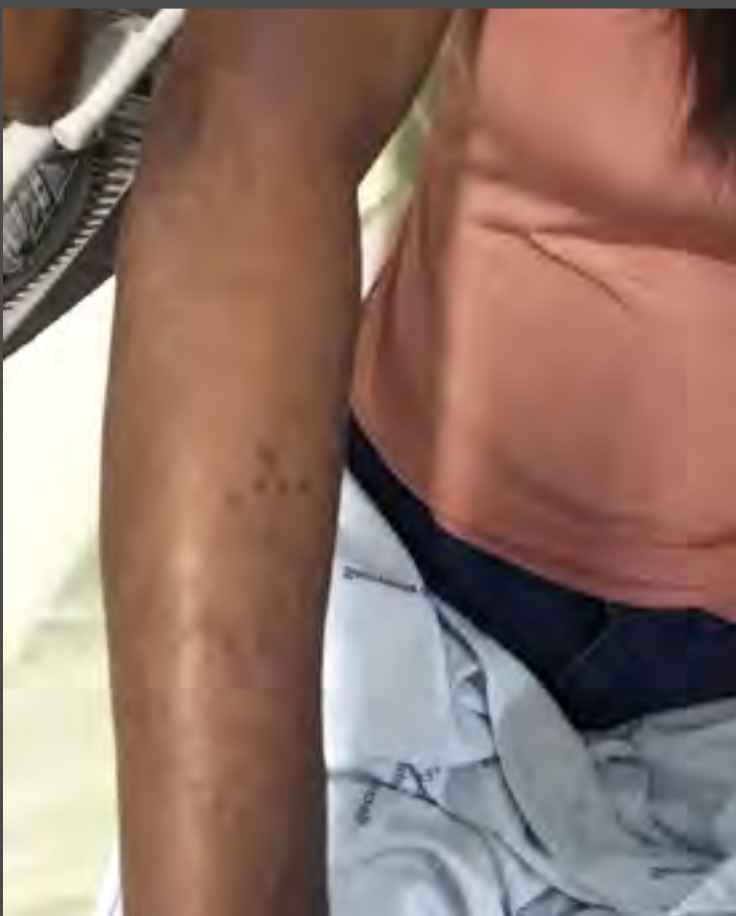The differential diagnosis of PKDL is made with diseases that cause similar skin lesions, such as leprosy, lupus, diffuse cutaneous leishmaniasis, disseminated cutaneous leishmaniasis, psoriasis, and vitiligo, among others.



**Figure 5.14A.**  
PKDL in patient with HIV. Multiple nodular lesions on face. *Leishmania (L.) infantum*



**Figure 5.14B.**  
PKDL in patient with HIV. Multiple nodular lesions on face and ear. *Leishmania (L.) infantum*



**Figure 5.14C.**  
PKDL in patient with HIV. Macular lesions on right arm. *Leishmania (L.) infantum*



## Para-Kala-Azar Dermal Leishmaniasis

Very few cases of this clinical form of leishmaniasis have been reported. It is characterized by macular, papular, or nodular lesions concomitant with visceral manifestations.

Few cases caused by *L. donovani* have been described in India. In the Americas, this clinical form was recently reported in a patient with recurrence of visceral leishmaniasis, who presented papular lesions concomitant with visceral involvement caused by *L. (L.) infantum*, with no HIV association.

As with PKDL, differential diagnosis is with disseminated cutaneous leishmaniasis; it is also very important to observe the association with clinical manifestations of the visceral form. Some recent cases of para-kala-azar dermal leishmaniasis have been reported, such as the following one.

# Clinical Case



Mônica Elinor Alves Gama, Diego Aguiar, Leônidas Lopes Braga Júnior, Cláudia Maria de Castro Gomes, Dewton de Moraes Vasconcelos and José Angelo Lauletta Lindoso



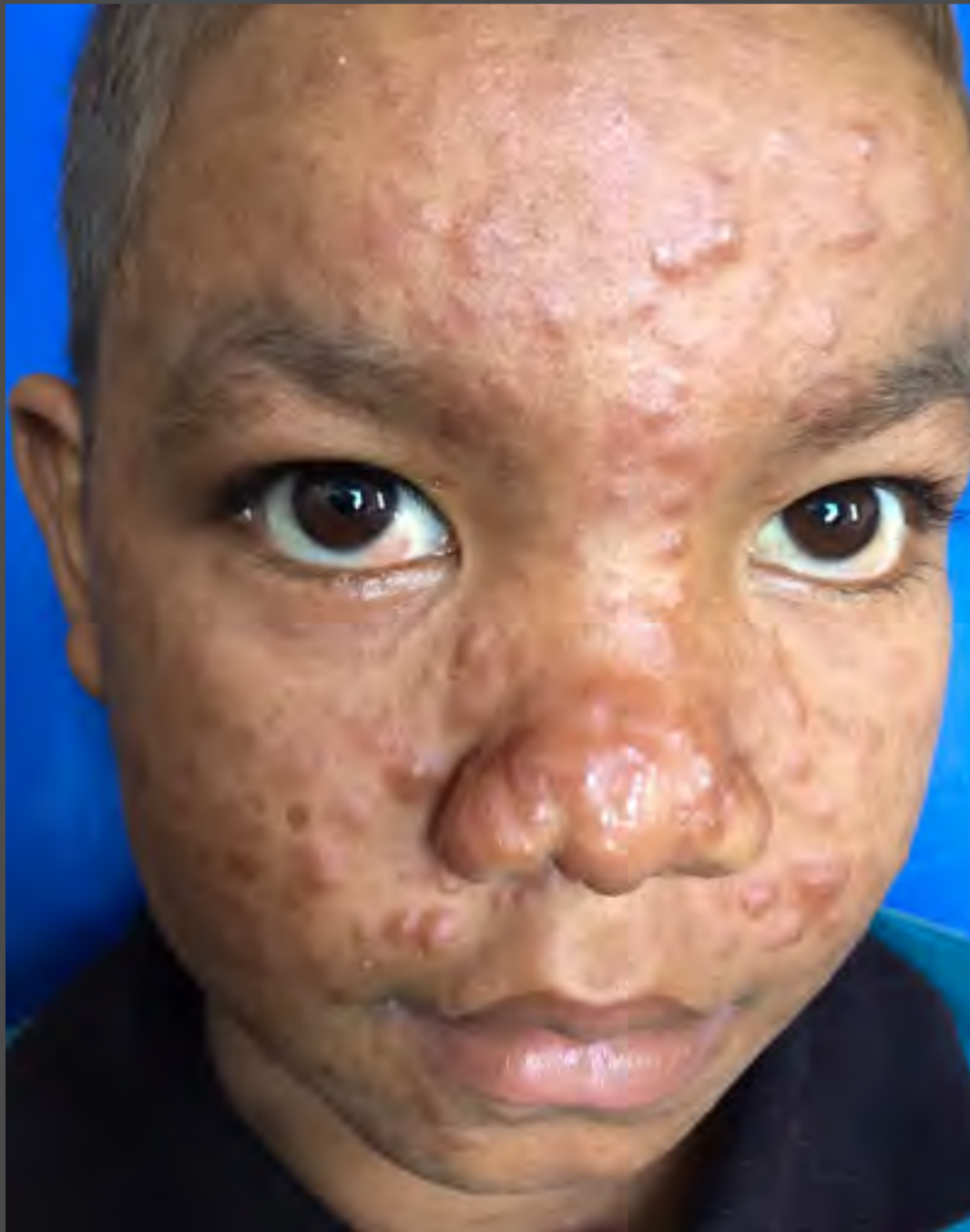A pediatric patient developed a clinical case of para-kala-azar dermal leishmaniasis during treatment of a third relapse of visceral leishmaniasis.

He was a mixed-race child aged 11 years 8 months, born and living in the Maranhão State (Brazil), with no history of having lived elsewhere.

He had presented five visceral leishmaniasis episodes since 2015. Each time, the diagnosis was made by the clinical manifestations and laboratory tests: hepatosplenomegaly, pancytopenia, and the rapid rK39 immunochromatographic test. The diagnosis was confirmed by bone marrow puncture that showed abundant *Leishmania* spp. amastigotes on two occasions. Two HIV tests were done, which were negative.

He was treated the first two times with N-methyl-glucamine antimonate and, the third, with amphotericin B deoxycholate, which led to improvement in clinical symptoms.

During the fourth visceral leishmaniasis treatment with liposomal amphotericin B, with a total dosage of 50 mg/kg, the patient presented nodular lesions in one of the nasal alae. After the treatment, the patient's skin lesions had disseminated; these were erythematous papular lesions, nodules, and atypical plaques, with areas of infiltration on the face, trunk, and limbs (*Figure 5.15*).



**Figure 5.15.**  
Para-kala-azar dermal leishmaniasis. Erythematous papular lesions, nodules, and atypical plaques with areas of infiltration on the face





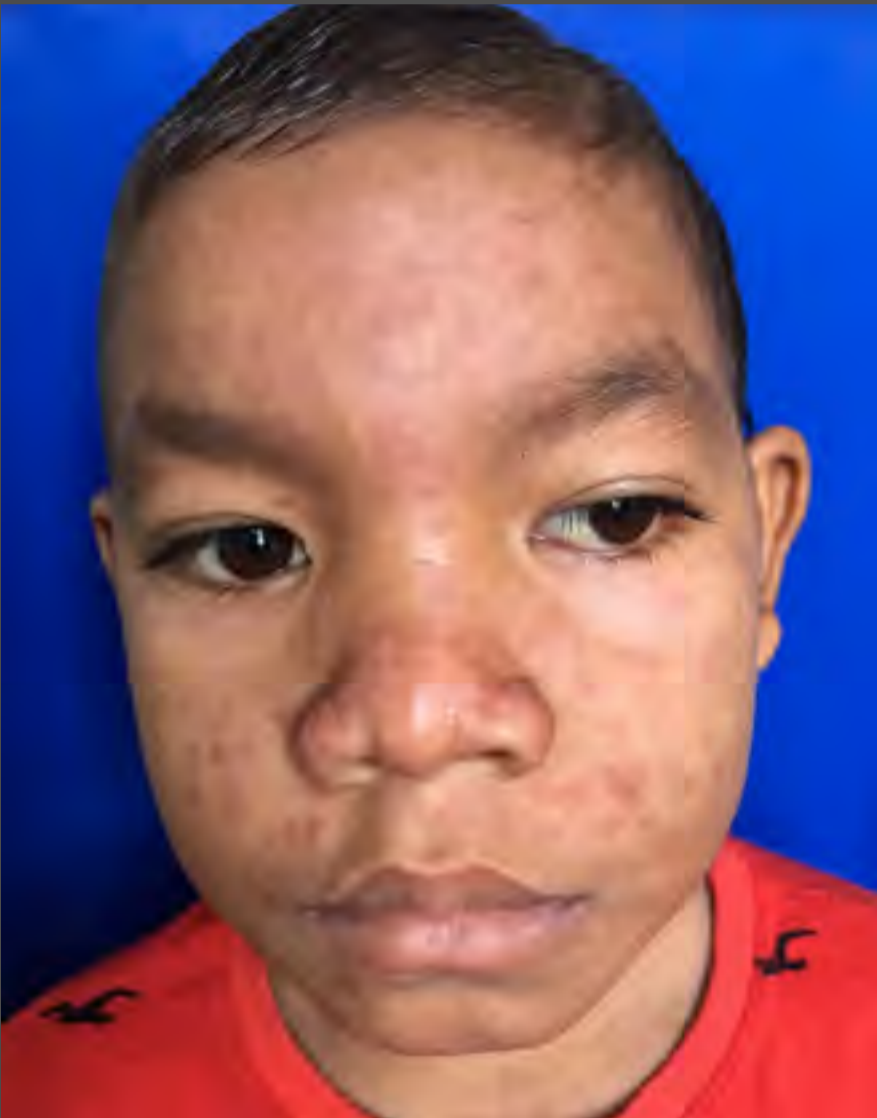This was considered to be a new recurrence with clinical manifestations of visceral leishmaniasis, for which he received liposomal amphotericin B, for a total dosage of 50 mg/kg.

On this occasion, general and specific immunosuppression by visceral leishmaniasis was investigated: immunophenotyping of T-lymphocytes, B-lymphocytes, and natural killer (NK) cells showed minor alterations. The *in vitro* lymphoproliferative reaction to *L. (L.) infantum* antigen showed a low stimulation index (2.26), and determination of concentration of cytokines in supernatant was in process.

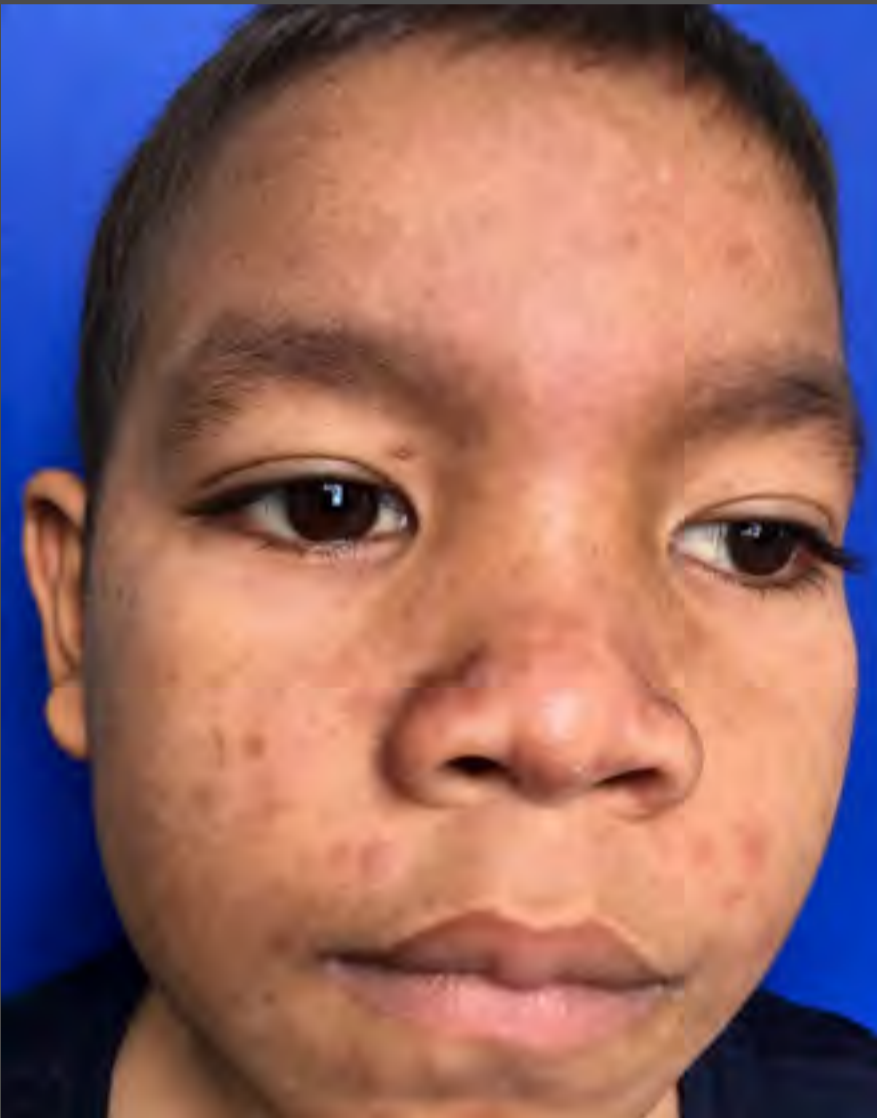To look for the parasite in the skin lesion, a scraping was stained with Giemsa; a biopsy was also done for a histopathology study, which showed moderate to dense inflammatory mononuclear infiltrate, with a preponderance of vacuolated macrophages and abundant parasites.

Blood and skin specimens were used for molecular identification of the *Leishmania* species through three different PCR tests (ITS-RFLP, kDNA, and SSU rDNA) and PCR product sequencing. *L. (L.) infantum* was identified as the causative agent of visceral leishmaniasis and para-kala-azar dermal leishmaniasis in the Amazon region of Maranhão (Brazil).

The disseminated skin lesions persisted and were therefore treated with liposomal amphotericin B every two weeks and with miltefosine for 28 days, resulting in partial, and eventually total, remission of the lesions (*Figure 5.16*).



**Figure 5.16A and B.**  
Para-kala-azar dermal leishmaniasis. Patient  
at follow-up, seven months and one year after  
treatment with miltefosine



**Figure 5.17A and B.**  
Para-kala-azar dermal leishmaniasis. Patient at follow-up, seven months and one year after treatment with miltefosine



## Recommended Reading

- Bittencourt A, Silva N, Straatmann A, Nunes VL, Follador I, Badaró R. Post-kala-azar dermal leishmaniasis associated with AIDS. *Braz J Infect Dis.* 2003;7:229-33.
- Kumar R, Das VN, Topno RK, Pal B, Imam A, Agrawal K, *et al.* Para-kala-azar dermal leishmaniasis cases in Indian subcontinent - A case series. *Pathog Glob Health.* 2016;110:326-9.
- Lindoso JAL, Moreira CHV, Celeste BJ, Oyafuso LKM, Folegatti PM, Zijlstra EE. Para-kala-azar dermal leishmaniasis in a patient in Brazil: A case report. *Rev Soc Bras Med Trop.* 2018;51:105-7.
- Trindade MA, Silva LL, Braz LM, Amato VS, Naafs B, Sotto MN. Post-kala-azar dermal leishmaniasis and leprosy: Case report and literature review. *BMC Infect Dis.* 2015;23:543.
- Zijlstra EE, Musa AM, Khalil EA, el-Hassan IM, el-Hasan AM. Post-kala-azar dermal leishmaniasis. *Lancet Infect Dis.* 2003;3:87-98.
- Zijlstra EE. PKDL and other dermal lesion in HIV co-infected patient with leishmaniasis: Review of clinical presentation in relation to immune responses. *PLoS Negl Trop Dis.* 2014;8:3258.

# APPENDIX



# Table Index



**Table 1.1:** Main species of *Leishmania* recognized as etiological agents of human leishmaniasis in the American continent - p. 36

**Table 3.1:** Local treatments of cutaneous leishmaniasis by quality of the evidence and strength of the recommendation - p. 179

**Table 3.2:** Systemic treatments for cutaneous leishmaniasis by quality of the evidence and strength of the recommendation - Intervention - p. 180

**Table 3.3:** Clinical picture, histology, parasitological diagnosis, and response to delayed hypersensitivity in disseminated leishmaniasis and diffuse cutaneous leishmaniasis in the Americas - p. 188

**Table 3.4:** Diseases for cutaneous leishmaniasis differential diagnosis by clinical characteristics of the lesions - p. 223

**Table 3.5:** Diseases for differential diagnosis of cutaneous leishmaniasis and their paraclinical examinations to confirm diagnosis - p. 226

**Table 4.1:** Clinical stages of nasal involvement in mucosal leishmaniasis - p. 370

**Table 4.2:** Patterns of mucosal disease progression - p. 377

**Table 4.3:** Levels of mucosal disease severity - p. 378

**Table 4.4:** Differential diagnosis of mucosal leishmaniasis by order of frequency - p. 444

**Table 4.5:** Clinical differences between paracoccidioidomycosis and mucosal leishmaniasis - p. 445



# Figure Subject Index



**Cutaneous  
Leishmaniasis**

Atypical, *figures 3.204A and B*, p. 199

Classic lesion, *figure 2.2A*, p. 88

Crusted lesion with satellite papules, *figure 2.2B*, p. 89

Destruction of the helix, *figure 2.2C*, p. 90

Diffuse, *figures 3.190 to 3.203C*, p. 192 to 196

Disseminated, *figures 3.186A to 3.189D*, p. 185 to 187

Localized, abdomen, *figures 3.122 to 3.125*, p. 150 and 151

Localized, back, *figures 3.126A to 3.131C*, p. 152 to 155

Localized, chest, *figures 3.116 to 3.120*, p. 148 and 149

Localized, ears, *figures 3.132 to 3.166*, p. 156 to 168

Localized, face, *figures 3.85 to 3.112B*, p. 136 to 145

Localized, lower limbs, *figures 3.42 to 3.59*, p. 120 to 126

<b>Cutaneous Leishmaniasis</b>	Localized, lower limbs, <i>figures 3.61 to 3.84C</i> , p. 127 to 135	
	Localized, neck, <i>figures 3.113 to 3.115B</i> , p. 146 and 147	
	Localized, upper limbs, <i>figures 3.1 to 3.24</i> , p. 104 to 112	
	Localized, upper limbs, <i>figures 3.30 to 3.41</i> , p. 116 to 119	
	Lymphatic, lower limbs, <i>figure 3.60</i> , p. 126	
	Lymphatic, upper limbs, <i>figures 3.25 to 3.29B</i> , p. 113 to 115	
	<i>Recidiva cutis</i> , <i>figure 2.2F</i> , p. 92	
	Recurrent chronic, <i>figures 3.205A to 3.216D</i> , p. 202 to 219	
	Scars, <i>figures 3.167 to 3.185</i> , p. 170 to 175	
	<b>Differential Diagnosis</b>	<i>Cutaneous Leishmaniasis</i>
Atypical mycobacteria, <i>figures 3.223A to 3.227D</i> , p. 236 to 238		
Banal ulcer, <i>figure 3.296</i> , p. 324		

Differential Diagnosis	<i>Cutaneous Leishmaniasis</i>	Basal cell carcinoma, <i>figures 3.297 to 3.316</i> , p. 326 to 332
		Bowen's disease, <i>figures 3.317A to 3.318</i> , p. 333 and 334
		Chromomycosis, <i>figures 3.246A to 3.247D</i> , p. 259 to 262
		Cutaneous lymphoma, <i>figures 3.334A to 3.339</i> , p. 344 to 346
		Cutaneous necrosis, <i>figure 3.286</i> , p. 313
		Cutaneous tuberculosis, <i>figures 3.228 to 3.229B</i> , p. 239 and 240
		Diabetic ulcer, <i>figures 3.280A and B</i> , p. 308
		Discoid lupus, <i>figures 3.281 to 3.283</i> , p. 309 and 310
		Histoplasmosis, <i>figures 3.252A to 3.258</i> , p. 271 to 278
		Insect bites, <i>figures 3.290A and B</i> , p. 317
		Kaposi's sarcoma, <i>figure 3.341</i> , p. 347
		Keratoacanthoma, <i>figures 3.330A to 3.333</i> , p. 341 to 343

Differential Diagnosis	<i>Cutaneous Leishmaniasis</i>	Leprosy, <i>figures 3.237A to 3.245B</i> , p. 250 to 257
		Lobomycosis, <i>figures 3.259 to 3.263D</i> , p. 279 to 283
		Lupus vulgaris, <i>figures 3.235A and 3.236C</i> , p. 246 to 249
		Mixed vascular ulcers, <i>figures 3.275A to 3.276B</i> , p. 299 to 302
		Orifice cutaneous tuberculosis, <i>figures 3.232A to 3.233C</i> , p. 244 and 245
		Papulonecrotic tuberculid, <i>figures 3.234A and B</i> , p. 246
		Paracoccidioidomycosis, <i>figures 3.264A to 3.268B</i> , p. 284 to 288
		Psoriasis, <i>figures 3.284 to 3.285B</i> , p. 311 and 312
		Pyoderma gangrenosum, <i>figures 3.291A to 3.292E</i> , p. 318 to 320
		Pyogenous bacterial ulcers, <i>figures 3.217A to 3.222C</i> , p. 230 to 234
		Sarcoidosis, <i>figures 3.293A to 3.295C</i> , p. 321 to 323
		Scrofuloderma, <i>figures 3.230A and 3.231C</i> , p. 241 to 243

Differential Diagnosis	<i>Cutaneous Leishmaniasis</i>	Sickle cell anemia, <i>figuras 3.287A, B and C</i> , p. 314
		Sporotrichosis, <i>figures 3.248 to 3.251E</i> , p. 264 to 270
		Squamous cell carcinoma, <i>figures 3.319A to 3.329B</i> , p. 334 to 340
		Traumatic ulcers, <i>figures 3.288 to 3.289B</i> , p. 315 and 316
		Ulcerated infantile hemangioma, <i>figure 3.340</i> , p. 347
		Vascular diseases, <i>figures 3.279A and B</i> , p. 307
		Vascular ulcer infections, <i>figures 3.277A to 3.278C</i> , p. 303 to 306
		Venous ulcers, <i>figures 3.269A to 3.273G</i> , p. 290 to 296
	<i>Mucosal Leishmaniasis</i>	Adenoma, <i>figure 4.91</i> , p. 476
		AIDS-associated disseminated histoplasmosis, <i>figures 4.83A to 4.84E</i> , p. 458 to 462
		Basal cell carcinoma, <i>figures 4.92A to 4.93C</i> , p. 478 to 481
		Cocaine use, <i>figure 4.98</i> , p. 489

<b>Differential Diagnosis</b>	<i>Mucosal Leishmaniasis</i>	Granulomatosis with polyangiitis, <i>figures 4.99 to 4.100E</i> , p. 489 to 491
		Lepromatous leprosy, <i>figures 4.79A to 4.80C</i> , p. 452 to 454
		Nasal cutaneous T-cell lymphoma, <i>figures 4.94A to 4.96C</i> , p. 483 to 486
		Orifice cutaneous tuberculosis, <i>figures 4.81A and 4.82C</i> , p. 456 and 457
		Paracoccidioidomycosis, <i>figures 4.75A to 4.78B</i> , p. 446 to 450
		Rhinoentomophthoromycosis, <i>figures 4.89A to 4.90E</i> , p. 472 to 474
		Rhinoscleroma, <i>figures 4.85A to 4.86C</i> , p. 464 to 466
		Rhinosporidiosis, <i>figures 4.87 to 4.88E</i> , p. 467 to 471
		Sarcoidosis, <i>figure 4.97</i> , p. 489
		<b>Epidemiology</b>
Cutaneous leishmaniasis, endemic state, 2018, <i>figure 1.27</i> , p. 68		
Cutaneous leishmaniasis, incidence per 100,000 population, 2018, <i>figure 1.32</i> , p. 75		

Epidemiology	Proportion of cutaneous and mucosal leishmaniasis cases, 2018, <i>figure 1.33</i> , p. 76	
	Visceral leishmaniasis, cases, 2018, <i>figures 1.30 and 1.34</i> , p. 72 and 78	
	Visceral leishmaniasis, endemic state, 2018, <i>figure 1.28</i> , p. 69	
	Visceral leishmaniasis, incidence per 100,000 population, 2018, 2018, <i>figure 1.35</i> , p. 79	
	Visceral leishmaniasis, number of deaths and fatality rate, <i>figure 1.36</i> , p. 80	
	Hamster, <i>Mesocricetus auratus</i> , <i>figure 1.8</i> , p. 34	
History	Brazil	<i>Archives of Brazilian Medicine</i> , 1912, <i>figure 1.4</i> , p. 15
		Gaspar de Oliveira Vianna, 18 years old, <i>figure 1.3A</i> , p. 12
		Gaspar de Oliveira Vianna, identity card, <i>figure 1.3C</i> , p. 14
		Gaspar de Oliveira Vianna, in Manguinhos, <i>figure 1.3B</i> , p. 13
		Ceramic, <i>figure 1.2B</i> , p. 8
	Colombia	José del Carmen Rodríguez, book, <i>figure 1.2A</i> , p. 7
		Mucosal leishmaniasis patient, <i>figure 1.2C</i> , p. 9



## Mucosal Leishmaniasis

Clinical stage I, *figures 4.16A to 4.16E*, p. 371 and 372

Clinical stage II, *figures 4.17A to 4.17F*, p. 373 and 374

Clinical stage V, *figures 4.18A to 4.18D*, p. 375

Cutaneous and mucosal leishmaniasis spectrum, *figure 4.1*, p. 357

Escomel's cross, *figure 4.71D*, p. 433

Excoriation and edema in the lower nasal turbinate, *figure 2.2D*, p. 91

Foreskin involvement, *figure 4.15*, p. 369

Lip involvement, *figures 4.2A to 4.3C*, p. 361 and 362

Lip involvement, *figures 4.4A to 4.11*, p. 363 to 367

Lip involvement, *figures 4.14A and B*, p. 369

Nasal and upper lip destruction, *figure 2.2E*, p. 91

Nasal involvement, *figures 4.12A to 4.13*, p. 368

Mucosal Leishmaniasis	Of the nose, <i>figures 4.20A to 4.58B</i> , p. 379 to 403
	Of the oral cavity, <i>figures 4.59A to 4.63</i> , p. 405 to 423
	Partial obstruction of the airway, <i>figures 4.73A, B, C and D</i> , p. 435
	Severe mucosal disease, <i>figures 4.64 to 4.74B</i> , p. 425 to 436
	Tapir nose, <i>figure 4.18D</i> , p.375
	Tapir nose, <i>figure 4.55A</i> , p. 401
	Tapir nose, <i>figure 4.74B</i> , p. 436
Parasites	Amastigotes, Giemsa stain, <i>figures 1.7A, B, C and D</i> , p. 26 to 29
	Amastigotes, scanning electron microscopy, <i>figures 1.7E, F and G</i> , p. 30 to 32
	<i>Leishmania</i> spp. life cycle, <i>figure 2.1</i> , p. 84
	PCR gel, hsp70, <i>figures 1.9A, B and C</i> , p. 39
	Promastigote, Giemsa stain, <i>figures 1.5A, B and C</i> , p. 22 and 23

Parasites	Promastigote, immunofluorescence, <i>figure 1.6</i> , p. 25
	Promastigote, scanning electron microscopy, <i>figure 1.5D</i> , p. 24
	Red kangaroo, <i>Macropus rufus</i> , <i>figure 1.1</i> , p. 4
Reservoirs	Anteater, <i>Tamandua tetradactyla</i> , <i>figure 1.19</i> , p. 57
	Armadillo, <i>Dasypus novemcintus</i> , <i>figure 1.18</i> , p. 57
	Bats, <i>Chiroptera</i> , <i>figure 1.26</i> , p. 63
	Bush dog, <i>Speothus venaticus</i> , <i>figure 1.25</i> , p. 62
	Caviomorph rodent, <i>Trichomys pachyurus</i> , <i>figure 1.22</i> , p. 59
	Crab-eating fox, <i>Cerdocyon thous</i> , <i>figures 1.24A and B</i> , p. 61
	Domestic dog, <i>Canis lupus familiaris</i> , <i>figure 1.23</i> , p. 60
	Opossum, <i>Didelphis albiventris</i> , <i>figure 1.17</i> , p. 56
	Opossum, <i>Didelphis marsupialis</i> , <i>figure 1.16</i> , p. 56

Reservoirs	Sloth, <i>Bradypus tridactyla</i> , figure 1.20, p. 58
	Sloth, <i>Choloepus didactylus</i> , figure 1.21, p. 58
	Tapir, <i>Tapirus terrestres</i> , figure 4.19, p. 376
Vectors	<i>Lutzomyia</i> , adults, figures 1.14 and 1.15A and B, p. 48
	<i>Lutzomyia</i> , larvae, figures 1.13A and B, p. 46
	<i>Lutzomyia longipalpis</i> , figures 1.12A and B, p. 45
	<i>Lutzomyia longipalpis</i> , figure 5.1, p. 496
	Phlebotomines, adults, figures 1.10 and 1.11, p. 44
Visceral Leishmaniasis	Bone marrow puncture, figures 5.13A and B, p. 515
	Clinical exam, figures 5.5A to D, p. 500
	Hemorrhages, figures 5.11A to 5.11G, p. 509 and 510
	In a dog, figure 5.2, p. 496

**Visceral  
Leishmaniasis**

In adults, *figures 5.7A, B and C*, p. 502

In children, *figures 5.3A to 5.4*, p. 498 and 499

In children, *figures 5.6A, B and C*, p. 501

In children, *figures 5.8A to 5.10D*, p. 504 to 507

Jaundice, *figures 5.12A, B, C and D*, p. 511

Para-kala-azar dermal leishmaniasis, *figures 5.15 to 5.17B*,  
p. 528 to 531

Post-kala-azar dermal leishmaniasis, *figures 5.14A, B and C*,  
p. 524

The *Interactive Atlas of Leishmaniasis in the Americas: Clinical Aspects and Differential Diagnoses* is an innovative publication that addresses the main concepts, knowledge, and clinical differences of leishmaniasis in different endemic countries of the Region of the Americas. In addition, it presents the main diseases of the skin and mucosa that must be considered in the differential diagnosis of the various clinical manifestations of leishmaniasis, which represents one of the main challenges for professionals responsible for diagnosing the disease.

This publication is the result of a joint work of the Pan American Health Organization (PAHO) with experts and collaborators, with the support of the Federico Lleras Acosta University Hospital Dermatology Center of Colombia and the Ministries of Health of PAHO Member States.

The objective of this work is to provide health professionals the ability to interactively search and analyze 1,029 photographs and illustrations of leishmaniasis and the 55 main diseases that are considered in the differential diagnosis. We hope that it will be of great value to students, teachers, researchers, and professionals of the health care system in our Region and of all other continents when treating patients infected in the Americas.

525 Twenty-third Street, NW  
Washington, D.C., 20037  
Estados Unidos de América  
Tel.: +1 (202) 974-3000  
[www.paho.org](http://www.paho.org)



# PAHO



Pan American  
Health  
Organization



World Health  
Organization  
REGIONAL OFFICE FOR THE  
Americas