

BIRTH DEFECTS SURVEILLANCE

QUICK REFERENCE HANDBOOK OF SELECTED CONGENITAL ANOMALIES AND INFECTIONS



International Clearinghouse for Birth Defects
Surveillance and Research

Birth defects surveillance: quick reference handbook of selected congenital anomalies and infections

ISBN 978-92-4-001541-8 (electronic version)

ISBN 978-92-4-001542-5 (print version)

© **World Health Organization 2020**

Some rights reserved. This work is available under the Creative Commons Attribution-NonCommercial-ShareAlike 3.0 IGO licence (CC BY-NC-SA 3.0 IGO; <https://creativecommons.org/licenses/by-nc-sa/3.0/igo>).

Under the terms of this licence, you may copy, redistribute and adapt the work for non-commercial purposes, provided the work is appropriately cited, as indicated below. In any use of this work, there should be no suggestion that WHO endorses any specific organization, products or services. The use of the WHO logo is not permitted. If you adapt the work, then you must license your work under the same or equivalent Creative Commons licence. If you create a translation of this work, you should add the following disclaimer along with the suggested citation: "This translation was not created by the World Health Organization (WHO). WHO is not responsible for the content or accuracy of this translation. The original English edition shall be the binding and authentic edition".

Any mediation relating to disputes arising under the licence shall be conducted in accordance with the mediation rules of the World Intellectual Property Organization (<http://www.wipo.int/amc/en/mediation/rules/>).

Suggested citation. Birth defects surveillance: quick reference handbook of selected congenital anomalies and infections. Geneva: World Health Organization; 2020. Licence: [CC BY-NC-SA 3.0 IGO](https://creativecommons.org/licenses/by-nc-sa/3.0/igo).

Cataloguing-in-Publication (CIP) data. CIP data are available at <http://apps.who.int/iris>.

Sales, rights and licensing. To purchase WHO publications, see <http://apps.who.int/bookorders>. To submit requests for commercial use and queries on rights and licensing, see <http://www.who.int/about/licensing>.

Third-party materials. If you wish to reuse material from this work that is attributed to a third party, such as tables, figures or images, it is your responsibility to determine whether permission is needed for that reuse and to obtain permission from the copyright holder. The risk of claims resulting from infringement of any third-party-owned component in the work rests solely with the user.

General disclaimers. The designations employed and the presentation of the material in this publication do not imply the expression of any opinion whatsoever on the part of WHO concerning the legal status of any country, territory, city or area or of its authorities, or concerning the delimitation of its frontiers or boundaries. Dotted and dashed lines on maps represent approximate border lines for which there may not yet be full agreement.

The mention of specific companies or of certain manufacturers' products does not imply that they are endorsed or recommended by WHO in preference to others of a similar nature that are not mentioned. Errors and omissions excepted, the names of proprietary products are distinguished by initial capital letters.

All reasonable precautions have been taken by WHO to verify the information contained in this publication. However, the published material is being distributed without warranty of any kind, either expressed or implied. The responsibility for the interpretation and use of the material lies with the reader. In no event shall WHO be liable for damages arising from its use.

Design and layout: Green Ink

BIRTH DEFECTS SURVEILLANCE

QUICK REFERENCE HANDBOOK
OF SELECTED CONGENITAL ANOMALIES
AND INFECTIONS

Acknowledgements

The Quick Reference Handbook of Selected Congenital Anomalies is a collaborative effort between the World Health Organization (WHO), the National Center on Birth Defects and Developmental Disabilities (NCBDDD) from the United States Centers for Disease Control and Prevention (CDC), and the International Clearinghouse for Birth Defects Surveillance and Research (ICBDSR).

For their technical input in the preparation of this quick reference handbook, we would like to acknowledge the staff of the NCBDDD, ICBDSR and WHO, particularly the following individuals (in alphabetical order): Mr James K Archer, Dr Jose F Arena, Dr Alejandro Azofeifa, Dr Robert J Berry, Dr Jan Ties Boerma, Dr Lorenzo Botto, Dr Marie Noel Brune Drisse, Ms Grace Davis, Dr Margaret Davis, Dr Luz Maria De-Regil, Dr Pablo Duran, Ms Alissa Eckert, Dr Marcia Feldkamp, Dr Alina Flores, Dr Jaime Frias, Dr Shona Goldsmith, Dr Melba Filimina Gomes, Dr Boris Groisman, Mr Dan J Higgins, Dr Margaret Honein, Ms Jennifer Hulse, Dr Vijaya Kancharla, Ms Christina Kilgo, Dr Eve Lackritz, Dr Ornella Lincetto, Dr Cara Mai, Dr Elizabeth Mary Mason, Dr Pierpaolo Mastroiacovo, Dr Mario Merialdi, Dr Cynthia Moore, Dr Allisyn Moran, Dr Joseph Mulinare, Dr Teresa Murguia de Sierra, Dr Maria Neira, Dr Richard Olney, Dr Mina Patel, Dr Juan Pablo Pena-Rosas, Dr Nelangi Pinto, Dr Vladimir B Poznyak, Dr Ingrid Rabe, Dr Hilda Razzaghi, Dr Françoise Renaud, Dr Lisa Rogers, Dr Nathalie Roos, Dr Jorge Rosenthal, Dr Csaba Siffel, Dr Haley Smithers-Sheedy, Dr Joseph Sniezek, Dr Gretchen Stevens, Dr Melanie Taylor, Dr Marleen Temmerman, Ms Diana Valencia, Dr Claudia Vellozzi, Dr Severin Von Xylander, and Dr Jennifer Williams.

The drawings were all supplied by CDC/NCBDDD.

We would also like to thank Dr Rajesh Mehta and Dr Neena Raina from the WHO Regional Office for South-East Asia for their valuable feedback during the development process.

We gratefully acknowledge and thank the United States Agency for International Development for providing financial support for this work.

The findings and conclusions in this quick reference handbook are those of the authors and do not necessarily represent the views of the Centers for Disease Control and Prevention.



Abbreviations

AFP	alpha fetoprotein
ASD	atrial septal defect
cCMV	congenital cytomegalovirus
CDC	United States Centers for Disease Control and Prevention
CHARGE	c oloboma, h ear defects, choanal a tresia, growth r etardation, g enital abnormalities, e ar abnormalities
CHD	congenital heart defect
CLIA	chemiluminescence immunoassay
CMV	cytomegalovirus
CNS	central nervous system
CRI	congenital rubella infection
CRS	congenital rubella syndrome
CSF	cerebrospinal fluid
CT	computed tomography
CVS	chorionic villus sampling
CZS	congenital Zika syndrome
DORV	double outlet right ventricle
DQI	data quality indicator
d-TGA	D(dextro)-transposition of the great arteries
ECLAMC	Latin American Collaborative Study of Congenital Malformations
EIA	enzyme immunoassay
ELISA	enzyme-linked immunosorbent assay
ETOP	elective terminations of pregnancy
ETOPFA	elective termination of pregnancy for fetal anomaly
EUROCAT	European Network of Population-Based Registries for the Epidemiological Surveillance of Congenital Anomalies
HC	head circumference
HLHS	hypoplastic left heart syndrome
IAA	interrupted aortic arch



ICBDSR	International Clearinghouse for Birth Defects Surveillance and Research
ICD-9	<i>International Statistical Classification of Diseases and Related Health Problems, Ninth revision</i>
ICD-10	<i>International Statistical Classification of Diseases and Related Health Problems, Tenth revision</i>
Ig(G/M)	immunoglobulin G/immunoglobulin M
LMIC	low- and middle-income country
MCA	multiple congenital anomalies
MRI	magnetic resonance imaging
MURCS	m ullerian, r enal, c ervicothoracic, s omite association
NAATs	nucleic acid amplification tests
NBDPN	National Birth Defects Prevention Network
NCBDDD	National Center on Birth Defects and Developmental Disabilities
NOS	not otherwise specified
NTD	neural tube defect
OAV(S)	o culo- a uriculo- v ertebral (s pectrum)
OEIS	o mphalocele, e xstrophy of the cloaca, i mperforate anus, s pinal defects
PRNT	plaque reduction neutralization test
RCPCH	Royal College of Paediatrics and Child Health
RENAC	National Network of Congenital Anomalies of Argentina
RPR	rapid plasma regain
RT-PCR	reverse transcriptase polymerase chain reaction
SOP	standard operating procedure
TAR	thrombocytopenia absent radius
TEF (also TOF)	tracheo-oesophageal fistula
TEV	talipes equinovarus
TPHA	Treponema pallidum hemagglutination assay
TPPA	Treponema pallidum particle agglutination assay
USA	United States of America
VACTERL	v ertebral, a nus, c ardiac, t rachea, o esophagus, r enal, l imb
VDRL	Venereal Disease Research Laboratory
WHO	World Health Organization
ZIKV	Zika virus



Contents

Congenital anomalies of the nervous system: Neural tube defects	2
Anencephaly (Q00.0).....	4
Craniorachischisis (Q00.1)	6
Iniencephaly (Q00.2)	8
Encephalocele (Q01.0–Q01.83, Q01.9)	10
Spina bifida (Q05.0–Q05.9)	12
Congenital anomalies of the nervous system: Microcephaly (Q02)	18
Congenital anomalies of the ear.....	20
Microtia/Anotia (Q16.0, Q17.2).....	20
Congenital heart defects.....	23
Common truncus (Q20.0)	24
Transposition of great arteries (Q20.3)	26
Tetralogy of Fallot (Q21.3)	28
Pulmonary valve atresia (Q22.0).....	30
Tricuspid valve atresia (Q22.4).....	32
Hypoplastic left heart syndrome (Q23.4).....	34
Interrupted aortic arch (Q25.21, preferred; also Q25.2, Q25.4).....	36
Orofacial clefts.....	38
Cleft palate (Q35, Q35.1, Q35.3, Q35.5, Q35.59, Q87.0)	38
Cleft lip only (Q36, Q36.0, Q36.9, Q36.90, Q36.99).....	40
Cleft palate with cleft lip (Q37, Q37.0–Q37.5, Q37.8, Q37.9, Q37.99).....	42
Congenital anomalies of the digestive system.....	44
Oesophageal atresia/tracheo-oesophageal fistula (Q39.0–Q39.2)	44
Large intestinal atresia/stenosis (Q42.8–Q42.9).....	46
Anorectal atresia/stenosis (Q42.0–Q42.3)	48
Congenital anomalies of genital and urinary organs	50
Hypospadias (Q54.0–Q54.9).....	50
Renal agenesis/hypoplasia (Q60.0–Q60.5)	52
Congenital anomalies and deformations of the musculoskeletal system	54
Talipes equinovarus (Q66.0).....	54
Congenital anomalies and deformations of the musculoskeletal system: Limb reduction defects/ limb deficiencies.....	56
Limb deficiency: Amelia (Q71.0, Q72.0, Q73.0)	58
Limb deficiency: Transverse terminal (Q71.2, Q71.3, Q71.30, Q72.2, Q72.3, Q72.30).....	60
Limb deficiency: Transverse intercalary (Q71.1, Q72.1, Q72.4)	64
Limb deficiency: Longitudinal preaxial (tibia, radius, first ray) (Q71.31, Q71.4, Q72.31, Q72.5).....	68
Limb deficiency: Longitudinal axial defects – split hand and foot (Q71.6, Q72.7).....	72
Limb deficiency: Longitudinal postaxial (fibula, ulna, fifth ray) (Q71.30, Q71.5, Q72.30, Q72.6).....	74
Abdominal wall defects.....	76
Omphalocele (Q79.2).....	76
Gastroschisis (Q79.3).....	78
Chromosomal abnormalities.....	80
Trisomy 21 (Down syndrome) (Q90.0–Q90.2, Q90.9).....	80
Congenital Infectious Syndromes	82
Congenital rubella syndrome (CRS).....	82
Congenital syphilis.....	84
Congenital cytomegalovirus (cCMV).....	86
Congenital Zika syndrome (CZS)	88

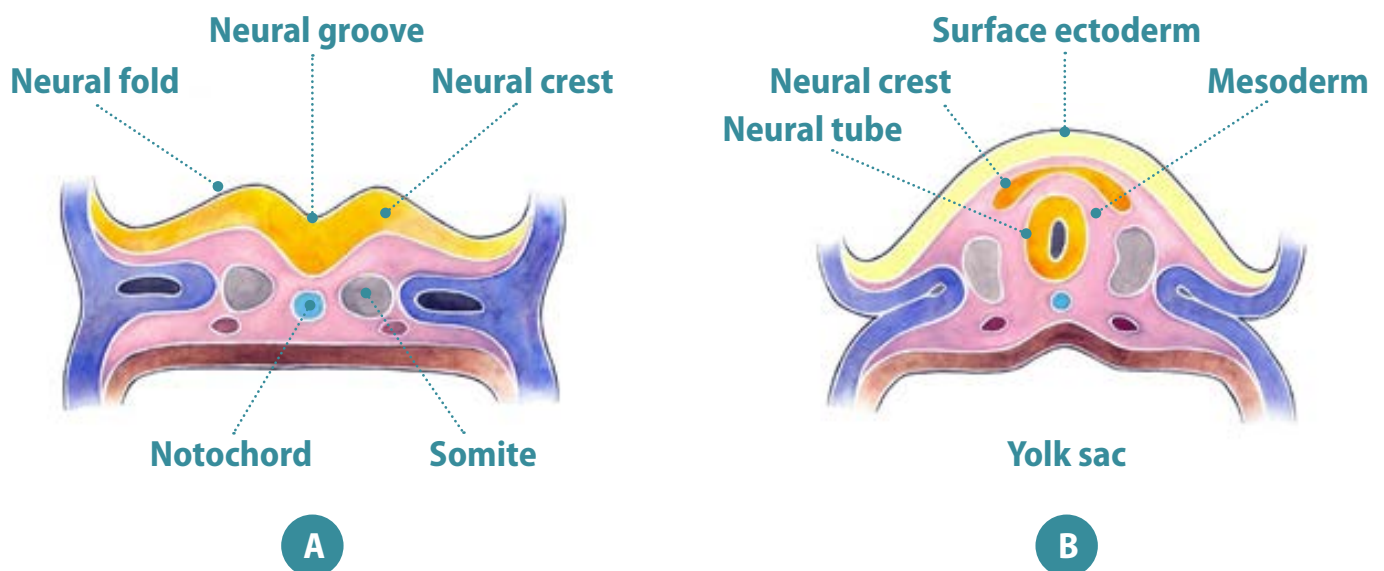


CONGENITAL ANOMALIES OF THE NERVOUS SYSTEM: NEURAL TUBE DEFECTS

Neural tube defects (NTDs) affect the brain and spinal cord, and are among the most common of the congenital anomalies (see Fig. 1). *Panel A* shows a cross section of the rostral end of the embryo at approximately three weeks after conception, showing the neural groove in the process of closing, overlying the notochord. The neural folds are the rising margins of the neural tube, topped by the neural crest, and demarcate the neural groove centrally. *Panel B* shows a cross section of the middle portion of the embryo after the neural tube has closed. The neural tube – which will ultimately develop into the spinal cord – is now covered by surface ectoderm (later, the skin). The intervening mesoderm will form the bony spine. The notochord is regressing. *Panel C* shows the developmental and clinical features of the main types of NTDs. The diagram in the centre is a dorsal view of a developing embryo, showing a neural tube that is closed in the centre but still open at the cranial and caudal ends. The dotted lines marked A and B refer to the cross sections shown in *panels A* and *B*. Shaded bars point to the region of the neural tube relevant to each defect.

The most prevalent types of NTDs are anencephaly, encephalocele and spina bifida. In anencephaly, the absence of the brain and calvaria can be total or partial. Craniorachischisis is characterized by anencephaly accompanied by a contiguous bony defect of the spine and exposure of neural tissue. In open spina bifida, a bony defect of the posterior vertebral arches (in this case, the lower thoracic vertebrae) is accompanied by herniation of neural tissue and meninges and is not covered by skin. In iniencephaly, dysraphia in the occipital region is accompanied by severe retroflexion of the neck and trunk. In encephalocele, the brain and meninges herniate through a defect in the calvaria. In closed spina bifida, unlike open spina bifida, the bony defect of the posterior vertebral arches (in this case, the lumbar vertebrae), the herniated meninges and neural tissue are covered by skin.

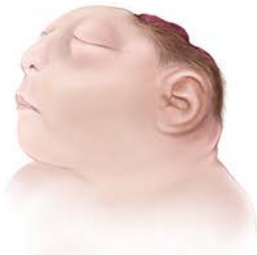Fig. 1. Neural tube defects



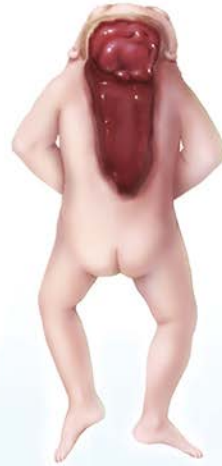Adapted from: Botto LD, Moore CA, Khoury MJ, Erickson JD. Neural tube defects. *N Engl J Med.* 1999;341(20):1509–19. Reproduced with permission from the publisher.



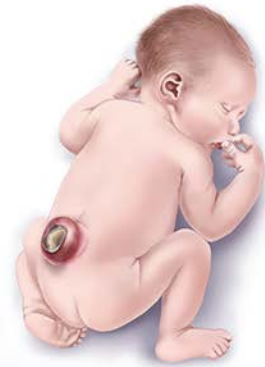Anencephaly



Craniorachischisis



Open spina bifida



Cranial neuropore

A

B

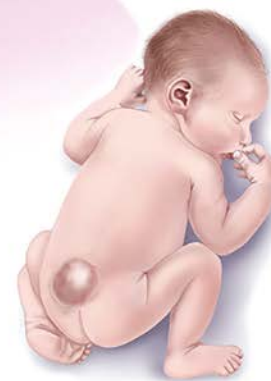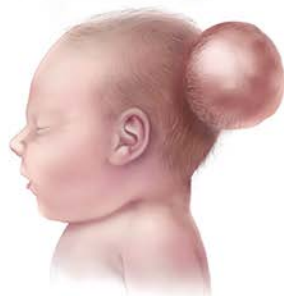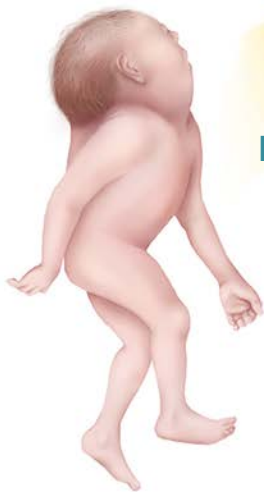Caudal neuropore

Neural fold

C

Somite

Neural groove



Iniencephaly

Encephalocele

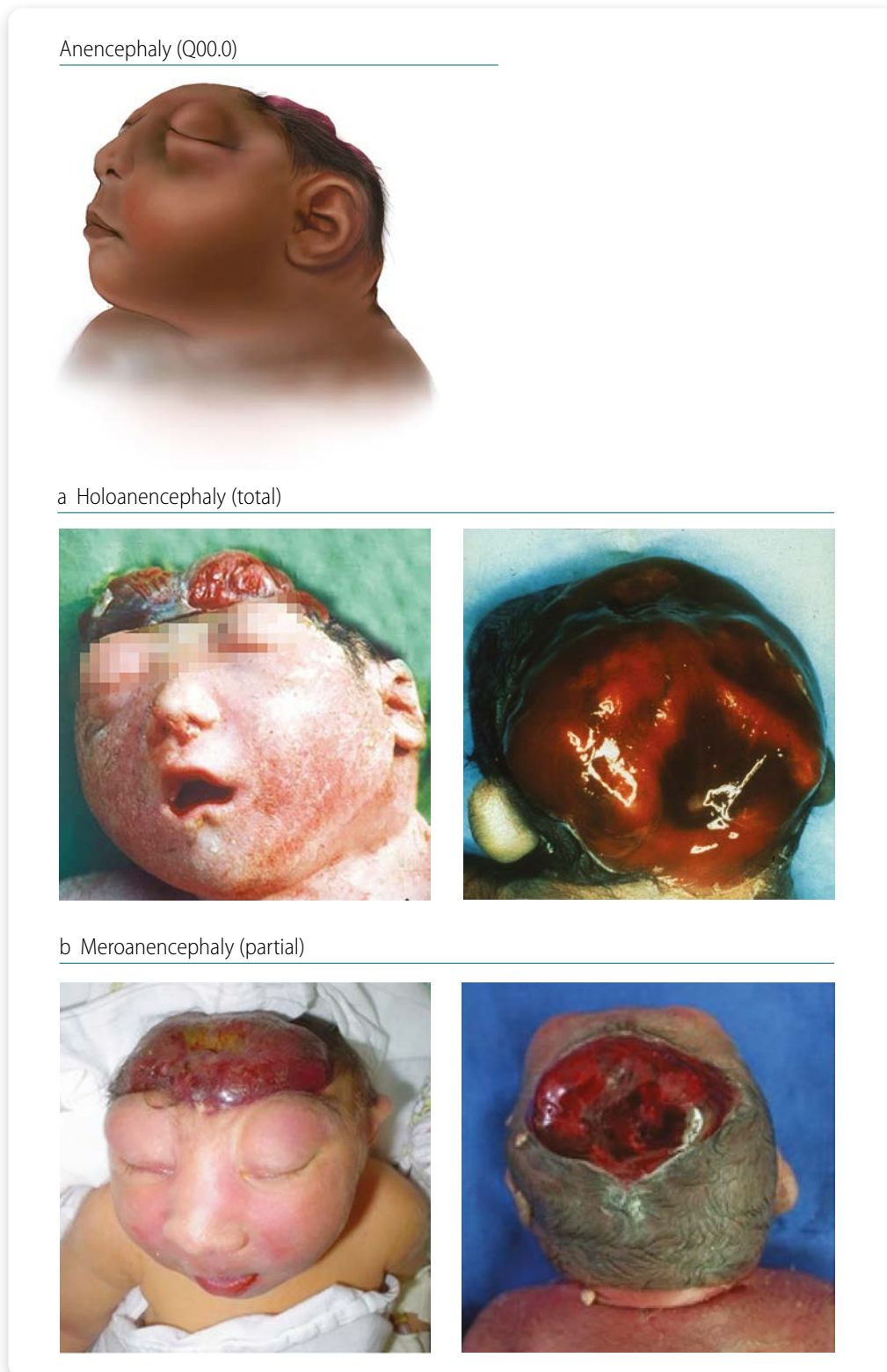
Closed spina bifida

Adapted from: Botto LD, Moore CA, Khoury MJ, Erickson JD. Neural tube defects. N Engl J Med. 1999;341(20):1509–19. Reproduced with permission from the publisher.

ANENCEPHALY (Q00.0)

Anencephaly is characterized by a total (holo) or partial (mero) absence of the brain with absence of the cranial vault (calvaria) and covering skin.

Fig. 2. Anencephaly



Photograph sources: Latin American Collaborative Study of Congenital Malformations (ECLAMC); CDC–Beijing Medical University collaborative project.



Key findings in anencephaly (see Fig. 2):

1. **Type** – holooanencephaly (*panel a*: total absence) is the most common type of anencephaly; meroanencephaly (*panel b*: partial absence).
2. **Covering** – no skin covering residual brain tissue or cranial vault (calvarium).

Diagnosis

Prenatal. Anencephaly is diagnosed prenatally but should always be confirmed postnatally. Use programme rules (standard operating procedures [SOPs]) to decide whether to accept or not accept prenatal diagnoses without postnatal confirmation (e.g. in cases of termination of pregnancy or unexamined fetal death).

Postnatal. The newborn examination confirms the diagnosis and will distinguish anencephaly from the other anomalies of the brain and cranium.

Clinical and epidemiologic notes

Anencephaly is a lethal condition and is often an isolated, non-syndromic anomaly.

- ▶ Eyes are normally formed; bulging is a result of absence of the frontal portion of the cranial vault.
- ▶ Cerebellum, brain stem and spinal cord are intact.

Additional clinical tips:

- ▶ Anencephaly can be confused with:
 - Craniorachischisis characterized by anencephaly plus rachischisis, a contiguous upper spine defect without meninges covering the neural tissue.
 - Amniotic band or limb-body wall spectrum, which have other findings (facial schisis, limb and ventral wall anomalies, bands) and allow the differentiation from typical anencephaly.

Checklist for high-quality reporting

Anencephaly – Documentation Checklist

□ Describe defect in detail:

- ▶ Extent – holooanencephaly versus meroanencephaly.
- ▶ Cervical spine – document no contiguous defects.
- ▶ Whether a non-contiguous spina bifida is present (location).
- ▶ Whether amniotic bands are present.

□ **Take and report photographs:** *Show clearly* the missing cranium; can be crucial for review.

□ Describe evaluations to find or rule out related and associated anomalies:

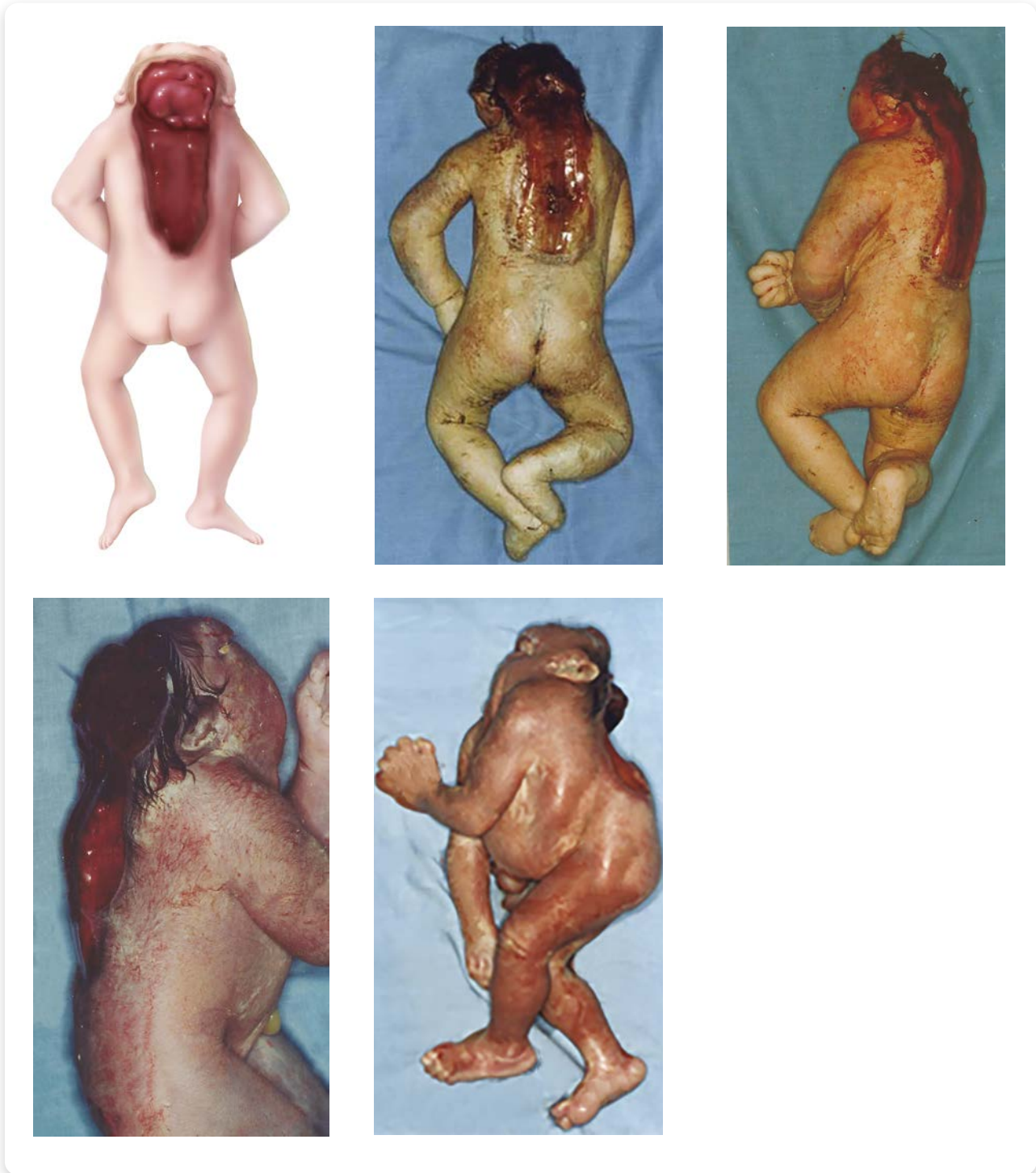- ▶ Eyes protruding but normally developed (do not include as an associated anomaly).
- ▶ Head circumference will be small – do not code as microcephaly.

□ **Report whether autopsy (pathology) findings are available and if so, report the results.**

CRANIORACHISCHISIS (Q00.1)

Craniorachischisis is characterized by the combination of anencephaly (absence of the brain and cranial vault, without skin covering) with a contiguous bony defect of the cervical spine (also without meninges covering the neural tissue – rachischisis).

Fig. 3. Craniorachischisis



Photograph source: CDC–Beijing Medical University collaborative project.



Key findings in craniorachischisis (see Fig. 3):

1. **Head** – anencephaly (absence of the brain and cranial vault).
2. **Covering** – no skin covering residual brain tissue, spinal cord tissue, or cranial vault (calvarium).
3. **Spine** – open (rachischisis) might be limited to the cervical spine, but the open defect can extend to the thoracic spine or even lumbar or sacral spine (craniorachischisis totalis).

Diagnosis

Prenatal. Craniorachischisis is readily diagnosed using ultrasound but can be confused with other defects involving the brain – anencephaly, acrania and amniotic band syndrome. Use programme rules (SOPs) to decide whether to accept or not accept prenatal diagnoses without postnatal confirmation (e.g. in cases of termination of pregnancy or unexamined fetal death).

Postnatal. Careful examination of the fetus or newborn can confirm the diagnosis of craniorachischisis and distinguish it from the other rare anomalies that involve the brain, cranium and spine.

Clinical and epidemiologic notes

Craniorachischisis is a lethal condition and is often an isolated, non-syndromic anomaly.

- ▶ Eyes are normally formed; bulging is a result of absence of the frontal portion of the cranial vault.
- ▶ Neck may appear to be shortened and is sometimes retroflexed.
- ▶ Cerebellum and brain stem are intact.
- ▶ Craniorachischisis is always an open lesion, with the anencephaly always being contiguous with the spinal lesion.

Additional clinical tips:

- ▶ Craniorachischisis might co-occur with other anomalies: Cleft lip and palate, omphalocele, limb defects, or cyclopia.
- ▶ Check for chromosomal anomaly: Case reports of trisomy 18 with craniorachischisis and omphalocele have been reported.
- ▶ Craniorachischisis might be confused with:
 - Amniotic band or limb-body wall spectrum, which have other findings (facial schisis, limb and ventral wall anomalies, bands) and allow the differentiation from typical craniorachischisis.
 - Iniencephaly if spinal retroflexion is present.

Checklist for high-quality reporting

Craniorachischisis – Documentation Checklist

Describe in detail:

- ▶ Defect – overall presentation.
- ▶ Extent of spinal involvement (cervical spine or lower) – especially comment on and document the fact that the head involvement (anencephaly) and the spine defect are contiguous, without intervening normal-appearing spine.
- ▶ Retroflexion of neck and spine – this is more typical of iniencephaly, so important to note.
- ▶ If amniotic bands are present – disruptions by amniotic bands could possibly mimic severe atypical NTDs.

Take and report photographs: *Show clearly* the missing cranium and spine; can be crucial for review.

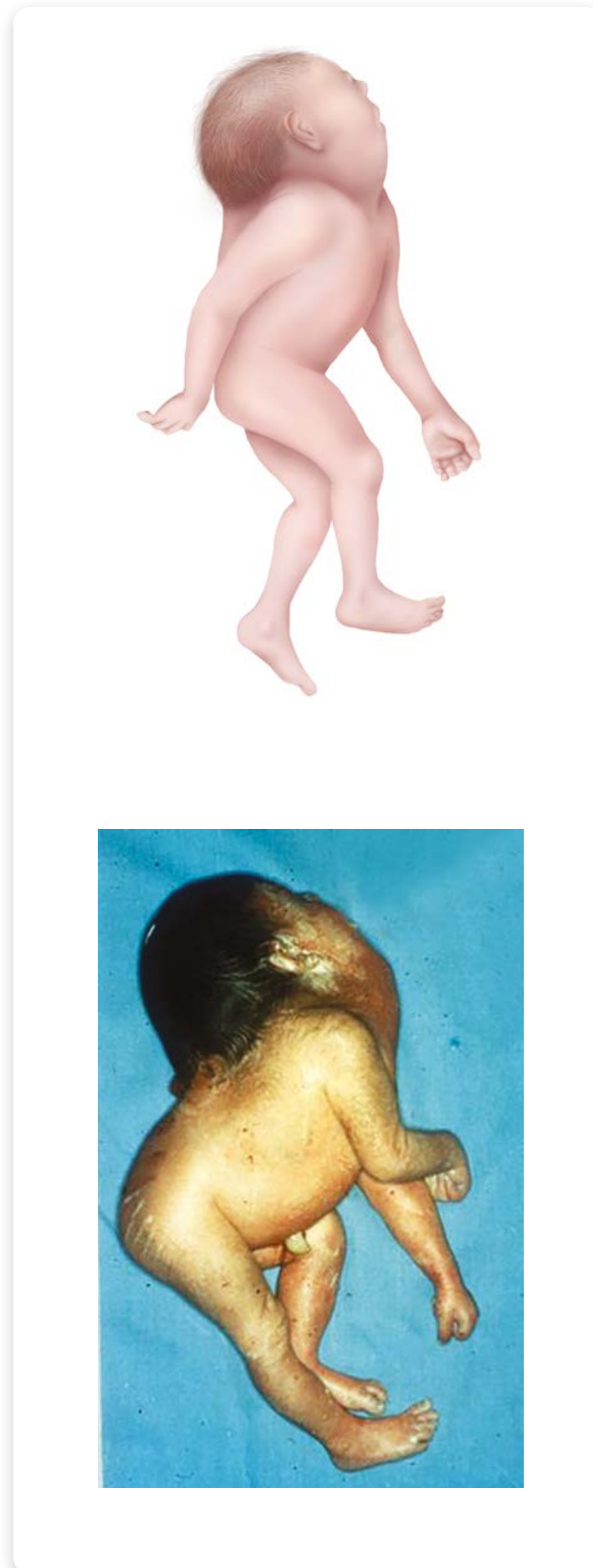
Describe evaluations to find or rule out related and associated anomalies:

- ▶ Orbits – usually protruding but normally developed (do not include as an associated anomaly).
- ▶ Head circumference will be small – do not code as microcephaly.
- ▶ Spina bifida (mention but do not code contiguous defects).
- ▶ Other anomalies or chromosomal abnormality.

Report whether autopsy (pathology) findings are available and if so, report the results.

Iniencephaly is a rare and complex neural tube defect (NTD) involving the occiput and inion, resulting in extreme retroflexion of the head, variably combined with occipital encephalocele or rachischisis of the cervical or thoracic spine.

Fig. 4. Iniencephaly



Photograph source: CDC-Beijing Medical University collaborative project.



Key findings in iniencephaly (see Fig. 4):

1. **Head** – tilted (retroflexed) with upward looking face, a short neck or neck may appear to be missing (due to fusion of the cervical and thoracic vertebrae). Some infants also have an occipital encephalocele.
2. **Covering** – cranium is closed and covered in skin. The internal spine abnormalities result in the skin of the face appearing to be directly connected to the skin of the chest and the skin of the scalp also appearing to be directly connected to the skin of the back.
3. **Spine** – usually closed but might be open at the cervical spine.

Diagnosis

Prenatal. Iniencephaly may be difficult to diagnose by ultrasound and can be confused with other defects involving the brain and spine – anencephaly, encephalocele and craniorachischisis, as well as teratomas, goiter, lymphangioma, and some syndromes. Use programme rules (SOPs) to decide whether to accept or not accept prenatal diagnoses without postnatal confirmation (e.g. in cases of termination of pregnancy or unexamined fetal death).

Postnatal. Careful examination of the fetus or newborn can confirm the diagnosis of iniencephaly and distinguish it from the other anomalies that involve the brain, cranium and spine.

Clinical and epidemiologic notes

Iniencephaly is a lethal condition and often (84%) associated with other findings:

- ▶ With other unrelated birth defects:
 - Micrognathia, cleft lip and palate, cardiovascular disorders, diaphragmatic hernias, and gastrointestinal malformations.
- ▶ With certain chromosomal conditions – trisomy 13 and 18, and monosomy X.

Additional clinical tips:

- ▶ Iniencephaly is more common among female infants.
- ▶ Can be confused with craniorachischisis with spinal retroflexion.

Checklist for high-quality reporting

Iniencephaly – Documentation Checklist

Describe in detail:

- ▶ Defect description – note in particular whether cranium is skin-covered, head retroflexed.
- ▶ Presence or absence of occipital encephalocele.
- ▶ Presence or absence of spina bifida (open or closed).
- ▶ Report other anomalies.

Take and report photographs: *Show clearly* the lateral view of the cranium and spine; can be crucial for review.

Describe evaluations to find or rule out related and associated anomalies:

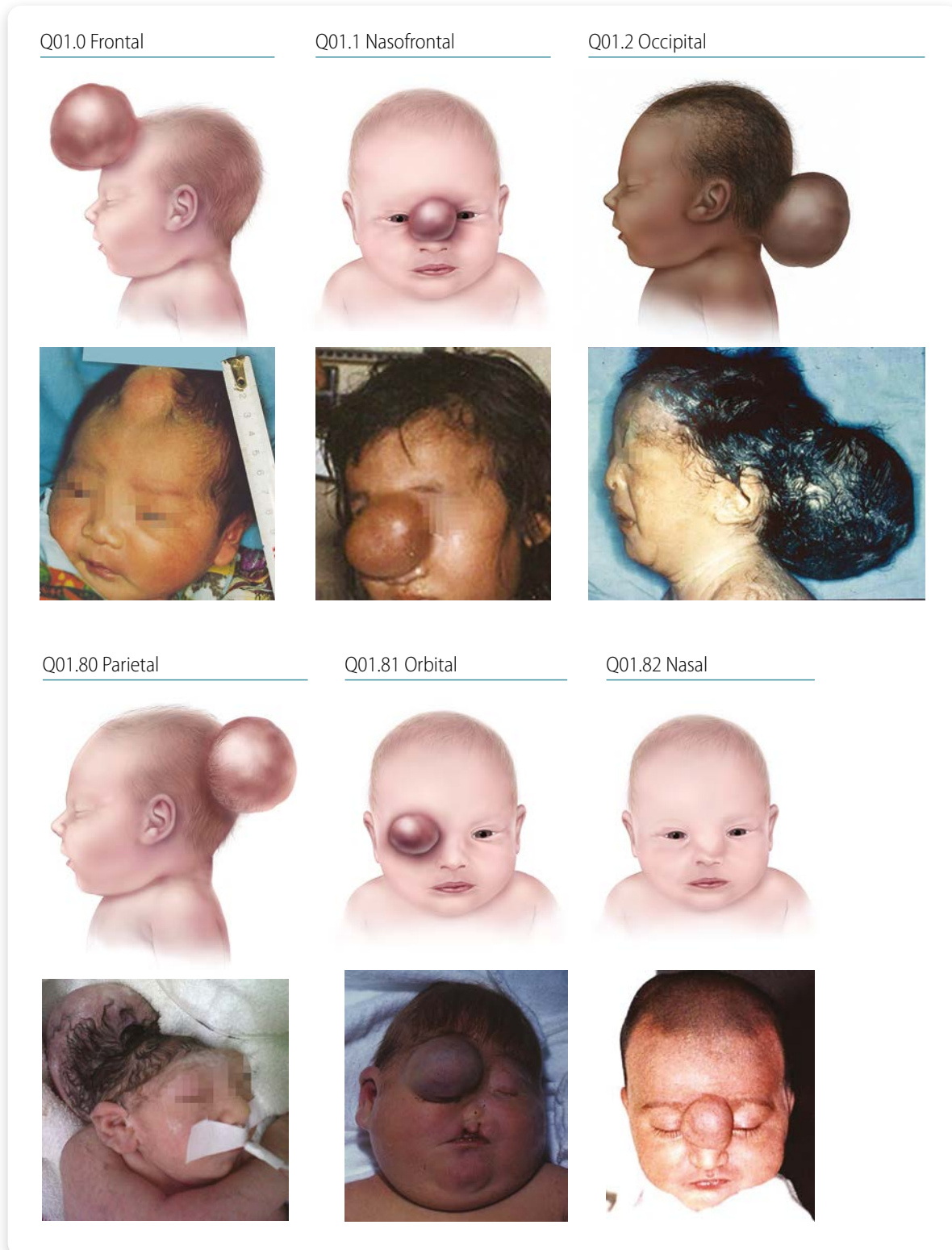- ▶ Head circumference may be large – do not code as hydrocephaly.
- ▶ Spina bifida (code as non-contiguous defect).
- ▶ Encephalocele (code although contiguous defect).
- ▶ Include radiographs (or report) of the spine if performed.

Report whether autopsy (pathology) findings are available and if so, report the results.

ENCEPHALOCELE (Q01.0–Q01.83, Q01.9)

Encephalocele is an NTD characterized by a pedunculated or sessile cystic, skin-covered lesion protruding through a defect in the cranium (skull bone). Encephaloceles can contain herniated meninges and brain tissue (encephalocele or meningoencephalocele) or only meninges (cranial meningocele).

Fig. 5. Encephalocele



Photograph sources: CDC–Beijing Medical University collaborative project; Dr. Jaime Frias.



Key findings in encephalocele (see Fig. 5):

1. **Location** – the midline defect will vary in location and size; the most common location is occipital (~74%), followed by parietal (13%).
2. **Covering** – encephalocele is skin covered (unless a rupture has occurred).
3. **Herniation** – may contain meninges and brain tissue (encephalocele) or meninges only (cranial meningocele).

Diagnosis

Prenatal. Encephalocele might be diagnosed prenatally using ultrasound but should always be confirmed postnatally. Use programme rules (SOPs) to decide whether to accept or not accept prenatal diagnoses without postnatal confirmation (e.g. in cases of termination of pregnancy or unexamined fetal death).

Postnatal. The newborn examination, x-ray and magnetic resonance imaging (MRI) or computed tomography (CT) confirm the diagnosis and will distinguish it from the other anomalies that may involve the brain and cranium.

Clinical and epidemiologic notes

Approximately 20% of infants with encephalocele will have at least one additional unrelated major birth defect:

- ▶ Polydactyly and/or renal anomalies.
- ▶ May co-occur with Dandy-Walker malformation or Chiari malformation.
- ▶ Can occur with many single genes disorders (e.g., Meckel-Gruber syndrome) and with some chromosomal anomalies (e.g., trisomy 13, trisomy 18).

Additional clinical tips:

- ▶ Always look for additional anomalies and syndromes.
- ▶ Note encephalocele location and size, and document if meninges and brain are herniated.
- ▶ Check if amniotic bands are mentioned – encephalocele might be confused with the amniotic band spectrum. The occurrence of other findings (facial schisis, limb and ventral wall anomalies, bands) points towards the diagnosis of amniotic band spectrum.

Checklist for high-quality reporting

Encephalocele – Documentation Checklist

Describe in detail:

- ▶ Defect location – occipital, frontal, nasal, parietal, etc.
- ▶ Extent – size and whether brain is present in the sac.
- ▶ Skin covering – it is expected with encephalocele (but could be ruptured).
- ▶ Other anomalies – internal and external anomalies, including polydactyly, renal anomalies, etc.
- ▶ Cephalohematoma or caput succedaneum (benign scalp swelling) – can be confused with encephalocele.
- ▶ Amniotic bands or limb-body wall anomalies – check if present and if so, describe.

Take and report photographs: *Show clearly* the cranial lesion; can be crucial for review.

Describe evaluations to find or rule out related and associated anomalies:

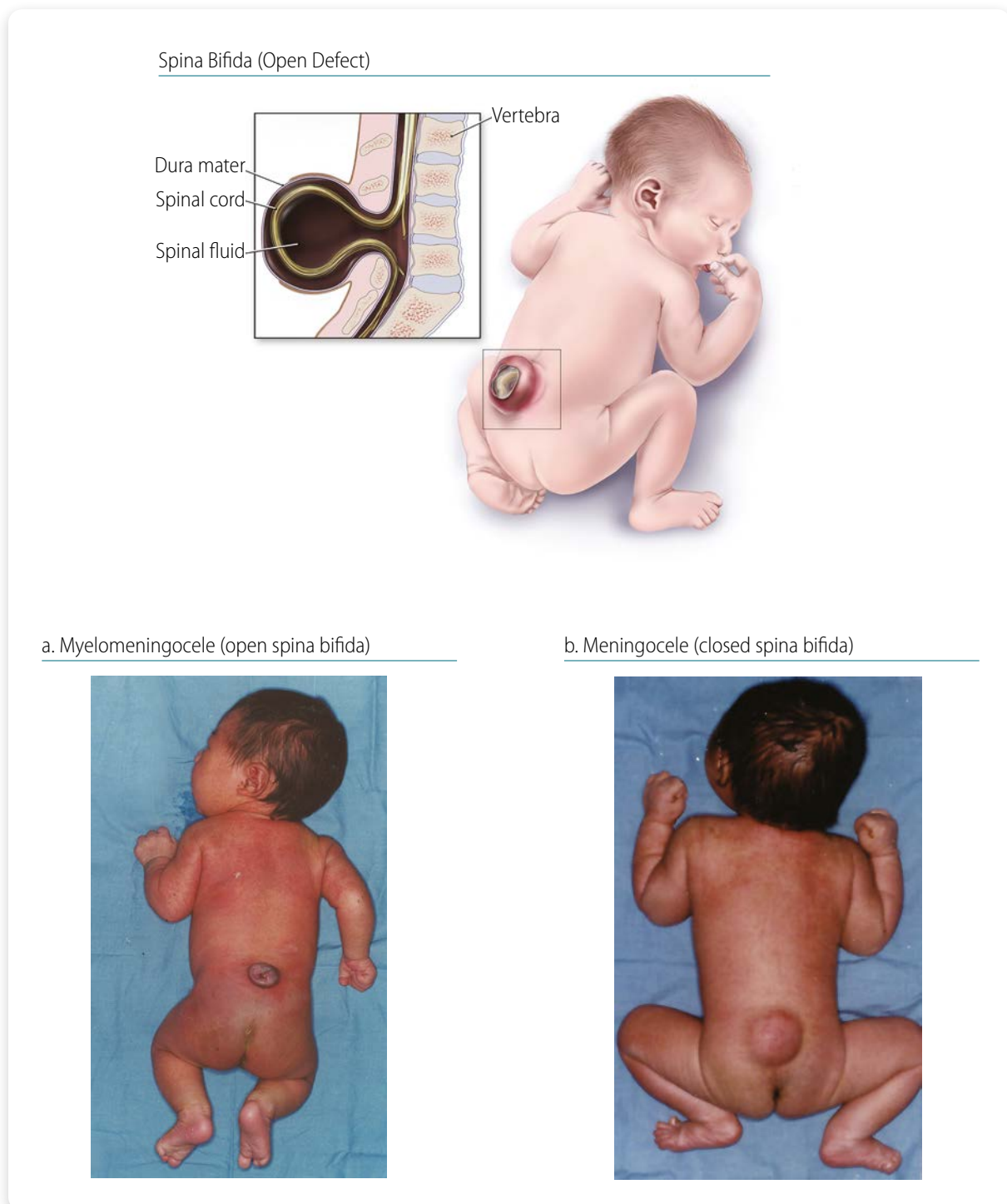
- ▶ Head circumference might be small – do not code as microcephaly.
- ▶ Hydrocephalus might be present – do not code as hydrocephalus.
- ▶ Genetic or chromosomal testing performed, where available.
- ▶ Specialty consultations and surgical reports.

Report whether autopsy (pathology) findings are available and if so, report the results.

SPINA BIFIDA (Q05.0–Q05.9)

Spina bifida is an NTD characterized by herniation of meninges and spinal cord (see Fig. 6, *panel a*: myelomeningocele) or meninges only (see Fig. 6, *panel b*: meningocele). Lesion can be open or closed. Hydrocephalus is a common complication, especially among children with open myelomeningocele. Figs. 7–10 show the different spina bifida lesion levels.

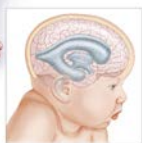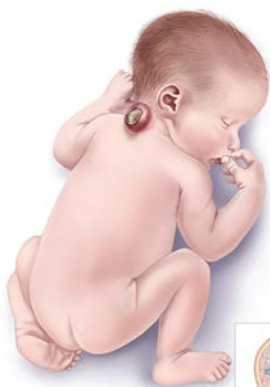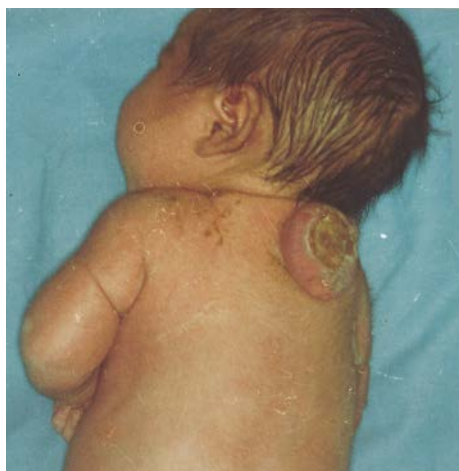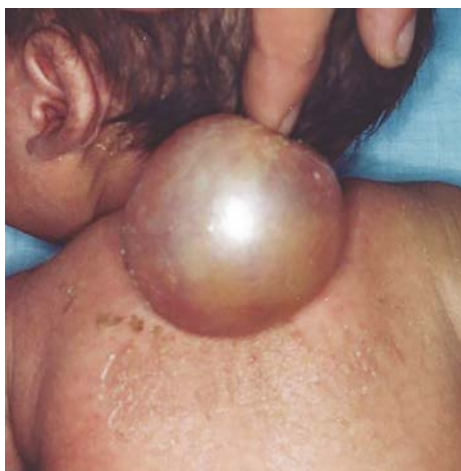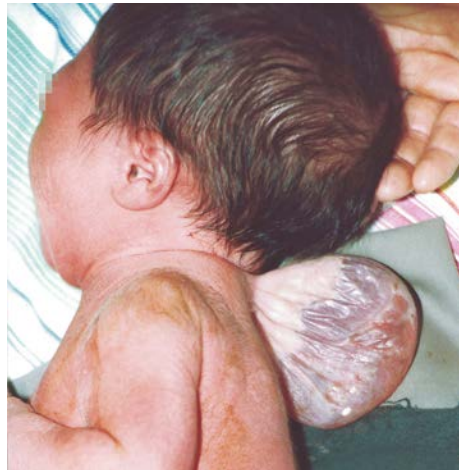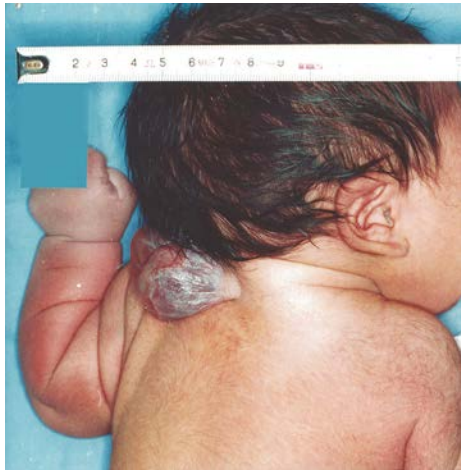Fig. 6. Spina bifida



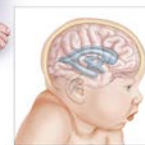
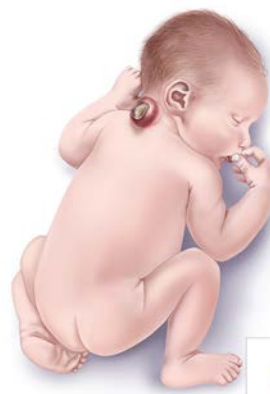
Spina bifida lesion levels
Cervical spina bifida

Fig. 7. Cervical spina bifida



Cervical spina bifida with hydrocephalus (Q05.0)



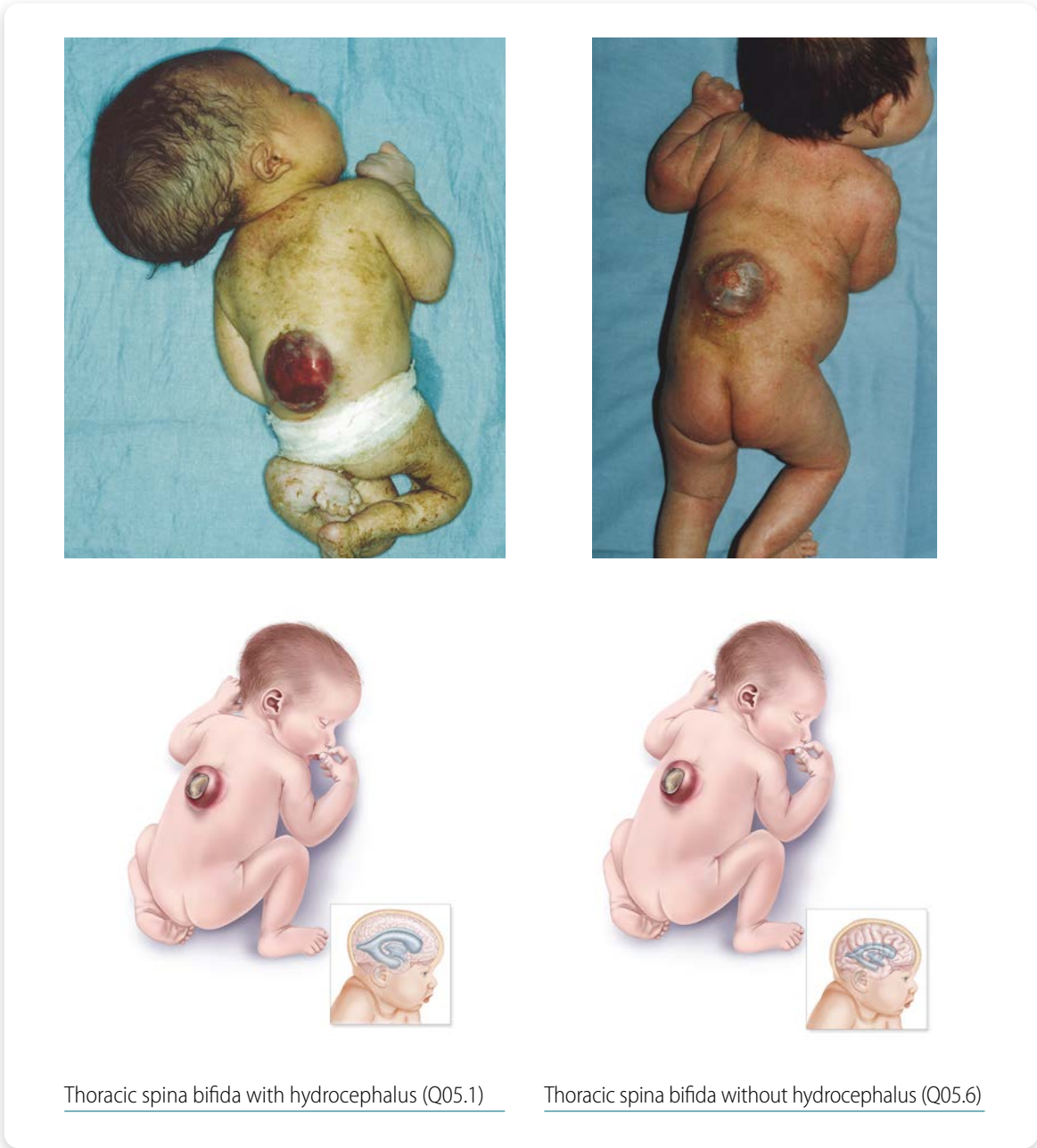
Cervical spina bifida without hydrocephalus (Q05.5)

Photograph source: CDC—Beijing Medical University collaborative project.



Thoracic spina bifida

Fig. 8. Thoracic spina bifida

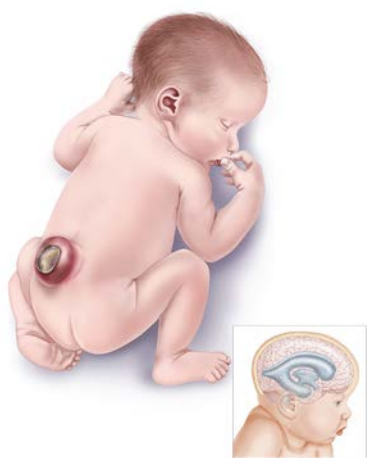
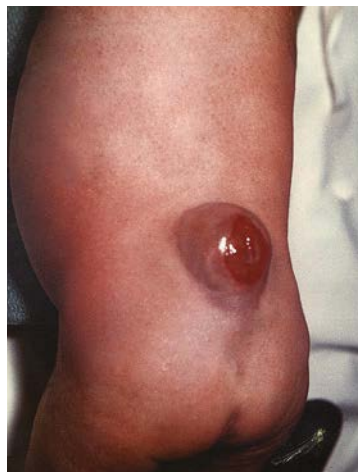
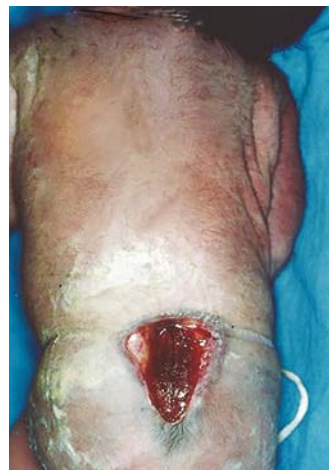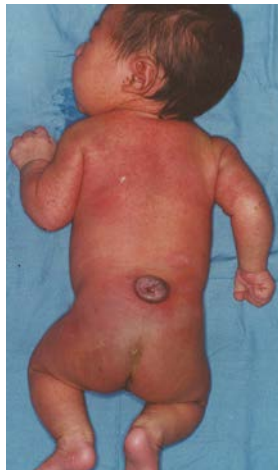Photograph source: CDC—Beijing Medical University collaborative project.

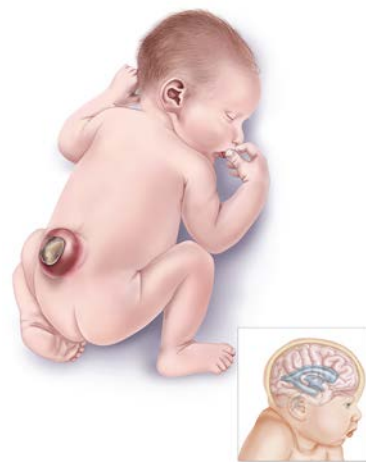

Lumbar spina bifida

Fig. 9. Lumbar spina bifida



Lumbar spina bifida with hydrocephalus (Q05.2)



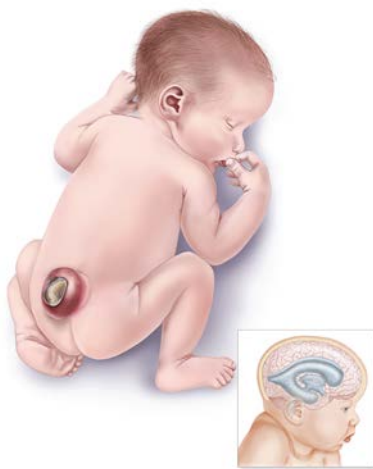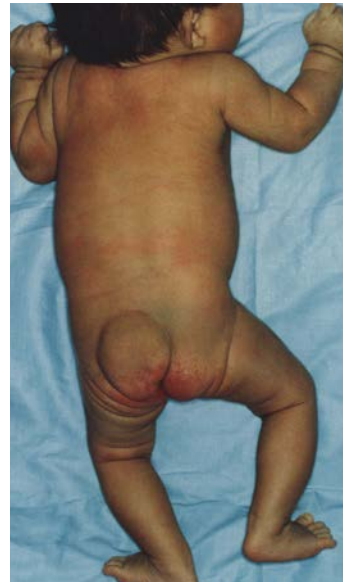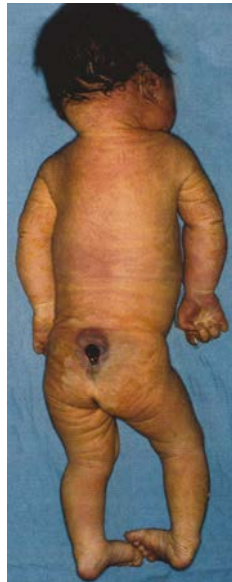Lumbar spina bifida without hydrocephalus (Q05.7)

Photograph sources: CDC–Beijing Medical University collaborative project; Idalina Montes, MD, and Rafael Longo, MD, FACS, Puerto Rico.

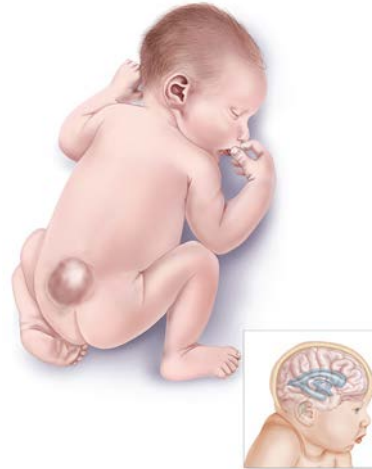

Sacral spina bifida

Fig. 10. Sacral spina bifida



Sacral spina bifida with hydrocephalus
(Q05.3)



Sacral spina bifida without hydrocephalus
(Q05.8)

Photograph source: CDC-Beijing Medical University collaborative project.



Key findings in spina bifida:

1. **Location** – level of the lesion; that is, lumbar spine (the most common location), followed by sacral, thoracic and cervical.
2. **Covering** – open, non-skin covered (myelomeningocele) represents 90% of spina bifida; 10% have a closed lesion (meningocele – containing only meninges and cerebral spinal fluid).
3. **Size** – can vary from single vertebral to multiple levels (thoracic-lumbar).

Diagnosis

Prenatal. Spina bifida might be diagnosed prenatally using ultrasound, but distinguishing if the lesion is open or closed can be challenging. Maternal serum screening might help to determine an open versus a closed lesion. Use programme rules (SOPs) to decide whether to accept prenatal diagnoses without postnatal confirmation (e.g. in cases of termination of pregnancy or unexamined fetal death).

Postnatal. The newborn examination usually confirms the diagnosis. Imaging (when available) can provide additional information to characterize the location, extent and content of the lesion, as well as the presence or absence of frequently co-occurring brain findings (e.g. hydrocephalus, Chiari II malformation).

Clinical and epidemiologic notes

Spina bifida is often an isolated, non-syndromic (~80%) anomaly. Related findings include:

- ▶ Chiari II malformation and hydrocephalus.
- ▶ Hip dislocation, talipes, lower limb paralysis.
- ▶ Loss of sphincter control, including neurogenic bladder.

Additional clinical tips:

- ▶ Always look for additional anomalies and syndromes (trisomy 18).
- ▶ Occurs in OEIS complex (**o**mphalocele–**e**xstrophy of the bladder–**i**mperforate anus–**s**pinal defects).
- ▶ Review examinations, procedures and imaging – rare conditions misdiagnosed as spina bifida include spina bifida occulta, sacrococcygeal teratoma, isolated scoliosis/kyphosis, and amniotic band syndrome.
- ▶ Lipomeningo(myelo)cele is a rare type of spina bifida with an overlying lipoma; many programmes do not include lipomeningo(myelo)celes as an NTD.

Checklist for high-quality reporting

Spina Bifida – Documentation Checklist

- Describe defect in detail:**
 - ▶ Location – specify level (e.g. cervical, thoracic, thoraco-lumbar, lumbar, lumbosacral, sacral, etc.).
 - ▶ Size of lesion.
 - ▶ Covering – covered by skin or not covered by skin.
 - ▶ Content – only meninges (meningocele) or also spinal cord (myelomeningocele – spinal cord visible).
 - ▶ Anomalies – document sequence defects (hydrocephalus, talipes) and other anomalies.
- Take and report photographs:** *Show clearly* the level of spina bifida (back and side if possible); can be crucial for review.
- Describe evaluations to find or rule out related and associated anomalies:**
 - ▶ Sequence – hydrocephalus, talipes, other.
 - ▶ Other unrelated anomalies – describe procedures to assess other anomalies.
 - ▶ Genetic or chromosomal conditions.
 - ▶ Specialty consultations, imaging and surgery.
- Report whether autopsy (pathology) findings are available and if so, report the results.**

CONGENITAL ANOMALIES OF THE NERVOUS SYSTEM

MICROCEPHALY (Q02)

Microcephaly is a cranial vault that is smaller than normal for the baby's sex and gestational age at birth (see Fig. 11). The size of the cranial vault is an indicator of the size of the underlying brain.

Fig. 11. Newborn with a normal head size, microcephaly, and severe microcephaly

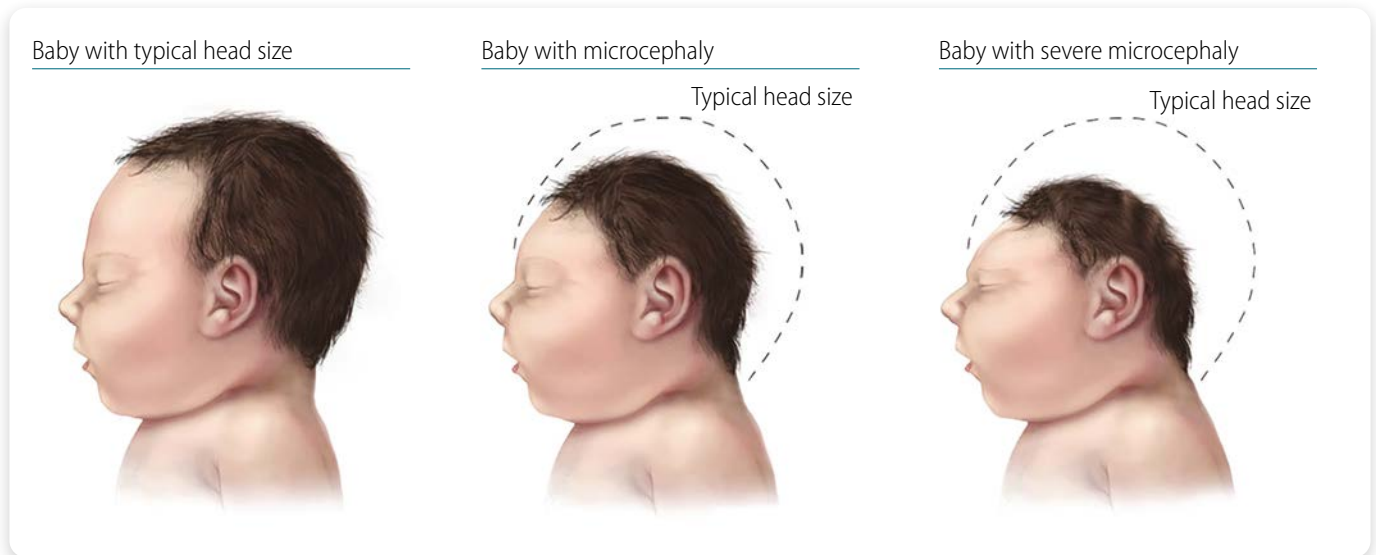
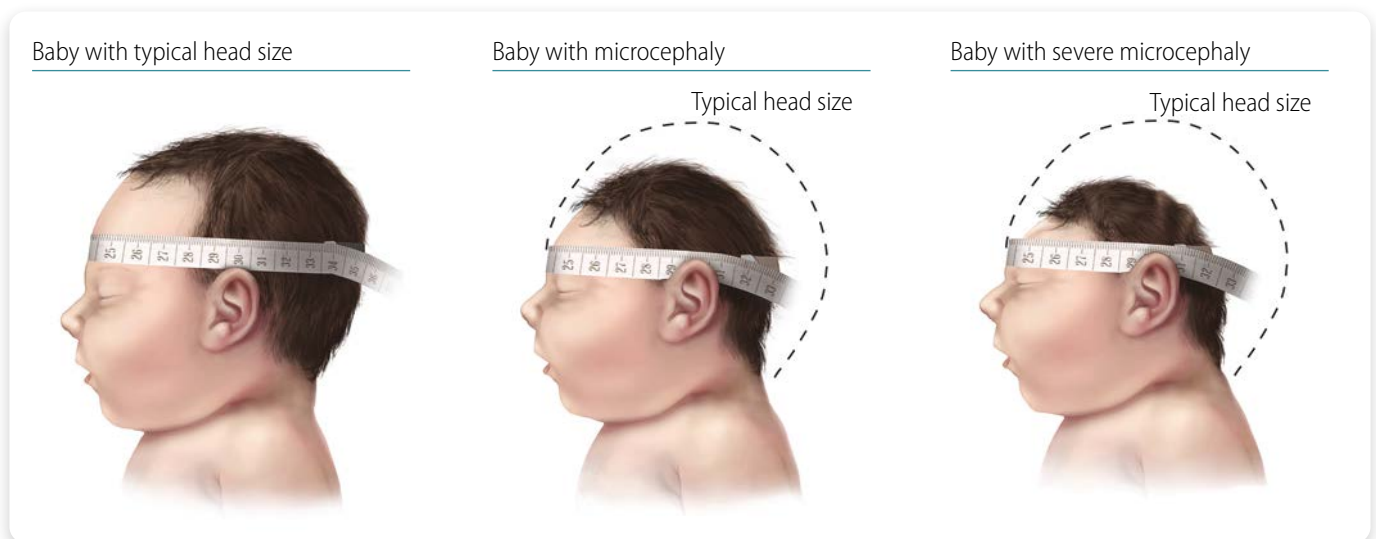

Fig. 12. Measurement of head size



Diagnosis

Prenatal. Transabdominal ultrasound between 18 and 37 weeks' gestation might identify a small head size and with serial ultrasounds, showing poor growth over time.

Postnatal. At delivery, a measurement of the occipito-frontal circumference (OFC) or head circumference (HC) that is three standard deviations (SD) below the mean for the age- and sex-appropriate distribution curves is diagnostic of severe microcephaly.

Report if using a different definition or cut-off point to define microcephaly (e.g. two SD below the mean). Detailed imaging and expert consultations (e.g. paediatric geneticist, paediatric neurologist) can confirm the diagnosis of an underlying brain abnormality and might help identify the underlying cause of microcephaly.



Clinical and epidemiologic notes

Measurement of head size:

- ▶ Use a tape measure that cannot be stretched.
- ▶ Place the tape around the widest part of the head, above the eyebrows and ears, on the forehead and most prominent part of the occiput (see Fig. 12).
- ▶ Record the measurement to the nearest 0.1 cm.
- ▶ Ideally, the measurement should be taken three times (use largest).
- ▶ Although head moulding and/or swelling can occur during the birthing process, HC measurements should be obtained within the first 24 hours of life. Standards for HC were developed on early measurements (i.e. INTERGROWTH-21st measurements were obtained before 12 hours of life and WHO measurements were obtained before 24 hours of life). Therefore, postponing HC measurements until after 24 hours of life to allow for birth process changes to subside results in not having appropriate comparison standards.

Calculating the percentile of the HC:

The INTERGROWTH-21st online tool (<http://intergrowth21.ndog.ox.ac.uk>) can be used to enter data to calculate the percentile of the HC or compare to standards based on the infant's sex and prematurity.

Clinical presentation:

- ▶ Many genetic syndromes are associated with microcephaly: Autosomal recessive microcephaly; trisomy 18; inborn errors of metabolism; Rett syndrome, etc.
- ▶ Teratogenic conditions with microcephaly include congenital rubella, CMV, congenital Zika infection and congenital toxoplasmosis.

Additional clinical tips:

- ▶ Always calculate the percentile of HC considering sex and gestational age.
- ▶ There is no single definition of microcephaly that is universally used. Report which charts (e.g. INTERGROWTH-21st) and cut-off points you are using to define microcephaly.
- ▶ Microcephaly can occasionally be a normal trait in a family (though less likely if severe or symptomatic); therefore, measuring parents' OFC if possible is reasonable.
- ▶ Obtain a thorough pregnancy history, looking in particular for infections and other exposures.

Depending on capacity and clinical findings, consider imaging to document intracranial anatomy and selected laboratories (genetic studies, viral studies, etc.).

Checklist for high-quality reporting

Microcephaly – Documentation Checklist

Describe in detail:

- ▶ Measure and document HC in newborn.
- ▶ Establish and use a standardized approach (e.g. follow standard rules for taking HC measurement within 24 hours after birth).
- ▶ Document the HC percentile or SD, by gestational age and sex (use the Recommended References for HC provided by INTERGROWTH-21st or WHO).
- ▶ Distinguish microcephaly from craniosynostosis.

Take and report photographs: *Show full face and body photographs, if allowed; can be crucial for review.*

Describe evaluations to find or rule out related and associated anomalies:

- ▶ Report neurologic status and signs (e.g. tone, seizures, irritability).
- ▶ Report whether laboratory examinations (e.g. serology to identify infections) or specialty consultations (e.g. genetics) were done, and if so, report the results.










Report whether autopsy (pathology) findings are available and if so, report the results.

CONGENITAL ANOMALIES OF THE EAR

MICROTIA/ANOTIA (Q16.0, Q17.2)

Microtia/anotia is a congenital malformation of the ear in which the external ear (auricle) is underdeveloped and either abnormally shaped (microtia) or absent (anotia). The external ear canal may be atretic (absent). The spectrum of severity in microtia ranges from a measurably small external ear (defined as longitudinal ear length below minus two SD from the mean, or approximately 3.3 cm in the term newborn) with minimal structural abnormality, to an ear that consists of few rudimentary structures and an absent or blind-ending external ear canal.

Fig. 13. Microtia/anotia

Normal infant ear			
			
<p>Microtia I</p> <ul style="list-style-type: none"> ▶ Ear is small ▶ Ear canal may be narrowed ▶ Structures and ear shape are otherwise normal 	<p>Microtia II</p> <ul style="list-style-type: none"> ▶ Ear is small ▶ Some components are missing ▶ Shape is markedly abnormal ▶ Ear is still recognizable 	<p>Microtia III</p> <ul style="list-style-type: none"> ▶ Ear consists of a vertical mass of soft tissue and cartilage ▶ Typically associated with atresia of the external canal 	<p>Microtia IV or Anotia</p> <ul style="list-style-type: none"> ▶ Most extreme and rarest form ▶ All external ear structures are absent
			
<p>Microtia I Q17.21</p>	<p>Microtia II Q17.22</p>	<p>Microtia III Q17.23</p>	<p>Microtia IV or Anotia Q16.0</p>
			

Photograph source: <http://en.atlaseclamc.org>



Key findings in microtia/anotia (see Fig. 13):

1. **Severity** – I-IV degree, based on the extent of external ear involvement and atresia of the external canal.
2. **Sidedness** – unilateral (usually unilateral; more often on right side) versus bilateral; severity can vary between the left and right sides.

Diagnosis

Prenatal. Microtia/anotia is easy to miss prenatally. Delineating the position and shape of the ear might require three-dimensional ultrasound. Even if prenatal ultrasonography suggests microtia/anotia, the diagnosis should always be confirmed postnatally. When such confirmation is not possible – due, for example, to termination of pregnancy or unexamined fetal death – the programme should have criteria in place to determine whether to accept or not accept a case based only on prenatal data.

Postnatal. Microtia-anotia can be easily recognized and classified based on the newborn physical examination. However, abnormalities of the middle and inner ear, commonly associated with the more severe degrees of microtia, should be sought, and typically require advanced imaging (CT or MRI scan), surgery, or autopsy. Because microtia (second degree and above) is associated with hearing loss, hearing should be evaluated as soon as possible, ideally in the newborn period, so that appropriate management can be put in place.

Clinical and epidemiologic notes

Microtia/anotia is an isolated finding in 60–80% of infants. Related findings include:

- ▶ Hearing loss.
- ▶ Other anomalies and syndromes, especially those involving the mandible and face.

Additional clinical tips:

- ▶ Look for microtia/anotia occurring in conjunction with other anomalies and syndromes, especially those involving the mandible and face. Such conditions include the oculo-auriculo-vertebral spectrum (OAVS) and Goldenhar “syndrome”, as well as genetic syndromes, such as Treacher-Collins syndrome and trisomy 18, or teratogenic, such as retinoic acid embryopathy.
- ▶ Review examinations, procedures and imaging.

Checklist for high-quality reporting

Microtia/Anotia – Documentation Checklist

Describe in detail:

- ▶ Defect (unilateral, bilateral).
- ▶ Severity (absent structures, shape, compare to second–third–fourth degrees).
- ▶ Presence/absence of ear canal; presence of ear tags.

Take and report photographs: *Show clearly* the side and front; can be crucial for review.

Describe evaluations to find or rule out related and associated anomalies:

- ▶ Exclude microtia type I – small ear with normal components or with minor anomalies of individual structures is a minor anomaly, not to be included in public health surveillance.
- ▶ Check for preauricular tag or pits (describe; code Q17.0).
- ▶ Downslanting palpebral fissures, small jaw, eyelid coloboma – suggests selected syndromes.
- ▶ Cervical vertebral anomalies suggests OAVS (check for radiographs).
- ▶ Hearing evaluation.
- ▶ Genetic or chromosomal testing.
- ▶ Specialty consultations and surgical reports.

Report whether autopsy (pathology) findings are available and if so, report the results.





CONGENITAL HEART DEFECTS

Overview and early presentation

Congenital heart defects/diseases (CHD) are common, occurring in about one in 100 newborns. Many types of CHD require prompt diagnosis and care, both medical and surgical, to improve survival and health. In some of the milder cases, CHD might resolve on its own (e.g. small ventricular septal defects) or require only regular follow-up. At the other extreme are the critical CHDs, a heterogeneous group of structural heart anomalies that have in common the fact that, if undiagnosed and untreated, they can lead to a baby becoming very sick and dying in the newborn period.

Critical CHDs (CCHDs) include conditions such as hypoplastic left heart syndrome, in which the abnormally small left ventricle cannot support systemic circulation, leading to shock; and conditions such as tetralogy of Fallot or pulmonary atresia, which tend to cause visible cyanosis (bluish tinge on skin, especially notable in the fingers, toes, lips and nose). At times, newborns with CCHD can present a combination of cyanosis and heart failure or shock.

Prompt diagnosis is crucial, but can be challenging. A diagnosis of CCHD can be suspected in a newborn but requires the clinician to have a high level of suspicion, as the findings – often a sick infant getting worse – mimic other common conditions of the newborn, such as infection (e.g. sepsis) or lung disease (e.g. pneumonia).

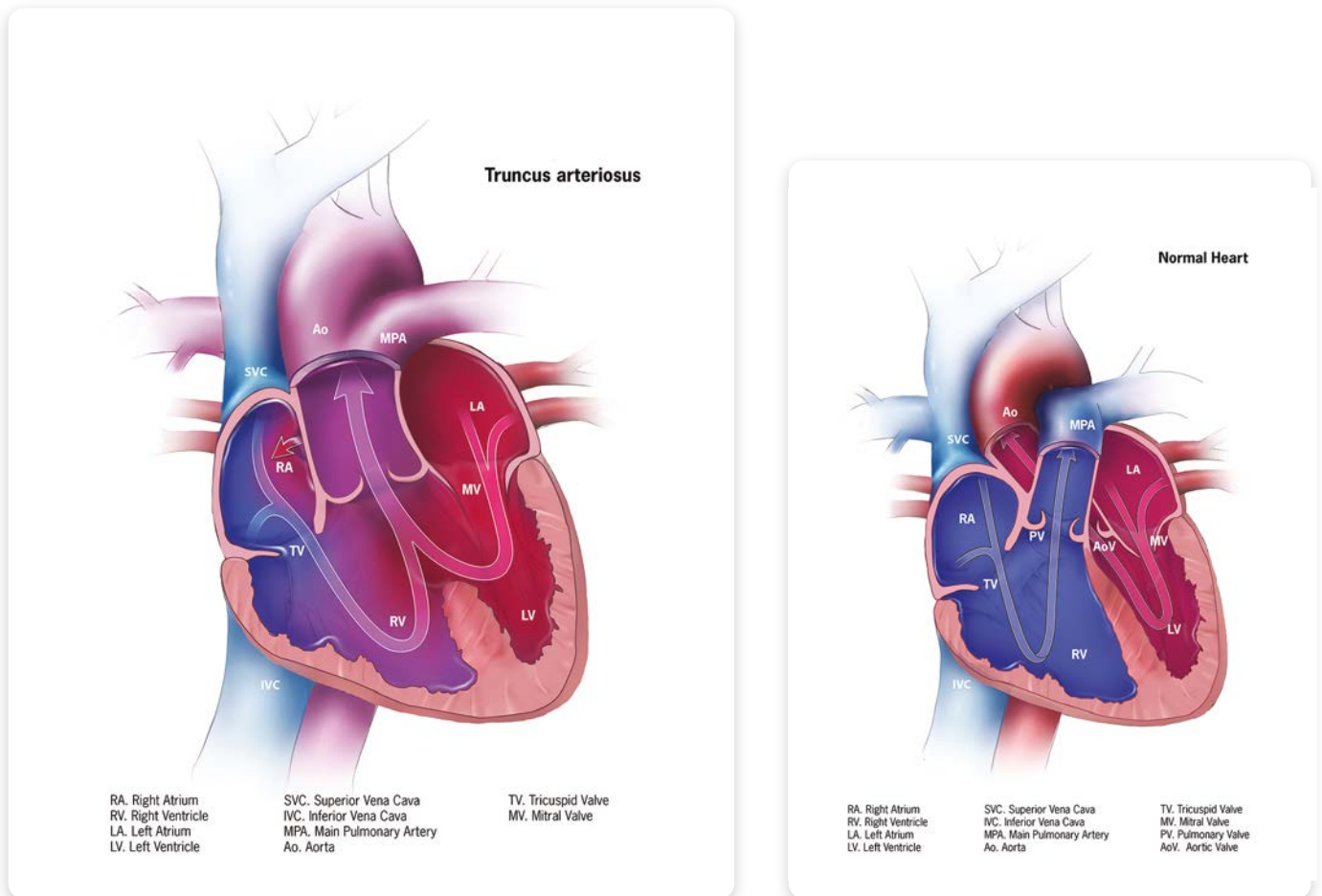
Some clinical clues can help:

- ▶ Often the baby appears fairly normal at birth, but gets worse in the next 24–72 hours, as the ductus arteriosus (a fetal structure that helps blood move between aorta and pulmonary artery) closes. An open ductus can help compensate some of the abnormal physiology in CCHD, and when it closes, the baby might decompensate quickly. This timing unfortunately means that in some cases an undiagnosed baby with a CCHD is discharged home, and may get very sick at home, without ready access to hospital care.
- ▶ In many types of CCHD, the blood oxygen saturation is low. When it is low enough, cyanosis appears. A pulse oximeter, a simple non-invasive instrument available in many nurseries, can measure oxygen saturation quickly and identify low levels even before cyanosis appears. A low oxygen saturation is seen in other conditions such as lung disease, but typically in CCHD, giving oxygen to the baby does not significantly improve the saturation (whereas it will in many cases of lung disease). Pulse oximetry is used in many places to perform newborn screening for CCHD; a specific protocol has to be used for best results.
- ▶ Auscultation is helpful. Many types of CCHD produce murmurs, but a murmur can be absent in some very severe CHDs, so the absence of a murmur does not exclude that the child has a CCHD.
- ▶ Palpation of peripheral pulses – including in the groin and feet – can provide clues to a diagnosis of coarctation of the aorta, in which pulses in the arms are palpable but those in the groin or feet (pedal pulses) are not.
- ▶ In general, the first diagnostic tool is clinician suspicion. Consider the possibility of critical CHDs in every sick newborn. All four pulses may be weak or absent in conditions where cardiac output is low, as can occur, for example, with hypoplastic left heart syndrome.

Babies suspected of having a clinically significant CHD in the newborn period require urgent follow-up with a clinician familiar with CHDs, ideally a paediatric cardiologist aided by appropriate imaging, typically an echocardiogram. In expert hands, an echocardiogram can quickly exclude a major CHD or provide a firm specific diagnosis. Such a diagnosis is extremely helpful for planning the care of the baby.

Common truncus or common arterial trunk is a structural heart defect characterized anatomically by having a single common arterial trunk, rather than a separate aorta and main pulmonary artery (see Fig. 14). This common trunk carries blood from the heart to the body, lungs, and the heart itself – that is, the common trunk gives rise to the systemic, pulmonary and coronary circulation. A ventricular septal defect is always present. Other terms for the condition are (persistent) truncus arteriosus.

Fig. 14. Common truncus





Key findings in common truncus:

1. Common truncus instead of separate aorta and main pulmonary artery.
2. Ventricular septal defect, typically “high”.
3. Common truncal valve.
4. Variable origin of the pulmonary arteries from the common trunk.
5. Frequently associated extracardiac anomalies and genetic syndromes, especially deletion 22q11.

Diagnosis

Prenatal. Common truncus can be diagnosed prenatally but might be missed or misdiagnosed, and therefore must be confirmed postnatally, typically by echocardiography.

Postnatal. The presentation after birth varies and might include a combination of heart failure (fast breathing, fast heart rate, poor feeding, and excessive sweating) and cyanosis.

Newborn screening via pulse oximetry – by non-invasively measuring blood oxygen saturation – can detect cases of common truncus if a sufficient degree of hypoxia is present at the time of screening. Echocardiography provides the specific diagnosis.

Clinical and epidemiologic notes

Clinical tips:

- ▶ The clinical presentation in the newborn period might include a combination of cyanosis and heart failure.
- ▶ Pulse oximetry can identify low blood oxygen saturation and can identify cases earlier.
- ▶ Look for extracardiac anomalies (e.g. cleft palate, internal anomalies) and genetic conditions, especially deletion 22q11.
- ▶ This condition can be familial, so consider inquiring about congenital heart disease in family members.

Checklist for high-quality reporting

Common Truncus – Documentation Checklist

❑ Describe in detail the clinical and echocardiographic findings:

- ▶ Anatomy – specify intracardiac anomalies, including the presence and type of ventricular septal defects, the origins of the pulmonary arteries and the morphology of the truncal valve.
- ▶ Procedure – specify whether the cardiac findings are from a prenatal or postnatal echocardiogram, or from other investigations (e.g. catheterization, MRI), surgery, or autopsy.
- ▶ Additional cardiac findings – specify any additional findings in addition to the basic anatomy of truncus (see above).

❑ Look for and document extracardiac birth defects: Common truncus can occur with genetic syndromes such as deletion 22q11, in which many external (e.g. cleft palate) as well as internal anomalies have been described.

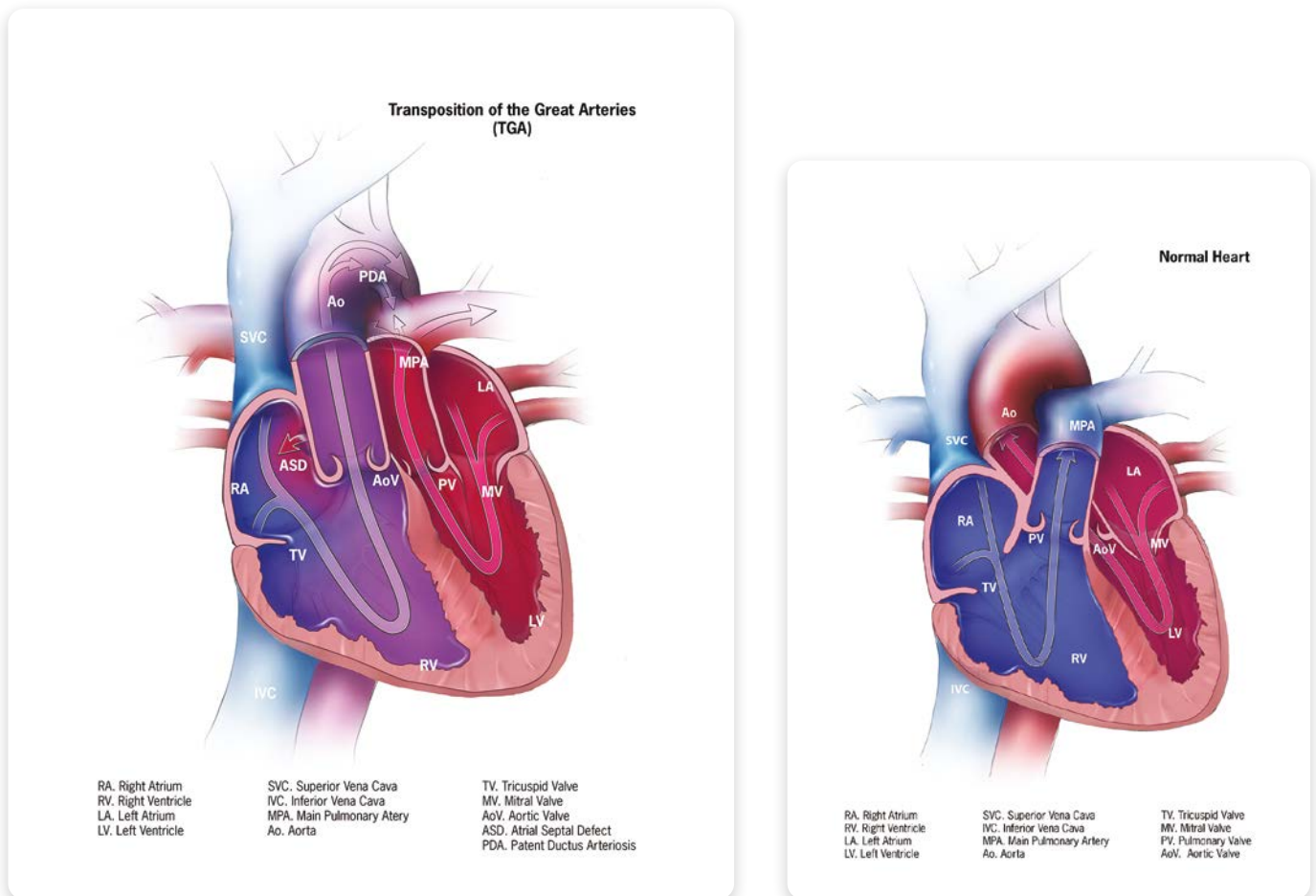
❑ Report whether specialty consultation(s) have been done; in particular, whether the diagnosis was done by a paediatric cardiologist, and whether the patient was seen by a geneticist.

❑ Report genetic testing (e.g. chromosomal studies, genomic microarray, etc.) if done, and if so, report the results.

TRANSPOSITION OF GREAT ARTERIES (Q20.3)

d(dextro)-transposition of the great arteries (d-TGA) is a structural heart anomaly characterized clinically by cyanosis (usually) and anatomically by an abnormal origin of the great arteries, such that the aorta exits from the right ventricle (instead of the left) and the pulmonary artery exits from the left ventricle (instead of the right) (see Fig. 15).

Fig. 15. Transposition of great arteries





Key findings in transposition of great arteries:

1. Aorta exits from the right ventricle (instead of the left) and the pulmonary artery exits from the left ventricle (instead of the right).
2. Ventricular septal defect might or might not be present, and if present, should be documented and reported.
3. Terms to look for and to document (to help the coder and central reviewer distinguish d-TGA from other forms of transposition) include double outlet right ventricle, levo (l)-transposition of the great arteries, heterotaxy and single ventricle.
4. Echocardiography is the evaluation that in most cases provides all the information required for a precise diagnosis.

Diagnosis

Prenatal. d-TGA can be suspected prenatally, but prenatally diagnosed or suspected cases should be confirmed postnatally.

Postnatal. Infants with d-TGA present in a variety of ways, most commonly with cyanosis that worsens as the ductus closes, or occasionally also with heart failure (usually when a large ventricular septal defect is present).

Newborn screening via pulse oximetry, which is based on the non-invasive detection of low blood oxygen saturation, can detect many cases of d-TGA even before overt clinical symptoms.

Clinical and epidemiologic notes

As noted, infants present typically early after birth with cyanosis, which does not improve much or at all by providing oxygen (the problem is not in the lungs but in the abnormal circulation of blood due to the transposed arteries). As noted, rapid clinical deterioration is expected as the ductus arteriosus closes. d-TGA is most commonly an isolated heart anomaly, but extracardiac anomalies are found in ~10% of cases.

Checklist for high-quality reporting

d-TGA – Documentation Checklist

☐ Describe in detail the clinical and echocardiographic findings:

- ▶ Anatomy – specify intracardiac anomalies, including the presence and type of valvar involvement, of ventricular septal defects, and whether there is evidence of double outlet right ventricle, single ventricle (double inlet left ventricle), or heterotaxy (the latter would make the case not part of simple d-TGA).
- ▶ Procedure – specify whether the cardiac findings are from a prenatal or postnatal echocardiogram, or from other investigations (e.g. catheterization, MRI), surgery, or autopsy.
- ▶ Additional cardiac findings – specify any additional findings, including atrial septal defect, atrial isomerism, etc.

☐ Look for and document extracardiac birth defects: These are not as common as in other conotruncal defects, but can occur.

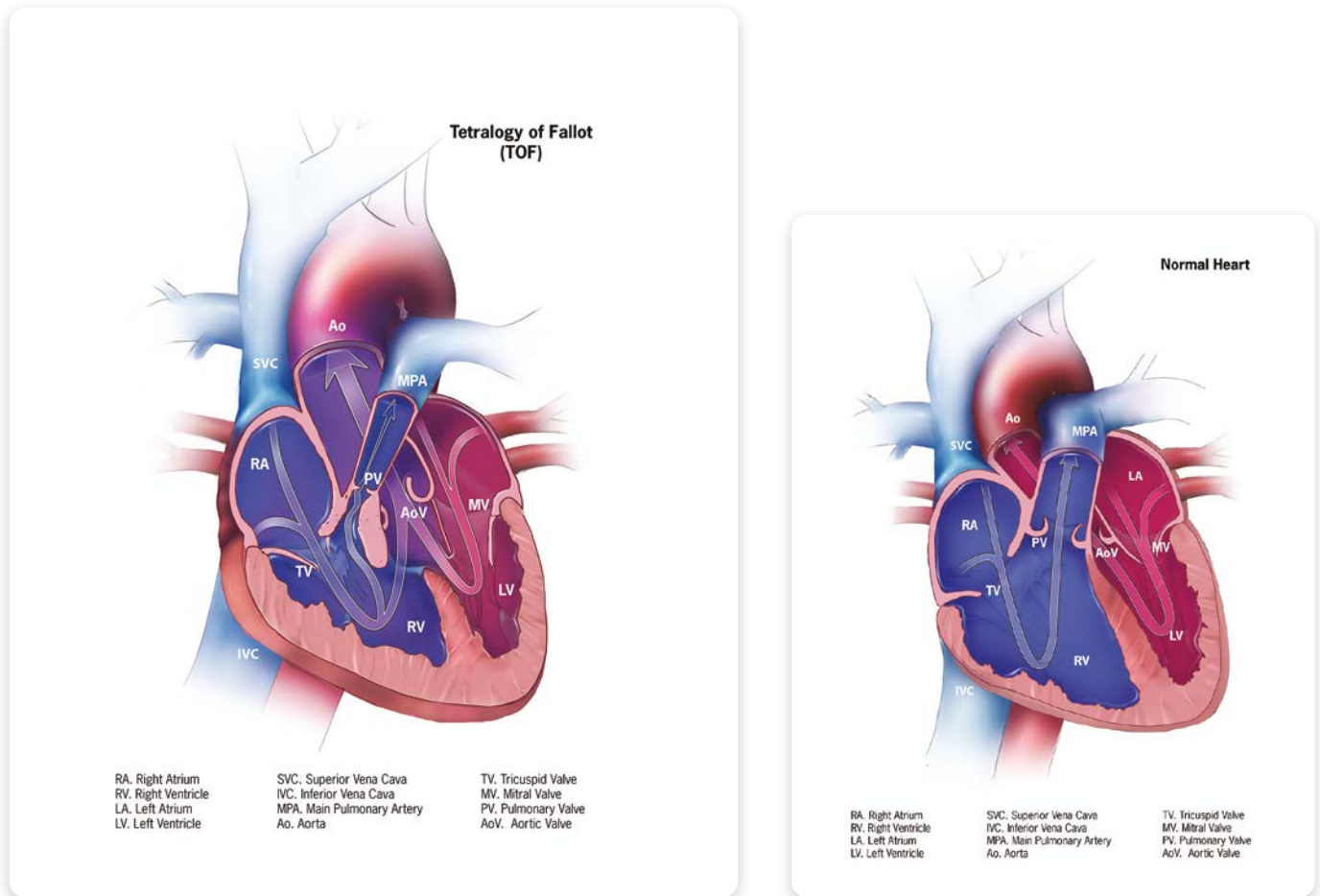
☐ Report whether specialty consultation(s) were done; for instance, whether the diagnosis was made by a paediatric cardiologist, and whether the patient was seen by a geneticist.

☐ Report any genetic testing and results (e.g. chromosomal studies, genomic microarray, etc.).

TETRALOGY OF FALLOT (Q21.3)

Tetralogy of Fallot is a structural heart anomaly characterized clinically by cyanosis, and anatomically by an obstructed right ventricular outflow tract associated with a ventricular septal defect (see Fig. 16); compare left panel with normal anatomy on the right).

Fig. 16. Tetralogy of Fallot





Key findings in tetralogy of Fallot:

1. Stenosis at or below the pulmonary valve, or pulmonary valve atresia (absent pulmonary valve can occur but is rare).
2. Ventricular septal defect.
3. Aorta overriding (sitting above the) ventricular septal defect.

Clinically, the classic presentation is a newborn who becomes progressively cyanotic (blue tinge most evident in the lips, nose and extremities), either constantly or intermittently, and continues to decompensate. Providing oxygen does not help, as it is not a lung problem. Non-invasive newborn screening via pulse oxymetry, though not perfect, is a helpful screening tool to detect cases that could be missed at birth by clinical examination alone. These babies require a quick diagnosis and treatment (first medical, then surgical).

Diagnosis is mainly by echocardiogram. Cases should be confirmed by a cardiologist with expertise on congenital heart disease.

Diagnosis

Prenatal. While tetralogy of Fallot can be suspected prenatally, it can be easily missed or misdiagnosed; therefore, postnatal confirmation is imperative.

Postnatal. A chest radiograph and a careful clinical examination might suggest the diagnosis; however, a definitive diagnosis is done by echocardiography. Other imaging techniques might be used but are more complex and costly (e.g. catheterization, MRI) and are used in specific, more complex cases to help with management. Newborn screening via pulse oxymetry, a non-invasive approach, can detect some cases with low blood oxygenation that might escape clinical detection.

Clinical and epidemiologic notes

Tetralogy of Fallot is in fact a spectrum of diseases and might be clinically severe or mild, depending on the degree of obstruction in the right ventricular outflow tract.

- ▶ **In milder cases, cyanosis might be mild or absent**, and might escape detection at birth.
- ▶ **Pulse oximetry**, available in many nurseries, is a helpful initial tool to screen for low blood oxygenation, though not specifically for tetralogy of Fallot as there are many causes of low oxygen saturation in the newborn, including sepsis, lung disease and a variety of CHDs.

In cases of tetralogy of Fallot, always look for other birth defects and signs of genetic syndromes:

- ▶ A common genetic condition with tetralogy of Fallot (seen in about 15–20 % of cases) is deletion 22q11, a condition in which a small part of chromosome 22 is missing. This deletion leads to some CHDs and many types of birth defects, both visible externally (e.g. cleft palate, spina bifida) and internally (e.g. renal anomalies and many others) (~15–20%).
- ▶ Maternal pregestational diabetes is a modifiable risk factor for tetralogy of Fallot and other conotruncal conditions (e.g. truncus arteriosus).

Checklist for high-quality reporting

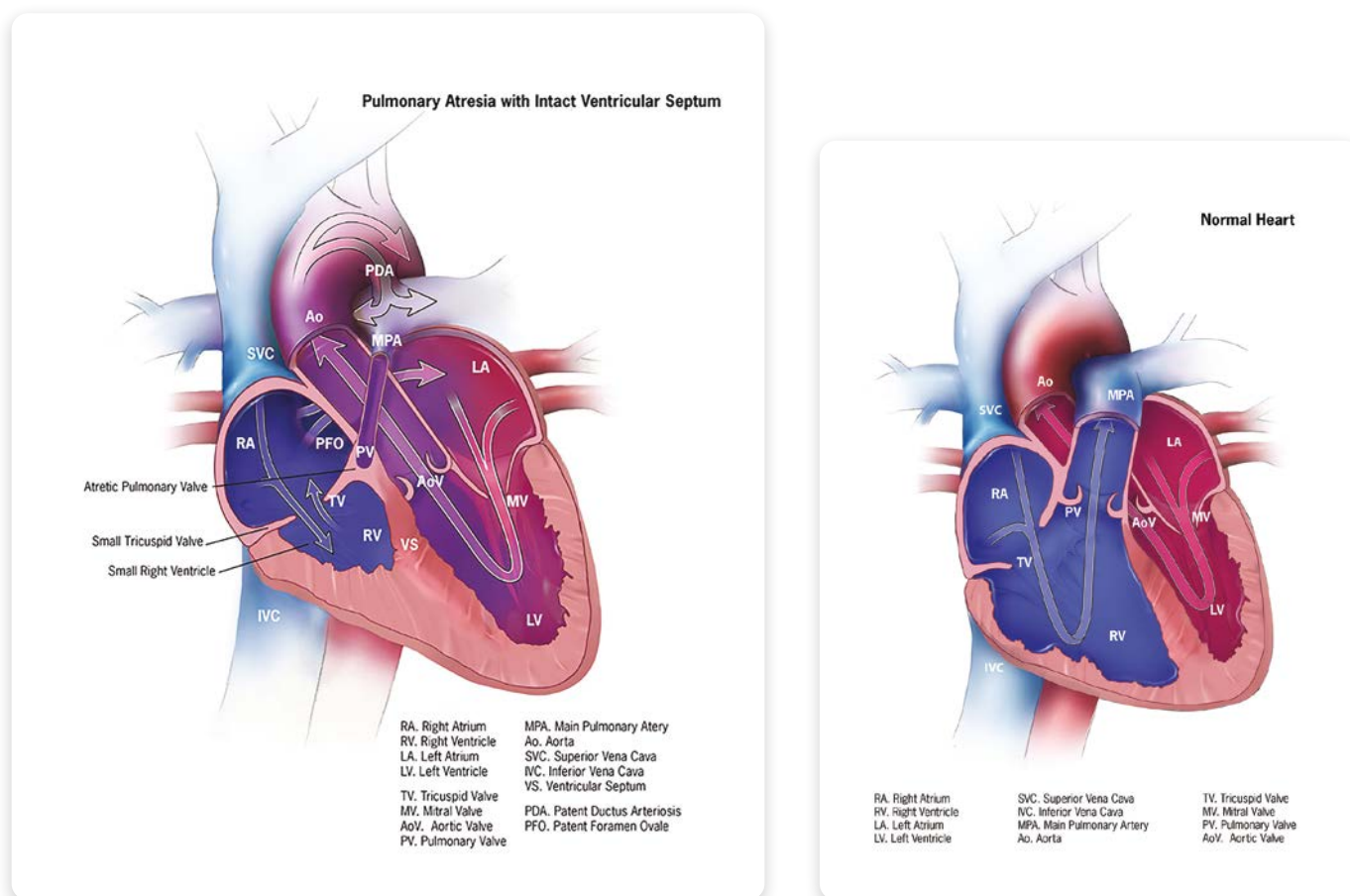
Tetralogy of Fallot – Documentation Checklist

- Describe in detail the clinical and echocardiographic findings:**
 - ▶ Anatomy – specify the type of right ventricular outflow tract obstruction (severity of stenosis, or presence of atresia) and the presence and type of ventricular septal defect (e.g. “subaortic”, “perimembranous”).
 - ▶ Procedure – specify whether the cardiac findings are from a prenatal or postnatal echocardiogram, or from other investigations (e.g. catheterization, MRI), surgery, or autopsy.
 - ▶ Additional cardiac findings – specify any additional findings, including atrial septal defect, pulmonary collaterals, etc.
- Look for and document extracardiac birth defects:** In deletion 22q11, the heart anomaly can be associated with several internal and external anomalies, including cleft palate, spina bifida, vertebral anomalies, or other defects.
- Report whether specialty consultation(s) were done**, such as whether the diagnosis was made by a paediatric cardiologist, and whether the patient was seen by a geneticist.
- Report any genetic testing and results** (e.g. chromosomal studies, genomic microarray, etc.).

PULMONARY VALVE ATRESIA (Q22.0)

Pulmonary valve atresia is a structural heart anomaly characterized clinically by cyanosis and anatomically by an imperforate pulmonary valve that blocks completely the flow of blood through the right ventricular outflow tract. The atresia can take the form of a membrane – because the valve failed to form – or of an imperforate muscle structure (see Fig. 17).

Fig. 17. Pulmonary valve atresia





Key findings in pulmonary valve atresia:

1. An imperforate pulmonary valve.
2. A ventricular septum that is intact or can present a ventricular septal defect: This is a very important detail to look for and describe – the panel above in Fig. 17 shows the form of pulmonary atresia with an intact ventricular septum.
3. An underdeveloped right ventricle and possibly a small or narrowed tricuspid valve, especially if the ventricular septum is intact.

Diagnosis

Prenatal. Pulmonary valve atresia can be suspected prenatally based on ultrasonography but must be confirmed postnatally.

Postnatal. Infants with pulmonary atresia (with or without ventricular septal defect) typically present early in the neonatal period with low oxygen saturation and cyanosis, which worsens over time as the ductus closes. Some infants might also have massive cardiomegaly. Because pulmonary atresia causes low blood oxygen saturation, newborn screening with pulse oximetry can help with early detection of these cases. Echocardiography is the key diagnostic procedure, although other imaging techniques, including catheterization, might be necessary to fully guide management and care.

Clinical and epidemiologic notes

Pulmonary atresia with intact ventricular septum is often isolated but can be associated with unrelated anomalies and syndromes as well as with other intracardiac anomalies, especially those that involve the right side of the heart.

Pulmonary atresia with ventricular septal defect can be associated with deletion 22q11, unlike the form with intact ventricular septum. Because of this association, look for other birth defects, including cleft palate and internal anomalies.

Checklist for high-quality reporting

Pulmonary Atresia – Documentation Checklist

Describe in detail the clinical and echocardiographic findings:

- ▶ Specify intracardiac anatomy, including the presence of valve atresia, the involvement of the tricuspid valve, and whether the right ventricle is underdeveloped.
- ▶ Specify whether the ventricular septum is intact or whether a ventricular septal defect is present (if so, note whether a specific type of ventricular septal defect is described in the notes).
- ▶ Specify whether the cardiac findings are from a prenatal or postnatal echocardiogram, or from other investigations (e.g. catheterization, MRI), surgery, or autopsy.
- ▶ Document any additional cardiovascular finding, including atrial septal defect, pulmonary collaterals, etc.

Look for and document extracardiac birth defects: In deletion 22q11, the heart anomaly can be associated with several internal and external anomalies, including cleft palate, spina bifida, vertebral anomalies, or other defects.

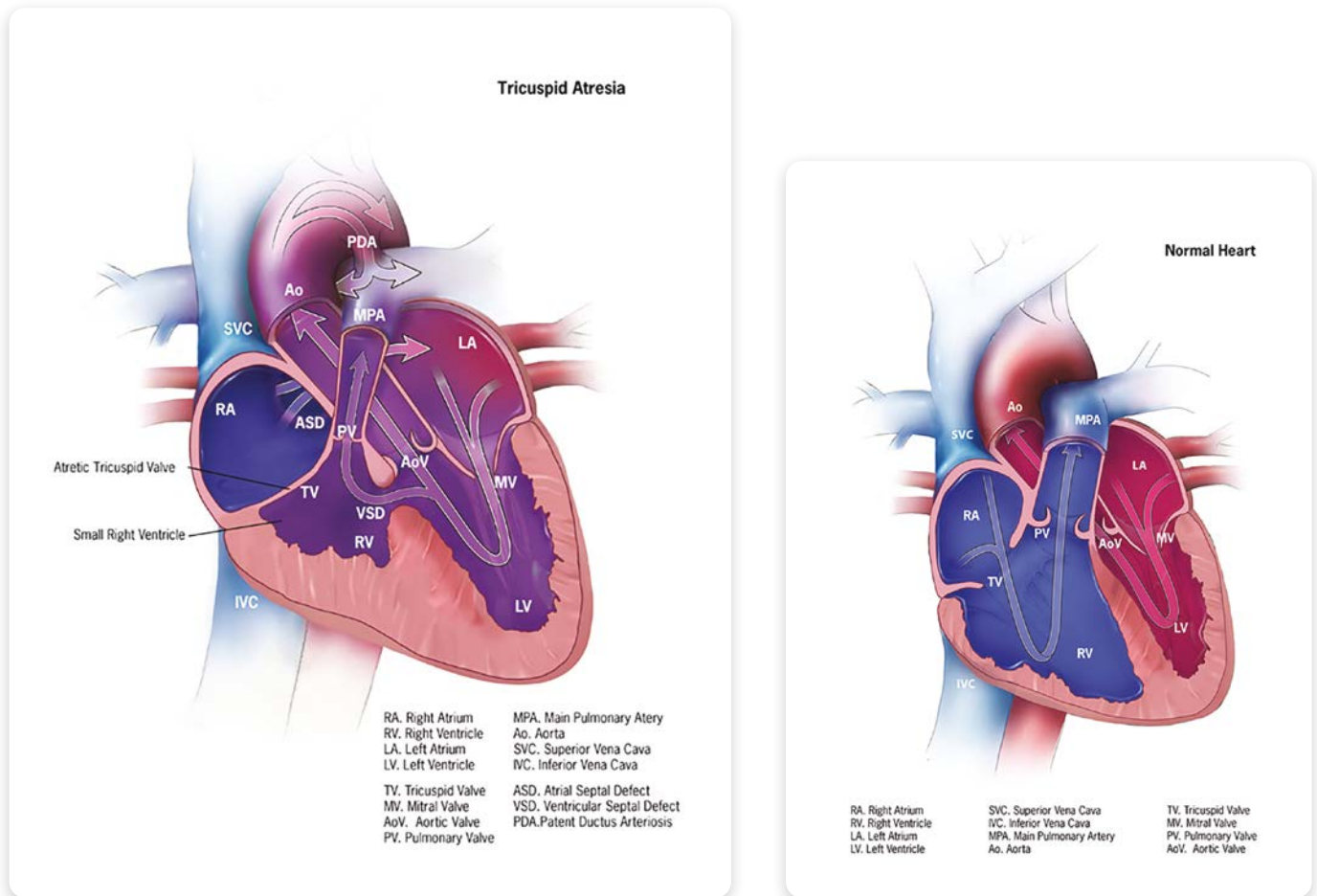
Report whether specialty consultation(s) were done, such as whether the diagnosis was made by a paediatric cardiologist, and whether the patient was seen by a geneticist.

Report any genetic testing and results (e.g. chromosomal studies, genomic microarray).

TRICUSPID VALVE ATRESIA (Q22.4)

Tricuspid valve atresia is a structural heart defect characterized anatomically by a complete agenesis (failure of formation) of the tricuspid valve, leading to absence of a direct communication and blood flow from the right atrium to the right ventricle. Having an atrial septal defect is crucial for survival (see Fig. 18, left panel), but blood mixing causes significant cyanosis.

Fig. 18. Tricuspid valve atresia





Key findings in tricuspid valve atresia:

1. Atretic tricuspid valve.
2. Presence or absence of ventricular septal defect, important to note.
3. Frequent occurrence of pulmonary valve stenosis/atresia, especially if ventricular septum is intact.
4. Frequent occurrence in the context of complex heart anomalies (e.g. heterotaxy, single ventricle).
5. Associated at times with extracardiac anomalies and genetic syndromes, especially deletion 22q11.

Diagnosis

Prenatal. Tricuspid valve atresia can be readily suspected prenatally but can be misdiagnosed and should be confirmed postnatally.

Postnatal. The common clinical presentation in the newborn is cyanosis. Echocardiography has largely superseded other imaging techniques, although these have a role (e.g. catheterization to assess right ventricular pressures and resistance). Newborn screening via pulse oximetry – which is based on the detection of low blood oxygen saturation – is expected to detect most cases of tricuspid atresia.

Clinical and epidemiologic notes

Infants can deteriorate quickly, especially if the atrial septal defect is small or when the ductus closes.

Clinical tips:

- ▶ The common clinical presentation in the newborn is cyanosis.
- ▶ Pulse oximetry can identify low blood oxygen saturation and can identify cases earlier.
- ▶ Look for extracardiac anomalies (e.g. cleft palate, internal anomalies) and genetic conditions, especially deletion 22q11.
- ▶ Note additional cardiac findings – tricuspid atresia can also occur in the context of complex cardiovascular anomalies; for example, with heterotaxy and single ventricle (double inlet left ventricle).
- ▶ Look for extracardiac anomalies – tricuspid atresia can be associated with deletion 22q11 (5–10%), common trisomies, and other rarer conditions.

Checklist for high-quality reporting

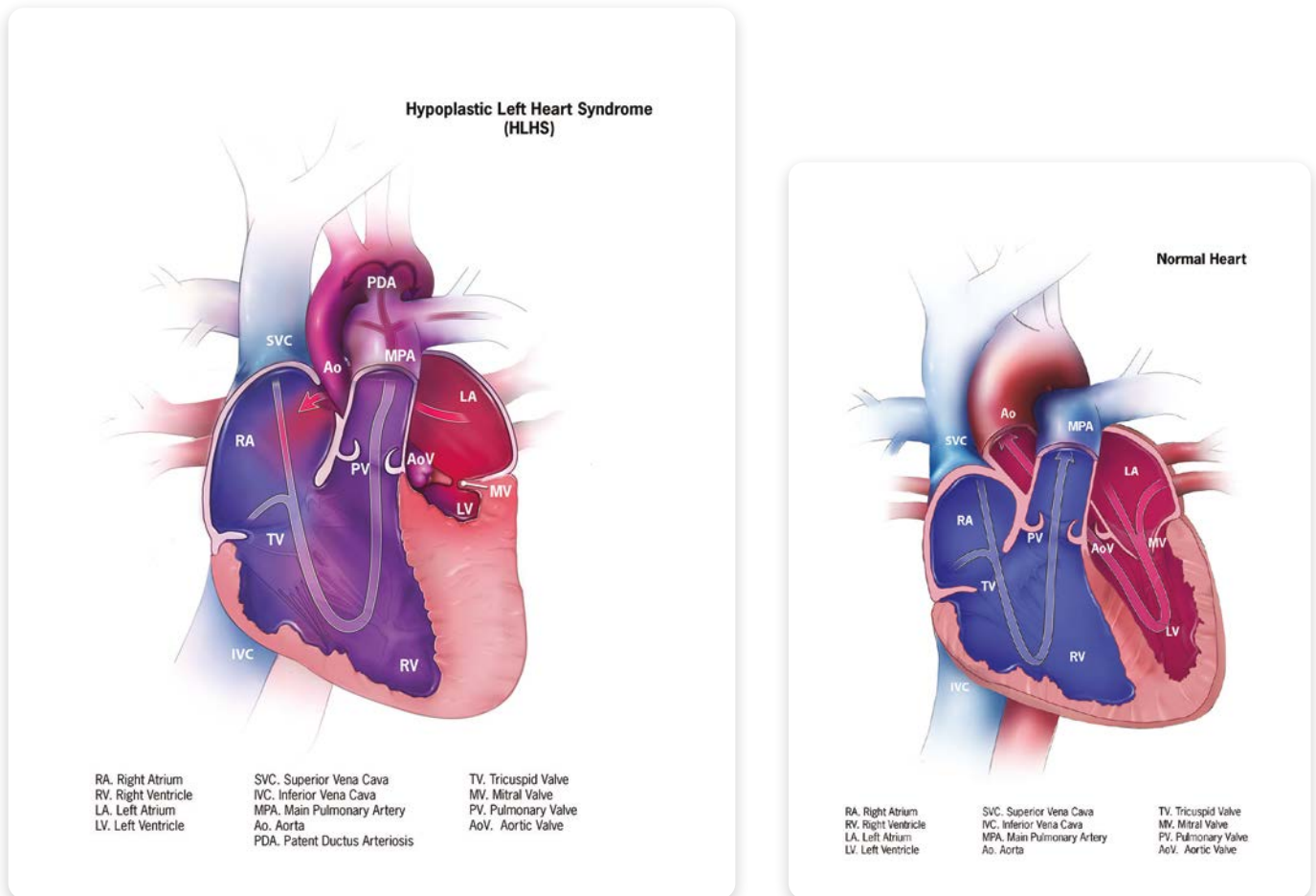
Tricuspid Atresia – Documentation Checklist

- Describe in detail the clinical and echocardiographic findings:**
 - ▶ Anatomy – specify intracardiac anomalies, including the presence of ventricular septal defects, abnormally small right ventricle, pulmonary valve stenosis or atresia, transposition or malposition of the great arteries.
 - ▶ Procedure – specify whether the cardiac findings are from a prenatal or postnatal echocardiogram, or from other investigations (e.g. catheterization, MRI), surgery, or autopsy.
- Look for and document extracardiac birth defects and genetic conditions**, such as deletion 22q11.
- Report whether specialty consultation(s) was done**, such as whether the diagnosis was made by a paediatric cardiologist, and whether the patient was seen by a geneticist.
- Report any genetic testing and results** (e.g. chromosomal studies, genomic microarray, etc.).

HYPOPLASTIC LEFT HEART SYNDROME (Q23.4)

Hypoplastic left heart syndrome (HLHS) is structural heart anomaly characterized clinically by varying degrees of **heart failure** (cardiogenic shock) in the newborn and anatomically by an **underdeveloped left side of the heart, especially the left ventricle and aorta** (see Fig. 19).

Fig. 19. Hypoplastic left heart syndrome





Key findings in HLHS:

1. A small left ventricle.
2. A small, narrowed or atretic mitral valve and/or aortic valve.
3. Underdeveloped ascending aorta, sometimes with hypoplastic aortic arch and descending aorta.
4. Clinically, the heart is unable to sustain the systemic circulation, especially after the ductus closes, resulting in heart failure and cardiogenic shock.

Diagnosis

Prenatal. HLHS can be suspected and, in expert hands, diagnosed prenatally. Prenatal diagnoses should be confirmed postnatally; for example, by echocardiography.

Postnatal. In HLHS, the norm is early-onset heart failure (cardiogenic shock). The timing of heart failure varies. Some cases, especially in the presence of a widely open ductus arteriosus, might be missed in the early newborn period and can become clinically obvious only after the ductus closes, which can happen after discharge from the nursery.

As with other severe heart disease, newborn screening via pulse oximetry – which is based on the non-invasive detection of low peripheral oxygen saturation – can detect many cases before they become clinically obvious. Other cases can be suspected because of absence of pulses. The final, specific diagnosis is readily made by echocardiography.

Clinical and epidemiologic notes

HLHS can occur in association with genetic conditions, though in >75% of cases it seems to be an isolated condition. Family members may have subtle variants of left-sided heart defects, which may require echocardiograms for diagnosis.

Some common HLHS genetic syndromes associated with HLHS include Turner syndrome, Noonan syndrome and the common trisomies.

Notes:

Left-sided obstructive defects such as aortic stenosis/atresia and mitral stenosis/atresia may occur together but do not necessarily qualify as a diagnosis of HLHS. **The latter diagnosis should be made by an expert clinician such as a paediatric cardiologist.**

Checklist for high-quality reporting

Hypoplastic Left Heart Syndrome (HLHS) – Documentation Checklist

Describe in detail the clinical and echocardiographic findings:

- ▶ Anatomy – specify the elements of HLHS present in the child; for example, mitral stenosis or atresia, hypoplastic left ventricle, stenosis or atresia of the aortic valve, hypoplastic aorta, interrupted aortic arch, endocardial fibroelastosis, etc.
- ▶ Procedure – specify whether the cardiac findings are from a prenatal or postnatal echocardiogram, or from other investigations (e.g. catheterization, MRI), surgery, or autopsy.
- ▶ Additional cardiac findings – specify any additional findings, including atrial septal defect, patent ductus arteriosus, etc.

Look for and document extracardiac birth defects, major or minor (minor anomalies can suggest Turner syndrome).

Report whether specialty consultation(s) was done, such as whether the diagnosis was made by a paediatric cardiologist, and whether the patient was seen by a geneticist.

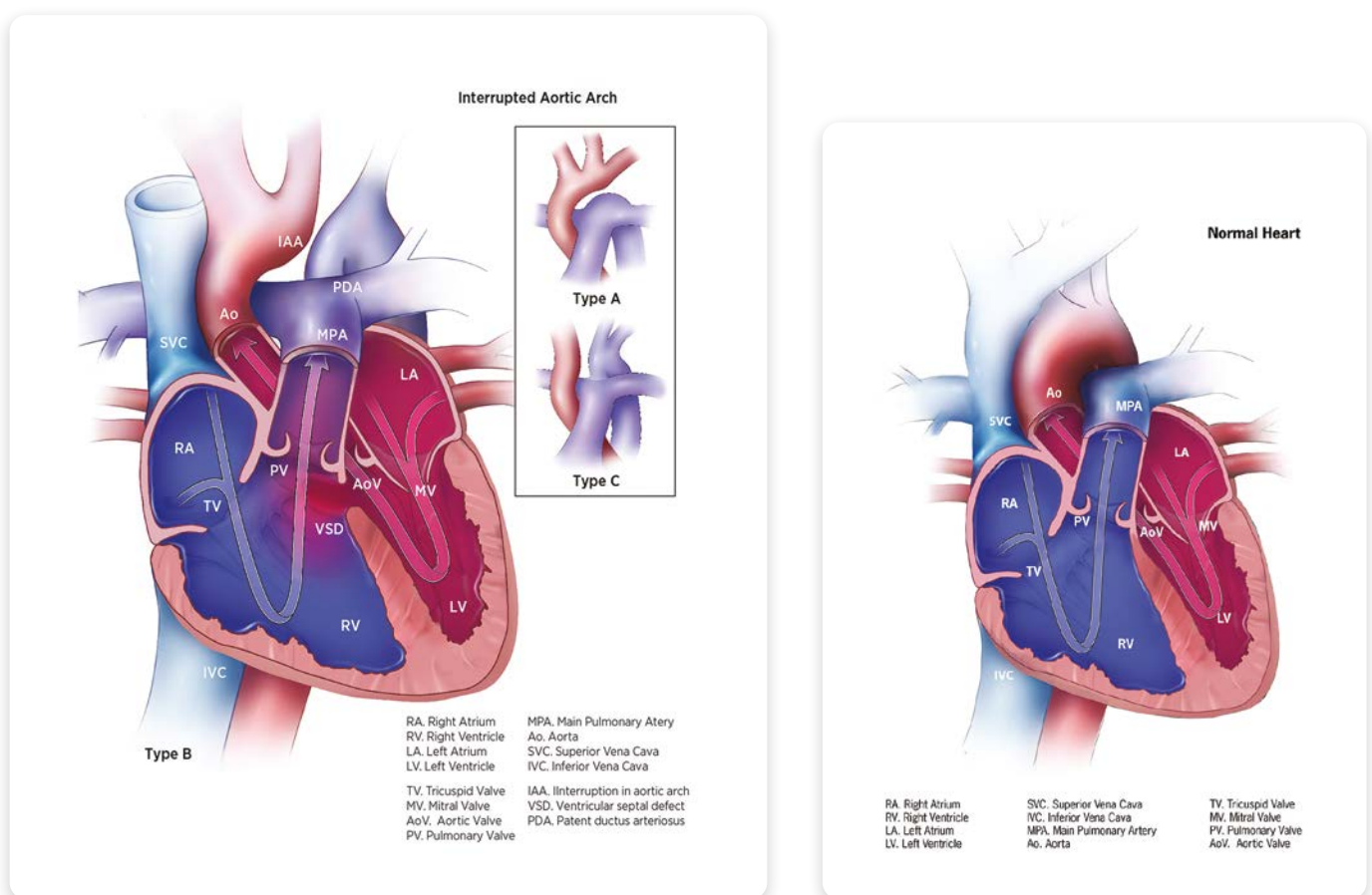
Report any genetic testing and results (e.g. chromosomal studies, genomic microarray, etc.).

INTERRUPTED AORTIC ARCH (Q25.21, PREFERRED; ALSO Q25.2, Q25.4)

Interrupted aortic arch (IAA) is a structural heart defect characterized anatomically by a discontinuity (interruption) along the aortic arch. Depending on the site of discontinuity, IAA is classified into three types (see Fig. 20), of which type B is the most frequent (50–70%). Type A is less common (30–45%) and type C is rare.

- ▶ Type A: The discontinuity is distal to the left subclavian artery (approximately in the same region as coarctation of the aorta).
- ▶ **Type B, the most common form: The discontinuity is more proximal, between the left carotid and subclavian.**
- ▶ Type C: The discontinuity is more proximal still, between the brachiocephalic artery and the common carotid artery.

Fig. 20. Interrupted aortic arch





Diagnosis

Prenatal. IAA is easily missed on the obstetric anomaly scan, though it might be suspected based on discrepancy between the left and right ventricular sizes. Whereas in expert hands fetal echocardiography can provide a firm diagnosis, prenatally diagnosed cases should be confirmed postnatally.

Postnatal. Infants can present clinically in the early neonatal period, when the ductus closes, with signs and symptoms of congestive heart failure and systemic hypoperfusion (cardiogenic shock). Newborn screening via pulse oximetry can lead to earlier diagnosis.

Clinical and epidemiologic notes

As noted, early presentation is one of heart failure and cardiogenic shock, with rapid clinical deterioration as the ductus closes. Because of right-to-left shunting at the ductus arteriosus, infants may initially show differential oxygen saturation or cyanosis. In type A, the difference in saturation is between upper and lower limbs (the latter being lower); in type B, it is between the left and right arm (lower saturation in the left).

Ventricular septal defect and other intracardiac defects are often present.

The three types of IAA differ in their association with genetic risk factors. For example, deletion 22q11 occurs in 50% or more of cases of type B IAA, and is rare in the other types. Other syndromes that can occur with IAA include CHARGE syndrome (Q30.01).

Checklist for high-quality reporting

Interrupted Aortic Arch (IAA) – Documentation Checklist

- Describe in detail the clinical and echocardiographic findings:**
 - ▶ Anatomy – specify site of discontinuity, type of IAA as noted in echocardiographic report, and intracardiac anomalies, including the presence of ventricular septal defects.
 - ▶ Procedure – specify whether the cardiac findings are from a prenatal or postnatal echocardiogram, or from other investigations (e.g. catheterization, MRI), surgery, or autopsy.
- Look for and document extracardiac birth defects:** IAA can occur with genetic syndromes such as deletion 22q11, which is associated with many external and internal anomalies.
- Report whether specialty consultation(s) was done** (e.g. a paediatric cardiologist or geneticist).
- Report any genetic testing and results** (e.g. chromosomal studies, genomic microarray, etc.).

OROFACIAL CLEFTS

CLEFT PALATE (Q35, Q35.1, Q35.3, Q35.5, Q35.59, Q87.0)

Cleft palate (also called palatoschisis) is characterized by a fissure (clefing) in the secondary palate (posterior to the incisive foramen) and can involve the soft palate only (the most posterior part of the palate), or both the hard palate and the soft palate. The cleft can be narrow (V-shaped), or wider (U-shaped) (see Fig. 21). The lip is intact.

Fig. 21. Cleft palate

Cleft palate, including hard and soft palate (Q35.5)

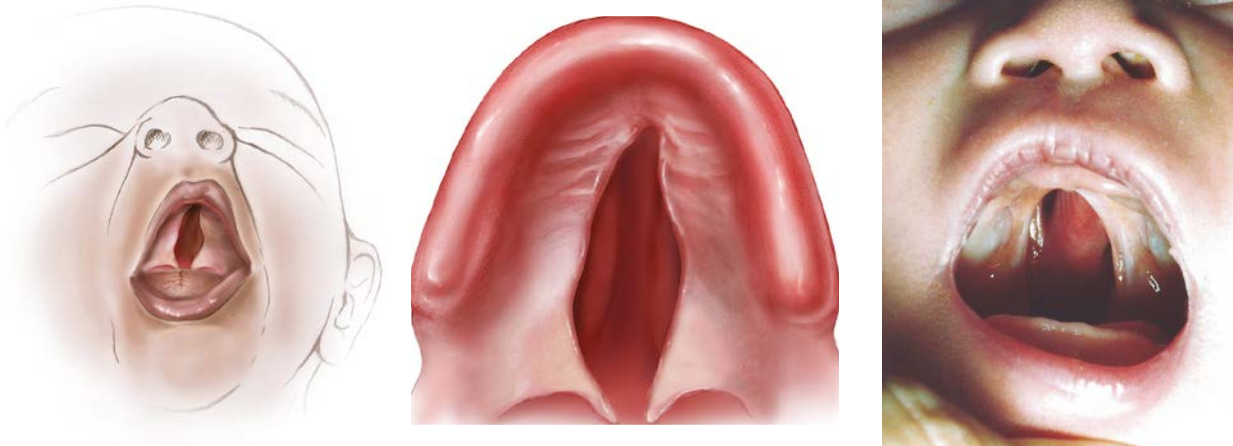

Fig. 22. Anatomy of the lip and palate

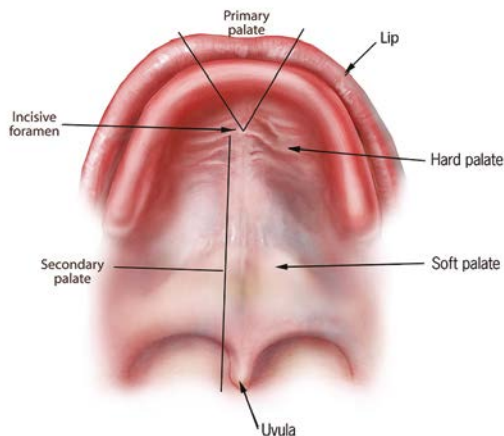
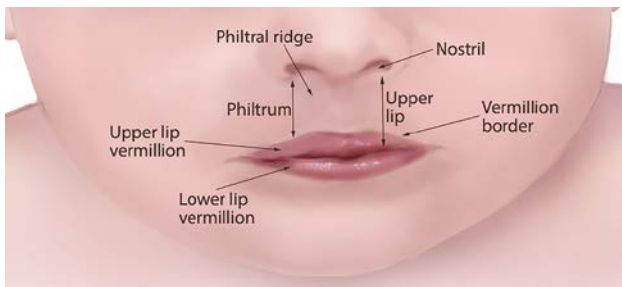
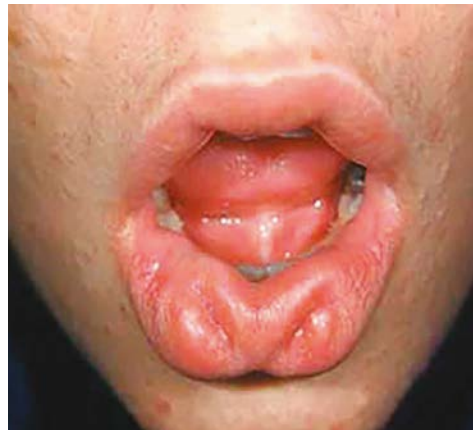

Fig. 23. Lip pits



Photograph source: <https://elementsofmorphology.nih.gov/index.cgi?tid=54f2dee42a1f9ef7>.

Photograph source: CDC–Beijing Medical University collaborative project.



Diagnosis

Prenatal. Cleft palate alone can be suspected prenatally but can easily be missed or misdiagnosed. Cases identified or suspected prenatally should be confirmed postnatally before inclusion in a surveillance programme.

Postnatal. Cleft palate can be missed at the external newborn examination if the palate is not systematically and carefully examined. This requires visualization of the entire length of the palate.

Clinical and epidemiologic notes

In cleft palate, a complete evaluation and physical examination is crucial as it is more commonly associated with additional anomalies and syndromes compared to other types of clefts (e.g. cleft lip).

Additional clinical tips:

- ▶ Check for lip pits in the lower lip (see Fig. 23), in the child **and** in the parents – it is a sign of a genetic condition (van der Woude syndrome) with high recurrence risk (a parent may have the pits but not the cleft).
- ▶ Check for additional anomalies, especially of the heart (e.g. in deletion 22q11 syndrome) and eye (e.g. Stickler syndrome).
- ▶ Check for components of the Pierre Robin sequence, including microretrognathia (small recessed jaw), glossoptosis (posterior displacement of the tongue) and respiratory obstruction.

Checklist for high-quality reporting

Cleft Palate – Documentation Checklist

- Describe in detail**, including:
 - ▶ Extension (cleft palate) – hard palate, soft palate.
 - ▶ Lower lip (see Fig. 23) – pits present or absent (when present, the van der Woude syndrome should be strongly suspected).
 - ▶ Presence of components of the Pierre Robin sequence – microretrognathia (small recessed jaw), glossoptosis (posterior displacement of the tongue) and respiratory obstruction.
- Describe procedures to assess further additional malformations and if present, describe.**
- Take and report photographs:** Very useful; can be crucial for review.
- Report whether specialty consultation(s) were done and if so, report the results.** Plastic surgery and genetics consultation reports are useful.

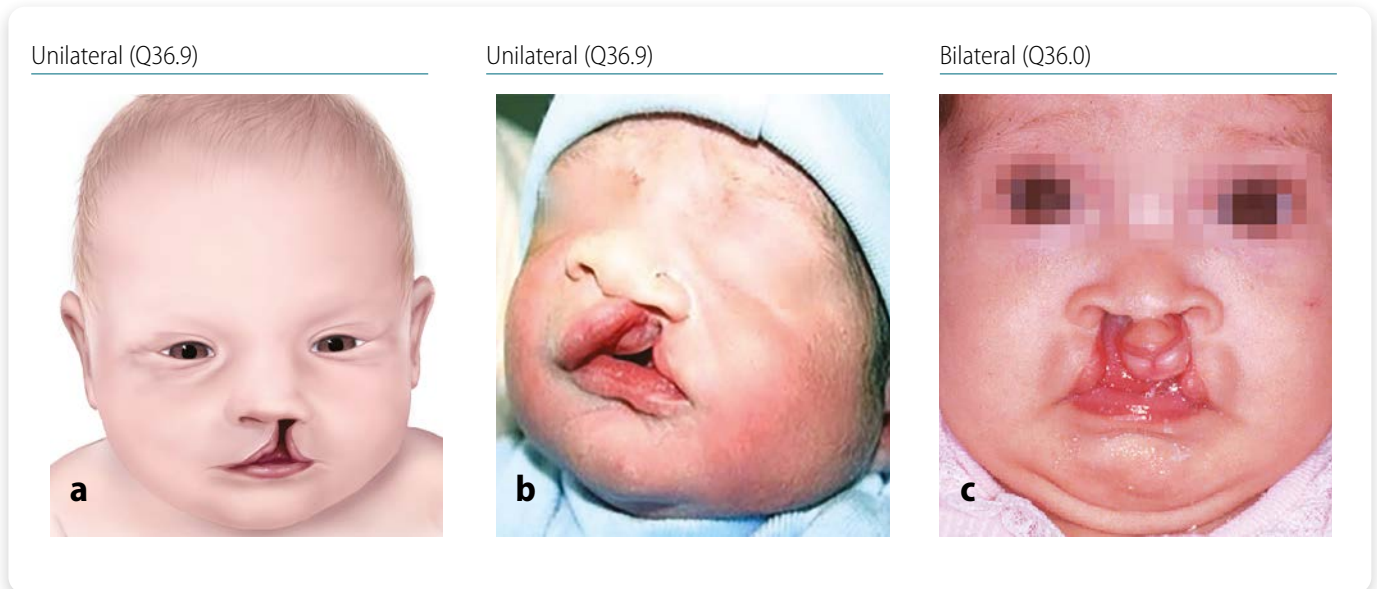
Key visuals:

Anatomy of the lip and palate. Note that in bilateral cleft lip, a median remnant of the philtrum is still present. Note also that the clefting can extend to the gum or alveolus but does not extend beyond the incisive foramen (thus involving only the primary palate) (see Fig. 22).

Lip pits. Lip “pits” are indentations, often with raised borders, on the lower lip (see Fig. 23). They are a sign of specific syndromes (most commonly van der Woude syndrome).

Cleft lip is characterized by a **partial or complete fissure of the upper lip**. It can be unilateral (see Fig. 24, *panels a and b*) or bilateral (see Fig. 24, *panel c*). The cleft lip **can extend through the gum, but not beyond the incisive foramen**. If the cleft extends further backwards into the secondary palate it becomes a different entity – a cleft lip with cleft palate.

Fig. 24. Cleft lip



Photograph source: b: Dr Jaime Frías (EE. UU.); c: Dr Pedro Santiago and Dr Miguel Yanez (EE. UU).

Fig. 25. Anatomy of the lip and palate

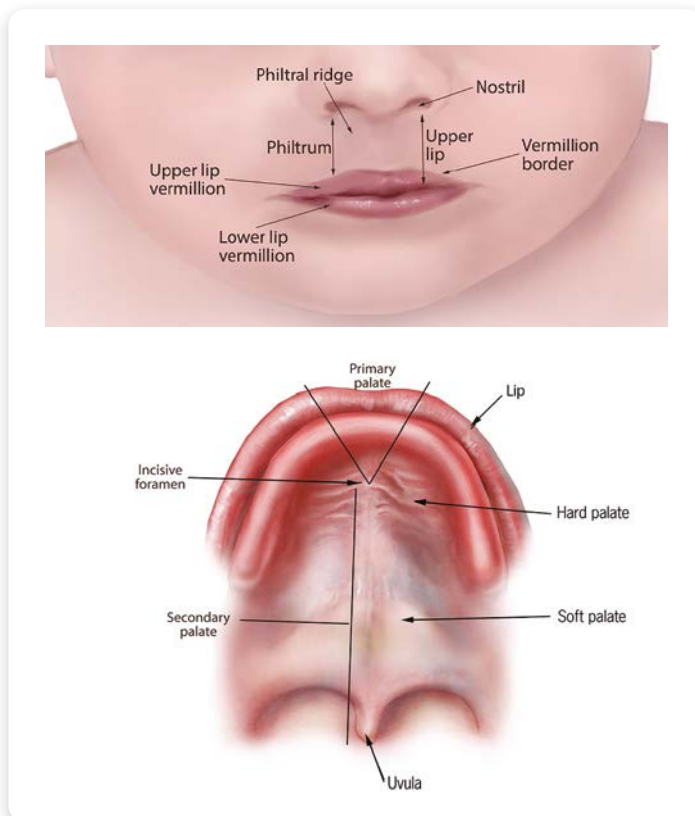
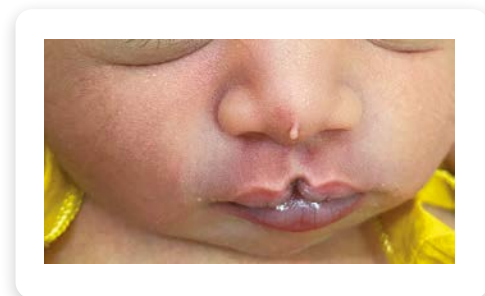

Fig. 26. Median cleft lip



Photograph source: Prof Tahmina Banu, Chittagong Research Institute for Children Surgery, Bangladesh.



Diagnosis

Prenatal. Cleft lip can be suspected prenatally but can easily be missed or misdiagnosed. Cases identified or suspected prenatally should be confirmed postnatally before inclusion in a surveillance programme.

Postnatal. Cleft lip is easily recognized on physical examination after delivery. Check the palate carefully to rule out cleft lip with cleft palate.

Clinical and epidemiologic notes

Rarer conditions that can be confused with typical cleft lip are median cleft lip and atypical or Tessier type clefts.

- ▶ Median cleft lip can be distinguished from bilateral cleft lip by examination of the philtrum. In median cleft lip, there is no remnant of tissue (philtrum) in the area below the nasal septum. In bilateral cleft lip a midline remnant of tissue is always present (see Fig. 24, *panel c*; also, see below for more information on median cleft lip).
- ▶ Atypical or Tessier type craniofacial clefts are a group of clefting defects that involve the cranial and/or facial skeleton. Unlike cleft lip, where the cleft extends up towards the nose, the 14 various Tessier's clefts extend through radiating axes of facial and cranial bones, including towards the eye or nasolacrimal canal, or even more laterally towards the ear.
- ▶ Cleft lip is occasionally associated with other birth defects or syndromes.

Additional clinical tips:

- ▶ Always check the palate to exclude cleft palate with cleft lip; this is important both for surveillance and for clinical care.
- ▶ Check for lip pits in the lower lip (see Fig. 23), in the child **and** in the parents – it is a sign of a genetic condition (van der Woude syndrome) with high recurrence risk (a parent may have the pits but not the cleft).

Checklist for high-quality reporting

Cleft Lip – Documentation Checklist

- Describe in detail**, including:
 - ▶ Laterality – right, left, or bilateral.
 - ▶ Lower lip (see Fig. 23) – pits present or absent (when present, van der Woude syndrome should be suspected).
 - ▶ Extension of the cleft lip – minimum, partial, or total involvement of the gum extending at most through the alveolus to the incisive foramen (not beyond).
- Describe procedures to assess further additional malformations, and if present describe.**
- Take and report photographs:** Very useful; can be crucial for review.
- Report whether specialty consultation(s) were done, and if so, report the results.**

Key visuals:

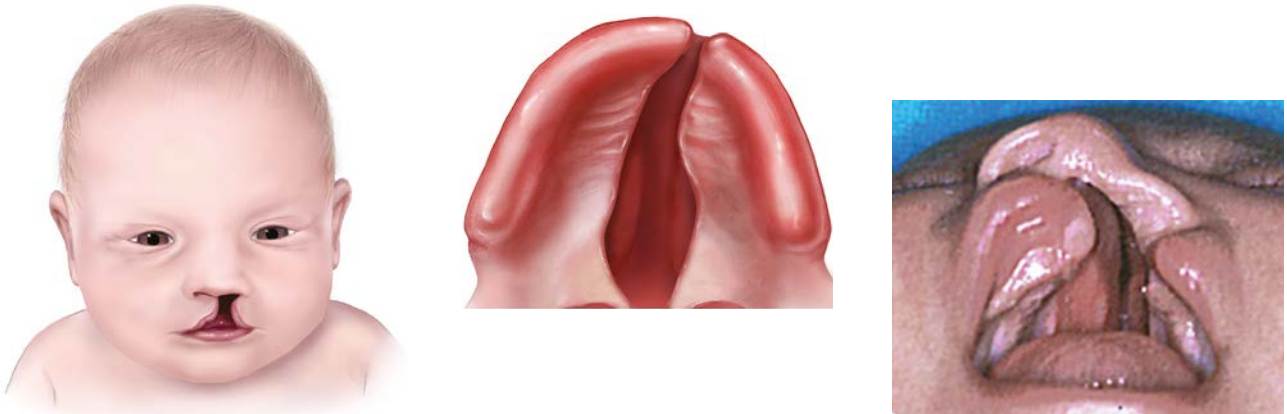
Anatomy of the lip and palate. Note that in bilateral cleft lip, a median remnant of the philtrum is still present. Note also that the clefting can extend to the gum or alveolus but does not extend beyond the incisive foramen (thus involving only the primary palate) (see Fig. 25).

Median cleft lip. In median cleft lip, there is no remnant of tissue (philtrum) in the area below the nasal septum (see Fig. 26). Median cleft lip is part of a condition called absent premaxilla and is often an external finding in holoprosencephaly, a severe brain malformation. Absent premaxilla and holoprosencephaly are associated with genetic syndromes, including trisomy 13.

Cleft palate with cleft lip is characterized as a cleft of the upper lip extending through the hard palate (primary and secondary palate), and might also extend through the soft palate (see Fig. 27).

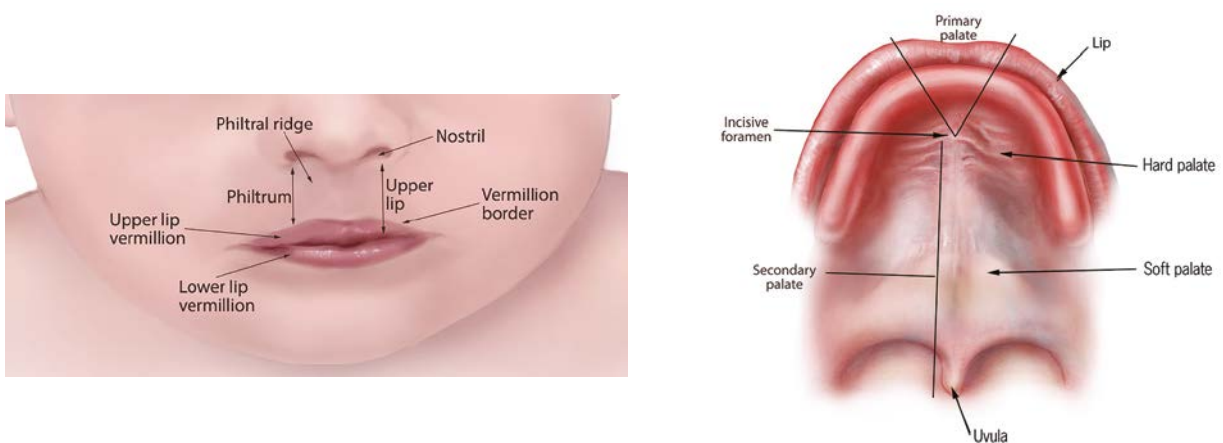
Fig. 27. Cleft palate with cleft lip

Cleft palate with unilateral cleft lip (Q37.10)



Photograph source: Dr Pedro Santiago and Dr Miguel Yáñez (EE. UU.).

Fig. 28. Anatomy of the lip and palate





Diagnosis

Prenatal. It can be suspected prenatally but can easily be missed or misdiagnosed. Cases identified or suspected prenatally should be confirmed postnatally before inclusion in a surveillance programme.

Postnatal. Cleft lip with cleft palate is easily recognized on physical examination after delivery, provided the palate is also checked carefully.

Clinical and epidemiologic notes

Rarer conditions that can be confused with typical cleft lip are the atypical or Tessier type clefts and the amniotic band spectrum.

- ▶ Atypical or Tessier type craniofacial clefts are a group of clefting defects that involve the cranial and/or facial skeleton. The 14 various Tessier's clefts extend through radiating axes of facial and cranial bones, including towards the eye or nasolacrimal canal, or even more laterally towards the ear. Amniotic band spectrum can cause facial disruptions that involve both the lip and palate, and often include atypical skull and brain lesions (e.g. atypical encephaloceles).

Cleft lip with cleft palate can be associated with other birth defects or syndromes, more commonly so than cleft lip alone.

Additional clinical tips:

- ▶ Always check the palate when you see a cleft lip – the diagnosis is important both for surveillance and for clinical care.
- ▶ Check for lip pits in the lower lip (see Fig. 23), in the child **and** in the parents – it is a sign of a genetic condition (van der Woude syndrome) with high recurrence risk (a parent may have the pits but not the cleft).
- ▶ When in doubt that what you see is a typical cleft, take a photograph or a very careful drawing – such documentation helps the clinical reviewer reach a correct diagnosis.

Checklist for high-quality reporting

Cleft Lip with Cleft Palate – Documentation Checklist

- Describe in detail**, including:
 - ▶ Laterality – right, left, or bilateral.
 - ▶ Extension (cleft palate) – hard palate, soft palate.
 - ▶ Lower lip (see Fig. 23) – pits present or absent (when present, van der Woude syndrome should be strongly suspected).
- Describe procedures to assess further additional malformations, and if present describe.**
- Take and report photographs:** Very useful; can be crucial for review.
- Report whether specialty consultation(s) were done, and if so, report the results.** Plastic surgery consultation reports are often useful.

Key visuals:

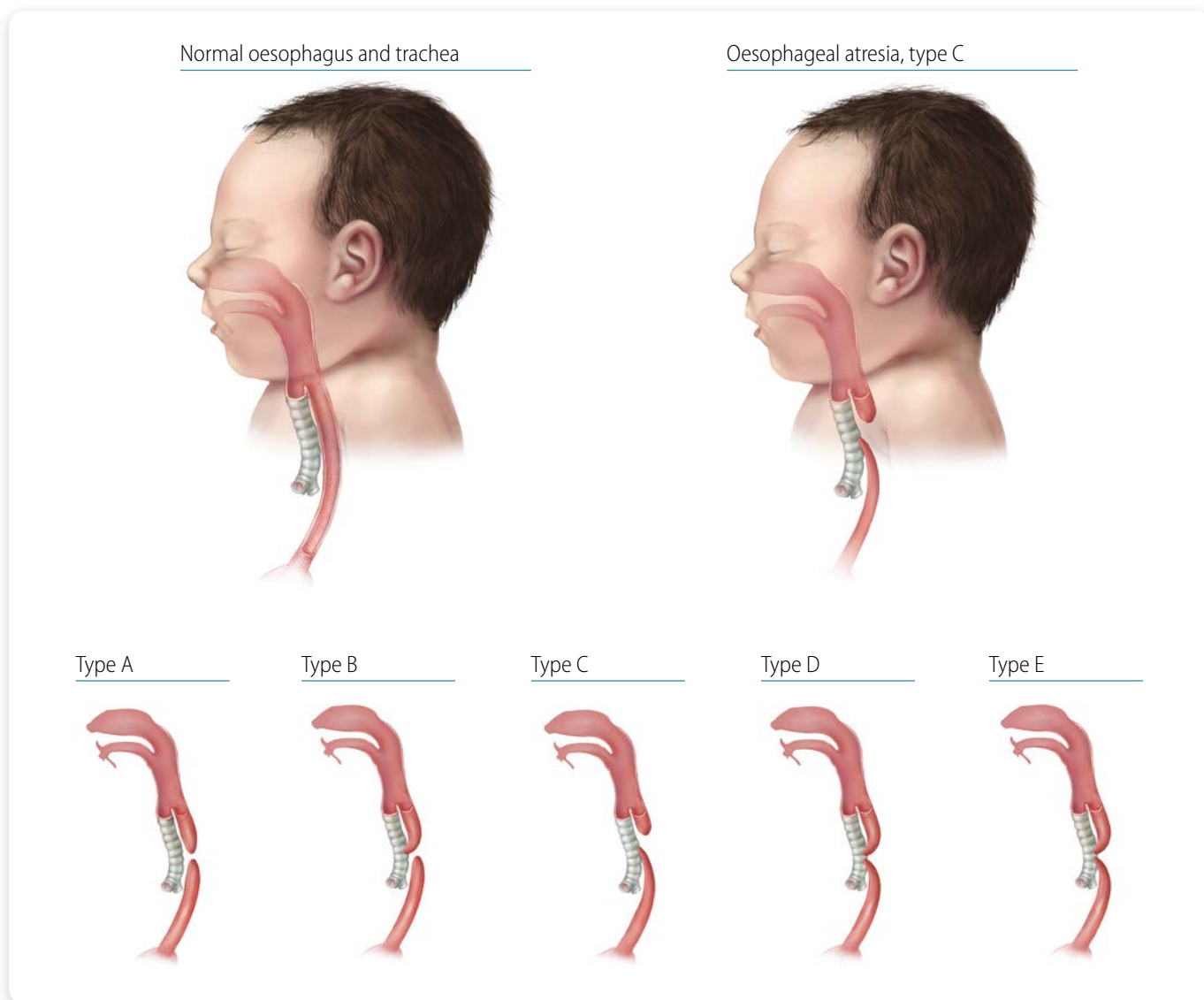
Anatomy of the lip and palate. Note that in bilateral cleft lip, a median remnant of the philtrum is still present (see Fig. 28). Note also that the clefting can extend to the gum or alveolus but does not extend beyond the incisive foramen (thus involving only the primary palate).

CONGENITAL ANOMALIES OF THE DIGESTIVE SYSTEM

OESOPHAGEAL ATRESIA/TRACHEO-OESOPHAGEAL FISTULA (Q39.0–Q39.2)

Oesophageal (esophageal) atresia is a congenital malformation characterized by the oesophagus ending in a blind pouch that does not connect to the stomach. Tracheo-oesophageal fistula (TEF or TOF) consists of a communication between the oesophagus and the trachea that is not normally present. Although it might occur alone, TEF is commonly associated with oesophageal atresia.

Fig. 29. Oesophageal atresia/tracheo-oesophageal fistula





Key findings in oesophageal atresia (see Fig. 29):

1. The anatomical types of oesophageal atresia are:
 - Type A: Oesophageal atresia **without** TEF.
 - Type B: Oesophageal atresia with **proximal** TEF.
 - **Type C: Oesophageal atresia with distal TEF.**
 - Type D: Oesophageal atresia with proximal and distal TEF.
 - **Type E: TEF without** oesophageal atresia.

Types A–D are typically recognized oesophageal atresia, with type C being by far the most common.

2. Signs of oesophageal atresia at birth include vomiting immediately after feeding, excessive drooling or mucus, and, if TEF is present, respiratory distress.

Diagnosis

Prenatal. Oesophageal atresia is difficult to diagnose prenatally. Always confirm a prenatal diagnosis.

Postnatal. Oesophageal atresia can be diagnosed radiographically when a feeding tube cannot pass from the pharynx into the stomach and, if there is no TEF, by absence of air in the stomach. Because of the variability in symptoms, the diagnosis of TEF without oesophageal atresia may be delayed for weeks, months, or even years.

Clinical and epidemiologic notes

Oesophageal atresia is frequently (55%) associated with additional birth defects that include:

- ▶ Other unrelated birth defects, particularly cardiac, anorectal, skeletal/vertebral and urogenital.
- ▶ Anomaly complexes (e.g. OAVS [**o**culo-**a**uriculo-**v**ertebral **s**pectrum], VATER or VACTERL association [**v**ertebral, **a**nus, **c**ardiac, **t**rachea, **o**esophagus, **r**enal, **l**imb]).
- ▶ Genetic syndromes (e.g. trisomies 18 and 21, CHARGE [**c**oloboma, **h**eart defects, choanal **a**tresia, growth **r**etardation, **g**enital abnormalities, **e**ar abnormalities] syndrome, Feingold syndrome).

Additional clinical tips:

- ▶ Always look for additional internal anomalies and syndromes.
- ▶ Note the type of oesophageal atresia and if TEF occurs.

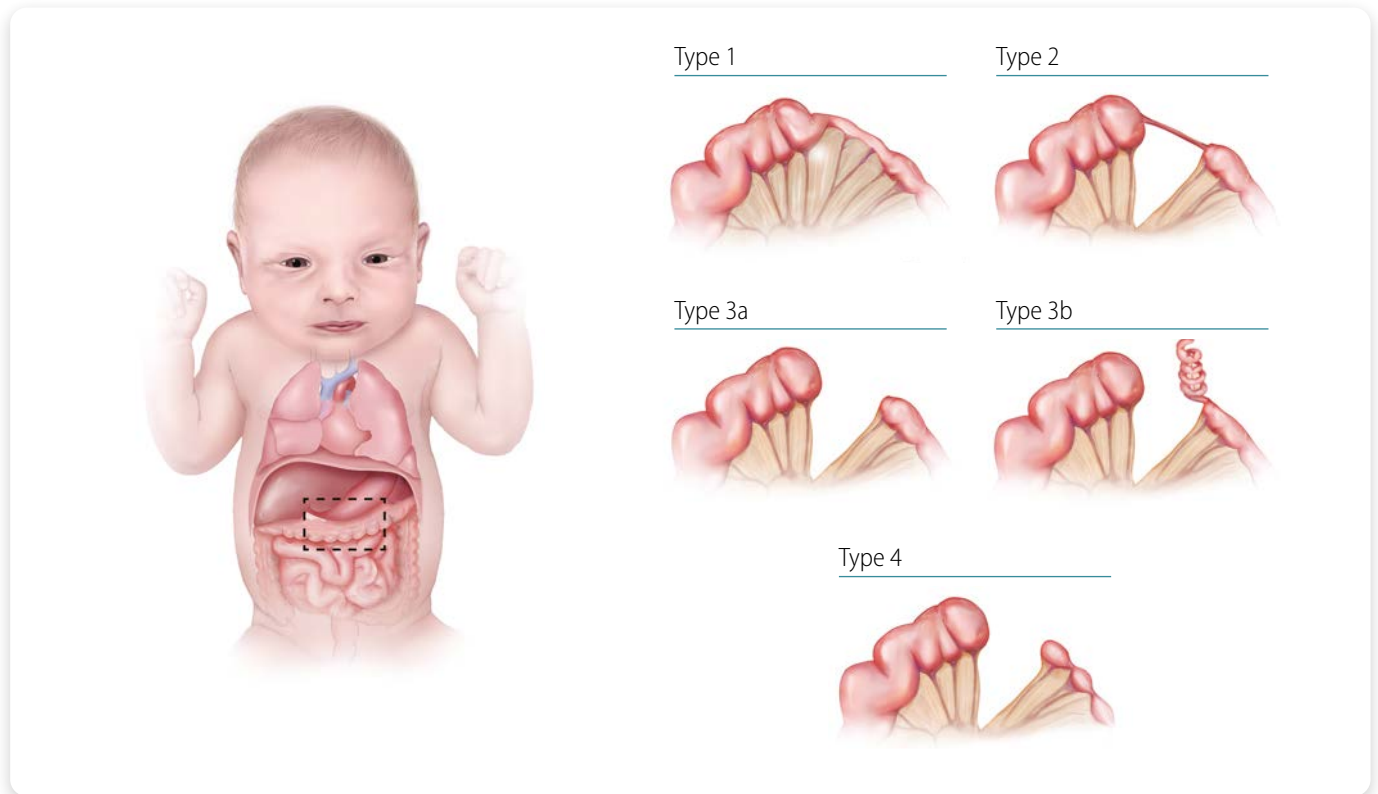
Checklist for high-quality reporting

Oesophageal Atresia with or without TEF – Documentation Checklist

- Describe in detail:**
 - ▶ Defect – anatomical type of oesophageal atresia with or without TEF (describe anatomy and which type A to E).
- Describe evaluations to rule out additional malformations/associations/syndromes:**
 - ▶ Especially OAVS, VATER/VACTERL, trisomies 18 and 21, CHARGE, Feingold, etc.
 - ▶ Genetic or chromosomal testing performed.
 - ▶ Specialty consultations and surgical reports.
- Take and report photographs:** Show clearly oesophageal atresia and, if present, TEF type; can be crucial for review.
- Report whether autopsy (pathology) findings are available and if so, report the results.**

Large intestinal atresia or stenosis – also known as colonic atresia – is the complete or partial obstruction of the opening (lumen) within the colon.

Fig. 30. Main types of large intestinal atresia





Key findings in large intestinal atresia/stenosis:

1. **Type:** Four types of atresia have been recognized (see Fig. 30):
 - In type 1, the lumen is occluded by internal tissue (mucosal web) with intact mesentery.
 - In type 2, the atretic segment is a fibrous cord, and connects the two ends of the large intestine.
 - In type 3a, the atretic segment occurs with a V-shaped mesenteric gap defect (in type 3b, there is an “apple peel” appearance of a portion of the gut).
 - In type 4, the atresia involves two or more regions of the colon, with an appearance described as a string of sausages (approximately one third of all large intestinal atresias are type 4).
2. **Location:** Sigmoid and transverse regions are most commonly affected.

Diagnosis

Prenatal. These conditions are difficult to detect and diagnose prenatally, so any prenatal diagnosis should be confirmed postnatally.

Postnatal. Large intestinal atresia or stenosis should be suspected in the newborn infant who fails to pass meconium or stool, has abdominal distention and/or bilious vomiting. Diagnosis is confirmed through direct imaging of the bowel by x-ray, barium enema, surgery, or autopsy. Partial colonic stenosis may be diagnosed later, even weeks after delivery.

Clinical and epidemiologic notes

Large intestinal atresia is rare, with an estimated birth prevalence of approximately 1 in 20 000 births. This condition represents less than 10% of all intestinal atresias.

Checklist for high-quality reporting

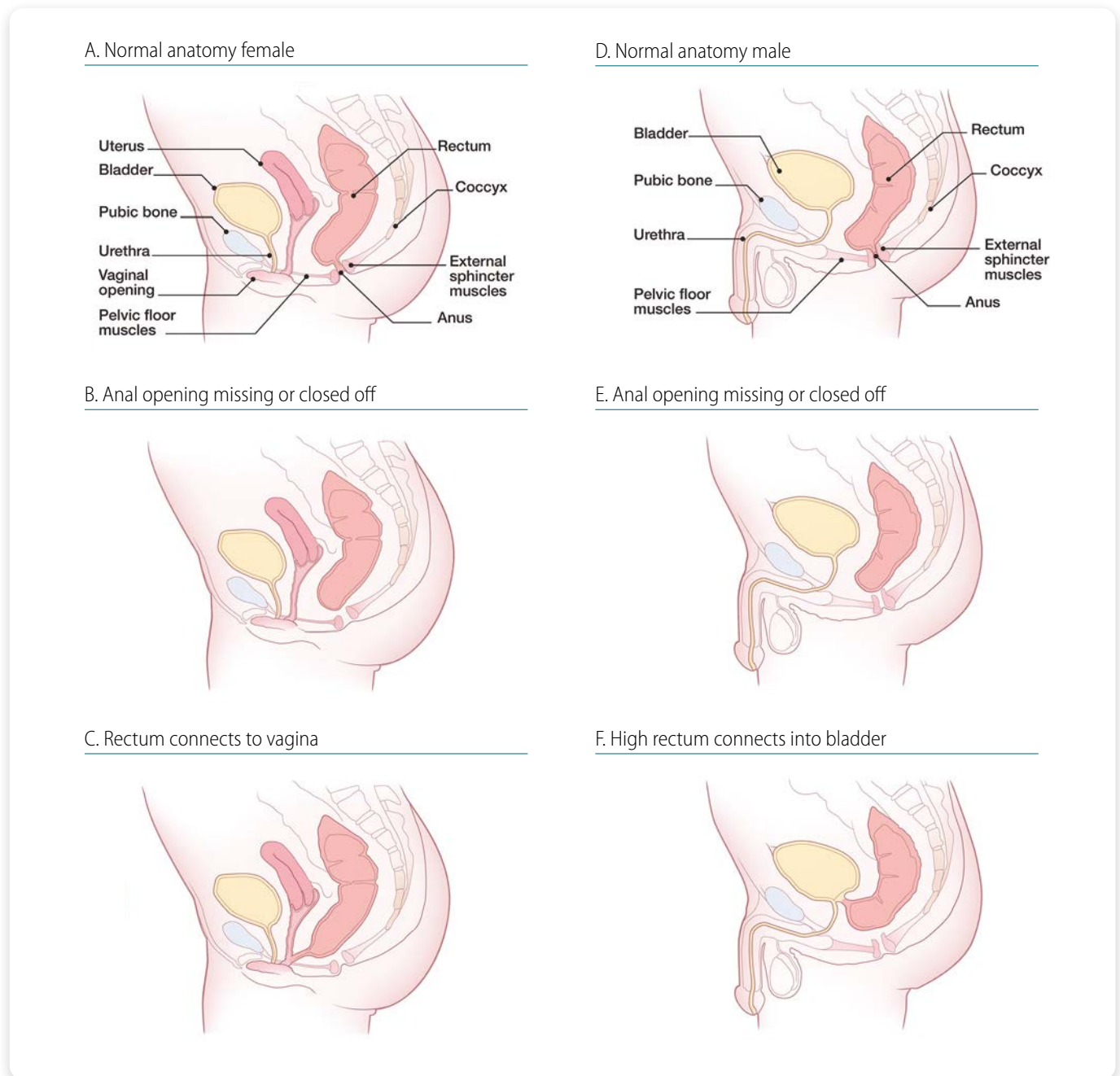
Large Intestinal Atresia/Stenosis – Documentation Checklist

- Describe the anatomy in detail, best using a combination of clinical, imaging, and surgical reports;** specifically include information on the following elements:
 - ▶ Atresia/stenosis location in large intestine.
 - ▶ Single versus multiple atresias.
 - ▶ Vesicoenteric fistula present.
 - ▶ Jejunal atresia – found in 10–20% of cases.
- Describe procedures to assess further additional malformations:**
 - ▶ Most involve the gastrointestinal system (e.g. malrotation, aganglionosis, volvulus).
 - ▶ Craniofacial or ocular anomalies.
- Copy and attach key imaging.**
- Report findings of surgery or autopsy.**
- Report whether specialty consultation(s) were done and if so, report the results.**

ANORECTAL ATRESIA/STENOSIS (Q42.0–Q42.3)

Anorectal anomalies include a wide spectrum of anomalies in which the atresia or stenosis can involve the anus alone or also a segment of the rectum. Imperforate anus is a term that properly reflects the outward appearance in the physical examination of a child, but internally the anomaly may be much more complex, involving the rectum and often associated with fistulas (e.g. Fig. 31, *panel C* – rectovaginal fistula in a girl; *panel F* – rectovesical fistula in a boy).

Fig. 31. Anorectal atresia/stenosis





Key findings in anorectal atresia/stenosis:

1. **Location:** “Low” or “high” lesions, depending on whether or not the rectum has descended into the sphincter complex (e.g. compare panel E [low lesion] –with panel F [high lesion]).
2. **Fistula:** Presence or absence.
3. **Associated findings:** Low and high lesions tend to vary by clinical presentations and frequency of associated malformations (greater in high lesions).

Diagnosis

Prenatal. Anorectal anomalies might be difficult to diagnose prenatally by ultrasonography and might be missed if an isolated anomaly. A prenatal diagnosis of anorectal anomalies should always be confirmed postnatally.

Postnatal. Anal atresia or stenosis is usually easily recognized at birth by visual inspection during the newborn physical examination. The external examination does not predict the level of the lesion. If missed at birth, rectal atresia or stenosis may be suspected in the first 24 hours when the newborn develops abdominal distension, does not pass meconium or stool, or when a fistula is present (meconium is passed through the urethra or vagina). The diagnosis of rectal atresia or stenosis is confirmed through direct imaging of the bowel by radiography, barium enema, surgery, or autopsy.

Clinical and epidemiologic notes

Only one third of anorectal anomalies are isolated. Babies must be evaluated for the presence of additional anomalies of the following:

- ▶ urinary tract;
- ▶ vertebrae or sacrum with tethered cord (the association of anorectal atresia, sacral defect and presacral mass forms the Currarino triad, often an autosomal dominant condition); and
- ▶ vagina and uterus (e.g. bicornuate uterus or uterus didelphys) in females.

Additional clinical tips:

- ▶ Non-syndromic multiple congenital anomaly patterns include caudal regression, cloacal exstrophy, OEIS (omphalocele, bladder exstrophy, imperforate anus, spinal defects) and VATER/VACTERL (**v**ertebral, **a**nus, **c**ardiac, **t**rachea, **o**esophagus, **r**enal, **l**imb) association.
- ▶ More than 100 genetic syndromes are known to include anorectal anomalies, including Townes-Brock syndrome (autosomal dominant, SALL1 gene), cat-eye syndrome (tetrasomy 22q11), Opitz G-BBB syndrome (X-linked, MID1 gene), among many others.

Checklist for high-quality reporting

Anorectal Atresia – Documentation Checklist

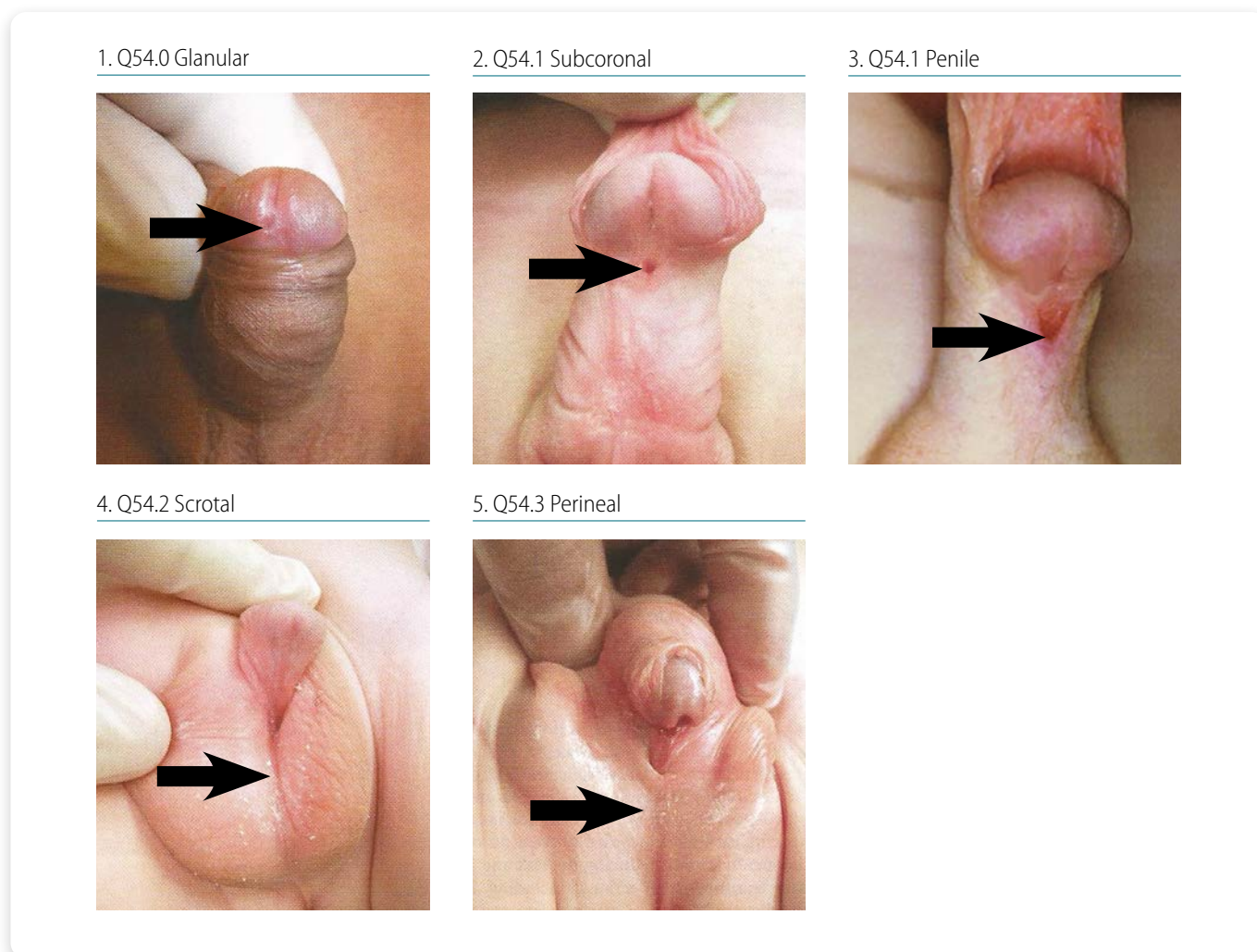
- Describe in detail**, including:
 - ▶ Atresia limited to anus versus including rectum.
 - ▶ Level of atresia – high or low.
 - ▶ Fistula – absent or present.
 - ▶ Fistula type – involving which structures.
- Describe procedures to assess further additional malformations (e.g. spine radiographs, echocardiogram) and if one or more is present, describe.**
- Take and store photographs of anomaly and baby.**
- Find and store key diagnostic imaging.**
- Report findings of surgery or autopsy.**
- Report whether specialty consultation(s) were done, and if so, report the results.**

CONGENITAL ANOMALIES OF GENITAL AND URINARY ORGANS

HYPOSPADIAS (Q54.0–Q54.9)

Hypospadias is characterized by an abnormal (ventral) placement of the external urethral meatus in male infants. Normal placement of the urethral meatus is on the tip of the penis, whereas in hypospadias the meatus is ventrally and proximally displaced (on the underside of the penis).

Fig. 32. Hypospadias



Photograph source: 1, 2, 4, 5: Nelson Textbook of Pediatrics (<http://www.slideshare.net/wadoodaref/congenital-anomalies-videosession-v3-11680674>).

Key findings in hypospadias:

1. **Location:** Hypospadias is classified by severity (see Fig. 32) depending on the location of the meatus – first degree includes the more distal forms, glanular and coronal; second degree includes subcoronal and penile shaft hypospadias; and third degree, the most severe, includes scrotal and perineal hypospadias.
2. **Potential associated findings:** The shortening of the ventral side of the penis found in hypospadias can result in a curvature of the penis, known as chordee. Note the presence of chordee. Note if the testes are present or absent.

Diagnosis

Prenatal. Hypospadias is difficult to diagnose prenatally using ultrasound and may be confused with micropenis, penile cyst, chordee, or ambiguous genitalia. A prenatal diagnosis of hypospadias should always be confirmed postnatally.

Postnatal. A careful, systematic examination of the newborn should allow a firm diagnosis of hypospadias. Note that the milder forms such as glanular hypospadias are easily missed at delivery and may be discovered during circumcision. The surgical report may provide definitive detail of the urethral placement and whether chordee is present.



Clinical and epidemiologic notes

Hypospadias is often an isolated (>80%) non-syndromic anomaly.

Additional clinical tips:

- ▶ Note if testes are present/absent and if chordee is present.
- ▶ When stratified by type, the proportion of isolated defects decreases with increasing severity (penile 74% and scrotal 65%, the most severe).
- ▶ Look for additional anomalies, in particular for penile and scrotal hypospadias as these are associated with syndromes.
- ▶ Report all findings and obtain good clinical photographs (or note location of urethra in figure below) for the expert reviewer.

Checklist for high-quality reporting

Hypospadias – Documentation Checklist

❑ Describe in detail:

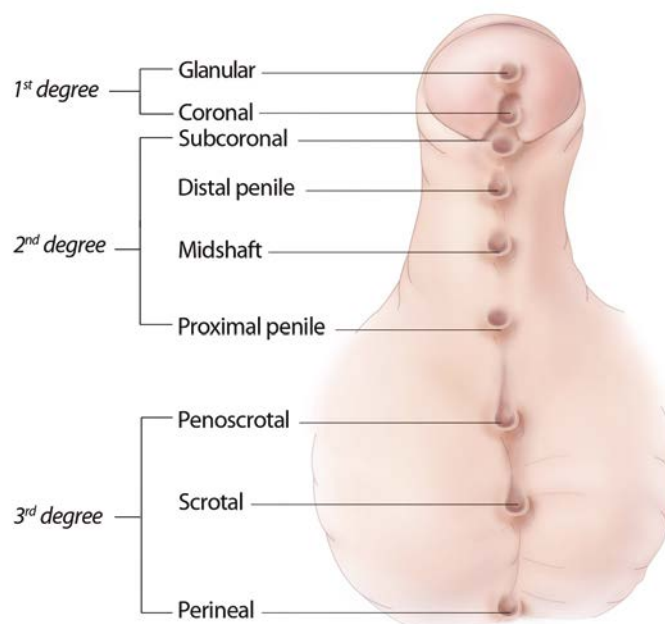
- ▶ Location of urethral meatus – glanular, coronal, subcoronal, shaft, scrotal, perineal.
- ▶ Testes present/absent (if not palpable, consider diagnoses of virilization in females, such as in cases of congenital adrenal hyperplasia).
- ▶ Presence of chordee.

❑ Include photographs: *Show clearly* the location of the urethra or use drawing; can be crucial for review.

❑ Describe evaluations to find or rule out related and associated anomalies:

- ▶ Report undescended testis (unilateral Q53.1, bilateral Q53.2).
- ▶ Chordee – do not report cases of isolated chordee if no hypospadias.
- ▶ Surgical reports – can be very helpful to identify type.
- ▶ Other anomalies of urinary tract (renal) or genitalia.
- ▶ Report if specialty consultations were done and if so, report the results.
- ▶ Genetic/chromosomal/biochemical testing if syndrome suspected.

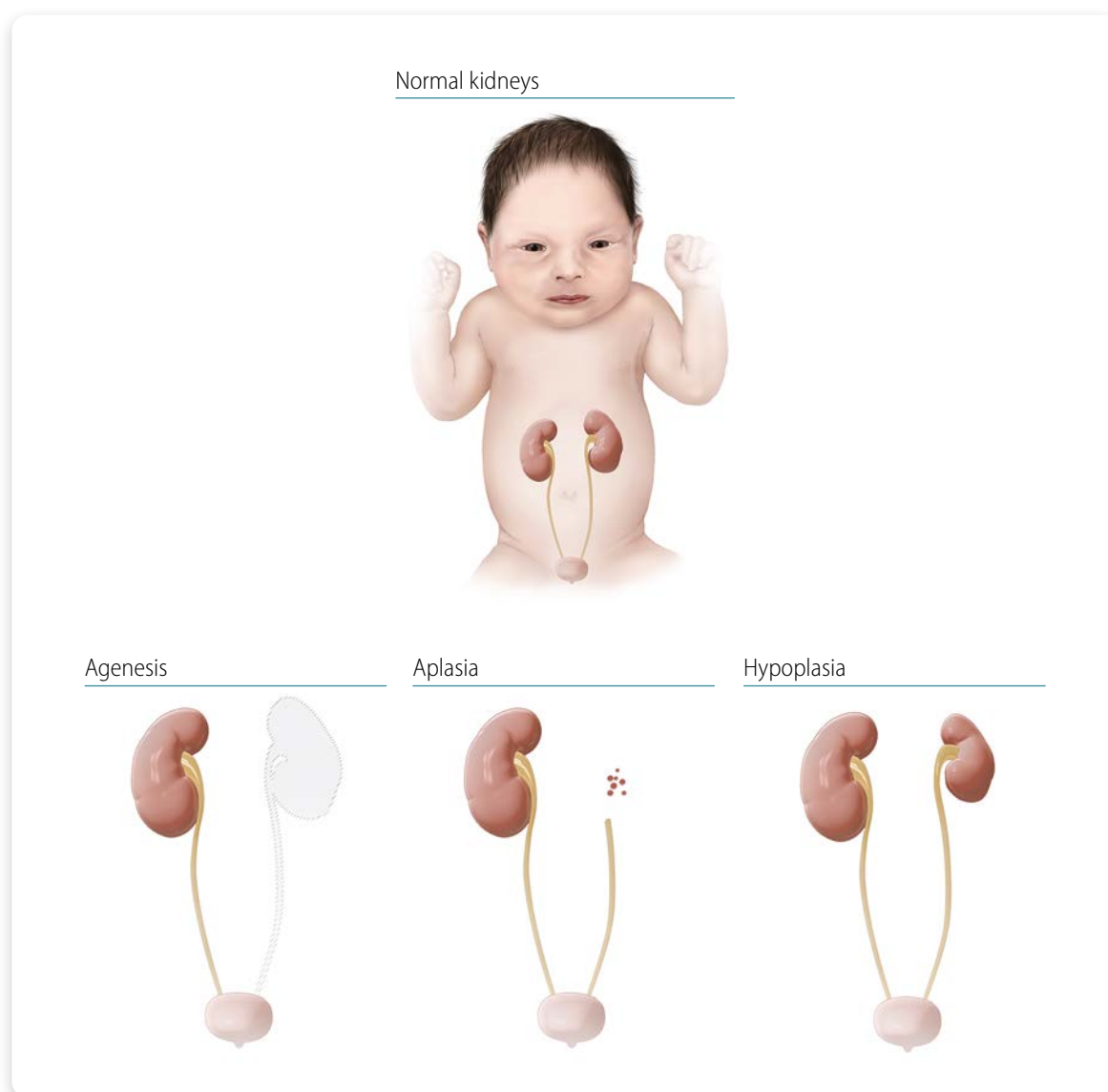
❑ Report whether autopsy (pathology) findings are available and if so, report the results.



Note: Illustration indicates all possible locations for the malformation; select the location closest to what you see in the patient.

Renal agenesis is a complete absence of one (unilateral) or both (bilateral) kidneys, whereas in renal aplasia the kidney has failed to develop beyond its most primitive form. In practice, renal agenesis and renal aplasia might be indistinguishable. Renal hypoplasia is a congenitally small kidney without dysplasia and can be bilateral or unilateral (see Fig. 33).

Fig. 33. Renal agenesis/hypoplasia





Key findings in renal agenesis:

1. **Location:** Unilateral or bilateral; if bilateral, findings can be asymmetric (e.g. agenesis on one side, hypoplasia on the other side).
2. **Agenesis/degree of hypoplasia:** Kidney absent versus present but small or rudimentary.

Note: **Be sure not to confuse this condition with multicystic dysplastic kidney or multicystic renal dysplasia.**

Diagnosis

Prenatal. Renal agenesis can be diagnosed or strongly suspected prenatally by ultrasound but should always be confirmed postnatally.

Postnatal. Renal agenesis or hypoplasia is conclusively diagnosed only through direct assessment by abdominal ultrasound, CT or MRI scan, surgery, or autopsy. Bilateral renal agenesis should be considered in an infant with features of Potter sequence. Bilateral renal *hypoplasia* might or might not be recognized after delivery, depending on the severity and degree of residual kidney function. Unilateral renal agenesis or hypoplasia may be clinically silent at delivery if the contralateral kidney is functional, such that the diagnosis may occur months or years after birth (if at all).

Clinical and epidemiologic notes

In about half of all cases of bilateral renal agenesis there are other structural anomalies (e.g. urogenital, cardiac, skeletal, central nervous system) or syndromes (chromosomal or genetic).

The non-syndromic multiple anomaly patterns include:

- ▶ VATER/VACTERL (**v**ertebral, **a**nus, **c**ardiac, **t**rachea, **o**esophagus, **r**enal, **l**imb) association;
- ▶ MURCS association (**M**ullerian, **r**enal, **c**ervicothoracic **s**omite abnormalities), a developmental disorder affecting primarily females and involving mainly the reproductive and urinary systems;
- ▶ sirenomelia; and
- ▶ caudal dysplasia (also seen in pregestational diabetes).

Additional clinical tips:

- ▶ Bilateral renal agenesis is a lethal condition – the fetus may be stillborn or die shortly after delivery.
- ▶ Look for major anomalies and minor anomalies – renal agenesis is seen in hundreds of genetic conditions, including common trisomies, deletion 22q11, Melnick-Fraser syndrome, Fraser cryptophthalmos syndrome, and branchio-oto-renal syndrome.
- ▶ Determine related anomalies in bilateral renal agenesis (Potter sequence: abnormal facies, talipes [clubfoot] and other contractures, pulmonary hypoplasia).
- ▶ Distinguish renal agenesis from other kidney anomalies (multicystic dysplasia and polycystic renal disease).

Checklist for high-quality reporting

Renal Agenesis/Hypoplasia – Documentation Checklist

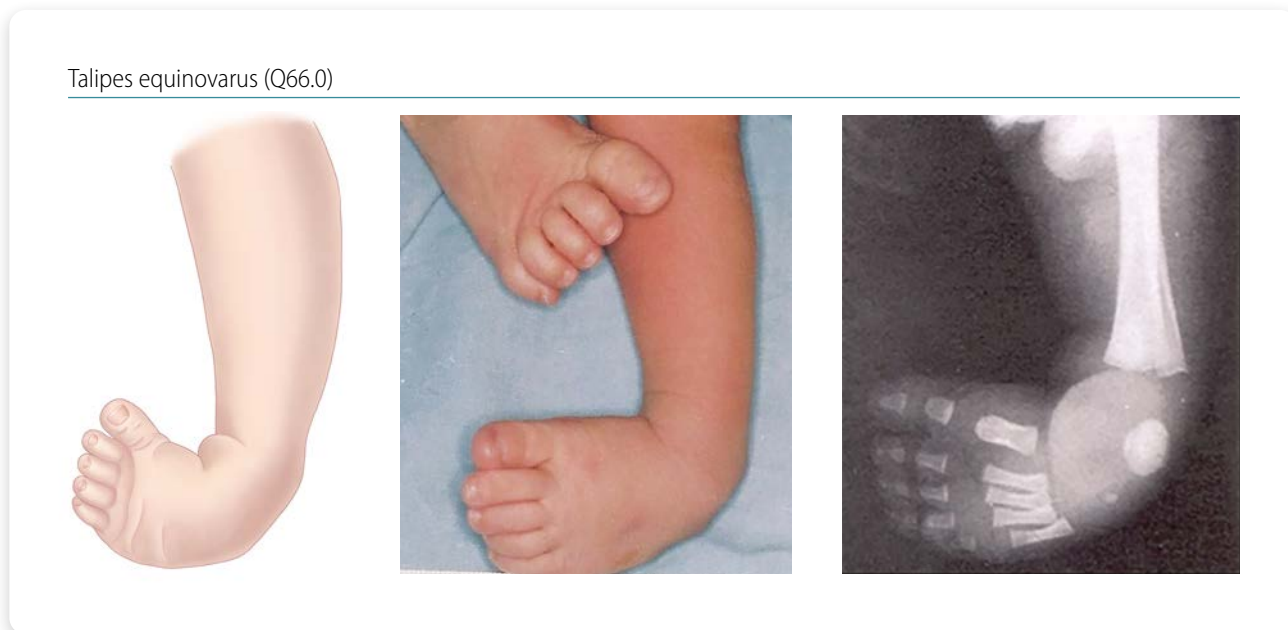
- Describe in detail**, including:
 - ▶ Unilateral (specify side) versus bilateral.
 - ▶ Agenesis and/or hypoplasia (unilateral renal agenesis with contralateral renal hypoplasia).
- Take and report photographs of any external defects:** *Especially show clearly* the location of the urethra; can be crucial for review.
- Describe evaluations to find or rule out related and associated anomalies:**
 - ▶ Other anomalies of urinary tract (renal) or genital organs.
 - ▶ Other unrelated anomalies (such as VATER, VACTERL).
 - ▶ Report if specialty consultations were done and if so, report the results.
 - ▶ Genetic or chromosomal testing if syndrome suspected.
- Report whether autopsy (pathology) findings are available and if so, report the results.**

CONGENITAL ANOMALIES AND DEFORMATIONS OF THE MUSCULOSKELETAL SYSTEM

TALIPES EQUINOVARUS (Q66.0)

Talipes equinovarus (TEV) is the specific term and common type of what is sometimes called “clubfoot”, a term that encompasses a range of anomalies of the ankle or foot present at birth.

Fig. 34. Talipes equinovarus



Photograph and x-ray source: Dr Idalina Montes and Dr Rafael Longo (Puerto Rico).

Key findings in TEV (see Fig. 34):

1. **Position:** Fixation of the foot (forefoot and hindfoot) in plantar flexion (equinus), deviation toward the midline (varus) and upward rotation so the foot rests on its outer side (supinatus).
2. **Severity:** Milder cases are “positional”, meaning that the foot and ankle can be gently manipulated into a normal position. In more severe cases the foot and ankle can be “rigid” or “fixed”, in that they cannot be manipulated into a normal position and require orthopaedic or surgical treatment.

Diagnosis

Prenatal. Clubfoot can be identified or suspected on prenatal ultrasound. However, it should not be included in birth defects surveillance data without postnatal confirmation.

Postnatal. Clubfoot is readily diagnosed in the newborn examination. Cases should be followed and evaluated sequentially to assess the degree of severity and whether treatment other than manipulation is necessary.



Clinical and epidemiologic notes

TEV has a wide spectrum of severity, which is important to define because it drives management and outcomes.

- ▶ Milder cases are “positional”, meaning that the foot can be gently manipulated into a normal position and typically does not require orthopaedic or surgical interventions. Positional talipes is excluded in surveillance.
- ▶ More severe cases are “rigid” or “fixed”, meaning the foot cannot be manipulated into a normal position and requires orthopaedic or surgical treatment.

Imaging is very helpful but a clinical examination in expert hands can provide a firm diagnosis.

Additional clinical tips:

- ▶ TEV can occur with deformations in other joints (e.g. elbow, hands, knees) – check and report.
- ▶ TEV can be due to many syndromes and disorders, especially of the brain and bone/cartilage – evaluate carefully.
- ▶ Be sure to differentiate TEV from other types of “clubfoot”, such as talipes calcaneovalgus, common in trisomy 18 (in which the ankle joint is dorsiflexed instead of plantar flexed, and the forefoot deviated outwards); and talipes calcaneovarus (in which the ankle joint is dorsiflexed, and the forefoot deviated inwards).

Checklist for high-quality reporting

Talipes Equinovarus – Documentation Checklist

❑ Describe in detail, including:

- ▶ Laterality – right, left, or bilateral.
- ▶ Mobility of foot – rigid (contracted) versus flexible (flexible is the same as positional, and is excluded in most systems).
- ▶ The typical features of TEV (plantar flexion, varus deformity, upward rotation).
- ▶ Related findings if present (medial creases, hypotrophic calf).

❑ Describe other deformations if present (e.g. knees, fingers, elbows), especially if rigid (e.g. in arthrogyriposis).

❑ Describe procedures to assess further additional malformations and, if one or more is present, describe.

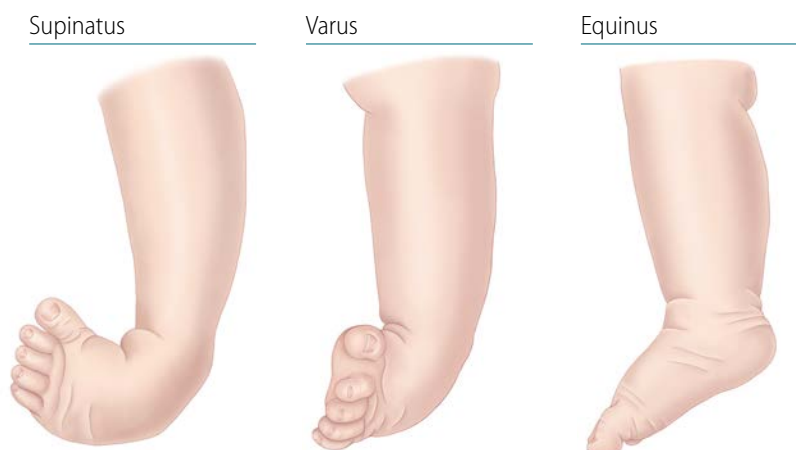
❑ Take and report photographs of anomaly and whole baby; useful for review but not sufficient as confirmation.

❑ Specialty consultations: Report which were done (including genetics and orthopaedics) and results.

❑ Note that the following conditions are usually not considered eligible conditions:

- ▶ Flexible/positional TEV – because of variability, frequency and minor health impact.
- ▶ Talipes associated with neuromuscular sequences and syndromes – programmes should code the associated clubfoot but exclude when determining prevalence rates of talipes.
- ▶ Other presentations of deformities of the foot.

Additional visual: foot positions





CONGENITAL ANOMALIES AND DEFORMATIONS OF THE MUSCULOSKELETAL SYSTEM: LIMB REDUCTION DEFECTS/LIMB DEFICIENCIES

The key finding in limb reduction defects – also known as limb deficiencies – is the absence or severe hypoplasia of a limb or part of a limb. Severe hypoplasia is operationally defined as hypoplasia (small size) associated with **abnormal shape**.

Limb reduction defects need to be kept separate from other limb anomalies such as mild hypoplasia (with normal shape), syndactyly, or sirenomelia.

Hypoplasia with relatively normal shape is seen in many skeletal dysplasias, such as achondroplasia. Skeletal dysplasias are typically single-gene disorders and are not included among limb deficiencies in public health surveillance.

Other examples of mild hypoplasia with normal shape, to be distinguished from limb reduction defects, are: brachydactyly (without severe hypoplasia or absent bones of hand or feet) and clinodactyly (incurving of the finger, most commonly the fifth finger, due to hypoplasia of middle phalanx). Usually, mild hypoplasia does not require treatment and should be regarded as a minor anomaly.

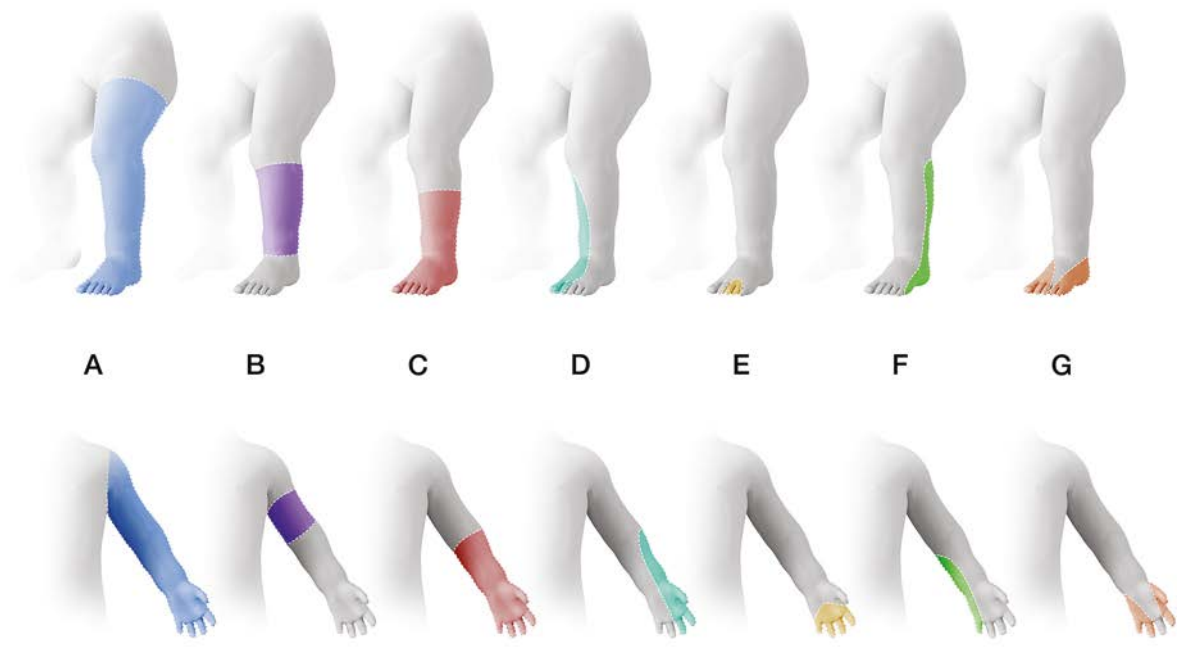
Syndactyly with severe hypoplasia of phalanges should be excluded. Sirenomelia is a severe sequence with fusion of lower limbs and visceral anomalies. Sirenomelia should not be included among limb deficiencies. The standard nomenclature divides limb deficiencies into two basic types – longitudinal and transverse. Longitudinal deficiencies are along the long axis of the limb and are distinguished into further subgroups: preaxial (radial and tibial side), postaxial (ulnar and fibular side) and axial (central). In contrast, transverse deficiencies occur across (transversally to) the long axis of the limb. Transverse defects may be terminal (more frequent) when the *terminal part of the limb is completely missing*; or intercalary when some part of the limb is missing *but the terminal part is present*, even if malformed. It is important to categorize limb reduction defects in the correct specific subtypes as these subtypes tend to differ by etiology and pathogenesis (see Table 1 and Fig. 35).

Table 1. Types of limb deficiencies by axis and segment involved

Axis of the limb	Segment	Involvement
Complete absence	All segments	Amelia.
Transverse	Terminal	Absence of terminal segment of limb (at any level).
	Intercalary	Absence or severe hypoplasia of part of limb with normal or nearly normal terminal segment, including: <ul style="list-style-type: none"> • typical and atypical intercalary defects • femoral hypoplasia.
Longitudinal	Preaxial	Radial, tibial, first digit/toe (with or without involvement of second digit/toe).
	Axial	Hand/foot only: Third ray involved (with or without second and fourth ray). Includes typical split-hand/foot and split-hand/foot monodactyly type.
	Postaxial	Fifth digits/toes (with or without fourth digit/toe involved).
Mixed		Any other combination of two or more subtypes; for example, femoral-fibula-ulnar complex.



Fig. 35. Types of limb deficiencies by axis and segment involved (see text for details)



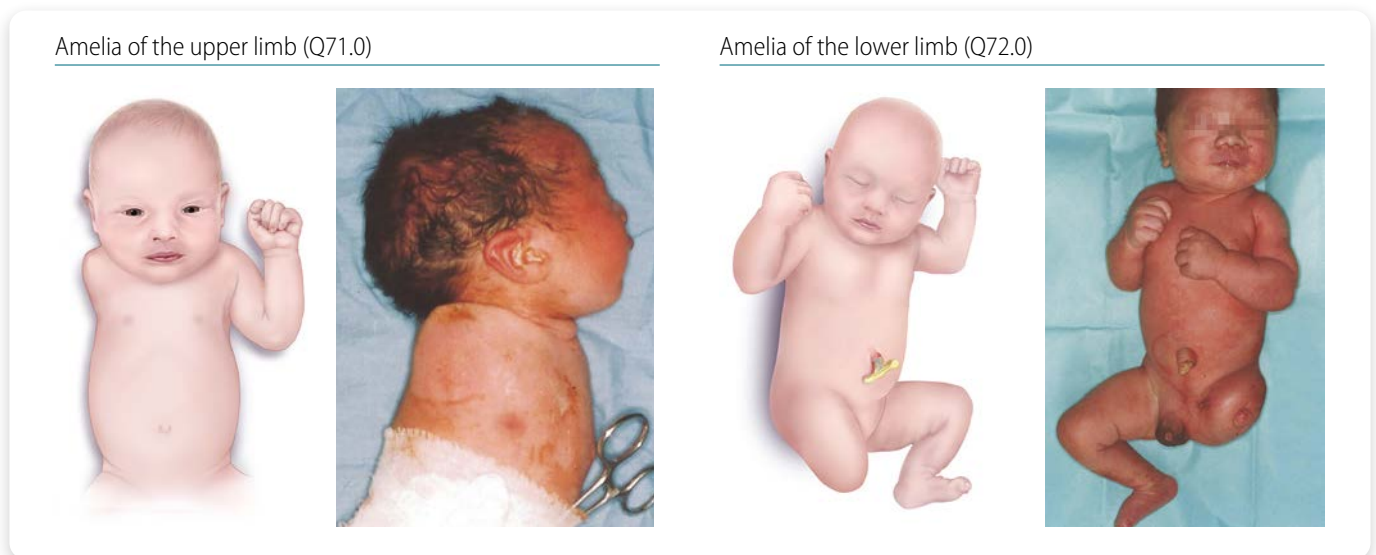
Absent or hypoplastic structures are shaded. A: complete absence of limb (amelia); (B) intercalary defect; (C) terminal transverse defect; (D) longitudinal defect, preaxial; (E) longitudinal defect, central; (F) longitudinal defect, postaxial; (G) longitudinal, pre- and postaxial.

Adapted from: Gold NB, Westgate MN, Holmes LB. Anatomic and etiological classification of congenital limb deficiencies. *Am J Med Genet A.* 2011;155A(6):1225–35).

Note: Avoid old and imprecise terms such as ectrodactyly, meromelia, micromelia and hemimelia. Avoid what are now considered pejorative terms, such as phocomelia (for transverse intercalary defects) and lobster claw (for split hand/foot).

Amelia is a congenital anomaly characterized by the complete absence of one or more limbs (see Fig. 36). It can be distinguished from other limb deficiencies, especially terminal transverse deficiencies, and rare conditions such as sirenomelia and limb-body wall spectrum (see Fig. 37 and Table 2). Radiographs are strongly recommended to confirm the condition and characterize the bony anatomy.

Fig. 36. Amelia



Photograph source: CDC–Beijing Medical University collaborative project.

Diagnosis

Prenatal. Amelia can be diagnosed prenatally but can be missed or misdiagnosed. Cases identified or suspected prenatally should be confirmed postnatally before inclusion in a surveillance programme.

Postnatal. Careful examination of the newborn, aided by radiography, confirms the diagnosis of amelia and distinguishes it from other limb reduction defects (e.g. terminal transverse defects) and sirenomelia (very rare).

Clinical and epidemiologic notes

A carefully clinical examination is crucial, with special attention focused on confirming the absence of the proximal segment of the humerus or femur. Radiological examination is essential to firmly characterize the bony anatomy of the region.

Clinical presentation:

- ▶ Multiple congenital anomalies are the most frequent. Amelia has been reported in association with musculoskeletal defects, intestinal defects, some renal and genital defects, oral clefts, defects of cardiac septa, and anencephaly.
- ▶ Though infrequently, amelia can be seen in certain syndromes, genetic (e.g., Roberts syndrome) as well as teratogenic (e.g., thalidomide embryopathy).

Clinical tips:

- ▶ Make sure that all bony segments of the affected limb are absent. If a segment is present, the defect is not amelia.
- ▶ Look for additional birth defects, not uncommon in cases with amelia.



Checklist for high-quality reporting

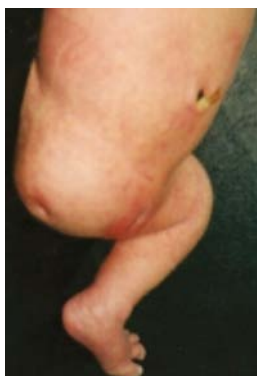Amelia – Documentation Checklist

- Describe in detail** (avoid using only the term “amelia”), including:
 - ▶ Limb(s) involved.
 - ▶ The segment(s) involved for each affected limb – confirm that all segments of the limb are absent.
 - ▶ Laterality – right, left, bilateral.
- Use Fig. 35 to distinguish amelia from other limb deficiencies.**
- Describe procedures to assess further additional malformations** and, if one or more is present, describe.
- Distinguish from transverse terminal defects, sirenomelia and limb-body wall spectrum.**
- Take and report photographs:** Very useful; often crucial for review.
- Take and report radiographs:** Crucial for review and classification.
- Report whether specialty consultation(s) were done and if so, report the results.**

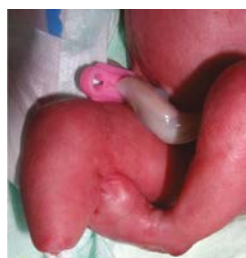Table 2. Distinguishing amelia from other congenital anomalies

Congenital anomaly	Main features
Amelia	Complete absence of one or more limbs.
Transverse terminal defect	Terminal transverse limb deficiencies appear as an “amputation” of an arm, leg, or digit. Some remnant of the limb is present.
Sirenomelia sequence	Complex phenotype, with total or partial fusion of lower limbs, variably associated with sacral defects, anal atresia, malformed genitalia and renal a/dysgenesis.
Limb-body wall complex	Complex phenotype, consisting of a spectrum of anomalies, including limb deficiencies, atypical exencephaly/encephalocele, ventral body wall defects, atypical facial clefts, and at times, amniotic bands.

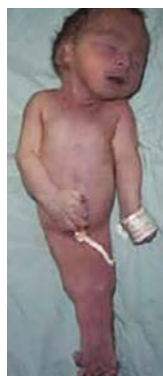Fig. 37. Distinguishing amelia from other congenital anomalies



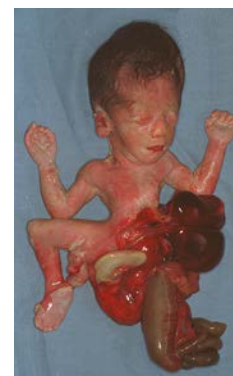Amelia of the right lower limb. Note the **complete** absence of the limb.
Photograph source: ECLAMC.



Transverse terminal defect of left limb, with missing foot and partial absence of leg.
Photograph source: ECLAMC.



Sirenomelia sequence.
Photograph source: ECLAMC.



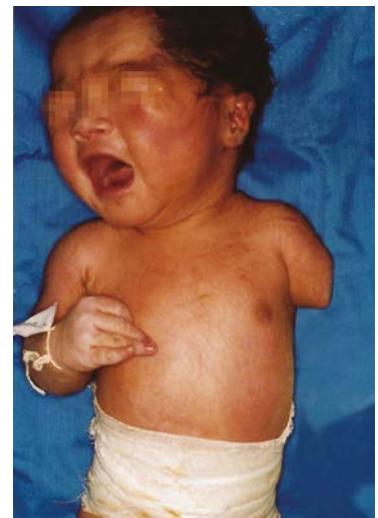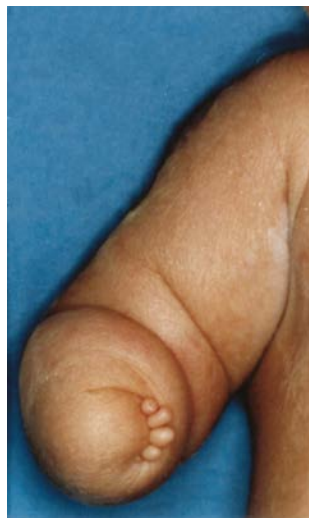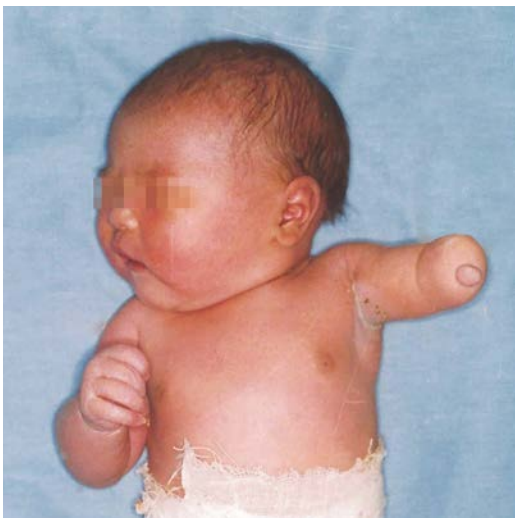Limb-body wall spectrum: Very severe lethal defects involving abdominal wall, limb, and often craniofacial structures. Note the partial absence of the left lower limb as a component of the complex in this photo. Limb-body wall complex is excluded in prevalence counts of amelia.
Photograph source: CDC–Beijing Medical University collaborative project.

LIMB DEFICIENCY: TRANSVERSE TERMINAL (Q71.2, Q71.3, Q71.30, Q72.2, Q72.3, Q72.30)

Terminal transverse limb deficiency is a congenital anomaly that appears as an “amputation” of an arm, leg, or digit/toe. The limb is missing the terminal (distal) segment(s), with preservation of all the segment(s) proximal to the missing segment (see Fig. 38). For example, if fingers are missing, the remainder of the hand, forearm and arm are all still present. Radiographs are strongly recommended and can be essential to confirm the condition and characterize the bony anatomy.

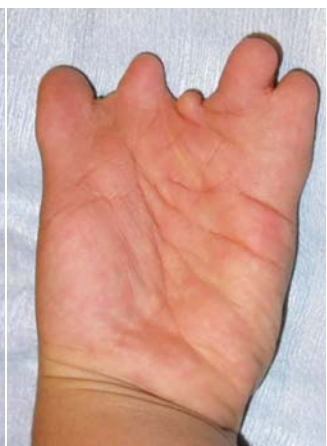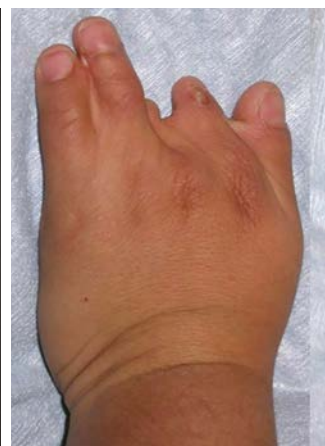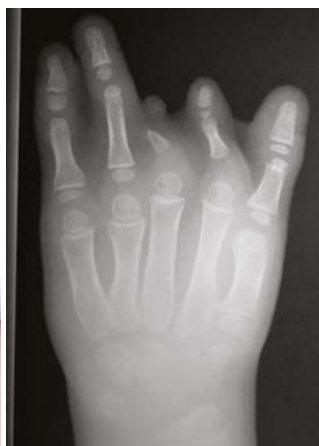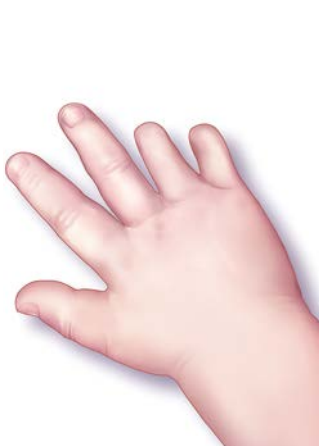Fig. 38. Transverse terminal

Congenital absence of both forearm and hand (Q71.2)



Photograph source: CDC–Beijing Medical University collaborative project.

Congenital absence of finger(s) (remainder of hand intact) (Q71.30)

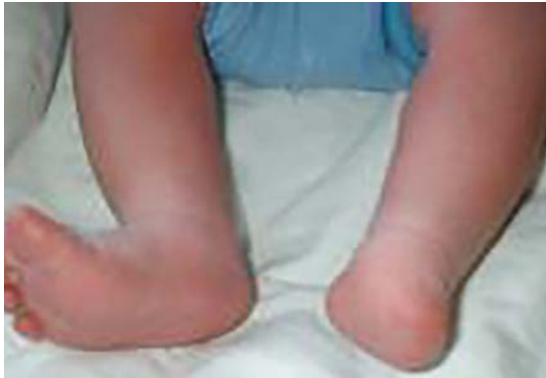

Photograph and x-ray source: Dr E. Gene Deune, Johns Hopkins Department of Orthopedic Surgery, Division of Hand Surgery.



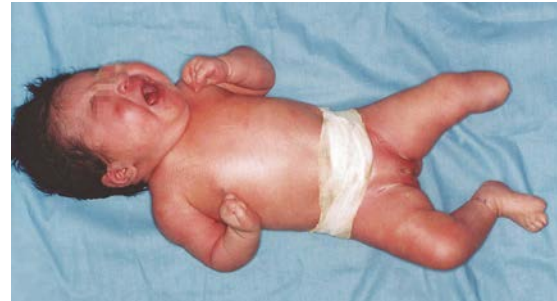Fig. 38. Transverse terminal (continued)

Congenital absence of foot and toes (Q72.3)



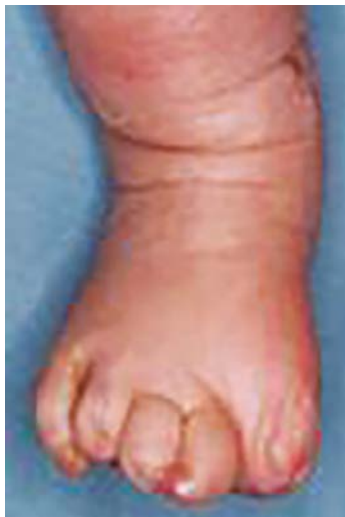Photograph source: ECLAMC

Congenital absence of both lower leg and foot (Q72.2)



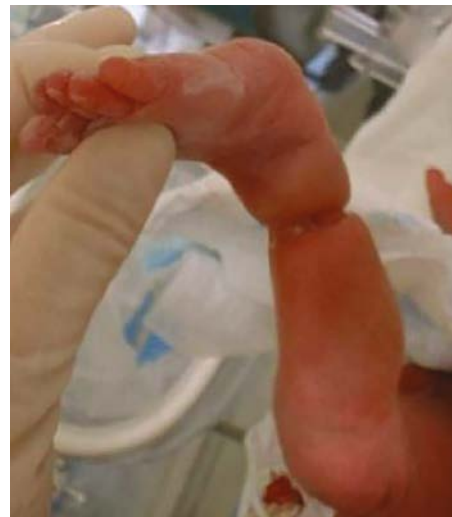Photograph source: CDC–Beijing Medical University collaborative project.

Congenital absence or hypoplasia of toe(s) with remainder of foot intact (Q72.30)



Photograph source: CDC–Beijing Medical University collaborative project.

Constriction ring (Q84.81)



Photograph source: ECLAMC.

Diagnosis

Prenatal. Transverse terminal limb defects can be suspected prenatally but can easily be missed or misdiagnosed. Cases identified or suspected prenatally should be confirmed postnatally before inclusion in a surveillance programme.

Postnatal. The newborn examination, aided by radiographs, confirms the diagnosis of terminal transverse limb deficiencies and distinguishes it from other limb reduction defects. It is important to underline the importance of a detailed examination and documentation, including imaging (photographs and radiographs).

Clinical and epidemiologic notes

Terminal transverse deficiency includes a wide spectrum of limb deficiencies, with partial amputation of the distal limb. The terminal partial amputation can involve digits, toes, forearm, arm, leg, or thigh. Transverse deficiencies are the most common of the limb deficiencies.



Clinical presentation:

- ▶ Most cases of terminal transverse deficiency occur sporadically as an isolated abnormality of one hand or foot in an otherwise healthy individual.
- ▶ Some cases of terminal transverse defects have been attributed to instances of “early amnion rupture disruption sequence”, also referred to as amniotic bands. The damage attributed to amniotic bands ranges from constriction of a limb to hypoplasia of digits with syndactyly, rudimentary digits, and absence of the limb distally from the site of the in utero amputation. Amniotic bands can also cause disruptions at other sites, such as the face and body wall.
- ▶ In cases of terminal deficiencies that involve the hand, proper digits are absent but the presence of small soft tissue nubbins arranged in a pattern suggest rudimentary digits.
- ▶ Transverse limb deficiency is seen in Adams–Oliver syndrome, a genetic condition with features that also include aplasia cutis congenita and other anomalies (e.g. congenital heart disease, brain calcifications).
- ▶ Transverse limb deficiency has been observed after maternal exposure to the medication misoprostol, taken to induce abortion.

Clinical tips:

- ▶ Make sure that the distal part of the limbs is affected and that proximal segments are present.
- ▶ Transverse terminal limb defects look like an amputation – the affected limb segment often ends abruptly, without any obvious relation to anatomical boundaries.
- ▶ Distinguish terminal deficiency from amelia (**complete** absence of the limb), and from “split hand” when the transverse terminal defect affects the central digits (see Fig. 39).
- ▶ If possible, take and attach radiographs, as these are very useful to confirm and describe the bony anatomy, thus characterizing precisely the level of the amputation and which specific bones are involved (i.e. missing).
- ▶ Look for and note the presence or absence of specific findings that can be associated with transverse limb deficiency, such as soft tissue nubbins, constriction rings, or amniotic bands.

Checklist for high-quality reporting

Transverse Terminal Defects – Documentation Checklist

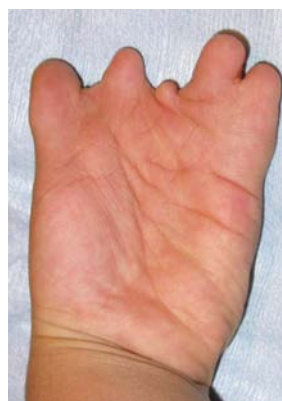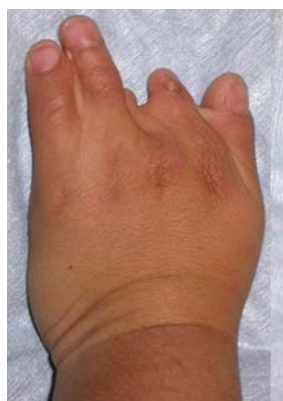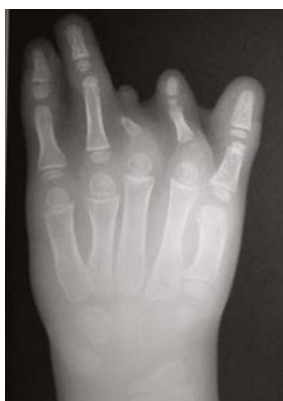- Describe in detail**, including:
 - ▶ Limbs involved.
 - ▶ Note each segment involved for each limb affected – describe what is deficient or absent. Indicate involvement of digits, toes, forearm, arm, leg, thigh.
 - ▶ Laterality – right, left, bilateral.
 - ▶ Report whether or not soft tissue nubbins are present.
 - ▶ Report whether or not amniotic bands and or ring constrictions are present.
 - ▶ Document specialty consultations (e.g. genetics, orthopaedics).
- Use Fig. 35 to distinguish transverse terminal defects from other subtypes of limb deficiencies.**
- Describe procedures to assess further additional malformations and, if one or more is present, describe.**
- Describe procedures to assess syndromes.**
- Distinguish from other limb deficiencies** (e.g. amelia or axial defects).
- Take and report photographs:** Very useful; can be crucial for review.
- Take and report radiographs:** Crucial for review and classification, at times even more so than photographs.
- Report whether specialty consultation(s) were done and if so, report the results.**



Key visuals:

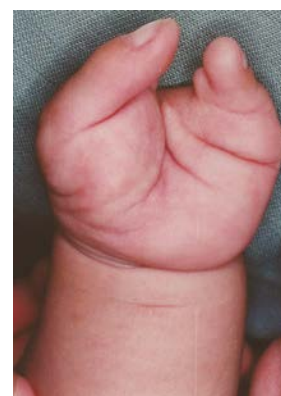Fig. 39. Distinguishing transverse terminal defects from longitudinal axial defects and amelia (side-by-side comparison)

Terminal transverse defect – absence of fingers (Q71.30)



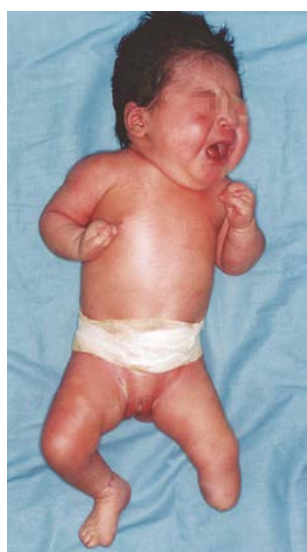Photograph source: Dr E Gene Deune, Johns Hopkins Department of Orthopedic Surgery, Division of Hand Surgery (USA)

Longitudinal axial defect – cleft hand (Q71.6)



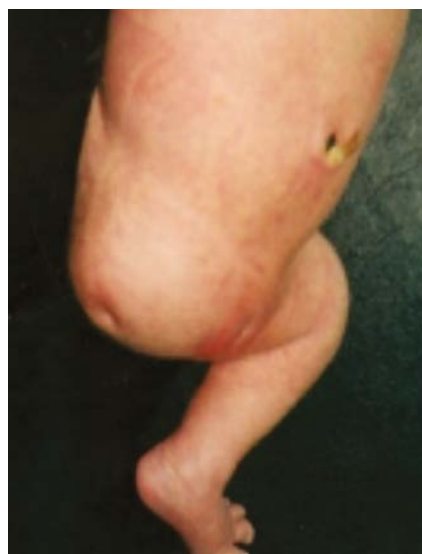Photograph source: CDC–Beijing Medical University collaborative project.

Transverse terminal defect of left limb, with missing foot and partial absence of leg (Q72.2)



Photograph source: CDC–Beijing Medical University collaborative project

Amelia of right lower limb (Q72.0)

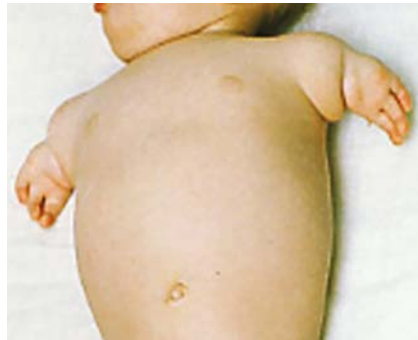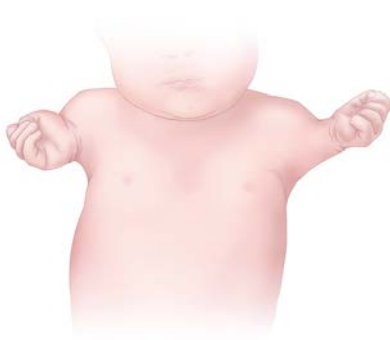


Photograph source: ECLAMC

Transverse intercalary limb deficiencies are characterized by the absence of proximal or middle segments of a limb with all or part of the distal segment present (see Fig. 40). Radiographs are strongly recommended to confirm the condition and characterize the bony anatomy.

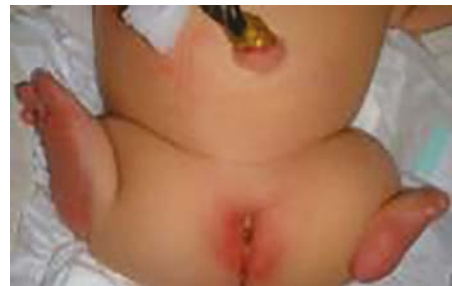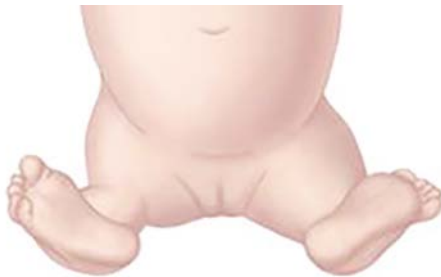Fig. 40. Transverse intercalary

Congenital absence of upper arm and forearm with hand present



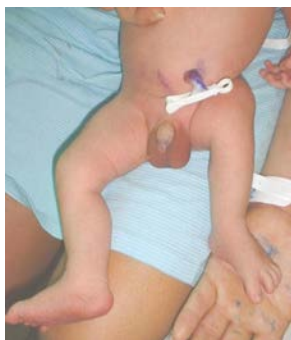Photograph source: Dr Jaime Frias (EE. UU).

Congenital absence of thigh and lower leg with foot present

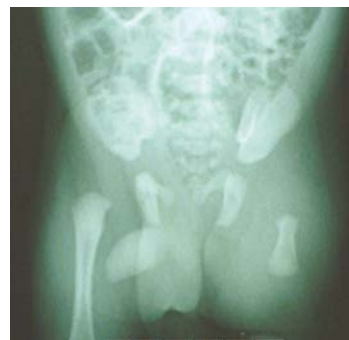

Photograph source: ECLAMC.

Longitudinal reduction defect of femur



Photograph source: ECLAMC.



Photograph source: ECLAMC.



Diagnosis

Prenatal. Transverse intercalary limb deficiency can be suspected prenatally but can easily be missed or misdiagnosed. Cases identified or suspected prenatally should be confirmed postnatally before inclusion in a surveillance programme.

Postnatal. The newborn examination confirms the diagnosis of intercalary limb deficiencies and distinguishes it from other limb reduction defects. A careful clinical examination and documentation, aided by imaging (photos and radiographs), are essential for an accurate and complete diagnosis.

Clinical and epidemiologic notes

Note that the term “phocomelia”, associated in the past with these conditions, is now considered pejorative and should not be used (the word alludes to the shape of the limb resembling a flipper on a seal).

Typical intercalary deficiencies present with absence of all limb bones proximal to a normal or malformed hand or foot that attaches directly to the trunk. Atypical intercalary deficiencies present with absence of a humerus or femur, or both radius-ulna (tibia-fibula) with a normal or malformed hand or foot.

Clinical presentation:

- ▶ About half of cases are isolated. Most of the remaining cases have multiple congenital anomalies. A small proportion of cases are syndromic.
- ▶ Syndromes with intercalary limb deficiencies include Roberts syndrome, and in its most severe form, thrombocytopenia absent radius (TAR) can have intercalary limb deficiencies.
- ▶ A teratogen that can cause intercalary limb deficiencies is thalidomide.
- ▶ Femoral hypoplasia-unusual facies syndrome (now more commonly called femoral-facial syndrome or FFS) is characterized by unilateral or bilateral deficiency of femurs, with variable deficiencies of other long bones. It has been reported in association with pregestational diabetes.

Clinical tips:

- ▶ Make sure that the distal part of the limbs (hand and foot) is intact. Only the proximal or middle segments of the limbs are affected in terminal intercalary defects. Carefully distinguish from terminal transverse defects, which look like an amputation (see Fig. 41).
- ▶ Take photographs and attach radiographs – the combined information is extremely helpful to confirm the diagnosis, characterize accurately the specific bones involved, and distinguish typical from atypical intercalary deficiencies.



Checklist for high-quality reporting

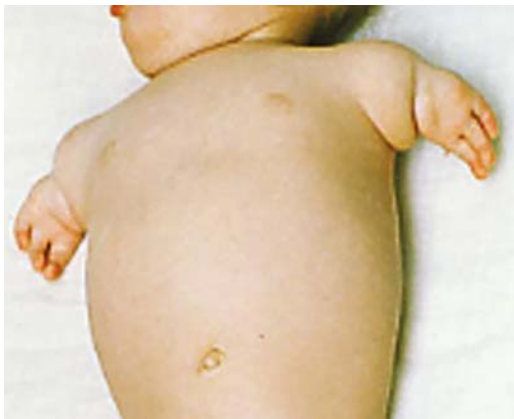Intercalary Defects – Documentation Checklist

- Describe in detail**, including:
 - ▶ Limbs involved.
 - ▶ Note each segment involved for each limb affected – describe what is deficient or absent. Indicate involvement of forearm, arm, leg, thigh. Indicate bones involved.
 - ▶ Laterality – right, left, bilateral.
 - ▶ Avoid using solely a “diagnostic term” (e.g. phocomelia).
 - ▶ Document specialty consultations (e.g. genetics, orthopaedics).
- Use Fig. 35 to distinguish transverse intercalary defects from other subtypes of limb deficiencies.**
- Describe procedures to assess further additional malformations and, if one or more is present, describe.**
- Describe procedures to assess syndromes.**
- Distinguish from other limb deficiencies** (e.g. transverse terminal deficiencies).
- Take and report photographs:** Very useful; can be crucial for review.
- Take and report radiographs:** Crucial for review and classification, at times even more than photographs.
- Report whether specialty consultation(s) were done and if so, report the results.**

Key visuals:

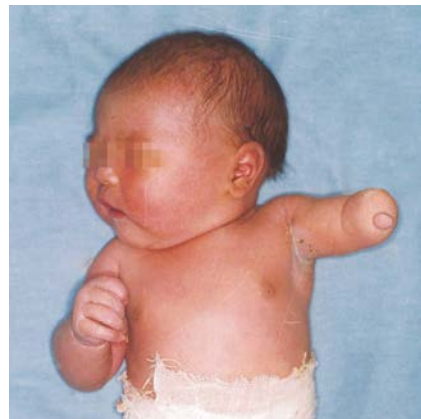Fig. 41. Distinguishing intercalary defects from transverse terminal defects (side-by-side comparison)

Typical transverse intercalary defect – congenital absence of upper arm and forearm with hand present.



Photograph source: Dr Jaime Frías (USA).

Transverse terminal defect – partial absence of forearm with an absence of hand.



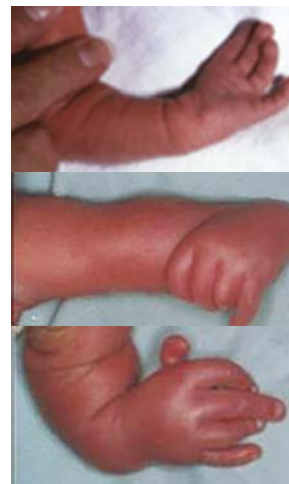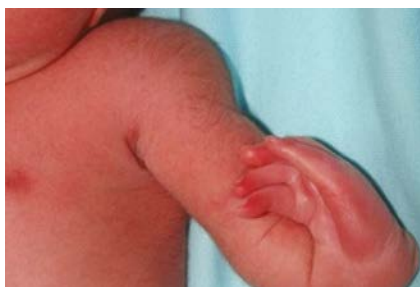Photograph source: CDC–Beijing Medical University collaborative project.



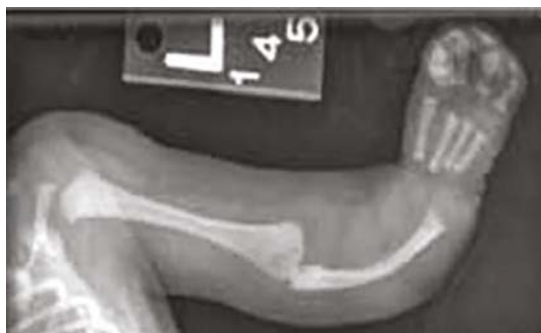LIMB DEFICIENCY: LONGITUDINAL PREAXIAL (TIBIA, RADIUS, FIRST RAY) (Q71.31, Q71.4, Q72.31, Q72.5)

Fig. 42. Longitudinal preaxial

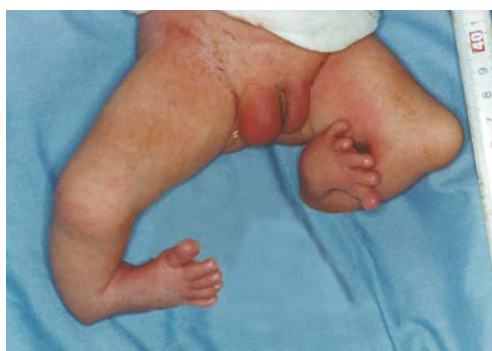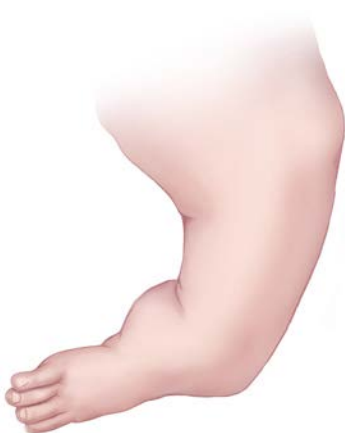Absence/hypoplasia of thumb (Q71.31)



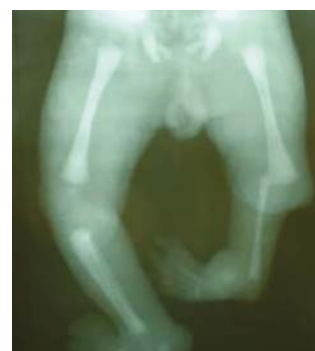Longitudinal reduction defect of radius (Q71.4)



Hypoplasia of first toe with other digits present (Q72.31)



Longitudinal reduction defect of tibia (Q72.5)



Photograph source: ECLAMC.



Preaxial limb deficiency is characterized by the absence or hypoplasia of the “preaxial” segments (those on the side of the thumb or big toe side) of the upper or lower limb (see Fig. 42). Preaxial limb deficiencies include:

- ▶ Hypoplasia/absence of the thumb (sometimes of the second finger)
- ▶ Hypoplasia/absence of the radius
- ▶ Hypoplasia/absence of the big toe (sometimes of the second toe)
- ▶ Hypoplasia/absence of the tibia.

Diagnosis

Prenatal. Preaxial limb deficiencies can be suspected prenatally but can easily be missed or misdiagnosed. Cases identified or suspected prenatally should be confirmed postnatally before inclusion in a surveillance programme.

Postnatal. The newborn examination can identify a longitudinal preaxial limb deficiency and distinguish it from other limb reduction defects (e.g. longitudinal postaxial defects). An accurate and complete diagnosis requires a detailed physical examination aided by radiography to characterize completely the bony anatomy.

Clinical and epidemiologic notes

Radial deficiency is often associated with hypoplasia or aplasia of the thumb and bowing of the ulna (so-called radial club hand, angulated to the radial side of the wrist). Isolated thumb hypoplasia or triphalangeal thumb is the mildest manifestation of a preaxial deficiency.

Longitudinal preaxial defects of the lower limb include absence or hypoplasia of the first toe with or without hypoplasia or absence of the tibia. Tibial deficiencies are often associated with equinovarus deformities, and there may be fibular hypoplasia/aplasia.

Clinical presentation:

- ▶ Radial deficiencies are commonly associated with other anomalies such as in the VATER/VACTERL (**v**ertebral, **a**nus, **c**ardiac, **t**rachea, **o**esophagus, **r**enal, **l**imb) association as well as several genetic syndromes. Some possible genetic diagnoses include trisomy 18, Fanconi anaemia, Holt-Oram syndrome, thrombocytopenia absent radius syndrome (TAR). Of note, several genetic conditions with radial deficiency present also hematologic abnormalities (Diamond-Blackfan anaemia, Fanconi anaemia, TAR).
- ▶ Thalidomide and valproate are known teratogens associated with longitudinal preaxial defects (as well as other types of limb deficiency).
- ▶ Tibial deficiencies occur most often as an isolated, unilateral malformation with the fibula present.

Useful **clinical tips** for diagnosis:

- ▶ Make sure that the **preaxial** side of the limb is affected – absent thumb with or without second finger, radius (upper limb); absent first with or without second toe, tibia (lower limb). Carefully distinguish from postaxial defects (see Fig. 43).
- ▶ Radiographs are very useful to characterize the bony anatomy and the missing bony segments.
- ▶ Look for signs of genetic conditions, including those that are associated with blood disorders that can be at times suspected with simple blood tests (e.g. thrombocytopenia on a complete blood count).



Checklist for high-quality reporting

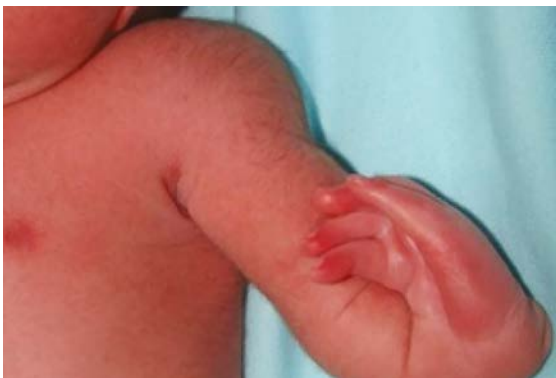Longitudinal Preaxial Defects – Documentation Checklist

- Describe in detail**, including:
 - ▶ Limbs involved.
 - ▶ Note each segment involved for each limb affected – describe what is deficient or absent. Indicate involvement of radius, tibia, first–second finger, first–second toe, fibula, and others.
 - ▶ Laterality – right, left, bilateral.
 - ▶ Document specialty consultations (e.g. genetics, orthopaedics).
- Use Fig. 35 to distinguish longitudinal preaxial defects from other subtypes of limb deficiencies.**
- Describe procedures to assess further additional malformations and, if one or more is present, describe.**
- Describe procedures to assess syndromes.**
- Distinguish from other longitudinal limb deficiencies** (e.g. longitudinal postaxial).
- Take and report photographs:** Very useful; can be crucial for review.
- Take and report radiographs:** Crucial for review and classification, at times even more than photographs.
- Report whether specialty consultation(s) were done and if so, report the results.**

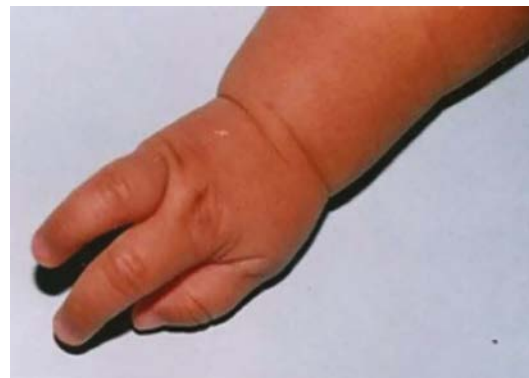Key visuals:

Fig. 43. Distinguishing longitudinal preaxial defects from longitudinal postaxial defects (side-by-side comparison)

Longitudinal **preaxial** defect – absence of thumb (Q71.31) and longitudinal reduction defect of radius (Q71.4)



Longitudinal **postaxial** defect – congenital absence of fourth and fifth fingers (Q71.30)



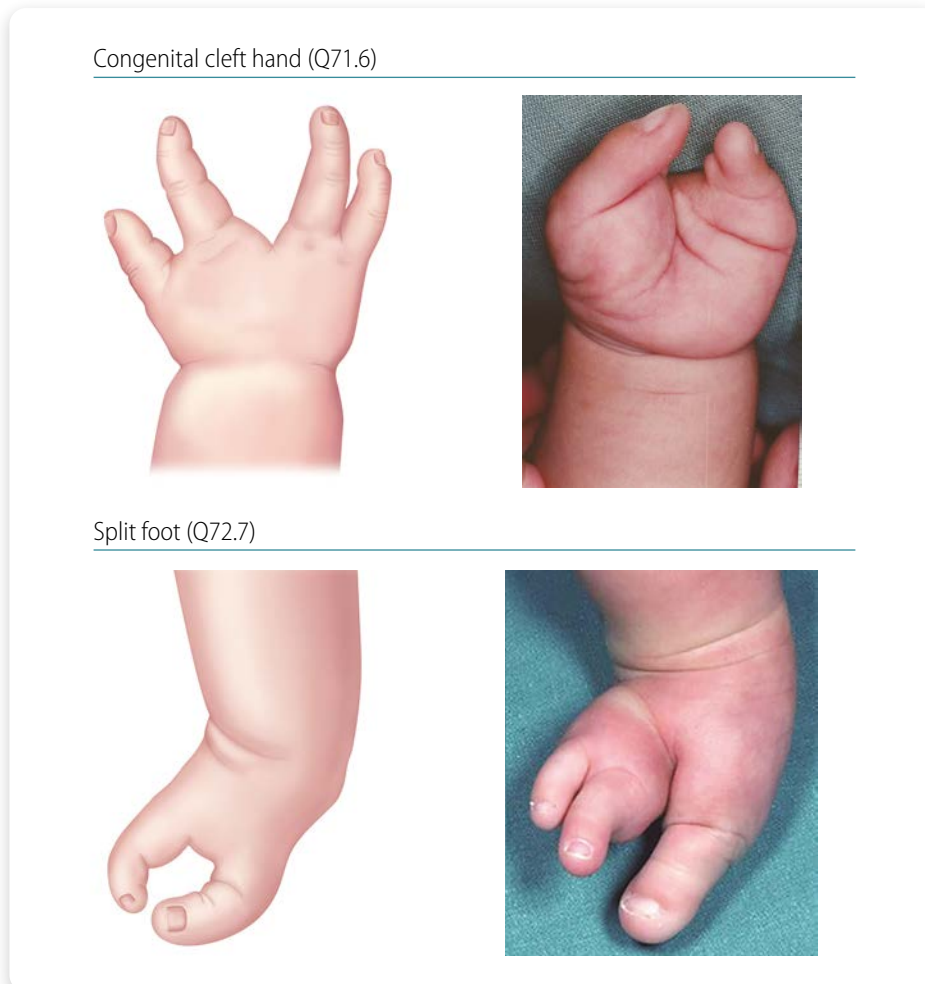
Photograph source: ECLAMC.



LIMB DEFICIENCY: LONGITUDINAL AXIAL DEFECTS – SPLIT HAND AND FOOT (Q71.6, Q72.7)

A longitudinal deficiency of the central digits/toes often involving the associated carpal/tarsal bones leads to a split-hand or split-foot appearance (see Fig. 44). Radiographs are strongly recommended to confirm and further characterize the condition.

Fig. 44. Longitudinal axial defects (split hand and foot)



Photograph source: CDC–Beijing Medical University collaborative project.

Diagnosis

Prenatal. Split hand/foot can be suspected prenatally but can easily be missed or misdiagnosed. Cases identified or suspected prenatally should be confirmed postnatally before inclusion in a surveillance programme.

Postnatal. The newborn examination confirms the diagnosis of split hand and foot and distinguishes it from other limb reduction defects (e.g. transverse terminal defects with amputation of digits or toes). It is important to underline the need for a proper examination of cases, in order to confirm the absence of the axial segment of the hand or foot. For these purposes, a radiological examination is essential.

Clinical and epidemiologic notes

The terms “ectrodactyly” and “lobster claw hands” are imprecise and pejorative and should not be used. The anatomic distribution can be hands only, feet only, or affected hands and feet. The hands are affected much more frequently than the feet. In many cases of split hand/foot, there is syndactyly and hypoplasia of some of the remaining digits. The most severe form of split hand/foot is monodactyly, where the hand or foot has but a single digit.



Clinical presentation:

- ▶ Split hand/foot may be isolated, or there may be deficiency of the adjacent long bones of the limbs.
- ▶ Split hand/foot is part of a large group of syndromes, some with overlapping features. The most common of these is EEC syndrome (ectrodactyly, ectodermal dysplasia and cleft lip/palate). Another syndrome with split hand/foot is limb-mammary syndrome (split hand/foot, absence of breast tissue, cleft palate).

Additional clinical tips:

- ▶ Make sure that the **central** segment of the hand or foot is affected – third digit/toe, with or without involvement of second and fourth digit/toe. Carefully distinguish from transverse terminal defects affecting the same digits/toes (see Fig. 45).
- ▶ Radiographs are useful to confirm and describe which specific bones are involved in the defect.
- ▶ Consider additional procedures to assess syndromes (e.g. skin examination, oral clefts), which are not uncommon in longitudinal axial defects.

Checklist for high-quality reporting

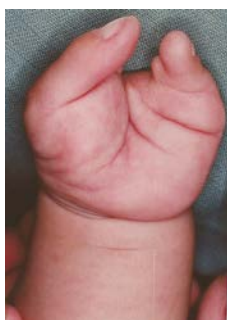Split Hand and Foot – Documentation Checklist

- Describe in detail**, including:
 - ▶ Limbs involved.
 - ▶ Note each segment involved for each limb affected – describe what is deficient or absent. Indicate involvement of digits and toes (third, with or without second and fourth).
 - ▶ Laterality – right, left, bilateral.
 - ▶ Document specialty consultations (e.g. genetics, orthopaedics).
- Use Fig. 35 to distinguish longitudinal axial defects from other subtypes of limb deficiencies.**
- Describe procedures to assess further additional malformations and, if one or more is present, describe.**
- Describe procedures to assess syndromes.**
- Distinguish from other longitudinal and transverse limb deficiencies** (e.g. transverse terminal deficiencies of fingers or toes).
- Take and report photographs:** Very useful; can be crucial for review.
- Take and report radiographs:** Crucial for review and classification, at times even more than photographs of the defect.
- Report whether specialty consultation(s) were done and if so, report the results.**

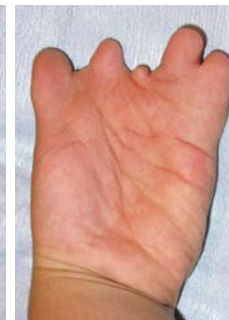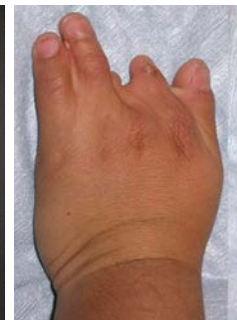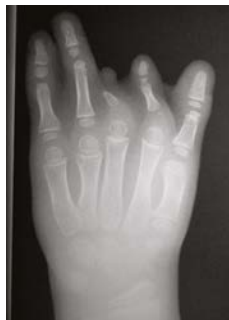Key visuals:

Fig. 45. Distinguishing longitudinal axial defects from transverse terminal defects of hand (side-by-side comparison)

Longitudinal axial or central defect – split hand (Q71.6)



Transverse terminal defect – absence of fingers (Q71.30)



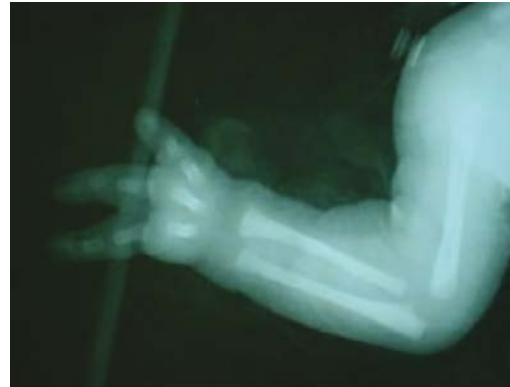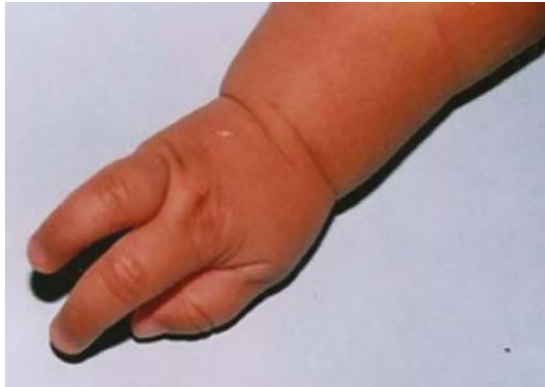Photograph source: CDC–Beijing Medical University collaborative project.

LIMB DEFICIENCY: LONGITUDINAL POSTAXIAL (FIBULA, ULNA, FIFTH RAY) (Q71.30, Q71.5, Q72.30, Q72.6)

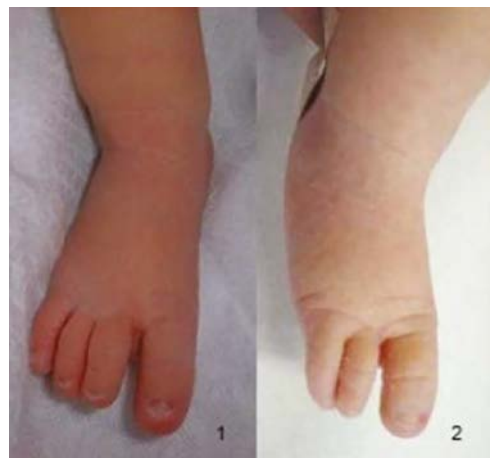Longitudinal postaxial defects include absence or hypoplasia of the fifth toe/finger (sometimes including the fourth toe/finger), and absence/hypoplasia of the fibula or ulna (see Fig. 46). Radiographs are strongly recommended to confirm and further characterize the condition.

Fig. 46. Longitudinal postaxial

Congenital absence of fourth and fifth fingers (Q71.30)



Congenital absence or hypoplasia of toe(s) with remainder of foot intact (Q72.30)



Photograph source: ECLAMC.

Diagnosis

Prenatal. Longitudinal postaxial defects can be suspected prenatally but can easily be missed or misdiagnosed. Cases identified or suspected prenatally should be confirmed postnatally before inclusion in a surveillance programme.

Postnatal. The newborn examination confirms the diagnosis of longitudinal postaxial limb deficiencies and distinguishes it from other limb reduction defects (e.g. longitudinal preaxial defects). It is important to underline the need for a proper examination of cases, in order to confirm the absence of the postaxial segment of the upper or lower limb. For these purposes, a radiological examination is essential.

Clinical and epidemiologic notes

Absence or hypoplasia of the ulna is much more likely to be a partial deficiency affecting only one arm. With complete absence of the ulna there is often a marked flexion deformity of the elbow. The hand can be straight or angulated to the ulnar side of the wrist. Ulnar deficiency is less common than radial deficiency.



Clinical presentation:

- ▶ Ulnar hypoplasia is often associated with radioulnar synostosis (fusion of the radius and ulna), absence of the postaxial digits (fourth and fifth fingers) and fibular deficiency.
- ▶ Two associations with postaxial defects have been identified:
 - The unilateral absence or hypoplasia of the ulna, femur and fibula (femur-fibula-ulna complex).
 - The ulnar-mammary syndrome, in which there are deficiencies of the ulna, fibula and postaxial digits; hypogenitalism; and absence of one or both breasts.
- ▶ Postaxial limb defects of the hand occur in Miller syndrome.

Additional clinical tips:

- ▶ Make sure that the **postaxial** side of the limb is affected: absent fifth finger with or without fourth finger, ulna (upper limb); absent fifth with or without fourth toe, fibula (lower limb). Carefully distinguish from preaxial defects (see Fig. 47).
- ▶ **Radiographs** are useful to confirm and describe which specific bones are involved in the defect.
- ▶ Look for **femoral deficiency**, a feature of the femur-fibula-ulna complex.

Checklist for high-quality reporting

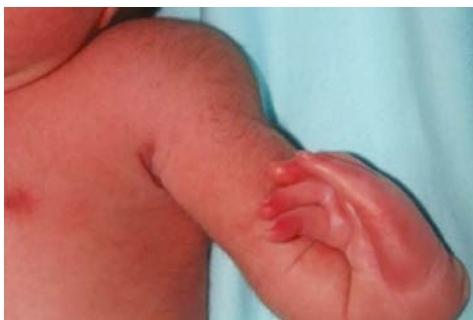Longitudinal Postaxial Defects – Documentation Checklist

- Describe in detail**, including:
 - ▶ Limbs involved.
 - ▶ Note each segment involved for each limb affected – describe what is deficient or absent. Indicate involvement of ulna, fibula, fourth–fifth finger, fourth–fifth toe, and others.
 - ▶ Laterality – right, left, bilateral.
 - ▶ Document specialty consultations (e.g. genetics, orthopaedics).
- Use Fig. 35 to distinguish longitudinal postaxial defects from other subtypes of limb deficiencies.**
- Describe procedures to assess further additional malformations and, if one or more is present, describe.**
- Describe procedures to assess syndromes.**
- Distinguish from other longitudinal and transverse limb deficiencies** (e.g. longitudinal preaxial).
- Take and report photographs:** Very useful; can be crucial for review.
- Take and report radiographs:** Crucial for review and classification, at times even more than photographs.
- Report whether specialty consultation(s) were done and if so, report the results.**

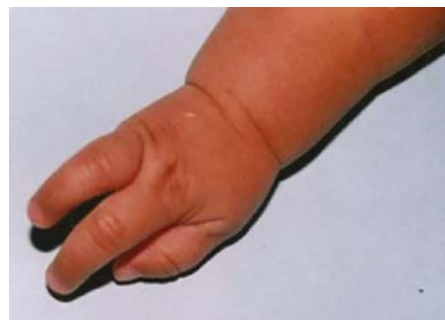Key visuals:

Fig. 47. Distinguishing longitudinal postaxial defects from longitudinal preaxial defects (side-by-side comparison)

Longitudinal preaxial: Absence of thumb (Q71.31)



Longitudinal postaxial: Congenital absence of fourth and fifth fingers (Q71.30)



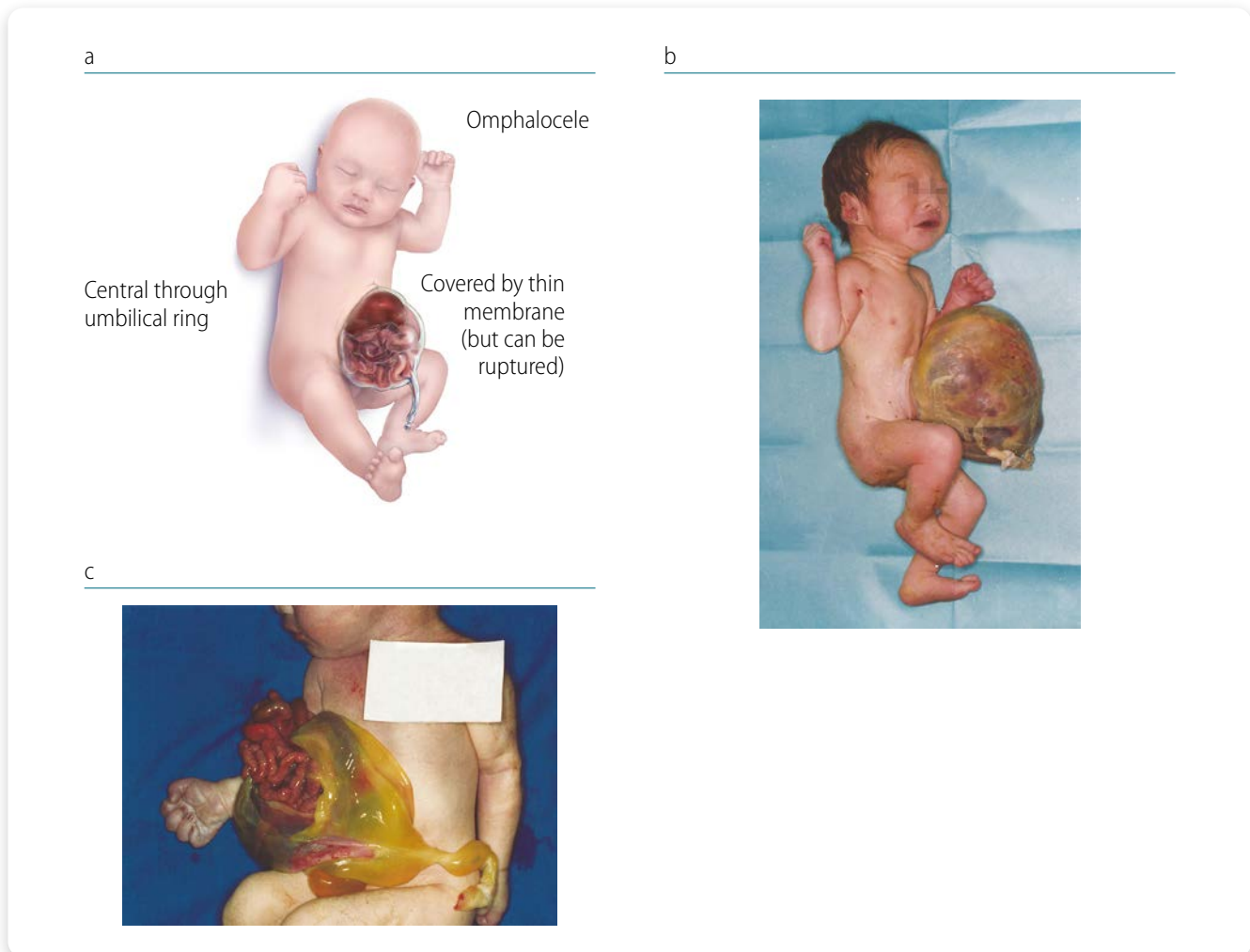
Photograph source: ECLAMC.

ABDOMINAL WALL DEFECTS

OMPHALOCELE (Q79.2)

Omphalocele is a birth defect of the anterior abdominal wall, characterized by a centrally located and membrane-covered herniation of gut and possibly other organs (liver, spleen, stomach).

Fig. 48. Omphalocele



Photograph source: CDC–Beijing Medical University collaborative project.

Key findings in omphalocele (see Fig. 48):

1. **Location** – the defect is central (not lateral) and the organs herniate through a dilated umbilical ring.
2. **Covering** – organs are covered or contained by a membrane (not skin) and the umbilical cord inserts into the distal part of the sac. The membrane can be **thin and translucent** (panel a) or more **opaque and nearly fibrous** (panel b) due to in utero exposure to amniotic fluid. Note also that the **membrane may be ruptured** in utero or during birth (panel c).

Note: **Be sure not to confuse this condition with gastroschisis.** In gastroschisis the abdominal defect is lateral to the umbilical cord and herniated organs are never covered by membrane (see Fig. 49).

Diagnosis

Prenatal. Always confirm the diagnosis postnatally – prenatal diagnosis is possible but is tricky, and misdiagnoses are not uncommon. Use programme rules (SOPs) to decide whether to accept prenatal diagnoses without postnatal confirmation (e.g. in cases of termination of pregnancy or unexamined fetal death).

Postnatal. A careful examination should be able to confirm or exclude the diagnosis. Differentiate from gastroschisis. Some other conditions can be confused with omphalocele but are much rarer and more complex (e.g. limb-body wall spectrum).



Clinical and epidemiologic notes

Omphalocele is frequently (50% of cases or more) associated with other findings:

- ▶ With other unrelated birth defects, particularly cardiac, urogenital, brain, spina bifida.
- ▶ With certain complex anomaly patterns (OEIS [**o**mphalocele, **c**loacal **e**xstrophy, **i**mperforate anus, **s**pinal defects]).
- ▶ With some genetic syndromes, including trisomies 13 and 18, and Beckwith-Wiedemann syndrome.

Additional clinical tips:

- ▶ Always look for additional internal anomalies and syndromes.
- ▶ Note the size of the omphalocele – the bigger the size, the more likely the presence of anomalies and syndromes, the presence of liver in the sac, the complexity of treatment/surgery, and the risk for morbidity, mortality, disability.

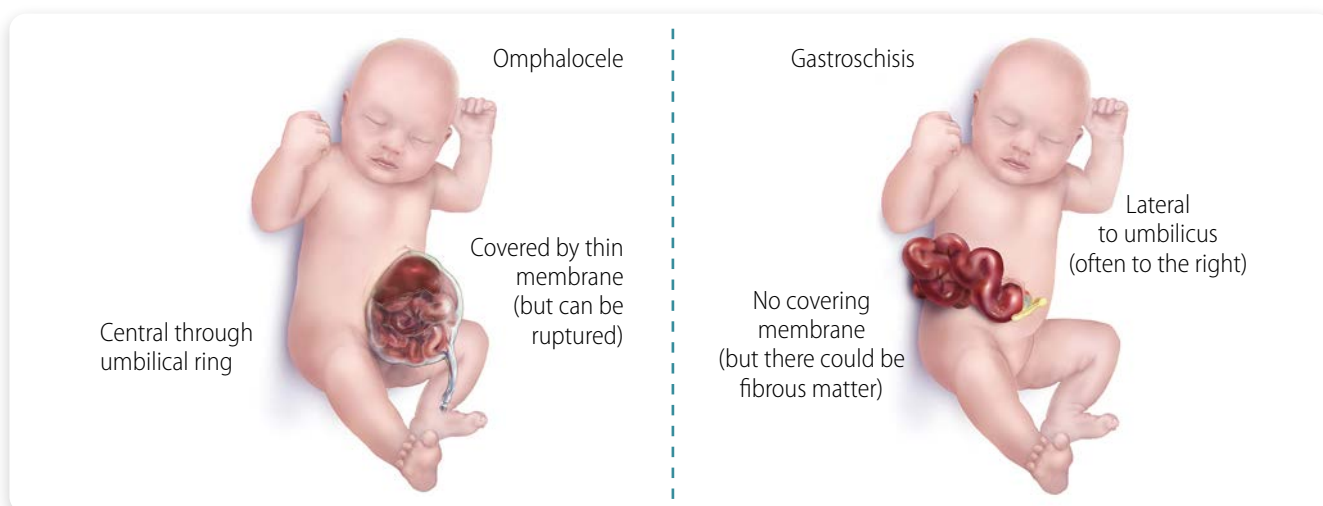
Checklist for high-quality reporting

Omphalocele – Documentation Checklist

- ❑ **Describe in detail:** Avoid just using the term “omphalocele” but add further details:
 - ❑ Cord insertion – describe if midline, over umbilicus.
 - ❑ Covering membranes – yes/no, intact/ruptured.
 - ❑ Size – measure/estimate (in centimetres).
 - ❑ Extruded organs – small intestine, liver, spleen, etc.
- ❑ **Describe evaluations to rule out additional malformations/syndromes:**
 - ❑ Especially trisomies 13 and 18, Beckwith-Wiedemann syndrome.
- ❑ **Take and report photographs:** Show clearly umbilical cord/membrane; can be crucial for review.
- ❑ **Report whether specialty consultation(s) were done** (including genetics, surgery) and if so, report the results.

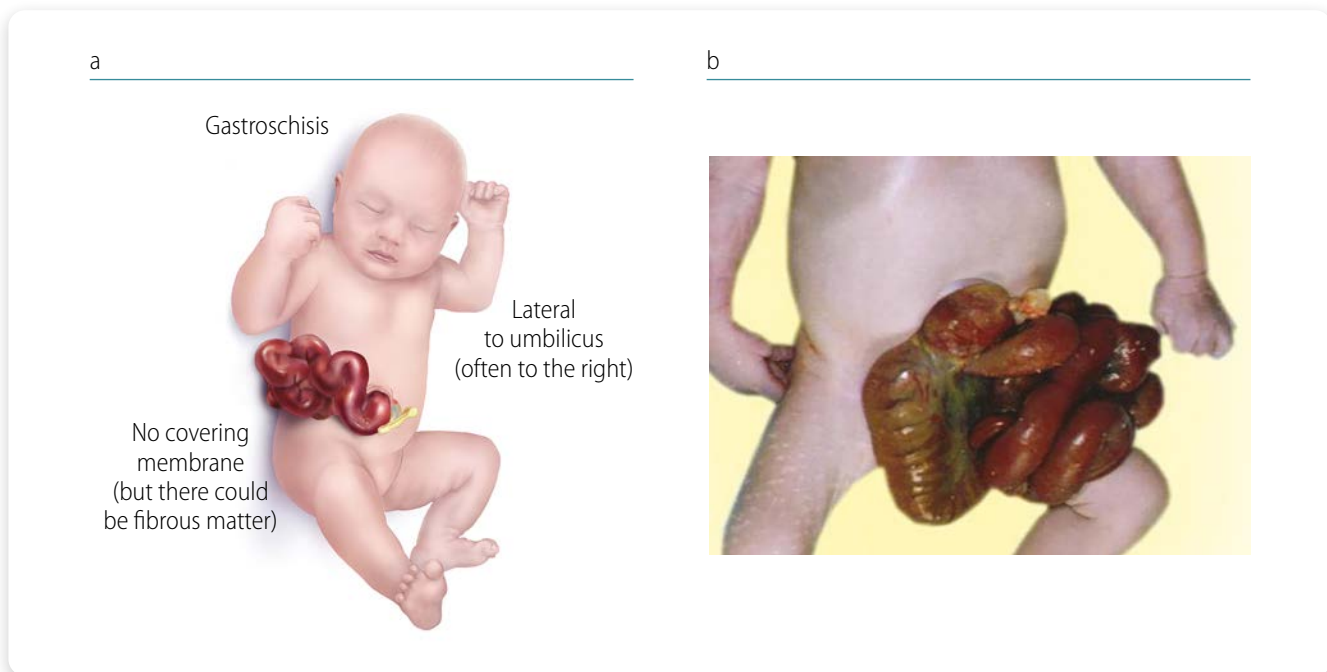
Key visuals

Fig. 49. Distinguishing omphalocele from gastroschisis



Gastroschisis is an abdominal defect, with herniation of gut and possibly liver and other organs.

Fig. 50. Gastroschisis



Photograph source: CDC–Beijing Medical University collaborative project.

Key findings in gastroschisis (see Fig. 50):

1. **Location** – the defect is just to the side of (lateral to) the inserted umbilical cord (and generally to the right).
2. **Covering** – there is **no covering membrane**, and the organs are exposed (at times these can be covered by fibrous material due to in utero exposure to fluids).

Note: **Be sure not to confuse this condition with omphalocele.** In omphalocele, the organs (a) herniate centrally through a widened umbilical ring and (b) are covered by a thin, typically translucent membrane (not skin) that may, however, be ruptured (see Fig. 51 and Table 3).

Diagnosis

Prenatal. Always confirm the diagnosis postnatally – prenatal diagnosis is possible but is tricky, and misdiagnoses are not uncommon. Use programme rules (SOPs) to decide whether to accept prenatal diagnoses without postnatal confirmation (e.g. in cases of termination of pregnancy or unexamined fetal death).

Postnatal. A careful examination should be able to confirm or exclude the diagnosis. Differentiate from omphalocele. Some other conditions can be confused with gastroschisis but are much rarer and more complex (e.g. limb-body wall spectrum).

Clinical and epidemiologic notes

Gastroschisis **is most often an isolated, non-syndromic anomaly.** There can be other anomalies of the gut (which are not considered associated but related), but usually not of other organs. Arthrogyrosis (multiple contractures) can occur in a small fraction of babies with gastroschisis. Diagnostic confusion can arise with omphalocele, which has a much higher proportion of associated anomalies and syndromes.

Useful **clinical tips** for diagnosis:

- ▶ If the child has a syndrome (e.g. trisomy 21 or 18), very probably it is not gastroschisis – review and document.
- ▶ If the child has gastroschisis, look for related anomalies, especially of the gut – intestinal malrotation, small intestinal atresia, microcolon. Assess for pulmonary hypoplasia. These related anomalies can affect survival and long-term function.



Checklist for high-quality reporting

Gastroschisis – Documentation Checklist

- ❑ **Describe in detail.** Avoid using only the term “gastroschisis”; specify the following details:
 - ❑ Side relative to the umbilical cord – right/left.
 - ❑ Covering membranes – yes/no.
 - ❑ Size – extension of the abdominal defect (in centimetres).
 - ❑ Extruded organs – also specify bowel segment involved.
- ❑ **Take and report photographs:** *Show clearly* the umbilical cord; can be crucial for review.
- ❑ **Describe evaluations to find or rule out related and associated anomalies:**
 - ❑ If present, describe these anomalies.
- ❑ **Report whether specialty consultation(s) were done** (particularly surgery) **and if so, report the results.**

Key visuals

Fig. 51. Distinguishing omphalocele from gastroschisis

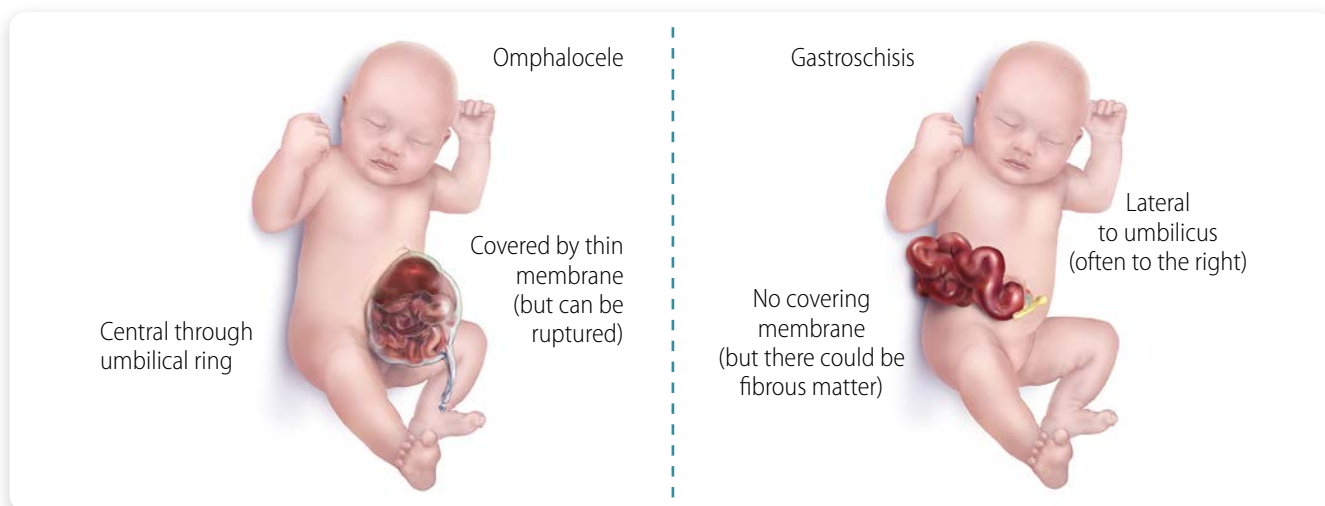
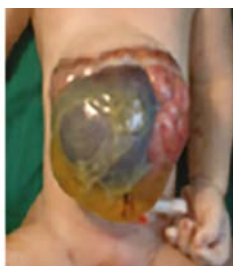
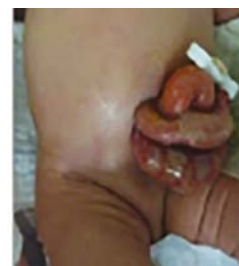
Table 3. Omphalocele versus gastroschisis

	Omphalocele	Gastroschisis
Location	Within umbilical cord (central)	Lateral (R>>L) to intact umbilical cord
Covered by membrane	Yes (but can be ruptured)	Never (but surface can be matted)
Extruded viscera	Gut, +/- stomach, liver, etc.	Gut, occasionally other organs
Associated anomalies	Common (including syndromes)	Rare (syndromes very rare)



Photograph source: ECLAMC.



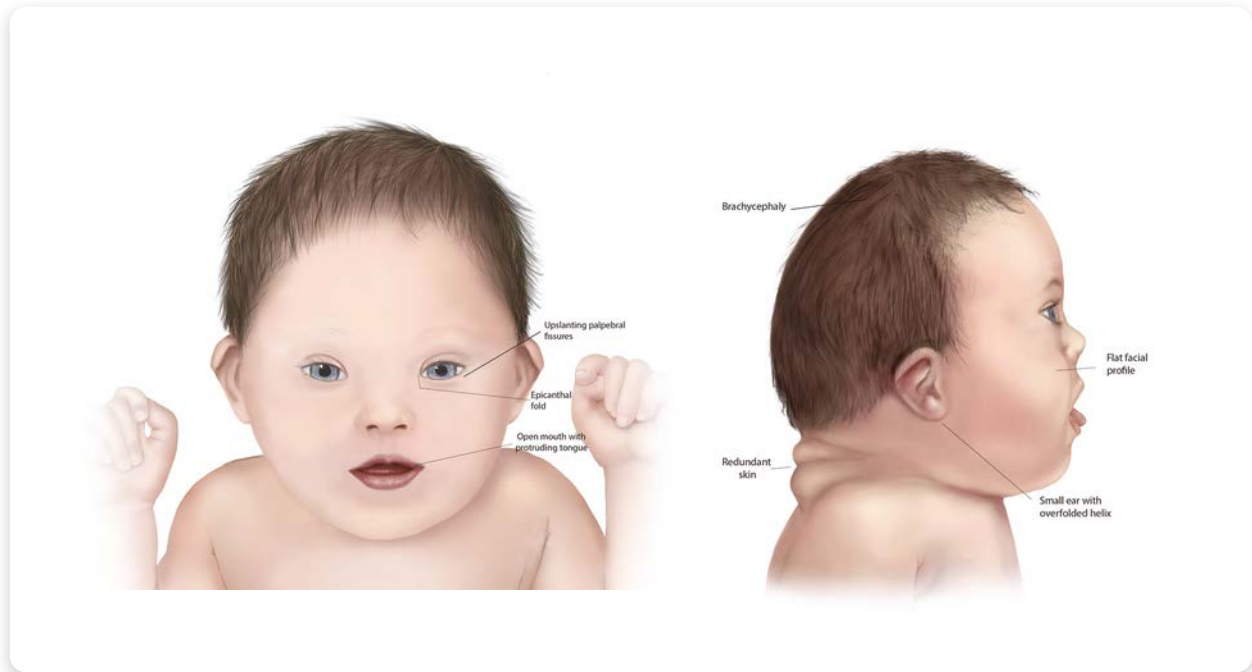
Photograph source: ECLAMC.

CHROMOSOMAL ABNORMALITIES

TRISOMY 21 (DOWN SYNDROME) (Q90.0–Q90.2, Q90.9)

Trisomy 21, also known as Down syndrome, is a condition characterized by a distinctive pattern of minor and major anomalies associated with excess chromosome 21 material.

Fig. 52. Common traits in trisomy 21 (Down syndrome)



Key findings in trisomy 21 (see Fig. 52):

Physical traits – include upslanting palpebral fissures, flat nasal bridge and midface, decreased muscle tone (hypotonia), wider space between first and second toe (“sandal gap”), nystagmus, brachycephaly, incurving of the fifth finger (clinodactyly), narrow palate, overfolded helix of the ear (especially with a small ear), short-appearing neck with redundant skin on the back of the neck, broad and short hands and feet, and single transverse crease in the palm of the hand.

Abnormal karyotype – approximately 95% of cases result from chromosomal non-disjunction of chromosome 21 (47,XX,+21 or 47,XY,+21) at conception. Translocation trisomy 21 (2% of cases) is often familial, and commonly involves chromosomes 14 and 21. Mosaicism occurs in about 2% of cases (post-zygotic non-disjunction or more rarely from trisomic rescue). In 1% of cases, the extra chromosome 21 material originates from other rearrangements.

Diagnosis

Prenatal. Trisomy 21 may be diagnosed through direct analysis of fetal chromosomes, by karyotype or DNA microarray, obtained from amniocentesis, chorionic villus sampling, or percutaneous umbilical blood sampling. Use standard operating procedures to decide whether to accept prenatal diagnoses without postnatal confirmation (e.g. in cases of termination of pregnancy or unexamined fetal death).

Postnatal. Trisomy 21 can be strongly suspected or diagnosed clinically during the neonatal period by recognizing the typical physical traits. Clinical diagnosis should be confirmed by genetic testing (typically, karyotype from infant’s blood or tissue).



Clinical and epidemiologic notes

Major malformations associated with Down syndrome include, among others:

- ▶ heart defects (in about 50%, most notably endocardial cushion defects)
- ▶ gastrointestinal atresias (duodenal or esophageal atresia)
- ▶ vertebral abnormalities.

Infants with Down syndrome can present with many other health and developmental issues, such as:

- ▶ hypothyroidism
- ▶ vision and hearing issues (e.g. cataracts)
- ▶ intellectual disability of varying degree.

Additional clinical tips:

- ▶ For diagnosis, consider physical traits with greatest discriminant diagnostic value.
- ▶ Karyotype is needed for counselling and for estimating recurrence risk (risk in future pregnancies).
- ▶ Look for associated anomalies, in particular, certain subtypes of heart defects, like atrioventricular canal.

Checklist for high-quality reporting

Trisomy 21 – Documentation Checklist

❑ Describe in detail:

- ▶ Clinical signs that allowed the diagnosis.
- ▶ If karyotype available, report results.
- ▶ If karyotype not available, check clinical signs on which diagnosis was based.
- ▶ In all cases, report:
 - Associated malformations.
 - Specialty consultations (including genetic and cardiology) and the results, if applicable.

❑ Take and report photographs: *Show clearly* the side and front views of the face; can be crucial for review.

❑ Describe evaluations to find or rule out related and associated anomalies.

- ▶ General – hypotonia.
- ▶ Head and neck – brachycephaly, large anterior fontanelle, short neck, excess nuchal skin, protruding tongue, narrow palate, flat nasal bridge, upslanting palpebral fissures, epicanthal folds, nystagmus, Brushfield spots on iris, small ears (<3 cm), overfolded helix (ear).
- ▶ Chest – absent breast buds.
- ▶ Extremities – short broad hands, fifth finger clinodactyly, fifth finger single flexion crease, single palmar crease, wide gap between first and second toe.

❑ Document specialty consultations (e.g. genetics, cardiology).

❑ Report whether autopsy (pathology) findings are available and if so, report the results.



CONGENITAL INFECTIOUS SYNDROMES

This quick reference handbook presents common congenital infectious conditions during pregnancy that contribute to the burden of birth defects, stillbirths and neonatal deaths – namely, congenital rubella syndrome (CRS), congenital syphilis, congenital cytomegalovirus (cCMV) infection and congenital Zika syndrome (CZS). Vaccination, prompt detection and treatment, and other preventive strategies can reduce the number of adverse pregnancy outcomes (birth defects, miscarriages, stillbirths and neonatal deaths) resulting from congenital infections. Surveillance can assess the national and international burden of maternal infection and adverse infant outcomes, and formulate strategies to reduce transmission from the mother to the fetus.

For each congenital infection, information on the background of the infectious agent, the clinical manifestations in the mother and the infant, photographs, case definition, and the relevant international classification of codes from the *International Statistical Classification of Diseases and Related Health Problems*, Tenth Revision (ICD-10) that could be used for surveillance are presented. As part of the documentation and improved description of these conditions, each section also includes a checklist of items that need to be done as part of the management of a suspected case with a congenital infectious syndrome.

When infection during pregnancy is clinically suspected, laboratory tests to detect congenital infection might include those for cytomegalovirus (CMV), herpes simplex virus, rubella, HIV, toxoplasmosis, syphilis and Zika virus. Prospective mother–infant linked surveillance coupled with birth defects surveillance can provide a more complete picture of these infections and the outcomes associated with them.

CONGENITAL RUBELLA SYNDROME (CRS)

Background

CRS is the infection of a fetus with rubella virus following the infection of the mother during pregnancy, causing a constellation of malformations. The most critical period to contract CRS is around the time of conception and in early pregnancy (8–10 weeks), when the risk of CRS is as high as 90% or can even result in miscarriage or stillbirth. In cases when the rubella infection occurs after 18 weeks of gestation, the fetus is infected but does not develop CRS.

Main clinical manifestations in the mother

The incubation period of rubella virus infection is 14 days (range, 12–23 days). Clinical symptoms include mild illness with low-grade fever (<39 °C), headache, conjunctivitis and rhinitis. A characteristic feature is post-auricular, occipital and posterior cervical adenopathy (swelling of the lymph nodes), which precedes a red, maculopapular rash by 5–10 days. The rash occurs in 50–80% of rubella-infected persons, begins on the face and neck, and progresses to the lower parts of the body, lasting about three days. In 70% of women, joint pain (arthralgia) also occurs.

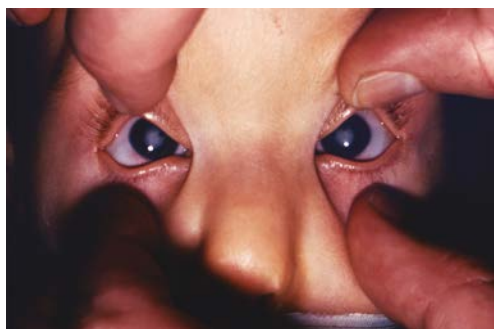Main clinical manifestations in the infant

If primary rubella infection occurs during pregnancy, the virus can infect the placenta and fetus, causing a constellation of specific malformations labelled CRS. The classic triad of clinical manifestations associated with CRS among surviving neonates are hearing impairment; congenital heart defects – in particular, branch pulmonary artery stenosis and patent ductus arteriosus; and eye anomalies such as cataract(s), pigmentary retinopathy (salt and pepper type), chorioretinitis or congenital glaucoma. Additional clinical signs include skin purpura (blueberry muffin skin lesions), splenomegaly (enlargement of the spleen), microcephaly (small head circumference), developmental delay, meningoencephalitis, low birth weight, radiolucent bone disease and jaundice within 24 hours after birth (see Fig. 53). The periconception period and early pregnancy (8–10 weeks) are the most vulnerable time frames and pose the greatest risk of CRS, which is as high as 90%. CRS can result in fetal death. For infants with CRS, hearing impairment, eye symptoms and developmental delay might not be detected until later.

If maternal rubella infection is diagnosed beyond 18 weeks of gestation, the fetus might be infected but does not typically develop signs and symptoms of CRS. Infants with laboratory evidence of rubella and without any signs or symptoms of CRS are classified as having congenital rubella infection (CRI) only.

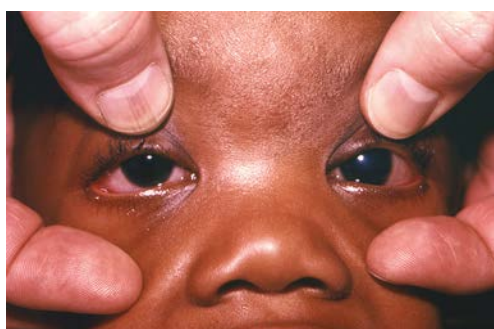

Fig.53. Clinical findings in the infant



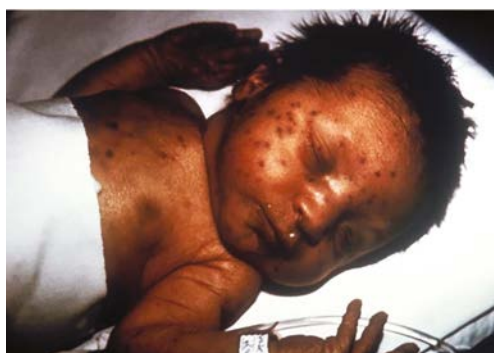Infant with typical cloudiness of the eye lenses; that is, **cataracts**, in a case of CRS.

Photograph source: CDC public health image library/Dr Andre J. Lebrum



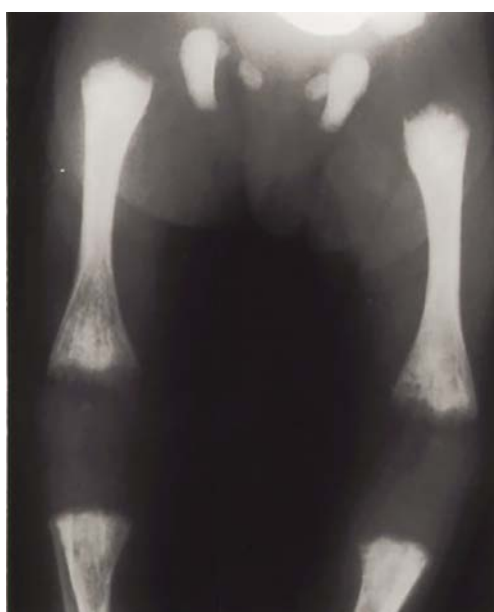Congenital glaucoma (and cataract) in a seven-month-old infant with CRS. The left eye displays a congenital cataract; the right eye is normal. The infant was operated on day 3 of life to correct the congenital cataract.

Photograph source: CDC public health image library/Dr Andre J. Lebrum.



Infant with congenital rubella and **"blueberry muffin" skin lesions**. Lesions are sites of extramedullary hematopoiesis and can be associated with several different congenital viral infections and hematologic diseases.

Photograph source: CDC public health image library/Dr Andre J. Lebrum.



Radiolucent bone disease. X-ray of the lower limbs in a newborn with CRS. The ends of the long bones are ragged and streaky (like celery stalks) – changes due to active rubella infection.

Photograph source: Government of Canada web page (Public health/ Rubella).



Relevant ICD-10 codes

- P35.0 Congenital rubella syndrome (CRS)
- Q02 Microcephaly
- Q12.0 Congenital cataract
- Q15.0 Congenital glaucoma
- Q25.0 Patent ductus arteriosus
- Q25.6 Stenosis of pulmonary artery

Checklist

Checklist
<ul style="list-style-type: none"><input type="checkbox"/> Examine the neonate for:<ul style="list-style-type: none"><input type="checkbox"/> Eye: Glaucoma, cataracts, chorioretinitis or pigmentary retinopathy (salt and pepper) and the sclera for jaundice<input type="checkbox"/> Skin: Jaundice that begins within 24 hours after birth and purpura<input type="checkbox"/> Abdomen: Splenomegaly<input type="checkbox"/> Cardiac: Murmur<input type="checkbox"/> Neurological system: Developmental delay, meningoencephalitis.<input type="checkbox"/> Additional clinical examinations:<ul style="list-style-type: none"><input type="checkbox"/> Skeletal radiograph: Radiolucent bone disease<input type="checkbox"/> Hearing screening test: Hearing impairment (failed hearing screening must be followed with diagnostic testing to verify hearing loss)<input type="checkbox"/> Echocardiography: CHD.<input type="checkbox"/> Inquire about maternal medical health and pregnancy history to ascertain rubella infection and vaccination status. Lack of a history of known infection should not preclude suspicion of CRS.<input type="checkbox"/> Collect neonatal samples for laboratory testing (immunoglobulin M [IgM] and G [IgG]).<input type="checkbox"/> Determine whether the case is suspected, clinically confirmed, laboratory-confirmed, CRI, or excluded.<input type="checkbox"/> Obtain photographs of any malformations noted.

CONGENITAL SYPHILIS

Background

Syphilis is caused by the bacterium *Treponema pallidum*. The infection is most commonly transmitted through sexual contact (vaginal, oral, or anal sex). Birth defects can occur in infants born to women who are infected with syphilis prior to or during pregnancy.

Main clinical manifestations in the mother

In primary syphilis, a sore or multiple sores appear at the site where the bacterium entered the body – typically near the genitals, the rectum, or the oral cavity. The sores are usually firm, round and painless. In secondary syphilis, fever, swollen lymph nodes and skin rash, and wart-like genital lesions (condyloma lata) can be seen. In latent stage, there are no signs or symptoms. In tertiary syphilis, several medical problems affecting the heart, neurologic system and other organs can be seen. Individuals with the infection move from one stage to the next in the absence of treatment.

Main clinical manifestations in the infant

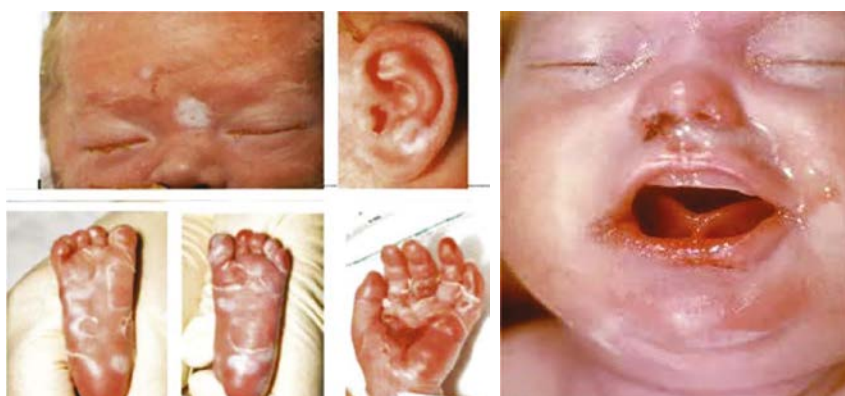Some infants with early congenital syphilis are asymptomatic at birth. Clinical manifestations of early congenital syphilis might include rhinitis (“snuffles”), hepatosplenomegaly, skin rash with desquamation, chorioretinitis and pigmentary chorioretinopathy (salt and pepper type), glaucoma, cataracts, interstitial keratitis, optic neuritis, periostitis and cortical demineralization of metaphysis and diaphysis areas of long bones, anaemia



and thrombocytopenia. Some clinical signs consistent with congenital syphilis – such as hydrops and hepatosplenomegaly – might be detected by ultrasound during pregnancy. Infants who remain undiagnosed and untreated can progress to late congenital syphilis, resulting in numerous additional clinical manifestations, including, but not limited to: saddle nose due to destruction of cartilage, frontal bossing due to periostitis, tibial thickening (saber shins), joint swelling (clutton joints), perforation of hard palate, abnormal tooth development (Hutchinson’s teeth, mulberry molars), interstitial keratitis, neurologic deafness and optic atrophy.

Infants might be born without clinical signs of syphilis but go on to develop late-stage manifestations of untreated congenital syphilis that include developmental delay, neurologic manifestations and late congenital syphilis physical signs.

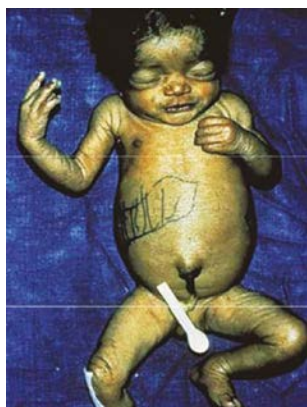Fig. 54. Clinical findings in the infant



Typical desquamating and maculopapular skin lesions; punched out, pale, blistered lesions mainly on ears and nasal bridge, and desquamation of feet and palm.

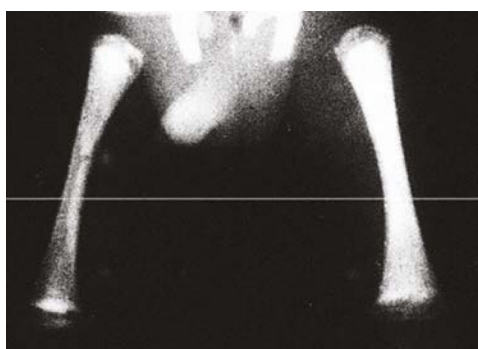Rhinitis with mucopurulent nasal discharge.

Photograph source: Dr Ronald Ballard.



Hepatosplenomegaly and jaundice in an infant with congenital syphilis. Black markings on infant indicate liver margins.

Photograph source: Dr Ronald Ballard.



X-ray of bone abnormalities, syphilitic metaphysitis in an infant with diminished density in the ends of the shaft and destruction at the proximal end of the tibia (right).

Photograph source: Dr Ronald Ballard.

Relevant ICD-10 codes

- A50.9 Congenital syphilis, unspecified
- Q12.0 Congenital cataract
- Q15.0 Congenital glaucoma



Checklist

Checklist

- ❑ Examine the neonate for:
 - ❑ Face: Rhinitis (snuffles) with mucopurulent nasal discharge
 - ❑ Skin: Jaundice, rash and desquamation
 - ❑ Abdomen: Hepatosplenomegaly (enlarged liver and spleen)
 - ❑ Eye: Chorioretinitis and pigmentary chorioretinopathy (salt and pepper type), glaucoma, cataracts, interstitial keratitis, optic neuritis.
- ❑ Additional clinical examinations:
 - ❑ Radiographs: Osteochondritis, diaphyseal osteomyelitis, periostitis.
 - ❑ Hearing test: Hearing impairment (failed hearing screening must be followed with diagnostic testing to verify hearing loss).
- ❑ Obtain maternal medical health and pregnancy history for syphilis diagnosis.
- ❑ Collect maternal and neonatal blood samples for laboratory testing (maternal titres rapid plasma reagin [RPR] and venereal disease research laboratory [VDRL], neonatal blood count and thrombocytopenia).
- ❑ As indicated, test cerebrospinal fluid (CSF) for reactivity for VDRL test, or elevated CSF cell count or protein.
- ❑ Use darkfield microscopy or fluorescent antibody detection to detect *Treponema pallidum* in relevant tissue samples.
- ❑ Obtain photographs of the congenital anomalies noted.

CONGENITAL CYTOMEGALOVIRUS (cCMV)

Background

Cytomegalovirus (CMV) is a very common herpesviridae virus. Most people will be infected at some point during their lifetime. CMV is transmitted through close person-to-person contact with infected secretions, including urine, saliva, blood transfusions, semen, cervical secretion and breast milk. Congenital cytomegalovirus infection (cCMV) occurs when the CMV crosses the placenta during pregnancy and infects the fetus. The highest risk of fetal infection is among mothers experiencing a primary infection during the first or second trimester of pregnancy. Women who are immunocompromised – for example, with HIV infection – have higher rates of fetal transmission.

Main clinical manifestations in the mother

CMV infection is very common and in most healthy people presents with mild flu-like symptoms or is asymptomatic (subclinical infection).

Main clinical manifestations in the infant

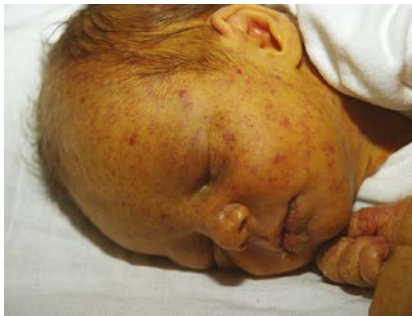Most infants with cCMV will not have signs or symptoms of cCMV disease at birth and will remain well. Infants born with symptoms – which might include growth restriction, ascites/hydrops, hepatosplenomegaly, jaundice, petechiae, hepatitis (raised transaminases or bilirubin), thrombocytopenia, anaemia, microcephaly, seizures, chorioretinitis and sensorineural hearing loss – are at the highest risk of poor neurodevelopmental outcomes. Rarely, infants with cCMV have severe microcephaly that is characterized by marked reduction in cranial vault height with overlapping sutures and redundant scalp with rugae or folds. This presentation is indistinguishable from CZS by physical examination alone. Long-term sequelae: While the majority of infants born with cCMV will not have any long-term sequelae, 10–20% will go on to have neurodevelopmental disabilities, including sensorineural hearing loss, epilepsy, cerebral palsy, visual impairment and learning difficulties. CMV is the most common infectious cause of sensorineural hearing loss and neurodevelopmental abnormalities in high-income settings, and is likely more common, but under-identified, in low-resource settings. cCMV is a known cause of stillbirth and neonatal death.

Relevant ICD-10 codes

P35.1 Congenital cytomegalovirus infection (CMV)

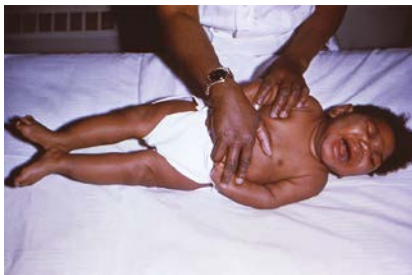

Fig. 55. Clinical findings in the infant



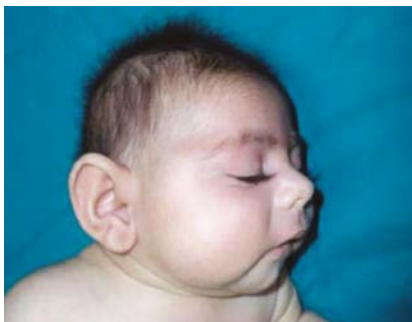Petechial rash (blueberry muffin rash) and jaundice in infant with cCMV.

Photograph source: Jacob Johan.



Infant born with cCMV. Note severe microcephaly and lower limb spasticity similar to features of severe congenital Zika infection.

Photograph source: CDC Public Health Image Library.



Microcephaly in an infant with cCMV.

Photograph source: Işıkay S, Yılmaz K Congenital cytomegalovirus infection and finger anomaly. Case Reports. 2013;2013:bcr2013009486.

Checklist

Checklist

- ❑ Examine the neonate for:
 - ❑ Eye: Glaucoma, cataracts, pigmentary retinopathy, chorioretinitis, chorioretinal scars, optic nerve atrophy (and the sclera for jaundice). Later nystagmus, strabismus and cortical visual impairment.
 - ❑ Skin: Jaundice that begins 24 hours after birth and purpura.
 - ❑ Abdomen: Hepatosplenomegaly.
 - ❑ Neurological system: Microcephaly, seizures, hyper/hypotonia, poor suck.
- ❑ Additional clinical examinations:
 - ❑ Blood tests: Complete blood count, liver enzymes, bilirubin.
 - ❑ Imaging: Cranial ultrasound, followed by magnetic resonance imaging (MRI) and computed tomography (CT) scan (might show ventricular calcifications).
 - ❑ Hearing screening test: Hearing impairment (failed hearing screening must be followed with diagnostic testing to verify hearing loss).
- ❑ Obtain maternal medical health and pregnancy history to ascertain CMV exposure, such as HIV status (or other immune-compromising condition); caring for young children.
- ❑ Collect neonatal samples (urine, blood and/or saliva) for laboratory testing within three weeks of life.
- ❑ Obtain photographs of the malformations noted.



CONGENITAL ZIKA SYNDROME (CZS)

Background

Zika virus (ZIKV) is a flavivirus (family Flaviviridae), an RNA virus primarily transmitted by *Aedes* mosquitoes. These mosquitoes generally bite during the day, with peak times in the morning and early evening. These mosquitoes also transmit dengue, chikungunya and yellow fever viruses. Transplacental (vertical) and sexual transmission of the virus have been documented, as well as transmission by blood transfusion. Although Zika virus has been recovered in human milk, transmission through breastfeeding has not been definitively demonstrated.

Main clinical manifestations in the mother

The risk of a pregnant woman acquiring a primary infection is the same as that of other adults. Symptoms of ZIKV infection are generally mild, non-specific and self-limited, lasting two to seven days. Symptoms vary and might include maculopapular rash, low-grade fever, conjunctivitis, muscle and joint pain, arthritis, malaise and headache. However, a large percentage of infections are asymptomatic.

The most concerning feature of ZIKV infection is maternal infection during pregnancy that poses a risk of congenital ZIKV and resultant birth defects in the fetus. ZIKV infection should be suspected based upon symptoms and exposure (residence in or travel to an area with active ZIKV transmission) or sexual contact with a person who has been exposed, with confirmatory laboratory testing whenever possible.

Main clinical manifestations in the infant

Congenital ZIKV infection can lead to a spectrum of birth defects. Severe manifestations can result in a recognized pattern of birth defects known as CZS. Although many of the components of this syndrome – such as cognitive, sensory and motor disabilities – are shared by other congenital infections, there are five features that are rarely seen with other congenital syndromes or are unique to congenital ZIKV infection:

1. severe microcephaly with partially collapsed skull and redundant scalp with rugae (extra skin folds);
2. thin cerebral cortices with subcortical calcifications;
3. macular scarring and focal pigmentary retinal mottling;
4. congenital contractures of major joints (arthrogryposis)*; and
5. marked early hypertonia or spasticity and symptoms of extrapyramidal involvement*.

* Noted in infants with structural brain anomalies only.

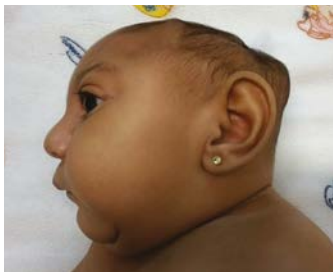Since initial clinical descriptions were published, three additional features that appear to be unique to congenital infection with ZIKV compared with other established TORCH infections include paralysis of the diaphragm, neurogenic bladder and hypertensive hydrocephalus following severe microcephaly.

Other anomalies that are commonly reported with congenital ZIKV infection can be seen with congenital CMV but less so with other congenital infections, including cortical atrophy, corpus callosal agenesis/hypoplasia, cerebellar (or cerebellar vermis) hypoplasia, neuronal migration defects such as gyral anomalies or heterotopia, periventricular calcifications, hydrocephalus ex vacuo, glaucoma, and postnatal-onset microcephaly. Additional anomalies that are common to a number of congenital infections (including CZS) are microcephaly, hydrocephaly/ventriculomegaly/colpocephaly, calcifications of basal ganglia or unspecified regions, hearing loss, porencephaly, hydranencephaly, microphthalmia/anophthalmia, optic nerve hypoplasia, coloboma, and cataracts – these anomalies cannot reliably be used to differentiate among congenital infections.

Primary ZIKV infection during the first and early-second trimesters of pregnancy is more commonly reported in infants with more adverse outcomes. Infection in the third trimester is associated with less severe defects of the brain and eyes. Milder cognitive effects such as learning disabilities have also been reported but are not yet linked to a specific trimester of exposure. Congenital ZIKV infection has been associated with other adverse birth outcomes such as miscarriage, stillbirth and neonatal death.



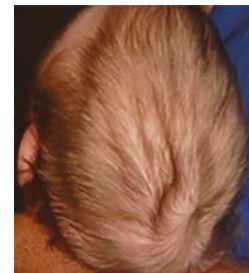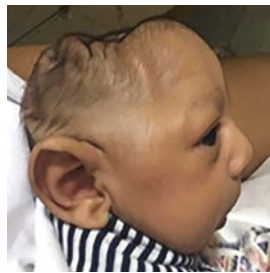Fig.56. Clinical findings in the infant



Lateral views showing collapse of the cranium and extreme reduction in height of the cranial vault.

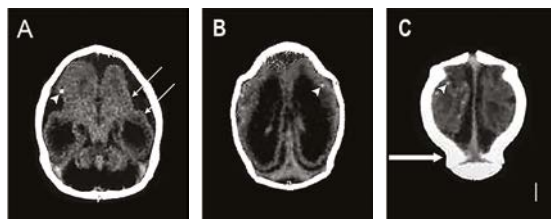
Photograph source: Moore CA, Staples JE, Dobyns WB, Pessoa A, Ventura CV, Fonseca EB, et al. Characterizing the pattern of anomalies in congenital Zika syndrome for pediatric clinicians. *JAMA Pediatr.* 2017;171(3):288–95.

Ritter JM, Martines RB, Zaki SR. Zika virus: pathology from the pandemic. *Arch Pathol Lab Med.* 2017;141(1):49–59.



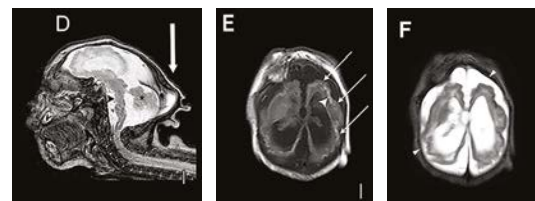
Posterior scalp view showing redundant scalp with folds (rugae).

Photograph source: Moore et al., 2017.



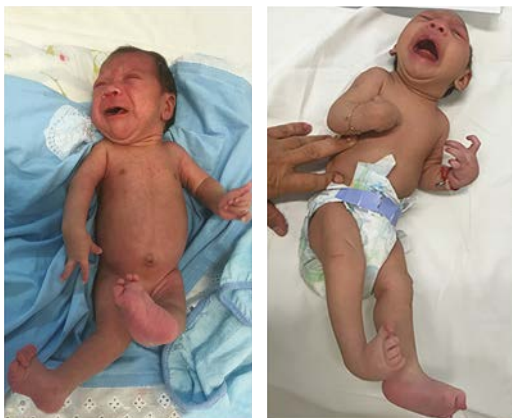Computed tomographic (CT) scan in one infant with prenatal ZIKV exposure shows scattered punctate calcifications (A, B and C; white arrowheads), striking volume loss shown by enlarged extra-axial space and ventriculomegaly (A, B and C), poor gyral development with few and shallow sulci (A; long white arrows). The occipital “shelf” caused by skull collapse (C; white arrow).

Photograph source: Moore et al., 2017.



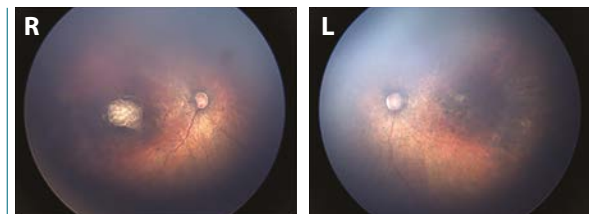
Magnetic resonance imaging (MRI) in infant with prenatal Zika exposure shows scattered punctate calcifications (E; white arrowheads), very low forehead and small cranial vault (D), striking volume loss shown by enlarged extra-axial space and ventriculomegaly (D, E and F), poor gyral development with few and shallow sulci (E; long white arrows), poor gyral development with irregular “beaded” cortex most consistent with polymicrogyria (F; white arrowheads), flattened pons and small cerebellum (D; black arrowhead and asterisk). The occipital “shelf” caused by skull collapse is seen in both infants (D; white arrowhead).

Photograph source: Moore et al., 2017.



Left: Newborn infant with bilateral contractures of the hips and knees, bilateral talipes calcaneovalgus, and anterior dislocation of the knees. *Right:* Newborn infant with bilateral contractures of the shoulders, elbows, wrists, hips, knees, and right talipes equinovarus. Hips are bilaterally dislocated in both infants.

Photograph source: Moore et al., 2017.



Fundus images of right and left eye: Optic nerve hypoplasia with the double-ring sign, gross pigmentary mottling, and chorioretinal scar in the macular region.

Photograph source: Moore et al., 2017.



Relevant ICD-10 codes

P35.8 Other congenital viral diseases

Q02 Microcephaly

Checklist

Checklist

- Examine the neonate for:
 - Severe microcephaly with collapsed skull and redundant scalp.
 - Congenital contractures of major joints (arthrogryposis).
- Hypertonia and spasticity.
- Macular scarring and focal pigmentary retinal mottling (paediatrician or ophthalmologist).
- Additional clinical examinations:
 - Radiographs: Thin cerebral cortices with subcortical calcifications.
 - Hearing assessment: Screening by auditory brain stem response methodology with diagnostic testing to verify hearing loss.
- Obtain maternal medical health and pregnancy history to ascertain ZIKV infection.
- Collect maternal and neonatal samples for diagnostic testing.
- Determine whether the case is suspected, probable or confirmed.
- Obtain photographs of the malformations noted.



For more information, please contact:

**National Center on Birth Defects and Developmental Disabilities
Centers for Disease Control and Prevention**

1600 Clifton Rd, MS-E86, Atlanta, GA 30333, United States of America
www.cdc.gov/ncbddd/birthdefects

International Clearinghouse for Birth Defects Surveillance and Research

International Center on Birth Defects (ICBD)
Rm 2S222 Division of Medical Genetics
University of Utah
295 Chipeta Way, Salt Lake City, Utah, United States of America
Email: icbd@icbd.org
www.icbdsr.org

Department of Maternal, Newborn, Child and Adolescent Health and Ageing

World Health Organization
Avenue Appia 20, 1211 Geneva 27, Switzerland
Email: mncah@who.int
www.who.int
www.who.int/teams/maternal-newborn-child-adolescent-health-and-ageing

9789240015418

