

**STANDARD TREATMENT
GUIDELINES
OTORHINOLARYNGOLOGY
(ENT)**

**Ministry of Health & Family Welfare
Govt. of India**

Contents

S.No.	Topic	Page No.
1	ALLERGIC RHINITIS	4
2	DEVIATED NASAL SEPTUM (DNS)	6
3	EPISTAXIS	9
4	BRANCHIAL CYST	12
5	BRANCHIAL FISTULA	14
6	MOUTH ULCERS	16
7	ACUTE PAROTITIS	17
8	SUBMANDIBULAR SIALADENITIS	19
9	THYROGLOSSAL DUCT CYST AND FISTULA	21
10	ACUTE LARYNGOTRACHEO BRONCHITIS	23
11	ADENOIDITIS	25
12	CHRONIC LARYNGITIS	26
13	BENIGN LESIONS OF LARYNX	28
14	DEEP NECK SPACE INFECTION	29
15	FOREIGN BODY IN AERODIGESTIVE TRACT	31
16	GOITRE	33
17	LARYNGOPHARYNGEAL REFLUX (LPR)	35
18	CARCINOMA ORAL CAVITY	37
19	CARCINOMA HYPOPHARYNX	44
20	CARCINOMA LARYNX	51
21	CERVICAL LYMPHADENOPATHY	64
22	PERITONSILLAR ABSCESS (QUINSY)	68

Group Head Coordinator of Development Team

Dr J M Hans

Ex-HOD

Dept. of Otorhinolaryngology

Dr.RML Hospital

New Delhi

ALLERGIC RHINITIS

WHEN TO SUSPECT/ RECOGNIZE

- A. Definition: Allergic rhinitis is allergic inflammation of nasal airways.
- B. Introduction: When a foreign protein (allergen) is inhaled by a previously sensitized individual, a reaction between the allergen and the antibodies takes place on the nasal mucosa. This inflammatory reaction presents as itching in the nose, sneezing and nose block.
- C. Allergic rhinitis may be seasonal or perennial. Allergic rhinitis is found to co exist with Bronchial asthma, nasal polyps, sinusitis, adenoid hypertrophy, Eustachian tube dysfunction and otitis media.

INCIDENCE IN OUR COUNTRY

- D. No exact data are available in our country.

DIFFERENTIAL DIAGNOSIS

- E. The diagnosis is clinical. The differential diagnosis would include
 1. Vasomotor rhinitis
 2. Hormonal rhinitis in pregnancy, hypothyroidism etc
 3. Nasal block due to deviated nasal septum
 4. Immotile cilia syndrome
 5. Specific rhinitis caused by granulomatous diseases like Wegener's and sarcoidosis.

PREVENTION AND COUNSELLING

- F. Allergic rhinitis can be prevented by environmental control measures and allergen avoidance by reducing outdoor exposure during pollen season. For indoor allergens prevention would include:
 1. Covering mattresses with impermeable covers
 2. Washing of bed linen every two weeks in hot water
 3. Avoidance of exposure to pets

OPTIMAL DIAGNOSTIC CRITERIA, INVESTIGATIONS, TREATMENT & REFERRAL CRITERIA

AT SECONDARY HOSPITAL/ NON METRO SITUATION

- G. **CLINICAL DIAGNOSIS:** the diagnosis is essentially based on history. The basic evaluation should include:
1. Complete ENT examination
 2. Nasal examination for condition of nasal mucosa and polyps if any.
 3. Evaluation of respiratory system to exclude asthma
- H. **INVESTIGATIONS:**
1. complete blood count,
 2. Absolute eosinophil count.
 3. X Ray of paranasal sinuses.
 4. Other investigations based on associated conditions
- I. **TREATMENT:**
1. **OUT PATIENT:**
 1. Nasal decongestants: avil, cetirizine, fexofenadine etc
 2. Nasal Steroid sprays: Fluticasone, Mometasone, Budesonide etc
 3. Oral steroids: for refractory cases and those with asthma.
 2. **DAY CARE:** nil
 3. **INPATIENT:**
 1. Surgical procedures like septoplasty, adenoidectomy with or without grommet insertion, polypectomy may be required.
 2. Management of comorbidities.
- J. **REFERRAL CRITERIA:**
1. Extensive nasal polyposis
 2. Associated complications not manageable in the centre.

AT TERTIARY HOSPITAL/ METRO SITUATION

- K. **CLINICAL DIAGNOSIS:** nasal examination is complemented with nasal endoscopy under local anaesthesia.
- L. **INVESTIGATIONS:**
1. Allergy skin testing
 2. IgE estimation if available
 3. CT Scan of paranasal sinuses
- M. **TREATMENT:** Additional measures which may be required are
1. **OUT PATIENT:** antihistamines, nasal steroid sprays, leukotriene antagonists and oral steroids.
 2. **DAY CARE/ INPATIENT:**
 1. Septoplasty
 2. Endoscopic sinus surgery
 3. management of comorbidities.
- N. **REFERRAL CRITERIA:**
1. In adequate facilities for any of the above.

DEVIATED NASAL SEPTUM (DNS)

WHEN TO SUSPECT/ RECOGNIZE

- O. Definition: Deviated Nasal Septum is deflection of nasal septum from midline.
- P. Introduction: Deviated Nasal Septum (DNS) may be caused by birth trauma, trauma to face during life or due to asymmetric growth of cartilages and bones of nose. They may present with nose block, recurrent nasal discharge, infections of nose and sinuses, bleeding from nose or headaches. In gross DNS, there may be a concomitant deviation of external nose also.

INCIDENCE IN OUR COUNTRY

- Q. Very few people have absolutely straight nasal septum. Most minor DNS are not symptomatic and do not require treatment. Only symptomatic DNS need be mentioned to the patient and treated.

DIFFERENTIAL DIAGNOSIS

- R. The differential diagnosis includes:
 1. Acute or chronic Rhinosinusitis
 2. Nasal Allergy
 3. Large Adenoid mass in children
 4. Foreign Body/ Rhinolith in children
 5. Nasal Polyps
 6. Growths/ Tumors of nose

PREVENTION AND COUNSELLING

- S. DNS cannot be prevented. Minor deviations do not require treatment. Symptomatic DNS can be corrected by surgery through the nostrils under Local or General Anaesthesia. Surgery is usually done after the age of 16 years when the facial growth is complete. Surgery in younger patients may be undertaken if grossly symptomatic and not amenable to medical management for nasal obstruction.
- T. In septoplasty, the deviated portion of the nasal septum is removed. The nose is packed for 1 -2 days to prevent bleeding. Patient is discharged after removal of packs. The nose takes 1 -2 weeks to heal completely.

OPTIMAL DIAGNOSTIC CRITERIA, INVESTIGATIONS, TREATMENT & REFERRAL CRITERIA

AT SECONDARY HOSPITAL/ NON METRO SITUATION

U. CLINICAL DIAGNOSIS: The diagnosis of DNS is made on:

1. History of facial trauma if any
2. Complaints of nasal obstruction, discharge, bleeding or headache
3. Complete ENT examination
4. Nasal examination including anterior rhinoscopy and Cold Spatula Test.
5. Evaluation of extent and site of trauma to face if any

V. INVESTIGATIONS:

1. complete blood count,
2. bleeding and clotting time.
3. X Ray of paranasal sinuses
4. X Ray of nasal bones in trauma.
5. Other investigations based on general clinical condition

W. TREATMENT:

1. **OUT PATIENT:** Associated conditions causing nasal obstruction can be treated medically as out patient with:
 1. Antihistaminics oral or nasal sprays
 2. Monteleukast
 3. Steroid nasal sprays
 4. Antibiotics for nasal and sinus infections
2. **DAY CARE:**
 1. Removal of foreign body or rhinolith from nose.
 2. Anterior nasal packing for bleeding from nose.
 3. Septoplasty surgery may be performed as day care if adequate facility for post op care is available at home.
3. **INPATIENT:**
 1. Septoplasty.
 2. Manangement of comorbidities.

X. REFERRAL CRITERIA:

1. External deformity requiring rhinoplasty
2. Nasal Polyps requiring endoscopic sinus surgery
3. Bleeding not controlled with anterior and posterior nasal packing.
4. Midface fractures would require a maxillofacial consultation.
5. Other co morbidities requiring appropriate cross consultations.

AT TERTIARY HOSPITAL/ METRO SITUATION

Y. CLINICAL DIAGNOSIS: The evaluation should include:

1. Review of general evaluation of clinical condition
2. Complete ENT examination

3. Nasal Endoscopic examination under Local/ General Anaesthesia to identify deviation of septum, sinusitis, polyps, site of bleeding or any growths in nose.
4. Evaluation of extent and site of trauma to face if any

Z. INVESTIGATIONS:

1. complete blood count,
2. bleeding and clotting time.
3. Prothrombin Time/ PTTK/ INR
4. CT Scan of nose and paranasal sinuses

AA. TREATMENT: Additional measures which may be required are

1. OUT PATIENT/ DAY CARE: Endoscopic electro cautery of bleeding point
2. INPATIENT:
 1. Rhinoplasty for external deviation of nose
 2. Endoscopic sinus surgery
 3. Maxillofacial reduction of fracture and wire and plate fixation.
 4. Biopsy and / or excision of tumor if any
 5. Management of comorbidiites.

BB. REFERRAL CRITERIA:

1. In adequate facilities for any of the above.

EPISTAXIS

WHEN TO SUSPECT/ RECOGNIZE

CC. Definition: Epistaxis is bleeding from nose. Blood may flow anteriorly or go posteriorly. It may be clotted or flow from nose .

DD. Introduction: Nose bleeds are common as nose is rich in blood supply and is prominent on the face. Most epistaxis are minor and are managed at home. Only a small percentage comes for medical attention.

INCIDENCE IN OUR COUNTRY

EE. No exact data are available in our country.

DIFFERENTIAL DIAGNOSIS

FF. The diagnosis is clinical. Hence it has no differential diagnosis. The various common causes of epistaxis may be local or systemic.

GG. Local causes

1. Low humidity: as in dry climate in summers and winters
2. Infection- Rhinitis, sinusitis
3. Trauma: Injury to nose by direct trauma or by nose picking.
4. Surgery: Septoplasty or endoscopic sinus surgery

HH. Systemic causes:

1. Hypertension
2. Blood thinning drugs like aspirin, clopidogrel, warfarin
3. Benign growths like Angiofibroma and Rhinosporidiosis
4. Cancers like Sinonasal cancers and Carcinoma of nasopharynx

PREVENTION AND COUNSELLING

II. Epistaxis can be prevented by keeping the nasal mucosa moist in dry climates by douching with water, applying creams and nasal sprays

JJ. Most epistaxis are mild and can be dealt effectively at home. The soft parts of nose are pinched tightly for 10-20 minutes. The head is bent forward and kept above the level of heart. Any blood flowing in to throat should be spit into a bowl. Ice can be applied locally. After the epistaxis is controlled, patient is advised not to blow nose, keep the nasal mucosa moist and blood pressure under control.

OPTIMAL DIAGNOSTIC CRITERIA, INVESTIGATIONS, TREATMENT & REFERRAL CRITERIA

AT SECONDARY HOSPITAL/ NON METRO SITUATION

KK. CLINICAL DIAGNOSIS: When the epistaxis is not controlled with local pressure for over 20 min, expert medical care is required. The basic evaluation should include:

1. Pulse, BP monitoring,
2. General evaluation of clinical condition
3. Complete ENT examination
4. Nasal examination to identify cause and site of bleeding.
5. Evaluation of extent and site of trauma to face if any

LL. INVESTIGATIONS:

1. complete blood count,
2. bleeding and clotting time.
3. X Ray of paranasal sinuses and nasal bones in trauma.
4. Other investigations based on general clinical condition

MM. TREATMENT:

1. **OUT PATIENT:** General condition of the patient is stabilized.
2. **DAY CARE:**
 1. If the site of bleeding is identified, chemical or electro cautery is done to stop the bleeding.
 2. If not, then anterior nasal packing is done with ribbon gauze soaked in liquid paraffin and antibiotic solution, gelfoam or hemostatic sponge. The packs are kept in place for two to three days.
3. **INPATIENT:**
 1. If the bleeding still continues, a posterior nasal packing with gauze or Foley's catheter may be done.
 2. Management of comorbidities.

NN. REFERRAL CRITERIA:

1. Massive blood loss
2. Bleeding not controlled with anterior and posterior nasal packing.
3. Midface fractures would require a maxillofacial consultation.
4. Other comorbidities requiring appropriate cross consultations.

AT TERTIARY HOSPITAL/ METRO SITUATION

OO. CLINICAL DIAGNOSIS: When the epistaxis is not controlled with anterior and posterior nasal packing, the evaluation should include:

1. Review of general evaluation of clinical condition
2. Complete ENT examination
3. Nasal Endoscopic examination under Local/ General Anaesthesia to identify cause and site of bleeding.
4. Evaluation of extent and site of trauma to face if any

PP. INVESTIGATIONS:

1. complete blood count,
2. bleeding and clotting time.
3. Prothrombin Time/ PTTK/ INR
4. Contrast enhanced CT Scan of paranasal sinuses
5. MR Angiography
6. Digital subtraction angiography (DSA) of carotid and vertebral artery system

QQ. TREATMENT: Additional measures which may be required are

1. OUT PATIENT/ DAY CARE: Endoscopic electro cautery
2. INPATIENT:
 1. Septoplasty
 2. Maxillofacial reduction of fracture and wire and plate fixation.
 3. External carotid artery ligation
 4. DSA embolisation of bleeding vessel
 5. Biopsy and / or excision of tumor if any
 6. Management of comorbidiites.

RR. REFERRAL CRITERIA:

1. In adequate facilities for any of the above.

BRANCHIAL CYST

Introduction: Branchial cleft cysts are congenital epithelial cysts, which arise on the lateral part of the neck from a failure of obliteration of the second branchial cleft in embryonic development. Phylogenetically, the branchial apparatus is related to gill slits. (*Branchia* is Greek for gills).

Definition: At the fourth week of embryonic life, the development of 4 branchial (or pharyngeal) clefts results in 5 ridges known as the branchial (or pharyngeal) arches, which contribute to the formation of various structures of the head, the neck, and the thorax. The second arch grows caudally and, ultimately, covers the third and fourth arches. The buried clefts become ectoderm-lined cavities, which normally involute around week 7 of development. If a portion of the cleft fails to involute completely, the entrapped remnant forms an epithelium-lined cyst with or without a sinus tract to the overlying skin.

Incidence in India: Unknown. Branchial cleft cysts are the most common congenital cause of a neck mass. An estimated 2-3% of cases are bilateral. A tendency exists for cases to cluster in families.

Differential diagnosis:

1. Lymphadenopathy (reactive, neoplastic, lymphoma, metastasis)
2. Vascular neoplasms and malformations
3. Capillary hemangioma
4. Carotid body tumor
5. Lymphatic malformation (cystic hygroma)
6. Ectopic thyroid tissue
7. Ectopic salivary tissue

Prevention and Counseling: NA

Optimal Diagnostic Criteria, Investigations, Treatment & Referral Criteria

Clinical Diagnosis: Diagnosis is usually made clinically. Many branchial cleft cysts are asymptomatic. Depending on the size and the anatomical extension of the mass, local symptoms, such as neck swelling, dysphagia, dysphonia, dyspnea, and stridor may occur.

A branchial cyst commonly presents as a solitary, painless mass in the neck of a child or a young adult. A history of intermittent swelling and tenderness of the lesion during upper

respiratory tract infection may exist. Discharge may be reported if the lesion is associated with a sinus tract.

Branchial cysts are smooth, non-tender, fluctuant, translucent masses, which occur along the lower one third of the antero-medial border of the sternocleidomastoid muscle between the muscle and the overlying skin.

Secondary branchial cleft cyst lesion: The lesion may be tender if secondarily inflamed or infected. When associated with a sinus tract, mucoid or purulent discharge onto the skin or into the pharynx may be present.

Investigations:

1. Fine-needle aspiration may be helpful to distinguish branchial cleft cysts from malignant neck masses. Fine-needle aspiration and culture may help guide antibiotic therapy for infected cysts.
2. A sinogram may be obtained. If a sinus tract exists, radio-opaque dye can be injected to delineate the course and to examine the size of the cyst.
3. Ultrasonography helps to delineate the cystic nature of these lesions.
4. A contrast-enhanced CT scan shows a cystic and enhancing mass in the neck. It may aid preoperative planning and identify compromise of local structures.
5. MRI allows for finer resolution during preoperative planning. The wall may be enhancing on gadolinium scans.

Treatment: Surgical excision is definitive treatment for branchial cleft cysts. A series of horizontal incisions, known as a stair step or stepladder incision, is made to fully dissect out the occasionally tortuous path of the branchial cleft cysts

Standard Operating Procedure: As in patient surgery should be performed

Referral Criteria: depends upon competency of operating surgeon and available resources.

BRANCHIAL FISTULA

Introduction: Branchial fistulas are uncommon anomalies of embryonic development of branchial apparatus. Second branchial arch and pouch anomalies are common anomalies of branchial apparatus.

Definition: During embryonic development, the second arch grows caudally; envelop the third, fourth and sixth arches and form the cervical sinus by fusing with the skin caudal to these arches. The edges of cervical sinus fuse and the ectoderm within the fused tube disappears. Persistence of ectoderm gives rise to branchial cyst.

The branchial fistula results from the breakdown of the endoderm, usually in the second pouch. A persistent fistula of the second branchial cleft and pouch pass from the external opening in the mid or lower neck in the line of the anterior border of the sternocleidomastoid muscle, deep to platysma along the carotid sheath, then pass medially deep between the internal and external carotid arteries after crossing over the glossopharyngeal nerve and hypoglossal nerve. Finally, it opens internally in the tonsillar fossa usually on the anterior face of the upper half of the posterior pillar of the fauces or in the intratonsillar cleft.

Most of the times it is a simple sinus opening that extend up the neck for a variable distance. Complete branchial fistula with internal opening into tonsillar region is rare.

Incidence in India: Unknown. Although branchial fistulas may occur in any age group, commonly patients present to clinician in first and second decades of life.

Differential diagnosis: sinus from an infected lymph node

Prevention and Counseling: NA

Optimal Diagnostic Criteria, Investigations, Treatment & Referral Criteria

Clinical Diagnosis:

1. History - Diagnosis is usually made clinically. Patient complains of mucopurulent discharge from an opening in lower lateral part of neck.
2. Examination – A small punctum in the skin at the junction of upper two third and lower one third of anterior border of sternocleidomastoid muscle.

Investigations:

The tract of fistula can be diagnosed by a dye test or fistulogram and sometimes negative preoperative test might become positive under general anaesthesia because of muscle

relaxation. Occasionally the fistula tract may be blocked by thick secretions or granulation tissue.

Treatment: Surgical excision

Standard Operating Procedure: As in patient surgery should be performed

Referral Criteria: depends upon competency of operating surgeon and available resources.

MOUTH ULCERS

Mouth ulcers are sores or open lesions in the mouth.

Causes, incidence, and risk factors

Mouth ulcers are caused by many disorders. These include:

SS. Canker sores

TT. Gingivostomatitis

UU. Herpes simplex

VV. Leukoplakia

WW. Oral cancer

XX. Oral lichen planus

YY. Oral thrush

The skin lesion of histoplasmosis may also appear as a mouth ulcer.

Canker sores are more common in young adults than in children or older adults.

Symptoms

1. Open sores in the mouth
2. Pain or discomfort in the mouth

The appearance and exact location of lesions varies with the specific disorder.

Signs and tests

A health care provider or dentist usually diagnoses the type of mouth ulcer, based on its appearance and location. Blood tests or a biopsy of the ulcer may be needed to confirm the cause.

Treatment

The goal of treatment is to relieve symptoms. The cause, if known, should be treated. Gentle, thorough oral hygiene may relieve some of the symptoms. Topical (rubbed on) antihistamines, antacids, corticosteroids, or other soothing preparations may be recommended for applying directly to the ulcer. Avoid hot or spicy foods, which often increase the pain of mouth ulcers.

ACUTE PAROTITIS

Parotitis is an inflammation of one or both parotid glands, the major salivary glands located on either side of the face, in humans. The parotid gland is the salivary gland most commonly affected by inflammation.

CAUSES :

Infectious parotitis

Acute bacterial parotitis:

Parotitis as Extrapulmonary Tuberculosis:

Acute viral parotitis (mumps):

HIV parotitis:

Autoimmune causes

These are also collectively known as chronic punctate parotitis or chronic autoimmune parotitis.

Sjögren's syndrome:

Mikulicz disease:

Lymphoepithelial lesion of Godwin:

Blockage

Blockage of the main parotid duct, or one of its branches, is often a primary cause of acute parotitis, with further inflammation secondary to bacterial superinfection. The blockage may be from a salivary stone, a mucous plug, or, more rarely, by a tumor, usually benign.

Chronic nonspecific parotitis:

Recurrent parotitis of childhood

Sialadenosis (sialosis):

Sarcoidosis:

Pneumoparotitis:

Symptoms

- ZZ. Abnormal tastes, foul tastes
- AAA. Decreased ability to open the mouth
- BBB. Dry mouth
- CCC. Fever
- DDD. Mouth or facial pain, especially when eating
- EEE. Redness over the side of the face or the upper neck
- FFF. Swelling of the face (particularly in front of the ears, below the jaw, or on the floor of the mouth)

Signs and tests

An examination by the health care provider or dentist shows enlarged salivary glands. Pus may drain into the mouth. The gland may be painful, particularly with bacterial infections. Viral infections such as mumps may cause painless swelling of the glands. A CT scan or ultrasound may be done if the doctor suspects an abscess.

Treatment

In some cases, no treatment is necessary.

If there is pus or a fever, or if the infection is known or thought to be bacterial, antibiotics may be prescribed. Antibiotics are not effective against viral infections.

If there is an abscess, surgical drainage or aspiration may be done.

Good oral hygiene, with thorough tooth brushing and flossing at least twice per day, may aid healing and help prevent an infection from spreading. If you are a smoker, stop smoking as it helps in recovery.

Warm salt water rinses (1/2 teaspoon of salt in one cup of water) may be soothing and keep the mouth moist.

Drink lots of water and use sugar-free lemon drops to increase the flow of saliva and reduce swelling. Massaging the gland with heat may help.

SUBMANDIBULAR SIALADENITIS

INTRODUCTION:

The submandibular gland, along with the parotid and sublingual glands, comprise the major salivary glands. The minor salivary glands are scattered along the upper aerodigestive tract, including the lips, mucosa of the oral cavity, pharynx, and hard palate.

The submandibular gland is the second largest (approximate weight, 10 g) of the major salivary glands (the parotid gland is the largest). Anatomically, it is situated in the submandibular triangle of the neck.

DEFINITION:

Sialadenitis of the submandibular gland is a relatively commonly encountered yet infrequently discussed topic. Causes range from simple infection to autoimmune etiologies.

Causes

- G.G.G. Acute sialadenitis
- H.H.H. Chronic sialadenitis
- I.I.I. Sialolithiasis
- J.J.J. Autoimmune sialadenitis
- K.K.K. Sialadenosis

Differential Diagnoses

The differential diagnosis of submandibular sialadenitis and sialadenosis includes the following:

1. Infectious (acute) cause - Bacterial or viral disease
2. Inflammatory cause - Sialolithiasis, radiation-induced disease
3. Autoimmune cause - Sjögren disease, lupus
4. Granulomatous cause - Tuberculosis, tularemia, sarcoidosis, catscratch disease, actinomycosis
5. Drug-related cause - Thiourea
6. Neoplastic (benign) cause - Pleomorphic/monomorphic adenoma, oncocytoma, ductal papilloma, hemangioma, foreign body, ranula, lymphoepithelial cyst
7. Neoplastic (malignant) cause - Adenoid cystic carcinoma, mucoepidermoid carcinoma, adenocarcinoma, undifferentiated carcinoma, malignant oncocytoma, squamous cell carcinoma
8. Endocrine cause - Hypothyroidism, diabetes mellitus
9. Metabolic cause - Vitamin deficiency, cirrhosis, obesity, bulimia, malabsorption

INVESTIGATIONS

1. Ultrasonography
2. Sialography
3. Computed tomography scanning
4. Magnetic resonance imaging
5. Fine-needle aspiration and biopsy

TREATMENT :

One management scheme is as follows:

1. Acute sialadenitis

1. Medical management - Hydration, antibiotics (oral versus parenteral), warm compresses and massage, sialogogues
 2. Surgical management - Consideration of incision and drainage versus excision of the gland in cases refractory to antibiotics, incision and drainage with abscess formation, gland excision in cases of recurrent acute sialadenitis
2. Salivary calculi
1. Medical management - Hydration, compression and massage, antibiotics for the infected gland
 2. Surgical management - Duct cannulation with stone removal, gland excision in recurrent cases

THYROGLOSSAL DUCT CYST AND FISTULA

Introduction: Thyroglossal duct cyst is a rare but occasional cause of a benign midline neck mass.

Definition: The cyst is usually located at the midline of the neck. Thyroglossal duct cysts result from the dilatation of a remnant tract at the site where the primitive thyroid descended from its origin at the base of the tongue to its permanent location, low in the neck. Failure of subsequent closure and obliteration of this tract predisposes to thyroglossal cyst formation.

It most often occurs before age 20, but may be found in the older population as well. It is more common in males. The thyroglossal duct cyst may rupture spontaneously and present as a draining sinus, which has been erroneously called a thyroglossal fistula, although communication with foramen caecum (true fistula) is extremely rare.

Incidence in India: Unknown

Differential diagnosis:

- Dermoid Cyst
- Lipoma
- Lymph Node
- Minor Salivary Gland Tumour
- Sebaceous Cyst
- Hypertrophied Pyramidal Lobe

Prevention and Counseling: NA

Optimal Diagnostic Criteria, Investigations, Treatment & Referral Criteria

Clinical Diagnosis: Diagnosis is usually made clinically. Thyroglossal duct cysts most often present with a palpable asymptomatic midline neck mass at or below the level of the hyoid bone. The neck mass moves with swallowing and on protrusion of tongue. Some patients will have neck or throat pain, or dysphagia (difficulty in swallowing).

Investigations:

1. Fine needle aspiration cytology
2. Ultrasound, thyroid function tests to ensure normal thyroid gland
3. Radionuclide scanning if normal thyroid not located

Treatment: Excision (Sistrunks operation). The intimate association of the tract with hyoid bone mandates simultaneous removal of the central portion of the hyoid bone to ensure complete removal of the tract.

Standard Operating Procedure: As In patient the surgery should be performed

Referral Criteria: depends upon competency of operating surgeon and available resources

ACUTE LARYNGOTRACHEO BRONCHITIS

Introduction:

Acute laryngotracheo bronchitis or Croup is most of the times a viral infection caused by parainfluenza type 1 and 2 virus in children between 6months to 3years of age. Secondary bacterial infection by gram positive cocci may occur.

Definition:

It is an inflammatory condition of the larynx, trachea and bronchi.

Differetial diagnosis:

It has to be differentiated from acute epiglottitis.

Acute epiglottitisAcutelaryngotracheobronchitis

H.influenza type b	Parainfluenza type 1 and 2
2-7years of age	3months to 3years
Supra glottis involved	subglottic area
No prodromal symptoms	prodromal symptoms present
Sudden onset	slow onset
High grade fever	low grade or no fever
Cough absent	present barking seal like cough
Stridor present	present
Odynophagia present	absent
Thumb sign on lateral view	steeple sign- anteroposterior view

Clinical diagnosis:

Hoarseness of voice, croupy cough, fever, inspiratory stridor, suprasternal, intercostal recession. Steeple sign on anteroposterior radiograph of neck. Examination of larynx is avoided, it may precipitate complete obstruction.

Investigations:

Complete blood count, serum electrolytes, radiograph of neck and chest.

Treatment:

Intravenous antibiotics, humidification, parenteral fluids, steroids to relieve oedema, racemic adrenaline via respirator, intubation/tracheostomy if respiratory obstruction increases despite of medical management. Tracheostomy if intubation is required beyond 72 hours.

ADENOIDITIS

Introduction:

The nasopharyngeal tonsils, commonly called “adenoids” are situated at the junction of roof and posterior wall of the nasopharynx. Adenoid tissue is present at birth, shows physiological enlargement upto the age of six years, and then tends to atrophy at puberty and almost completely disappears by the age of 20.

Definition:

Adenoiditis is the infection of the adenoids. Enlarged and infected adenoids may cause nasal obstruction, mouth breathing, nasal discharge, sinusitis, epistaxis, change of voice, Eustachian tube blockage leading to conductive hearing loss, recurrent attacks of acute otitis media, serous otitis media, typical facial appearance known as adenoid facies, pulmonary hypertension in long standing cases.

Differential Diagnosis:

1. congenital
2. infection- bacterial, viral
3. allergy
4. malignancy- adenoid cystic carcinoma
5. nasopharyngeal angiofibroma
6. causes of nasal obstruction

Clinical Diagnosis:

History, general examination, local examination with posterior rhinoscopy mirror, flexible or rigid nasopharyngoscope, lateral radiograph nasopharynx.

Investigations:

Complete blood count, blood grouping, prothombin time, bleeding time, clotting time, serum electrolytes, renal and liver function tests, xray chest and nasopharynx, electrocardiogram.

Treatment:

When symptoms are not marked breathing exercises, decongestant nasal drops and antihistaminics. When symptoms are marked adenoidectomy is done.

Adenoidectomy is the standard operating procedure. Done under general anesthesia with oral intubation. Boyle davis mouth gag is inserted, adenoids palpated digitally and removed with the help of adenoid curette with and without guard. Hemostasis is achieved by packing the area for sometime.

CHRONIC LARYNGITIS

LLL. Chronic Laryngitis Without Hyperplasia

It is a diffuse inflammatory condition symmetrically involving the whole larynx, i.e. true cords, ventricular bands, and root of the epiglottis.

Aetiology

1. It may follow incompletely resolved acute simple laryngitis or its recurrent attacks.
2. Presence of chronic infection in paranasal sinuses, teeth and tonsils.
3. Occupational factors, e.g. exposure to dust and fumes such as in miners, stokers, gold or iron smiths and workers in chemical industries.
4. Smoking and alcohol.
5. Persistent trauma of cough as in chronic lung disease.
6. Vocal abuse.

Clinical Features

1. Hoarseness. This is the commonest complaint.
2. Constant hawking. There is dryness and intermittent tickling in the throat and patient is compelled to clear the throat repeatedly.
3. Discomfort in the throat.
4. Cough. It is dry and irritating.

Treatment

1. Eliminate infection of upper or lower respiratory tract. Infection in the sinuses, tonsils, teeth or chronic chest infection should be treated.
2. Avoidance of irritating factors, e.g. smoking, alcohol or polluted environment.
3. Voice rest and speech therapy. Voice rest has to be prolonged for weeks or months.
4. Steam inhalations. They help to loosen secretions and give relief.
5. Expectorants. They help to loosen viscid secretions and give relief from hawking.

MMM. Chronic Hypertrophic laryngitis

It may be either a diffuse and symmetrical process or a localised one, the latter appearing like a tumour of the larynx.

Aetiology

Same as discussed under chronic laryngitis without Hyperplasia.

Pathology

Pathological changes starts in the glottis region and later may extend to ventricular bands base of epiglottis and even subglottis .

Initially there is hyperaemia ,oedema and cellular infiltration in the submucosa. The mucous glands suffer hypertrophy at first but later undergo atrophy with diminished secretion and dryness of larynx.

Clinical features

This disease mostly affects males (8:1) in the age group of 30-50 years.

Hoarseness, constant desire to clear the throat, dry cough and discomfort in throat when the voice has been used for an extended period of time, are the common presenting symptoms.

Examination:

On examination, changes are often diffuse and symmetrical.

1. Laryngeal mucosa, in general, is dusky red and thickened.
2. Vocal cords appear red and swollen.
3. Ventricular bands appear red and swollen and may be mistaken for prolapsed or eversion of the ventricle.
4. Mobility of cords gets impaired due to oedema and infiltration, and later due to muscular atrophy or arthritis of the cricoarytenoid joint.

Treatment

Conservative: Same as for chronic laryngitis without hyperplasia.

Surgical: Stripping of vocal cords, removing the hyperplastic and oedematous mucosa, may be done in selected cases. Damage to underlying vocal ligament should be carefully avoided. One cord is operated at a time.

BENIGN LESIONS OF LARYNX

TYPES

- NNN. Solid lesions
 1. Vocal nodule
 2. Vocal polyp
 3. Reinke's oedema
 4. Contact ulcer
 5. Intubation granuloma
 6. Leukoplakia or keratosis
- OOO. Cystic lesions

Vocal cord nodule

Vocal cord nodule is a mass of tissue that grows on the vocal folds (vocal cords). Typically this mass will appear on the junction of the anterior and middle two-thirds of the vocal fold, where contact is most forceful.

Vocal cord polyp

A polyp is usually a red or reddish lesion that has a sharp margin and is clearly different from surrounding tissue. It can be either broad-based or narrow-necked. It may be smooth and round, or it may have lobes. Some polyps that have been present for a long time can take on odd shapes. There is a lot of variability in size. Polyps may occur singly or in pairs, one on each vocal fold directly opposite one another. Almost always, they occur at the midpoint of the vocal fold.

Reinke's edema

Reinke's edema, also known as polypoid degeneration, is the swelling of the vocal folds due to fluid collection (edema).

Granuloma

A granuloma is a benign growth that results from irritation or trauma. It is usually found at the back of the vocal fold, over a part of cartilage called the vocal process which lies just underneath the membrane covering the larynx.

Contact Ulcer

Contact granuloma, also known as a **contact ulcer**, is a condition where an ulcer is found in the vocal fold. The most common cause of the condition is sustained periods of increased pressure on the vocal folds, and is commonly seen in people who use their voice excessively. Gastroesophageal reflux disease is also thought to be a contributing factor in the development of contact ulcers.

Treatment :

5. Voice rest,
6. To remove the source of the irritant (e.g. smoking cessation, vocal rest, etc.).
7. Microlaryngoscopic surgery

DEEP NECK SPACE INFECTION

INTRODUCTION

Deep neck space infections most commonly arise from a septic focus of the mandibular teeth, tonsils, parotid gland, deep cervical lymph nodes, middle ear, or sinuses. These deep cervical space infections have become relatively uncommon in the postantibiotic era. Consequently, many clinicians are unfamiliar with these conditions. In addition, with widespread use of antibiotics and/or profound immunosuppression, the classic manifestations of these infections, such as high fever, systemic toxicity, and local signs of erythema, edema, and fluctuance, may be absent.

Deep neck space infections often have a rapid onset and can progress to life-threatening complications. Thus, clinicians must be aware of such infections and should not underestimate their potential extent or severity.

SPACES:

Submandibular space

Parapharyngeal space

Retropharyngeal space

Prevertebral space

Peritonsillar space

Parotid space

Potential routes of spread — The deep cervical fascial spaces are normally bound together by loose connective tissue and intercommunicate to varied degrees. A thorough understanding of the potential anatomic routes of infection not only provides valuable information on the nature and extent of infection but also suggests the optimal surgical approach for effective drainage.

CLINICAL FEATURES

- A. Peritonsillar, parotid, parapharyngeal, and submandibular abscesses are generally associated with sore throat and trismus (the inability to open the jaw). Trismus indicates

pressure or infection of the muscles of mastication (the masseter and the pterygoids) or involvement of the motor branch of the trigeminal nerve. Findings on physical examination include swelling of the face and neck, erythema, and purulent oral discharge. There may be pooling of saliva in the mouth and asymmetry of the oropharynx. Lymphadenopathy is usually present.

- B. Dysphagia and odynophagia are secondary to inflammation of the cricoarytenoid joints.
- C. Dysphonia and hoarseness are late findings in neck infections and may indicate involvement of the tenth cranial nerve
- D. Unilateral tongue palsy indicates involvement of the twelfth cranial nerve.
- E. Stridor and dyspnea signify airway obstruction and may be manifestations of local pressure or spread of infection to the mediastinum.

INVESTIGATION

IMAGING

Computed tomography (CT) is the imaging modality of choice for the diagnosis of deep neck space infections . CT allows the critical evaluation of soft tissues and especially bone from a single exposure. In addition, the axial imaging format of CT is particularly well suited to the head and neck. Because CT can localize a process and define its extent, particularly extension into the mediastinum or the cranial vault, it is also an invaluable tool for planning and guiding aspiration for culture or open drainage.

Magnetic resonance imaging (MRI) is useful for assessing the extent of soft tissue involvement and for delineating vascular complications. However, MRI takes significantly longer than CT to obtain good quality images, which may cause discomfort or claustrophobia. In addition, individuals with certain implanted devices cannot undergo MRI.

Plain radiography is of limited utility for the evaluation of deep neck space infections; it is sometimes helpful for detecting retropharyngeal swelling or epiglottitis

TREATMENT — Appropriate antibiotics in conjunction with surgical drainage of loculated infection are essential for a successful outcome of deep neck space infections

FOREIGN BODY IN AERODIGESTIVE TRACT

Introduction:

Foreign body aspirated into air passage can lodge in the larynx, trachea or bronchi. Children below 4 years are more often affected. Non irritating foreign bodies like plastic, glass or metals may remain symptomless for a long time. Irritating foreign bodies(vegetative) like peanuts, beans, seeds, etc gives a diffuse violent reaction leading to congestion and oedema of tracheobronchial mucosa-vegetal bronchitis

Symptoms:

Choking, gaging, wheezing: lasts for short time. Foreign body can be cuffed out or it may lodge in arynx or tracheobronchial tree.

Symptomless interval

Later symptoms depend on site of its lodgement:

→Laryngeal: Large foreign body complete can lead to sudden death

Partial: pain, harseness, croupy cough,aphonia, dyspnoea, wheezing and hemopptysis.

→Traheal: loose- palpatory thud, audible slap

→Bronchial:Right>le. Can lead to atelectasis or check valve

Diagnosis:

Xray

Fluoroscopy

CT scan

Bronchograms

D/D

Acute laryngotraheo bronchitis

Acute Simple laryngitis

Laryngismus Striduluz

Management:

Antibiotics

Steroids

Laryngeal Foreign Body:

In complete obstruction Pound on back, turn patient upside down, follow Heimlich's Manoeuvre (stand behind the person, and place your arms around his lower chest and give four abdominal thrusts)

If this fails: Cricothyrotomy or emergency tracheostomy

Once acute respiratory emergency is over: Direct laryngoscopy/ laryngofissure

Tracheal/Bronchial Foreign bodies:

- Conventional rigid Bronchoscope
- Rigid Bronchoscope with telescopic aid
- Bronchoscopy with C arm fluoroscopy
- Dormia Basket/ Fogarty Balloon
- Thoracotomy and bronchotomy for peripheral foreign bodies
- Flexible Fibre optic bronchoscopy

GOITRE

A goiter or goitre (Latin gutteria, struma), is a swelling in the thyroid gland which can lead to a swelling of the neck or larynx (voice box). Goitre rarely occurs when the thyroid gland is functioning properly. Worldwide, over 90% cases of goitre are caused by iodine deficiency.

Classification :

They can be classified in several ways by morphology, appearance, cause and other characteristics.

- PPP. Non-Toxic:
 1. Simple (struma diffuse)
 2. Multinodular (struma nodosa)
 3. Uninodular (struma uninodosa)
- QQQ. Toxic:
 1. Diffuse (Graves)
 2. Toxic multinodular
 3. Toxic nodule
- RRR. Special:
 1. Cancer
 2. Thyroiditides
 3. Inflammatory
- SSS. Various causes:
 1. Chronic infection
 2. Actinomycosis
 3. Amyloidosis

Other type of classification:

1. Class I - palpation struma - in normal posture of the head, it cannot be seen; it is only found by palpation.
2. Class II - the struma is palpative and can be easily seen.
3. Class III - the struma is very large and is retrosternal; pressure results in compression marks.

Causes :

Worldwide, the most common cause for goiter is iodine deficiency. Selenium deficiency is also considered a contributing factor. In countries that use iodized salt, Hashimoto's thyroiditis is the most common cause.

Further causes include

1. thyroid autonomy
2. autoimmune conditions of the thyroid (Hashimoto thyroiditis, Morbus Basedow)
3. medications and substances such as lithium, antithyroid agents, thiocyanate
4. inflammations (thyroiditis)
5. cysts

6. benign and malignant neoplasms
7. pituitary problems
8. acromegaly
9. thyroid hormone insensitivity
10. sarcoidosis, amyloidosis
11. hydatiform mole

Signs and symptoms :

Goiter associated with hypothyroidism or hyperthyroidism may present with symptoms of the underlying disorder although the symptoms are often unspecific and hard to diagnose.

Goiter not associated with hormonal abnormalities will not cause any symptoms aside from the presence of anterior neck mass. However, for particularly large masses, compression of the local structures may result in difficulty in breathing or swallowing. In those presenting with these symptoms, malignancy must be considered.

Toxic goiters will present with symptoms of thyrotoxicosis such as palpitations, hyperactivity, weight loss despite increased appetite, and heat intolerance.

Treatment :

Goiter caused by suspected iodine deficiency is very frequently treated by a combination of levothyroxine and iodine supplementation depending on thyroid hormone levels.

Treatment may not be necessary if the goiter is small. Goiter may be related to hyper- and hypothyroidism (especially Graves' disease) and may be reversed by treatment. Graves' disease can be corrected with antithyroid drugs (such as propylthiouracil and methimazole), thyroidectomy (surgical removal of the thyroid gland), and iodine-131 (¹³¹I - a radioactive isotope of iodine that is absorbed by the thyroid gland and destroys it). Hypothyroidism may raise the risk of goiter because it usually increases the production of TRH and TSH. Levothyroxine, used to treat hypothyroidism, can also be used in euthyroid patients for the treatment of goitre. Levothyroxine suppressive therapy decreases the production of TRH and TSH and may reduce goiter, thyroid nodules, and thyroid cancer. Blood tests are needed to ensure that TSH is still in range and the patient has not become subclinically hyperthyroid. If TSH levels are not carefully monitored and allowed to remain far below the lower limits of normal (below 0.1 mIU/L or IU/mL), there is epidemiologic evidence that levothyroxine may increase the risk of osteoporosis and both hip and spinal fractures.^[4] (Such low levels are therefore not intentionally produced for long periods, except occasionally in the treatment of TSH-dependent thyroid cancers.)

Thyroidectomy with ¹³¹I may be necessary in euthyroid goitrous patients who do not respond to levothyroxine treatment, especially if the patients have difficulty breathing or swallowing. ¹³¹I, with or without the pre-injection of synthetic TSH, can relieve obstruction and reduce the size of the goitre by thirty to sixty-five percent. Depending on how large the goitre is and how much of the thyroid gland must be removed or destroyed, thyroidectomy and/or ¹³¹I treatment may destroy enough thyroid tissue as to produce hypothyroidism, requiring life-long treatment with thyroid hormone pills.

LARYNGOPHARYNGEAL REFLUX (LPR)

INTRODUCTION ;

Laryngopharyngeal reflux (LPR), also extraesophageal reflux disease (EERD) refers to retrograde flow of gastric contents to the upper aero-digestive tract, which causes a variety of symptoms, such as cough, hoarseness, and asthma, among others.

Although heartburn is a primary symptom among people with gastroesophageal reflux disease (GERD), heartburn is present in fewer than 50% of the patients with LPR. Other terms used to describe this condition include atypical reflux, and supraesophageal (or supra-esophageal) reflux.

Signs and symptoms :

Extraesophageal symptoms are the result of exposure of the upper aerodigestive tract to the gastric juice. This causes a variety of symptoms, including hoarseness, postnasal drip, sore throat, difficulty swallowing, indigestion, wheezing, chronic cough, globus pharyngis and chronic throat-clearing.

Diagnosis :

As there are multiple potential etiologies for the respiratory and laryngeal symptoms, establishing LPR as the cause based on symptoms alone is unreliable. Further laryngoscopic findings such as erythema, edema, laryngeal granulomas, and interarytenoid hypertrophy have been used to establish the diagnosis; but these findings are very nonspecific, and have been described in the majority of asymptomatic subjects undergoing laryngoscopy. Response to acid-suppression therapy has been suggested as a diagnostic tool for confirming diagnosis of LPR, but studies have shown that the response to empirical trials of such therapy (as with proton-pump inhibitors) in these patients is often disappointing.

Treatment :

Management of symptoms for patients within this subgroup of the GERD spectrum is difficult. Several studies have emphasized the importance of measuring proximal esophageal, or, ideally, pharyngeal acid exposure in patients with clinical symptoms of LPR, to document reflux as the cause of the symptoms. Once these patients are identified, Nissen fundoplication should be offered to the patients in the early phase of disease, as medical treatments often don't provide any benefit, and a delay in referring patients for surgical treatment is associated with poor outcome

ACUTE PHARYNGITIS

INTRODUCTION : It is acute inflammation of pharynx.

AETIOLOGY:

VIRAL:

- TTT. Rhinovirus
- UUU. Influenza
- VVV. Parainfluenza
- WWW. Measles
- XXX. Chickenpox
- YYY. Herpes simplex

BACTERIAL

1. Streptococcus
2. Diphtheria
3. Gonococcus

FUNGAL

1. Candida albicans

CLINICAL FEATURES

1. Mild pharyngitis : Discomfort in throat ,malaise,low grade fever
2. Moderate to severe : Pain in throat ,malaise,dysphagia,headache,high fever,pharynx show erythema,exudates,enlargement of tonsils and lymphoid follicles on the posterior pharyngeal wall
3. Very severe : Oedema of soft palate and uvula with enlargement of cervical nodes

DIAGNOSIS

1. Culture of throat swab is helpful in the diagnosis of bacterial pharyngitis.It can detect 90% of group A Streptococci.Diphtheria is cultured on special media.Swab from a suspected case of gonococcal pharyngitis should be cultured immediately without delay.

TREATMENT

1. General measures : Bed rest ,plenty of fluids,warm saline gargles or pharyngeal irrigations and analgesics form the mainstay of treatment.
2. Specific treatment :
3. Streptococcal pharyngitis treated with penicillin G
4. Diphtheria is treated with penicillin and erythromycin
5. Gonococcal treated with tetracycline
6. Fungal pharyngitis : Nystatin is the drug of choice

THE VIRAL INFECTION CAUSING PHARYNGITIS

Herpangina : It is caused by group A coxsackie virus and mostly affects children. Characteristic features include fever,sore throat and vesicular eruption on the soft palate and pillars. Vesicles are small and surrounded by a zone of erythema.

Infectious mononucleosis : It is caused by Epstein-Barr virus.It affects older children and young adults, and is characterised by fever ,sore throat, exudative pharyngitis,Lymphadenopathy, splenomegaly and hepatitis.

Cytomegalovirus : It most affects immunosuppressed transplant patients.Clinically,it mimics infectious mononucleosis but heterophil antibody test is negative.

Measles and chickenpox : Measles is characterised by the appearance of Koplik's spots on the buccal mucosa opposite the molar teeth.The spots appear 3-4 days before the appearance of rash.

CARCINOMA ORAL CAVITY

Introduction-

Tumours of lips and oral cavity often present a significant problem to the surgeon with regards to early diagnosis and staging, access for resection and reconstruction of both soft tissues and bone. Tumour of lips are now included within the UICC classification for oral cavity tumours.

Surgical Anatomy-

Anatomic Sites and Subsites for Lip and Oral Cavity-

Lip

External upper lip (vermillion border)

External lower lip (vermillion border)

Commissure

Oral Cavity

Buccal mucosa

Mucosa of upper and lower lips

Cheek mucosa

Retromolar areas

Bucco-alveolar sulci, upper and lower (vestibule of mouth)

Upper alveolus and gingiva (upper gum)

Lower alveolus and gingiva (lower gum)

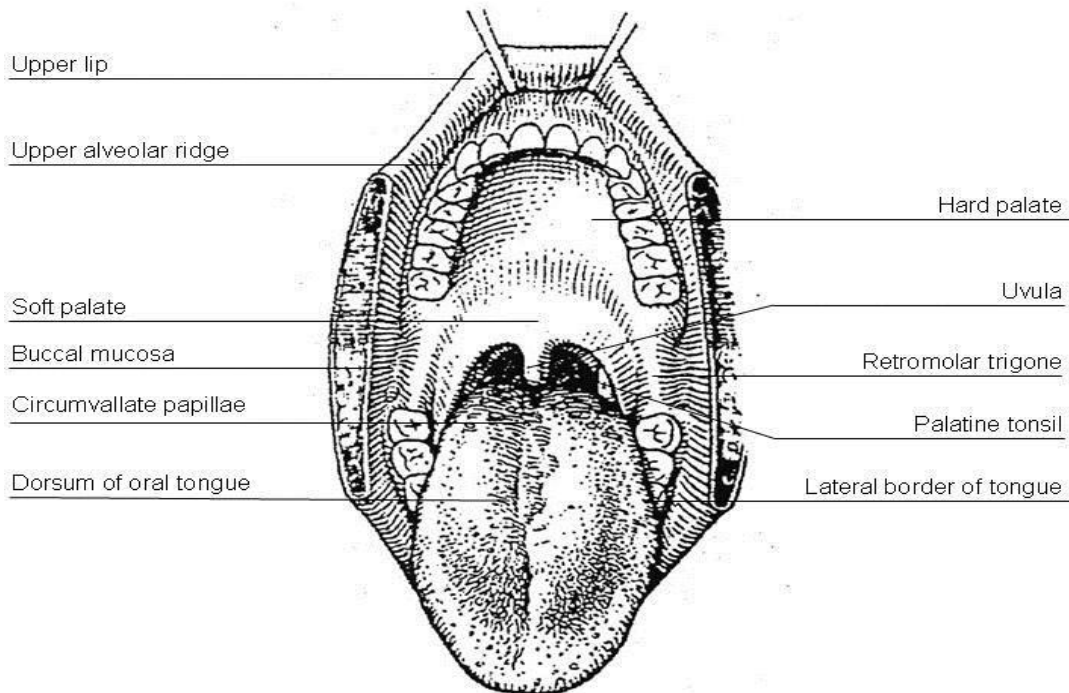
Hard palate

Tongue

Dorsal surface and lateral borders anterior to circumvallate papillae (anterior two thirds)

Inferior (ventral) surface

Floor of mouth



Epidemiology-

The lip is the most common site of cancer in the mouth. It is most common in white people and approximately 93% of the tumour present in the lower lip and the male to female ratio 80:1. The most common tumour is squamous cell carcinoma.

In case of oral cavity cancer an estimated 387500 new cases are diagnosed annually worldwide. It constitutes 30-40% of head and neck cancer in India and the country ranks among the top few in the world in the incidence of these cancers. Buccal mucosa is a common subsite in Indian population, probably aided by the chewing habit that is prevalent in this country. In India, buccal mucosa cancer is the most common cancer in men and third most common cancer

in women. The oral cancers assume importance in the cancer control programme of the country because of its impact on the overall health of the population as well as potential as a target for early detection and prevention

Predisposing Factors-

- ☐ Smoking tobacco is a potential risk factor for oral cancer. An interaction occurs between redox-active metals in saliva and the low reactive free radicals in cigarette smoke. The incidence of oral cavity cancers in persons who smoke is approximately 6 times that of those who do not. It causes sequential histological changes in oral mucosa. Over a prolonged period of exposure, these changes eventually lead to neoplastic transformation.
- ☐ Alcohol consumption- alcohol beverages may contain carcinogens or pro-carcinogens including nitrosamine and urethane contaminants and ethanol. Ethanol is metabolized by alcohol dehydrogenase and to some extent by cytochrome p450 to acetaldehyde, which may be carcinogenic. The combined effect of alcohol and cigarette is synergistic. The risk for a person who smokes and drink is 15 that of an individual who neither habit.
- ☐ Betel nut chewing- it cause damage to buccal mucosa.
- ☐ Dental caries
- ☐ Hot spicy food
- ☐ Chronic glossitis
- ☐ Malnutrition
- ☐ Poor oral hygiene

Precancerous Conditions-

Oral cancer can occur as denovo or on existing pre-malignant conditions. These include-

1. Leucoplakia- this is a clinical term without a definitive histological definition.

Leukoplakia is a white mucosal based keratotic plaque that cannot be wiped free from the underlying tissue. It is defined as white patch in oral mucosa that cannot be characterized clinically or pathologically as any other disease. Most frequent

sites are the buccal mucosa and the commissures. Leukoplakia with epithelial dysplasia (20%) is found to have greater chance of malignant transformation. Only 6% of lesion eventually progressed to SSC. A biopsy is indicated if the lesion is suspicious.

2. Erythroleukoplakia- the associated risk for malignant transformation is greater than leukoplakia.
3. Submucosal fibrosis- most frequently encountered in individuals who chew betel nut, or poor oral hygiene, or periodontitis. The risk of developing oral carcinoma is 7.6% over a 10 year period.
4. Lichen planus- it also been associated with the development of oral carcinoma.

Symptoms of Oral Cancer-

- ☐ White or red patches in your mouth
- ☐ A mouth sore that won't heal
- ☐ Bleeding in mouth
- ☐ Loose teeth
- ☐ Problems or pain with swallowing
- ☐ A lump in neck
- ☐ An earache

Differential Diagnosis-

1. Chronic non-healing ulcer in oral cavity- characteristic findings in favor of malignant ulcer are-
 - Seen in elderly
 - Usually seen at margin and ant 2/3 of tongue
 - Single or multiple
 - Raised, rolled out and everted edge
 - Floor covered with necrotic debris and looks dirty gray
 - Discharge is offensive
 - Painless initially but painful later with Otolgia due to involvement of lingual nerve
 - Associated with lymph node enlargement and it is hard in consistency
2. Pre-malignant conditions like leukoplakia and erythroleukoplakia

TNM Staging-

T1: Tumor 2 cm or less in greatest dimension

T2: Tumor more than 2 cm but not more than 4 cm in greatest dimension

T3: Tumor more than 4 cm in greatest dimension

T4a: Moderately advanced local disease.

Lip: Tumor invades through cortical bone, inferior alveolar nerve, floor of mouth, or skin of face, ie, chin or nose

Oral cavity: Tumor invades adjacent structures only (eg, through cortical bone [mandible, maxilla], into deep [extrinsic] muscle of tongue [genioglossus, hyoglossus, palatoglossus, and styloglossus], maxillary sinus, skin of face)

T4b: Very advanced local disease. Tumor invades masticator space, pterygoid plates, or skull base, and/or encases internal carotid artery

Prognostic Markers-

Various features of the cancer allow to prognosticate the outcome of the treatment.

- ☐ Pathological involvement of cervical node
- ☐ T-stage
- ☐ Tumour thickness- chance of nodal metastasis is maximum with tumour thickness >5mm.
- ☐ Surgical margins- the chance of treatment failure is high when the margin of resection is closed (<5mm) or involve.

Evaluation-

1. History & Examination - Almost 90% of the cancers are of squamous cell variety. Buccal mucosa is the most common site affected in India. The sump area or 'coffin corner' at the posterior tongue/ floor of the mouth is a common site for cancer but may be missed by cursory

inspection. So, a thorough history and physical examination is very important for its early detection.

2. Biopsy can be taken at OPD if lesion is large otherwise it can be taken under GA.
3. Endoscopies can be carried out to rule out other synchronous malignancy.
4. Chest imaging, CT/MRI if indicated.
5. Preanesthesia studies.
6. Dental evaluation.

Treatment protocol-

1. For T1–2, N0 disease
 - a) Excision of primary (preferred) ± unilateral or bilateral selective neck dissection.
 - If it is associated with No adverse features like (extracapsular nodal spread, positive margins, pT3 or pT4 primary, N2 or N3 nodal disease, nodal disease in levels IV or V, perineural invasion, vascular embolism) then only follow up is required.
 - If it is associated with one positive node without adverse feature RT can be given optional. If it is associated Adverse features then planned for Re-excision or Chemo/RT and follow up.
 - b) An alternative to surgery - External-beam RT ± brachytherapy 70 Gy to primary 50 Gy to neck at risk.
 - If pt came with No residual disease then follow up is required.
 - If pt landed with Residual disease then Salvage surgery can be better choice.

2. For T3, N0 disease Excision of primary and reconstruction as indicated and unilateral or bilateral selective neck dissection is the treatment of choice.
 - If it is associated with No adverse features like (extracapsular nodal spread, positive margins, pT3 or pT4 primary, N2 or N3 nodal disease, nodal disease in levels IV or V, perineural invasion, vascular embolism) RT can be given optional.

- If it is associated adverse features then planned for Re-excision or Chemo/RT and follow up.

3. T4a, Any N; T1-3, N1-3 disease Surgery is treatment of choice.

a) For N0, N1, N2a-b, N3 Excision of primary, ipsilateral comprehensive neck dissection ± contralateral selective neck dissection (reconstruction as indicated) can be considered.

b) For N2c (bilateral) disease Excision of primary and bilateral comprehensive neck dissection (reconstruction as indicated) can be planned.

- In both cases if there are No adverse features RTc (optional) can be given and then follow up.

- If it is associated Adverse features (extracapsular nodal spread, positive margins, pT3 or pT4 primary, N2 or N3 nodal disease, nodal disease in levels IV or V, perineural invasion, vascular embolism) then planned for Re-excision or Chemo/RT and follow up.

Treatment Protocol for Pre-Malignant Lesion-

1. Full history and examination.

2. Biopsy

a) Biopsy negative- Discharge

b) Leukoplakia and other pre-malignant lesion- Excision biopsy, Laser etc- Follow up in H & N clinic

c) Other pathology like Lichen planus, candidiasis- Oral medication

d) Biopsy positive- EUA and imaging- Definitive treatment

Preventive Measures-

☑ Don't smoke. Don't drink more than 1 or 2 alcoholic drinks, if any, a day

☑ Sick immediate attention to doctor in chronic non-healing ulcer mouth

☑ Maintain adequate oral/dental hygiene.

CARCINOMA HYPOPHARYNX

Introduction- Hypopharynx is a highly important anatomical site as physiologically it is a component upper aero-digestive tract and it also represents a common conduit for both respiration and deglutition. Hence, any tumor or treatment of tumors in this area will produce disturbances in swallowing and inevitable aspiration. Tumors arising in this area often present in advanced state and so, key to cure lies in early and accurate diagnosis and prompt treatment.

Surgical Anatomy- It is triangular space extending from the level of hyoid bone above to the lower border of cricoid cartilage below. The hypopharynx consists of three regions- pyriform sinus on each side, the posterior pharyngeal wall, and the post cricoid region.

Pyriform sinus (PFS)- It represents channels formed on either side of the larynx. It is bounded by pharyngoepiglottic fold superiorly, the apex inferiorly, thyroid cartilage laterally and hypopharyngeal surface of AE fold medially.

Posterior pharyngeal wall- It extends from floor of ventricle superiorly to inferior border of cricoid cartilage inferiorly and from one apex of PFS to the other.

Post-cricoid region- It extends from at the level of arytenoid cartilage and connecting folds to inferior border of cricoid cartilage.

The hypopharynx is lined throughout by squamous epithelium. The pyriform sinus has rich lymphatic supply. In general, the lymphatic in this area drain in deep cervical lymph node at level IV but inferior part of PFS and post cricoid area also drain in paratracheal lymph node in level VI and posterior pharyngeal wall drain in retropharyngeal area.

Almost all carcinoma of hypopharynx are SSC carcinoma in type. PFS comprise maximum of around 50% of total, postcricoid tumors make up around 40% and posterior pharyngeal wall make up remaining around 10%.

Tumors of PFS can be divided into those which primarily involve the lateral wall or the medial wall. Those arising from medial wall are more extensive and involve AE fold and paraglottic space and can therefore fix the hemilarynx on that side. Occasionally it can involve postcricoid area where vocal cord fixation can occur if cricoarytenoid joint is involved.

As PFS is rich in lymphatic supply, 70-75% patients of pyriform fossa tumor have palpable neck mass at presentation which usually involve level II-IV deep cervical node and 5% have bilateral node at presentation.

Epidemiology- Age specific incidence of pharyngeal cancer show an increase risk of developing disease with increasing age for both men and women. Postcricoid tumors remain the only SSC of head and neck that is more common in women. The overall incidence of tumor in UK is approximately 1-3 per 100000.

Etiological Factors-

Alcohol and tobacco remain the two principal carcinogen implicated in the tumors of the upper aerodigestive tract, to include the hypopharynx and they are synergistic to each other. A major dietary risk factor (iron deficiency) in relation to postcricoid carcinoma has been described particularly in patients with Plummer-Vinson syndrome. This syndrome is associated with anemia, glossitis, esophageal web, koilonychias and achlorhydria. Some also have a history of radiation to the neck.

Symptomatology-

- Dysphagia
- Pain
- Hoarseness
- Neck mass
- Hemoptysis
- Weight loss

The clinical picture caused by a large tumor is often unmistakable, but in the early stages the symptoms may be indefinite. Whilst the feeling of lump in the throat, which is worse on swallowing saliva is rarely of serious significance (e.g globus pharyngicus) or persistent soreness, should always be treated with extreme suspicion, especially in elderly patients who smoke and drink. Persistent pharyngeal pain is nearly always a sinister symptom and if associated with malignancy it reflects deep invasion in larynx and pharyngeal structures. It is often associated with referred pain to ipsilateral ear.

Differential Diagnosis-

1. Globus pharyngicus- It usually presents in young women as a sensation of a lump in throat in midline between hyoid and suprasternal notch but more commonly at cricoid level. It is intermittent and typically occurring between meals, when swallowing saliva, in the evening or during stress and, although uncomfortable but never painful.
2. Pharyngeal oesophageal motility disorder- in patients with throat symptoms who have no abnormality found on examination and investigation and diagnosis can be confirmed by barium video fluoroscopic swallow examination.
3. Benign tumors like Leiomyomas common in hypopharynx and upper oesophagus.
4. Lipomas and fibrolipomas occur occasionally.

TNM CLASSIFICATION-

- | | |
|-----|---|
| T1 | Tumor size \leq 2 cm and limited to one sub-site |
| T2 | Tumor size $>$ 2 but \leq 4 cm or more than one sub-site |
| T3 | Tumor size $>$ 4 cm or hemilarynx fixation |
| T4a | Tumor invades Thyroid / cricoid cartilage, hyoid bone, thyroid gland esophagus, central compartment soft tissue |
| T4b | Prevertebral fascia, mediastinal structures, Internal carotid artery |

Work up-

History and physical examination, Biopsy ,HPV testing suggested, Chest imaging, CT with contrast or MRI or PETCT and CT with contrast of primary and neck, Dental evaluation, including panorex as indicated, Speech & swallowing evaluation as indicated, Examination under anesthesia with endoscopy and Pre-anesthesia studies.

Examination - All patients presenting with a throat complaint or a mass in the neck requires a full head and neck and general examination. Patients can be examined in OPD using either indirect laryngoscopy, a rigid Hopkin's endoscope or FOL passed through the nose. Particular attention should be paid to obvious swelling or ulceration and also to the presence of pooling of saliva in pyriform fossa (Chevalier Jackson's sign) and oedema of arytenoids. Presence or absence of laryngeal crepitus should be look for. Absence of crepitus means any postcricoid or posterior pharyngeal wall involvement.

It is important to carry out any imaging studies prior to endoscopy and biopsy if possible since FNAC; endoscopic and open biopsy can all create artifactual features on both CT and MRI.

Specific Uses of Imaging-

- ❑ To assess the extent of primary tumour, its relation to larynx, and any extension into pre and paraglottic space
- ❑ To exclude a second primary or distant metastases
- ❑ Involvement of cartilage
- ❑ To assess the neck

Barium swallows extremely useful investigation in tumour involving postcricoid and cervical oesophagus.

Treatment Protocol-

1. *T1, N0, selected T2, N0 (not requiring total laryngectomy) disease* -
 - a) Definitive RT can be considered
 - If Primary site: complete response then only follow up is required.

- If pt presented with Primary site: residual tumor then Salvage surgery+ neck dissection as indicated.

b) Alternatively Surgery: Partial laryngopharyngectomy (open or endoscopic) + Ipsilateral or bilateral selective neck dissection is the treatment of choice.

- If there are no adverse features like extracapsular nodal spread, positive margins, pT3 or pT4 primary, N2 or N3 nodal disease, Perineural invasion, vascular embolism only follow up is required.

- With Adverse features Chemo/RT can be consider.

2. *T1, N+; T2-3, any N (if total laryngectomy required) disease –*

a) Induction chemotherapy x 2 cycles and follow-up.

- If Primary site: Complete response then Definitive RT can be considered.

- If patient presents with residual tumor in neck then Neck dissection can be done.

- If primary site: Partial response then planned for Induction Chemotherapy 3rd cycle and follow up.

- If primary site: CR then Definitive RT can be considered.

- Primary site: PR then Chemo/RT and follow up

- If CR: only observation required.

- If Primary site: < PR then planned for Surgery.

- If pt is having no adverse features RT can be considered.

- With any adverse features Chemo/RT can be given.

b) An alternative to induction chemotherapy - surgery Laryngopharyngectomy + selective (N0) or comprehensive (N+) neck dissection, including level VI can be consider.

- Patient with no adverse features only follow-up required

- With adverse features Chemo/RT and follow up required.

c) Third option is CCRT.

- If Primary site: complete response but with Residual tumor in neck then Neck dissection can be consider.
- In case of complete response of neck then Post-treatment evaluation (minimum 12 wks) with PET, Contrast-enhanced CT or MRI and physical exam is required.
- If inv are negative only observation is required. And if inv are positive then Neck dissection is considered.
- If patient presented with Primary site: residual tumor then Salvage surgery + neck dissection as indicated.

3. For T4a, any N disease –

a) Surgery + comprehensive neck dissection (preferred) is treatment of choice followed by RT or Chemo/RT.

b) Or alternatively Induction chemotherapy x 3 cycles and follow-up.

- If patient presented with Primary site: CR or PR and stable disease in neck then consider Chemo/RT.
- If Primary site: complete response but Residual tumor in neck then Neck dissection can be consider.
- If patient presented with Primary site: residual tumor after chemo/RT then Salvage surgery + neck dissection as indicated.
- If pt presented with Primary site: < PR or progression in neck after NACT then Salvage surgery + neck dissection as indicated.

c) Third option is CCRT.

- If patient presented with Primary site: complete response but Residual Tumor in neck then Neck dissection can be considered.
- If pt presented with Primary site: residual tumor Salvage surgery + neck

dissection is indicated.

Prognostic Factors-

- Tumour sizes (less or more than 5 cm)
- Tumour site (PFS and posterior pharyngeal wall tumours do best)
- Vocal cord paralysis
- Presence or absence of lymph node metastases
- Size and number of node involve
- Presence or absence of distant metastases
- Presence of Perineural spread

5 year survival rates in the Liverpool series-

- PFS- 31%
- Postcricoid- 29%
- Posterior pharyngeal wall- 20%

Prevention And Counseling- Abstinence of alcohol and cessation of smoking is first and foremost for prevention.

CARCINOMA LARYNX

Introduction- Larynx is not only important for respiratory function but also for deglutition and phonation. Carcinoma of larynx along with carcinoma of oral cavity is the most common malignancies in head and neck malignancy. It often present early when a high cure rate can be achieved. Treatment remains controversial but early cancer may treat with either surgery or radiotherapy, depending on size, site of tumor and patient and doctor preference. Advanced disease treated with radical surgery and post op radiotherapy.

Surgical Anatomy- The larynx can be embryological, clinically and anatomically divided into Supraglottis, glottis and subglottis.

Supraglottis- the Supraglottis subsites include-

- ❑ Epiglottis- including tip, lingual and laryngeal surfaces
- ❑ AE fold
- ❑ Arytenoids
- ❑ Ventricles
- ❑ False cords

The inferior boundary of Supraglottis as defined by the AJCC is the horizontal plane passing through the apex of the ventricle. The anatomic division is located at the arcuate line, which marks the change from respiratory epithelium to squamous variety.

Glottis- It includes

- ❑ True vocal cords
- ❑ Anterior commissures
- ❑ Posterior commissures

According to AJCC the inferior border of glottis is the horizontal plane 1 cm inferior to level of the upper surface of the vocal cord.

Spread of Tumour- Laryngeal cancer may spread from its original site to other parts of the larynx by direct mucosal and sub mucosal extension, by lymphatic and vascular permeation, by perineural spread or by direct invasion of adjacent structures. These “pathways of spread” have traditionally been the basis of conservation surgical procedures.

Barriers of Tumour Extension-

- Ventricular fold
- Conus elasticus
- Anterior commissure
- Perichondrium

Preferred Pathways for Tumour Extension-

- ❑ Epiglottis fenestrations
- ❑ Anterior commissure ligament
- ❑ Pre/Paraglottic space
- ❑ Cricothyroid/ thyrohyoid membrane

Supraglottis-

Supraglottis tumours have a propensity for bilateral spread and also a high propensity for lymph node metastases. Midline tumors may metastasize bilaterally.

Glottic tumours-

The anterior commissure ligament (Broyle’s ligament) has been traditionally believed to be resistant to tumour spread. However, once involved, it facilitates subglottic and supraglottic spread along the anterior midline as its fibers extends longitudinally.

Lateral extension to paraglottic space has traditionally been assessed by clinical sign of limitation/fixation of vocal fold movement. Currently imaging should be used to supplement this assessment.

Subglottis-

Early extralaryngeal extension through cricothyroid membrane and circumferential involvement usual.

Epidemiology- 1.5 % of all cancers. Glottic: Supraglottic = 3:1. Incidence in UK 4 per 100000. In India its incidence is 10 per 100000. Peak age of incidence 55-65 years of age with male: female= 3-4:1.

Risk Factors-

- ☐ Geographic
- ☐ Social class V
- ☐ Urban
- ☐ Smoking
- ☐ Alcohol
- ☐ Radiation

Etiology-

Until the complex molecular interactions of all associated etiologic agents for any cancer can be understood, these interactions are best thought of as associations. Thinking of intrinsic (eg, genetic) factors and/or extrinsic (eg, smoking) factors as causes is too simple.

To most people, a cause implies a condition that is both necessary and sufficient to produce a pre specified result. Laryngeal carcinomas have multiple associations.

The foremost risk factor for the development of laryngeal cancer is tobacco use. The risk of developing laryngeal cancer with tobacco increases with use and decreases after cessation. When associated with the intake of alcohol, a strong synergistic effect is created. However, whether or not alcohol alone is an independent risk factor is still unclear.

All the potential risk factors for laryngeal cancer that have been studied are as follows:

- ☒ Tobacco use
- ☒ Excessive ethanol use
- ☒ Male sex
- ☒ Infection with human papilloma virus
- ☒ Increasing age
- ☒ Diets low in green leafy vegetables
- ☒ Diets rich in salt preserved meats and dietary fats
- ☒ Metal/plastic workers
- ☒ Exposure to paint
- ☒ Exposure to diesel and gasoline fumes
- ☒ Exposure to asbestos
- ☒ Exposure to radiation
- ☒ Laryngopharyngeal reflux

Pathophysiology-

The larynx is an essential organ that is responsible for the following vital functions:

- ☒ Maintaining an open air way
- ☒ Vocalizing
- ☒ Protecting the lungs from more direct exposure to noxious fumes and gases of unsuitable temperatures
- ☒ Protecting the lungs from aspiration of solids and liquids
- ☒ Allowing leverage, by closing the glottis during a Valsalva maneuver, to increase upper-body strength and to ease solid-waste removal

Malignant tumors of the larynx affect laryngeal physiology depending on tumor location and size. Supraglottic tumors usually cause upper airway obstruction. Conversely, glottic tumors affect initially voice quality. In addition, malignant tumors of the larynx affect swallowing physiology. The mechanism of swallowing is altered when tumors invade and alter the physiology of the swallowing muscles. This is expressed as difficulty swallowing and aspiration.

Liquids and solid food gain access into the trachea. Pathophysiology of malignant tumors of the larynx is at the molecular and histologic level. Histologic progression occurs from normal laryngeal mucosa to dysplastic mucosa to carcinoma in situ to invasive carcinoma. This progression is a multi-step process of accumulated genetic events that lead to the development of larynx tumors.

Presentation-

Given the functions of the larynx mentioned above, one can easily imagine the consequences of a carcinoma destroying and/or obstructing the laryngeal structures and their mechanisms (eg, vocal-cord movement). Symptoms vary with the structures involved by malignancy and its accompanying inflammatory reaction. Although the particular tumor, the site, and the patient's constitution play key roles in any given individual, laryngeal cancers as a whole can cause any of the following findings, alone or in combination:

1. Glottis-
 - a) Hoarseness
 - b) Sore throat
 - c) localized pain(cartilage invasion)
 - d) Dyspnea
 - e) Otagia (involvement of deep structure)
2. Supraglottis-
 - a) Odynophagia
 - b) Sore throat
 - c) Weight loss
 - d) Aspiration
 - e) Tone breath
 - f) Otagia
 - g) Neck mass (either tumour itself or lymph node)
 - h) Lymph node metastases in Supraglottic tumour-

- T1- 0%
- T2- 15%
- T3- 20%
- T4- 30%

3. Subglottis-

- a) Dyspnoea
- b) Hemoptysis

Differential Diagnosis-

1. Chronic laryngitis- present with hoarseness of voice and mimic early glottic cancer specially in older people or should be differentiated from squamous intraepithelial neoplasia like, Keratosis (keratin formation by superficial layer only), parakeratosis (nucleus retained abnormalities in superficial layer), dysplasia (nuclear variation, mitosis, loss of normal epithelial layering), carcinoma in situ (cells of malignant cytology but confined superficial to basement membrane).
2. Benign tumour papillomas- it constitutes 85% of all benign tumour larynx and can be multiple (Juvenile papilloma) or single (adult papilloma). The causative organism Human papilloma virus type 6 and 11. Malignant changes may occur in a juvenile papilloma but usually only if the patient has been irradiated.

Evaluation-

1. *History* - As in all clinical evaluations, the history is the first step in gathering the facts. Assess or inquire about the following:

- Weight loss
- Fatigue
- Pain
- Difficulty breathing or swallowing
- Vocal changes noted by the patient and his or her family
- Ear pain
- Coughing up blood or solid material

2. *Physical examination-*

- General condition
- Nutritional status
- Full head and neck examination which includes inspection and palpation of the oral cavity and oropharynx to rule out second primary tumors or other lesions, as well as evaluation of dentition.

- Flexible laryngoscope - to evaluate the function and anatomy of the entire larynx. Evaluation of vocal cord motility and the location and extension of the tumor are crucial to stage the patient accurately.
- Palpation of the neck looking for enlarged lymph nodes
- Evaluation of the cranial nerves should also be included in the physical examination.

Imaging Studies-

It is important to carry out any imaging studies prior to endoscopy and biopsy if possible since FNAC; endoscopic and open biopsy can all create artefactual features on both CT and MRI.

Specific Uses of Imaging-

- To assess the extent of primary tumour, its relation to larynx, and any extension into pre and para glottic space
- To exclude a second primary or distant metastases
- Involvement of cartilage
- To assess the neck

Tissue Biopsy- DL scopy and biopsy and panendoscopy

TNM Staging

(Glottic carcinoma)

T1 - limited to VC, normal mobility (May inv ant/post com.)

T1a - one vocal cord

T1b - both VC

T2 - extends to Supraglottis and/or glottis, impaired VC mobility

T3 - limited to larynx with hemilarynx fixation, paraglottic space/minor thyroid cart erosion
(inner cortex)

T4a - invades through thyroid cartilage, /extralaryngeal tissues,(trachea, soft tissues, muscles of tongue, strap muscles, thyroid gland & esophagus, l

T4b - Prevertebral fascia, mediastinal structures, ICA.

Treatment protocol- (glottic carcinoma)

1. For carcinoma in situ
 - a) Endoscopic removal (stripping/laser)
 - b) RT and follow up.

2. For Most T1-2, N0 (total laryngectomy not required)
 - a) RT
 - b) Partial laryngectomy is the treatment of choice.

3. For most T3; N0-1 Resectable tumors requiring total laryngectomy
 - a) CCRT
 - if Primary site: Complete response (N0 at initial staging) then only follow up is required.
 - If Primary site: Complete response (N+ at initial staging) with residual tumor in neck then Neck dissection can be considered.
 - If Primary site: residual tumor is there then Salvage surgery + neck dissection is indicated.
 - b) Second option is Surgery. In case of No disease Laryngectomy with ipsilateral thyroidectomy unilateral or bilateral selective neck dissection (reconstruction as indicated) and follow up. And in case of N1 disease Laryngectomy with ipsilateral thyroidectomy, ipsilateral comprehensive neck dissection ± contralateral selective neck dissection (reconstruction as indicated).
 - If pt presented with No adverse features like extracapsular nodal spread, positive margins, pT4 primary, N2 or N3 nodal disease, perineural invasion, vascular embolism only follow up required.

- Adverse features chemo/RT can be consider.

4. For most T3, N2-3 disease

a) CCRT can be tired.

- If Primary site: complete response but with Residual tumor in neck then Neck dissection can be consider.

- In case of complete response of neck then Post-treatment evaluation (minimum 12 wks) with PET, Contrast-enhanced CT or MRI and Physical exam is required. If inv are negative only observation is required. And inv are Positive then Neck dissection is considered.

- If pt presented with Primary site: residual Tumor then Salvage surgery + neck dissection as indicated.

b) Second option is Surgery- Laryngectomy with ipsilateral thyroidectomy, ipsilateral or bilateral comprehensive neck dissection (reconstruction as indicated).

- If pt presented with No adverse features like extracapsular nodal spread, positive margins, pT4 primary, N2 or N3 nodal disease, perineural invasion, vascular embolism only follow up required.

- With Adverse features chemo/RT can be consider.

c) Third option is Induction chemotherapy x 3 cycles and follows the same principle of management.

5. For most T3, N2-3; Selected T4a

a) NACT 3 cycle and follow up.

- If pt presented with Primary site: CR or PR and stable disease in neck then Chemo/RT can be consider.

- If Primary site: complete response but with Residual tumor in neck then Neck dissection is done.

- If pt presented with Primary site: residual tumor then Salvage surgery +neck dissection as indicated.

- In case of Primary site: < PR or progression in neck then Salvage surgery + neck dissection as indicated.

6. For T4a, Any N disease

a) Surgery is the only treatment.

- For N0 disease Laryngectomy with ipsilateral thyroidectomy unilateral or bilateral selective neck dissection (reconstruction as indicated).

- For N1 disease Laryngectomy with ipsilateral thyroidectomy, ipsilateral comprehensive neck dissection ± contralateral selective neck dissection (reconstruction as indicated).

- For N3 disease Laryngectomy with ipsilateral thyroidectomy, ipsilateral or bilateral comprehensive neck dissection (reconstruction as indicated) followed by Chemo/RT.

TNM Classification-

(Supraglottis)

T1 - one subsite, normal vocal cord mobility

T2 - more than one adjacent subsite of supraglottis/ region outside supraglottis (mucosa of BOT, vallecula, PF med wall) without larynx fixation

T3 - limited to larynx with hemilarynx fixation/ invades postcricoid, pre-epiglottic area, paraglottic space/minor thyroid cart erosion (inner cortex)

T4a - invades thyroid cartilage / extra-laryngeal tissues, (trachea, soft tissues, muscles of tongue, strap muscles, thyroid gland & esophagus, l

T4b - pre-vertebral fascia, mediastinal structures, ICA.

Treatment protocol- (Supraglottic Larynx)

1. For Most T1-2, N0 disease not requiring total laryngectomy

a) Endoscopic resection ± selective neck dissection

- b) Open partial supraglottic laryngectomy ± selective neck dissection
 - c) Definitive RT .
 - d) if pt presented with One positive node without other adverse features then Consider RT. if pt presented with adverse features: positive margins then Further surgery or RT or Consider chemo/RT. if pt presented with Adverse features: extracapsular nodal spread then consider Chemo/RT and follow up.
2. For T3, N0 T4a, N0 requiring total laryngectomy
- a) Low-volume base-of tongue involvement not penetrating through cartilage planned for CCRT.
 - If pt presented with Primary site: Complete response then only follow up required.
 - If pt presented with Primary site: residual tumor then Salvage surgery +neck dissection as indicated.
 - b) Second option is Laryngectomy, ipsilateral thyroidectomy with ipsilateral or bilateral selective neck dissection.
 - If pt presented with N0 or one positive node without adverse features then RT optional.
 - If pt presented with Adverse features then consider Chemo/RT.
 - c) Third option is RT if patient not candidate for concurrent chemo/RT and follow up.\
3. For T4, N0 High volume invasion of base of tongue, penetration through cartilage
- a) Laryngectomy, ipsilateral thyroidectomy with ipsilateral or bilateral selective neck dissection can be considered followed by Chemo/RT.
4. For Node positive disease T1-2, N+ and selected T3-4a, N0-1disease
- a) CCRT can be tired.
 - If Primary site: complete response but with Residual tumor in neck then Neck dissection can be consider.

- In case of complete response of neck then Post-treatment evaluation (minimum 12 wks) with PET, Contrast-enhanced CT or MRI and Physical exam is required. If inv are negative only observation is required. And inv are Positive then Neck dissection is considered.

b) Second option is Partial supraglottic laryngectomy and comprehensive neck dissection(s).

- if there is No adverse features only Observation required. With Adverse features give Chemo/RT.

5. For Most T3, N2-N3 disease requiring total laryngectomy

a) CCRT can be tried.

- If Primary site: complete response but with Residual tumor in neck then Neck dissection can be consider.

- In case of complete response of neck then Post-treatment evaluation (minimum 12 wks) with PET, Contrast-enhanced CT or MRI and Physical exam is required. If inv are negative only observation is required. And inv are Positive then Neck dissection is considered.

- If Primary site: residual tumor then Salvage surgery + neck dissection as indicated.

b) Second option is Laryngectomy, ipsilateral thyroidectomy with comprehensive neck dissection. If no adverse features consider RT. With Adverse Features give Chemo/RT.

c) Third option Most T3, N2-3 disease NACT 3 cycle and follow up.

- If pt presented with Primary site: CR or PR and stable disease in neck then Chemo/RT can be consider.

- If Primary site: complete response but with Residual tumor in neck then Neck dissection is done.

- If pt presented with Primary site: residual tumor then Salvage surgery + neck dissection as indicated.

- In case of Primary site: < PR or progression in neck then Salvage surgery + neck dissection as indicated.

6. For T4a, N2-N3 Cartilage destruction Skin involvement Massive invasion of base of tongue then Laryngectomy, ipsilateral thyroidectomy with ipsilateral or bilateral neck dissection followed by Chemo/RT can be considered.

Preventive Measures

- ☒ Don't smoke. Don't drink more than 1 or 2 alcoholic drinks, if any, a day.
- ☒ Avoid exposure to known toxins.
- ☒ Seek attention of doctor in case of change of voice and any other throat problem.

CERVICAL LYMPHADENOPATHY

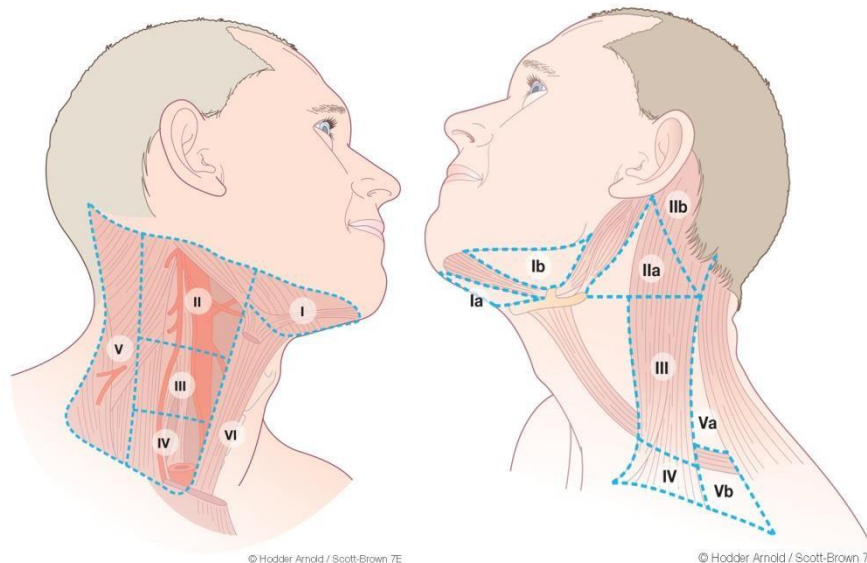
Introduction-

Lymphadenopathy is an abnormal increase in size and/ or altered consistency of lymph nodes. It is a clinical manifestation of regional or systemic disease and serves as an excellent clue to the underlying disease. Cervical lymphadenopathy (C.L.) is a fairly common clinical presentation.

Surgical anatomy and classification - Cervical lymph nodes are lymph nodes found in the neck. There are approximately 300 lymph nodes in the neck

Cervical lymph nodes are classified into 7 groups. They are-

- Level I: Submental and submandibular nodes
- Level Ia: Submental triangle
- Level Ib: Submandibular triangle
- Level II: Upper jugular nodes
- Level III: Middle jugular nodes
- Level IV: Lower jugular nodes
- Level V: Posterior triangle group
- Level VI: Pre-tracheal, pre-laryngeal and post-tracheal
- Level VII: Mediastinal



Incidence

- Age < 30 - 79% benign; 15% lymphomatous; 6% carcinomas
- Age > 50 - 40% benign; 16% lymphomatous; 44% carcinomas
- 0.6 annual incidence of generalized lymphadenopathy

Differential diagnosis-

Common infectious causes of lymphadenopathy

1. Adenovirus
2. CMV
3. Enterovirus
4. EBV
5. Varicella
6. Herpes simplex
7. Staphylococcus infection
8. Group A hemolytic Streptococcus
9. Tularemia
10. Brucellosis
11. Tuberculosis
12. Atypical mycobacteria
13. Klebsilla
14. AIDS
15. Bubonic plague
16. Anthrax

Common non-infectious causes of lymphadenopathy

1. Hodgkin's disease
2. Lymphomas
3. Leukemia
4. Metastatic disease
5. Histiocytosis
6. SLE and JRA
7. Kawasaki Disease
8. Sarcoidosis_

Symptoms and signs-

1. Neck Swelling

Lymph node character

- i) Stone hard: typical of cancer usually metastatic
 - ii) Firm rubbery: can suggest lymphoma
 - iii) Soft: infection or inflammation
 - iv) Matting: tubercular
2. Pain-
- (i) Painful lymph node present in acute inflammatory condition.
 - (ii) Painless lymph node mainly present in granulomatous or malignant conditions
3. Size - Rapid increase in size could be due to malignancy.

Evaluation

1. Laboratory studies
- a) CBC count, including a careful evaluation of the peripheral blood smear. An erythrocyte sedimentation rate is nonspecific but may be helpful.
 - b) Evaluation of hepatic and renal function and a urine analysis are useful to identify underlying systemic disorders that may be associated with lymphadenopathy.
 - c) Additional studies, such as lactate dehydrogenase (LDH), uric acid, calcium, and phosphate, may be indicated if malignancy is suspected. Skin testing for tuberculosis is usually indicated.
 - d) In evaluating specific regional adenopathy, lymph node aspirate for culture may be important if lymphadenitis is clinically suspected.
 - e) Titers for specific microorganisms may be indicated, particularly if generalized adenopathy is present. These may include Epstein-Barr virus, cytomegalovirus (CMV), *Toxoplasma* species, and human immunodeficiency virus (HIV).
2. Imaging studies
- a) Chest radiography is usually the primary screening imaging study. Additional imaging studies are usually based on abnormal chest radiograph findings. Chest radiography is often helpful in elucidating mediastinal adenopathy and underlying diseases affecting the lungs, including tuberculosis, coccidioidomycosis, lymphomas.
 - b) CT scan and MRI especially helpful in case of metastatic disease to know the extent of involvement.

- c) Nuclear medicine scanning is helpful in the evaluation of lymphomas.
 - d) Ultrasonography may be helpful in evaluating the changes in the lymph nodes in evaluating the extent of lymph node involvement in patients with lymphadenopathy.
- and
3. Fine Needle aspiration Cytology
 4. Lymph Node Biopsy / Excisional Biopsy.

Management

1. Treatment with antibiotics (covering the bacterial pathogens frequently implicated in lymphadenitis) followed by re-evaluation in 2-4 weeks is reasonable if clinical findings suggest lymphadenitis. Benign reactive adenopathy may be safely observed for months.

Infectious lymph adenopathy usually requires treatment with appropriate antibiotics.

2. Granulomatous condition requires address of general condition, and treatment with steroids and immunoglobins depending on conditions.
3. In cases of malignant conditions, patient can be managed on different modality of treatment viz chemotherapy, radiotherapy or surgery depending on type and stage of malignancy.

PERITONSILLAR ABSCESS (QUINSY)

Introduction: Peritonsillar abscess is a common infection of Head & Neck region. Although not generally considered as a deep neck space infection physicians must be aware of the typical clinical presentation & diagnostic strategies in order to quickly diagnose & appropriately treat these patients to prevent complications.

Case Definition: PTA is a collection of pus between the fibrous capsule of the tonsil usually at the upper pole & the superior constrictor muscles of pharynx.

Incidence in our Country: 0.9/10000/yr (Age Range- 3-91 yrs)

Differential Diagnosis

1. Infectious - Peritonsillar Cellulitis
Parapharyngeal abscess
Dental - Upper 3rd molar abscess
Co-existing Infectious Mononucleosis
2. Inflammatory-Kawasaki disease
3. Vascular-Post traumatic Internal Carotid Artery Aneurysm
4. Benign lesions-Benign Lympho-epithelial Cysts
5. Neoplastic –Large tonsil tumours with extra tonsillar spread (eg. Squamous cell carcinoma); Tonsillar lymphoma; Rhabdomyosarcoma
6. Peritonsillar space tumours-Minor Salivary gland tumours
7. Anterior Pillar Mucosal tumours-Squamous cell carcinoma

Prevention and Counselling

1. Do not smoke.
2. Maintain good oral hygiene
3. Promptly treat oral infections.
4. If recurrent tonsillitis, tonsillectomy can be considered.
5. Always finish the course of antibiotics given in prescription even if you feel better within few days of starting the course.

Optimal Diagnostic Criteria & Investigations

**Situation 1: At Secondary Hospital / Non Metro situation: Optimal standards of treatment in situations where technology & resources are limited*

1. *Clinical diagnosis-*

a) History

(i) Progressive, usually unilateral sore throat over 3-4 days.

(ii) Odynophagia

(iii) Dysphagia for solids then liquids

(iv) Ipsilateral otalgia

(v) Headache, body ache

(vi) Fever, chills & rigors

b) General Examination

(i) Muffled & thick speech (hot potato voice / plummy voice)

(ii) Foul breath

(iii) Vitals – Fever; tachycardia

c) Local Examination

(i) Limited mouth opening (Trismus)

(ii) Torticollis

(iii) Oral cavity- Dental caries

(iv) Oropharynx- Soft Palate-Congested, Bulging

Anterior Tonsillar Pillar- Congested, Edematous

Tonsil-Edematous (May not appear enlarged as it gets buried in edematous pillars)

Uvula-Edematous, pushed to opposite side.

2. *Investigations*

a) Complete Blood counts

b) Serum electrolytes

c) Needle aspiration of pus

(i) Culture

(ii) Sensitivity

- d) Imaging
 - (i) Orthopantogram
 - (ii) X- Ray Neck
 - AP view – Distortion of soft tissue
 - Lateral view- Rule out other differential diagnosis

Treatment & Referral Criteria

Standard Operating Procedure

1. Needle Aspiration

- Infiltration of 2% Lignocaine with Adrenaline (1: 100,000) given.
- Using Needle 16-18 gauge & 10 ml syringe aspirate from the area which is most fluctuant.
- Aspirate at superior pole initially because it is the most common area where abscess is present; then middle 1/3rd followed by lower 1/3rd if pus is not returned from superior pole.
- Needle guard is used to prevent accidental injury to Internal Carotid Artery due to tip of needle migrating too far posteriorly. Only 0.5 cm of needle needs to be exposed.
- If needle guard is unavailable a curved clamp can be used to expose a small portion of needle before inserting it into area of aspiration.

2. Incision & Drainage

- Local infiltration of 2 percent Lignocaine with Adrenaline (1: 100,000) given.
- Using No.11 blade scalpel / Quinsy knife a large peritonsillar abscess is incised.
- It allows free flow of pus as the abscess cavity decompresses.
- To prevent risk of aspiration, allow patient to hold Yankauer catheter tip & do suction of pus.

3. Abscess /Hot Tonsillectomy

4. Interval Tonsillectomy

5. In-Patient Care

- a) Airway- Tracheostomy may be essential in case of compromised airway
- b) Breathing
- c) Circulation- IV Fluids
- d) Antibiotics- IV until acceptable swallowing is feasible.

- e) Antibiotic of choice-
 - Penicillin G Benzathine (Adult- 600mg iv q 6 hr for 12-24 hr Paediatric- 12,500- 25000 U/kg iv q 6hr)
 - Erythromycin (Adult- 15-20 mg /kg/day PO /iv divided q6h; Not more than 4 g/day; Paediatric- 30-50mg/kg/day PO/iv divided q6h)
- f) Analgesics- Paracetamol - 500 mg TDS; Pethidine
- g) Hydrogen peroxide/ Saline mouth wash
- h) Single dose iv Steroid

5. Out Patient Care

- a) Analgesics
- b) Antibiotics
- c) Hydrogen peroxide gargles

**Situation 2: At superspeciality Facility in Metro Location Where Higher End Technology Is Available*

1. *Clinical Diagnosis* - same

2. *Investigations*

- a) Complete blood count
- b) Serum Electrolytes
- c) Monospot /Heterophile Antibody Test for Infectious Mononucleosis
- d) Needle Aspiration of Pus - Culture & Sensitivity
- e) Blood Culture - If Septicemia.
- f) Imaging
 - (i) Orthopantogram
 - (ii) X- ray Neck - AP view; Lateral view
 - (iii) CT-Scan Neck with Contrast
 - Indications for CT Scan
 - Failure of I&D
 - Presence of Trismus
 - Young age (less than 7 yrs)

Findings in CT Scan

- Hypodense fluid collection with rim enhancement in tonsil.
- Foreign body (fish/chicken bone) as an inciting factor.

g) USG - Intraoral or Transcutaneous

h) MRI Angiography

3. *Treatment* - same

Further reading / references

1. Scott- Brown` S Otorhinolaryngology , Head And Neck Surgery 7th Edition
2. Otorhinolaryngology- PL Dhingra
3. eMedicine