
Basic laboratory methods in medical parasitology



World Health Organization
Geneva
1991

Reprinted 1997

WHO Library Cataloguing in Publication Data

Basic laboratory methods in medical parasitology.

1. Parasitology – laboratory manuals

ISBN 92 4 154410 4 (NLM Classification: WC 25)

© World Health Organization 1991

Publications of the World Health Organization enjoy copyright protection in accordance with the provisions of Protocol 2 of the Universal Copyright Convention. For rights of reproduction or translation of WHO publications, in part or *in toto*, application should be made to the Office of Publications, World Health Organization, Geneva, Switzerland. The World Health Organization welcomes such applications.

The designations employed and the presentation of the material in this publication do not imply the expression of any opinion whatsoever on the part of the Secretariat of the World Health Organization concerning the legal status of any country, territory, city or area or of its authorities, or concerning the delimitation of its frontiers or boundaries.

The mention of specific companies or of certain manufacturers' products does not imply that they are endorsed or recommended by the World Health Organization in preference to others of a similar nature that are not mentioned. Errors and omissions excepted, the names of proprietary products are distinguished by initial capital letters.

TYPESET IN INDIA
PRINTED IN ENGLAND

88/8318–Macmillan/Clays–7000
97/11444–Clays–1000

Contents

| | |
|---|-----------|
| Preface | vii |
| List of contributors | viii |
| Introduction | 1 |
| Laboratory safety | 2 |
| <hr/> | |
| Section 1. Techniques of collection, preparation and examination of samples | 5 |
| <hr/> | |
| Care of the microscope | 7 |
| Calibrating the microscope for measurement | 8 |
| Faecal specimens | 9 |
| Collection of faecal specimens | 9 |
| Examination | 10 |
| Macroscopic examination of stool | 10 |
| Microscopic examination of wet mounts | 10 |
| Identification of parasites | 13 |
| Supplementary techniques | 15 |
| Concentration technique | 16 |
| Permanent staining techniques | 17 |
| Identification of parasites in stained smears | 24 |
| Anal swabs for pinworm | 24 |
| Cellophane faecal thick-smear for diagnosis of intestinal schistosomiasis (Kato-Katz technique) | 25 |
| Sending specimens to a reference laboratory | 28 |
| Disposal of specimens | 29 |
| Quality control for faecal examination | 29 |
| Collection of specimens | 30 |
| Preparation of reagents | 30 |
| Performance of techniques | 31 |
| Urine specimens | 33 |
| Collection of urine for diagnosis of <i>Schistosoma</i> infection | 33 |
| Examination of urine | 33 |
| Sedimentation method for 24-hour terminal urine collection | 33 |
| Syringe filtration method | 34 |
| Identification | 36 |

| | |
|--|-----------|
| Vaginal and urethral material | 37 |
| Collection of specimens | 37 |
| Direct examination of vaginal and urethral smears | 37 |
| Blood and other specimens | 39 |
| Stained blood films | 39 |
| Collection of specimens | 39 |
| Staining blood films with Giemsa stain | 42 |
| Staining blood films with Field's stain | 43 |
| Staining blood films with Delafield's haematoxylin stain for microfilariae | 44 |
| Examination | 45 |
| Quality control for blood examination | 45 |
| Special techniques for plasmodia | 46 |
| Identification of malaria parasites | 46 |
| Examination of chloroquine resistance in falciparum malaria | 47 |
| Special techniques for <i>Trypanosoma</i> | 48 |
| Detection of trypanosomes in blood | 48 |
| Detection of trypanosomes in lymph node aspirates | 53 |
| Detection of trypanosomes in cerebrospinal fluid (CSF) | 55 |
| Special techniques for microfilariae | 57 |
| Collection of blood for microfilariae | 57 |
| Detection of microfilariae in peripheral blood | 57 |
| Special techniques for <i>Leishmania</i> | 58 |
| Skin specimens | 62 |
| Collection of specimens | 62 |
| Examination of specimens | 63 |
| <hr/> Section 2. Identification of parasite species | 65 |
| <hr/> Intestinal parasites | 67 |
| Helminths | 67 |
| Key to identification of eggs | 67 |
| Worm larvae | 70 |
| Protozoa | 71 |
| Amoebic trophozoites | 71 |
| Amoebic cysts | 73 |

| | |
|---|-----------|
| Flagellates | 76 |
| <i>Balantidium coli</i> | 77 |
| <i>Isospora belli</i> and <i>Cryptosporidium</i> | 78 |
| <i>Toxoplasma gondii</i> | 78 |
| Problems of identification | 79 |
| Blood parasites | 80 |
| Malaria | 80 |
| Identification of malaria parasites in thin blood films | 80 |
| Identification of malaria parasites in thick blood films | 80 |
| Things that may be confused with malaria parasites | 88 |
| <i>Trypanosoma</i> | 88 |
| Microfilariae | 89 |
| Bibliography | 92 |
| Annex 1. Equipment and materials for diagnostic parasitology in health centres and district hospital laboratories | 93 |
| Annex 2. Reagents and solutions and their preparation | 96 |
| Annex 3. Preparation of culture media | 107 |
| Annex 4. Cleaning and storage of microscope slides | 109 |
| Index | 111 |

Preface

This manual is intended as a practical guide for use by workers in laboratories in health centres and first-referral hospitals. Diagnostic methods are restricted to microscopy, though reference specimens may need to be sent for serodiagnosis.

The content of this manual is based on information contained in training material and manuals produced by the Hospital for Tropical Diseases, London, England; the Parasitology Training Section, Division of Laboratory Training and Consultation, Laboratory Program Office, Centers for Disease Control, Atlanta, Georgia, USA; the World Health Organization, Geneva, Switzerland; and the Pan American Health Organization, Washington, DC, USA. In particular, a number of illustrations were taken from the following publications: Brooke, M. M. & Melvin, D. M., *Morphology of diagnostic stages of intestinal parasites of humans*, 2nd ed. Atlanta, GA, US Department of Health and Human Services, 1984 (HHS Publication No. (CDC) 84-8116); Melvin, D. M. & Brooke, M. M., *Laboratory procedures for the diagnosis of intestinal parasites*, 3rd ed. Atlanta, GA, US Department of Health and Human Services, 1982 (HHS Publication No. (CDC) 82-8282).

List of contributors

The following have contributed to the preparation of this publication:

- Dr P. L. Chiodini, Consultant Parasitologist, Hospital for Tropical Diseases, London, England;
- Dr K. Engbaek, Department of Clinical Microbiology, Copenhagen County Hospital, Herlev, Denmark;
- Dr C. C. Heuck, Health Laboratory Technology and Blood Safety, WHO, Geneva, Switzerland;
- Dr L. Houang, Annemasse, France;
- Dr R. C. Mahajan, Department of Parasitology, Postgraduate Institute of Medical Education and Research, Chandigarh, India;
- Dr M. A. Melvin, Atlanta, Georgia, USA;
- Dr L. Monjour, Parasitology and Mycology, Tropical and Parasitological Diseases, Groupe Hospitalier Pitié-Salpêtrière, Pavillon Laverean, Paris, France;
- Dr J. C. Petithory, National Quality Control in Parasitology, Department of Medical Biology, Centre Hospitalier, Gonesse, France;
- Dr J. Vandepitte, Department of Clinical Microbiology, University Hospital St Raphael, Leuven, Belgium.

Introduction

Parasitic diseases are responsible for considerable morbidity and mortality throughout the world, and often present with nonspecific symptoms and signs. Most parasitic diseases cannot be diagnosed by physical examination alone, and laboratory investigation is necessary to decide whether or not the patient is infected with a parasite and, if so, what species of parasite is present. Thus the laboratory plays an important role in establishing the diagnosis of parasitic diseases and is therefore the key to the selection of the appropriate drug for treatment. Laboratory tests must be accurate and reliable if the results are to help the physician and benefit the patient.

This manual is a guide for the laboratory worker. Section 1 presents the techniques to be used when examining faeces, blood, urine, and other materials for the presence of parasites. Pitfalls and possible errors are pointed out and methods for avoiding these indicated. Quality control measures are also discussed. The laboratory worker must understand that only careful performance of the techniques required to recover and demonstrate parasites will make it possible for them to be seen clearly on microscopic examination.

Section 2 of the manual describes the morphological criteria used to identify parasites. Artefacts and problems of identification are also discussed.

Information about the equipment and reagents required is contained in four annexes. Annex 1 lists the materials and equipment needed in health centres and hospital laboratories at the primary health care level, Annex 2 gives the formulae and directions for preparing reagents, Annex 3 gives the formulae and directions for preparing culture media, and Annex 4 describes the procedure for cleaning and storing slides to be used for preparing blood films.

Laboratory safety

General principles

1. Each laboratory should have a written manual of safe laboratory methods, to be followed at all times.
2. The laboratory should have a first aid box and a designated first aider on the staff.
3. Non-laboratory staff must not be allowed to enter the working area of the laboratory.
4. Eating, drinking, smoking, and applying cosmetics should not be permitted in the laboratory.
5. Laboratory personnel should wear protective clothing, which should be removed on leaving the laboratory area.
6. Laboratory personnel should clean the benches with a detergent solution (soap) and disinfect the working surfaces after every working day, or after having spilt infectious material. The most commonly used disinfectants are:
 - 96% ethanol or isopropanol (irritant to skin),
 - 1% phenol solution (corrosive, caustic),
 - 0.5–1% hypochlorite solution (caustic, corrosive) (alkaline hypochlorite solution is more aggressive than neutral hypochlorite solution),
 - 1% formaldehyde or 2% glutaraldehyde solution (toxic and irritant to skin).Aldehyde and phenol solutions are active over a longer period. It is advisable to wipe the working areas with tissue soaked with a disinfectant solution rather than using a spray.
7. Laboratory personnel must always wash their hands before leaving the laboratory.

Handling specimens

Great care is needed in handling all laboratory specimens and rubber gloves should always be worn.

Blood samples. All blood samples must be regarded as potentially infectious. As very serious pathogens can be transmitted by blood (e.g., human immunodeficiency virus (HIV), hepatitis B virus) great care is required when collecting and processing samples. Particular risks are:

- (a) Stabbing or cutting injuries—dispose of used needles or lancets in a container which can then be incinerated or buried in a disposable specimen container after soaking in disinfectant solution. Do not reuse lancets. Do not leave used lancets lying around the laboratory. Do not use chipped or cracked glassware.
- (b) Contamination of damaged skin or of mucous membranes—cover any cuts with impervious dressings. Avoid spilling blood on to the skin or mucous membranes. Pipetting by mouth should be absolutely forbidden! If blood is spilt on to the skin, immediately wash the affected area with soap and water; if blood gets into the eyes, they should be irrigated with large amounts of water. Any blood spilt on to laboratory surfaces should be soaked with hypochlorite solution and then wiped up with a cloth impregnated with hypochlorite solution.

Stool samples. Skin contact must be avoided. When finished with, samples should be either (a) incinerated or (b) soaked in disinfectant solution and then buried in disposable specimen containers.

Urine samples. Skin contact must be avoided. Samples can be discarded via the sewage system.

Disposal of microscope slides

Slides should be discarded into a pot containing 1% hypochlorite solution and buried in disposable specimen containers, if they are not to be cleaned for reuse.



Section 1

Techniques of collection,
preparation, and examination
of samples



Care of the microscope

Do's

1. Do keep the microscope covered with a clean plastic or cloth cover when it is not in use.
2. Do take special care to protect the microscope from dust in hot dry periods.
3. Do take special care to protect the microscope lenses and prisms from fungal growth in hot humid periods. This can be done by:
 - keeping the microscope in an air-conditioned room,
OR
 - storing the microscope in a special dehumidified room—an electric dehumidifier is about half the price of an air-conditioner,
OR
 - connecting a number of 15 or 25 watt bulbs inside a cupboard with tightly fitting doors,
OR
 - placing a 15 watt bulb in the individual microscope box which then acts as a warm cupboard,
OR
 - in areas without electricity, placing a shelf to hold the microscope box about 30 cm over the chimney of the gas- or kerosene-operated refrigerator or freezer; an airtight bag and silica gel in its dry state (as indicated by its blue colour) will keep a microscope sufficiently dry to protect lenses from fungi.
4. Do clean the immersion oil from the immersion objective every day; use a soft cloth dampened with ethanol/ether (3 ml/7 ml) or benzine/ethanol/ether (2 ml/2 ml/1 ml) and polish with a clean, lint-free cloth.
5. Do clean the oculars with a soft, lint-free cloth; as an alternative, use lens tissue or facial tissue, if available.
6. Do use the microscope retaining screw fitted at the base of the microscope box to prevent damage to the instrument while in transit.
7. Do quote the model number and, if possible, the instrument and part number when ordering replacement parts.

Dont's

1. Don't use the tissue or cloth used for the oil immersion objective to clean the oculars.
2. Don't use alcohol to clean painted surfaces of the microscope.
3. Don't dismantle or try to clean parts of the microscope that are difficult to reach unless you have been trained to do so.
4. Don't leave the lens ports empty; use the appropriate cover or some sticking plaster to cover the empty port.
5. Don't exchange lenses from microscopes of different manufacture—even some models by the same manufacturer have different specifications.

Calibrating the microscope for measurement

Size is an important criterion for the identification of many parasites, particularly cysts and ova. Size can be determined using a blood cell counting chamber (Neubauer), or alternatively an eyepiece micrometer. Using an eyepiece micrometer, the procedure is as follows:

1. The eyepiece scale is divided into 100 small divisions.
2. The stage micrometer scale consists of 1 mm divided into 0.1 mm divisions and each 0.1 mm is divided in 0.01 mm.
3. Insert the eyepiece scale (a round glass disc) into the eyepiece by removing the uppermost lens and placing the scale on the field stop.
4. Insert the eyepiece into the microscope.
5. Place the stage micrometer on the microscope stage.
6. Focus the low-power objective on the stage scale.
7. Adjust the stage and eyepiece scales until the eyepiece scale and the stage scale are parallel.
8. Note the number of eyepiece divisions and its appropriate stage measurement, e.g., 50 eyepiece divisions = 0.75 mm; 10 eyepiece divisions = 0.15 mm.
9. From this reading, work out the value for one eyepiece division, as follows:
$$50 \text{ eyepiece divisions} = 0.75 \text{ mm}$$
$$1 \text{ eyepiece division} = 0.75/50 = 0.015 \text{ mm}$$

OR

$$10 \text{ eyepiece divisions} = 0.15 \text{ mm}$$
$$1 \text{ eyepiece division} = 0.15/10 = 0.015 \text{ mm.}$$
10. Change the measurement value from mm to μm (1 mm = 1000 μm), e.g., 0.015 mm = 15 μm .
11. Repeat for all objectives and note the reading for each.
12. Calibration need be done only once for each microscope used.

Faecal specimens

Faecal specimens are examined for the presence of protozoa and helminth larvae or eggs.

The stages of protozoa found in stools are trophozoites and cysts. The stages of helminths usually found in stools are eggs and larvae, though whole adult worms or segments of worms may also be seen. Adult worms and segments of tapeworms are usually visible to the naked eye, but eggs, larvae, trophozoites, and cysts can be seen only with the microscope. In order to see these structures, the faecal material must be properly prepared and examined.

Collection of faecal specimens

Because of the fragile nature of many intestinal parasites, and the need to maintain their morphology for accurate identification, reliable microscopic diagnosis cannot be made unless the stool is collected properly.

1. Give the patient the following:
 - a waxed cardboard box with an overlapping lid, or a plastic cup or box with a tight-fitting lid, and
 - 2 applicator sticks.

If waxed boxes or plastic cups are not available, tin boxes or glass jars can be used. Banana leaves and match boxes are not satisfactory containers for the collection and storage of stool specimens.

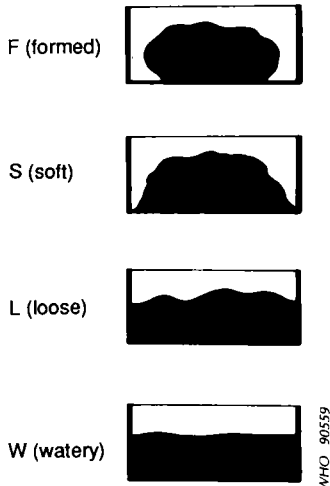
In control programmes, it is often sufficient to examine a single specimen, but for patients, three specimens are usually required, at 3-day intervals, to detect all parasitic infections. A variety of substances may interfere with the examination of stool specimens for parasites (e.g., laxatives, antacids, ingested contrast media, certain antibiotics).

2. Tell the patient to pass the stool specimen directly into the container, or to pass the stool on to a piece of paper and use the applicator sticks to transfer it to the container. If paper is not available, the faeces can be passed on to a large, clean leaf, such as a banana leaf. However, the stool *must be transferred immediately to the specimen container*. It should not remain on the leaf, or be brought to the laboratory on the leaf.
3. Some organisms, especially amoebic trophozoites, will begin to disintegrate or change within a short time after passage and become unrecognizable. Warm temperatures will hasten these changes. Therefore, specimens must reach the laboratory very soon (i.e., within half an hour) after passage. If this is not possible, the specimen must be treated with preservatives (see pp. 28–29).
4. The container with the specimen should be labelled clearly with the following information:
 - patient's name or number
 - date of collection
 - time the patient passed the stool (ask the patient when he/she passed the stool).
5. The stool specimen must be large enough for satisfactory examination. The smallest quantity that should be accepted is about the size of a pigeon's egg. Urine and dirt should be excluded. Urine will destroy any amoebic trophozoites and dirt will interfere with the examination. If the specimen is too small, or if it is mixed with urine or dirt, it should not be accepted. Ask the patient to pass another specimen.

6. Keep the carton containing the specimen in a refrigerator, or if this is not possible in the coolest, shadiest area in the laboratory. Do not keep the specimen artificially warm and do not leave it in the sun.

Examination

Macroscopic examination of stool



1. As soon as the specimen is received in the laboratory, check the consistency (degree of moisture) and write one of the following letters on the container: F (formed), S (soft), L (loose), or W (watery).

If mucus is present write M, and if blood is present write B. For example, a loose stool with blood and mucus would be recorded as L, B, M. The consistency, or degree of moisture, will be a guide as to whether the trophozoite stage or the cyst stage of protozoa is likely to be present. The various categories of stool and the appropriate techniques to be used are shown in Table 1.

2. If several specimens are received at the same time, those containing blood and mucus should be examined first, followed by liquid specimens. These specimens are the most likely to contain amoebic trophozoites (which die soon after being passed) and must be examined within 1 hour after passage. Formed specimens may be examined at any time during the first day, but should not be left overnight (cysts may disintegrate).

Microscopic examination of wet mounts

Wet mounting is the simplest and easiest technique for the examination of faeces, and this method should be performed in all laboratories at the peripheral level.

A wet mount can be prepared directly from faecal material or from concentrated specimens (see p. 16). The basic types of wet mount that should be used for each faecal examination are saline, iodine, and buffered methylene blue:

- The *saline wet mount* is used for the initial microscopic examination of stools. It is employed primarily to demonstrate worm eggs, larvae, protozoan trophozoites, and cysts. This type of mount can also reveal the presence of red blood cells and white blood cells.

Table 1. Categories of stool and appropriate techniques to be used

| Consistency | Protozoan stage most likely to be found ^a | Technique to use | | |
|-------------|--|------------------|--------|--|
| | | Saline | Iodine | Buffered methylene blue (if trophozoites are seen) |
| Formed | Cysts | + | + | |
| Soft | Cysts (occasionally trophozoites) | + | + | + |
| Loose | Trophozoites | + | | + |
| Watery | Trophozoites | + | | + |

^aWorm eggs and larvae may be found in stools of any consistency.


- The *iodine wet mount* is used mainly to stain glycogen and the nuclei of cysts, if present. Cysts can usually be specifically identified in this mount.
- The *buffered methylene blue (BMB) wet mount* should be prepared each time amoebic trophozoites are seen in a saline wet mount, or when their presence is suspected. BMB stains amoebic trophozoites, but does not stain amoebic cysts, flagellate trophozoites, or flagellate cysts. BMB stain is appropriate only for fresh unpreserved specimens. It is not used on preserved specimens in which the organisms have been killed.

Materials and reagents

1. Coverslips
2. Dropping-bottles containing: saline solution, isotonic (reagent no. 24)¹
Lugol's iodine (1% solution) (reagent no. 18)
buffered methylene blue (reagent no. 2)
3. Microscope slides
4. Pens or markers for labelling
5. Wire loop (or applicator sticks, matchsticks, or toothpicks).

Direct saline and iodine mounts

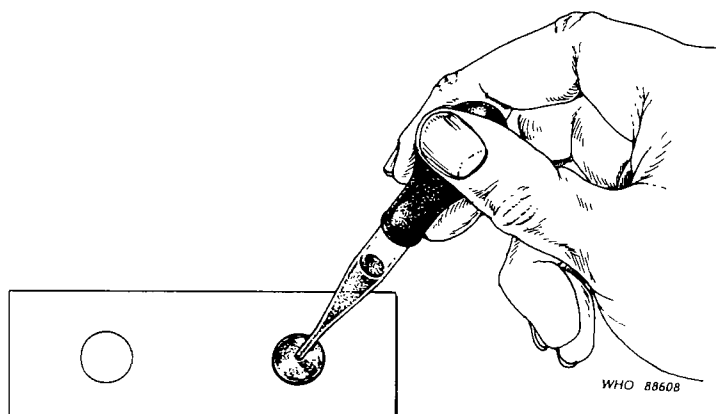
1. With a wax pencil write the patient's name or number and the date at the left-hand end of the slide.



2. Place a drop of saline in the centre of the left half of the slide and place a drop of iodine solution in the centre of the right half of the slide.

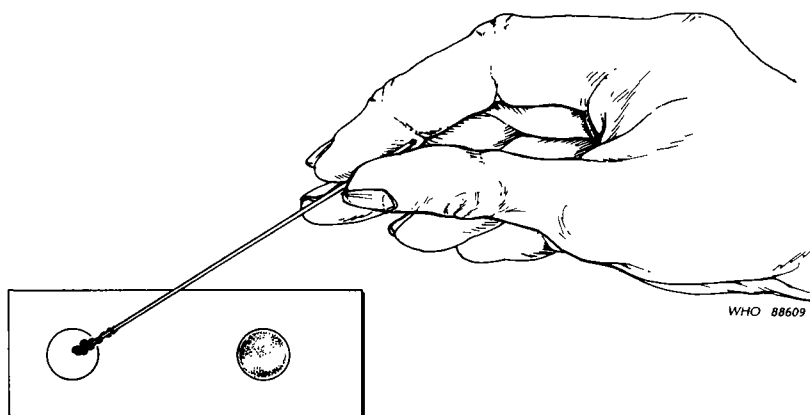
NOTE

If the presence of amoebic trophozoites is suspected, warm saline (37 °C) should be used.



¹ Throughout this manual the "reagent no." refers to the number assigned to the reagent in Annex 2.

3. With an applicator stick (match or toothpick), pick up a small portion of the specimen (size of a match head) and mix with the drop of saline.



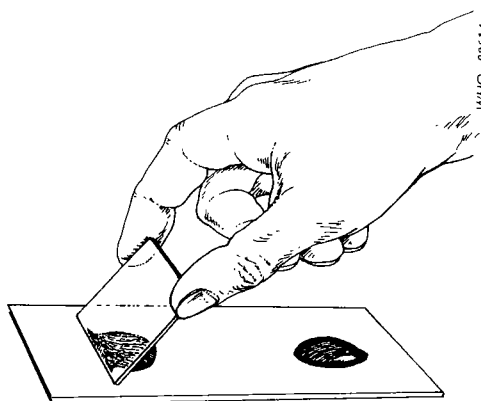
NOTE

Formed stool: take the portion of stool from an area to include inside and outside parts of the specimen.

Stool with mucus: if mucus is present, label a second slide with the patient's name or number. Put a drop of saline on the slide, pick up a small portion of mucus and mix with the saline. Trophozoites, if present, are sometimes more readily found in mucus than in the solid parts of the stool.

Loose watery stool: if mucus is not present, pick up a small portion of the stool (any part) and mix with the saline.

4. Similarly, pick up a small amount of the stool and mix with the drop of iodine, to prepare an iodine mount. If a wire loop is used, flame it after making the mount. If applicator sticks are used, discard them.
5. Cover the drop of saline and the drop of iodine with a coverslip. Hold the coverslip at an angle, touch the edge of the drop, and lower gently on to the slide. This will reduce the chance of including air bubbles in the mount.



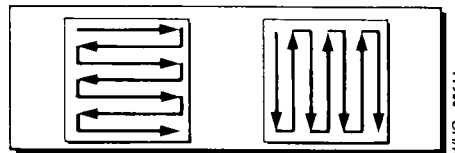
Buffered methylene blue (BMB) mount (to be prepared if amoebic trophozoites are seen in the saline mount)

Proceed as in steps 1 to 5 for "Direct saline and iodine mounts", but place a large drop of BMB on the slide instead of saline or iodine. Wait 5–10 minutes before

examining, to allow the stain to penetrate the trophozoites. BMB will overstain the trophozoites in about 30 minutes. Therefore the slide must be examined within 30 minutes after preparation.

Examination

1. Put the slide with the mounts on the microscope stage and focus on the mount with the $\times 10$ or low-power objective.
2. Regulate the light in the microscope field with the substage diaphragm. You should be able to see objects in the field distinctly. Too much or too little light is not good.
3. Examine the entire coverslip area with the $\times 10$ objective; focus the objective on the top left-hand corner and move the slide systematically backwards and forwards, or up and down.



4. When organisms or suspicious material are seen, switch to the high-dry objective, and increase the light by opening the substage diaphragm to observe the detailed morphology.

This is a systematic examination. If mounts are examined in this way, any parasites present will usually be found. If the mount is not examined systematically, parasites may be missed. Examine each microscopic field carefully, focusing up and down, before moving to the next field.

REMEMBER
EXAMINE MOUNTS SYSTEMATICALLY

Fig. 1 indicates which examinations should be carried out at laboratories at the different levels.

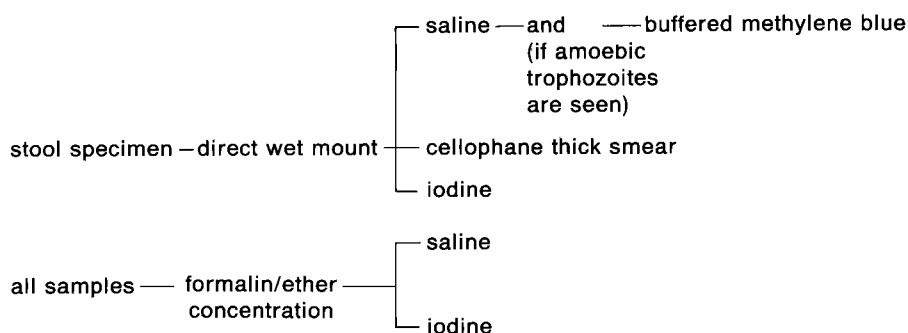
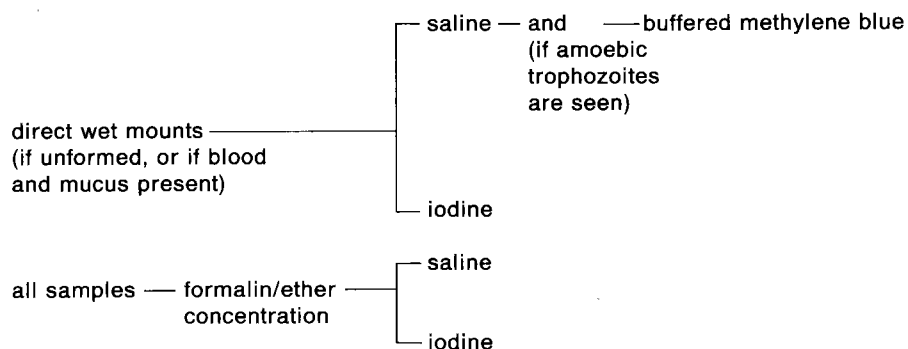
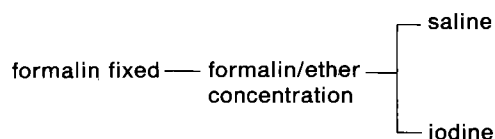
Identification of parasites

Worm eggs and larvae in saline mounts

Eggs may be easily detected and identified in saline mounts. They should not be stained (stains may interfere with identification). Most of the eggs are large enough to be recognized with the low-power ($\times 10$) objective, but a few small eggs will require a high-power, dry lens.

In saline mounts, larvae of *Strongyloides stercoralis* may be seen. Hookworm larvae are not usually present if the sample is fresh, but it may be necessary to distinguish between these two species if an old sample is examined.

The characteristics and features used to identify species of eggs and larvae are described in Section 2, pp. 67–70. The diagrams and keys in Section 2 can be used to help identify eggs and larvae.

Fig. 1. Techniques of stool examination according to level of laboratory**Health centre laboratory****District hospital***Unpreserved stool specimens**Preserved stool specimens*

Not all worms are found in every area of the world; some have a restricted geographical distribution. You should make a list of the species that are found in your area.

Protozoa in wet mounts*Saline wet mounts*

In saline mounts, trophozoites and cysts of amoebae and flagellates may be seen. Cysts will appear as round or oval, refractile structures; the trophozoites of amoebae may be round or irregular; the trophozoites of flagellates are usually pyriform (elongated, pear-shaped). In freshly passed faeces (the stool must not be more than 1 hour old), motile trophozoites may be seen. Motility can be very helpful in identifying species, especially in the case of flagellates. The characteristic motility of each species is described in Section 2, pp. 71–79.

Organisms may be detected with the low-power ($\times 10$) objective, but a high-power, dry objective will be necessary to identify reliably the structure as a cyst or

trophozoite. With the high-power, dry objective, you can see motility, inclusions like erythrocytes and yeasts in amoebic trophozoites, chromatoid bodies in amoebic cysts, and the shape and structural details (e.g., sucking discs, spiral grooves, or filaments) of flagellate trophozoites and cysts. You will not be able to see any detail in the nucleus in saline mounts. However, it is necessary to regulate carefully the microscope illumination so that the objects appear clearly. Too much or too little light will interfere with your observations. It is also necessary to focus up and down to see all the layers (levels) of the specimen. Remember to examine the whole coverslip area in a systematic manner to reduce the chances of overlooking organisms.

Buffered methylene blue wet mount

If you see amoebic trophozoites, or structures that resemble trophozoites, you should prepare and examine a BMB mount. After 5–10 minutes of staining, the trophozoites sometimes remain motile, but often they curl up in BMB preparations. (Do not confuse curled trophozoites with cysts; cysts do not stain with BMB solution.) In the trophozoites, the nucleus and inclusions (erythrocytes, yeasts) will stain dark blue; the cytoplasm will stain light blue. Occasionally, some trophozoites will not stain, so you should look for well-stained organisms. Look for peripheral nuclear granules (granules in the membrane around the nucleus); if these are present, the trophozoite is an *Entamoeba* species, and you must identify the species. (Characteristics for identifying amoebic trophozoites will be found in Section 2, pp. 71–74.) If there are no peripheral nuclear granules, the trophozoite is not an *Entamoeba* species.

Iodine wet mount

Iodine mounts are examined for amoebic and flagellate cysts. They can be detected with the $\times 10$ objective, but they are not as refractile as in saline mounts. High-power, dry magnification must be used to see the characteristics of the cysts and they must be measured to ensure correct identification.

In the iodine mount, cytoplasm of the cysts will stain yellow or light brown and nuclei will stain dark brown. In iodine-stained cysts of *Entamoeba*, the arrangement of the peripheral chromatin and the position of the karyosome can be seen. (If the peripheral chromatin is not present, the cyst is not an *Entamoeba* species.) These peripheral chromatoid bodies stain light yellow and may not be very clear. Sometimes, young cysts contain glycogen; this stains dark brown with iodine.

In iodine-stained flagellate cysts, the fibrils (filaments) can be seen.

Specific identification of amoebic and flagellate cysts can usually be made from iodine wet mounts. However, occasionally a definite identification cannot be made, and it may be necessary to use permanent stains.

Characteristics for identifying cysts will be found in Section 2, pp. 73–79.

Supplementary techniques

In addition to direct wet mounts, supplementary procedures are available for the diagnosis of intestinal parasites. The most commonly used procedures are concentration techniques for recovering eggs, larvae, and cysts, and permanent staining techniques for demonstrating trophozoites and cysts.

Concentration technique

If the number of organisms in the stool specimen is low, examination of a direct wet mount may not detect parasites. Thus, whenever possible, the stool should be concentrated. Worm eggs, larvae, and protozoan cysts may be recovered by concentration but protozoan trophozoites will NOT be seen as they are usually destroyed during the concentration procedure. This makes direct wet mount examination obligatory as the initial phase of microscopic examination.

The concentration procedure is indicated when the initial wet mount examination is negative despite the clinical symptoms indicating parasitic infection of a patient, and for the detection of *Schistosoma* and *Taenia*.

The concentration procedure recommended is the formalin–ether (or formalin–ethyl acetate) method.¹ All types of worm eggs (roundworms, tapeworms, schistosomes, and other fluke eggs), larvae, and protozoan cysts may be recovered by this method.

Materials and reagents

1. Applicator sticks, wooden
2. Bottles, dispensing or plastic “squeeze”, 250 ml or 500 ml. These bottles are convenient for adding formalin to the centrifuge tubes. However, any small bottles or flasks may be used.
3. Centrifuge, with head and cups to hold 15-ml conical tubes. Sealed buckets must be used.
4. Centrifuge tubes, 15 ml, conical (make a graduation at 7 ml and 10 ml with a grease pencil)
5. Cotton swabs
6. Coverslips
7. Funnel
8. Surgical gauze
9. Microscope slides
10. Pipettes, Pasteur, with rubber bulbs
11. Rack or support for tubes
12. Formalin, 10% (reagent no. 10). For everyday use, pour some of the solution into a “squeeze” bottle. Label the bottle.
13. Ether or ethyl acetate.¹
14. Lugol’s iodine, 1% solution—in a dispensing bottle with a pipette (reagent no. 18).
15. Saline solution, isotonic (reagent no. 24).

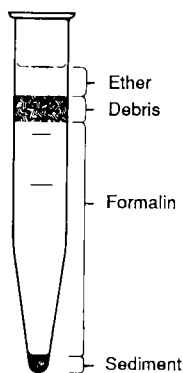
CAUTION

Ether is a highly flammable compound and will ignite and explode quickly if there is a flame or spark nearby. Store opened cans or bottles on an open shelf in the coolest part of the laboratory. Be sure the cans or bottles are stoppered. Do NOT put an opened container of ether in a refrigerator: fumes build up inside the refrigerator, even if the container is closed, and may explode when the door is opened. Do not put opened containers in a cabinet. It is better to leave the container on an open shelf so that the fumes can disperse readily.

Technique

1. Add 10 ml of 10% formalin to approximately 1 g of faeces and stir using an applicator stick, until you get a slightly cloudy suspension.

¹ If ether or ethyl acetate is not available, use ordinary petrol (gasoline) in exactly the same quantities as ether. Ethyl acetate is not as flammable or as explosive as ether, therefore it is less hazardous to use in the laboratory.



Four layers after final centrifugation

WHO 90560

2. Fit a gauze filter into a funnel and place the funnel on top of the centrifuge tube.
3. Pass the faecal suspension through the filter into the centrifuge tube until the 7 ml mark is reached.
4. Remove the filter and discard the filter with the lumpy residue.
5. Add 3 ml of ether or ethyl acetate and mix well for one minute.
6. Transfer back to the centrifuge tube and centrifuge for 1 minute. The tube should then look like the diagram below.
7. Loosen the fatty plug (debris) with an applicator stick, and pour away the supernatant by quickly inverting the tube.
8. Replace the tube in its rack and allow the fluid on the sides of the tube to drain down to the sediment. Mix well and transfer a drop to a slide for examination under a coverslip. Also make an iodine-stained preparation.
9. Use the $\times 10$ and $\times 40$ objectives to examine the whole area under the coverslip for ova, cysts, and larvae.

Examination of sediment

Mounts of concentrated material should be examined in the same way as described for direct wet mounts (see p. 13). The saline (or unstained) mount should be examined systematically, looking for eggs, larvae, and cysts. If cysts, or structures resembling cysts, are seen, you should examine the iodine mount to see more details.

Organisms will look the same as described for direct wet mounts. In saline mounts of formalin–ether (or ethyl acetate) concentrate, the nuclei of cysts are fixed and may be visible. However, iodine wet mounts should still be examined for more reliable identification.

Permanent staining techniques

Permanently stained slides are not made routinely in diagnostic practice and are not required for the identification of worm eggs or larvae. However, permanently stained preparations are occasionally required for the following purposes:

- identification of oocysts of *Cryptosporidium*;
- identification of protozoan trophozoites, if doubt exists;
- confirmation of the identity of protozoan cysts, where doubt exists;
- keeping a permanent record;
- sending to a reference laboratory for an expert opinion.

Staining for oocysts of *Cryptosporidium*

Oocysts of *Cryptosporidium* passed in faeces are spherical, measuring 4–6 μm in diameter. They may be concentrated using a modified formalin–ether technique, but must be identified by staining methods. The recommended method is the modified Ziehl–Neelsen technique. An alternative is the safranin–methylene blue technique.

Materials

Applicator sticks, wooden
Coverslips
Forceps
Microscope slides
Pen or marker for labelling
Rod, glass

Slide holder, for finished slides
 Small bottle of mounting medium
 Staining dishes
 Paper towel or sponge.

Modified Ziehl–Neelsen technique

Reagents

Carbol-fuchsin (reagent no. 4)
 Formalin (formaldehyde) (reagent no. 10)
 Hydrochloric acid–ethanol solution (reagent no. 13)
 Glycerol–malachite green (or methylene blue) solution (reagent no. 12)
 Hydrochloric acid–methanol solution (reagent no. 14)
 Water.

Preparation

1. Make a thin faecal smear, leave it to air-dry and fix it in methanol for 2–3 minutes. Further fixation in formalin vapour should be performed if possible, to reduce infectivity. (The sediment from formalin–ether extraction cannot be used.)
2. Stain the smear with cold carbol–fuchsin for 5–10 minutes.
3. Differentiate in 1% hydrochloric acid–ethanol until colour ceases to flood out.
4. Rinse in tap-water.
5. Counterstain with 0.25% malachite green (or methylene blue) for 30 seconds.
6. Rinse in tap-water.
7. Blot or drain dry.
8. Examine using the high-power, dry objective and confirm the morphology using oil immersion. Measure the cysts. *Cryptosporidium* cysts measure 4–6 μm .

When stained by this technique, *Cryptosporidium* oocysts appear as bright rose-pink spherules on a pale green background. Different degrees of internal staining are seen, depending on the age and condition of the oocyst.

Safranin–methylene blue technique

Reagents

Hydrochloric acid–methanol solution (reagent no. 14)
 Methylene blue–phosphate solution (reagent no. 19)
 Safranin solution (reagent no. 23)
 Water.

Preparation

1. Prepare a thin smear of faeces.
2. Air-dry the smear. Pass the slide once through the flame of a spirit lamp.
3. Fix the smear in hydrochloric acid–methanol solution for 4 minutes.
4. Wash with clean tap-water.
5. Stain the smear with 1% aqueous safranin solution for 1 minute. Heat the stain by holding a lighted spirit swab under the slide. Do not let the stain dry on the smear.
6. Wash off the stain with clean tap-water.
7. Counterstain with 1% (w/v) methylene blue solution for 30 seconds.
8. Wash with clean tap-water and dry the slide.
9. Scan the smear for oocysts with the $\times 40$ objective and identify oocysts with a $\times 100$ objective. *Cryptosporidium* oocysts are round to oval orange–pink bodies (4–6 μm diameter). The sporozoites within the oocysts stain slightly darker.

The trichrome stain technique for protozoa

The trichrome stain procedure is of value for staining fresh faecal specimens, as well as material fixed with polyvinyl alcohol (PVA). However, it is important to ensure that the shelf-life of the reagents is not exceeded and that the method is followed exactly, if reliable results are to be obtained.

Reagents

Acetic acid–alcohol destain solution (reagent no. 1)

70% ethanol (reagent no. 7)

95% ethanol¹

Carbol–xylene solution (reagent no. 5) or absolute ethanol

Iodine–alcohol solution (reagent no. 16)

Schaudinn's fixative (reagent no. 25)

Trichrome stain solution (reagent no. 27)

Xylene¹

Preparing the staining dishes, and replacement of the stains

(i) Label the staining dishes necessary for the procedure and arrange in a row in the following order:

1. Schaudinn's fixative
2. Iodine–alcohol solution
3. 70% ethanol (1)
4. 70% ethanol (2)
5. Trichrome stain solution
6. Acetic acid–alcohol destain solution
7. 95% ethanol (1)
8. 95% ethanol (2)
9. Carbol–xylene or absolute ethanol
10. Xylene

Put several layers of paper towel in front of the dishes. If paper towel is not available, use sponges or newspaper.

- (ii) Fill each dish with the appropriate solution. Be sure to use the Schaudinn's fixative with acetic acid added.
- (iii) Pour a small amount of mounting medium into a small bottle with a lid or stopper. (Keep the big stock-bottle tightly closed to prevent drying as a result of evaporation.)

The set of staining dishes is arranged in a convenient place and left, ready for use as needed. If the dish tops have ground glass rims, put a thin layer of petroleum jelly on the ground surface to make a good seal with the cover.

The solutions will need to be changed at intervals as follows:

1. Schaudinn's fixative—change every month. Pour out the used fixative into a waste bottle for organic solutions and replace with fresh solution.
2. Iodine–alcohol solution—change every 3 weeks. If the colour fades, or becomes too pale, replace immediately.
3. 70% ethanol (1). This solution will become yellow with iodine from the iodine–alcohol. Change it every 3 weeks or after staining 30 smears, whichever is sooner.
4. 70% ethanol (2)—change every 3 weeks.
5. Trichrome stain solution—change only when solution becomes greenish. Gently rock the jar back and forth. If the stain on the walls of the jar looks green rather than purple, discard the stain in the jar and replace it with fresh stain.

¹This reagent requires no preparation. It is used directly from the container in which it is purchased.

6. Acetic acid–alcohol destain solution—change after destaining 20 smears, or each week, whichever comes first.
7. 95% ethanol (1)—change every week.
8. 95% ethanol (2)—change every 2 weeks.
9. Absolute ethanol—change every week; carbol–xylene—change every month.
10. Xylene—change every month.

Keep a record of each solution and the date it was poured into the jar, for example:

| <i>Name of solution</i> | <i>Starting date</i> | <i>Changing date</i> |
|-------------------------|----------------------|----------------------|
| Schaudinn's | 13 January 1990 | 12 February 1990 |
| Iodine–alcohol | 7 January 1990 | 28 January 1990 |

Check this record each week. In this way, the stain solutions will always be satisfactory for staining faecal smears.

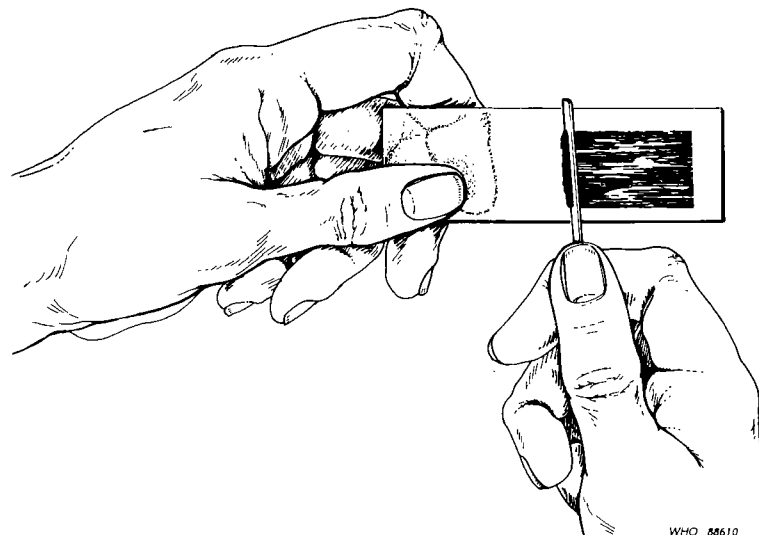
NOTE

Keep covers on the stain jars at all times except when slides are being put in or taken out. Do not leave the covers off while staining. The solutions will absorb moisture from the air if not kept covered, and will become unsatisfactory for staining.

The carbol–xylene solution and xylene are dehydrating and clearing solutions; they remove water from the smear and make the material translucent so it can be examined. If moisture gets into these solutions, they will not work properly. Sometimes beads of moisture will collect and can be seen in the jars. If this happens, discard the solution and replace with fresh solution.

Technique

1. Label a microscope slide with the patient's name or number, and the date.
2. With an applicator stick, pick up a small amount of the stool and spread it in a thin smear by rubbing the material back and forth with the applicator stick over the middle part of the slide. The layer of stool must be as uniform and even as possible and of the correct density.



This must be done quickly to prevent drying of the specimen. Immediately put the smear into Schaudinn's fixative.

NOTE

If the stool is hard, a small portion can be mixed with saline to soften it and the smear made from this.

**THE SMEAR MUST NOT DRY
FROM THE TIME IT IS MADE
UNTIL THE TIME IT IS MOUNTED**

3. Fix with Schaudinn's fixative for 1 hour at room temperature. (The smear may be left in the fixative for as long as 2 days, if necessary.) Put the slide in the dish, so that the end with the patient's name is at the top.
4. Use forceps to pick up the slide from the dish. Drain the excess fluid by touching the end of the slide with a paper towel or sponge. After draining, put the slide into the next staining dish.
5. Leave in iodine-alcohol solution for 1 minute (not more or less). Remove the smear and drain as directed in step 4. Transfer into next dish.
6. Leave in 70% ethanol (1) for 1 minute. Remove slide and drain.
7. Leave in 70% ethanol (2)¹ for 1 minute. Remove slide and drain.
8. Stain with trichrome stain solution for 8 minutes. Remove slide and drain.
9. Destain with acetic acid-alcohol solution—hold the slide with forceps and dip it in the solution twice (total time: 5 seconds). The acid-alcohol will continue to destain the specimen as long as it is in contact with the smear, and 5 seconds is therefore enough time for dipping the slide in the dish of acetic acid-alcohol. (Do NOT put the slide in the dish and count to 5.)
Drain the slide on a paper towel or sponge. Immediately rinse the smear in the 95% ethanol (1) to remove the acid.
10. Dip the slide once in the 95% ethanol (1) for 1–2 seconds. Drain the smear before putting it in the next dish.
11. Dip the slide twice in the 95% ethanol (2) for 2–3 seconds. Drain the smear before putting it in the next dish.
12. Dip the slide into the carbol-xylene or absolute ethanol for 1 minute. Drain the smear before putting it in the next dish.
13. Leave in xylene for 2–3 minutes.
14. Remove the slide and drain. DO NOT LET THE SLIDE DRY BEFORE MOUNTING WITH THE COVERSLIP. If it starts to dry, dip it in the xylene again—but drain the excess xylene before putting the mounting medium on the smear.
15. Lay the slide flat on a paper towel, or a piece of newspaper, and with a glass rod put 3 or 4 drops of mounting medium on the smear. Hold a coverslip at an angle and touch it to the edge of the smear. Lower it gently on to the smear so the medium spreads out under the coverslip and air bubbles are not trapped between the coverslip and smear.

NOTE

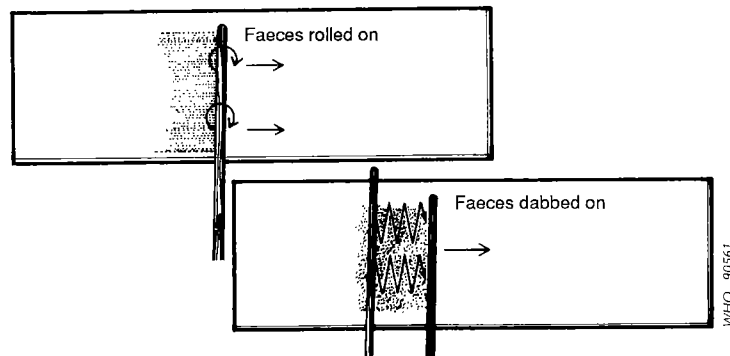
If more than one smear is being stained at the same time, destain each one separately. Take one smear from the stain, drain it, destain it, rinse in the 95% ethanol, drain, and put it in carbol-xylene or absolute ethanol (steps 9–12). Then remove another slide from the stain and treat it the same way. Continue until all of the smears have been destained.

¹ If the staining procedure must be interrupted, the slide may be left in the 70% ethanol (2). This is the only stage at which the process may be interrupted. If the staining procedure has gone past the second 70% ethanol (step 7), it must be completed; it must not be stopped or interrupted after step 7.

If more than 1 slide is being stained at the same time, remove from the xylene one at a time, drain and mount. If some of the smears remain in the xylene for 4 or 5 minutes, they will not be harmed. Leave the mounted preparation on a table or counter-top in a flat, horizontal position on a paper towel or a piece of newspaper; it should remain in a flat position until it dries. This may take overnight or longer. However, although not completely dry, the preparations may be examined after 30 minutes. After examination, do not attempt to remove the immersion oil until the mount is completely dry (about 24 hours) as wiping off the oil may remove the coverslip. If this should happen, immediately rinse the smear in xylene for 5 seconds and remount.

Technique for PVA-fixed stool specimens

1. Stir the PVA-fixed material (see pp. 28–29) gently but thoroughly, to mix the stool evenly with the fixative.
2. Label a microscope slide as indicated in step 1 for fresh stools.
3. Dip an applicator stick into the PVA-fixed specimen to pick up some of the material. Spread the material by rolling it on to the slide with the stick. The material can also be spread by dabbing it on—moving the stick up and down as you spread the specimen. The layer of the specimen should be as uniform and even as possible. Fine print should be just visible through the smear, but not clear enough to read. Preparations that are too thick do not stain well and are difficult to examine. If the preparation is too thin, there is not enough material for a reliable examination.



4. Smears MUST DRY before they can be stained. Leave the smears on a flat surface or in a slide holder to dry. They can be left at room temperature or in a 37 °C incubator. Drying takes 8–10 hours, usually overnight. It is better to make the smears one day, let them dry overnight, and stain them the next day. If necessary, dry unstained smears may be kept 3–4 weeks before staining.
5. Put the dried PVA-fixed smear into iodine–alcohol solution.
 - (i) Iodine–alcohol solution—15 minutes. Drain the smear as indicated previously for smears made from fresh faeces.
 - (ii) 70% ethanol (1)—5 minutes. Drain.
 - (iii) 70% ethanol (2)—5 minutes. Drain.
 - (iv) Trichrome stain solution—8 minutes. Take one slide out of stain and drain it. If more than one slide is being stained, leave the others in the stain. Destain only one slide at a time.
 - (v) Acetic acid–alcohol destain solution—hold the slide with the forceps and dip in and out of the destain 2 or 3 times (total time—5 seconds). Drain slide for 1–2 seconds. (See step 9 for fresh faeces, p. 21.)
 - (vi) 95% ethanol (1)—dip the slide in the solution twice to rinse off the acid. Drain slide for 2 seconds.
 - (vii) 95% ethanol (2)—5 minutes. Drain smear.
 - (viii) Carbol–xylene solution or absolute alcohol—7 minutes. Drain smear.

- (ix) Xylene—10 minutes.
- (x) Take one slide from the xylene, drain it for 2 seconds, then lay it flat on a paper towel or piece of paper. For mounting, proceed as indicated for fresh faecal specimens (p. 21).

Microscopic appearance of the stained smear

The appearance of smears from unpreserved and PVA-fixed stools is the same, but there is variation from smear to smear because:

- the thickness of the smears will not be exactly the same,
- the destaining time may be slightly different, and
- stool specimens vary from person to person.

In general, the background material stains green or blue-green. Occasionally a specimen will stain red, but this does not interfere with recognizing and identifying organisms. The different inclusions in the stool stain as follows:

GREEN (or blue-green)

- cytoplasm of trophozoites and cysts (well-fixed and well-stained),
- cytoplasm of pus cells and tissue cells,
- yeasts and moulds (usually),
- degenerate protozoa,
- organisms that have been destained too much or too little,
- *Blastocystis hominis* (a protozoan often seen in stools)—contains red granules around the outer edge of the cell.

PURPLE (or blue-purple or red-purple)

- cytoplasm of trophozoites and cysts (sometimes),
- *Entamoeba coli* cysts (sometimes),
- ingested red blood cells and bacteria inside trophozoites.

RED (or purple-red)

- ingested red blood cells and bacteria inside trophozoites,
- yeasts and moulds (sometimes),
- cysts that have not been properly fixed,
- nuclei of pus cells and tissue cells,
- nuclear chromatin of trophozoites and cysts,
- chromatoid bodies of amoebic cysts.

Examination of the stained smear

1. Place the mounted, completely dry smear on the stage of the microscope and focus on it with the low-power objective ($\times 10$). Select an area that looks neither too thin nor too thick. If the smear appears uniform (all areas are about equally thick), focus on any area with the $\times 10$ objective. Some of the smear may be too thick to see through easily; other areas may be too thin. If the whole smear is heavy or thick, look for the thinnest part. Better stained organisms will usually be seen in the thinner areas. If the whole smear looks light or thin, look for the heavier or thicker areas. Organisms will probably be better stained in thicker areas.
2. Put a drop of immersion oil on the selected area and change to the oil-immersion objective. Stained smears of stool specimens must be examined with the oil-immersion objective. Do not use the high-power, dry objective.
3. Focus carefully with the oil-immersion objective. Regulate the microscope illumination with the substage iris diaphragm so that there is adequate light, and cells, bacteria, and other things in the field may be seen distinctly. Move the

slide across the microscope stage while focusing carefully on each new field to see things at different levels in the smear. You should examine about half of the smear; you do not need to examine the entire coverslip area as directed for saline mounts.

4. You are looking for *Entamoeba histolytica* trophozoites and cysts and *Giardia* trophozoites and cysts. If there are many organisms in the specimen, you may find them within a few minutes. If you do not, continue to examine the smear. If you do *not* find *E. histolytica* or *Giardia* organisms report the smear as "No pathogens found".

Identification of parasites in stained smears

In stained smears, both trophozoites and cysts of amoebae and flagellates will be seen. The cytoplasm will stain greenish-blue or green; the nuclei, inclusions like red blood cells and bacteria, chromatoid bodies in amoebic cysts, and fibrils (filaments) in flagellates will usually stain red or purple. Glycogen is dissolved during the staining process and is not visible in stained preparations. You will see a clear or white area where the glycogen has been removed.

Characteristics used to identify protozoa in stained smears are presented in Section 2, pp. 71-79.

Anal swabs for pinworm

Anal swabs are used to detect the presence of pinworms (*Enterobius vermicularis*). Pinworms are more common in children than adults. Often, however, if one child in a family has pinworms other members of the family will be infected. Therefore, if a child is found positive, it is desirable to examine swabs from all members of the family group, especially the children. Pinworm eggs are usually found in the folds of skin around the anus. They rarely appear in the stool.

Collection of specimens

Materials for Method A

Centrifuge
Cotton swabs
Microscope slides
Pipettes, Pasteur, with rubber bulbs
Saline solution to moisten cotton swabs
Test tubes, 100 × 13 mm.

Technique—Method A

Spread buttocks apart, and rub cotton swab over the area around the anus, but do not insert into the anus. Place the cotton swab in the tube.

Materials for Method B

Transparent adhesive tape
Tongue depressor or plastic spoon with handle 10 cm long
Microscope slide.

Technique—Method B

1. Fold a strip of transparent adhesive tape over the end of a spoon handle or tongue depressor.

2. Separate the patient's buttocks with the other hand. Press the end of the spoon covered with tape against the skin around the anus in several places.
3. Place the tape with the sticky side down on a microscope slide. Before examining the slide, lift the tape up and place a drop of immersion oil under the middle of the tape and replace the tape. This will improve the transparency of the tape.

Wash your hands after sample collection; otherwise, eggs that may have contaminated your hands could get into your mouth and lead to infection.

In order to increase the chances of picking up eggs, the swab should be taken between 22h 00 and midnight, or early in the morning before the patient urinates, defecates, or bathes. It may be necessary to collect several swabs before a positive diagnosis can be made.

Examination procedure

Tape-swab slides may be examined directly. For cotton swabs, proceed as follows:

1. Into the tube containing the swab, pour enough saline to cover the cotton swab—about 5 ml.
2. Let stand for 4–5 minutes.
3. Remove the swab from the saline. Roll it against the side of the tube to squeeze out the saline.
4. Discard the swab.
5. Concentrate by centrifugation for 1 minute.
6. With a pipette, remove the supernatant fluid *carefully* so as not to disturb the small quantity of sediment present.
7. With a pipette, transfer the sediment to a slide for examination. Reduce the microscope illumination and focus up and down to see the *Enterobius* eggs (for description see Section 2, pp. 67–69).

Cellophane faecal thick-smear for diagnosis of intestinal schistosomiasis (Kato-Katz technique)

The cellophane faecal thick-smear examination technique has proved to be an efficient means of diagnosis of intestinal schistosomiasis and intestinal helminths. Cellophane thick-smear slides can be prepared in the field, stored in microscopic slide boxes, and shipped great distances, for examination at a central laboratory if required. The technique is not suitable for examining larvae, cysts, or eggs from certain intestinal parasites.


Materials and reagent

Applicator sticks, wooden
 Screen, stainless steel, nylon or plastic—60–105 mesh
 Template, stainless steel, plastic or cardboard
 Microscope slides
 Cellophane, 40–50 μm thick, strips 25 \times 30 or 25 \times 35 mm
 Flat-bottomed jar
 Forceps
 Toilet paper or absorbent tissue
 Newspaper
 Glycerol–malachite green (or methylene blue) solution (reagent no. 12).


Technique

Care must be taken during collection of stool specimens. Always wear gloves to avoid contamination of the fingers.

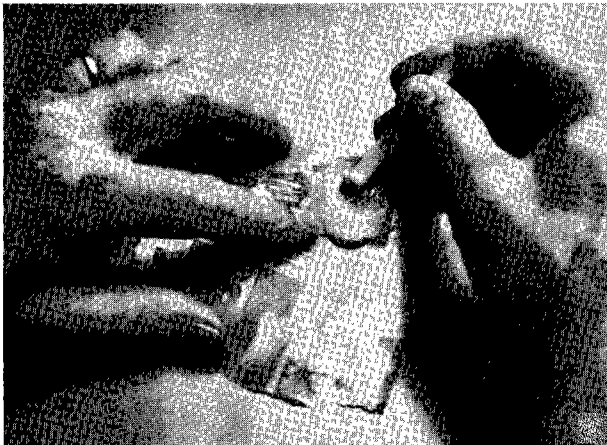Fig. 2. Cellophane faecal thick-smear examination technique (Kato) for diagnosis of intestinal schistosomiasis and gastrointestinal helminth infections




1. Different materials are available. This slide shows the plastic spatula, plastic template and nylon screen in a commercially available Kato-Katz kit. The first two items and the microscope slides may be reused. The nylon screen is disposable. A few kits may be ordered to provide standard reusable templates.



2. The nylon screen and the cellophane required for the thick smear technique may be purchased in bulk. From the roll, cellophane is cut into 25–30 mm sections and placed in a wide-mouth, flat-bottom jar containing a 50% (or greater) glycerol solution with malachite-green or methylene blue stain (100 ml water, 100 ml glycerol, 1 ml 3% aqueous malachite green or methylene blue).




3. The procedure for this technique is the same no matter which material is used. The faecal specimen is forced through the screen by a spatula to separate faecal material from the large debris.




4. The screened faecal material is transferred to the template which is laid flat centrally on a microscope slide. The template hole is completely filled with screened faecal material and levelled to the surface of the template. The Kato-Katz template shown delivers 41.7 mg of faeces. The number of eggs observed is multiplied by 24 to obtain the number of eggs per gram of faeces.

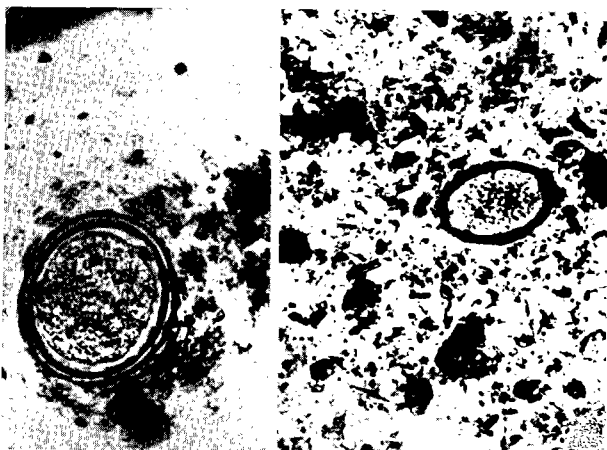
Fig. 2. (continued)




5. The cellophane square soaked in glycerol for at least 24 hours is placed over the faecal specimen.



6. The slide is inverted against a piece of glass or another glass slide and the faecal specimen spread evenly under the cellophane as shown here. After the slide is prepared an additional drop of glycerol may be placed on the cellophane and the edges of the cellophane pressed smooth to ensure conservation of the slide. If air bubbles form under the cellophane during storage, a couple of drops of glycerol on the cellophane allowed to stand overnight will eliminate the bubbles. Cellophane thick-smear slides can be prepared in the field, stored in microscope slide boxes and shipped great distances, which permits examination at a central laboratory if required within days or weeks after preparation.



7. *Ascaris* (left) and *Trichuris* eggs (right) are visible at any time. Hookworm eggs (not shown) are visible for up to 30 minutes after preparation.



8. The ideal time for observing *S. mansoni*, *S. intercalatum* or *S. japonicum* eggs is 24 hours after preparation. In bright sunlight the slides clear rapidly and a 24-hour delay may not be necessary.

1. Soak the cellophane strips in the 50% glycerol–malachite green (or methylene blue) solution for at least 24 hours before use.
2. Transfer a small amount of faeces on to a piece of scrap paper (newspaper is ideal).
3. Press the screen on top of the faecal sample.
4. Using a flat-sided applicator stick, scrape across the upper surface of the screen to sieve the faecal sample.
5. Place a template on a clean microscope slide.
6. Transfer a small amount of sieved faecal material into the hole of the template and carefully fill the hole. Level with the applicator stick.
7. Remove the template carefully so that all the faecal material is left on the slide and none is left sticking to the template.
8. Cover the faecal sample on the slide with a glycerol-soaked cellophane strip.
9. If an excess of glycerol is present on the upper surface of the cellophane, wipe off the excess with a small piece of toilet paper or absorbent tissue.
10. Invert the microscope slide and press the faecal sample against the cellophane on a smooth surface (a piece of tile or flat stone is ideal) to spread the sample evenly.
11. Do not lift the slide straight up. The cellophane may separate. Gently slide the microscope slide sideways holding the cellophane.

Preparation of the slide is now complete. It may be necessary to wipe off excess glycerol with a piece of toilet paper to ensure that the cellophane stays fixed. After practice you can obtain perfect preparations. The various stages of preparation of the thick smear are shown in Fig. 2.

Thick or hard stool specimens

The main problem with the thick-smear technique has been that it is impossible to see the helminth eggs in some hard (constipated) stool specimens. In such cases:

- after preparation by the standard method, be sure to wait 24–48 hours before counting eggs on these slides—the slide may clear slowly;
- make another pair of samples on a large (5 × 7.6 cm) microscope slide and use a slightly larger piece of cellophane (35 × 35 mm), then press very hard to flatten the specimen as much as possible;
- when the large slide is used, the stool may be softened with saline or glycerol before sieving.

Proper reading of slides

At ambient temperature the slide should be kept for at least 24 hours before microscopic examination (see below regarding hookworm eggs). If the slide is placed in an incubator (40 °C) or under an intense fluorescent or incandescent light in the laboratory, or in sunlight in the field, it may be read within minutes.

To facilitate the microscopic reading, one or two drops of eosin in saline (1:100) may be placed on the upper surface of the cellophane, left for 3–5 minutes, then wiped off with a piece of toilet paper or absorbent paper. This makes the *Schistosoma* eggs easier to see.

Sending specimens to a reference laboratory

If specimens are to be sent to another laboratory for examination, they must be preserved to keep the parasites in good condition. Two preservatives are used:

- 10% formalin—preserves eggs, larvae and cysts for wet mount examinations;
- PVA-fixative—preserves trophozoites and cysts so that permanent stained smears can be made.

Materials and reagents

Adhesive tape
 Applicator sticks, wooden
 Bottles, 1000 ml
 Labels
 Pen or marker for labelling
 Vials, 20 ml, with tight-fitting screw-caps
 Formalin (formaldehyde), 10% (reagent no. 10)
 PVA-fixative¹ (reagent no. 22).

Preservation of specimens

1. Label two 20-ml vials with the patient's name or number. Write F in the upper right-hand corner of the label on one vial; write PVA in the upper right-hand corner of the label on the other vial.
2. Fill the "F" vial about half full with 10% formalin. Fill the "PVA" vial about half full with PVA-fixative.
3. With an applicator stick, pick up a portion of the stool to include areas from the inside and edges of the sample and mix with the 10% formalin. Be sure to mix *very* well; break up lumps. Use enough, but not too much, stool so that the mixture will occupy about 2/3 to 3/4 of the vial.
4. With an applicator stick, pick up a portion of the softest part of the stool and mix with the PVA-fixative as described for formalin. The total amount of stool-PVA mixture should not occupy more than 3/4 of the vial. Be *very* sure that the stool is thoroughly mixed with the fixative. Break up lumps by crushing them against the side of the vial.
5. Screw the caps of the vials securely. Wrap a piece of adhesive tape around the top of each vial to prevent leaking.
6. Pack the vials carefully in a box or shipping container and send to the reference laboratory. Be sure that the vials are surrounded by absorbent material (e.g., cotton wool, newspaper) and are packed so they will not break.
7. Be sure to include the necessary information: patient's name or number, date of shipping, organisms you found.

Disposal of specimens

1. If stools are collected in paper boxes, the best way to dispose of them is by burning the entire container. If they cannot be burned, or if the stool was collected in a metal or glass container, add enough 10% formalin to cover the stool left in the container. This will kill any parasites that might be present. Allow to stand for 1 hour or more before discarding or washing (if the container is glass).
2. Slides used for wet mounts should be put in a pan of disinfectant (e.g., sodium hypochlorite) for at least 1 hour before washing. Use an applicator stick to push the coverslip off into a beaker or small pan of disinfectant and then put the slide into another pan of disinfectant.
 Coverslips break easily, and if put in with the slides, they may break and cut the hands of the person washing them.

¹ Preparation of PVA-fixative is complicated, and involves poisonous and corrosive solutions. The technique is presented in Annex 2 (reagent no. 22), but preparation is perhaps best done in a higher level laboratory. Alternatively, the fixative may be purchased already prepared.

3. Funnels, stoppers, and centrifuge tubes should also be put into disinfectant for 1 hour before washing.
4. Applicator sticks and gauze squares should be burned. If burning is not possible, they can be discarded after soaking in disinfectant.

Quality control for faecal examination

To ensure accurate and reliable results, quality control must be applied to laboratory procedures for diagnosing parasitic infections. Controls must apply to collection of specimens, preparation of reagents, performance of the techniques and examination of the final preparations.

Collection of specimens

If faecal specimens are not properly collected and taken care of before examination, they will be of little or no value for accurate diagnosis. This is especially true of protozoa. Amoebic trophozoites will begin to degenerate 1–2 hours after passage and alterations in appearance may result in erroneous identification. Flagellate trophozoites may also undergo changes that would make differentiation difficult. Cysts will deteriorate if faecal specimens are left standing for many hours or overnight, especially if the temperature is high.

Helminth eggs and larvae are less affected by the age of the specimen than are protozoa. Nevertheless, changes may occur that would affect identification. Hookworm eggs, for example, may become embryonated and larvae may hatch from the eggs. Even *Ascaris* eggs may develop to multicellular stages. In addition, larvae may degenerate in old stools making it impossible to identify the species.

To ensure that good specimens are provided for examination, pay attention to the following points:

1. Use clean, dry containers for collecting faeces. (Dirt will interfere with examinations and may introduce free-living organisms from the soil that would cause problems in identifying the species. Urine and water will destroy trophozoites, if present).
2. Have the specimen brought to the laboratory as soon as it is passed to prevent deterioration of protozoa and alterations in the morphology of protozoa and helminths. Note the patient's name and the date and time of passage on the specimen.
3. Accept only freshly passed specimens for examination. Do not attempt to examine old specimens or those contaminated with dirt, water, or urine. Instead, ask the patient to pass another specimen.
4. If specimens cannot be examined as soon as they arrive, put them in a refrigerator (4–5 °C) or in the coolest, shadiest area in the laboratory. Do not leave them in the sun.
5. Examine diarrhoeal specimens and those containing blood and mucus immediately upon their receipt in the laboratory.

Preparation of reagents

Reagents should be prepared exactly according to the formula and directions. Do not alter the ingredients, or their quantity, or the method of preparation in any way. Store reagents as recommended in the preparation procedure.

Some reagents will last indefinitely if kept properly stoppered and out of direct sunlight. Examples are formalin solutions, isotonic saline, fixatives, and alcohol solutions (unless evaporation occurs). Other reagents may last for only a short time and are ineffective if too old. The “life” of each solution is indicated in the directions for preparing it.

1. Label all reagents with the date of preparation. Keep records for each solution. Review these every week and discard outdated solutions.
2. Many of the solutions used in the method for trichrome stain need to be changed at regular intervals. The intervals are stated in the directions for that technique and must be observed. Failure to do so will result in poor preparations that are of no value for diagnosis.

Performance of techniques

No procedure used for examining faecal specimens is 100% effective—that is, the procedures will not always recover all the species present and, if a particular species is present in only very low numbers, they may fail to demonstrate them when used on a single specimen. Because the techniques are not perfect, you should perform them as carefully as possible for optimum results. Also, be sure to use techniques that are appropriate for the material you are examining.

Direct wet mounts

1. Be sure the density of the mount is correct. You should be able to read small print through it (but not too clearly). If it is too thick or too thin, observation of the elements in the mount may be difficult.
2. Be sure to prepare fresh iodine solutions every 10–14 days. Old iodine will not stain cysts properly. The iodine must not be too strong or the faecal material may clump and trap organisms in the clumps so that they cannot be seen. If the iodine is too weak, it will not stain cysts properly.

Concentration procedure

1. Select a fully representative sample of the stool for concentration.
2. Prepare well mixed suspensions of faeces and water or saline.
3. Use the appropriate quantities of materials.
4. Use the correct centrifuge speed and time.
5. Prepare and examine mounts carefully as described for direct wet mounts.
6. Do not discard the tube containing the concentrated material until you have completed your examination. You may need to make another mount.

Staining procedure

1. Select soft portions of the stool, and portions of mucus, if present, for making smears for staining.
2. Be sure that solutions are in good condition. Change them as described in the procedures for staining. Keep the bottles of stock solutions tightly closed and store away from direct sunlight.
3. Be sure to keep dishes covered. Keep the covers on except when putting slides into, or taking them out of, the dish. If the staining dishes are left uncovered, the solutions may evaporate or debris may get into them and adhere to the preparation.

4. Use the correct quantity of mounting medium. Too much medium may result in a thick layer through which it will be difficult to focus, and you will not be able to see the smear clearly. Too little medium will leave gaps under the coverslip. If the smear was prepared from fresh, unpreserved faeces, areas where there are gaps may become unsatisfactory for diagnosis. Gaps in the medium also make the mount difficult to examine.
5. Always examine stained smears with the oil-immersion objective. Use the $\times 10$ objective to focus on the smear. If the smear is not uniform, locate an area for examination where the smear is not too thin or too thick and the staining is good. Then change to the oil-immersion lens and examine for protozoan trophozoites and/or cysts.

REMEMBER

RELIABLE AND ACCURATE PARASITE IDENTIFICATION DEPENDS ON:

- **COLLECTING SATISFACTORY SPECIMENS**
- **PREPARING AND MAINTAINING REAGENTS CORRECTLY**
- **CAREFUL PERFORMANCE OF APPROPRIATE TECHNIQUES AND THOROUGH EXAMINATION OF FINISHED PREPARATIONS**

Urine specimens

Urine specimens are usually examined for *Schistosoma haematobium* eggs. *Trichomonas vaginalis* trophozoites may also be seen. Microfilariae of *Wuchereria bancrofti* and *Onchocerca volvulus* may be found in the centrifuged sediment of sometimes milky urine from patients in countries where filariasis is endemic.

In areas where schistosomiasis is endemic, the first indirect evidence of infection is haematuria and/or proteinuria, detectable using a reagent strip. Gross haematuria indicates heavy infection.

Collection of urine for diagnosis of *Schistosoma* infection

The number of ova in the urine varies throughout the day, being highest in urine obtained between 10h 00 and 14h 00. The specimen should be collected between these times and consist of a single, terminal urine of at least 10 ml. Alternatively a 24-hour collection of terminal urine can be made. The whole specimen must be examined as ova may be very scanty. Ask the patient to pass the urine into a clean flask or bottle, and examine the urine at once.

If the urine must stand for an hour or longer, add 1 ml of undiluted formalin (37% formaldehyde solution) to each 100 ml of urine. This will preserve any eggs that might be present.

NOTE

If formalin is not available, 2 ml of ordinary household bleach can be added to each 100 ml of urine.

WARNING

Formalin and bleach are corrosive, and dangerous if swallowed.

Examination of urine

The two methods used for detection of *Schistosoma haematobium* ova are sedimentation and filtration. The sedimentation method is less sensitive but cheaper and simpler to perform. The filtration technique is used in public health care mainly when quantitative information is required.

Sedimentation method for 24-hour terminal urine collection

Materials

Centrifuge, with head and cups to hold 15-ml tubes
Centrifuge tubes, conical, 15 ml
Coverslips
Flask, conical for urine collection
Microscope slides
Pen or marker for labelling
Pipettes, Pasteur, with rubber bulbs.

Technique

1. Shake the urine specimen well and pour into a conical urine flask.
2. Allow the urine to sediment for 1 hour. Withdraw the supernatant, transfer the sediment into a centrifuge tube, and centrifuge at 2000 g for 2 minutes.
3. Examine the deposit of the centrifuged sample for the presence of ova, using the $\times 10$ objective to screen the whole of the deposit.

Do not increase the centrifugation time and do not exceed 2000 g as this may rupture the ova and release miracidia.

- **PROCESS AS SOON AS POSSIBLE**
- **SHAKE CONTAINER BEFORE POURING**
- **LABEL SLIDES/TUBES/PAPERS CAREFULLY**

Syringe filtration method**Materials and reagents**

Coverslips

Filter holder, diameter 13 mm or 16 mm

Forceps

Syringe, plastic, 10 ml

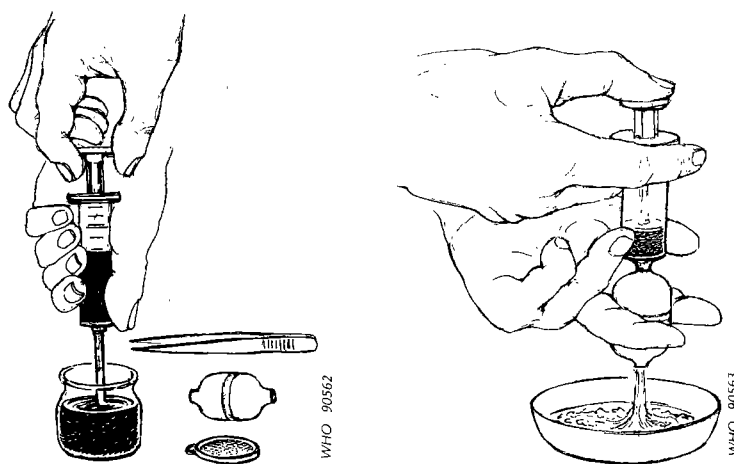
Membrane filter,¹ 12 μm or 20 μm (polycarbonate), nylon filter, or paper filter

Microscope slides

Lugol's iodine (stock 5% solution) (reagent no. 17).

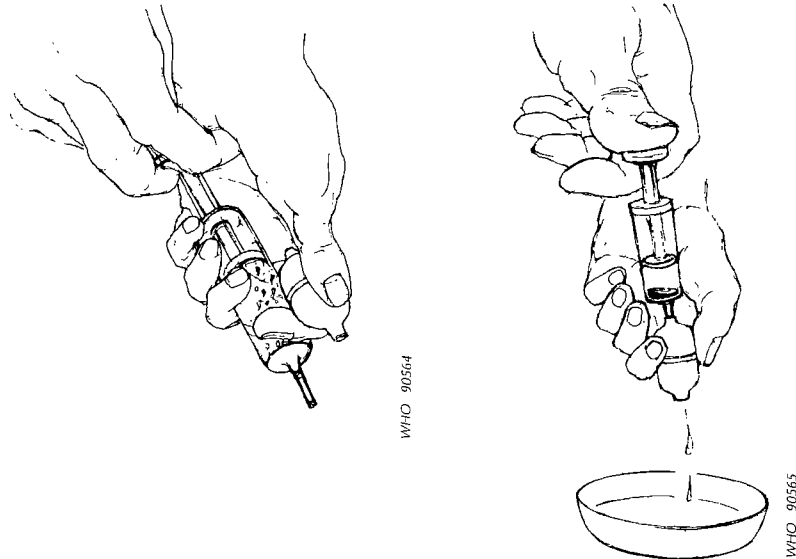
Technique

1. Place a polycarbonate or nylon filter (pore size 12–20 μm) in the filter holder. Alternatively, paper filters (Whatman No. 541 or No. 1) can be used. Agitate the urine sample by shaking it gently or by filling and emptying the syringe twice.
2. Draw 10 ml of the urine into the syringe and attach the filter-holder to the bottom of the syringe. (If less than 10 ml is available record in notebook.)
3. Keeping the unit level, expel the urine from the syringe into the filter holder over a bucket or sink.

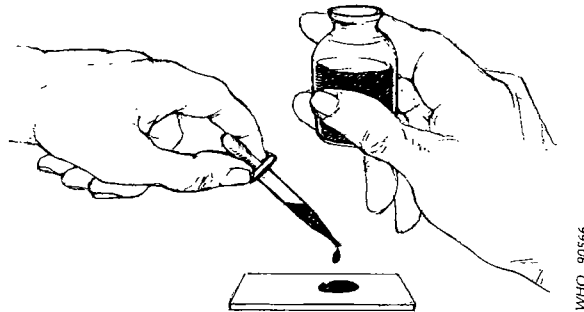


¹Polycarbonate filters and filter holders are available from: Sartorius GmbH, PO Box 19, D-3400 Göttingen, Germany; Millipore Intertech Inc., Ashby Road, PO Box 255, Bedford, Massachusetts 31730, USA. Nylon filters (Nytrel TI HD 20) in rolls or packages of 500 are available from l'Union Gazes à Bluter, B.P. 2, F-42360 Panissières, France.

4. Carefully unscrew the filter holder, draw air into the syringe, reattach the syringe to the holder, and expel the air. (This is important as it helps to remove excess urine and also makes sure the eggs, if present, are attached to the filter.)



5. Unscrew the filter holder, remove the filter with the forceps and place it (top side up) on a microscope slide. Add one drop of Lugol's iodine and wait for 15 seconds for the stain to penetrate the eggs.



6. Examine the whole filter under the microscope immediately at low power ($\times 40$). Schistosome eggs stain orange and can be seen clearly. Infection loads are recorded as the number of eggs per 10 ml of urine. Therefore it is important to note the amount of urine examined, if it is less than 10 ml. To estimate the intensity of infection of the sample, divide the number of eggs counted by 10. If less than 10 ml was examined use the following equation:

$$\text{number of eggs per 10 ml sample} = \frac{\text{number of eggs counted}}{x} \times 10$$

where x = no. of ml of filtered urine examined.

Reuse of filters

Remove the plastic filter immediately after use and soak it overnight in a 1% hypochlorite solution (domestic bleach). Wash the filter thoroughly with detergent solution and then several times with clean water. Check the filter microscopically to ensure that it is free of parasites before being reused.

Identification

Schistosoma haematobium eggs are large, about 120–150 μm long, and have a terminal spine at one end. An embryo (the miracidium) can be seen inside the egg.

Sometimes, it is necessary to determine whether the eggs are viable. This can be done if the specimen is fresh and no preservatives have been added.

Look carefully at the eggs to see if the embryos are moving. This is the best indication of viability. If no movement is seen, look for the "flame cells". There are 4 flame cells, one at each corner of the embryo. Use high-power, dry magnification, reduce the illumination slightly and look for the rapid movement of cilia (short hairs) in the cells.

Quantitative urine examination

Quantitative data from urine examinations, by the syringe filtration technique for detection of *S. haematobium* infection, may be reported according to egg count categories:

- light infection—1–49 eggs per 10 ml of urine
- heavy infection—> 50 eggs per 10 ml of urine.

A third category, such as over 500 or over 1000 *S. haematobium* eggs per 10 ml of urine, may be appropriate in areas where the intensity of infection frequently reaches this level (e.g., in more than 10% of cases).

Vaginal and urethral material

Vaginal and urethral materials are examined for the presence of *Trichomonas vaginalis*, a flagellate parasite of the urogenital system. It parasitizes both men and women, but men are usually asymptomatic. *Trichomonas vaginalis* is usually identified in wet mounts of vaginal and urethral material. (In stained preparations these organisms are badly distorted and may not be recognizable.)

Collection of specimens

Materials

Centrifuge with head and cups to hold 100 × 13-mm tubes (the same cups will hold both 15-ml conical tubes and 100 × 13-mm tubes)

Coverslips

Cotton swabs, sterile

Microscope slides

Pipettes, Pasteur, with rubber bulbs

Pen or marker for labelling

Test tubes, small, 100 × 13 mm, with cotton plugs or screw-caps and 3 ml of sterile saline in each.

Technique

1. With a sterile cotton swab, collect the vaginal or urethral discharge.
2. Put the swab immediately into a sterile tube containing about 3 ml of sterile saline. The top of the stick can be broken off if it is too long for the tube.
3. Smears for staining can be made if desired. For these, collect more material with a second sterile swab and smear on the slide. Allow to dry.
4. Label tubes and slides with patient's name or number, and the date of collection.

NOTE

If the patient can come to the laboratory, wet mounts can be examined directly; tubes are not needed.

Direct examination of vaginal and urethral smears

1. If the patient can come to the laboratory, obtain some of the vaginal or urethral discharge with a sterile swab and put into a drop of saline on a microscope slide.
2. Cover with a coverslip and examine with the ×10 and ×40 objectives for motile flagellates.

Centrifuged or sedimented material

1. If a swab in saline is received, remove the excess fluid from the swab by squeezing it against the side of the tube. Discard the swab.
2. Centrifuge the tube for 2 minutes. If a centrifuge is not available, let the tube stand for 10 minutes to allow any sediment to settle on the bottom.
3. With a pipette remove the supernatant fluid. Do not disturb the sediment.
4. Take a drop of the sediment and put on a microscope slide.
5. Cover with a coverslip and examine with ×10 and ×40 objectives for motile flagellates.

In wet mounts, flagellates can be identified by their pattern of movement. *Trichomonas* trophozoites move with a nervous, jerky or jumpy movement. Since *T. vaginalis* is the only species of *Trichomonas* that inhabits the urogenital system, there is no need to study the morphological features or to differentiate it from *T. hominis*, which lives in the intestine. On rare occasions, ciliated bodies from epithelial cells of the genital tract may be mistakenly identified as some sort of parasitic organism.

Blood and other specimens

Blood is examined for the following parasites:

- *Plasmodium*
- microfilariae
- *Trypanosoma*
- *Leishmania*

The most commonly used technique for blood examination is stained blood films. Giemsa stain (one of the Romanowsky stains) is usually used to stain the films. Field's stain is an alternative where rapid diagnosis is required. Delafield's haematoxylin stain is used for microfilariae. Either thick films or thin films may be used depending on the circumstances. The thick film is more sensitive in detecting parasites and also saves time in examination. However, the thin film technique causes very little distortion of the parasite, and permits species identification when it may not be possible in thick films, but many fields must be examined to detect parasites when they are few in number. Therefore, both thick and thin films must always be prepared when searching for plasmodia and trypanosomes; if a precise identification cannot be made from the thick film, the thin film will be available. Thick films should be used when searching for microfilariae.

The most economical use of slides is achieved by making a combination thick and thin slide, i.e., a thick film and a thin film on the same slide. However, combination films must dry thoroughly (8–10 hours or overnight) before they can be satisfactorily stained. Slides for malaria should be stained the same day. Sometimes, the physician may need a diagnosis quickly. In these cases, make thin films and thick films on separate slides.

The thin films will dry quickly and can be stained as soon as they are dry. Use the rapid Field's stain method and examine while the Giemsa stain is working. Examine for malaria parasites. If parasites are seen, a diagnosis of malaria can be made and, using the Giemsa stain, the species can be identified.

If parasites are not seen in the thin film, stain the thick film using Field's stain. Examine the thick film for malaria parasites.

Sometimes, species cannot be readily identified in thick films and it may be necessary to send to another laboratory for an expert opinion.

Direct wet mounts of fresh whole blood (or centrifuged blood) are usually used for detection of microfilariae and trypanosomes. This only gives evidence of infection and stained films are necessary for confirmation of the species present.

In areas where malaria, trypanosomes, and/or microfilariae may all be present, both wet and stained films should be prepared and examined. If neither trypanosomes nor microfilariae occur in the region, only stained films need to be made for detection of plasmodia.

Stained blood films

Collection of specimens

Careful attention to technique is necessary in the collection of blood and the preparation of blood films. One should always be aware that a number of viral, bacterial, and parasitological diseases may be transmitted in blood.

Materials and reagents

Block, wooden with grooves (to hold slides)
 Bottle, small (30–100 ml capacity) with a dropper-top and screw-cap, or small glass bottle (30–100 ml capacity) with a screw-cap and a separate dropper (with rubber bulb)
 Cylinders, graduated, 10 ml, 25 ml, and 50 ml
 Forceps
 Gauze pads
 Glass rod
 Lancets, sterile
 Pen or marker for labelling
 Microscope slides
 Register or record form
 Staining dishes
 Towels (paper), or sponge
 Alcohol, 70% ethanol or isopropanol
 Phosphate buffer (reagent no. 3)
 Methanol in a dropping bottle.
 Stain dilution (see "Staining blood films with Giemsa stain" pp. 42–43). The directions for preparing the stain dilution needed for each type of film are given with details of the technique.¹ Giemsa stain dilutions are good for only 8 hours. The dilution should be prepared at the time it is needed, not before. Diluted stains should be discarded at the end of the day.

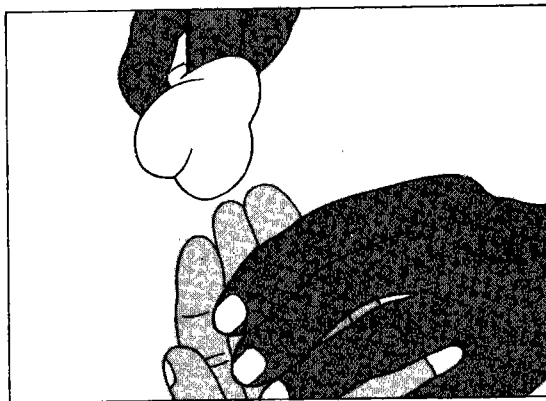
Preparation of a thick and thin blood film on the same slide

For routine malaria microscopy, a thin and a thick film are made on the same slide. The thin film is used as a label but, if well prepared, is also available for species confirmation. The thick film should be used for examination.

Technique

After patient information has been recorded in the appropriate form or register, the blood films are made as follows:

1. With the patient's left hand, palm upwards, select the third finger. (The big toe can be used with infants. The thumb should never be used for adults or children.) Use cotton wool lightly soaked in alcohol to clean the finger—using firm strokes to remove dirt and grease from the ball of the finger. With a clean cotton towel dry the finger, using firm strokes to stimulate blood circulation.




¹ Stock Giemsa stain is usually purchased as a prepared solution.

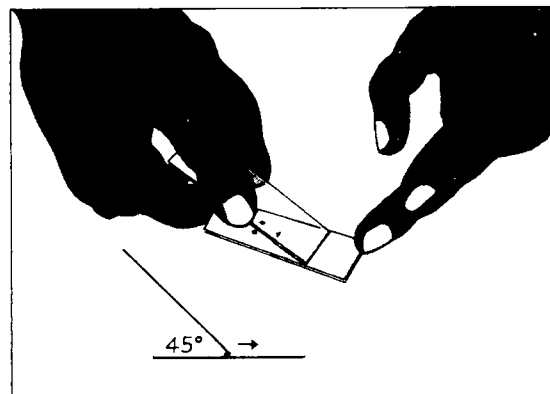
2. With a sterile lancet puncture the ball of the finger using a quick rolling action. By applying gentle pressure to the finger, express the first drop of blood and wipe it away with dry cotton wool. Make sure no strands of cotton remain on the finger.



3. Working quickly and handling clean slides only by the edges, collect the blood as follows:
 Apply gentle pressure to the finger and collect a single small drop of blood, about this size ●, on to the middle of the slide. This is for the thin film.
 Apply further pressure to express more blood and collect two or three larger drops, about this size ●, on to the slide about 1 cm from the drop intended for the thin film as illustrated.
 Wipe the remaining blood away from the finger with cotton wool.



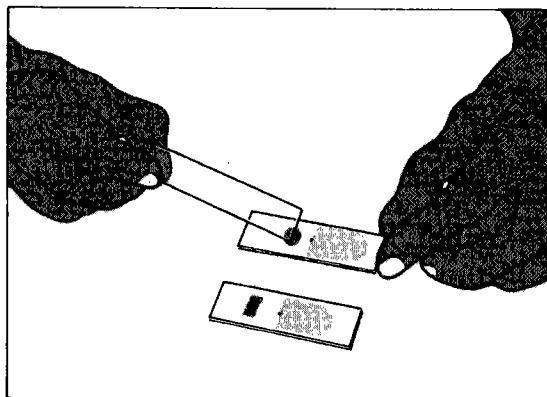
4. *Thin film.* Using another clean slide as a "spreader", and with the slide with the blood drops resting on a flat, firm surface, touch the small drop with the spreader and allow the blood to run along its edge. Firmly push the spreader along the




slide, away from the largest drops, keeping the spreader at an angle of 45° . Make sure the spreader is in even contact with the surface of the slide all the time the blood is being spread. The blood film should not extend to the edges of the slide in order to prevent infection of the investigator.

5. *Thick film.* Always handle slides by the edges, or by a corner, to make the thick film as follows:

Using the corner of the spreader, quickly join the larger drops of blood and spread them to make an even, thick film. The blood should not be excessively stirred but can be spread in a circular or rectangular form with 3–6 movements.



6. Allow the thick film to dry in a flat, level position protected from flies, dust, and extreme heat. Label the dry film with a pen or marker pencil by writing across the thicker portion of the thin film the patient's name or number and date (as shown below). Do not use a ball pen to label the slide.



7. Wrap the dry slide in clean paper, and dispatch with the patient's record form to the laboratory as soon as possible.
8. The slide used for spreading the blood films must be disinfected and could then be used for the next patient, another clean slide from the pack being used as a spreader.

Staining blood films with Giemsa stain

Regular method for staining thick and thin blood films on the same slide

For optimum staining, the thick and thin films should be made on separate slides and different concentrations and times used for staining. This is often not possible and the thick and thin films are generally made on the same slide. When this is done, good-quality staining of the thick film is of primary importance. Best results are obtained if the blood films have dried overnight.

1. Fix the thin film by adding 3 drops of methanol, or by dipping it in a container of methanol for a few seconds. With prolonged fixation it may be difficult to demonstrate Schüffner's dots and Maurer's dots. To permit dehaemoglobinization, the thick film should not be fixed; therefore avoid exposure of the film to methanol or methanol vapour.

2. Place the slides back to back in a staining dish.
3. Prepare a 3% Giemsa solution in buffered, distilled or deionized water, pH 7.2, in sufficient quantity to fill the number of dishes being used. Mix the stain well.
4. Pour the stain gently into the dish, until the slides are totally covered.
5. Allow to stain for 30–45 minutes out of sunlight.
6. Pour clean water gently into the dish to float off the iridescent scum on the surface of the stain. Alternatively, gently immerse the whole dish in a vessel filled with clean water.
7. Gently pour off the remaining stain, and rinse again in clean water for a few seconds. Pour the water off.
8. Remove the slides one by one and place them in a slide rack to drain and dry, film side downwards, making sure that the film does not touch the slide rack.

Rapid method for staining thick and thin blood films on the same slide

This method is suitable for rapid staining of thick films in a busy laboratory when urgent results are required, but it uses much more stain.

1. Allow the thick film to dry thoroughly; if results are required urgently, drying may be hastened by fanning, or briefly exposing the slide to gentle heat such as that from the microscope lamp. Care should be taken to avoid overheating, otherwise the thick film will be heat-fixed.
2. Fix the thin film by gently dabbing with cotton wool dampened with methanol, or by dipping it in a container of methanol for a few seconds. To permit dehaemoglobinization, the thick film should not be fixed; therefore avoid exposure of the film to methanol or methanol vapour.
3. Prepare a 10% Giemsa solution in buffered, distilled or deionized water, pH 7.2; if a small quantity is being used, 3 drops of stain per ml of buffered water will give the correct concentration of Giemsa solution. One slide requires about 3 ml of made-up stain.
4. Gently pour the stain on the slide; a pipette can be used for this purpose. Alternatively, slides can be placed face down on a concave staining-plate and the stain introduced underneath the slide.
5. Stain for 5–10 minutes.
6. Gently flush the stain off the slide by adding drops of clean water; do not tip off the stain and then wash, as this will leave a deposit of scum over the smear.
7. Place the slide in the rack, film side downwards, to drain and dry, making sure that the film does not touch the slide rack.

Staining blood films with Field's stain

Staining with Field's stain allows rapid detection of malaria parasites (but it does not always stain Schüffner's dots).

Method for staining thick films

Materials

One staining dish filled with Field's stain A
One staining dish filled with Field's stain B
Two dishes filled with clean water.

Technique

1. Dip the slide into Field's stain A for 3 seconds.
2. Wash gently by dipping (once) into clean water.

3. Dip into Field's stain B for 3 seconds.
4. Wash gently as in step 2.
5. Place slide upright in a draining rack to air-dry.

Method for staining thin films

Reagents

Field's stain A.

Field's stain B diluted—1 part by volume of stain plus 4 volumes of buffered water (pH 7.2).

Buffered water, pH 7.2.

Technique

1. Fix film in methanol for one minute.
2. Wash off methanol with water.
3. Using a pipette, cover the film with diluted Field's stain B.
4. Immediately add an equal volume of Field's stain A and mix well by tilting the slide.
5. Leave to stain for one minute.
6. Wash off stain with clean water.
7. Place slide upright in a draining rack to air-dry.

Staining blood films with Delafield's haematoxylin stain for microfilariae

Materials and reagents

Five staining dishes

Ether-ethanol fixative (reagent no. 8)

Hydrochloric acid-water destain (reagent no. 15)

Delafield's haematoxylin stain (reagent no. 6). This stain may be purchased as a prepared solution.

Technique

1. Prepare thick films¹ of blood obtained by finger-prick. Allow to dry for 8–10 hours or overnight.
2. Prepare staining dishes as follows:
 - dish 1—tap-water
 - dish 2—ether-ethanol
 - dish 3—Delafield's haematoxylin stain
 - dish 4—hydrochloric acid-water (0.05% HCl)
 - dish 5—tap-water.
3. Put the dry film in tap-water (dish 1) for 5–10 minutes. The red blood cells lyse and the film will be clear, or white, when lysis is complete.
4. Let film dry.
5. Put the film in ether-ethanol for 10 minutes (dish 2).
6. Let dry.
7. Put the film in Delafield's haematoxylin stain for 15 minutes (dish 3).
8. Destain with hydrochloric acid-water (dish 4). Dip slide into hydrochloric acid-water twice. Do this QUICKLY. The film will turn red.
9. *Immediately* put slide in tap-water (dish 5) to wash off acid. Put dish under a stream of running water until the film turns blue. Put a piece of rubber tubing

¹ If films of sediment from concentrated blood are used, start with step 5.

on the tap long enough to reach the top of the dish and let the water run gently; if the flow of water is too strong, the film will be washed off.

If running water cannot be used, change the water in the dish several times until the film turns blue. Put your finger over the top of the dish to keep the slide from falling out, pour the water out, and refill the dish.

10. Let the film dry and examine with the $\times 10$ and oil-immersion objectives for microfilariae.

Examination

Thick films

1. Focus on the film with the $\times 10$ objective and search for microfilariae. They are easily detected with the $\times 10$ objective.
2. If microfilariae are present, switch to the oil-immersion objective and identify the species. Also look for malaria parasites with the oil immersion objective. At least 100 fields should be examined.

Microscopy of thick films should reveal the following features:

- The background should be clean, free from debris, with a pale mottled-grey colour derived from the lysed erythrocytes.
- Leukocyte nuclei are stained a deep, rich purple.
- Malaria parasites are well defined with deep-red chromatin and pale purplish-blue cytoplasm. In *Plasmodium vivax* and *P. ovale* infections, the presence of Schüffner's stippling in the "ghost" of the host erythrocyte can sometimes be seen at the edge of the film.

Thin films

1. Focus with the $\times 10$ objective on the thin terminal end of the film where the red blood cells are in one layer.
2. Put immersion oil on the slide and switch to the oil-immersion objective.

When examining for malaria parasites and trypanosomes, at least 200 fields should be examined. Microscopy should reveal the following features:

- The background should be clean and free from debris; erythrocytes are stained a pale greyish-pink.
- Neutrophil leukocytes have deep purple nuclei and well defined granules.
- The chromatin of malaria parasites is stained a deep purplish-red and cytoplasm a clear purplish-blue.
- Schüffner's dots should be seen as stippling in erythrocytes containing *P. vivax* or *P. ovale*, and Maurer's dots show as stippling in erythrocytes containing the larger ring forms of *P. falciparum*.

Quality control for blood examination

To ensure reliable examination for blood parasites, the laboratory worker must pay attention to the following points:

1. *Equipment must be clean.* Slides must be free from dust, grease, soap, fingerprints, and debris, otherwise the blood may not adhere to the slide or may not stain properly. The lancet used for puncturing the finger (or ear or toe) must be sterile to avoid transferring disease from one patient to another. The puncture should be deep enough to provide sufficient blood for the films to be made. Gauze, rather than cotton, should be used to clean the finger. (Cotton may leave fibres

that will get into the blood film.) The finger should be cleaned thoroughly before puncturing to remove dirt, mould, or other contaminants. Blood obtained by venepuncture can be used if the films are made immediately after the blood is collected. Anticoagulants will affect adhesion of the blood to the slide and staining.

2. *Films must be of the correct density.* The thin film should have a terminal edge where the blood cells are in a single layer so the morphology of the red blood cells can be seen. If the film is too thick the red blood cells may be "piled-up" in layers and the morphology may not be clear. If it is too thin, the blood cells may be grossly distorted and thin layers of blood often do not stain well. In addition, in thin areas the parasites are usually distorted.
It should just be possible to read small print through a thick film. If the film is too thick, the blood may flake or peel off during staining and portions of the film be lost. If the film is too thin, the advantage of the thick film containing a larger sample may be lost.
3. *Films must be allowed to dry in a horizontal position and for the correct time* to ensure good results. If thick films are tilted or slanted the blood may run to one edge of the slide producing an uneven smear. The thick area may flake off. If films do not dry thoroughly, they will not stain properly.
While drying, films must be protected from dust, mould, or other debris that may fall on to the blood and cause problems in diagnosis. They must also be protected from flies or other insects that may damage the film.
Thin films must be fixed with methanol before staining to prevent the red blood cells from lysing. The methanol must be absolute and moisture-free. Otherwise the blood cells will be damaged, and the staining will be poor. **Never fix thick films.** Be careful not to let methanol get on the thick film.
4. The stain dilutions and the buffered water used for staining must be accurately prepared and the stock stain must be of good quality. The bottle of stock Giemsa stain must be kept tightly closed and out of sunlight. If moisture gets into the stain it will be ruined. It is recommended that a portion of the stock stain be poured into a clean, dry bottle for use. This will protect the remainder of the stock from accidental contamination with moisture or debris. **Never put a wet pipette into the bottle of stock stain.**
Diluted Giemsa stain is good for about 8 hours. Therefore, stain dilutions must be prepared fresh on the day they are required.
The pH of the stain is a very important factor in obtaining well stained films. The pH is controlled by using water buffered to pH 7.2 which gives the best staining results. Buffered water can be kept for some time if the bottle is kept tightly closed. However, the pH should be checked occasionally to be sure it is still neutral.
5. *The staining procedure should be followed very carefully.* Be sure to use the procedure developed for the type of film you are staining. Wash the stain exactly as indicated in the procedure. If thin films are washed too much, the colour will wash out. If the thick films are not washed enough, a lot of cellular and stain residue may remain on the slide causing problems in examination. Be sure combination thick and thin films are dried in a vertical position with the thick film at the bottom. Otherwise, water will run on to the thin film and wash out the colour.

Special techniques for plasmodia

Identification of malaria parasites

Three components of malaria parasites may be seen. These are blue-staining cytoplasm, red or purple chromatin, and brown or black pigment granules or rods.

Except for the early (young) ring stages, you should be able to see all three components. (Early rings usually do not have pigment.) Observation of the three components is important in order to distinguish malaria parasites from host cells, like white blood cells, and artefacts that may appear on the slide during preparation.

In thin films, look at the appearance of the parasite and the appearance of the red blood cells containing the parasites. Observe the following:

1. The appearance of the red blood cell containing the parasite.
 - *Size*. Is the parasitized cell the same size as the blood cells without parasites (that is, normal size) or is it bigger (enlarged)?
 - *Stippling*. Is the red blood cell filled with pink- or red-staining dots? These are Schüffner's dots and occur only in *P. vivax* and *P. ovale* infections. (They will *not* be present in blood cells without parasites.) Cells containing late stage trophozoites of *P. falciparum* often include irregular red-mauve dots. These are Maurer's dots.
2. The appearance of the parasite.
 - Are the growing trophozoite stages irregular in outline?
 - Are they regular or smooth?
 - What colour is the pigment in the older trophozoites, schizonts, and gametocytes?
 - How many merozoites are there (if any) in the mature schizont?
 - What is the shape of the gametocytes, if seen?
 - What stages (rings, growing trophozoites, schizonts, gametocytes) are present?

Let the films dry completely before examining. If you are in an area where filariasis occurs, you should scan the thick film with the $\times 10$ objective for microfilariae (see pp. 57–58). Use of the oil-immersion objective is necessary to observe the morphology of the blood parasites.

Examine the centre portion of the thick film first. Organisms are more likely to be detected in this thicker area. If the morphology is not distinct, go to the thinner, outer edges to find parasites with a more characteristic appearance.

In thick films, the red blood cells are lysed and no longer present. The blood layer is much thicker than in a thin film and parasites may be located at different levels. Focus up and down carefully to see the organisms. In thick films, the parasites often appear smaller than in thin films, but the same parasite characteristics are used to separate species. Sometimes, parasites in the thinner, outer edges of the thick film are more like those in thin films than are those in the centre. Occasionally, the outlines of the red blood cells can be seen in the thin edges.

Specific characteristics used to identify species of malaria in thick and thin films are presented and problems in diagnosis discussed in Section 2, pp. 80–88.

Examination of chloroquine resistance in falciparum malaria

A drug-resistant parasite is defined as a parasite that will survive and multiply in a patient despite treatment with the drug in a dosage that normally cures the infection. The commonly used standard field test requires the examination of a thick blood smear daily for the first 7 days of treatment. If asexual forms have disappeared in the peripheral blood on day 7, the examination has to be extended to 28 days to exclude a case of RI resistance with late recrudescence. It is simpler to examine a thick blood film on day 2 in severely ill patients, or on day 4 in less sick

patients. If the parasite count on either of these days is 20–25% above the level before treatment, it indicates a resistant strain and a need for a change in treatment.

Technique—the standard field test

1. Make a total white blood cell count and calculate the number of white blood cells per μl of blood (WBC).
2. Make a thick blood film (pretreatment parasite level) and count the number of parasites (P) and leukocytes until 300 leukocytes have been enumerated. The number of parasites per μl of blood is then $\text{WBC} \times P/300$.
3. Give the patient 10 mg of chloroquine (base) per kg of body weight orally once a day for the first 2 days and 5 mg/kg of body weight on the third day (a total of 25 mg of chloroquine base per kg of body weight during the 3 days).
4. Make a thick blood film each day for the first 7 days, and on days 14 and 28, if no sign of remission has appeared during the first 1–2 weeks.

Interpretation of the standard field test

1. If no asexual forms are found by day 6 and no parasites (ring forms and gametocytes) are present on day 7, the infection may be either sensitive (S) or resistant at the RI level. To differentiate between these two, the observation should be extended to 28 days. If ring forms do not reappear by day 28, the strain is sensitive; if the ring forms reappear, the strain is resistant at the RI level.
2. If ring forms disappear for at least 2 consecutive days, but return and are present on day 7, the parasites are resistant at the RI level.
3. If ring forms do not disappear, but are reduced to 25% or less of the pretreatment level during the first 48 hours of treatment, the parasites are resistant at the RII level.
4. If the ring forms are reduced by less than 75% during the first 48 hours, if they remain at the same level, or if they continue to increase, the parasites are resistant to the standard dose of the drug at the RIII level.

Special techniques for *Trypanosoma*¹

Trypanosomes can be identified in:

- blood films
- cerebrospinal fluid (CSF)
- lymph node aspirates.

Detection of trypanosomes in blood

Of the *Trypanosoma* species occurring in Africa, *Trypanosoma brucei gambiense* and *Trypanosoma brucei rhodesiense* cannot be distinguished morphologically. They may be identified in either thick or thin blood films. However, in the thick film, they may be distorted and difficult to differentiate from cellular debris. *Trypanosoma cruzi*, found in the Americas, is badly distorted in thick films and is more readily identified in the thicker areas of the thin film.

Like plasmodia, the cytoplasm of trypanosomes stains blue. The nucleus and kinetoplast stain red or purple. Look for an elongated organism with a prominent nucleus located near the centre of the body and a smaller dot, the kinetoplast, located near one end. The flagellum originates from the posterior part of the trypanosome close to the kinetoplast. The flagellum is attached to the cell wall except at the anterior tip, where it terminates with a free end. Since the flagellum is

¹ Adapted from the *Trypanosomiasis control manual*, unpublished WHO document, 1983.

constantly moving it pulls the cell wall into irregular extensions, this feature being known as the undulating membrane. The trypanosome may be undulated (with 2 or 3 curves) or it may be in a C or U shape. The shape, the position of the nucleus, and the size and location of the kinetoplast are features used in identifying species. More detailed characteristics for species identification are described in Section 2, pp. 88–89.

The wet blood film

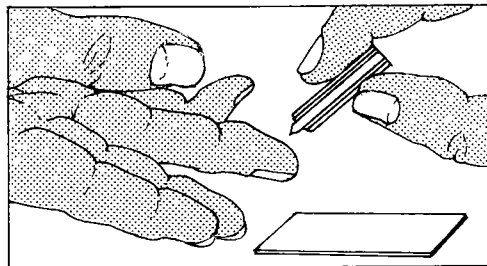
This method is the easiest and least expensive way to show the presence of parasites in blood, but it is the least sensitive test.

Materials

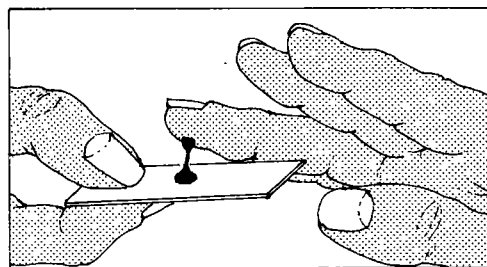
Blood lancet
Cotton wool swabs
Coverslip
Microscope slide
Saline solution (reagent no. 24)
Ethanol.

Method

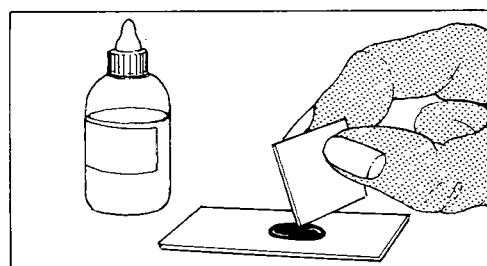
1. Select the third finger from the thumb. Clean the finger with a cotton wool swab lightly soaked in ethanol. Dry well. Prick with the lancet.



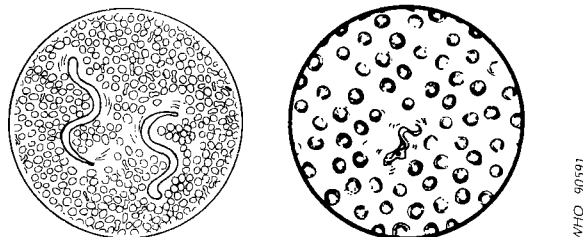
2. Collect the *first* drop of blood that appears directly on to the middle of the slide.



3. Add an equal drop of saline. Mix the blood and saline solution using the corner of a coverslip. Cover the preparation with the coverslip.



4. Prepare two thick films on another slide using 2 more drops of blood. Examine the fresh smear systematically under the microscope ($\times 10$ objective with reduced condenser aperture). The first sign of the presence of live trypanosomes or microfilariae is rapid movement among the red cells.



(The illustration on the right shows a view ($\times 40$) of a trypanosome and red blood cells, that on the left, microfilariae ($\times 10$).

5. Scan the whole preparation systematically. The trypanosomes are refractile and difficult to see. They are easier to see with slightly reduced lighting.

The thick blood film

This is more sensitive than the wet blood film because more blood is observed per microscope field.

1. Place a drop of blood on to a clean dry microscope slide.
2. Prepare and stain a thick blood film in the same way as for malaria parasites (see pp. 40–43).
3. Examine the whole film using the oil-immersion objective.
4. Trypanosomes are seen among the mass of lysed red blood cells and can be recognized by their typical shape and light bluish colour, with a dark nucleus and kinetoplast.

The microhaematocrit method

Materials and reagents

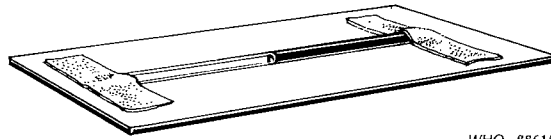
Adhesive tape
 Capillary tube
 Microhaematocrit centrifuge
 Plasticine
 Sodium citrate solution (reagent no. 26).

Only a small quantity of blood is needed, so blood obtained by finger-prick can be used if venepuncture cannot be performed. However, a special centrifuge that will accommodate microhaematocrit tubes is needed.

Method

1. Prick the finger and obtain 2 drops of blood on a slide. Add 1 drop of 2% sodium citrate solution and mix. Fill the capillary tube $3/4$ full. If venous blood has been collected, fill the capillary tube $3/4$ full with blood from the bottle or flask.
2. Seal the open end of the tube by heating or with plasticine.
3. Centrifuge in a microhaematocrit centrifuge for 2 minutes for microfilariae or 4 minutes for trypanosomes.

4. Lay the capillary tube on a microscope slide and secure the ends with adhesive tape to keep the tube from rolling around.



WHO 88615

5. With the $\times 10$ objective, examine the area between the red blood cells and the plasma. Motile microfilariae or trypanosomes may be seen. Switch to the high-power, dry lens for better observation.

The sterile mini-anion exchange centrifugation technique (m-AECT)

This method is the most sensitive test so far developed for the detection of trypanosomes in human blood. Prepared columns in kits with sterile reagents require no refrigeration for storage. Once open, the column and the buffer must be used immediately. Care should be taken to dispose of every item in disinfectant solution (e.g., water with 2% bleach).

Materials and reagents

The kit must include the materials and reagents required for one test, which are:

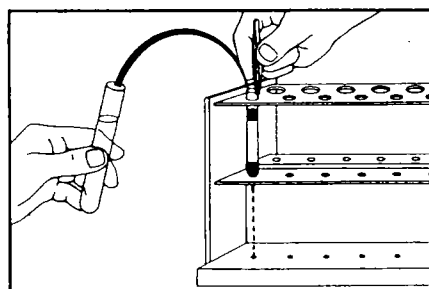
Sterile column in a tube container kept in phosphate-buffered saline
 Tube with pre-weighed glucose or glucose solution
 Heparinized capillary tube (Caraway tube) for blood collection
 Lancet
 Reservoir and centrifuge tube
 Plastic pipette to handle the buffer.

The additional equipment required is:

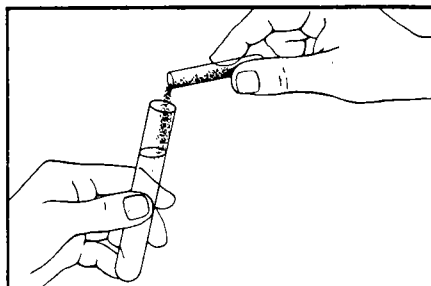
Manual centrifuge
 Column rack
 Good microscope, allowing magnification up to $\times 150$
 Standard microscope glass slides
 Coverslips
 Masking tape
 Modelling clay for the fabrication of the viewing chamber.

Technique

1. Remove the column from its tube container and place it in the front row of the rack and let it drain.

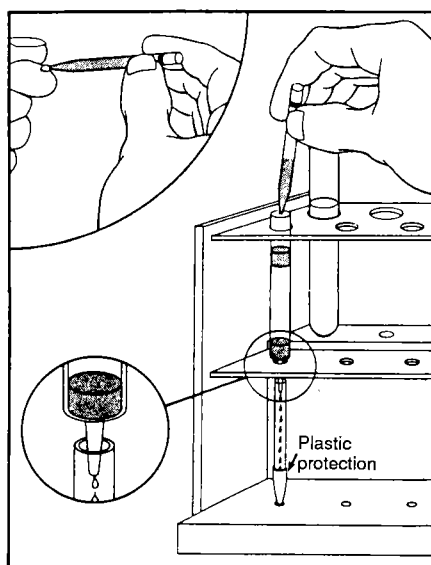


2. Add the pre-weighed glucose or glucose solution to the remaining buffer in the container and mix thoroughly. Store the tube behind the column in the back row of the rack. With the pipette, add a small amount of the buffered saline–glucose solution to the column and let the column drain out. Repeat this step. You will use the rest of the buffer later.



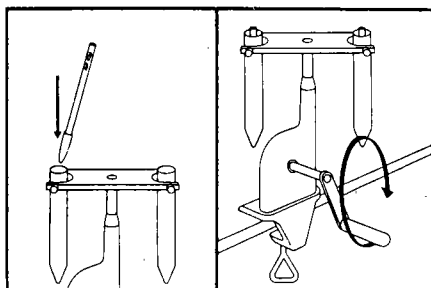
WHO 90569

3. Following the finger-prick, fill the capillary tube (Caraway tube) with blood up to the red mark, and empty it on to the column immediately. Let the blood soak in the upper filter until the column stops running. Add a few drops of buffer with the pipette and immediately place the reservoir on the column and fill it up with buffer. The column will start draining drop by drop. Count 6–7 drops and place the collecting tube under the column, making sure that no air lock forms. Only the very tip of the column should enter the centrifuge tube (the column height is adjustable)—this avoids the formation of an air lock and any loss of eluate out of the centrifuge tube. Top up the reservoir with buffer and let the column run slowly by itself.



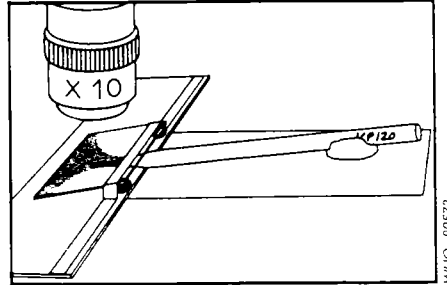
WHO 90570

4. When the centrifuge tube is full, remove it and place it in the swinging bucket of the manual centrifuge. Balance the centrifuge by placing an equivalent weight in the opposite bucket. Centrifuge for 5 minutes.

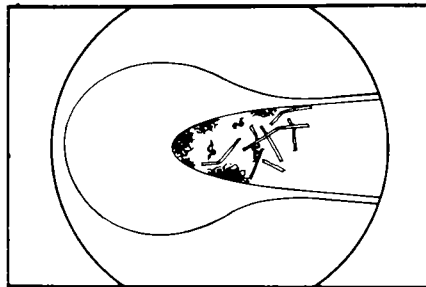


WHO 90571

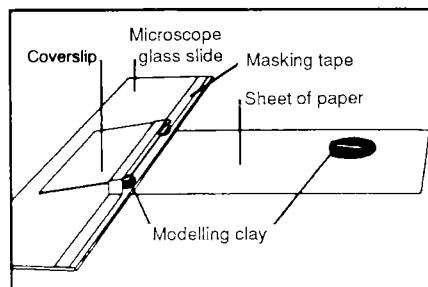
- Take the collecting tube from the centrifuge and remove the plastic protection. Place the tip of the centrifuge tube in a viewing chamber and add water between the slide and the coverslip. Examine the very tip of the m-AECT centrifuge tube under the microscope using the $\times 10$ objective.



- You will easily see trypanosomes as small wiggling organisms at the very tip of the tube. Occasionally cellulose particles may have passed through the bottom filter of the column and may complicate the examination. In that case rotate the tube.



- This is a viewing chamber:



WARNINGS

REMEMBER TO IDENTIFY the collecting tube with a label or a special felt pen.

REMEMBER TO BALANCE the centrifuge rotor if an uneven number of tubes are centrifuged.

REMEMBER TO DISCARD all contaminated items in a bucket with disinfectant solution.

Detection of trypanosomes in lymph node aspirates

The standard method of diagnosis of sleeping sickness, in the early stage, is to search for trypanosomes in aspirates from enlarged cervical lymph nodes. The

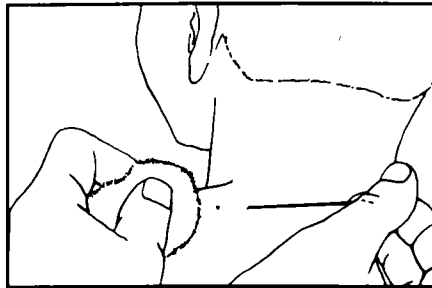
sample is examined under a coverslip and the trypanosomes are identified by their movements.

Materials

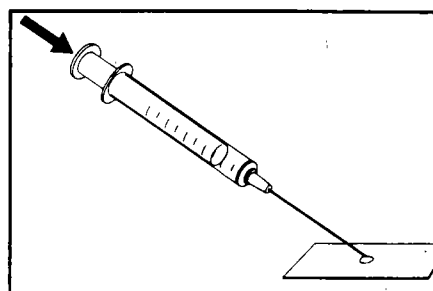
Cotton swabs
Cotton wool
Coverslips
Microscope slides
Needle (for subcutaneous injection), 25 gauge, 0.5 × 16 mm
Syringe, 5 or 10 ml
70% ethanol.

Technique

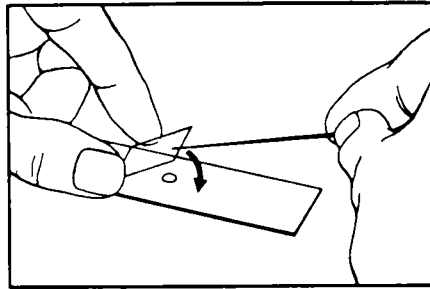
1. Prepare the syringe; pull the piston as far back as possible.
2. Wash your hands with soap.
3. Ask the person to sit down. Disinfect the chosen site on the neck with 70% ethanol.
4. With your left hand, take the gland between the thumb and index finger and make it stand out. Hold your hand steady.
5. Holding the needle between your thumb and finger, introduce it at right angles into the centre of the gland. First pierce the skin, then penetrate the centre of the gland. Make sure that you avoid the jugular veins and arteries.



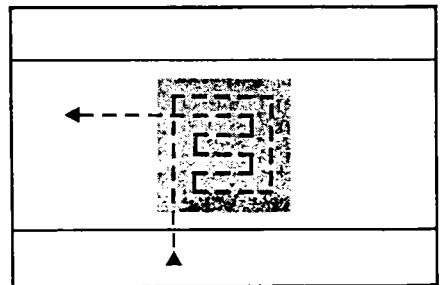
6. With your left hand, gently knead the gland. With your right hand, revolve the needle in both directions.
7. The glandular fluid will ooze into the needle. The operation should last about one minute.
8. Withdraw the needle in one rapid movement, holding your index finger over the hub. Apply a swab dipped in disinfectant to the point of entry. Never apply the disinfectant swab before you withdraw the needle, as some disinfectant may get on to the tip of the needle and make the trypanosomes non-motile.
9. Attach the needle to the syringe, with the piston pulled back. Push the piston gently half way down the barrel to discharge the glandular fluid in the needle on to the slide.



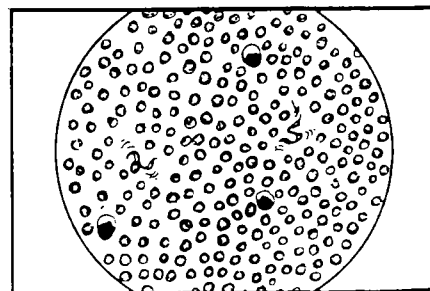
10. Cover the preparation with a coverslip. Examine at once under the microscope at a magnification of approximately $\times 400$, using the $\times 40$ objective.



11. Wait until the convection currents stop. It is impossible to see the movement of trypanosomes among moving cells. Begin by examining the periphery of the preparation, near the edges of the coverslip, as the trypanosomes tend to make their way to the edges. Then examine the rest of the preparation.



12. The preparation will contain red blood cells and leukocytes. Trypanosomes are about $20\ \mu\text{m}$ long and are often hidden by the cellular elements, which are disturbed by the flagella as they move. Any movement is suspicious. Trypanosomes occasionally disappear, hiding under masses of cells. Look very carefully!



Detection of trypanosomes in cerebrospinal fluid (CSF)

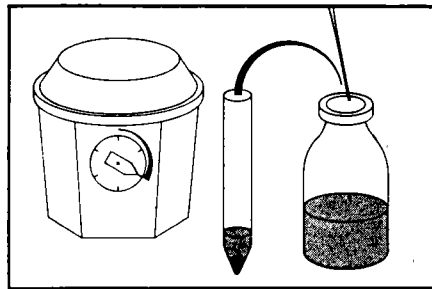
When the trypanosomes have passed the blood–brain barrier and invade the central nervous system, the patient is in the second stage of the disease. The only way to diagnose trypanosomes in the nervous system is to examine the cerebrospinal fluid. Three tests are commonly done:

- white cell counts in the CSF;
- measurement of protein concentration in CSF;
- detection of trypanosomes in CSF.

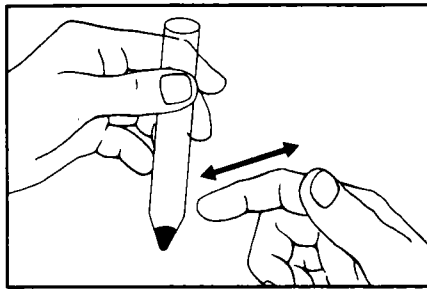
Cells and trypanosomes are rapidly lysed. Therefore the cell count must be carried out soon after collection of the CSF. Trypanosomes are examined after concentration in the CSF by single or double centrifugation. The more convenient technique of single centrifugation will be described. The number of parasites found in the CSF of patients in the advanced stage of disease is highly variable.

Single centrifugation technique

1. After making a white cell count, centrifuge the CSF collected by lumbar puncture for 10 minutes at 900 g. Decant the supernatant and save it for other tests.

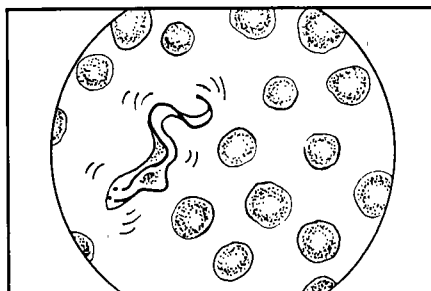


2. Resuspend the sediment in the small amount of CSF left at the bottom of the tube by tapping it with the finger.



3. Place one drop of this resuspended CSF pellet on a clean dry microscope slide. Cover the drop with a coverslip immediately. Wait a few minutes until convection stops.
4. Place the preparation on the stage of the microscope and examine with the $\times 10$ objective first. Use higher magnification to confirm the presence of trypanosomes. Scan the whole preparation starting with the edges since trypanosomes are often found at the very edge of the preparation.

If motile trypanosomes are found in the CSF it means that the patient has reached the later stage of the disease and that the central nervous system is involved.



Indirect detection

Inoculation of biological material from man, host animals, or vectors into susceptible animals has been used to detect trypanosomes. This method is more sensitive for *T. b. rhodesiense* than for *T. b. gambiense*.

Several culture systems have been developed that can support trypanosome growth, but these *in vitro* systems are not commonly used for primary isolation of trypanosomes from patients with sleeping sickness.

Special techniques for microfilariae

Collection of blood for microfilariae

In cases of suspected filariasis, the time of day is important in taking blood samples for examination. Some species have a “periodicity”—that is, microfilariae are present in the blood only at certain times of the day and to detect their presence the blood must be collected at the appropriate time (see Table 2).

Table 2. Blood collection times for suspected filariasis patients

| Species | When to take a specimen ^a | Part of world |
|---|---|--|
| <i>Wuchereria bancrofti</i> | At night (between 22 h and 24 h) | Tropical Africa, Asia, Central and South America, Indian Ocean Pacific Ocean |
| <i>Wuchereria bancrofti</i> (var. <i>pacifica</i>) | Any time | |
| <i>Brugia malayi</i> | Mainly at night (between 22 h and 24 h) | Southern China, Southern India, South-East Asia |
| <i>Loa loa</i> | During the day (between 10 h and 12 h) | West and Central Africa |
| Doubtfully pathogenic filariae: | | |
| – <i>Mansonella perstans</i> | Any time | Tropical Africa |
| – <i>Mansonella ozzardi</i> | Any time | Tropical Africa |

^aThese periods are not invariable.

Detection of microfilariae in peripheral blood

Three microscopic methods are commonly used for detection of microfilariae in peripheral blood:

- the thick blood film
- capillary blood examination
- examination of haemolysed venous blood.

Microfilariae must be stained to confirm the species present.

The thick blood film

Prepare and stain as described on pp. 40–43.

Capillary blood examination

Mix a fresh smear of capillary blood from the finger with saline, place between a slide and coverslip, and examine for motile microfilariae under the microscope. The microfilariae can also be concentrated using venous blood. The examination should be carried out as described for trypanosomes (see pp. 49–50) at the appropriate time of day.

Examination of haemolysed venous blood

Materials and reagents

Bottle, 10 ml
 Centrifuge
 Centrifuge tubes, conical, 15 ml
 Microscope slides
 Needles for venepuncture
 Rack for centrifuge tubes
 Syringe, 5 ml
 Anticoagulant—2% sodium citrate solution (reagent no. 26)
 2% formalin solution (reagent no. 10)
 Giemsa stain (reagent no. 11)
 Ether
 Ethanol.

Method

1. Add 1 ml of venous blood to 9 ml of 2% formalin; wait for 5 minutes for the red cells to haemolyse and then centrifuge at high speed.
2. Pour off the supernatant fluid. Tap the tube to mix the deposit.
3. Place 1 drop of the deposit on a slide. Spread the drop to form a thin smear. Leave to dry in the air. Fix the smear using a mixture of equal parts of ether and ethanol. Leave to dry for 2 minutes. Stain immediately with Giemsa stain. The microfilariae stain well.

Other filtration techniques have been developed for the isolation of microfilariae, but as these techniques are restricted to specialized laboratories, a description of the methods would be beyond the scope of this manual. They are described by Melvin & Brooke.¹

Special techniques for Leishmania

Leishmaniasis is caused by infection with flagellate protozoan parasites of the genus *Leishmania*. Depending on the species concerned, the disease may take a cutaneous, mucocutaneous, or visceral form. Promastigote forms of the parasite are transmitted by the bite of infected sandflies. They are taken up by mononuclear phagocytes in the skin or viscera, where they develop intracellularly into amastigote forms. Although amastigotes can occasionally be detected in mononuclear leukocytes in peripheral blood, microscopic examination of bone marrow, lymph node, and splenic aspirates is more sensitive. For the examination, blood leukocytes can be concentrated in a buffy coat layer by the microhaematocrit method as described for the detection of trypanosomes (see p. 50).

On the basis of clinical signs and symptoms, it is impossible to differentiate visceral leishmaniasis from other causes of febrile splenomegaly. Parasites may be

¹ MELVIN, D. M. & BROOKE, M. M., ed. *Laboratory procedures for the diagnosis of intestinal parasites*. Atlanta, US Department of Health and Human Services, 1982 (HHS Publication No. (CDC) 82-8282).

demonstrated in aspirates of spleen (98% positivity), bone marrow (54–86%), or enlarged lymph nodes (64%). Splenic aspiration can be a high-risk technique and there is no consensus on its use, although it is preferred by some because of its superior sensitivity. It requires no special equipment, is less painful than bone-marrow aspiration, and is relatively easy to perform in experienced hands and when proper precautions are taken. In acute visceral leishmaniasis, when the spleen is small and soft or impalpable, bone-marrow or lymph-node aspiration is recommended.

Splenic aspiration should be performed in patients only after a measurement of prothrombin time and platelet count. It should not be done if the prothrombin time is more than 5 seconds longer than the control, or if the platelet count is below 40×10^9 per litre ($40\,000/\text{mm}^3$).

The two important precautions to take, if the procedure is to be safe, are:

- be quick, so that the needle remains within the spleen less than 1 second; and
- be sure that the entry and exit axes of the aspirating needle are identical, to avoid tearing the splenic capsule.

Materials

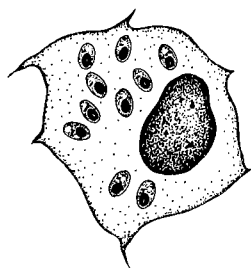
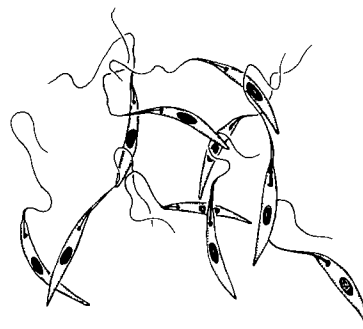
Cotton swabs
 Microscope slides
 Needle, 21 gauge (32×0.8 mm)
 Pen or marker for labelling
 Syringe, 5 ml
 Tubes for culture media
 Novy Nicolle-McNeal (NNN) culture medium¹
 Schneider's enriched medium.¹

Technique

1. Clean 3 glass slides and label with patient's name, date, and "splenic aspirate". Have culture media ready (one tube each of NNN and Schneider's) and labelled in the same way as the slides. Allow the culture media to reach room temperature. Attach a 21 gauge (32×0.8 mm) needle to a 5 ml syringe. Place all items on a table at the bedside.
2. Obtain the patient's informed consent to the procedure. Palpate the spleen and outline its margins on the patient's abdomen with a pen. For safety reasons, the spleen should be palpable at least 3 cm below the costal margin on expiration. Use an alcohol swab to clean the skin at the site of aspiration and allow the alcohol to dry.
3. With the 21 gauge (0.8 mm) needle attached to the 5 ml syringe, just penetrate the skin, midway between the edges of the spleen, 2–4 cm below the costal margin. Aim the needle cranially at an angle of 45° to the abdominal wall. The actual aspiration is done as follows: pull the syringe plunger back to approximately the 1 ml mark to apply suction, and with a quick in and out movement push the needle into the spleen to the full needle depth and then withdraw it completely, maintaining suction throughout.
4. In young restless children, arrange for two assistants to hold the child (arms folded across chest, with shirt raised to obstruct line of vision, and pelvis held firmly). Carry out the aspiration as a single-stage procedure, using the same landmarks, angles and suction as in step 3, all in one quick motion. The insertion should be timed with the patient's breathing so that the diaphragm is not moving; this should be during fixed expiration if the child is crying. Only a

¹ See Annex 3 for the preparation of culture media.

- minute amount of splenic material is obtained but this is sufficient for culture and smear.
5. Slowly pull the plunger back to the 2–3 ml mark and, using sterile techniques, insert the needle into a tube of culture medium and briskly push the plunger to expel the contents of the needle on to the side walls of the tube. If necessary, repeat once or twice until splenic material is visible in the tube. Replace the cap on the tube and invert to wash splenic material off the side of the tube. Repeat the expulsion procedure for the second tube of culture medium. Sterile techniques are essential throughout.
 6. Expel additional material gently on to glass slides holding the needle tip on the surface of the slide. Immediately spread evenly with the needle using a linear (not circular) motion. The smear should not be quite as thick as a thick blood film for malaria. Remove the needle and use the end of it to obtain additional material from the tip of the syringe and spread on slides. Further material may be found on the end of the plunger and dabbed directly on to a slide and spread. Allow the slides to dry.
 7. Write the time of aspiration on the patient's chart and the instructions: "Record pulse and blood pressure every 30 min for 4 hours, then hourly for 6 hours: The patient must remain in bed for 12 hours." See that the patient understands the instructions. Enter the procedure in the notes and sign.
 8. Take the slides and media to the laboratory. Cultures are incubated at 25 °C and examined regularly for up to two weeks. Slides are stained with Giemsa or Field's stain and examined under oil-immersion (see illustration below). The pH of the buffered saline used in the Giemsa stain should be 6.8 for *Leishmania* (not 7.2 as used for malaria). The parasite density is graded according to Table 3.

A. *Leishmania* amastigotesB. *Leishmania* promastigotes

WHO 90578

For visceral leishmaniasis, serodiagnostic methods provide useful support for the diagnosis. Serodiagnosis is of less value for mucocutaneous leishmaniasis and of no value for cutaneous leishmaniasis.

Table 3. Grading of *Leishmania* parasites

| Grade | Average parasite density |
|-------|------------------------------------|
| 6+ | > 100 parasites/field ^a |
| 5+ | 10–100 parasites/field |
| 4+ | 1–10 parasites/field |
| 3+ | 1–10 parasites/10 fields |
| 2+ | 1–10 parasites/100 fields |
| 1+ | 1–10 parasites/1000 fields |
| 0 | 0 parasites/1000 fields |

^aUsing ×10 eyepiece and ×100 oil-immersion lens.

A detailed description of the numerous immunological techniques available is beyond the scope of this manual. The enzyme-linked immunosorbent assay (ELISA) and the indirect fluorescent antibody test (IFAT) are the most suitable. The test may be carried out on serum or on a measured volume of blood collected by finger-prick on to suitable absorbent paper strips and allowed to dry. The sample is eluted in the laboratory and tested at a single dilution that has previously been determined as giving an acceptable sensitivity and specificity in that area. Cross-reactions may occur with *Trypanosoma cruzi* infections. These can usually be eliminated by dilution, or identified by testing in parallel against *T. cruzi* antigens.