

Ankle Block

The ankle block is a common peripheral nerve block. It is useful for procedures of the foot and toes, as long as a tourniquet is not required above the ankle. It is a safe and effective technique.

Indications

The ankle block is suitable for the following:

- Orthopedic and podiatry surgical procedures of the distal foot.

Advantages & Disadvantages

Advantages include the following:

- Easy to administer
- Safe technique when used appropriately
- Rapid onset of anesthesia
- Avoids complications related to neuraxial or general anesthetic techniques

Disadvantages include the following:

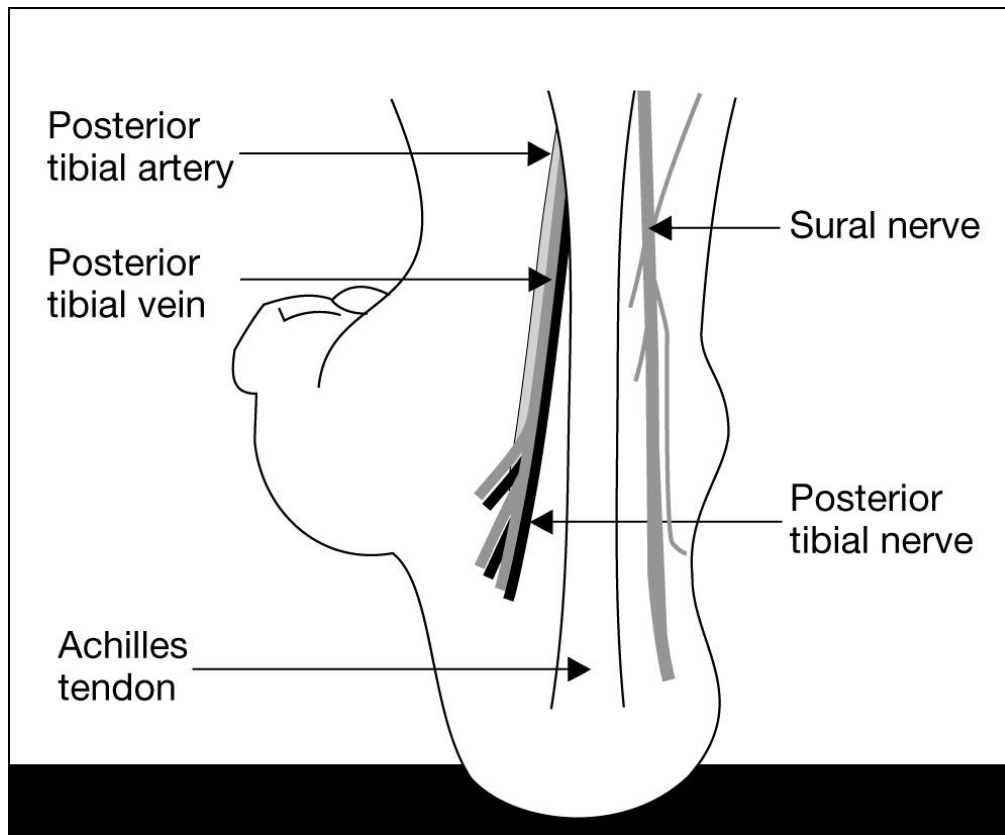
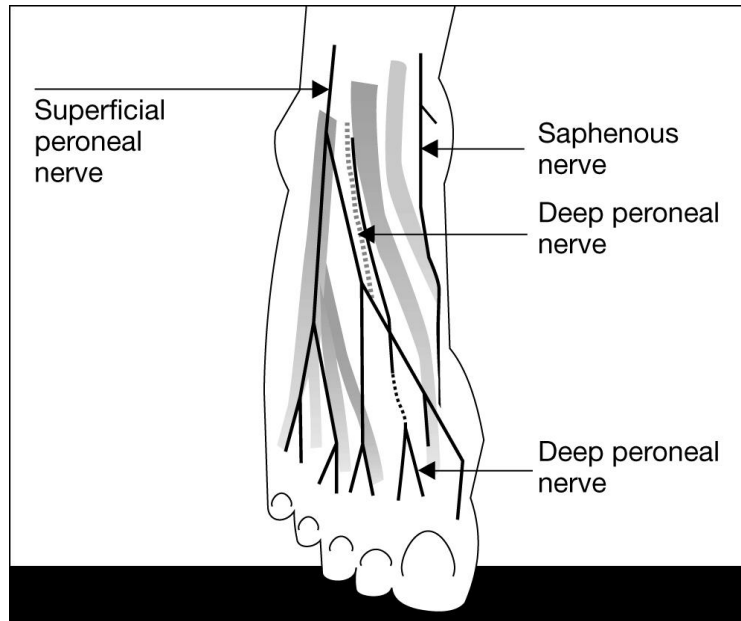
- Is a superficial block and purely sensory. The patient will still be able to move their toes and foot.
- Requires at least 3 separate injections
- Placing an ankle block is uncomfortable. The patient may require conscious sedation for analgesia and amnesia. It is important not to over sedate the patient and to maintain communication. Over sedation will result in an uncooperative patient who may move at critical times, placing the anesthesia provider and patient at risk for injury.
- It is possible to “miss” a nerve distribution. It is easy to remedy the situation by adding additional local anesthetic.

Contraindications

- Few contraindications exist. Should not be used when the foot is infected. Local anesthetic does not work in an acidotic environment. In addition, there is the risk of introducing infectious agents to healthy tissue.
- Young children
- Compromised circulation to the foot

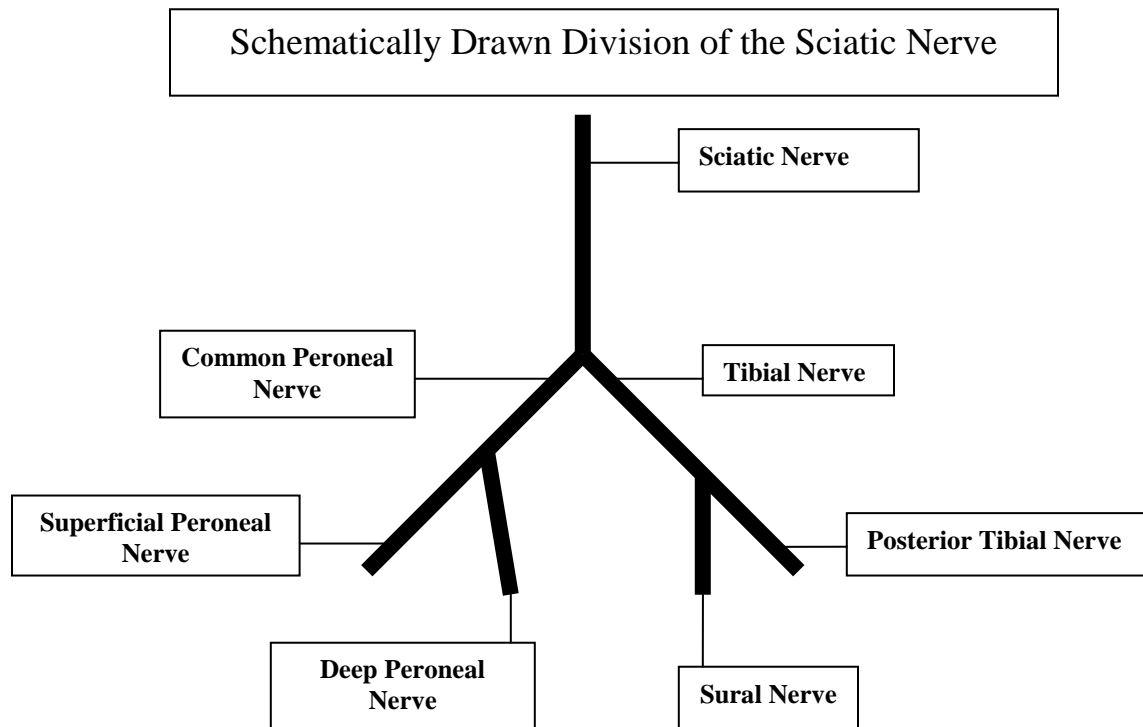
Anatomy

Nerve Distribution



The ankle block involves blockade of 5 nerves. Four of the five nerves are terminal branches of the sciatic nerve and include the following:

- Posterior tibial nerve
- Sural nerve
- Superficial peroneal nerve
- Deep peroneal nerve



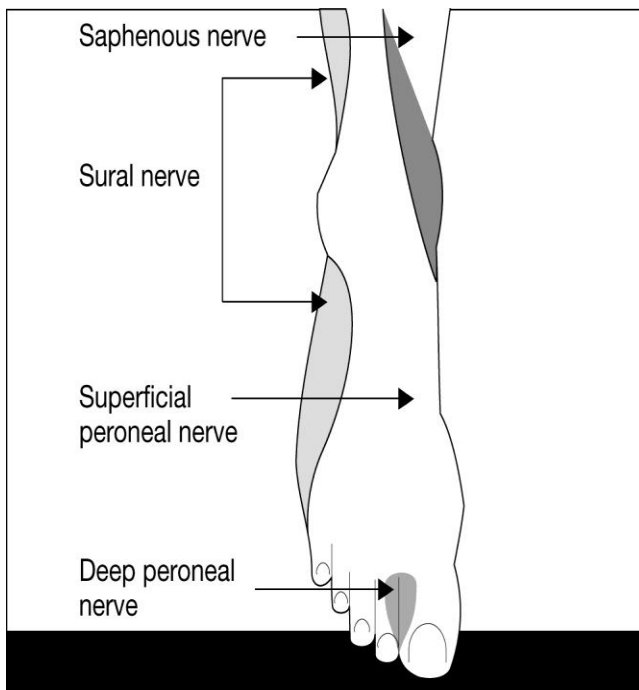
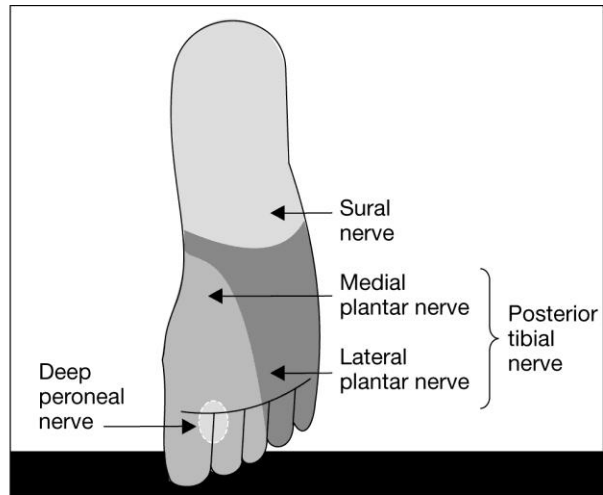
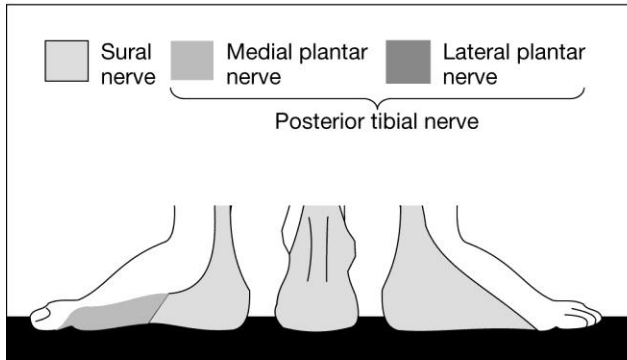
The sciatic nerve divides, forming two branches: common peroneal and tibial nerve. The common peroneal nerve descends laterally around the fibular head, dividing into superficial and deep peroneal nerves. The tibial nerve divides into the posterior tibial and sural nerve.

- Deep peroneal nerve- continues as an extension of the common peroneal nerve entering the ankle between the flexor hallucis longus tendons.
- Superficial peroneal nerve- continues as an extension of the common peroneal nerve entering the ankle lateral to the extensor digitorum longus.
- Posterior tibial nerve- continues as an extension of the tibial nerve entering the foot posterior to the medial malleolus where it branches into the lateral and medial plantar nerves. It is located behind the posterior tibial artery level adjacent to the medial malleolus.
- Sural nerve- continues as an extension of the tibial nerve entering the foot between the Achilles tendon and lateral malleolus.

The saphenous nerve is a terminal branch of the femoral nerve.

- Saphenous nerve- located anterior to the medial malleolus.

Sensory Distribution



- Deep peroneal nerve- provides sensation to the medial half of the dorsal foot and between the first and second digits.
- Superficial peroneal nerve- provides sensation to the dorsum of the foot as well as all five toes.
- Posterior tibial nerve- provides sensation to the heel, medial, and lateral sole of the foot.
- Sural nerve- provides sensation to the lateral foot.
- Saphenous nerve- provides sensation to the anteromedial foot.

Equipment

- Betadine and alcohol wipes
- Sterile gloves
- Sterile 4x4 or 2x2's
- Sterile towels
- 2-3 10 cc syringes with local anesthetic
- 22-25 gauge, 4 cm blunted needle

Local Anesthetic Choice and Considerations

Choice of local anesthetic depends on the length of blockade. Longer acting local anesthetics are slower in onset. Some anesthesia providers mix 2% lidocaine with 0.5% bupivacaine to help speed onset and still have a moderate duration of action. NEVER USE EPINEPHRINE! This can cause vasoconstriction and ischemia.

Common Local Anesthetics Onset and Duration

Local Anesthetic	Onset	Duration
1.5% mepivacaine	15-20 minutes	2-3 hours
2% lidocaine	10-20 minutes	2-5 hours
0.5% ropivacaine	15-30 minutes	4-8 hours
0.75% ropivacaine	10-15 minutes	5-10 hours
0.5% bupivacaine	15-30 minutes	5-15 hours

Be careful with the total volume of local anesthetic. Since there are 5 nerves to block around the ankle, the volume of local anesthetic may increase the risk of a tourniquet effect, resulting in ischemia. This should be a consideration for patients with peripheral vascular disease, and diabetics. The provider may choose to block specific nerves required for the surgical procedure. If this is done, inform the patient that portions of his/her foot may have normal sensation. Blocks should not be performed in infected tissue. The site of infection should be removed from the injection site. Check with the surgeon to ensure there is not a risk of tracking the infection into healthy tissue. If this is a risk, choose an alternative form of anesthesia.

Preparing for the Ankle Block

- Assemble required equipment
- Intravenous access with a running IV should be initiated and maintained prior to an ankle block. This provides for the administration of analgesics, sedatives, and emergency medications.
- Attach routine monitors including ECG, blood pressure, and pulse oximetry.
- Ensure that local anesthetics do NOT contain epinephrine.

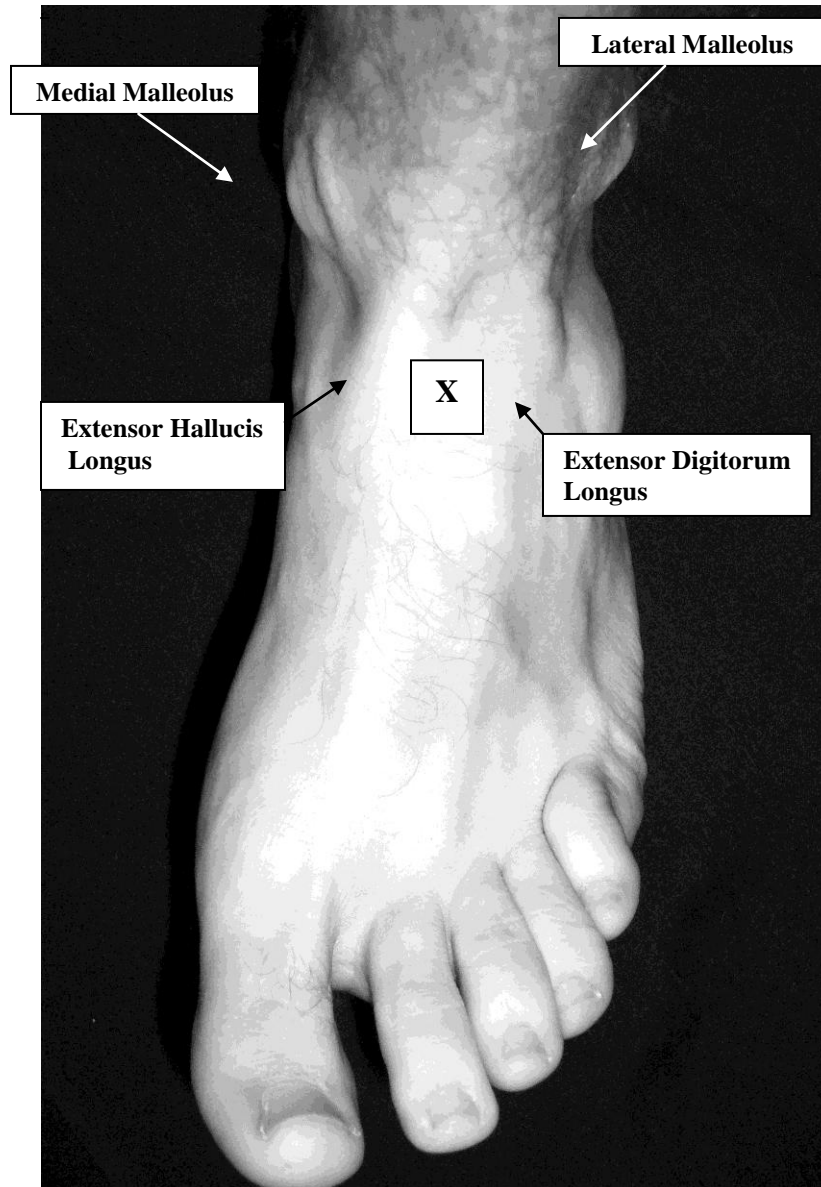
Performing the Ankle Block

Position the foot to access all five nerves. Placing blankets or pillows under the lower leg raises the foot off of the bed, improving access to all five nerves. Maintain sterile technique.

Blocking the Deep Peroneal, Superficial Peroneal, and Saphenous Nerve

Blockade of the deep peroneal, superficial peroneal and the saphenous nerves can be accomplished with one injection. The following steps should be followed:

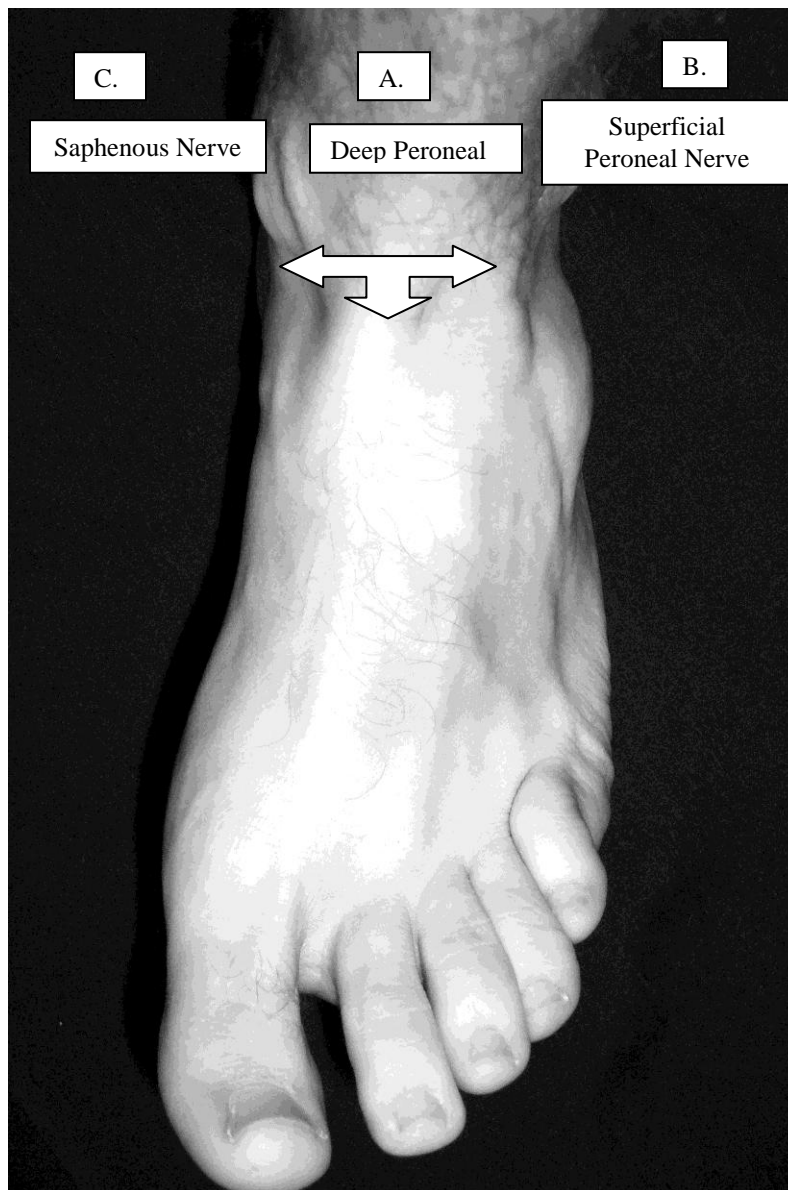
- Draw a line between the two malleoli
- Identify the extensor hallucis longus tendon by asking the patient to flex their toes, and palpate the anterior tibial artery, found between the extensor hallucis longus and the extensor digitorum longus muscle.



X = location of the deep peroneal nerve

- Place a skin wheal lateral to the artery

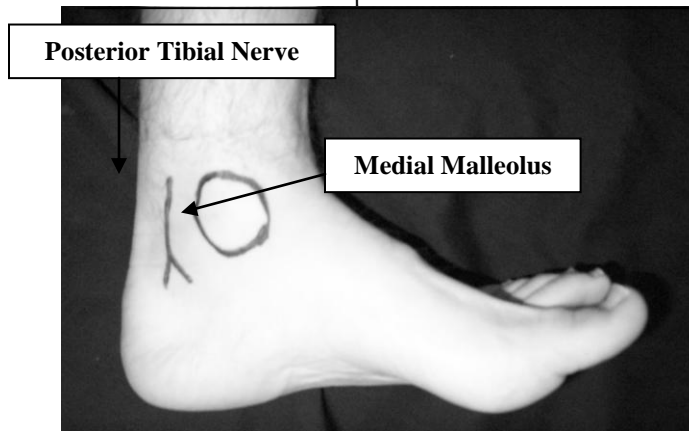
- Advance needle between these structures, perpendicular, aspirating for blood, and deposit 3-5 ml of local anesthetic deep to the extensor retinaculum. This will block the deep peroneal nerve.
- Bring the needle back, direct it superficially towards the lateral malleolus. Deposit 3-5 ml subcutaneously to block the superficial peroneal nerve.
- Now direct the needle superficially towards the medial malleolus. Deposit 3-5 ml subcutaneously to block the saphenous nerve.



- A. Deep Peroneal Nerve-** advance needle perpendicular and deep to the retinaculum.
- B. Superficial Peroneal Nerve-** direct needle superficially towards the lateral malleolus.
- C. Saphenous Nerve-** direct needle superficially towards the medial malleolus.

Blockade of the Posterior Tibial Nerve

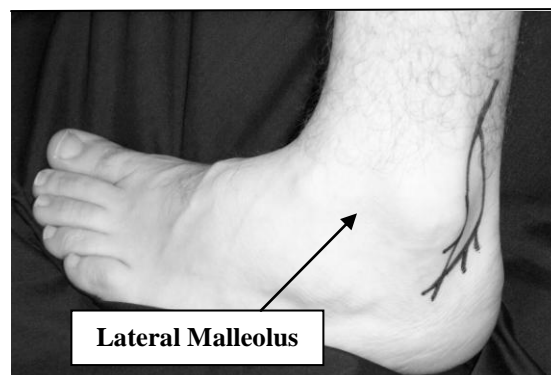
- Warn the patient to hold still in case a paresthesia is elicited! Movement may cause trauma to the nerve.
- Identify the posterior tibial artery by palpation
- Insert the needle posterolateral to the artery, at the level of the medial malleolus. Advance the needle slowly and carefully.
- If a paresthesia is elicited, withdraw the needle slightly and inject 3-5 ml of local anesthetic. Make sure that the patient does not experience a paresthesia with injection.
- Inject 7-10 ml of local anesthetic solution as you withdraw the needle. A paresthesia is not necessary for successful blockade of the posterior tibial nerve.



Blockade of the Sural Nerve

- Identify the lateral malleolus and Achilles tendon
- Insert the needle superficially, lateral to the tendon, in the direction of the lateral malleolus. Inject 5-10 ml of local anesthetic subcutaneously as the needle is withdrawn.

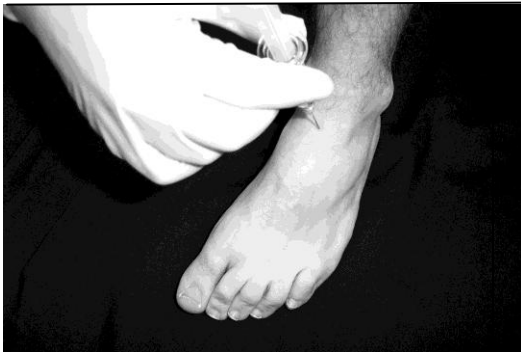Sural Nerve



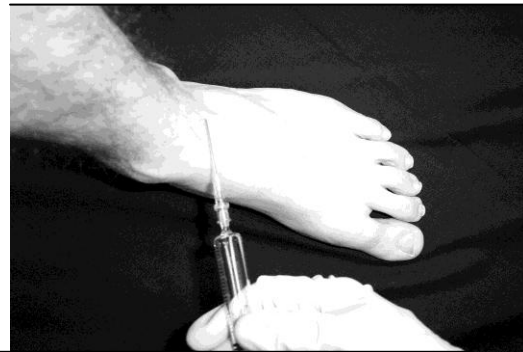Complications

- Discomfort- conscious sedation for amnesia and analgesia
- Injury to the patients foot after discharge due to a “numb” foot- instruct patient to be aware of where their foot is and to be careful not to injure it
- Nerve injury or paresthesia- do not inject if patient complains of paresthesia or if resistance is met during injection. Do not repeat injections to anesthetized sites. Most paresthesia’s are self limiting.
- Hematoma and vascular injury- avoid puncture of veins or arteries. Avoid multiple injection sites. Always aspirate. If a vessel or artery is punctured, hold pressure for 5 minutes, ensuring homeostasis.
- Infection- rare if sterile technique is used
- Intravascular injection- aspirate frequently during injection. The risk of local anesthetic toxicity is low.
- Block failure- may be supplemented by the surgeon or anesthesia.

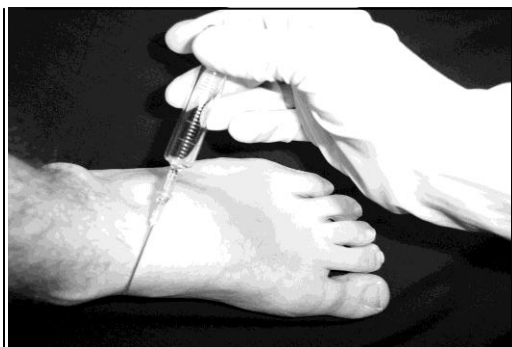Placement of Ankle Block



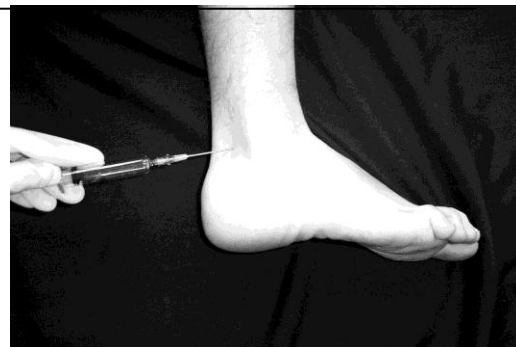A. Deep Peroneal Nerve



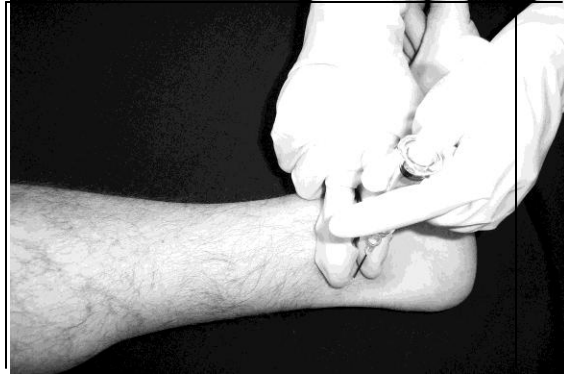B. Superficial Peroneal Nerve



C. Saphenous Nerve

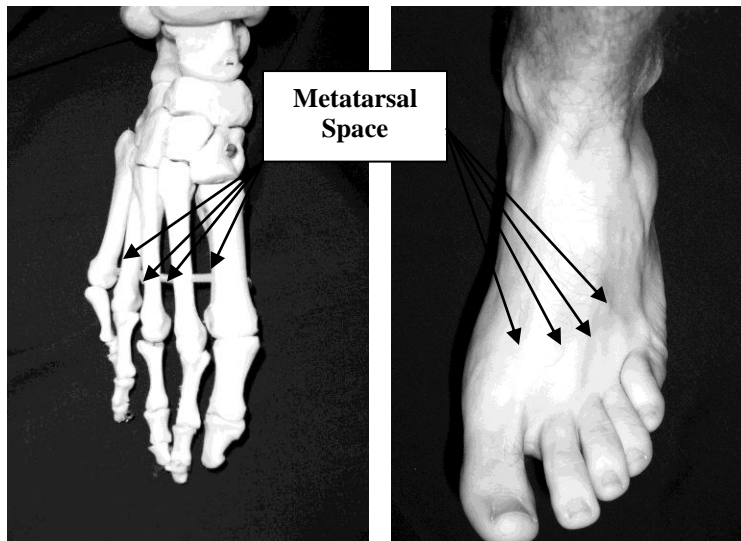


D. Sural Nerve



E. Posterior Tibial Nerve

Metatarsal Block of the Foot



A metatarsal block may supplement an ankle block if a nerve distribution has been missed. Never use epinephrine containing solutions. This can result in ischemia of the digits. Place a small skin wheal at the site of injection on the dorsum of the foot. Advance the needle while injecting local anesthetic parallel to the metatarsal bone. Do not go through the surface of the sole of the foot! The individual nerves are located closer to the sole of the foot than the dorsum. A total of 3-5 ml of local anesthetic solution may be deposited. The same procedure should occur on the other side of the metatarsal of the location that anesthesia is desired.

References

Burkard J, Lee Olson R., Vacchiano CA. Regional Anesthesia. In Nurse Anesthesia 3rd edition. Nagelhout, JJ & Zaglaniczny KL ed. Pages 977-1030.

Morgan, G.E. & Mikhail, M. (2006). Peripheral nerve blocks. In G.E. Morgan et al *Clinical Anesthesiology*, 4th edition. New York: Lange Medical Books.

Wedel, D.J. & Horlocker, T.T. Nerve blocks. In Miller's Anesthesia 6th edition. Miller, RD ed. Pages 1685-1715. Elsevier, Philadelphia, Penn. 2005.

Wedel, D.J. & Horlocker, T.T. (2008). Peripheral nerve blocks. In D.E. Longnecker et al (eds) *Anesthesiology*. New York: McGraw-Hill Medical.