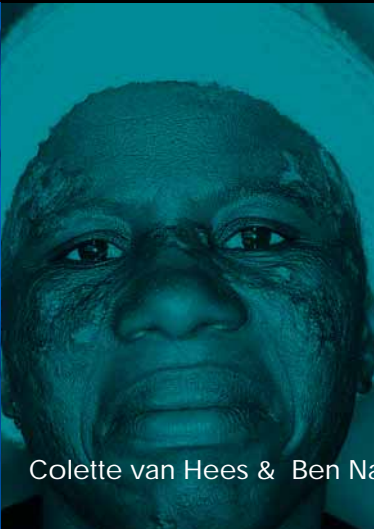



Common Skin Diseases in Africa
An illustrated guide



Colette van Hees & Ben Naafs

ISBN 90-9014738-1

*This guide was produced by the authors and the printer on a non-profit basis.
The contents may be reproduced with proper acknowledgement,
on the condition that they are not used for financial gain.*

CONTENTS	Page
INTRODUCTION	7
THE PATIENT WITH A SKIN PROBLEM	8
SOME NOTES ON TOPICAL TREATMENT	8-9
ECZEMA	11
Atopic eczema	11-12
Pityriasis alba	13
Infantile eczema	14-15
Seborrhoeic eczema	16-17
Lichen simplex	18
Infective eczema	19
Contact eczema	20-21
FUNGAL / YEAST INFECTIONS	
Mycids	23
Tinea corporis	24
Tinea capitis	25
Tinea unguium	26
Athlete's foot	27
Pityriasis versicolor	28
Candidiasis	29
Mycetoma	30
BACTERIAL INFECTIONS	
Impetigo	31
Folliculitis	32
Folliculitis keloidalis nuchae	33
Erythrasma	34
Secondary syphilis	35
Yaws	36
Leprosy	37-41
Buruli ulcer	42
Noma / cancrum oris	43

VIRAL INFECTIONS

HIV infection	45
Pityriasis rosea	46
Chickenpox	47
Herpes zoster	48-49
Herpes simplex	50-51
Kaposi's sarcoma	52-54
Warts	55-59
Molluscum contagiosum	60

PARASITIC INFECTIONS

Creeping eruption	61
Scabies - Crusted scabies	62-63
Leishmaniasis	64
Lymphatic filariasis	65
Onchocerciasis	66

AUTO-IMMUNE DISEASE

Alopecia areata	67
Chronic bullous dermatosis of childhood	68
Chronic discoid lupus erythematoses	69
Lichen planus	70
Vitiligo	71

MISCELLANEOUS SKIN DISEASES

Acne	73
Albinism	74
Dermatosis papulosa nigra	75
Drug eruptions	76-78
Hemangioma	79
Infantile acropustulosis	80
Keloids	81
Malignant melanoma	82
Papular pruritic eruption	83
Pearly penile papules	84
Porphyria cutanea tarda	85
Psoriasis	86-87
Urticaria - Papular urticaria	88-89

INTRODUCTION

The importance of skin diseases is often overlooked. They are usually not life-threatening and tend to be "shrugged away".

Skin diseases are, however, a significant problem all over the world. In 1996 11,3 % of the new attendances presenting at all OPD's in Masvingo Province, Zimbabwe concerned skin diseases (Masvingo Health Profile 1996, HIS Office, PMD Masvingo). These figures are similar elsewhere. This guide originated there to provide a quick and easy reference for diagnosis and management of common skin diseases in Zimbabwean clinics and hospitals (Common skin diseases in Zimbabwe, an illustrated guide, ISBN 90-9013558-8).

In order to facilitate the use of the guide in East and West Africa as well as in Southern Africa Dr Ben Naafs has joined me in preparing the current edition. His helpful comments and contributions on leprosy and other common skin diseases occurring outside of Southern Africa have broadened its scope substantially.

Nowadays many skin diseases are related to or influenced by concomitant HIV infection. These conditions are presented rather than other, rare skin diseases. There are many more congenital malformations and syndromes, benign and malignant tumours, tropical infections, skin manifestations of systemic and metabolic disease, auto-immune diseases etc. which are important but fall outside the context of this book as they are not common. On the other hand some common skin diseases like myiasis and jiggers are not included because they seldom reach a clinic, people know how to deal with them. Needless to say, when you are in doubt about a diagnosis the patient should be referred to a skin specialist.

When care is taken to make the proper diagnosis and to institute the proper treatment the management of skin diseases often results in great improvement and satisfaction for patient and health care worker alike. Treatments required generally need not be expensive and are locally available.

Our sincere thanks go to everyone who supported us in preparing this book and notably Jan Sterken of Studio Oss for producing the book on a non-profit basis. We would especially like to thank the patients who appear in this book for allowing us to use their photographs for publication.

Colette van Hees, 2001.

THE PATIENT WITH A SKIN PROBLEM

A patient who presents with a skin problem often complains of "itchy rash all over the body". Indeed many patients are referred to the skin clinic with "itchy rash all over the body" as a diagnosis. After taking a history and performing a proper skin examination you may find he or she is suffering from anything as varied as eczema, urticaria, a drug reaction, a skin infection, scabies or any other skin disease. A proper skin examination should be performed in good light, preferably daylight. Ideally the whole skin should be examined. The aspect, extent and localisation of all the lesions is essential for making a diagnosis and will influence your management.

Some terms used to describe skin lesions are: **Macule:** Circumscribed colour change without change in the level of the skin. **Papule:** Small superficial circumscribed elevation. **Plaque:** Superficial circumscribed elevation larger than a papule. **Lichenification:** Thickening of the skin with exaggeration of the normal skin lines and deepening of the natural creases, caused by scratching and rubbing. **Nodule:** Circumscribed, solid proliferation, clearly apart from surrounding tissue and often occurring in the dermis or subcutis. **Pustule:** Blister filled with pus. **Wheal (hive):** Temporary elevation of the skin caused by oedema in the upper dermis causing severe itchiness. **Atrophy:** thinning, wasting away of the skin.

8

SOME NOTES ON TOPICAL TREATMENT

Vaseline and mineral oil are widely used as a moisturiser in Africa. They are an important cause of skin problems. They cover the pores of sweat ducts so that sweat and other fluids are unable to get out. This causes irritation, which will worsen any inflammatory skin condition. Also, bacteria and fungi trapped in this warm and humid environment will thrive and overgrow resulting in clinical infection.

Aqueous cream or **emulsifying ointment** are good alternatives to vaseline for use as a moisturiser. They are generally available in supermarkets and chemists. Vegetable oils, e.g. coconut oil, can be used as well, provided they are applied on wet skin.

Ointments or creams: as a rule a cream base is preferred for wet and acutely inflamed lesions, an ointment for chronic, dry or lichenified lesions.

Topical steroids: the mildest topical steroid is hydrocortison acetate

1% cream or ointment. In cases where a steroid is indicated, for example eczema, start with hydrocortisone 1% before prescribing a stronger steroid such as betamethasone valerate 0.1%. Use a *cream* for wet and acute lesions, an *ointment* for chronic and dry lesions. Always use strong topical steroids intermittently (e.g. use 3 days, stop 4 days in a week). Do not use strong topical steroids for the face or the genital area, or on babies. When only strong topical steroids are available they may be diluted on the palm of the hand with an equal amount of cooking oil.

Imidazole preparations: there are many antifungal imidazole creams i.e. miconazole, clotrimazole, econazole, and ketoconazole. Use whichever is available.

Potassium permanganate solution 1:4000 to 1:10.000 should always be prepared freshly as it is inactivated rapidly after being diluted. It is an astringent (decreases oozing), antiseptic and mild antifungal. A pinch of the crystals in a bucket of water should give a solution with a pink colour (the colour of a fingernail). A purple solution is too strong, it will leave brown stains. A degraded solution is brown in colour. Soak dressings in the bucket or bathe affected body parts.

Coal tar paste or ointment: this has anti-inflammatory and anti-itch properties. It is used e.g. in chronic eczema and psoriasis, as an alternative to topical corticosteroids. It has photosensitising properties and should therefore be applied at night and washed off in the morning on sun-exposed areas. In chronic plaque psoriasis this quality of coal tar may be used specifically: apply coal tar to psoriatic lesions, expose to sun for a short time, e.g. 30 minutes, then wash off. The exposure time may be increased slowly if the treatment is tolerated.

Salicylic acid ointment: removes scales and softens thickened, horny skin and crusts.

Urea ointment or cream: urea is a strong moisturiser. It helps soften and smooth the horny layer and aids the penetration of other drugs. It is used in dry skin conditions, e.g. atopic eczema. It can cause a burning feeling when used on damaged skin.

GV paint: GV or Gentian Violet solution (0,5–1%) has antifungal and antiseptic properties. It is used for superficial infections of the skin and mucous membranes. It stains skin and clothing. When kept for too long, fluid may evaporate and the solution becomes too strong (>1%), this will damage the tissues.

Sulphur: Sulphur has antiseptic properties and promotes desquamation. It dries the skin and is antiseborrheic.

ECZEMA

The terms eczema and dermatitis are often used to describe the same condition. Eczema is a non-infectious inflammation of the skin. It may be acute, subacute or chronic and is influenced by many factors, i.e. constitutional, irritant (vaseline, mineral oils, soaps and detergents – vegetable oils usually are no problem), allergens, heat, stress, infection etc. An acute eczema characteristically shows redness, swelling, papules, blisters, oozing and crusts. Progressing to the subacute stage, the skin is still red but becomes drier and scaly and may show pigment changes. In the chronic stage lichenification, excoriations, scaling and cracks are seen. There are many different types of eczema, the most common ones will be presented on the following pages. They may have predominantly acute, subacute or chronic phases. Itching is often the major complaint.

ATOPIC ECZEMA

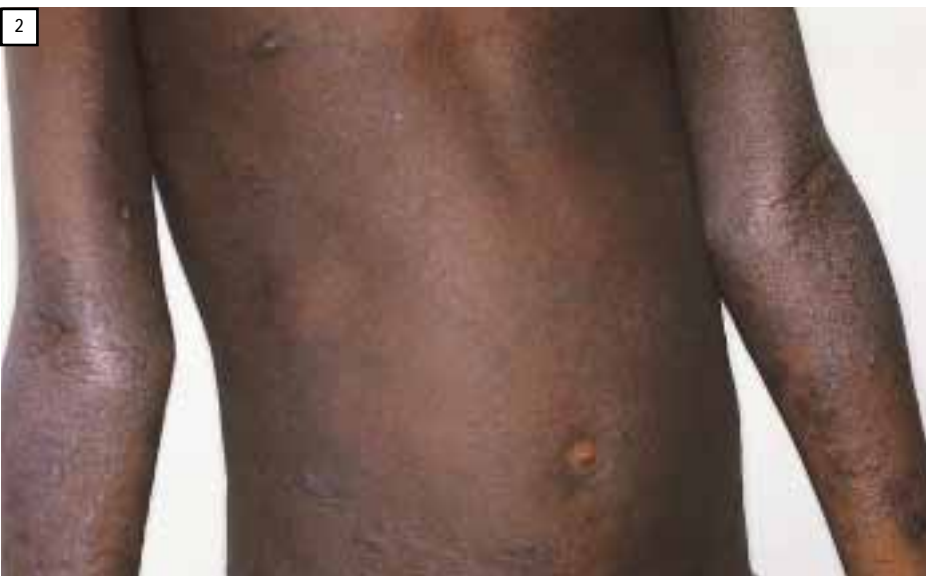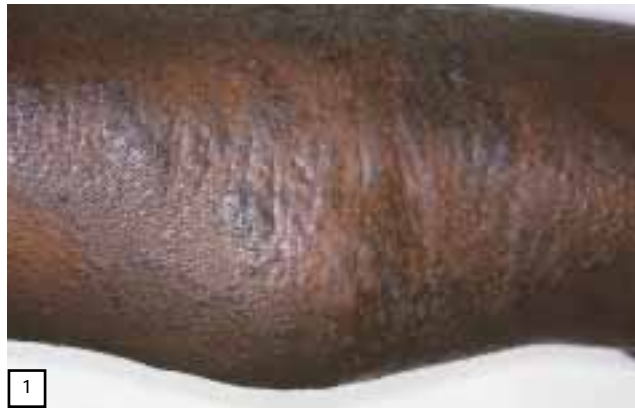Atopic eczema is a multifactorial skin disease seen in patients with an atopic constitution. This means that they have a genetic pre-disposition for hypersensitivity reactions such as asthma, hay fever and atopic eczema. The eczema comes and goes and may be triggered or worsened by dryness of the skin, infections, heat, sweating, contact with allergens or irritants and emotional stress. **Atopic eczema in children and adults** appears in elbow- and knee-folds, on the wrists and ankles and on the face and neck, in some cases it may become generalised. Itch is an important feature. In long-standing disease lichenification is common.

Management of atopic eczema in children and adults

- Explain to the patient the recurrent nature of the disease! Take the time to explain daily skin care as described below, and how to use the drugs prescribed.
- Stop the use of irritants such as vaseline, mineral oils and soap. Avoid temperature extremes and contact with wool. Use a non-greasy moisturiser such as aqueous cream, if the skin is very dry urea 5% or 10% ointment. Soap is an irritant, especially if not rinsed off properly after use. In active phases of eczema use aqueous cream or emulsifying ointment as a soap.
- In severe eczema, the patient should take rest.
- Lesions: - A mild topical steroid such as hydrocortisone 1% (cream for acute or wet, ointment for chronic or dry lesions) once to twice daily until lesions clear, usually in about 2 weeks.
 - In severe or refractive cases a stronger steroid e.g. betamethasone

- 0.1% once daily for 1-2 weeks. Do not use strong steroids in the face.
- Always use topical steroids intermittently when they are used over longer periods of time.
 - Chronic lichenified cases: coal tar 2-10% paste/ointment at night.
 - For severe itchiness use antihistamines e.g. promethazine 25 mg at night.
 - For bacterial superinfection use betadine shampoo as a soap or when weepy bathe in potassium permanganate 1:4000 solution. In severe or widespread infection give antibiotics (cloxacillin, erythromycin) as in *impetigo*.

Fig. 1 & 2. Recurrent atopic eczema in an 8 year old boy showing lichenification in the elbow folds.



PITYRIASIS ALBA

Pityriasis alba is a mini-form of eczema which occurs predominantly in infants, children and adolescents. Multiple hypopigmented, vaguely bordered, very finely scaling patches are found on the face and/or trunk, and sometimes the extremities. This can persist for years and the hypopigmentation usually does not clear with steroids, but will clear in time.

Management of pityriasis alba

A short course of hydrocortisone 1% cream or ointment for pityriasis alba may be given in case of itchiness or when there is evidence of concomitant atopic eczema. Usually it is enough to explain to the patient or the parents that the condition is not serious and will disappear in time.

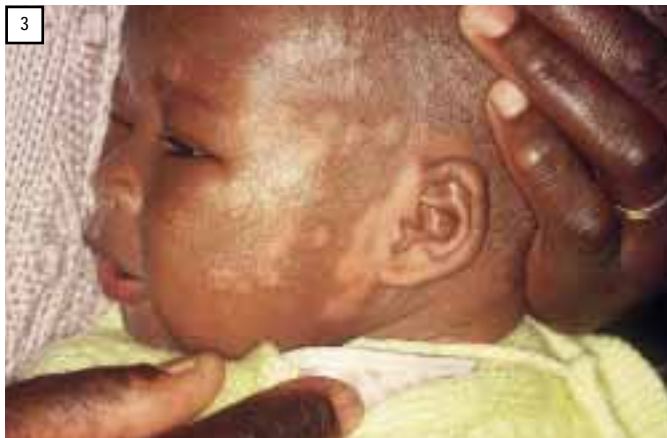

Fig. 3. Scaling hypopigmented macules of pityriasis alba after concomitant atopic eczema was treated.

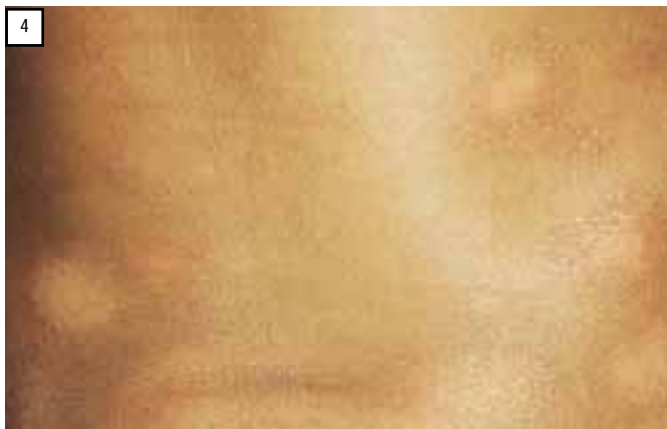

Fig. 4. Pityriasis alba on the back of a 4 month old girl.

INFANTILE ECZEMA

In **infants** atopic eczema is often papular and tends to occur on the face and the neck, the trunk, the hands and feet, which may be scratched open causing bacterial superinfection. The major complaint these infants have is itch. Often young infants also have seborrheic eczema especially on the scalp, in the nappy area and body folds. Attempts to differentiate between the two become difficult. For practical purposes the term infantile eczema is therefore used. In the majority of cases the course is chronic recurrent up to age 2 to 3 years, after which the eczema disappears. In a minority it progresses to childhood or adult atopic eczema.

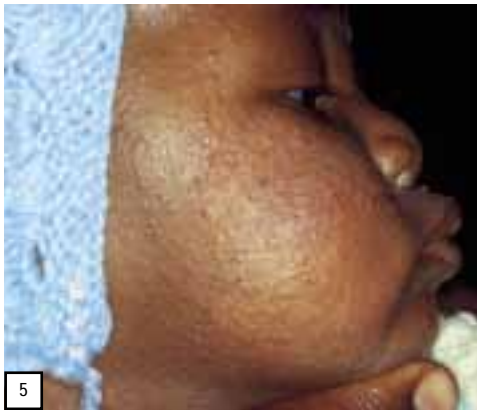Management of infantile eczema

- Explain to the parents the recurrent nature of the disease! Also reassure them that the eczema will most likely clear completely after some months to years. Explain how to take care of the skin and how to use topical medication.
- Stop the use of irritants such as vaseline and excessive use of soap, contact with wool, excessive sweating and temperature extremes. Bathe the baby using aqueous cream or emulsifying ointment as a soap. Apply moisturiser (aqueous cream, emulsifying ointment or coconut oil) while child is still wet.
- Keep fingernails short, cover itchy lesions with loose, airy clothing.
- Lesions:
 - A mild topical steroid such as hydrocortisone 1% once to twice daily until lesions clear, usually 1 or 2 weeks. Continue aqueous cream etc. and re-apply steroid only when lesions recur.
 - **Always use topical steroids intermittently when they are used over longer periods of time.**
 - In chronic cases with lichenification: coal tar 2-10% paste or ointment Apply this nightly because of its photosensitising potential.
 - Eczema in the nappy area, armpits and on the scalp is usually seborrheic in origin: use an imidazole or sulphur 3-5% cream twice daily. In the nappy area cover with a thick layer of zinc oxide paste.
- Itchiness: only in severe cases use a sedating antihistamine like promethazine. Take care not to overdose in infants!!
- For superinfection use betadine shampoo or bathe in potassium permanganate 1:4000 solution (this is **pink**, not purple, a purple solution is too strong, it will stain the skin and cause irritation), and if necessary antibiotics (cloxacillin, erythromycin).

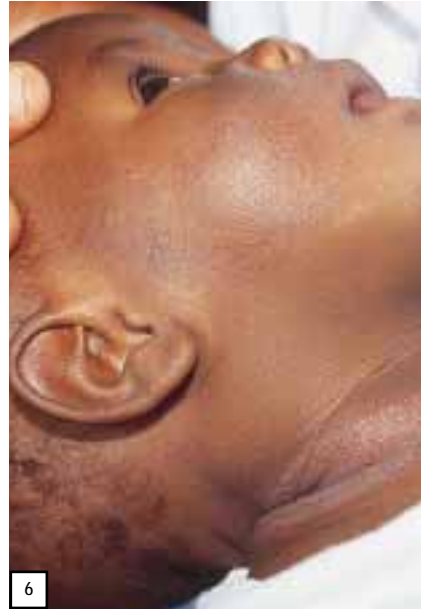Fig. 5. Papular infantile eczema on the face in a 5 month old girl.

Fig. 6. A common localisation of infantile eczema is the neck. The use of hats or caps with straps around the neck should be discouraged.

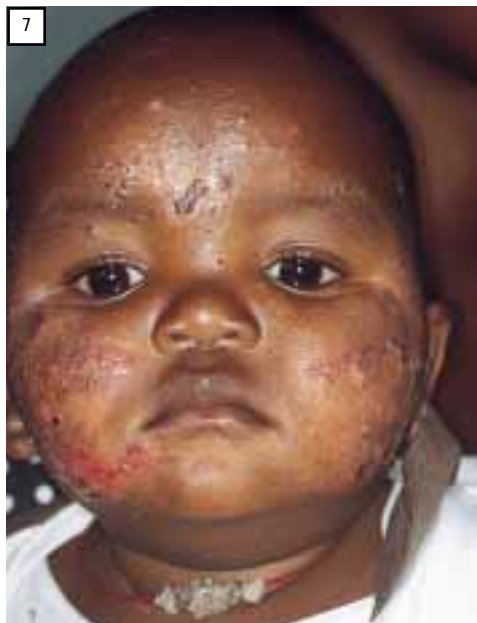Fig. 7 & 8. Infected infantile eczema.



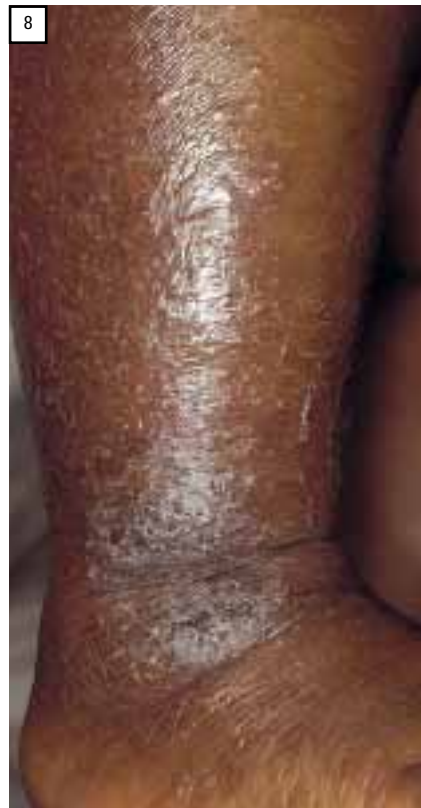5



6



7



8

SEBORRHOIC ECZEMA

This is an eczema with classically greasy scales on seborrheic areas of the skin; scalp, border of forehead/scalp, behind ears, above and in between eyebrows, in nasolabial folds, chin, the sternum, the middle of the upper back in between the shoulder blades, in axilla, groin and perianal area. Constitutional and stress factors play a role as well as a yeast, *pityrosporum ovale*, which is found in sebaceous glands. Patients often complain of oily skin as a result of their pronounced sebum production. The eczema comes and goes.

In mild cases only the face, scalp and chest are affected. Sometimes, and commonly in case of immunosuppression such as in HIV-infected persons the eczema can become very widespread and easily superinfected. It occurs in armpits and groin and is conspicuous behind the ears. It may generalise to cover the entire skin. Usually you will still find the typical greasy scales in e.g. the nasolabial folds. The entire skin is inflamed, red to a darker shade than normal.

Management of seborrheic eczema

- Stop vaseline, use a non-greasy or no moisturiser.

For minor lesions e.g. only on seborrheic areas in the face and on the scalp:

- An imidazole cream twice daily (suppresses *pityrosporon*) with or without hydrocortisone, sulphur 3-5% cream with or without hydrocortisone, or hydrocortisone cream twice daily. For chronic scaling salicylic acid 2-5% ointment or sulphur 2-5% ointment. Warn the patient that the eczema will probably recur.

9

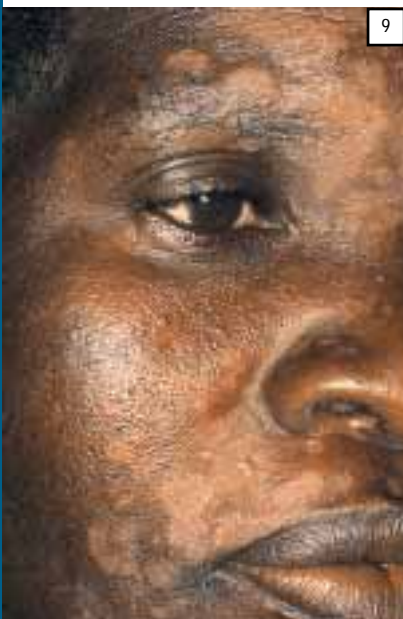For acute and severe, widespread lesions (usually infected):

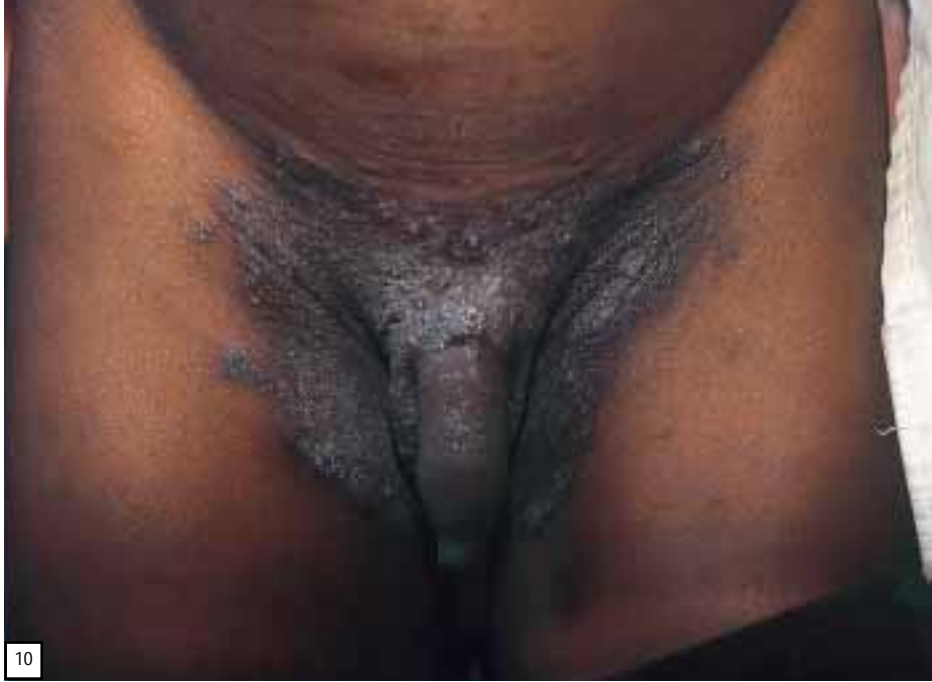- Hydrocortisone cream once or twice daily.
- An imidazole cream twice daily.
- Ketoconazole 200 mg once daily or 200 mg on alternate days orally 1-3 weeks.
- Antibiotics and betadine scrub/potassium permanganate solution as required.

For chronic recurrent widespread lesions:

- At night: Coal tar 2-6% in zinc paste or coal tar ointment or coal tar + sulphur 5-10% ointment (not on wet lesions).
- Daytime: Hydrocortisone cream or betamethasone cream once daily and / or an imidazole cream twice daily.
- Salicylic acid 2% or 5% ointment twice daily for dry scaling lesions.
- Systemic ketoconazole in low doses as above may be added when severe.
- Antibiotics and antiseptics as required.

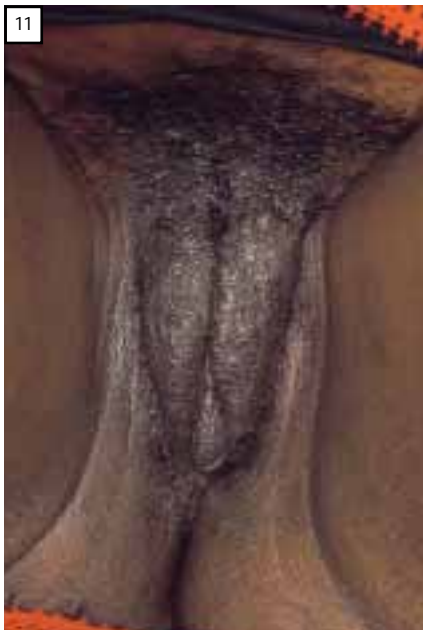Fig. 9. Typical greasy scales of seborrheic eczema in the face.



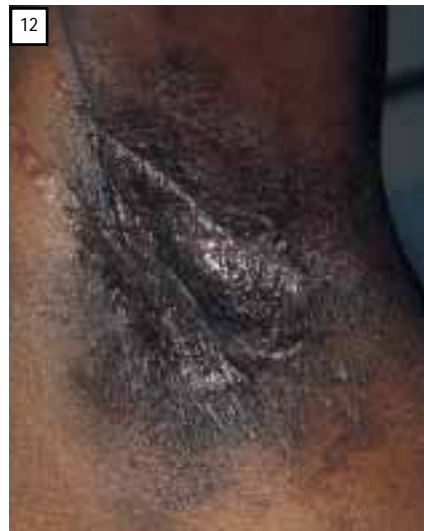

10

*Fig. 10. Infected Seborrheic eczema of the groin in a HIV positive 7 year old boy.
Fig. 11 & 12. Seborrheic eczema of groin and armpit easily becomes superinfected and is very common in HIV infected patients.*



11



12

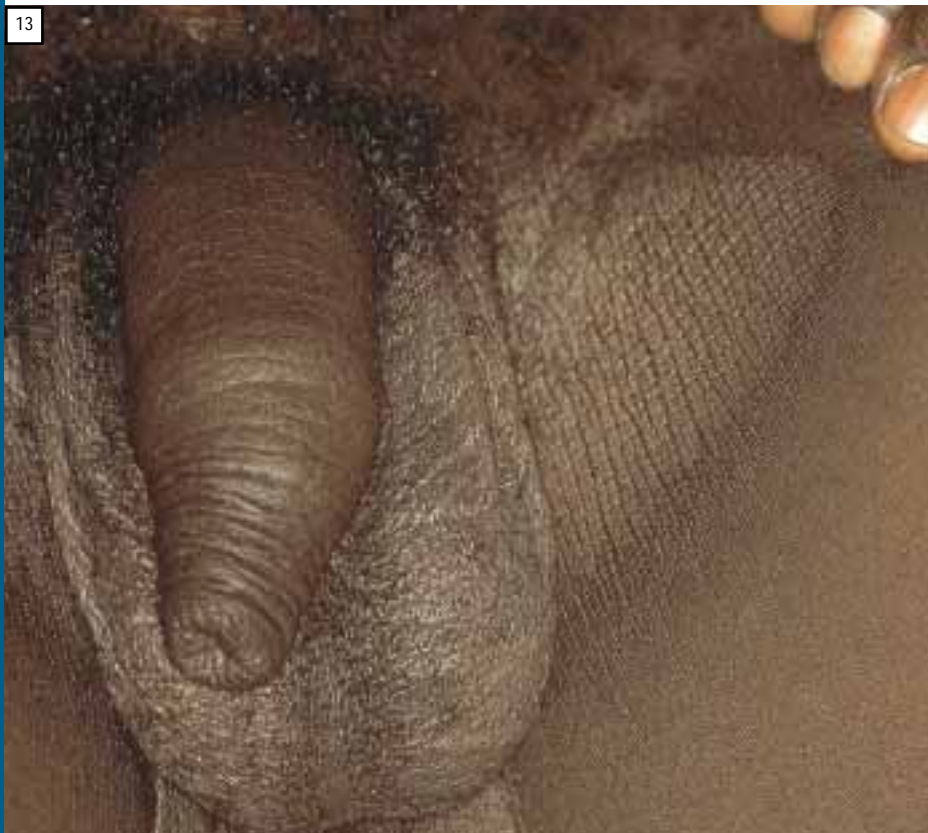LICHEN SIMPLEX

In lichen simplex there is one (sometimes more) well-circumscribed patch of lichenified skin which is very itchy. Lichenification means thickening of the skin with exaggerated skin lines and this is usually caused by continuous scratching, rubbing with a stone or stick and the likes. Patches are commonly seen in the neck, in the genital area and on the lower legs.

Management of lichen simplex

- The vicious circle of -itch-scratch-lichenification-itch- needs to be broken. The patient must therefore make a conscious effort to stop scratching!
- Coal tar ointment or coal tar in zinc paste applied nightly to reduce itching.
- Application of simple zinc-adhesive tape may prevent scratching and help to break the vicious cycle.
- A strong topical steroid, especially if applied at night under plastic occlusion (e.g. twice weekly) is usually very effective. To do this cover the lesion with plastic after applying the steroid, then tape the sides of the plastic to surrounding skin. Do not apply plastic occlusion in the genital area.

Fig. 13. Lichen simplex of the groin showing lichenification.



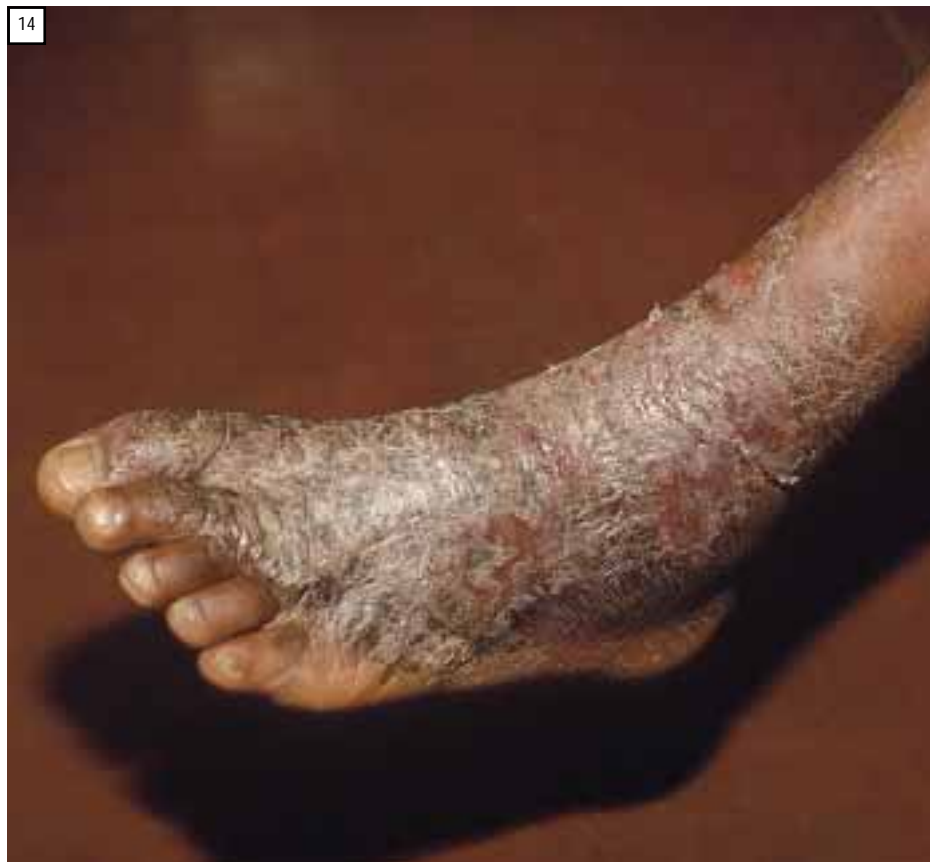INFECTIVE ECZEMA

This is an eczema which occurs as a response to an oozing skin infection. The most common localisation is the foot/ankle region, especially around the instep. Causative organisms are usually staphylococci or streptococci. The use of vaseline often aggravates the condition.

Management of infective eczema

- Stop the use of vaseline.
- Treat the infection with antibiotics (cloxacillin, erythromycin) and/or antiseptics (betadine solution/scrub, GV paint, potassium permanganate baths).
- When dry, add a topical steroid, starting with hydrocortisone cream twice daily.
- Prevent recurrences by preventing irritation (no vaseline, sweating), habitual scratching (instruct the patient, use aqueous cream, calamine lotion, keep fingernails short, cover at night) and infection (use betadine scrub as a soap for 4 weeks).

Fig. 14. Infective eczema.



14

CONTACT ECZEMA

Contact eczema is caused by contact of the skin with an irritant or an allergen.

Chronic irritant contact eczema is caused by excessive, repeated contact of an irritant with the skin. Vaseline commonly causes "vaseline dermatitis", which presents with papules and pustules on the lower legs, often of schoolgirls. Common causes of irritant contact eczema on hands, arms and legs are excessive use of water, soap (especially if not washed off properly after use) and detergents, and many types of chemicals (e.g. alkaline and acid solutions, organic solvents such as alcohol, benzene, toluene, gasoline). Saliva may cause "lip-licking disease" through repeated wetting of the skin around the lips.

Acute and chronic allergic contact eczema develop after sensitisation to an allergen through previous contacts with the same allergen.

In **acute allergic contact eczema** the contact site shows redness, small or large blisters which on bursting become oozing red erosive areas, and finally crusting and scaling. When the allergic reaction is set off by exposure to sunlight it is a photo-allergic contact eczema. Some soaps contain photo-allergens which cause these reactions. The history (e.g. "I have applied betadine dressings on that site") and the usually sharp margins of the eczema help define the causative allergen.

Chronic allergic contact eczema usually shows a symmetrical distribution and blurred borders. The skin is usually dry, scaly and shows lichenification (thickening), often cracks. It can spread to sites distant from the original contact making it difficult to determine the cause.

Some examples of contact allergens are: occupational (dyes, preservatives, rubber, bleach, soap, floor wax, nickel, oils, diesel, fertilisers, pesticides, cement), environmental (plants, spices), medical (betadine, lanolin, local anaesthetics, menthol, camphor), cosmetic (perfumes, nail polish, hair-chemicals), clothes or jewellery (chromate, nickel, rubber, dyes). This list is not complete. Allergy testing may be done by a dermatologist or allergologist.

Fig. 15. Allergic contact eczema caused by betadine dressings.



Management of contact eczema

- **Avoid contact with the relevant irritant or allergen!**
- **Avoid soap and vaseline, use aqueous cream/emulsifying ointment instead.**
- Vaseline dermatitis: use calamine or phenol-zinc lotion, betadine scrub or shampoo, use no vaseline for months or rather years.
Severe infection: cloxacillin or erythromycin for 1 week.
- Acute contact eczema: Wet dressings with saline or potassium permanganate solution twice daily. For itch calamine lotion or phenol-zinc lotion. When dry a topical steroid cream e.g. hydrocortisone 1% twice daily. Antihistamines orally e.g. promethazine 25 mg nightly for 5 days.
- Chronic contact eczema: Hydrocortisone 1% ointment, if necessary stronger topical steroid. Coal tar ointment for itch nightly. Aqueous cream, emulsifying ointment. If lichenified: urea 10% ointment or salicylic acid 2-5% ointment twice daily.
- If photo-allergic: sunprotection (sunhat, long sleeves, high collar).

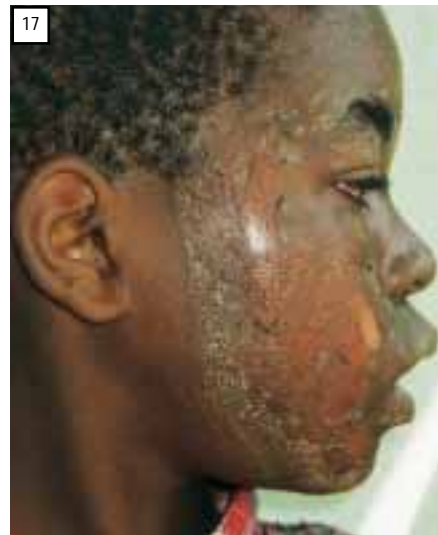
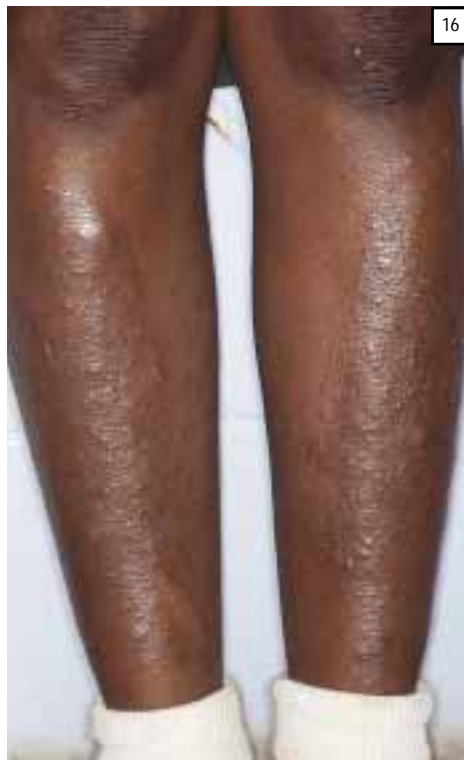
Fig. 16. Typical papules and pustules of "vaseline dermatitis" in a 14 year old schoolgirl.
Fig. 17. Acute photo-allergic contact eczema, in this case caused by Lifebuoy soap.

FUNGAL / YEAST INFECTIONS

Fungal infections may occur at any age. Children may easily infect each other or get infected by animals / pets. The most common fungal infection is "athlete's foot" = infection of the interdigital spaces of the toes. Skin, nails and / or hair may be infected. When a fungal infection is treated incompletely or too short it will almost certainly recur. In immunosuppressed patients fungal infections may be more widespread and take longer to treat than normal. **Always ask your patient to come for review when his or her treatment is about to be completed, if you then see any remaining sign of infection continue the treatment, as it is likely to recur if you do not.**

MYCIDS

A hyperergic reaction to the fungus may occur in the course of fungal infections. These are usually itchy eruptions of small blisters at a site distant from the fungal infection, often the hands and fingers (pompholyx). No fungi are found within these "mycids". They disappear when the causative fungal infection is treated. Sometimes the itching is so severe that treatment is advisable: a strong steroid cream under wet dressings for a couple of days.

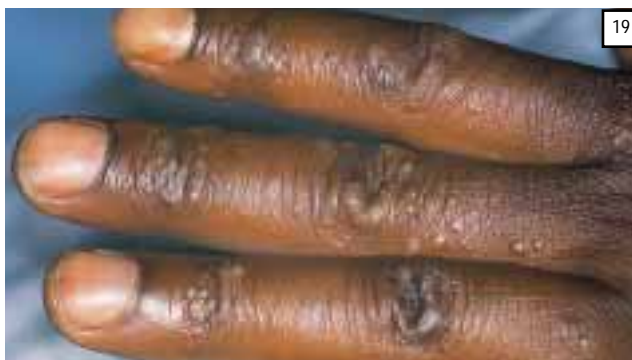
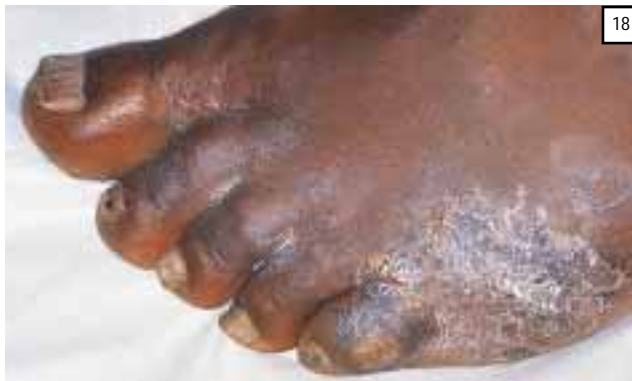
Fig. 18 & 19. A 53 year old man with a fungal infection of the foot and a mycid reaction on the hands.

Fig. 20. *Tinea corporis* of 2 years duration in a 32 year old woman.

Fig. 21. Concentric scaling macules of *tinea corporis* on the arm of a 31 year old woman.

TINEA CORPORIS

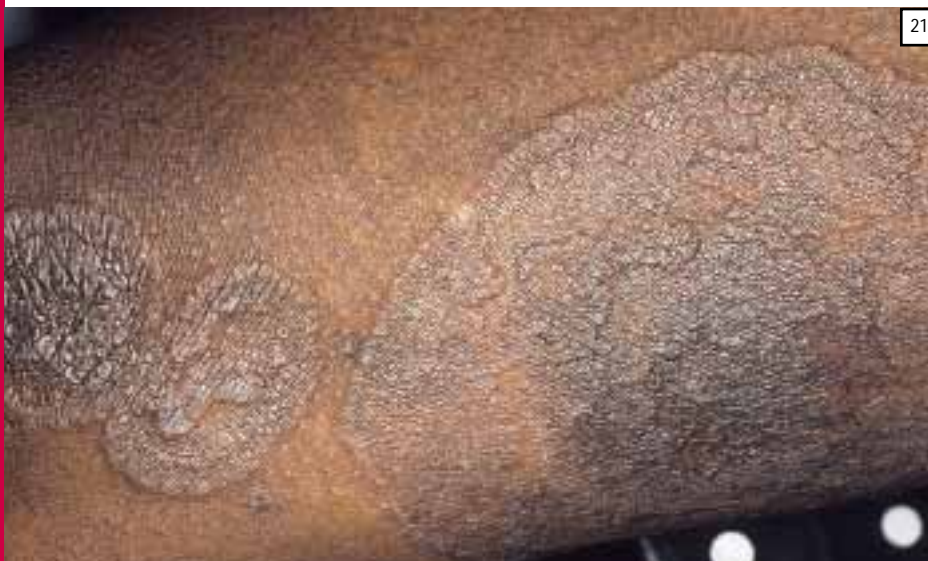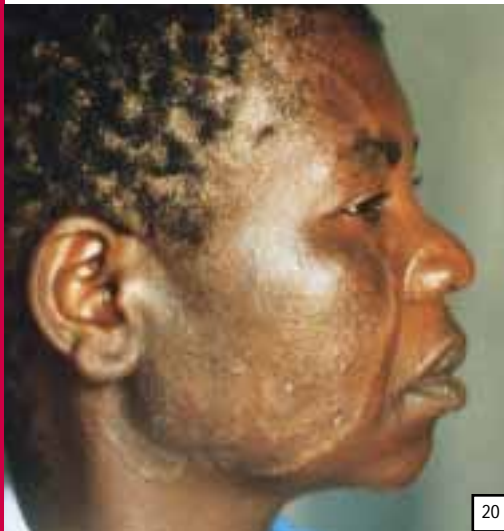Fungal infection of the skin, most common on the exposed surfaces of the body, namely the face, arms and shoulders. Tinea or ringworm presents in typical round lesions, which show scaling at the periphery, or in concentric rings. Usually one or a few lesions are seen and only topical treatment is necessary. Multiple, large or widespread lesions may be seen if a patient delays seeking treatment for a long time or is malnourished or immunosuppressed.

Management of tinea corporis

- An imidazole cream or Whitfield's ointment twice daily for a minimum of 4 weeks.
- Continue treatment until one week after symptoms have cleared.

Multiple, widespread lesions may be treated systemically:

- Griseofulvin 500 mg once daily for 2 to 6 weeks in adults or griseofulvin 10 –15 mg/kg once daily for 2 to 6 weeks in children or
- Ketoconazole 200 mg once or twice daily or itraconazole 200 mg (2 tabs) once daily for 2 to 4 weeks in adults.
- When there is severe itching a mild steroid may be added.



TINEA CAPITIS

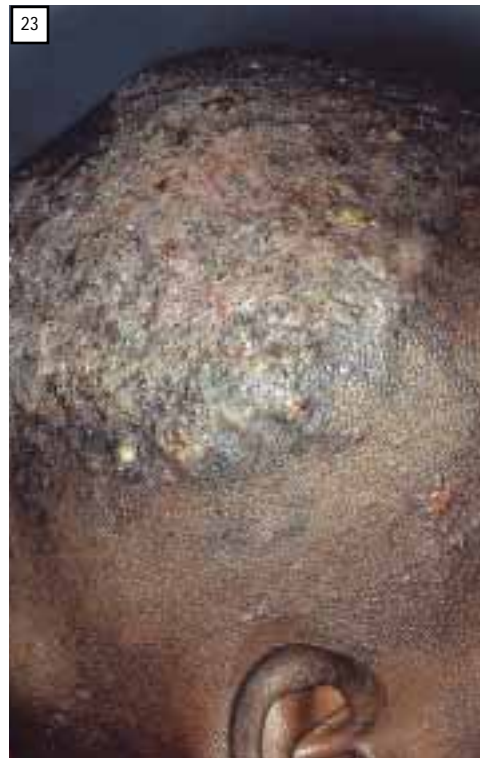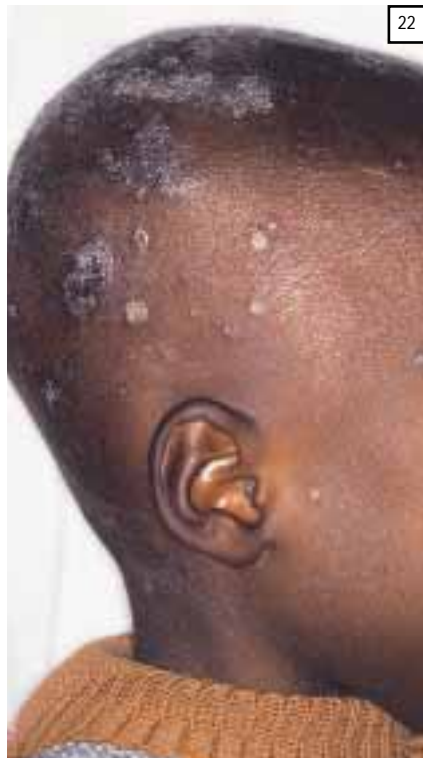Scalp ringworm is common in children. The fungus has grown into the hair follicle and will not be removed by topical treatment only. Severe pustular forms exist with follicular pustules and nodules and often massive purulent secretion. Lymph nodes in the neck swell and the patient may have a fever and headache. There may be bacterial superinfection. Systemic treatment is necessary to prevent scarring leading to permanent bald patches.

Management of tinea capitis

- Griseofulvin 500 mg once daily for 8-12 weeks in adults.
- Griseofulvin 10-15 mg/kg once daily for 8-12 weeks in children.
- Add Whitfield's ointment or miconazole twice daily topically for 4 weeks.
- Continue treatment after 12 weeks if the infection has not cleared completely.
- Alternative: Ketoconazole 200 mg twice daily or terbinafine 250 mg once daily or itraconazole 200 mg (2 tabs) once daily for 4-8 weeks in adults.
- Ask for signs of infection in siblings or friends of affected children or in pets or farm animals (bald patches, rash) and have these treated.
- In case of bacterial superinfection: antiseptics and / or antibiotics.

Fig. 22. Tinea capitis.

Fig. 23. Severe pustular tinea capitis.



TINEA UNGUIUM

Fungal infection of the nails is common, especially of the toenails in the elderly, where it generally does not require treatment. There may be a mixed fungal and yeast infection of toenails and /or fingernails.

Chronic paronychia is a chronic inflammation of the skin around the nail caused by mixed or yeast infections. It often occurs in people who frequently wet their hands such as domestic workers, cleaners, kitchen and laundry staff.

Management of tinea unguium

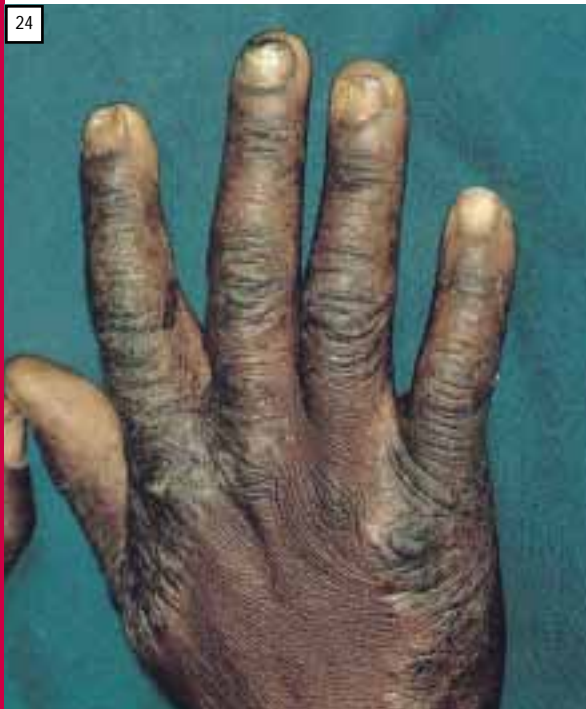Infection of the toenails:

- Usually this does not require any treatment. Thickened toenails may be softened using Whitfield's ointment or urea 10 to 40% ointment, and then thinned with a stone or a file.
- Systemic treatment of infected toenails is sometimes indicated e.g. when there is pain or when the patient is young: griseofulvin 500 mg once daily until the affected nails have grown out completely, this may take a year or longer. Recurrences are common, take this into account when deciding whether to use one of the more expensive drugs as listed below for infection of the fingernails.

Infection of the fingernails:

- Griseofulvin 500 mg once daily in adults or griseofulvin 10 mg/kg once daily in children. Continue treatment until the affected nails have grown out completely, this may take 4-9 months.

Fig. 24. Fungal infection of the hand and nails.



- If there is no improvement after 2-4 months, there may be a mixed infection (griseofulvin treats only fungal infections, not yeast infections) or resistance to griseofulvin. One of the systemic azoles should be given, e.g. ketoconazole 200 mg once daily until symptoms clear or itraconazole 200 mg once daily for 3 months or itraconazole 200 mg twice daily for 1 week per month during 3 months. Alternative: terbinafine 250 mg once daily for 6-16 weeks.

Chronic paronychia: Keep dry! Work conditions may need adapting. Bathe in betadine or potassium permanganate solution followed by application of an imidazole cream or GV paint twice daily. Massaging the nailfold with a mild steroid helps decrease swelling.

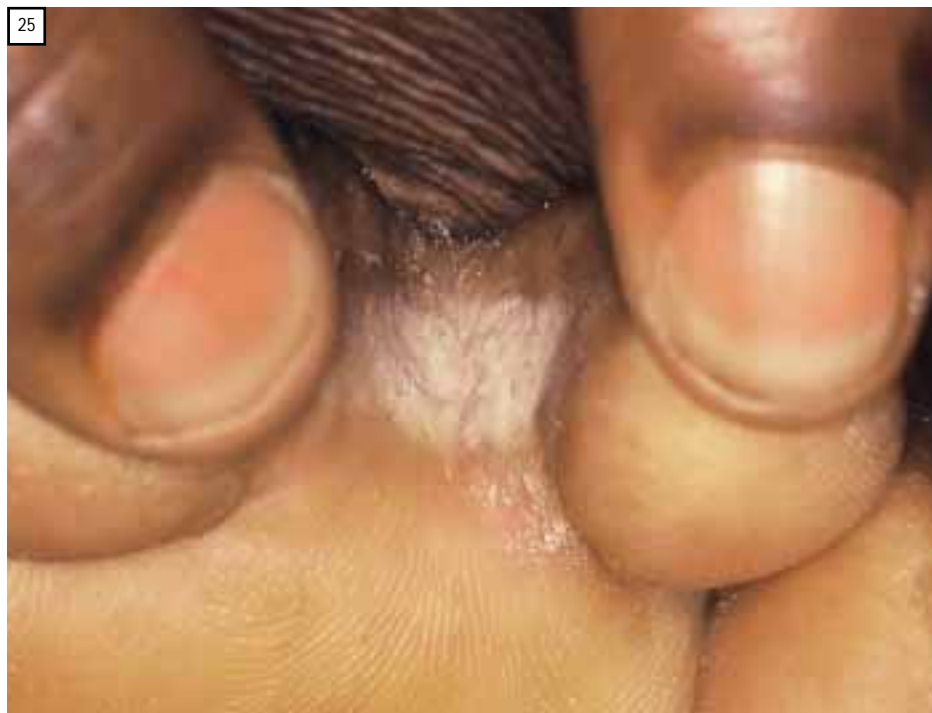ATHLETE'S FOOT

Itchy, often macerated whitish scaling lesions and inflammation of the skin in the interdigital spaces of the foot. Most common between the 4th and 5th toe. The condition is not always caused by fungi but can be caused by bacteria as well. For this reason oral antifungals are often ineffective. The condition is often seen in people wearing rubber boots or rubber / plastic sandals.

Management of Athlete's foot

- Keep the space in-between the toes DRY. This may be achieved by drying the skin thoroughly after washing, exposing to air, using betadine scrub, GV paint, wearing cotton socks and not wearing shoes that are too tight or hot. Changing socks daily will help prevent re-infection.
- An imidazole cream or Whitfield's ointment twice daily until a week after symptoms have cleared. This usually takes a minimum of 4 weeks.

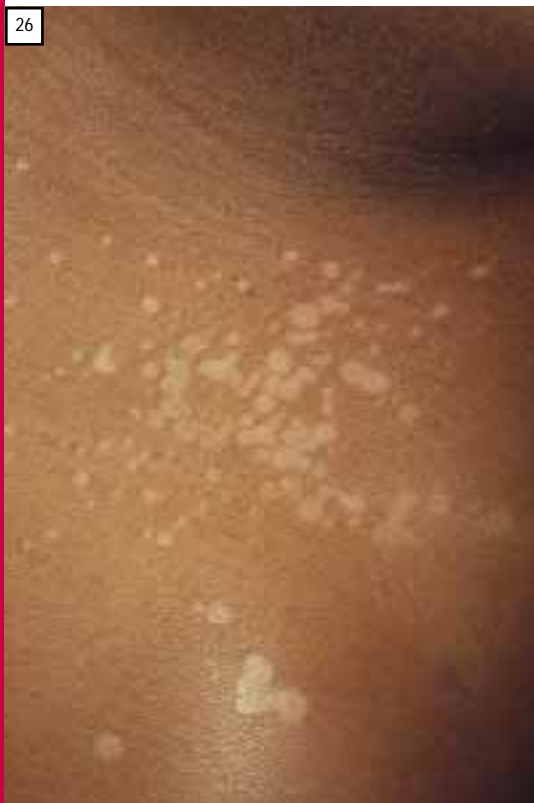Fig. 25. Typical white, macerated lesions of Athlete's foot.



25

27

Fig. 26. Fine scaling hypopigmented macules of pityriasis versicolor.



PITYRIASIS VERSICOLOR

This is a common, chronic, superficial fungal infection which is caused by the yeast pityrosporum. It is usually asymptomatic, causing only cosmetic complaints. Pityrosporum is a normal skin resident predominantly of seborrhoeic areas which becomes pathogenic under favourable circumstances: warmth and humidity, pregnancy, serious underlying disease or a genetic predisposition. On the scalp the infection presents as dandruff, from there the neck and upper trunk become infected. Recurrences are common, especially after inadequate treatment or re-infection.

Management of pityriasis versicolor

- Scrubbing the skin with a brush takes away a lot of the infected scales.
- Do not use vaseline, olive oil or palm oil.
- An imidazole cream twice daily on affected areas for 4 weeks. Add selenium sulphide shampoo or ketoconazole 2% shampoo (expensive) twice weekly for the scalp if lesions are widespread or if they are recurrences or
- Selenium sulphide suspension (e.g. Selsun shampoo) to affected areas overnight as a lotion or
- Selenium sulphide suspension (e.g. Selsun shampoo) to affected areas and the scalp for 10 minutes daily for 2-4 weeks or
- Sodiumthiosulphate 20% solution overnight for 2-4 weeks or
- Propylene glycol 50% in water applied twice daily to affected areas + scalp for 2-4 weeks or
- Salicylic acid 5% + sulphur 5% ointment overnight for 2-4 weeks or
- Salicylic acid 5% gel or lotion overnight for 2-4 weeks.
- Recurrences can be prevented by 2 weekly or once monthly preventive treatment with any of the above.
- In severe recurrent cases: ketoconazole 400 mg stat or ketoconazole 200 mg once daily for 5 days or itraconazole 200 mg once daily for 1 week.
- Treatment is complete when all the scales have disappeared. You can test this by stretching affected skin between two fingers; if scales appear the infection is still active. After treatment hypopigmentation may persist for some time and will re-pigment faster when exposed to the sun.

CANDIDIASIS

Candida is a resident yeast of the mucous membranes. It becomes pathogenic under favourable host conditions. These are:

- When host immunity is decreased such as in HIV-infected and cancer patients or by systemic steroids, cytotoxic drugs, and radiotherapy.
- Pregnancy and contraceptive pill use.
- Warmth and moisture (babies' nappy area, groins, under breasts, between toes).
- Use of broad-spectrum antibiotics which kill resident non-pathogenic bacteria.
- Diabetes mellitus.

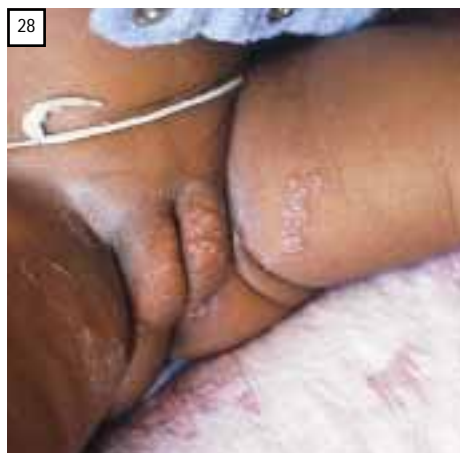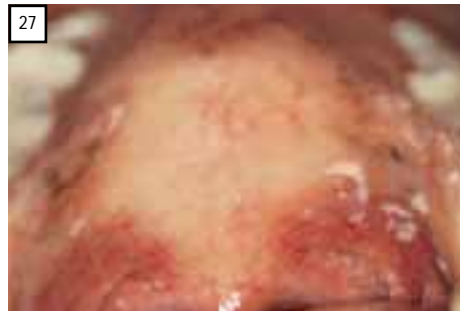Candidiasis or thrush presents on the skin as red macules often with small pustules on their periphery which break down as the lesion spreads outwards. On the oral and vulvo-vaginal mucosa redness, superficial erosions and white adherent plaques may be seen. These can be itchy and painful. When oral lesions extend to the throat and oesophagus they can cause anorexia. Infection of lips / corners of the mouth also occurs. Severe mucosal candidiasis is seen often in HIV infection.

Fig. 27. Oral candidiasis in a HIV infected patient.

Fig. 28. Nappy rash caused by candidiasis.

Management of candidiasis

- Treat large oozing lesions with potassium permanganate dressings or baths for 10 minutes twice daily. Keep lesional skin dry.
- Paint mucosal or smaller wet lesions with Gentian Violet solution once daily until healed. Application on normal skin or on large areas is very unsightly.
- Nystatin ointment or cream twice daily for skin, nystatin oral suspension (1 ml) swirled around mouth four times daily until two days after clinical cure for oral candidiasis, nystatin pessaries nightly for 2 weeks for vaginal candidiasis.
- An imidazole cream twice daily for skin infections, miconazole oral gel 5 ml 4 times daily for 1 week for oral thrush, imidazole pessaries 1-3 nights for vaginal thrush.
- Nappy rash: apply an imidazole cream and cover with zinc oxide cream or ointment.
- In severe cases e.g. oesophageal thrush ketoconazole 200 mg twice daily for 1-2 weeks or itraconazole 100 mg once daily for 2 weeks or fluconazole 50-200 mg once daily for 1-2 weeks.
- Treatment duration may need to be extended in immunocompromised patients.
- **Griseofulvin is not an effective treatment for candida infections.**



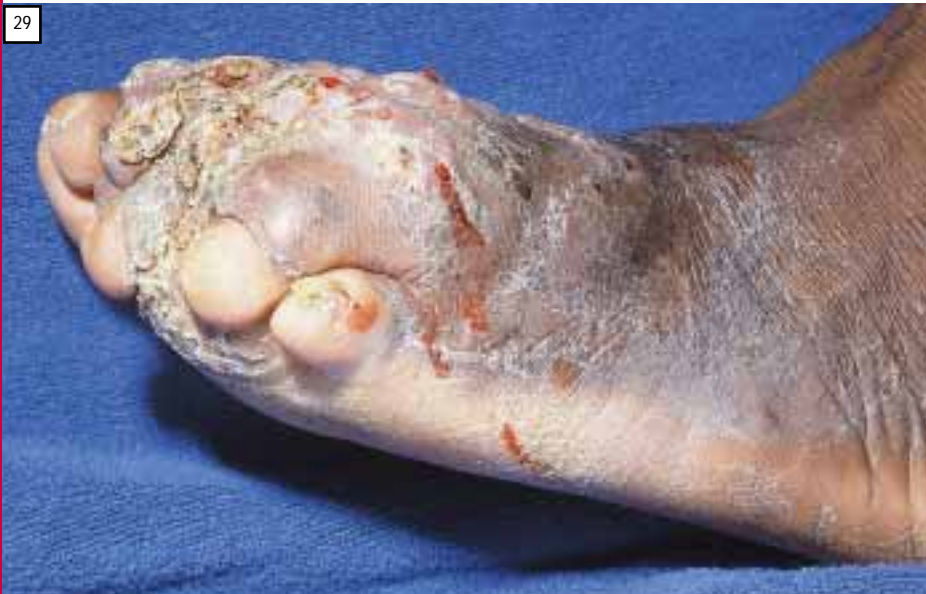MYCETOMA / MADURA FOOT

This is a chronic localised infection which can be caused by various species of fungi (eumycetoma) and bacteria, actinomycetes and nocardia (actinomycetoma). These micro-organisms live in the soil and enter the skin usually after a penetrating injury. The most common localisation is therefore the foot or lower leg in barefoot persons but lesions may appear anywhere on the body. A painless subcutaneous nodule or induration is followed by more nodules which may discharge pus with grains (small hard pinhead sized particles) through fistules, form abscesses and ulcers and spread to underlying bones and joints. The colour and hardness of the grain may help in deciding on the causative agent.

Management of mycetoma

- Smaller lesions which can be surgically removed without causing disability should be radically excised.
- Decide on fungal or bacterial origin before installing drug therapy. Direct microscopy (in 20% potassium hydroxide) of pus containing grains may help: after the grains are crushed eumycetomas show hyphae, actinomycetomas small slender filaments. Culture allows final identification. When in doubt, refer.
- Eumycetoma (caused by fungi) are virtually untreatable: antifungals e.g. itraconazole, fluconazole, ketaconazole, miconazole, and griseofulvin have a success rate of less than 30%. Actinomycetoma (caused by bacteria): dapsone or cotrimoxazole combined with streptomycin. Streptomycin can be substituted by amikacin, sulfonamides by rifampicin.
- Drug therapy often fails. Radical surgery / amputation is then the only option.

Fig.29 A 45 year old man with slowly progressive deformity since 13 years.



BACTERIAL INFECTIONS

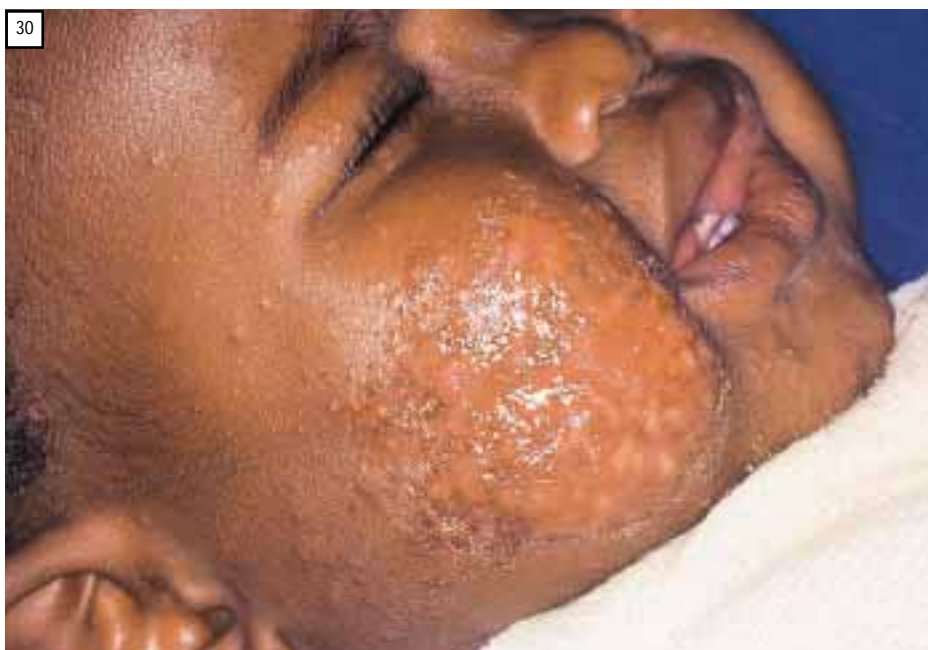IMPETIGO

This is a very common bacterial skin infection, usually caused by staphylococci and/or streptococci. It presents with superficial pustules or blisters which become oozing erosions with yellow crusts as it spreads. Impetigo is contagious and may even spread through the shared use of jars of vaseline. Vaseline application makes it worse.

Management of impetigo

- Dress or bathe affected areas with potassium permanganate, GV paint, betadine solution or saline or wash with betadine shampoo.
- Prevent spread to others: do not share towels or ointments, change clothes, towels and sheets frequently.
- Do not use vaseline, use aqueous cream instead.
- If severe give cloxacillin 250-500 mg 4 times daily for 7-10 days in adults, 50-100 mg/kg/24 hours divided in 4 doses for 7-10 days in children or erythromycin 250-500 mg 4 times daily for 7-10 days in adults, 25-50 mg/kg/24 hours divided in 4 doses for 7-10 days in children.

Fig. 30. A common localisation for impetigo is the face, as shown in this 15 month old boy.



FOLLICULITIS

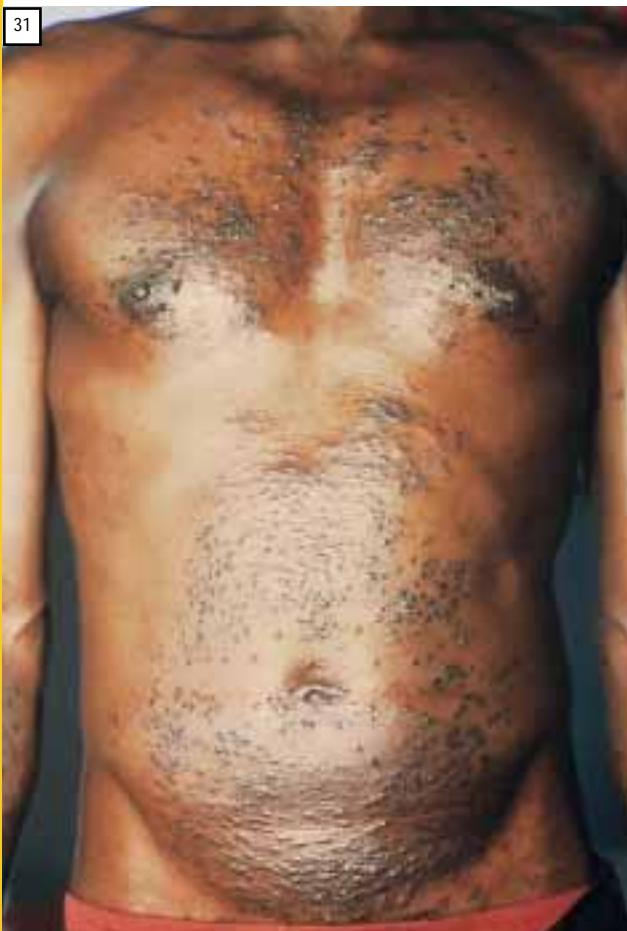Folliculitis is an inflammation of hair follicles, usually caused by infection with bacteria, specifically staphylococci. Common localisations are the face, the trunk and the buttocks, but any skin area with hair follicles may be affected. In HIV-infected patients gram negative bacteria may be implicated or yeast infections, particularly pityrosporon.

Folliculitis may be mild and superficial or severe and deep, it may become widespread and very refractive to treatment in immunosuppressed patients.

Management of folliculitis

Fig. 31. Widespread bacterial folliculitis in a 26 year old HIV infected patient.

- Stop vaseline!
- For itchiness use calamine or phenol-zinc lotion as often as necessary.
- Mild forms: Dress or bathe with potassium permanganate solution or betadine or chlorhexidine.



- Severe bacterial forms: oral cloxacillin, erythromycin, doxycycline or tetracycline for 7-10 days.
- Pityrosporon folliculitis: an imidazole cream twice daily is usually effective.
- If severe add ketoconazole 200 mg once daily for 1 to 3 weeks.
- Immunosuppressed patients may need prolonged treatment.

FOLLICULITIS KELOIDALIS NUCHAE

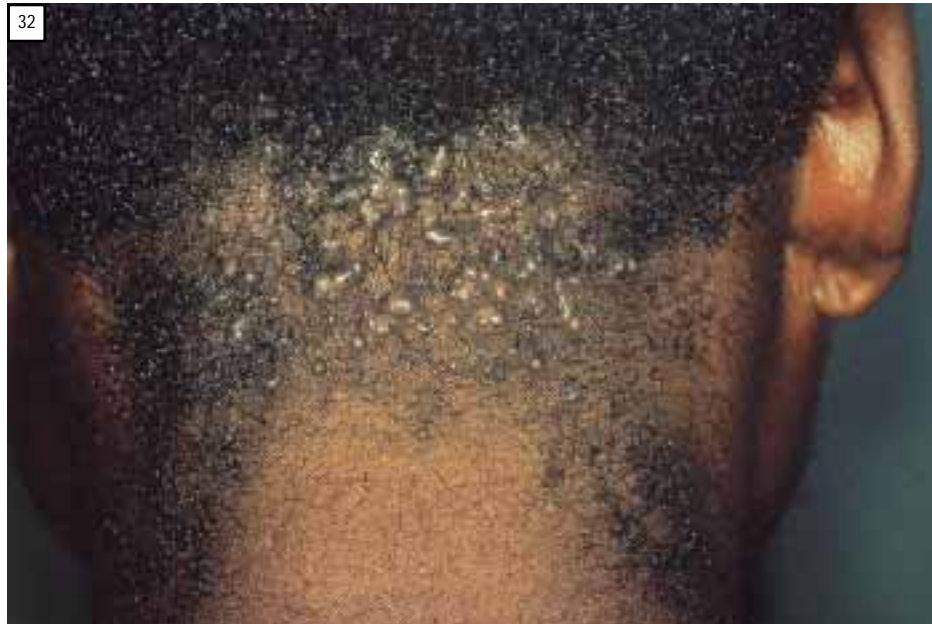This literally means "keloid-forming folliculitis of the neck". It may start after the neck is shaved. It is a common condition in African males. A deep folliculitis, usually caused by staphylococci progresses to a chronic fibrosing folliculitis and peri-folliculitis. Keloidal scars are produced in the deeper cutaneous tissue. New papules and pustules occur at the rims of the keloid. The course is very chronic.

Management of folliculitis keloidalis nuchae

Treatment is difficult.

- In active, pustular stages use doxycycline 100 mg twice daily for 2 weeks up to one month followed by doxycycline 100 mg once daily for 2 weeks up to one month or longer or other long-term antibiotics according to sensitivity tests.
- Excision of scars, with or without skin grafting. Recurrence of keloid is possible but seems to occur less often when skin grafts are not performed and the wound is allowed to heal per secundam, leaving an atrophic scar. Keloids may respond to injections of steroid suspension such as triamcinolone acetonide, 10 mg diluted 1:3 to 1:5 with a local anaesthetic, every 2 to 4 weeks for several months.
- A strong steroid e.g. betamethasone ointment twice daily on lesions.
- Cryosurgery or lasersurgery may be helpful.

Fig. 32. Folliculitis keloidalis nuchae.



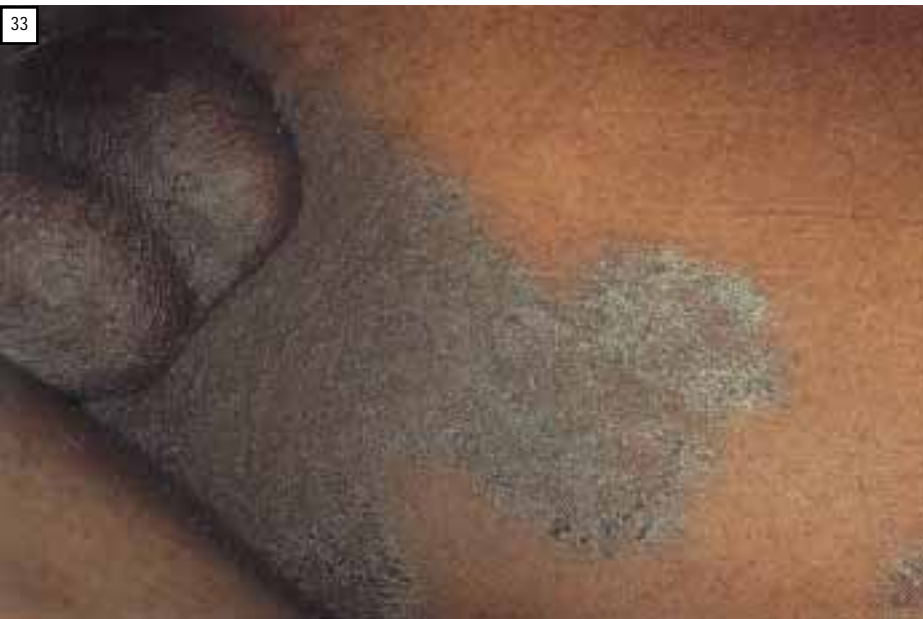ERYTHRASMA

Erythrasma is caused by *Corynebacterium minutissimum*. It presents as dry, smooth to slightly creased or scaly, clearly demarcated reddish-brown plaques, in the groins, armpits or under the breasts. It may easily be mistaken for a fungal infection but direct microscopy with KOH is negative for fungal elements. Lesions show red fluorescence when viewed under Wood's light.

Management of erythrasma

- An imidazole cream twice daily for 4 weeks. If not effective or recurrent infection:
- Erythromycin 250 mg 4 times daily for 2 weeks or
- Erythromycin 2% lotion twice daily for 4 weeks.

Fig. 33. Erythrasma in the groin of a 30 year old man.



SECONDARY SYPHILIS

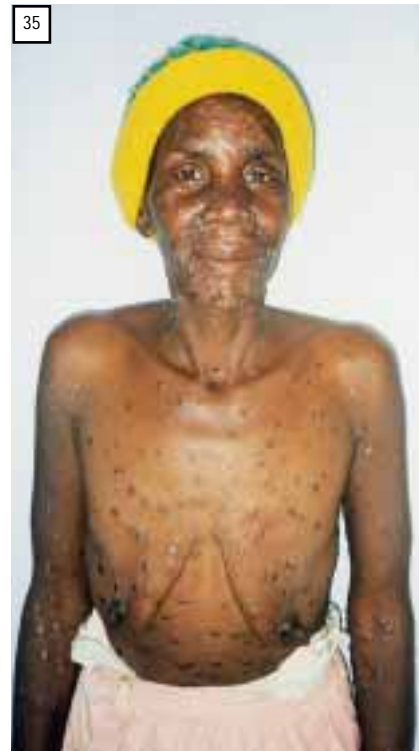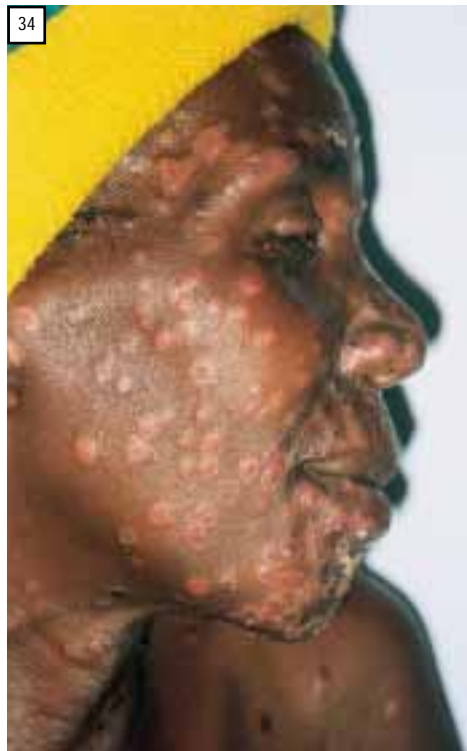Syphilis is a sexually transmitted infection caused by the bacterium *Treponema pallidum*. Ask for a history of a primary ulcer on the genital area or elsewhere (lips) 1 to 2 months before the development of the rash. Secondary syphilis presents with a generalised symmetric rash which can mimic almost any other skin condition. A helpful diagnostic symptom is the fact that secondary syphilis is not itchy. Also palms and soles are usually affected as well as the face.

A positive RPR or VDRL screenings test is very likely based on syphilis if confirmed by a positive TPHA (specific for Treponemal antibodies). In yaws endemic areas positivity may however be caused by contact with yaws. Results may be discordant in concomitant HIV-infection.

Management of secondary syphilis

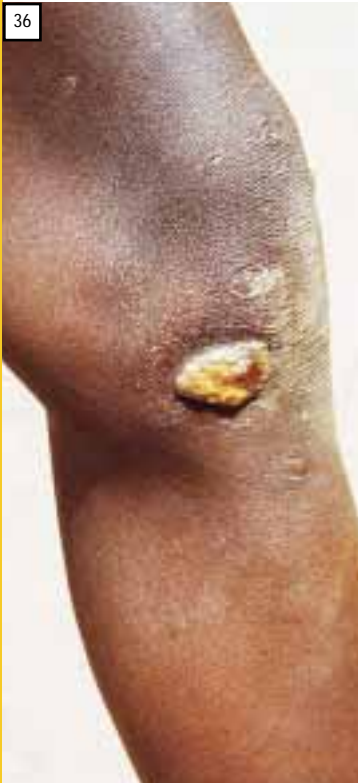- Benzathine penicillin 2,4 million units per IM injection weekly for 3 weeks.
- In case of penicillin-allergy: Erythromycin 500 mg 4 times daily for 2 weeks.
- Treat all partners!

Fig. 34 & 35. Widespread papular and scaling lesions of secondary syphilis.



YAWS

36



Yaws, like syphilis, is caused by a treponema. The primary lesion of yaws (mother yaws) is a wet, easily bleeding, raspberry-like papule or nodule, which disappears after a few weeks leaving an atrophic scar. When the primary infection is not treated secondary lesions (daughter yaws) may appear as generalised nodules, ulcerations and condylomata.

Note: Reactivity to VDRL and TPHA is the same as for syphilis.

Management of yaws

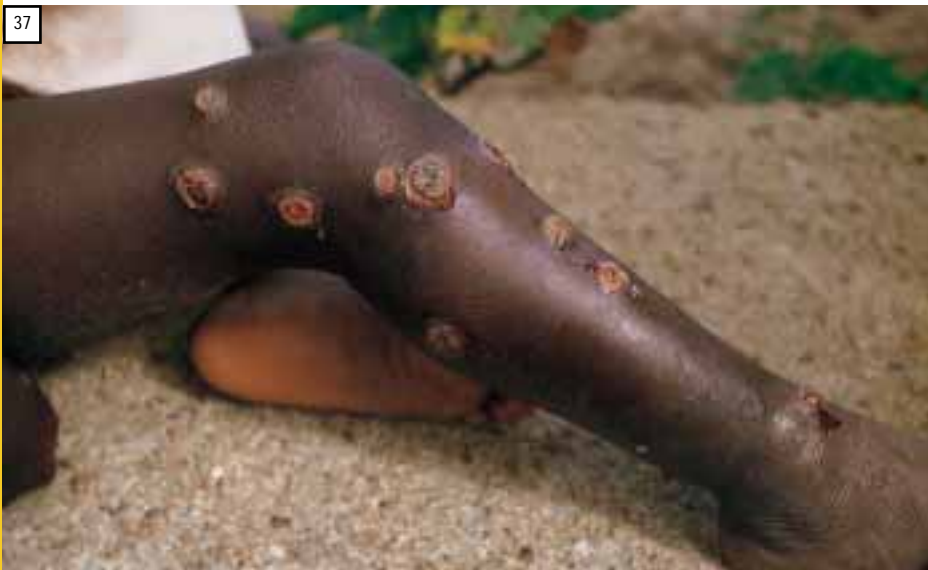- Benzathine penicillin 2,4 million units per IM injection, repeat after two weeks. For children benzathine penicillin 1,2 million units per IM injection, repeat after two weeks.
- In case of penicillin-allergy: Erythromycin 500 mg 4 times daily for 2 weeks.

36

Fig. 36. Mother yaws in an 11 year old boy.

Fig. 37. Daughter yaws in a child (Courtesy Dr. D.L. Leiker).

37



LEPROSY

Leprosy is an infectious disease caused by *Mycobacterium leprae*. It is an airborne infection (like tuberculosis) which affects skin and nerves. Leprosy often presents with hypopigmented or slightly erythematous patches on the skin with loss of sensation, and enlarged nerves. Loss of sensation is tested with a whisk of cotton wool. The skin is **touched, not stroked** with it. The patient is asked to close his or her eyes and to point at the spot which has been touched. Misreference and certainly "not felt" are diagnostic for leprosy. Nerves which should be checked for enlargement are the great auricular, ulnar and radiocutaneous nerves. Enlarged nerves are pathognomonic for leprosy. When there are infiltrated patches or papules and nodules skin smears may be positive for *M. leprae*. Unlucky patients, those who are diagnosed at later stages with nerve damage may show visible deformities such as facial palsy (an eye cannot close, lagophthalmos, and that side of the face sags) and loss of sensation of hands or feet which show dry skin with or without ulcers. Sometimes fingers are bent or even lost, the grip is gone, the feet drop.

For practical purposes two types of leprosy are recognised:

1. **Paucibacillary (PB) leprosy or tuberculoid leprosy.** These patients do not have bacilli in their skin smears and have 5 or less skin lesions (in some control programs 3). They are not infectious to others.
2. **Multibacillary (MB) leprosy or lepromatous leprosy.** These patients have bacilli in their skin smear and more than 5 (3) lesions which may be flat or raised patches, papules or nodules. Untreated lepromatous leprosy patients discharge bacilli from their nose and are therefore infectious to others.

Management of uncomplicated leprosy

1. **PB-leprosy** - Rifampicine 600 mg once a month under supervision plus dapsone (DDS) 100 mg daily for 6 months unsupervised.
 - When compliance is a problem, a 6 months dose taken within 9 months is acceptable.
 - Always check for complications!
2. **MB-leprosy** - Rifampicine 600 mg and clofazimine (Lampren) 300 mg once a month under supervision plus dapsone (DDS) 100 mg daily plus clofazimine 50 mg daily unsupervised for 12 or 24 months depending on the policy of the local leprosy control programme.
 - When compliance is a problem, a full treatment taken within 18 (for the 12 months programme) resp. 36 months (for the 24 months programme) is acceptable.
 - Always check for complications!

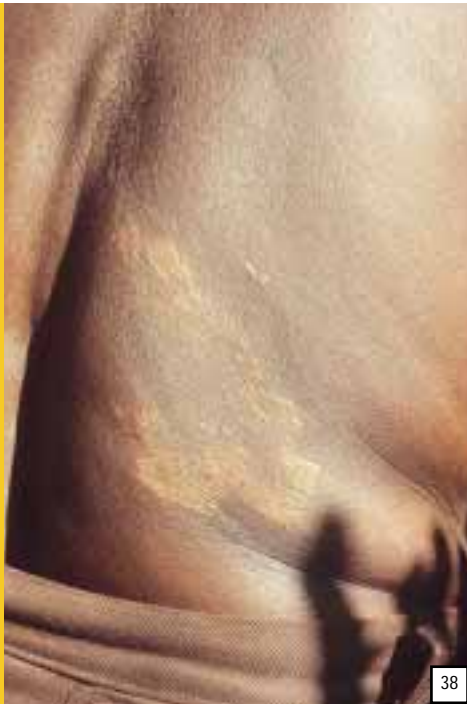

Fig. 38. PB leprosy, BT patient, the lesion has central healing, streaming edges and satellites.

Fig. 39. BT patient with more than 5 lesions has to receive MB treatment.

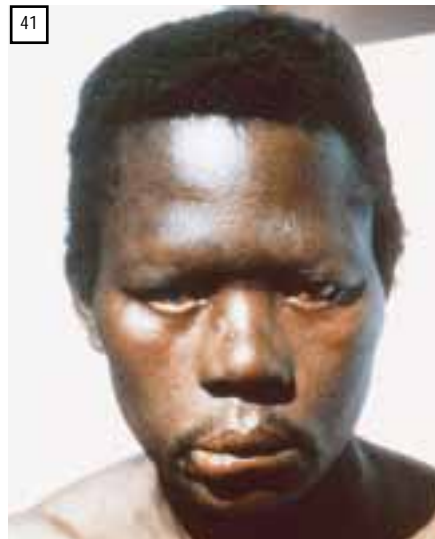
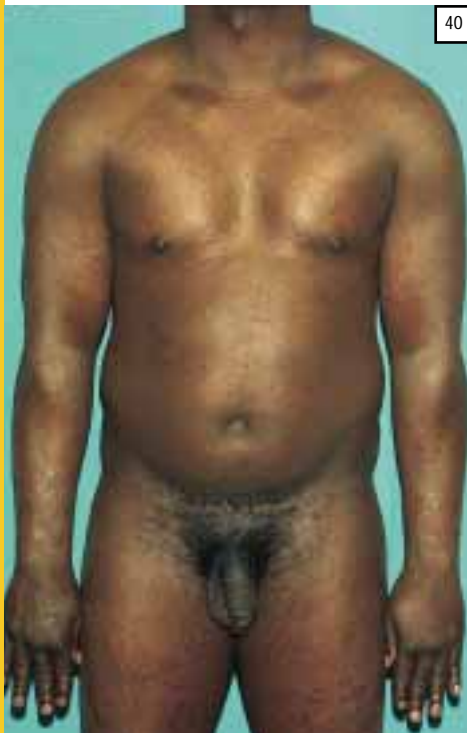
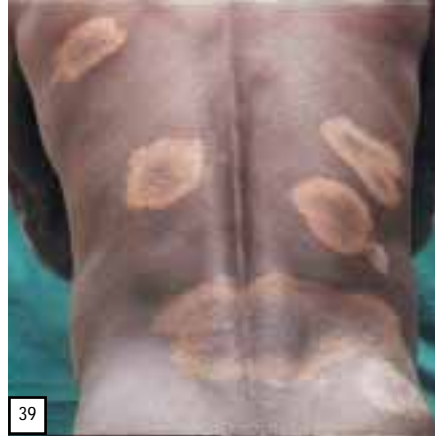Fig. 40. Subpolar LL patient (MB) with small papules and diffuse infiltration of the whole skin.

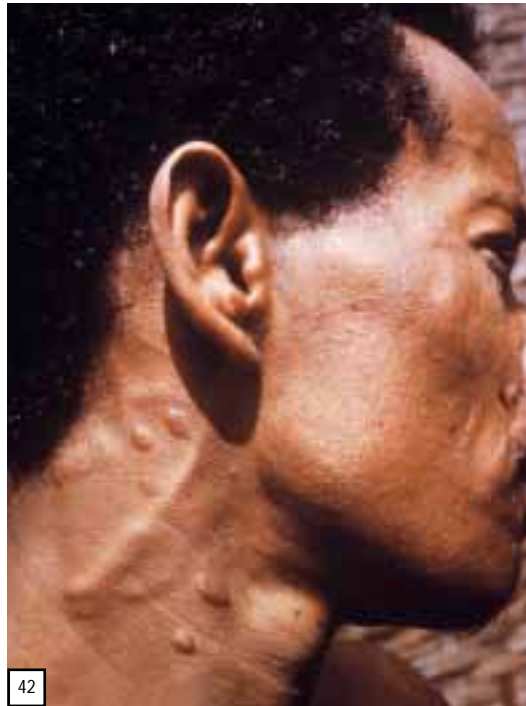Fig. 41. Bilateral lagophthalmos. Loss of facial expression may lead to social isolation. Eyes are in danger of exposure and drying out, eventually leading to blindness.

Fig. 42. Enlarged great auricular nerve in a BL patient.

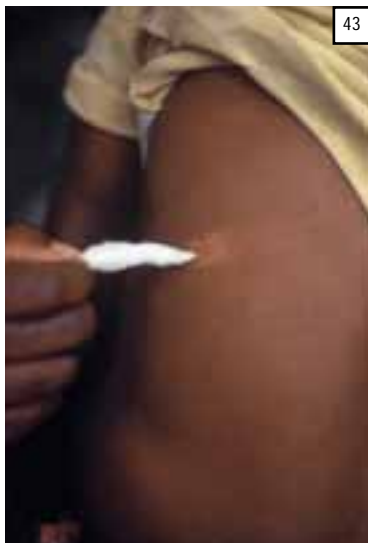Fig. 43. Test for loss of sensation (light touch).

Fig. 44. Palpating the radiocutaneous nerve. No other clinical or laboratory test has the same high sensitivity and specificity.

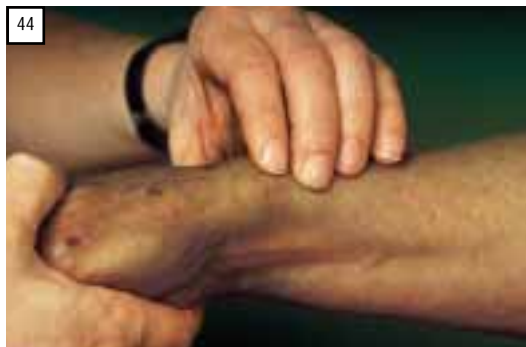Fig. 45. The ulnar nerve is felt just behind and above the medial epicondyle.



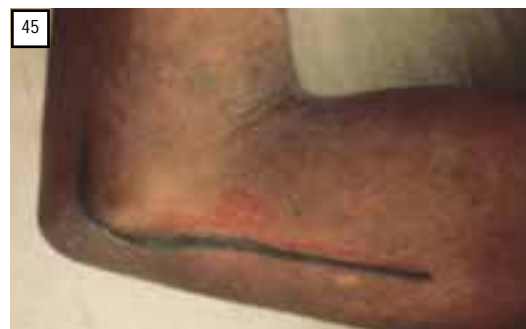42



43



44



45

LEPROSY COMPLICATIONS

Complications of leprosy are the reactions which cause nerve damage and the sequelae of this nerve damage; loss of sensation and loss of muscle strength, with **ulceration and deformity** as consequence.

Reactions

Two types of reactions are recognised, the **Reversal Reaction (RR)** and **Erythema Nodosum Leprosum (ENL)**. Symptoms of a **RR** can be increased swelling with erythema of previously existing lesions, the appearance of new lesions, enlargement and tenderness of nerves which may show increased function loss, and sometimes acral edema. The **ENL**-type reaction, in its characteristic form, shows a sudden appearance of tender erythematous nodules. The patient often feels ill. Nerves may be tender. Sometimes arthritis occurs, or lymphadenitis, orchitis may be encountered as well as iridocyclitis and glaucoma which can lead to blindness. Organs may be involved separately or simultaneously.

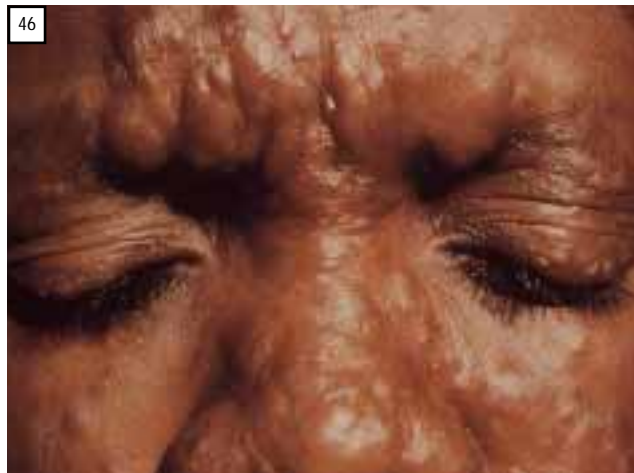Ulceration and deformity

Ulceration is secondary to the loss of protective sensation. The patient feels no heat, pressure or pain. Skin trauma is not felt and easily neglected. The risk of damage increases when there is loss of muscle strength (claw hand, drop foot). Ulceration may lead to cellulitis or deep infections, osteomyelitis and consequently to loss of digits.

When there is lagophthalmos, there is usually also anaesthesia of the eye and consequently there is no blink. The eye is at risk of drying out and ulceration with blindness may be the final result.

Deformity is the result of loss of muscle strength and ulceration followed by osteomyelitis and shortening of digits, mostly accompanied by stiffness and contractures.

Fig. 46. ENL, tender papules and nodules, the patient is ill.



Management of leprosy complications

Reversal Reaction

- Treat with steroids, prednisolone 30-40 mg daily to start with, taper down to 20 mg daily in 2 months. This daily dose should be maintained for some months (**PB** 1-2 months, **MB** 2-4 months or sometimes longer according to clinical assessments). Thereafter the dosage can be further tapered down to zero in 2 months.
- Make sure that treatment is continued for a sufficient time!
- Check for intercurrent infections (TB, strongyloides).

Erythema Nodosum Leprosum

- Treat mild **ENL**, i.e. without nerve, eye or genital involvement with acetyl salicylicum 1000 mg three times daily for 1-2 weeks.
- Treat severe **ENL**, i.e. a sick patient with nerve, eye, or genital involvement, with steroids. Start prednisolone at 80 - 100 mg daily for 2 days and taper off in 2 weeks. You may need to repeat this.
- Check for intercurrent infections!
- TB may complicate **ENL**!
- In countries where thalidomide is available 100 - 400 mg once daily may be given for 1-2 weeks.
- Do not give thalidomide to pregnant women or women who do not have 100% safe contraception!!! Thalidomide causes severe deformities in the unborn child!

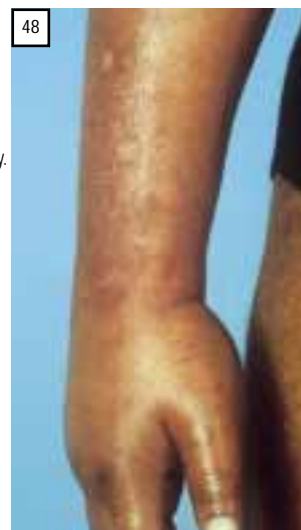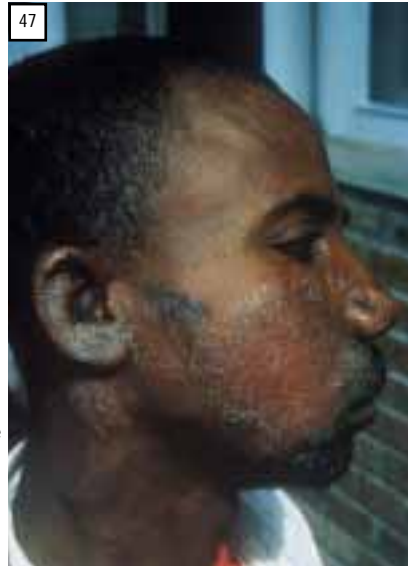Ulceration and deformity

- Wounds should be cleaned and covered. Superficial wounds can be covered with zinc adhesive sticking plaster which should be renewed after 1-2 weeks. Hyperkeratotic rims should be trimmed.
- Do not use bulky bandages on the feet. These give local pressure when walked upon and the wound will not heal!
- Use antibiotics only when there is cellulitis.
- Further deformity should be prevented by daily care by the patient: daily inspection, soaking and oiling, trimming of cracks and softening of the skin by applying 15% salicylic acid in vaseline. Digits should be stretched actively and passively to prevent further contractures. For the unblinking eye protective glasses during the day and a soft cover with vaseline during the night is necessary. The patient has to learn to consciously blink regularly in order to moisten the eye.

Warning: Complications, reactions and further deformities may occur for years after completion of antibacterial WHO treatment. Patients should be informed about this and proper treatment should be started immediately.

Fig. 47. RR, edematous patch on the face.

Fig. 48. RR, edematous extremity.



BURULI ULCER

Buruli ulcer caused by *Mycobacterium ulcerans* is the third most common mycobacterial disease after tuberculosis and leprosy in non-HIV-infected patients. The disease first described in Uganda is now endemic in swampy areas in West Africa, but may be seen elsewhere. It is transmitted by mild injuries, the bacillus probably residing in muddy water. Patients are usually children.

Two different forms of the disease are seen.

1. A slow form which develops in 2-3 months. A hard indurated plaque with surrounding severely constricting oedema forms and compromises the circulation in the affected limb, leading to ischaemia and necrosis.

2. A fast form which develops in 2-4 weeks. A painless papule or nodule forms and ulcerates, extending rapidly. The typical ulcer has undermined edges. The patient is not sick and there is no oedema.

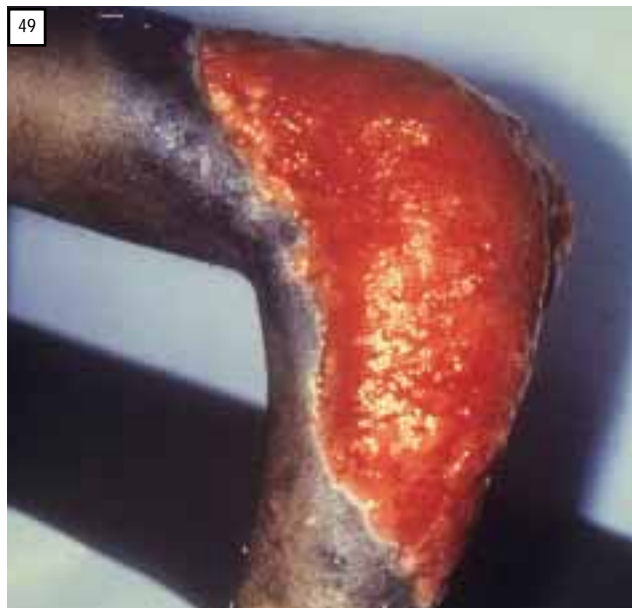Very extensive ulceration and secondary infection may occur and lead to sepsis, tetanus and death. Besides the skin and subcutis deeper structures may be involved. Particularly osteomyelitis may be seen.

The lesions may heal spontaneously with severe scarring and contractures.

Management of Buruli ulcer

- Prevent secondary infections.
- There is only one effective treatment: Surgery as soon as possible, wide excision with skin grafting. There is no effective medical treatment!

Fig.49. Buruli ulcer on the arm. (Courtesy Dr. P.L.A. Niemel).



NOMA / CANCRUM ORIS

Noma is a form of infectious gangrene of the mouth. It is thought to be caused by fusiform bacteria. It usually affects children 2 to 7 years of age. Predisposed are malnourished children, especially those with protein deficiency, hypovitaminosis and recurrent acute infections. The disease generally starts as peridontitis, then ulcerative stomatitis, always on one side of the mouth. It then progresses to gangrene with extensive sloughing of adjacent tissue and necrosis of bone. The area is foul-smelling and very painful. Untreated patients may die or survive with a severe handicap.

Management of noma

- Start treatment as soon as the diagnosis is suspected!
- When only peridontitis is present, oral hygiene (e.g. chlorhexidine mouthwash) may prevent development of noma.
- Massive doses of penicillin or in case of penicillin-allergy broad-spectrum antibiotics for at least 2 weeks. Treat longer if necessary, until all signs of activity have ceased.
- Intensive high-protein diet should be given, orally and parenterally, as well as vitamin supplements.
- Early treatment may lead to great improvement of tissue defects. Remaining deformities may need surgical repair.

50

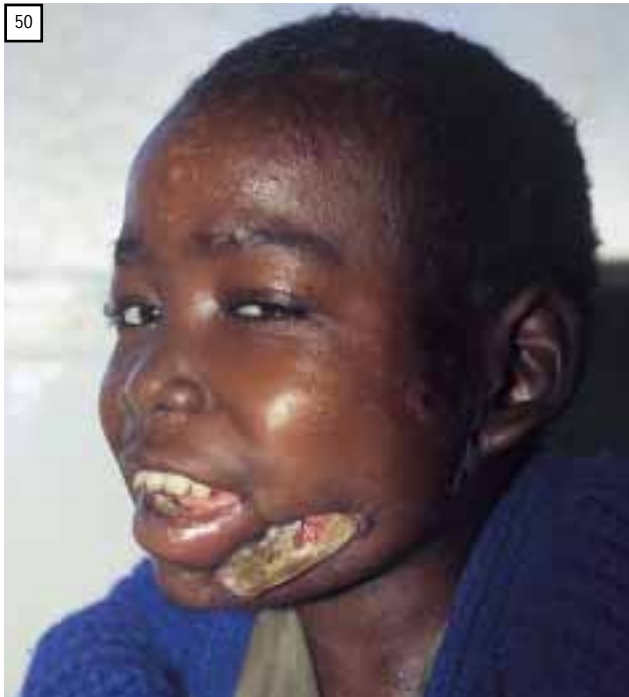

Fig. 50. Noma in a 7 year old HIV positive boy.

VIRAL INFECTIONS

HIV INFECTION

HIV related skin diseases occur throughout the course of HIV infection in 90% of the infected persons. During seroconversion an exanthema may occur together with fever and constitutional symptoms. After seroconversion there will be a period of symptomless HIV infection. Herpes zoster is an early clinical sign which in young age-groups (under 50 years) is very strongly related to HIV infection. Severe and chronic seborrheic eczema may also be an early manifestation. Other cutaneous manifestations of HIV infection are molluscum contagiosum, papular pruritic eruption, severe herpes simplex or human papilloma infection, severe bacterial, mycobacterial and fungal infections and Kaposi's sarcoma. Infestations such as scabies are more severe. Adverse drug reactions are very common in HIV infection.

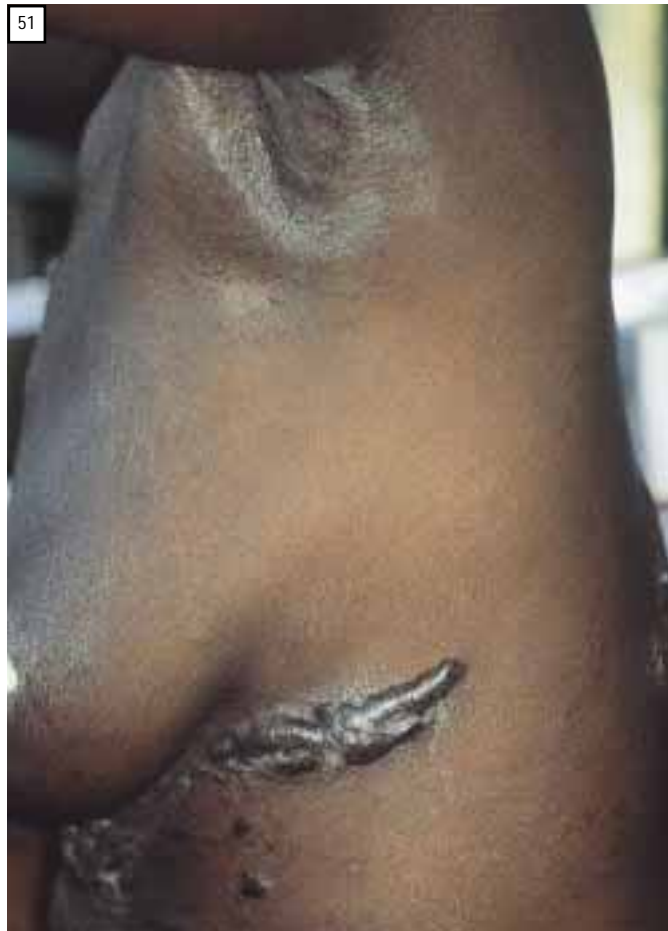

Fig. 51. A HIV positive patient with seborrheic eczema of the armpit and a scar from a previous herpes zoster infection.

PITYRIASIS ROSEA

This is probably an immune reaction to a viral infection ("a flu of the skin"). There is sometimes a flu-like prodromal episode. Skin symptoms start with a large "herald patch" or "mother patch" on trunk or arms, which many patients can point out to you. Soon after, many smaller oval lesions which scale at their borders appear on the trunk and (upper) arms. Typically the lesions take on the direction of the skin lines forming a "Christmas tree pattern" on the back. They generally cause no pain or itch and disappear spontaneously within 2 months.

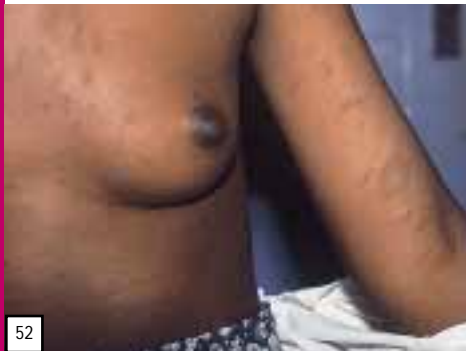It is difficult to differentiate between pityriasis rosea and secondary syphilis, therefore serological tests for syphilis should always be performed.

Management of pityriasis rosea

No causal treatment is available. It is essential to explain the self-limiting nature of the disease to the patient.

- Calamine lotion or rarely antihistamines for itch.
- Aqueous cream, emulsifying ointment or urea 10% cream for dry skin and scaling.

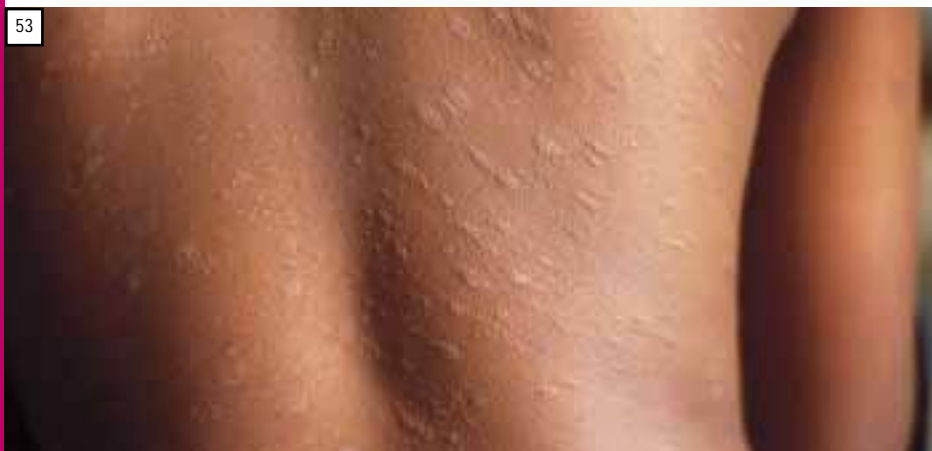46



52

Fig. 52. Pityriasis rosea with herald patch on the arm.

Fig. 53. "Christmas tree" pattern of pityriasis rosea on the back.



53

CHICKENPOX

Chickenpox or varicella is a primary infection with the varicella-zoster virus. It is a common, very contagious infection in children. After a mild prodrome with sometimes fever and malaise the exanthema appears suddenly. Red macules, papules and shortly thereafter vesicles, pustules and crusts develop on the trunk, scalp and mucous membranes, less so on extremities and face. New crops of lesions appear over the next few days and lesions in all stages of development are seen at the same time. Itch is the main complaint. Scratching is the main cause of bacterial superinfection and may cause scarring. Crusts fall off in 1-3 weeks. Signs, symptoms and complications become more severe with age. In adults, fever and constitutional symptoms practically always precede the exanthem. Possible complications include nephritis, myositis, otitis and meningo-encephalitis.

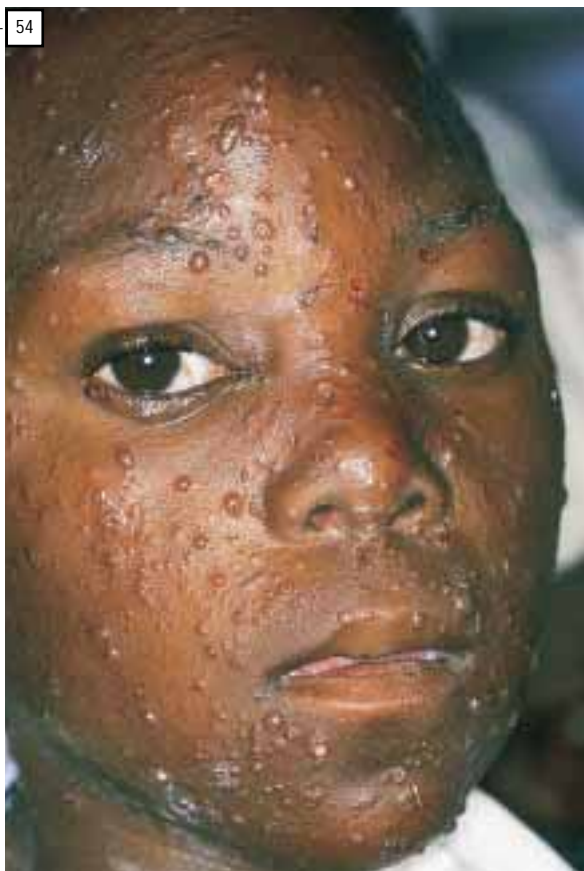In immunocompromised persons chickenpox becomes a life-threatening disease.

Fig. 54. Chickenpox in a 10 year old boy.

Management of chickenpox

- Calamine lotion or phenol-zinc lotion as necessary for itch and drying in.
- Antihistamines for extreme itch. Give rest. Isolate patient if possible.
- Use betadine scrub and chlorhexidine 1% mouthwash if necessary.
- In severe superinfection a systemic antibiotic e.g. cloxacillin or erythromycin.
- Immunocompromised patients: if available acyclovir 200-800 mg 5 times daily for 5-10 days.

54



HERPES ZOSTER

Herpes zoster or shingles is the recrudescence of a latent varicella-zoster infection in the partially immune host. After a short period of itch, tenderness or pain along one or occasionally several dermatomes on one side of the body papules and plaques appear which quickly change into blisters. Most often thoracic and cervical dermatomes are affected. If the ophthalmic branch of the trigeminal nerve is involved a keratoconjunctivitis may develop and can lead to blindness. After 1-2 weeks crusts begin to fall off. Over 10% of patients develop post-herpetic neuralgia, a persistent burning sensation or pain in the area which has healed. This can last from a few months to many years.

Herpes zoster may appear in otherwise healthy persons, especially the elderly, but is much more common in people with underlying malignancies and HIV-infection. It is an early indicator of HIV-infection in young people. Delayed healing, dissemination and complications are more common and severe in immunocompromised persons.

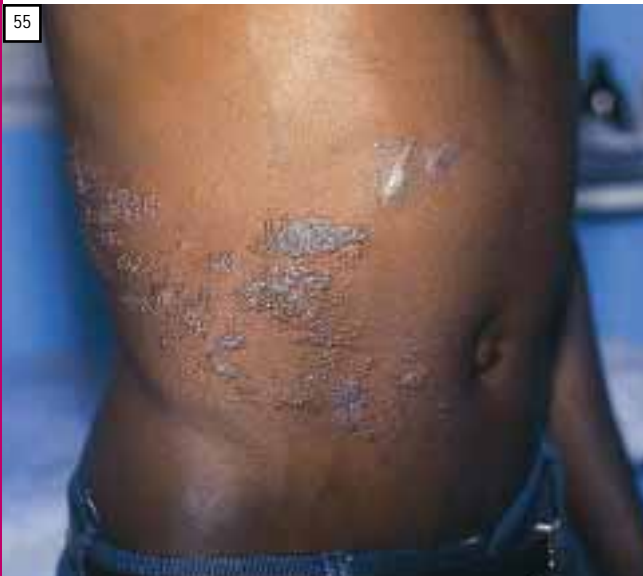Management of herpes zoster

- Analgesia with NSAID's, e.g. indomethacin 25 mg 3 times daily or ibuprofen 400 mg 3 times daily.
- Antibiotics for superinfection, as this is the main cause of keloidal scarring.
- Use betadine scrub/shampoo as a soap, do not use vaseline.
- Calamine or phenol-zinc lotion for vesicular stages.
- If the eye is involved refer to an eye-clinic
- In immune compromised persons if available acyclovir 800 mg 5 times daily for 1 week. Start acyclovir or other available antiviral (e.g. valaciclovir) early in the course of the disease.

Postherpetic neuralgia:

- 3 to 5% phenol in cream or ointment 2-6 times daily.
 - Amitriptyline 75 mg nightly or
 - Carbamazepine 600-800 mg once daily or
 - Amitriptyline 75 mg nightly + thioridazine 25 mg 4 times daily.
- Try any of these for at least 4-6 weeks before deciding whether they are effective.

Fig. 55. Herpes Zoster in more than one dermatome in a 30 year old HIV positive man.



55

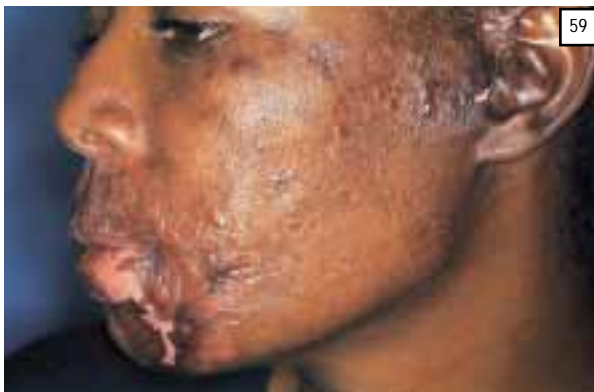
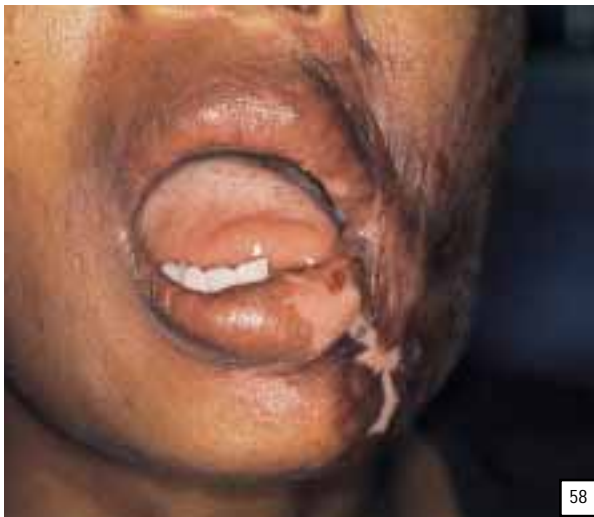
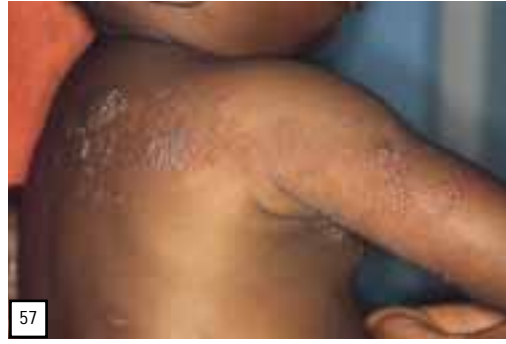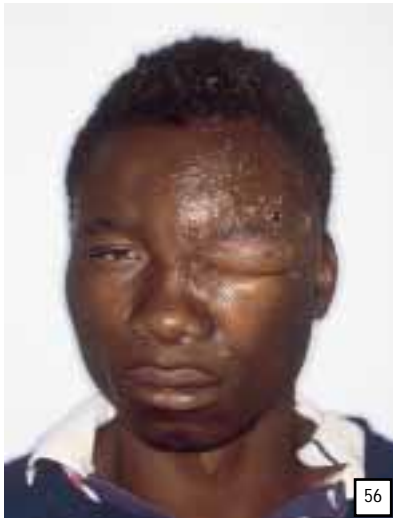Fig. 56. Ophthalmic herpes zoster in a 24 year old man.

Fig. 57. Herpes Zoster as the first sign of HIV infection in a 3 1/2 year old boy.

Fig. 58 & 59. Mutilating scars of herpes zoster in a 27 year old woman.

HERPES SIMPLEX - LIPS & GENITALS

The common presentations of a herpes simplex virus infection are the "cold sores" or "fever blisters" on the lip (herpes labialis) and the genital herpes infection. After a few days of prodromal burning sensation, a group of blisters appear, which quickly break down to form superficial ulcers. The primary infection may be accompanied by constitutional symptoms such as fever, malaise and anorexia and take up to 3 weeks to heal. If recurrences occur symptoms are less severe, usually without constitutional symptoms and they heal within 7 to 10 days. In most people they too are preceded by a burning sensation for a few days. Recurrences are triggered by:

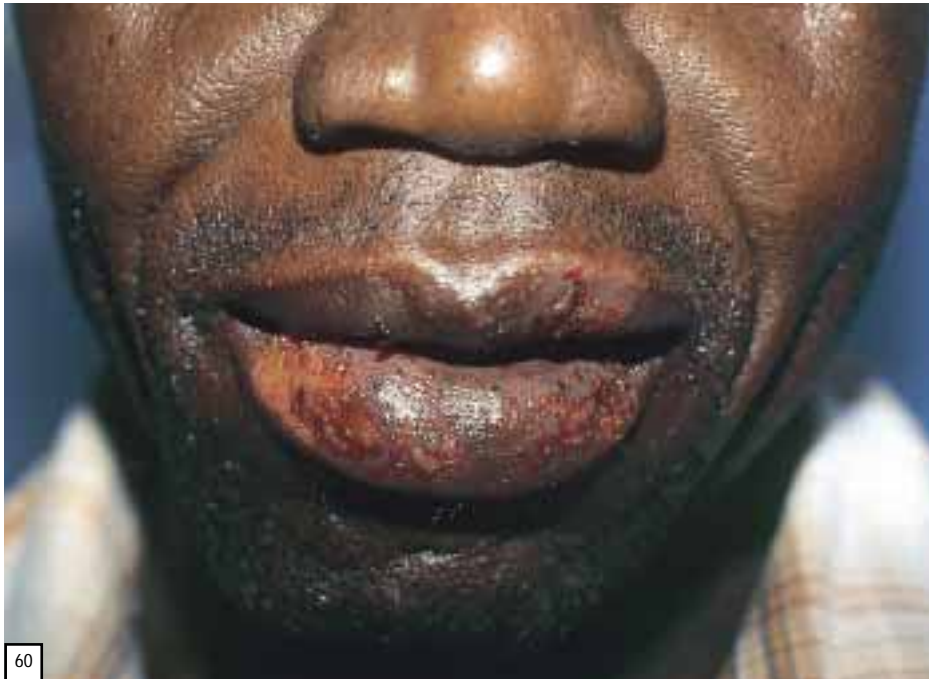- exposure to sunlight (herpes labialis)
- trauma (e.g. fighting-lip; sexual intercourse-genitals)
- fever

People with immunodeficiency as in HIV infection may have more severe infections and more frequent recurrences. Genital herpes may become chronic, persisting for months, ulcerating and may cover large parts of the genitals and surrounding skin, causing severe pain and disability.

Herpes simplex infection is spread by direct contact. It is highly contagious when lesions are visible and it has been shown that people shed virus even when there are no symptoms.

Management of herpes simplex infections

- **Primary infections** are very painful: analgesia is indicated.
- **Lips:** zinc oxide ointment or zinc oxide and castor oil; soothes and protects from sunlight.
Antiseptic mouthwash e.g. chlorhexidine mouthwash 3-4 times daily and topical antiseptic or antibiotic e.g. betadine ointment or oxytetracycline ointment 3 times daily for bacterial superinfection.
Use a lip cream / stick with a sunblocker daily to prevent recurrences.
- **Genital herpes:** Betadine or potassium permanganate solution sit baths 3 times daily. Zinc oxide and castor oil to soothe, or sulphur 5% in zinc oxide. Alternatively betadine ointment or oxytetracycline ointment 3 times daily.
- **Severe infections or infections in immunodeficient patients:** if available give acyclovir 200-400 mg 5 times daily for 5-10 days.



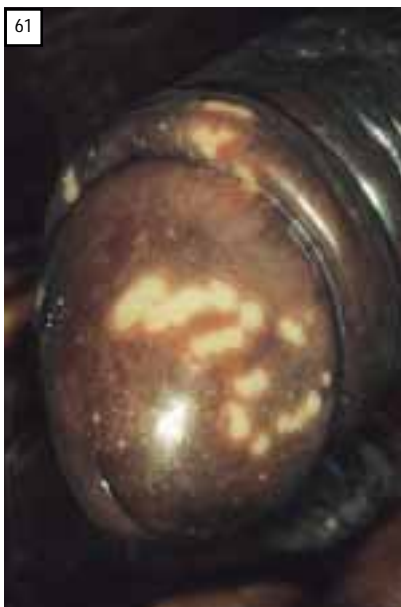60

Fig. 60. A HIV positive 43 year old man with primary herpes labialis.

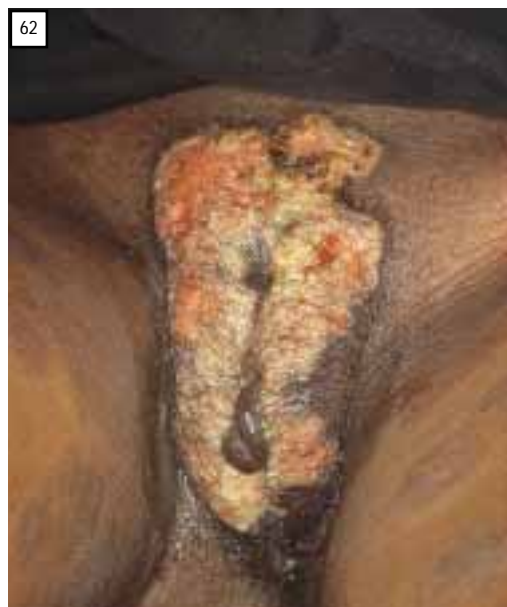Fig. 61. Recurrent genital herpes infection in a 32 year old man.

Fig. 62. Chronic ulcerating vulvar herpes simplex infection in a 30 year old HIV positive woman.

These lesions persisted for 6 months until they were cleared by acyclovir.



61



62

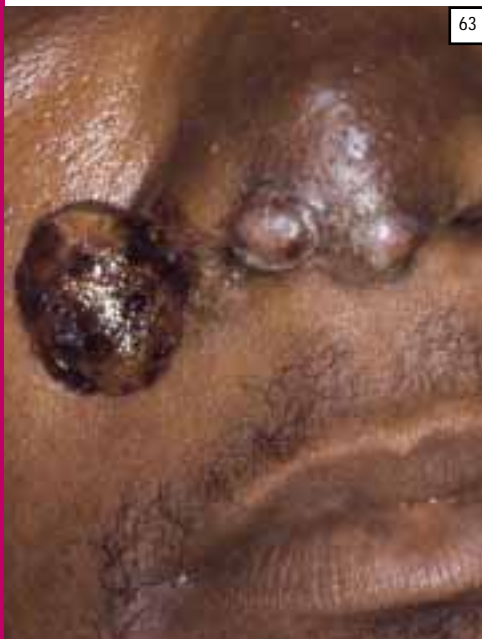KAPOSI'S SARCOMA

The incidence of Kaposi's sarcoma (KS) has increased dramatically with the current HIV epidemic. Although cases of classic (endemic) KS still occur, the vast majority we see today is HIV-related. KS, which has now been related to the oncogenic Human Herpes Virus-8, is a tumour of the cells of the vascular wall of blood and lymph vessels. Classic KS presents as purple-black papules and plaques usually on one leg which progress very slowly or remain stationary, even over 20 years or more. HIV related KS progresses much faster and more aggressively.

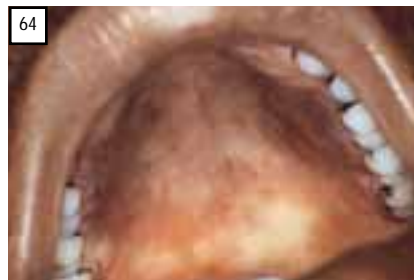HIV-related KS often presents with generalised lymph node enlargement or pleural lesions. Purple-black nodules and plaques appear on the face, the trunk, the genitalia or the proximal limbs, especially the thighs. Lesions may also be warty, tumorous, may ulcerate and they may cause gross oedema, especially in the face and of the penis and scrotum. Infiltration of the skin makes it "as hard as wood" on palpation. Plaques, nodules and tumours in the mouth, especially on the hard palate and tonsils are very common, always examine the mouth of a suspected KS patient.

Management of Kaposi's sarcoma

Treatment options depend on extent of tumor and growth rate, HIV viral load, and general condition of the patient. Limited skin disease may be treated with cryotherapy, or intralesional vinblastine or vincristine or radiation therapy. The extensively affected patient will need referral for radiotherapy or chemotherapy.



63



64

Fig. 63 & 64. Kaposi's sarcoma of the face and palate in a 27 year old HIV positive man.

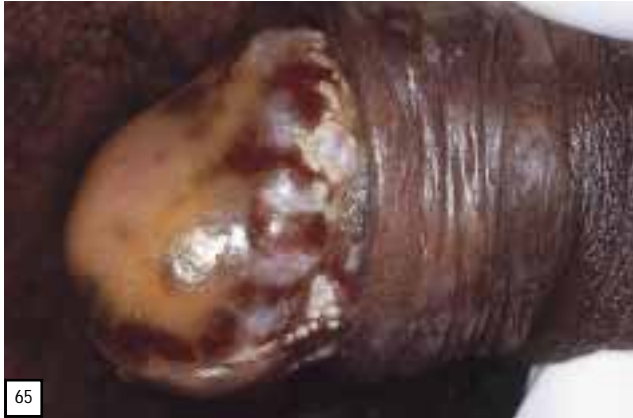

Fig. 65. Kaposi's sarcoma of the penis in a 57 year old man.

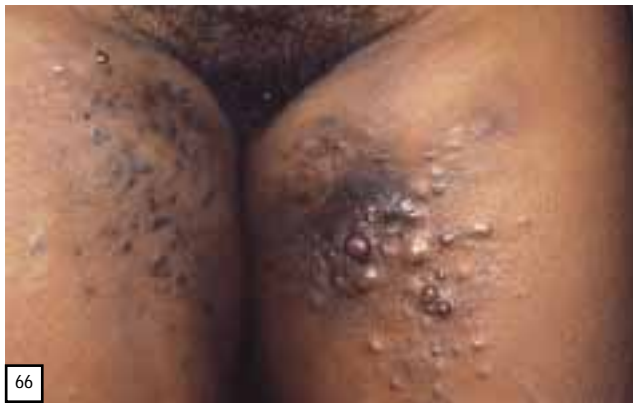

Fig. 66. Nodules and woodlike infiltration of the thighs in Kaposi's sarcoma.

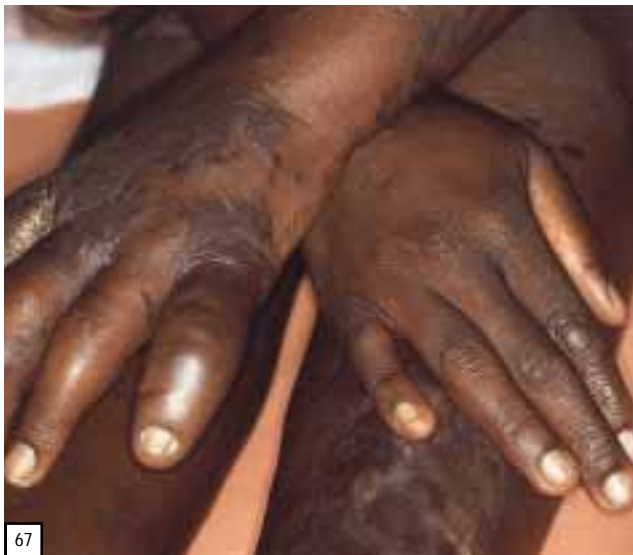
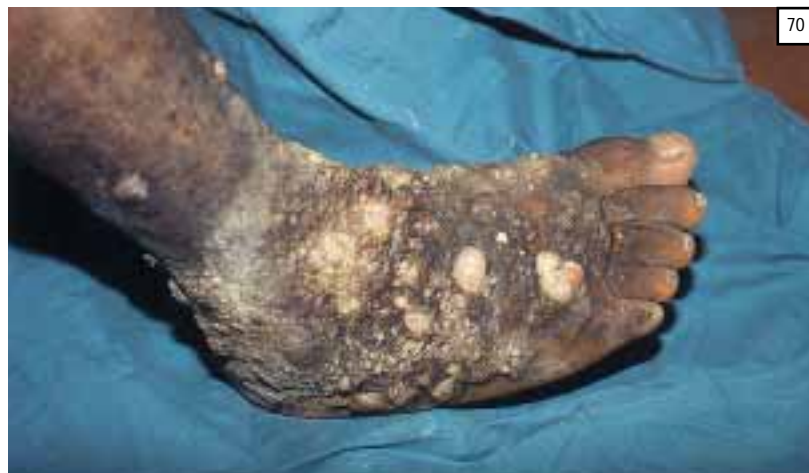
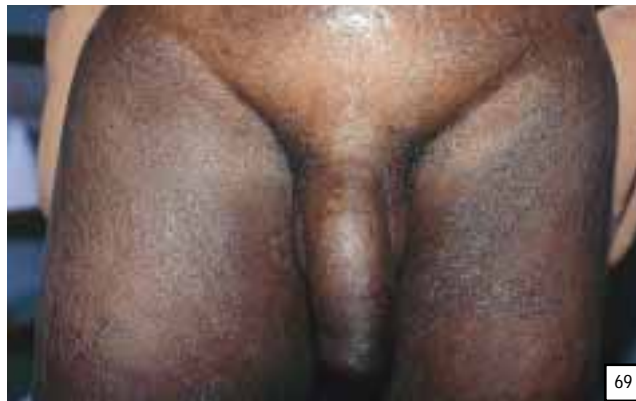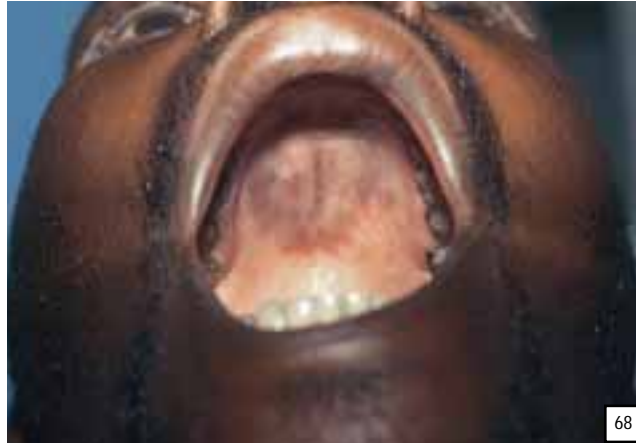Fig. 67. Multiple plaques of Kaposi's sarcoma in a 23 year old woman.

Fig. 68, 69 & 70. Kaposi's sarcoma in a 35 year old HIV positive man who presented with nodules and warty tumours on the foot. He also had purple discoloration of the palate and a woodlike infiltration of the thighs and groin with penile oedema.



COMMON WARTS

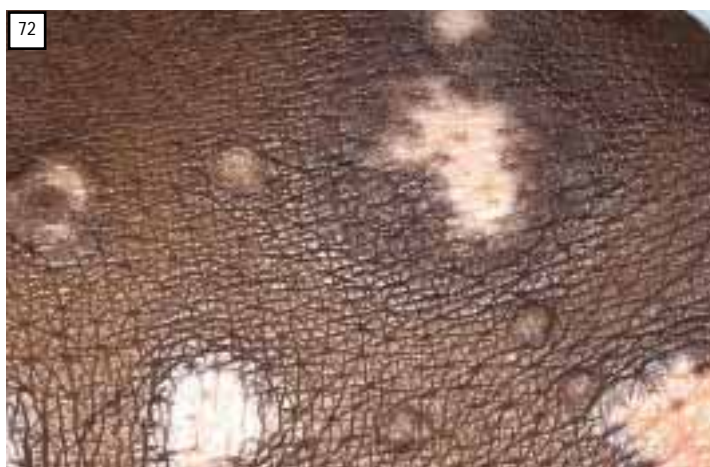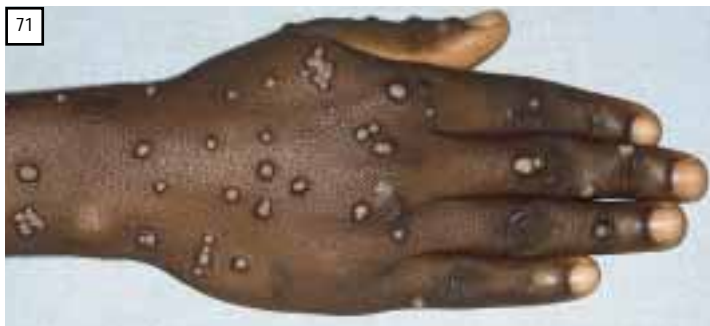Warts are caused by infection with Human papilloma virus (HPV). There are many types of HPV which cause different types of warts. They are found at any age but are most common in teenagers. They can spread by contact or auto-inoculation. The infected person's immune system clears the warts within 2 years in 2/3 of cases so treatment is often unnecessary. Treatment results vary greatly. In some people there is instant success, in others it may take many months or have no success at all. In immunodeficiency warts may spread quickly and fulminantly and become extremely difficult to treat.

Management of common warts

- Keratolytic therapy with salicylic acid 25% ointment twice daily followed by cutting or scraping the warts with a pumice stone, callus file or a knife twice a week. Preparations of salicylic acid 5-20% and lactic acid 5-20% in collodion are easier to use. This treatment may need to be repeated for months.
- Light electrodissection and curettage.
- Freeze with liquid nitrogen when available.

Fig. 71. Common warts on the hand of a 17 year old schoolboy.

Fig. 72. Depigmentation after treatment of warts with liquid nitrogen. This will heal in time.



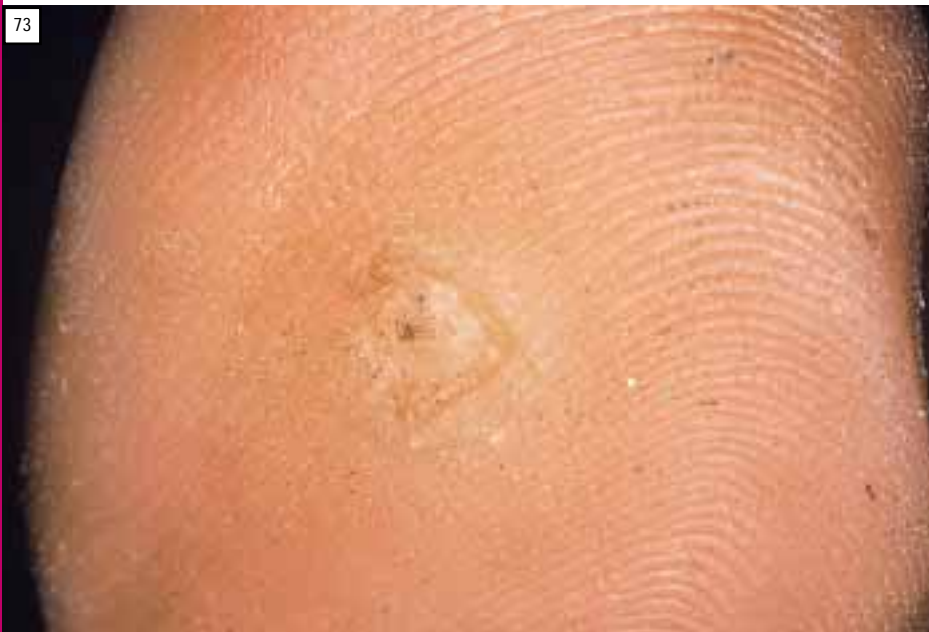PLANTAR WARTS

These are also common and they usually give no complaints. When this is the case they are best left alone. Sometimes they cause pain or discomfort urging the patient to seek treatment. It is then best to recommend non-aggressive therapy.

Management of plantar warts

- Regular flattening of the wart with a pumice stone, callus file or knife is usually enough to keep the warts asymptomatic.
- If there is only one or a few lesions curettage can be successful.
- Salicylic acid 50% ointment (25% in children) or preparations of salicylic acid 5-20% and lactic acid 5-20% in collodion can be used daily. Apply the keratolytic in the evening, cover with plaster and leave until the next evening. Then cut or scrape the warts with a stone or a knife. Soak the foot in hot water for 5 minutes before re-applying the keratolytic treatment.
- Avoid destructive electrosurgery and sharp scalpel excision. Although they may (or may not) remove the wart, the patient may not be able to walk properly for months and the resulting scar often becomes a more difficult problem to treat than the wart itself.

Fig. 73. Plantar wart.



PLANE (FLAT / JUVENILE) WARTS

These warts usually occur on the face in children and may spread to the upper trunk and arms or rarely to other parts of the body. They are very small (1-3 mm) slightly raised (palpate them!) papules which tend to present in large numbers. They exhibit a positive Koebner phenomenon which means that they appear in scratched or otherwise traumatised skin. In most children they eventually clear spontaneously.

Plane warts usually do not appear in adults but may do so in large numbers when they are immunocompromised, as in HIV infection.

Management of plane warts

- Salicylic acid 2-5% ointment twice daily for 4-8 weeks.
- If there are a limited number of lesions curettage with a sharp curette.
- Electrosurgery may be carefully tried but may leave hypopigmented scars.
- Caustic pencil (=silver nitrate pencil) daily.
- If lesions are widespread and salicylic acid 2-5% ointment is not successful it is best to leave them alone.

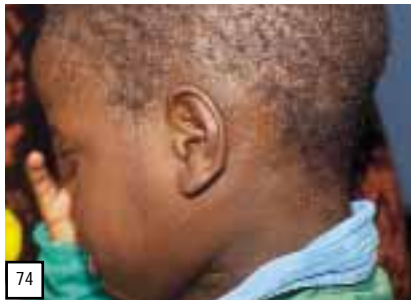
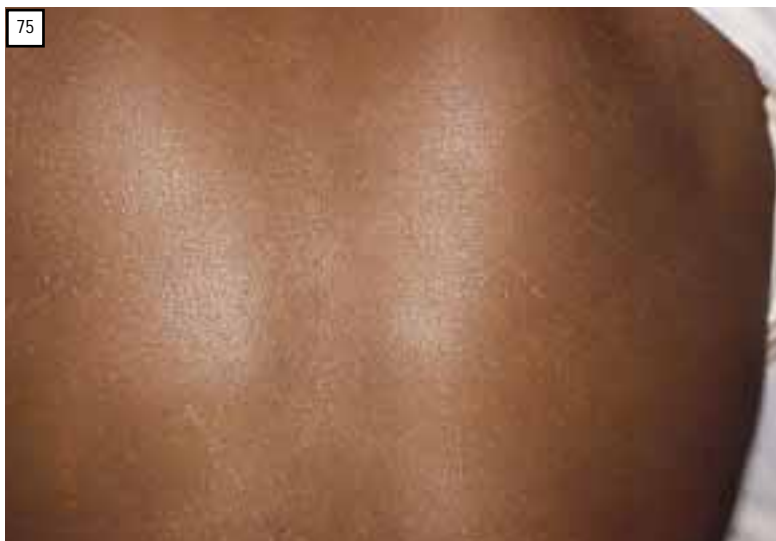
Fig. 74. Plane warts on the face and scalp of a 5 year old girl.

Fig. 75. Plane warts on the back of a 25 year old HIV positive woman.



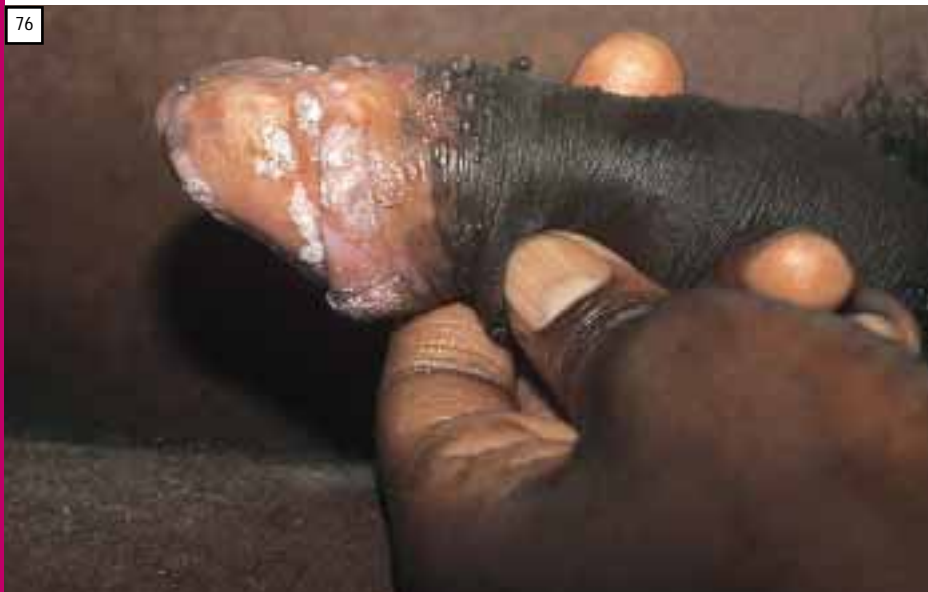GENITAL WARTS / CONDYLOMATA ACUMINATA

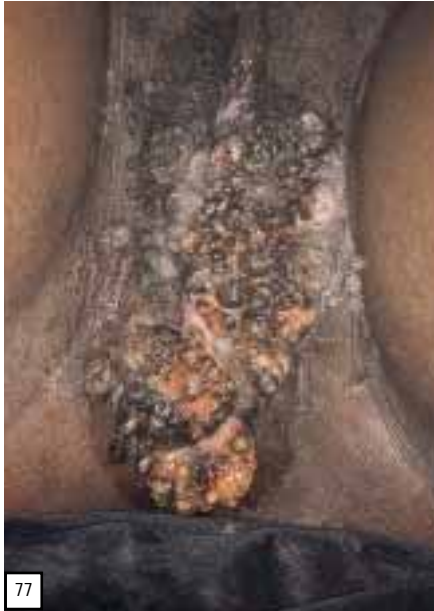Condylomata acuminata or genital warts are caused by HPV and are transmitted by direct contact, usually through sexual intercourse, sometimes by infected hands. Transmission is also possible from mother to child during childbirth. Genital warts may show accelerated growth in pregnancy followed by spontaneous reduction after childbirth. Excessive growth occurs in immune suppressed patients. Patients should have syphilis serology checked. Women with genital warts should have a Pap smear taken.

Management of condylomata acuminata

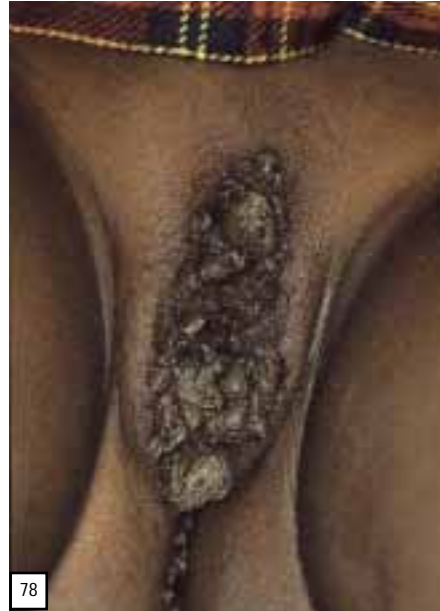- Podophyllin 10-25% solution. Protect the skin surrounding the warts with vaseline. Apply podophyllin carefully to the warts with the back of a matchstick. Leave it on for 4 to 6 hours then wash off with water and soap. Repeat weekly until cleared. **Podophyllin is contra-indicated in pregnancy!**
- Trichloroacetic acid 50-88% solution, applied in the clinic, may be used in pregnancy.
- Cryosurgery with liquid nitrogen .
- Cauterisation of large and/or refractive genital warts. This can be a very useful procedure but is controversial in immune suppression because the warts tend to recur quickly and extensive. When patients are severely disabled by their genital warts, you may however not have much choice.
- Topical 5% 5-fluoro-uracil cream (Efudix) may be used once daily to once weekly for up to 6 months after any of these treatments to prevent recurrences. **Efudix is contra-indicated in pregnancy.**
- Examine partners and perform syphilis serology.

Fig. 76. Condylomata acuminata on glans penis and foreskin of a 30 year old man.



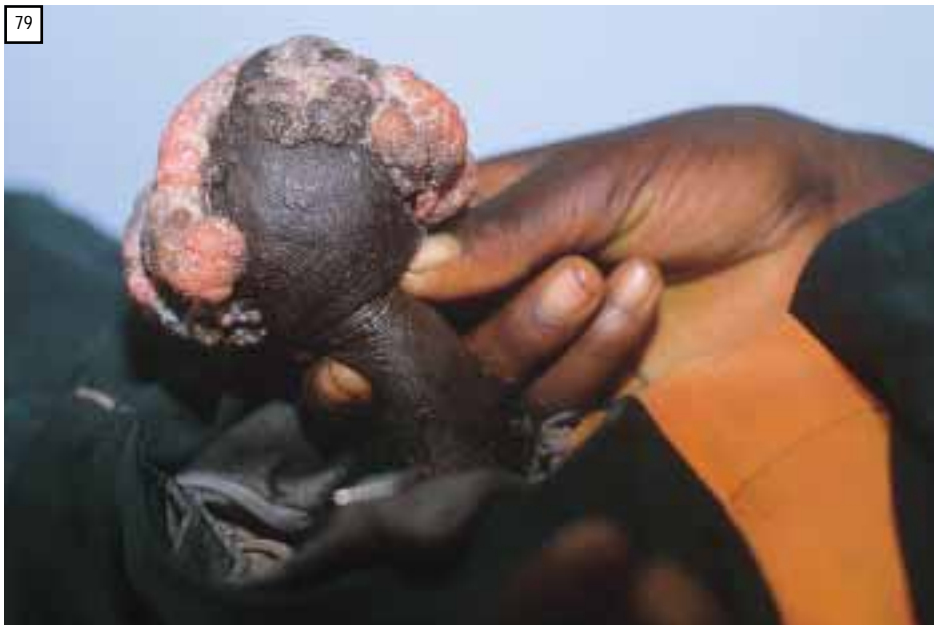

77



78

*Fig. 77. Persistent condylomata acuminata in a HIV positive 22 year old woman.
Fig. 78. Condylomata acuminata in an 11 year old rape victim who also tested HIV positive.
Fig. 79. Giant condylomata acuminata in a 24 year old man with clinical immune suppression.*



79

MOLLUSCUM CONTAGIOSUM

These infectious dome-shaped papules are caused by a pox-virus. They have a central dimple in which often typical whitish cheesy material can be seen, it looks like a little white ball. Molluscum normally occurs in small children in areas of warmth, moisture and friction such as the armpits and the groins, and on the face. Generally they are self-limiting and will disappear within a year without treatment. If they persist for a longer time or if they cause complaints they may be treated. When they occur in adults, particularly when there are multiple and large lesions, there may be immunosuppression.

Fig. 80. Multiple lesions of molluscum contagiosum on the eye lids and face of a 39 year old woman with immunosuppression.

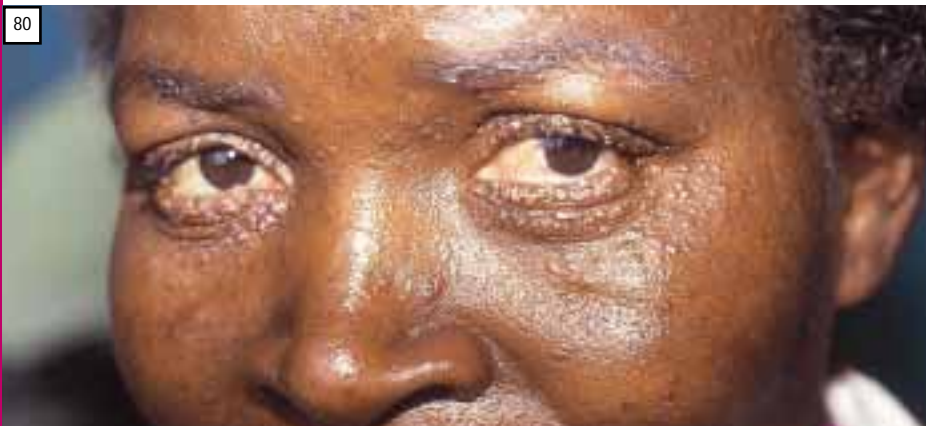Fig. 81. Removing a molluscum with a curette.

Management of molluscum contagiosum

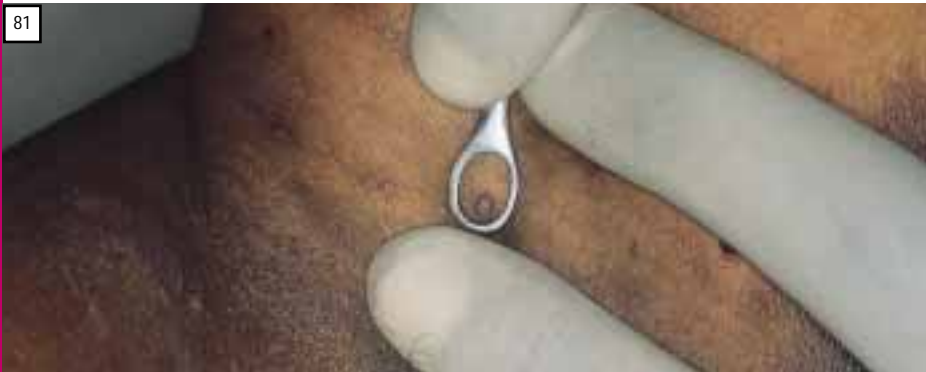- Prick the centre with a sharpened matchstick and press out contents.
- Curettage with a sharp curette or lance with a pin.
- Use betadine solution or scrub after the above until dry.
- Caustic pencil (silver nitrate pencil) for small molluscum.
- Caustic treatment with 80% phenol or 50-88% trichloro acetic acid.
- Freeze with liquid nitrogen.

60

80



81



PARASITIC INFECTIONS

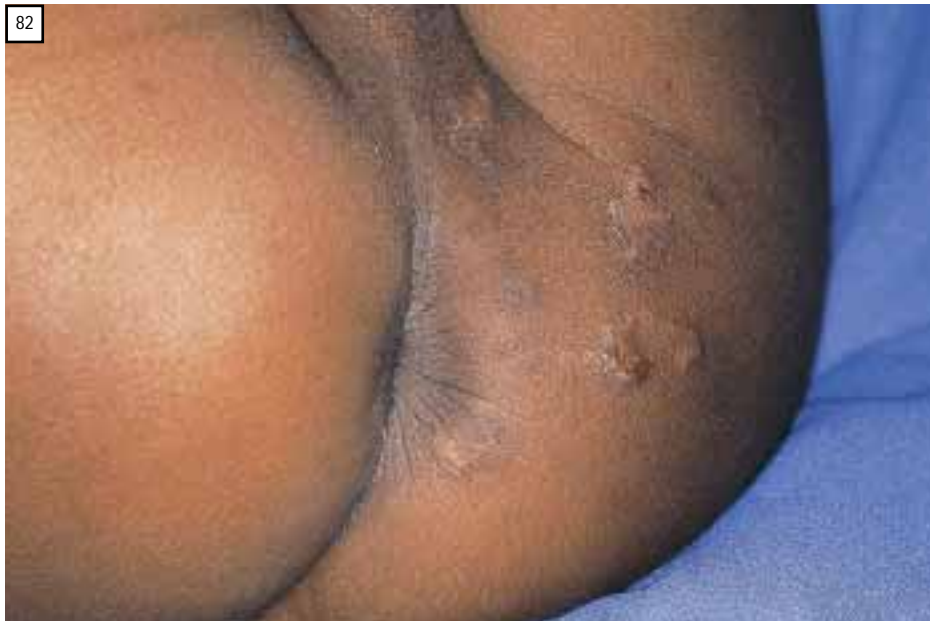CREEPING ERUPTION / LARVA MIGRANS

The larvae of hookworms of cats and dogs usually cause this disease. They enter the skin accidentally and migrate through the skin leaving a very itchy, winding red trail of inflamed skin behind them. Larvae may travel 1 to 5 cm or more daily. Sites of penetration are those in contact with the ground, usually the feet or especially in small children the thighs and buttocks. The larva can also be transmitted via towels or clothes, which have been in contact with the infected soil. Scratching often causes secondary infection and eczema. If untreated, the larvae eventually die after some weeks or months.

Management of creeping eruption

- Freezing the skin about 1 cm ahead of the visible trail, this is where the head of the larva is found. Chlorethyl spray, liquid nitrogen, solid carbon dioxide may be used, even plain ice can be tried. This is only effective in experienced hands.
- Albendazole 400 mg twice daily for 3 days for adults and children > 2 years of age, 200 mg twice daily for 3 days for children < 2 years of age.
- Thiabendazole 10-15% cream or ointment 4 times daily until 2 days after the burrows have disappeared (usually 1-2 weeks).
- Treat superinfection with betadine scrub, potassium permanganate solution, gentian violet paint or if severe antibiotics (see impetigo).
- Ivermectin 3-12 mg in a single dose depending on bodyweight.

Fig. 82. Creeping eruption in a 18 month old boy.



82

SCABIES

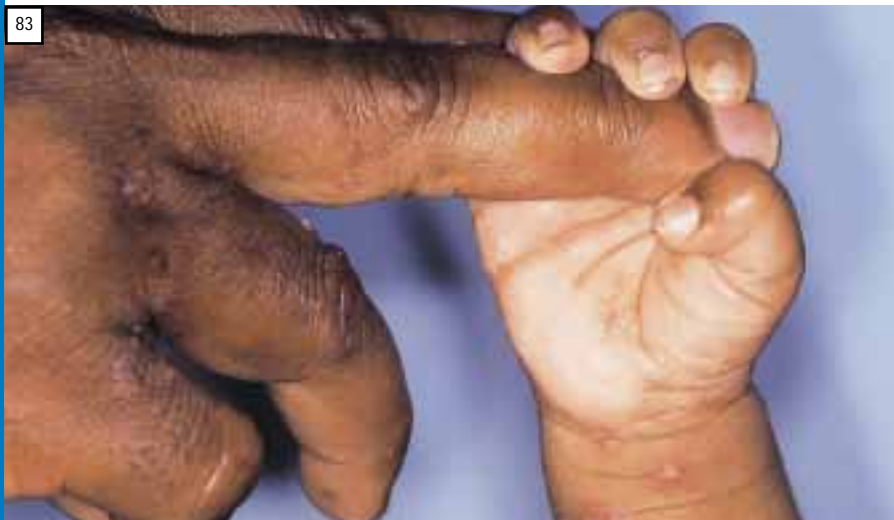Scabies is an infection caused by the mite *Sarcoptes scabiei*, which lives and moves in the skin producing burrows (S-shaped ridges), small blisters and papules. Itching is especially severe at night, and causes scratch marks and very commonly secondary infection with pustules and crusts. Lesions occur preferentially between the fingers, on the sides of the hands and feet, on the flexor sides of the wrists, in the armpits and on the genitals and buttocks. In infants and small children palms, soles, head and neck are often affected. Scabies is primarily spread through close personal contact but may be transmitted through clothing, linen, or towels.

Management of scabies

Whichever treatment is chosen, it is essential to treat all close contacts of the patients, e.g. people sharing the same household. Also linen and clothing should be washed or aired for at least 24 hours at the time of treatment. Secondary infection should be treated like impetigo for 5 days. Lesions should be closed before applying scabies treatment.

- Gamma benzene hexachloride (GBH) 1% lotion or cream. Apply from the neck down. Allow to dry and wash off after 24 hours. Give 10 ml for adults and 5 ml for children over 12 years. Do not use in pregnancy, breastfeeding mothers or babies < 6 months.
- Treat children with benzyl benzoate 25% emulsion diluted with one part water (1:1). Dilute with 3 parts water (1:3) for infants. Apply for 3 nights, wash off each morning.
- Sulphur 5-20% ointment twice daily for 1-2 weeks.
- Scabies epidemics in institutions (prison, army camp, boarding school) may be treated with ivermectin.
- Post-scabies itch often occurs. This can be mistaken for inadequately treated scabies. Treat with topical steroids.

Fig. 83. Papules and pustules of scabies in mother and child.



NORWEGIAN (CRUSTED) SCABIES

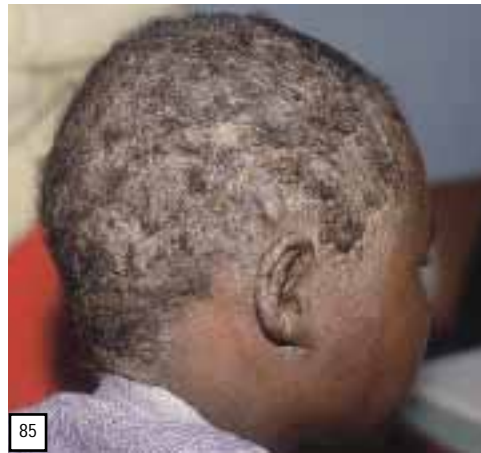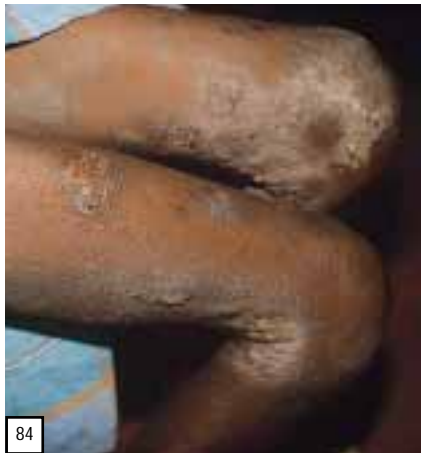This is a variant of scabies where the skin lesions are extremely massive and extensive. Thick, grey keratoses and crusts develop on the hands, elbows, knees and ankle joints and also extend to areas not normally affected by scabies such as the face and scalp, and nail beds. Norwegian scabies is seen in severely immunocompromised patients such as in AIDS patients. The crusts are teeming with scabies mites and thus very infective to others.

Management of Norwegian scabies

- Treatment is as for scabies though it may need to be prolonged.
- Keratolytics need to be applied to remove the thick crusts: salicylic acid 5-10% ointment or urea 10% ointment.
- Ivermectine 3-12 mg depending on bodyweight plus sulphur 5-20% ointment.

Fig. 84, 85 & 86.

Norwegian scabies in a 15 year old girl who responded well to treatment but died a year later, after extreme wasting.



LEISHMANIASIS

Leishmaniasis is caused by an infection with the leishmania parasite, after the bite of an infected sandfly. After an incubation period of two weeks to four months an erythematous or skin coloured nodule appears. This ulcerates and then becomes crusted or even verrucous, in most cases eventually leaving an ugly scar. The sandfly likes to bite on moist areas, preferably around the eyes, ears, nose and mouth. Lesions may be found on the skin, the mucous membranes or both. The latter, mucocutaneous leishmaniasis, may completely destroy the nose and does not heal spontaneously.

Leishmaniasis may cause lymphadenitis or become visceral, Kala Azar. After Kala Azar it may cause PKDL, Post Kala Azar Dermal Leishmaniasis. In a few cases leishmaniasis becomes generalised, showing infiltration and nodules over the whole body. This persists for life.

Management of leishmaniasis

The sore type of leishmaniasis:

- Cryosurgery.
- Excision.
- In some cases itraconazole or ketoconazole may be tried.

Leishmaniasis with lymphadenitis:

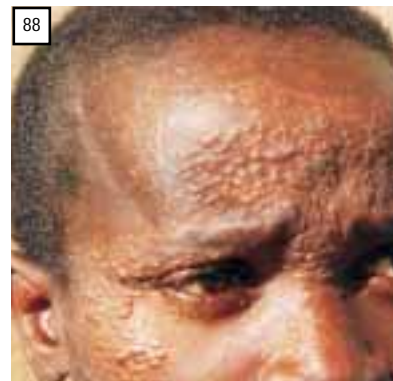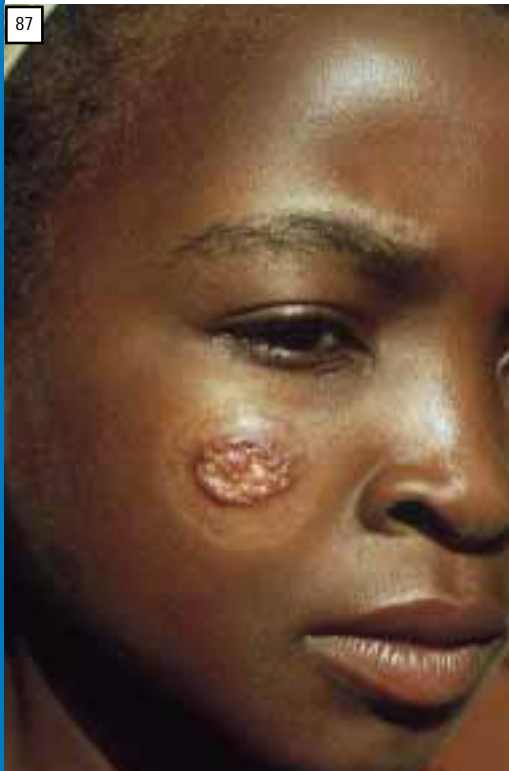- Pentavalent antimonium preparations (stibogluconate) Glucantime or Pentostam 20 mg/kg/day for 20-30 days i.v. or i.m.
- Pentamidine isothionate 4 mg/kg/week for 4 weeks to 8 months.
- Amphotericin B 1 mg/kg on alternate days for 2 months

PKDL: stibogluconate.

Diffuse generalised leishmaniasis: repeated courses of pentamidine isothionate.

Fig. 87. Teenage girl with sore type of leishmaniasis.

Fig. 88. A 30 year old man with PKDL.



LYMPHATIC FILARIASIS

Elephantiasis in the tropics may have a number of causes ranging from bacterial or fungal lymphangitis and adenitis to Price's disease. In the latter silicates in red volcanic soil which enter the skin through the soles cause an immune reaction which blocks the lymph nodes. A common cause of elephantiasis is the parasitic worm *Wuchereria Bancrofti*, which is transmitted by mosquitoes. It presents after an incubation period of 5 to 15 months with mild lymphangitis and lymphadenitis, and pitting oedema of one or more extremities or genitals. The lymphadenitis is descending rather than ascending. At first there are attacks of swelling but later the symptoms become chronic. Adult worms are present in the lymphatics and the resulting inflammatory response is thought to be the cause of the obstruction. The late effects include firm lymphoedema of the extremities, the vulva, scrotum, arms and breasts. The legs at this stage often have a warty appearance with folds and cracks in the lower legs and feet. Active infection can be diagnosed with a rapid card test using fingerprick blood.

Management of lymphatic filariasis

- Keep clean and manage intercurrent infections.
- Exercises to improve lymphatic flow.
Lymphmassage, intermittent compression, elastic compression bandages and stockings or lace-up boots may all be helpful.
- Ivermectine 12 mg plus albendazole 400 mg in a single dose for adults (see onchocerciasis) will kill microfilariae but not the adult worms.
This treatment therefore needs to be repeated yearly until all adult worms have died of old age (3-4 years).

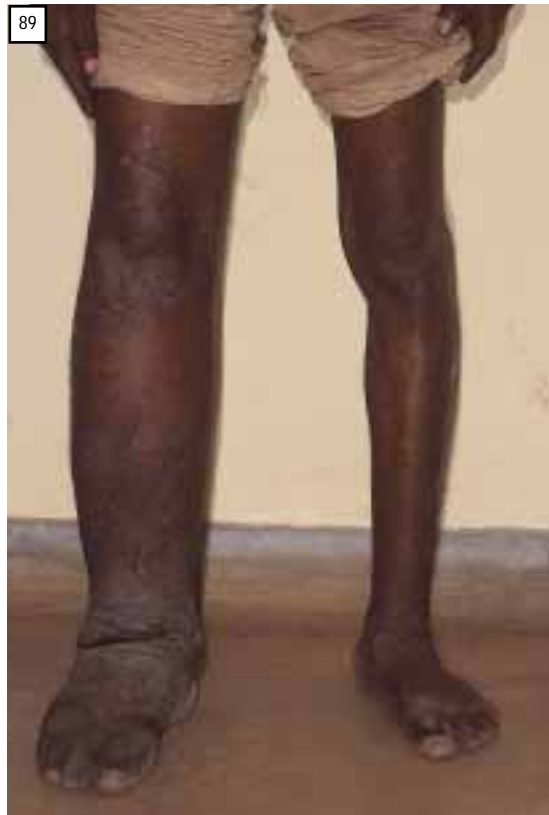

Fig. 89. Lymphatic filariasis.

Fig. 90. Longstanding onchocerciasis in a 40 year old woman.

Fig. 91. Onchonodules (Courtesy Dr. D.L. Leiker).



90

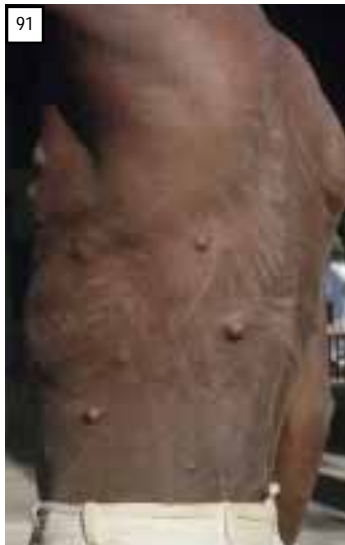ONCHOCERCIASIS

Onchocerciasis or river blindness is a chronic infection of the skin and the eyes by the filaria *Onchocercus volvulus*. It is transmitted by female blackflies which are typically found near fast moving water. People living in these areas get infected again and again, thereby accumulating hundreds to thousands of microfilariae in the skin and the eyes, where they move around freely. In the skin this causes severe itch as the major presenting complaint. In the first stages there are only a few erythematous hyperpigmented papules and scratch marks. Later the whole skin thickens and becomes dry and lichenified. There is loss of elasticity (hanging groins). Skin hyper-, hypo- and depigmentation may occur in chronic cases. Onchonodules, which represent the adult worms, can be seen and palpated, in particular above the hipbones but also elsewhere. Biopsy or skin snip may show microfilariae. Eye involvement is a well known cause of blindness.

If the history is suspect but microfilariae have not been demonstrated a Mazotti test can be performed. Under careful conditions (cave: anaphylactic shock) 50-100 mg diethylcarbamazepine (DEC, Hetrazan) is given. A positive test yields intolerable itch within a few hours.

Management of onchocerciasis

- Treat secondary infection with antiseptics or antibiotics as impetigo and secondary lichenified eczema as lichen simplex.
- Ivermectin kills microfilariae with a single oral dose. The adult worms are not affected however. A patient staying in an endemic area will therefore need repeated treatment every 3 to 12 months depending on the amount of itching. If the patient moves out of the endemic area repeated treatment may cure the infection as the adult worms will die after a few years.
- When there is eye involvement steroid treatment should precede ivermectin.
- Single dose of ivermectin (6 mg tablets) according to body weight in kilograms: under 30 kg: 0,5 tablet, 30 to 50 kg: 1 tablet, 50 to 70 kg: 1,5 tablet, over 70 kg: 2 tablets.



91

AUTO-IMMUNE DISEASES

ALOPECIA AREATA

Alopecia areata occurs in adults and in children and generally presents as one or more round or oval bald patches on the scalp or beard area. The hair is lost suddenly, the bald patch extends until it is usually some centimetres in diameter, and as a rule after weeks to months new hairs begin to grow within the lesion. The skin remains normal, showing hair-follicle openings without scaling or atrophy. The re-growing hair may be white in colour, giving the impression of "turning white overnight" when a large area is affected.

In progressive cases new bald patches develop as others heal, or patches do not heal for years. In alopecia areata totalis there is baldness of the whole head; in alopecia areata universalis all body hair including scalp, beard, eyebrows, eyelashes, pubic and axillary hair falls out.

Management of alopecia areata

- Explain to the patient that the condition is not serious and that the hair is likely to grow back after some time. This may take weeks or months and is different in each individual.
- A topical irritant such as garlic may be tried.
- People with very extensive alopecia areata or alopecia which does not heal may be referred to a skin specialist.

Fig. 92. Alopecia areata in a 49 year old man.

Fig. 93. Alopecia areata in a 31 year old man.

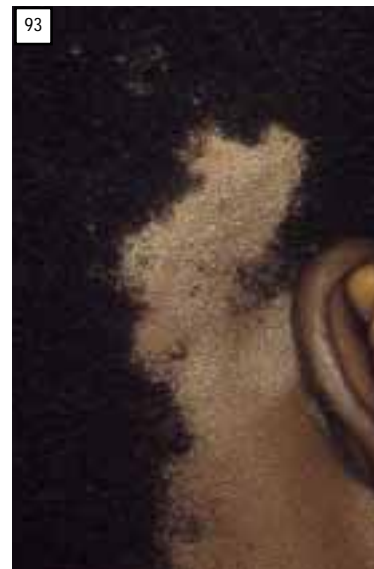
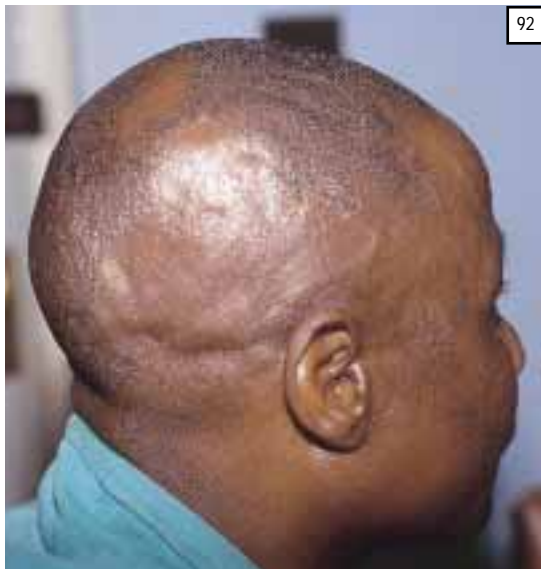
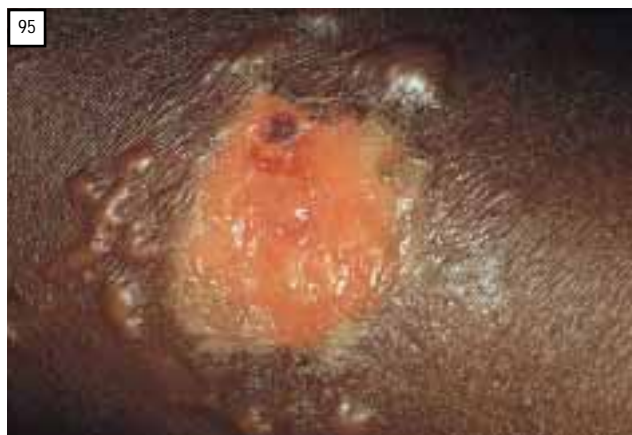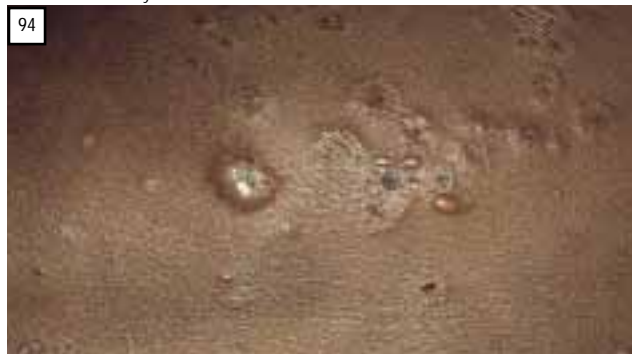
Fig. 94 & 95. Chronic bullous dermatosis of childhood. This 7 year old boy had the disease since age 3. He had been clear while on treatment with dapsone for one year. Lesions recurred within a month after stopping treatment.

CHRONIC BULLOUS DERMATOSIS OF CHILDHOOD

This is a chronic blistering disease which occurs in children. It usually starts before the age of 5 years. Small and large blisters appear predominantly on the lower trunk, genital area and thighs, often also on the scalp and around the mouth. They may spread all over the body. New blisters form around healing old blisters, forming "a cluster of jewels". There is often some itchiness. The course is chronic, spontaneous remission usually occurs after an average of 3-4 years.

Management of chronic bullous dermatosis of childhood

- Dapsone in doses from 12,5 to 125 mg daily or Sulphapyridine 250 mg to 3 grams daily usually control the eruption. After it clears you can **slowly** reduce the dosage to a maintenance dose but you may need to increase it again when disease activity flares up.
- Treat any superinfection with betadine, GV paint or if severe antibiotics.
- If there is no response to the above treatment, topical (strong) or systemic corticosteroids may need to be added. Take care not to overtreat, especially regarding the side effects of systemic steroids in children.



CHRONIC DISCOID LUPUS ERYTHEMATODES

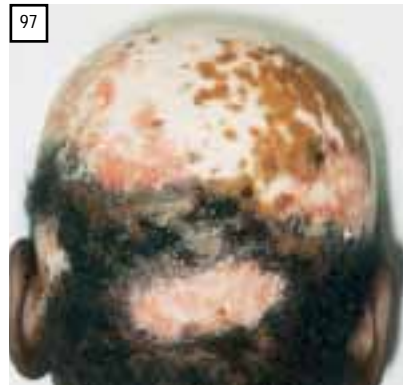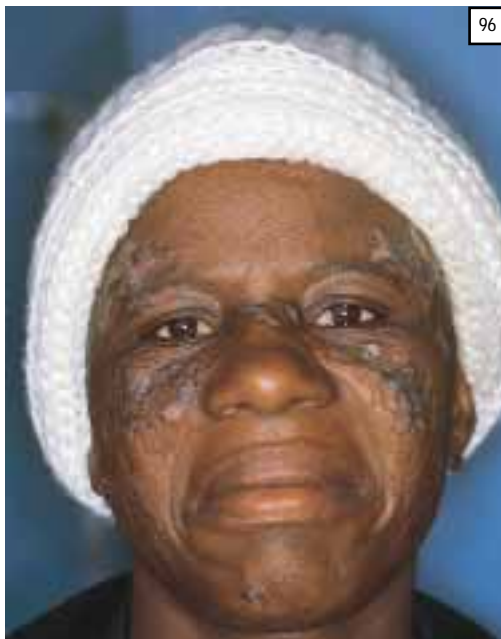Chronic discoid lupus erythematoses (CDLE) is a chronic scarring skin disease which occurs on sun-exposed areas. The face is the commonest site, but scalp, upper trunk and distal extremities may also be affected. On the face there may be a "butterfly distribution" on the cheeks and bridge of the nose, the lips may also be affected. The lesions are well-defined reddish patches with thick or hyperkeratotic scaling and hyper-, hypo- or depigmentation, they feel rough on palpation. They slowly increase in size and form atrophic hypopigmented scars. Exposure to sunlight aggravates the lesions and causes an increase in symptoms, such as itch and irritation.

Management of chronic discoid lupus erythematoses

- Sunprotection! Wear a sunhat, protective clothing, and stay out of the sun as much as possible. Use a sunscreen when outdoors (see albinism).
- Topical steroids e.g. betamethasone 0,1% once daily. If this is not effective after 2 months, this treatment should be stopped, as there is already a high risk of skin atrophy.
- Chloroquine 150 mg/hydroxychloroquine 200 mg once daily for 6-8 weeks. If improving continue until maximum improvement (i.e. no active lesions, scars will not disappear), then slowly decrease the dosage (over months). If no improvement occurs a double or triple dose may be tried for a short time. Do not use antimalarials for more than 9 months at a time.
- Sometimes dapsone, with or without antimalarials is effective.

Fig. 96. Active CDLE showing thick patches with hyperkeratotic scaling and hypopigmented scars in a 46 year old woman.

Fig. 97. CDLE of 20 years duration showing extensive scarring of the scalp in a 45 year old woman.



LICHEN PLANUS

Lichen planus presents with very typical itchy papules, which are small (1-3 mm) and are demarcated by the natural skin lines, making them polygonal. They have a sharp, elevated border, a flat surface (hence the name "planus") and they shine by reflecting light. They are often a shade of red, later reddish blue to purple and show "Wickham's striae", a fine milky-white network on the papule's flat surface. Neighbouring papules may join together to form plaques which resemble lichen growing on trees, explaining the name "lichen". They may occur anywhere on the skin but are most common on joint flexures (especially wrists), genitals, sacral region and inner thighs. A Koebner phenomenon is present. The oral mucosa and lips may be affected and show a network of white lines. Actinic lichen planus occurs on sun-exposed areas. In hypertrophic lichen planus there are thick, hyperkeratotic papules and nodules or thickened wart-like plaques on the shins. Lichen planus is self-limiting, it will disappear spontaneously, sometimes in months but it may take many years.

Fig. 98. Typical polygonal papules of lichen planus.

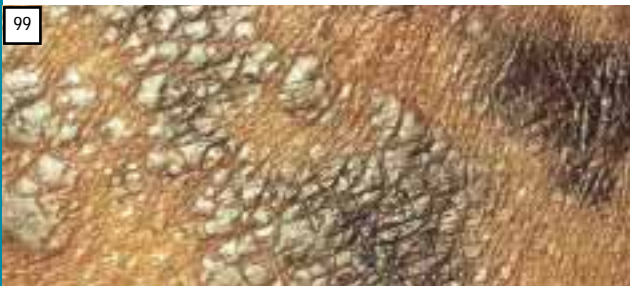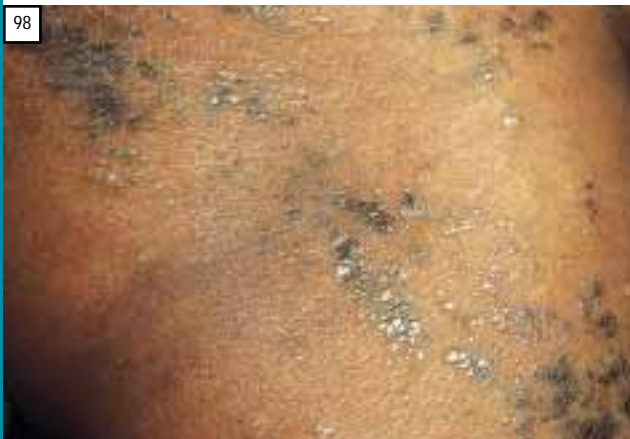Fig. 99. Lichen planus papules showing Wickham's striae.

Management of lichen planus

Treatment can be very difficult.

- For severe itch: calamine lotion and/or antihistamines.

- Coal tar 2-6% ointment nightly.
- Strong topical steroids combined with salicylic acid 5% once to twice daily.
- Refractive lesions: Apply strong steroid at night and cover with plastic 2 nights a week (see lichen simplex). This improves penetration of the steroid.
- Widespread, severe forms: a short course of prednisolone may be tried: start with 30 mg daily for a week then reduce to zero in two weeks.



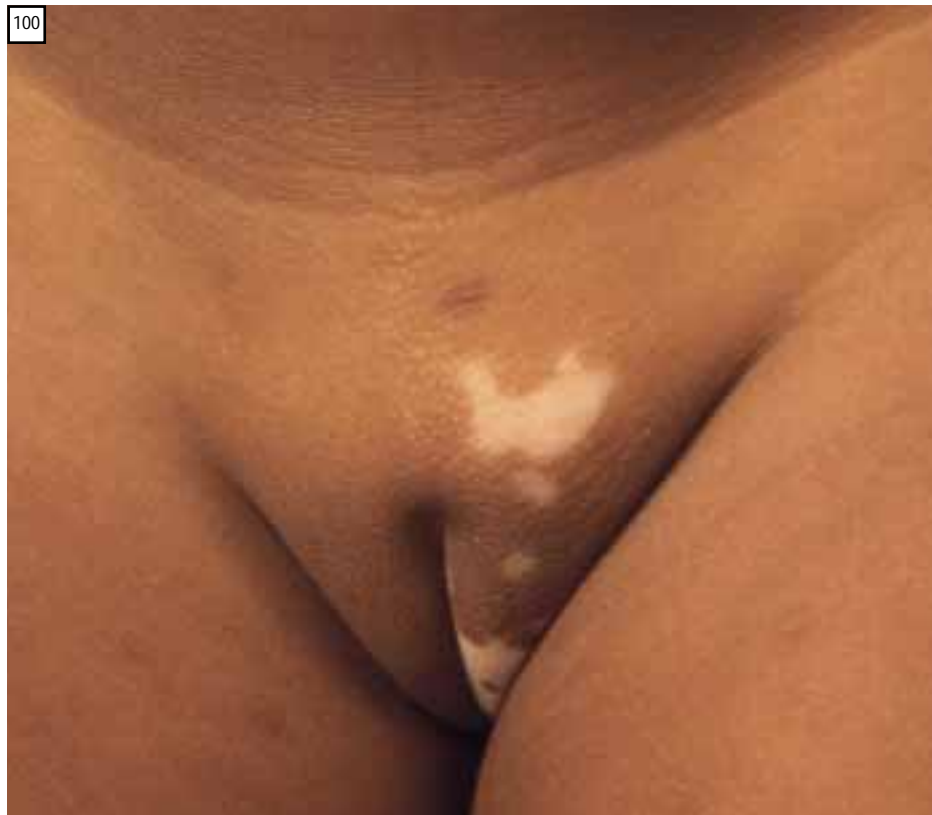VITILIGO

Vitiligo is a relatively common, sometimes familial disorder in which depigmentation of the skin occurs. It may start at any age but often starts in young adults. Lesions start as small white macules and become progressively larger and confluent, leading to bizarre shapes. Common localisations are the hands and feet and the skin around body openings, e.g. around the eyes, nose, mouth and lips, the umbilicus, and around the genitals and the anus. Vitiligo also occurs in traumatised skin and can affect hair bulbs, leading to streaks of white hair. The condition is usually slowly progressive and seldom regresses spontaneously. Vitiligo of the genital area should be distinguished from lichen sclerosis, in which depigmentation and atrophy are usually limited to this area.

Management of vitiligo

- There is no satisfactory treatment. Reassure the patient; there is only colour change, vitiligo is not a sign of abuse.
- Sometimes the combination of topical steroids and sun exposure results in repigmentation.

Fig. 100. Vitiligo of the genital area in a young girl.



MISCELLANEOUS SKIN DISEASES

ACNE VULGARIS

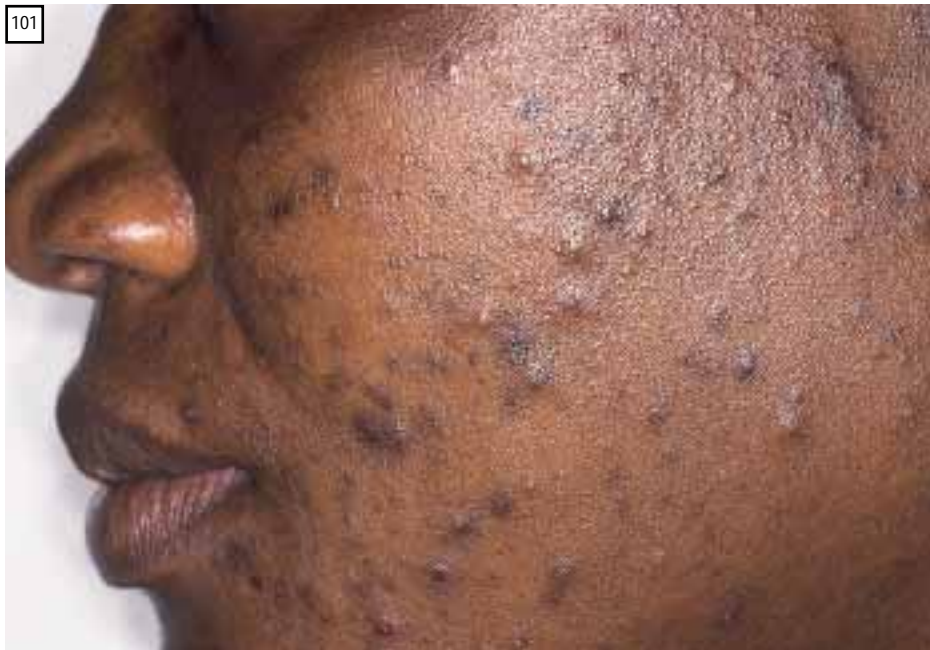Acne is very common in puberty and it usually regresses in early adulthood. Sometimes it persists up to age 30 or lifelong. Sebum production (patients complain of "oily skin") is the most important factor in acne. It occurs on the face and the upper trunk as blocked sebaceous gland ducts (forming comedones= blackheads and whiteheads), which may progress to inflammatory papules, pustules and nodules. Acne may be very mild to very severe. In severe acne conglobata, acne lesions blend together to form large inflammatory areas with cysts and scar formation.

Management of acne

- Stop the use of vaseline, oil or ointments and greasy cosmetics which further block sebaceous ducts.
- "Peeling" of the comedones with benzoylperoxide 5-10% gel or tretinoin 0.01-0.1% cream or gel, apply at night since both are photosensitisers. Salicylic acid 1-10% in an alcoholic solution. Alcoholic solutions remove excess sebum. Dilute methylated spirits with an equal amount of water to a 35% solution.
- For pustular/inflammatory lesions: topical clindamycin 1% lotion, erythromycin 2% lotion. If severe, use systemic tetracyclines, e.g. doxycycline 100 mg twice daily until substantial improvement (may be a month or more) followed by 100 mg once daily until acceptable or cleared, which may take many months.

73

Fig. 101. Acne vulgaris.



101

ALBINISM

Albinism is an inherited disorder of melanocytes, which do not synthesise melanin (pigment). This results in absence of pigmentation of skin, hair and eyes, combined with photophobia and nystagmus from birth. The skin is white, the hair white or yellow and the iris light blue. These patients are very light sensitive because they have no UV-absorbing melanin, which usually protects people from solar damage. After short term sun exposure sunburn, freckling, and early ageing of the skin already occurs and actinic keratoses with a tendency towards malignant transformation appear. Squamous cell carcinoma is seen at an early age, even in children.

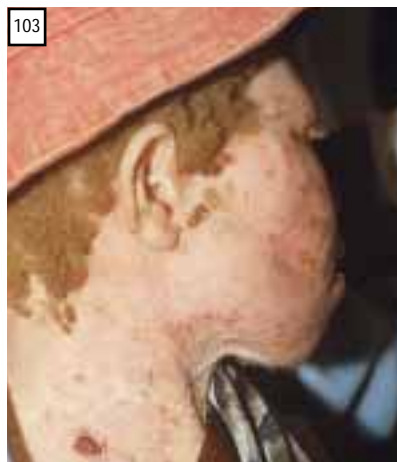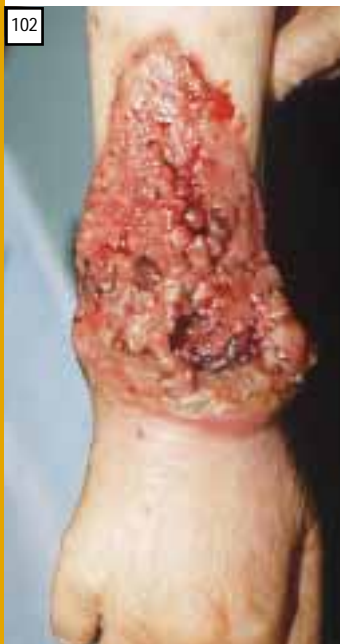Management of albinism

Sunprotection to prevent solar damage:

- Wear protective clothing (long sleeves, long skirts and trousers), a sunhat with a wide rim, providing protection for face, ears and neck, and sunglasses.
- Stay indoors as much as possible during the hot hours of the day.
- Children with visual impairment should be seated in front rows in classrooms.
- Use sunscreens with a high sun protection factor (SPF), e.g. PABA (para amino benzoic acid) which has SPF 15. Total sunblockers have even higher SPF's. Zinc oxide cream/paste/ointment blocks out sunlight and can be used for the lips. Apply sunscreen whenever going outdoors.

Regular skin check-ups for early detection and treatment of pre-cancerous keratoses and skin cancer. Single keratoses can be treated with liquid nitrogen, curettage and electro-dissection, shave excision followed by electrosurgery. Multiple and/or extensive lesions can be treated with topical 5% 5-fluoro-uracil. The extract from the fruit of the sausage tree (*Kigelia Africana*) is an effective alternative (ready-made cream at many pharmacies). The rough skin can be softened with urea 10% ointment or salicylic acid 2-5% ointment.

Fig. 102. Squamous cell carcinoma in a 27 year old woman with albinism.
Fig. 103. Keratosis and carcinoma in the same patient.




DERMATOSIS PAPULOSA NIGRA

A very common papular eruption in Africans which is probably genetically determined. Dark brown to black papules appear on the upper part of the face, especially on the cheeks and the temples. The first papules may appear from early teens and they increase in number with age. Forty percent of Africans over 30 years of age have this eruption in a limited or extensive form. It is more common in women than in men.

Management of dermatosis papulosa nigra

Treatment is not necessary and usually not requested.

- Cauterisation / diathermy which may be followed by curettage is possible. This may however leave undesired hypo- or hyperpigmentation. In extensive cases it is therefore advisable to treat a few lesions as a trial first.



104

Fig. 104. Dermatitis papulosa nigra in a 56 year old man.

DRUG ERUPTIONS

Most common are maculo-papular exanthema's, which are usually itchy. Drugs with a > 1% incidence of drug-induced exanthema are: penicillins, sulphonamides (fansidar, trimethoprim), NSAID's (like aspirin, indomethacin), isoniazid, erythromycin, hydantoin derivatives (e.g. phenytoin), carbamazepine, allopurinol, streptomycin and gold salts. They may occur soon after taking the drug (in previously sensitised patients), on finishing a course of drugs, or up to 3 weeks after taking a drug.

Urticaria is also a common reaction, often caused by penicillins, NSAID's, acetylsalicylic acid and X-ray contrast media.

Fixed drug eruptions recur on exactly the same spot every time the responsible drug is taken. There is usually one, sometimes two or more macules or plaques, reddish-purple in colour. They may show blistering and leave persistent hyperpigmentation on healing. Most frequent causes: barbiturates, paracetamol, pyrazolon derivatives, sulphonamides and tetracyclines.

Some drugs cause **photosensitivity**, commonly implicated are: amiodarone, chlorothiazide, fluoroquinolone derivatives, NSAID's, phenothiazines, psoralens, sulphonamides and tetracyclines.

Stevens-Johnson syndrome and **toxic epidermal necrolysis** are serious blistering eruptions which may affect large areas of skin and mucous membranes and may be fatal. Common causes: sulphonamides, hydantoin's, pyrazolon derivatives, carbamazepine and NSAID's.

Erythema exsudativum multiforme (EEM) shows characteristic "target" or "iris" lesions and is considered a minor form of Stevens Johnson syndrome. EEM and Stevens-Johnson syndrome are commonly caused by herpes simplex infections, only in second instance by drugs and other infections such as mycoplasma infections.

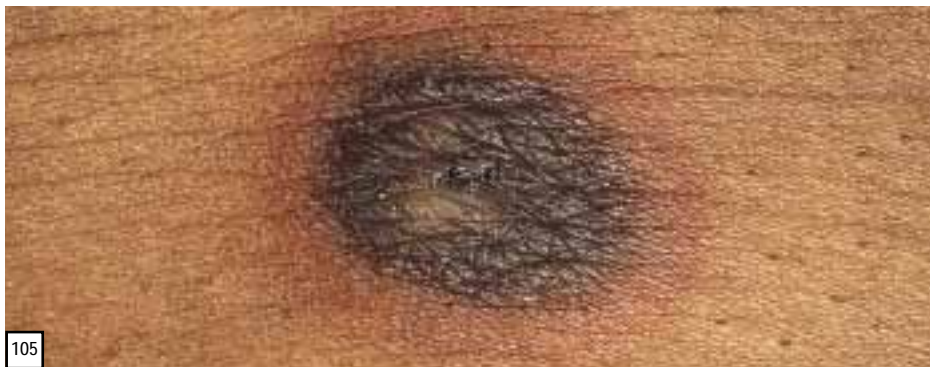Patients with HIV-infection are more susceptible to all drug eruptions.

Nearly all drugs can cause drug eruptions. Only the most commonly implicated drugs have been mentioned here.

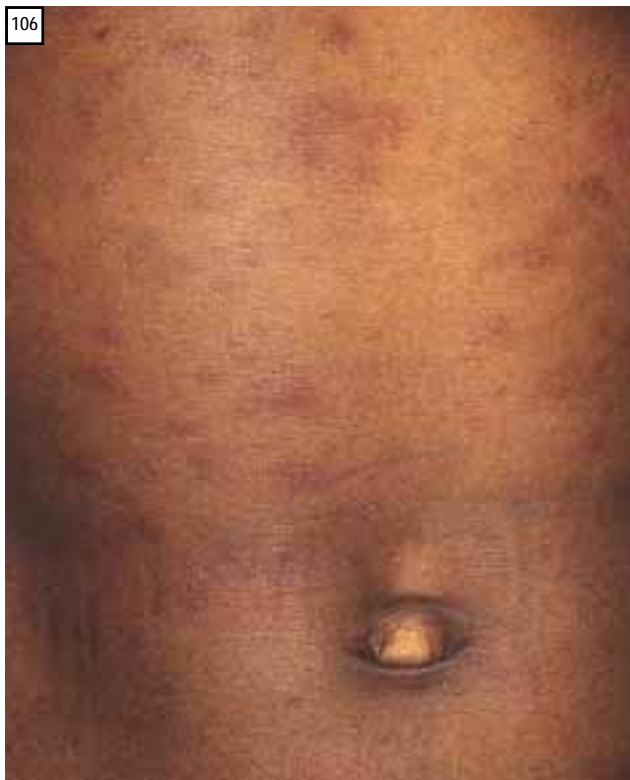Management of drug eruptions

- Identify the responsible drug and stop the use of that drug.
- For itchiness and drying in: Calamine lotion with or without menthol 0.25% and/or phenol 1% , or zinc oxide cream.
- Burn cream or honey.

- Oral antihistamines e.g. promethazine 25 mg once or twice daily or chlorpheniramine 4 mg 3 times daily.
- In severe reactions a short course of prednisolone may be given starting at 30-60 mg daily and quickly reducing the dose in 2 weeks.
- When there is extensive skin loss the patient should be hospitalised, given i.v. fluids and treated like a burn case i.e. given betadine baths, dressed with silver sulphadiazine 1% burn cream and given antibiotics and analgesics as required.



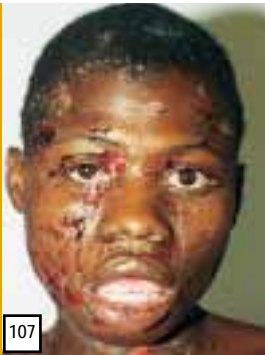105



106

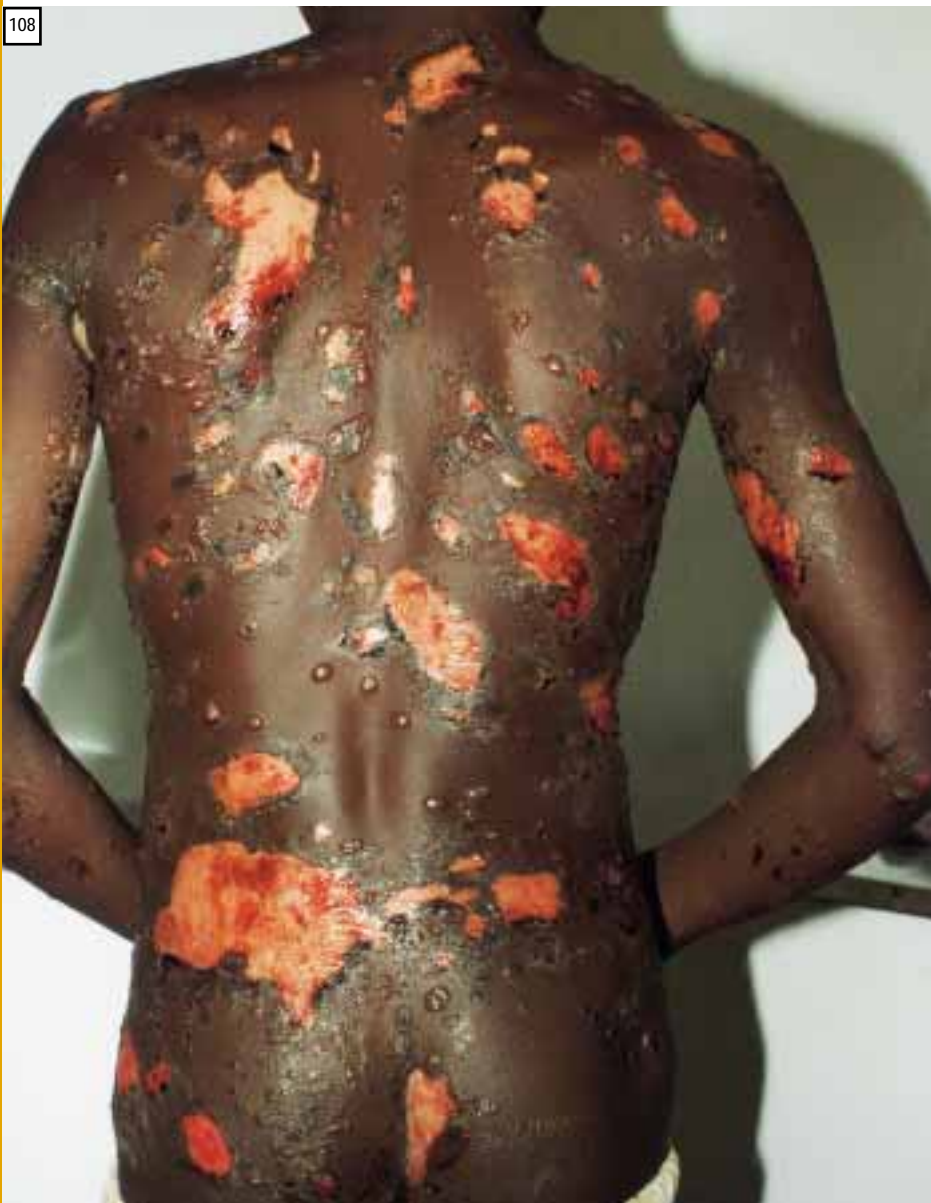Fig. 105. Fixed drug eruption as a reaction to cotrimoxazole.

Fig. 106. Urticarial exanthema as a reaction to amoxicillin.



107

Fig. 107 & 108. Stevens-Johnson syndrome as a reaction to cotrimoxazole in a 16 year old boy.



108

HEMANGIOMA (CONGENITAL)

Congenital hemangiomas are benign tumours of blood vessels which become manifest in the first few days of life. They can be single or multiple and vary in size from less than 1 cm to more than 10 cm. The preferred site is the face though they can occur anywhere on the skin. The mucous membranes i.e. the lip and tongue can be affected. Hemangiomas may grow rapidly in the first months causing great concern to the parents. However, they regress spontaneously in about 70% of the patients. Regression starts in the first year of life and takes 5-10 years. Sometimes a hemangioma may bleed easily or it may become (partly) necrotic after trauma or during a period of fast regression. Regression may show no scarring, there may be a slack, baggy area of skin if the hemangioma was large or the skin may be hypopigmented and atrophic.

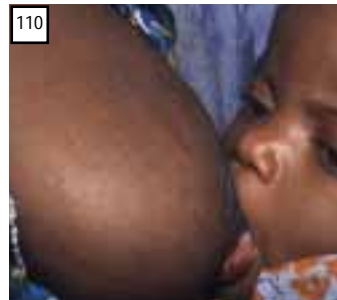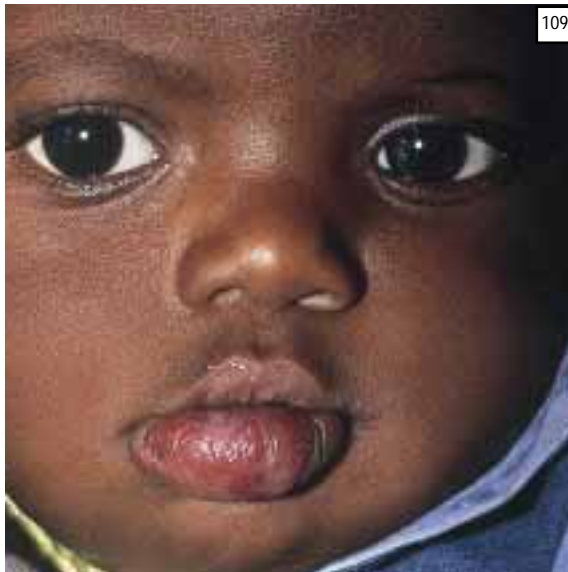Management of congenital hemangioma

- In most cases no treatment should be given. The parents need to be told that spontaneous regression is to be expected and that this gives the best cosmetic outcome. This is in contrast to surgery which may leave disfiguring scars.

Treatment is indicated in:

- 1 a lesion which does not disappear or gets bigger in a child > 7 years of age,
- 2 impaired function of vital organs, e.g. vision (by large lesions in the orbital region or on the eyelid), hearing, breathing,
- 3 bleeding and/or ulcerating lesions.

Refer to a skin specialist or paediatrician for treatment. In some cases intralesional steroids may be tried.



*Fig. 109 & 110.
Hemangioma of the
lower lip. The baby can
feed well, there is no
indication for treatment.*

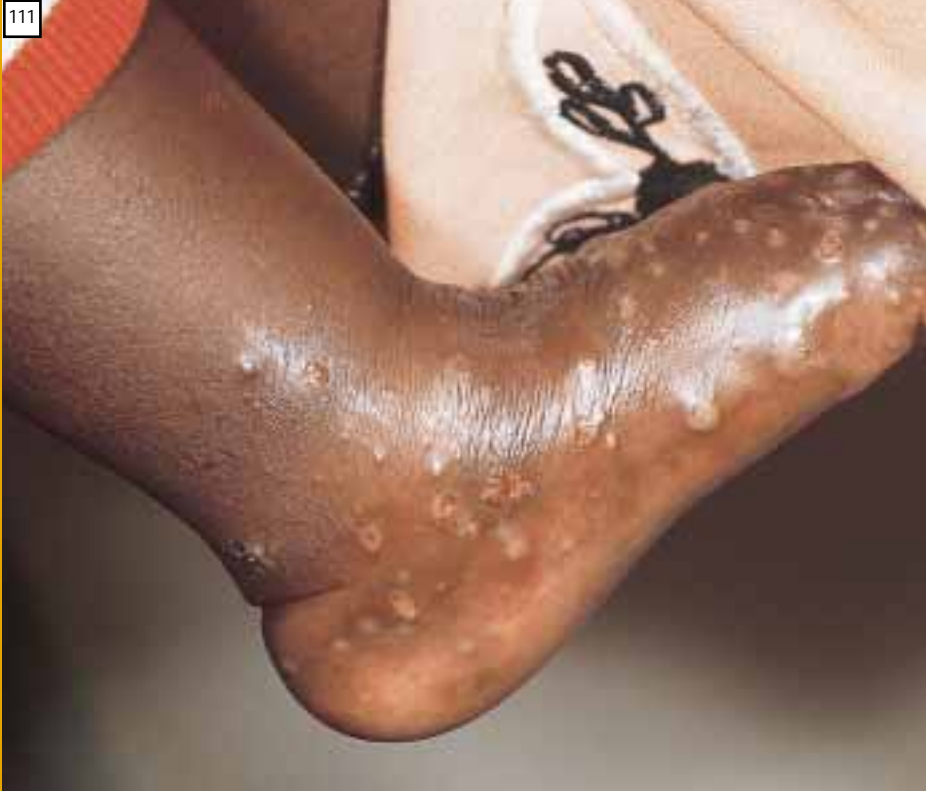INFANTILE ACROPUSTULOSIS

Infantile acropustulosis is a condition of unknown cause which occurs in infants, usually under the age of 1 year. Intensely itchy vesicles which quickly progress to pustules appear on the soles and the sides of the feet and on the palms, often in the first 3 months of life. The pustules last for one to several weeks and then subside only to reappear two to four weeks later. Attacks recur with diminishing severity and frequency in time and stay away at the end of the second or third year. The pustules are sterile and the condition does not warrant antibiotic treatment, which is a common misconception. Anti scabies treatment is also ineffective. The condition often seems to appear after successful treatment of scabies, which should make you wonder whether it was scabies which was treated in the first place.

Management of infantile acropustulosis

- Early use of topical corticosteroids is usually effective for itch and lessens the severity of the attack.
- For severe itch antihistamines may be required.
- Antibiotics and antiscabies treatment are ineffective.

Fig. 111. Infantile acropustulosis in a baby.



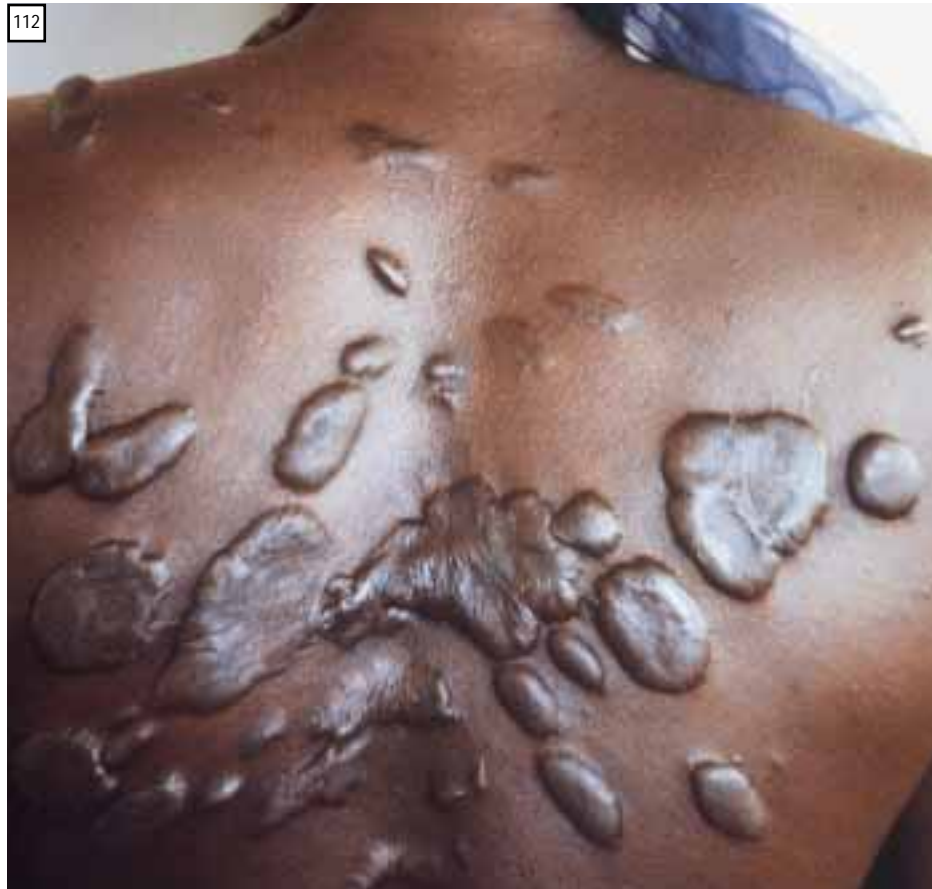KELOIDS

Keloids are fibrous tumours caused by overgrowth of connective tissue. They usually occur in a scar, weeks to months after the skin is traumatised. The keloid spreads beyond the boundary of the original injury to form a hard, irregular, shiny, sometimes painful or itchy ridge or plaque. In primary keloids there is no apparent preceding trauma. Once formed keloids remain stationary for years after which, some become partially flattened. They are especially common in Africans.

Management of keloids

- Treatment is difficult, especially in older lesions. Surgical excision will lead to recurrence and more severe deformity!
- Strong topical corticosteroids under occlusion are sometimes effective as are intralesional corticosteroids, with or without cryotherapy. Radiotherapy is an option in some cases. Pressure garments may be used to prevent and treat keloids especially after extensive trauma e.g. burns.

Fig. 112. Acne scars forming keloids on the back.



MALIGNANT MELANOMA

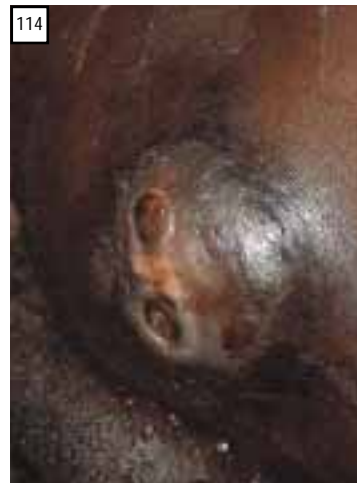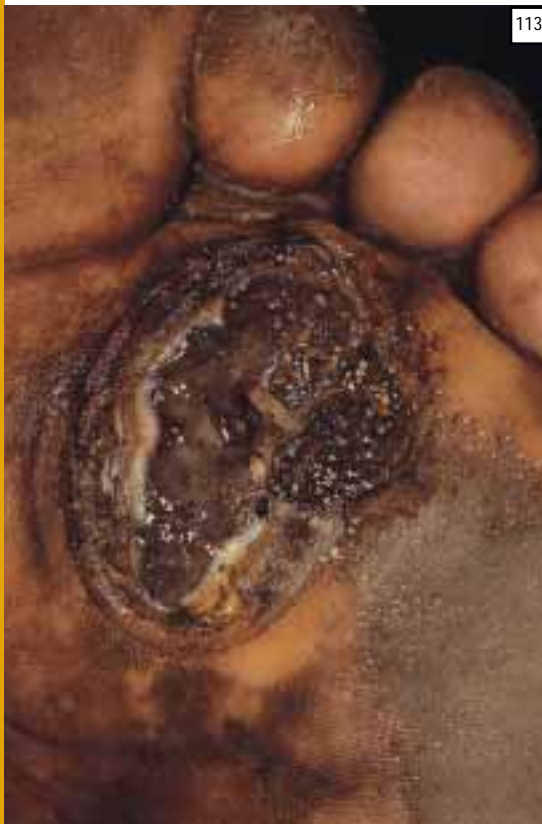This is a very malignant tumour which in Africans usually arises on the foot, less often on the hand (usually acro-lentiginous melanoma). It can start as a small pigmented papule or nodule which grows, often showing typical blue-grey-black shades of colour, and sometimes bleeding or ulcerating. It spreads to other organs rapidly and the diagnosis is often made when the tumour has already spread to at least regional lymph nodes and it is too late for cure. **Early diagnosis is therefore important.** Keep a melanoma in mind when someone presents with a chronic ulcer on the foot especially when it shows typical pigmentation or when it does not respond to ulcer-treatment.

An incision biopsy should not be performed in a lesion which is suspect for malignant melanoma, the lesion needs to be excised in total.

Fig. 113 & 114. Malignant melanoma of the sole with inguinal lymph node metastasis in a 62 year old man.

Management of malignant melanoma

- Wide surgical excision and histological examination.
- Refer to a specialised centre.



PAPULAR PRURITIC ERUPTION

The phrase "papular pruritic eruption" defines an itchy, persistent or chronic recurrent rash which is found in HIV-infected patients and for which no other cause (e.g. urticaria, scabies, folliculitis etc.) can be found. There are usually widespread inflammatory papules, hyperpigmented scars and scratch marks. The patient may or may not show other signs of HIV-infection.

Management of papular pruritic eruption

Treatment is symptomatic, any of the options below may be tried:

- Calamine lotion, phenol zinc lotion, menthol 0,5% cream or lotion or phenol 1% + menthol 0.5% preparation.
- Antihistamines e.g. promethazine 25 mg nightly or chlorpheniramine 4 mg 2 or 3 times daily.
- Betadine scrub in case of infected lesions.
- Hydrocortisone or betamethasone cream once to twice daily.
- Dapsone 100 mg once daily may be tried in severe cases.

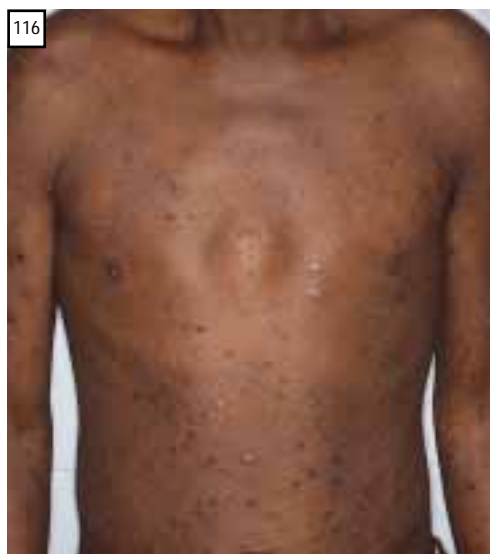
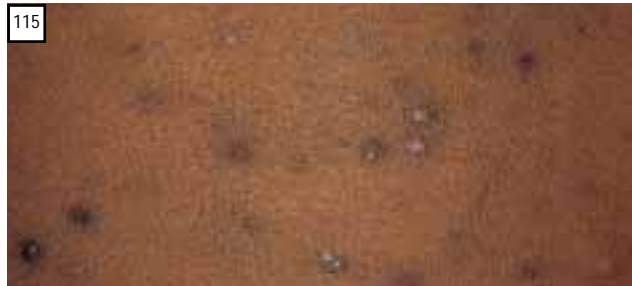
Fig. 115 & 116.
Papular pruritic eruption.

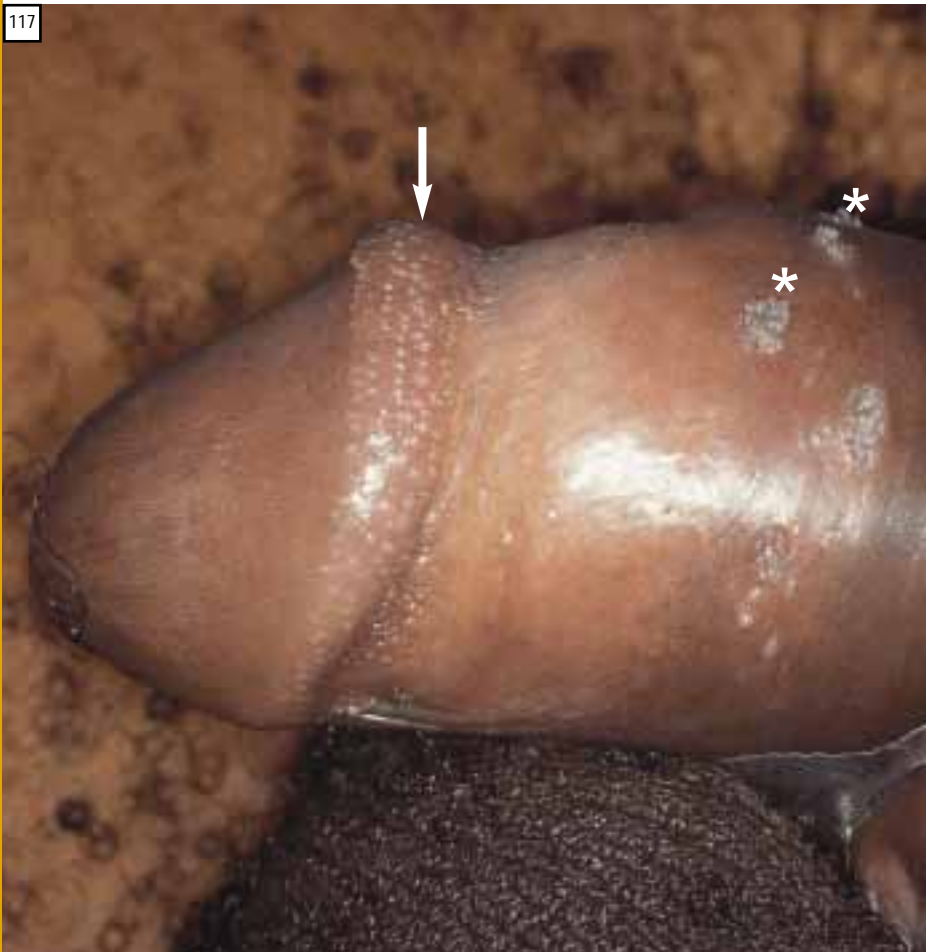PEARLY PENILE PAPULES

Pearly penile papules are not a disease, they are an anatomical variant. Small, usually whitish or skin coloured papules are found at the border of the glans penis, just before the coronary sulcus. They are very regularly spaced and regular in size. They are often a great worry to young men who think they have penile warts or another sexually transmitted infection and may have caused them to seek all sorts of treatments.

Management of pearly penile papules

Explain to the patient that no treatment is necessary.

Fig. 117. Pearly penile papules →
This patient also has
condylomata
acuminata *

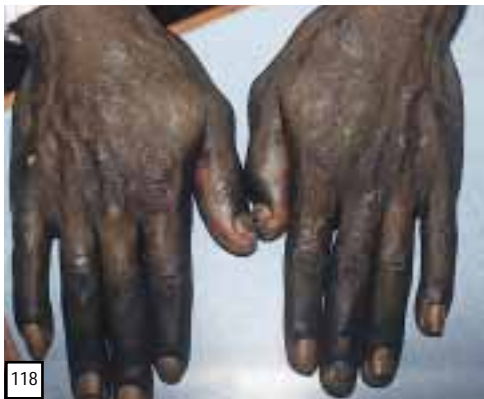

PORPHYRIA CUTANEA TARDA

Porphyria cutanea tarda is a chronic disturbance of the metabolism of porphyrins, manifested by liver damage and skin lesions. The disease affects more men than women, generally over the age of 40. Skin which is exposed to the sun is affected, mainly the face and the backs of the hands. Exposure to sunlight or trauma induces small blisters which lead to erosions, crusts, atrophy, flat or depressed scars and pigmentation changes. Milia are often present. Increased hairgrowth is also a feature. The urine of these patients is red in colour after sun exposure due to increased porphyrin excretion.

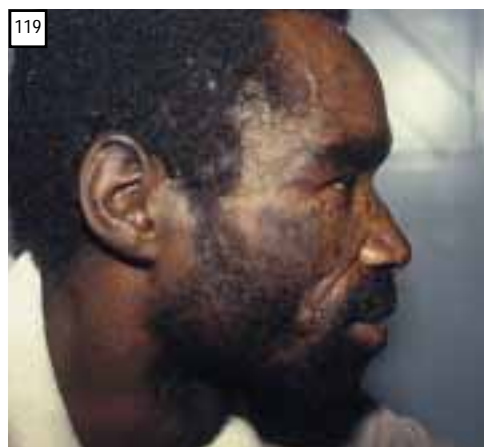Management of porphyria cutanea tarda

- Avoid triggering agents, e.g. alcohol, drugs, oral contraceptives.
- Avoid trauma, avoid sun exposure.
- Phlebotomy, not to be performed in liver cirrhosis. A specialist should decide.
- Chloroquine in low doses (e.g. 150 mg weekly) for a long time.



118

Fig. 118-120. Porphyria cutanea tarda in a 50 year old alcoholic. Scars and lesions are seen on the face and hands. The urine is red in colour.



119



120

PSORIASIS

Psoriasis is a chronic recurrent, inherited, non-infectious skin disease caused by an abnormally fast turnover of the epidermis. The turnover may be up to 40 times the normal and as a result the epidermis is not able to develop normally. All layers become too thick and the most obvious one is the horny layer, the outer layer of the skin. The skin is red, inflamed, and the scales are thicker than normal. They produce a so-called candle-wax phenomenon: when you scratch such a patch it becomes silvery-white. Psoriasis also displays a Koebner phenomenon, i.e. it appears in traumatised skin. Classical psoriasis occurs on the scalp, the extensor areas of extremities (esp. elbows, knees), the umbilicus and the buttocks. Finger- and toenails may show pitting, thickening of the nailbed or distal onycholysis (brownish oil-like changes on the distal nail where the nail is detached from the nailbed). Palms and soles may also show thickening; callus, scales and cracks. Treatment is often effective but you can never cure the patient of the disease as such. It may always recur, after weeks, months or years. Psoriasis may flare up after an infection (flu, angina) or drug use (e.g. antimalarial drugs, beta blockers, lithium). There is also a pustular psoriasis and an inverse form with lesions in skin folds rather than extensor areas, the latter may be difficult to distinguish from seborrhoeic eczema.

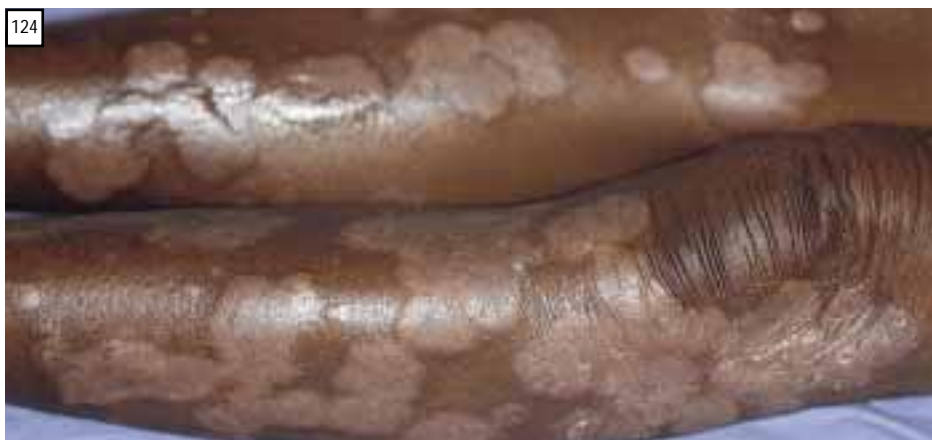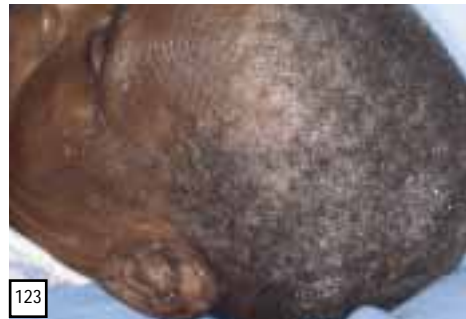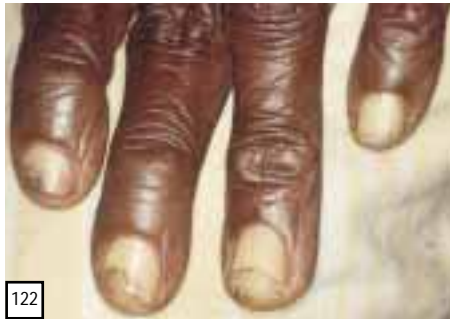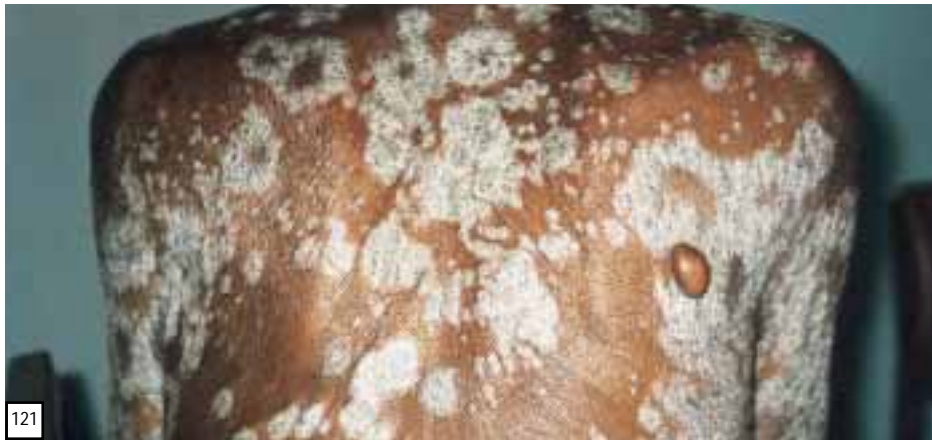Psoriatic arthritis of the small joints of the hands and feet occurs in 5-10% of patients. The arthritis may be mutilating and eventually become widespread.

Management of psoriasis

- Explain to the patient the recurrent nature of the disease.
- Salicylic acid 2-10% ointment twice daily to reduce scaling.
- Coal tar 5-10% ointment or sulphur 5% in coal tar 5-10% ointment nightly.
- Moisturise (vaseline, urea 10% ointment or cream) and expose to sun. In psoriasis coal tar ointment may be tried in combination with sunlight.
- Salicylic acid and coal tar should not be applied on body folds unless the skin is dry and thickened. They can be mixed together as ointments, or with zinc paste.
- In body folds sulphur added to a mild steroid cream is often effective.
- A strong topical steroid once or twice daily, cover with salicylic acid 2-10% ointment if necessary.
- Urea 10% cream or ointment as an emulsifier, aqueous cream in folds.
- Treat any superinfection with betadine or antibiotics if necessary.

- Psoriatic arthritis: NSAIDs e.g. ibuprofen 400 mg 4-6 x daily, indomethacin 75-100 mg daily, naproxen 500-750 mg daily or salazosulphapyridine 250 - 500 mg twice daily.
- Methotrexate is often effective in severe and arthropathic psoriasis and may be used in HIV infected patients.

*Fig. 121. Psoriasis with typical thick scaling.
Fig. 122, 123 & 124.
Psoriasis in a 50 year old man. The fingernails show distal onycholysis.*



URTICARIA / PAPULAR URTICARIA

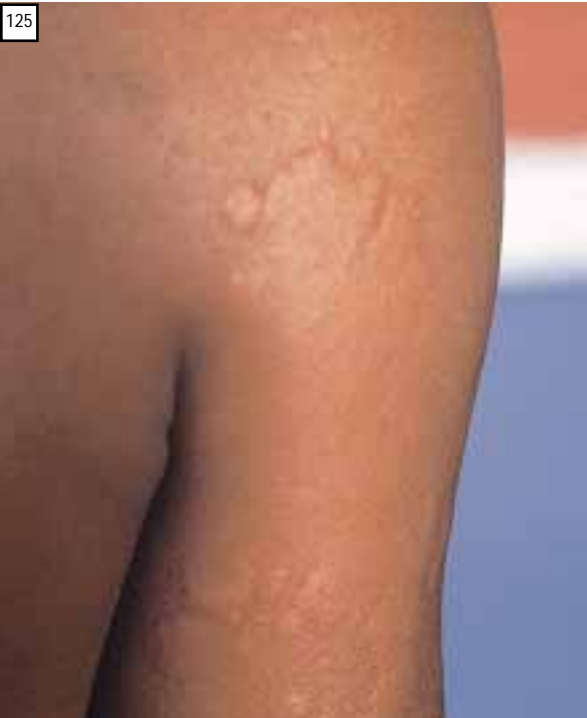Urticaria is a reactive phenomenon which is characterised by itching wheals (hives). These may be any shape or size, appear anywhere on the body and as angioedema in the face, at any interval. Sometimes there is a single attack of urticaria, sometimes there are attacks every few hours. Urticaria may come and go during a few days or persist for many years. There are many types of urticaria and possible causes of urticaria: contact urticaria (e.g. stinging nettles, caterpillars, formaldehyde); physical urticaria (cold, heat, pressure); cholinergic urticaria (sweat, exercise-induced); Drug-induced non-allergic urticaria (aspirin, pethidine, morphine, hydralazine); allergic urticaria by drugs (see drug eruptions), food (fish, milk, nuts, tomatoes, citrus fruits, cocoa, strawberries), insect allergens (bee, wasp), vaccines, worm infestations, and internal diseases. This list is not complete.

Papular urticaria is a specific form of urticaria which occurs again and again in susceptible children. It presents as very itchy persistent hives and papules, sometimes with vesicles on top. It is an exaggerated response to contact with insects, their vomits and bites. When extensive the rash may resemble HIV related papular pruritic eruption (though this usually occurs in adults) or scabies (in papular urticaria other family members are not affected).

Fig. 125. Urticarial wheals on the arm of a 15 year old boy.

The cause was unknown.

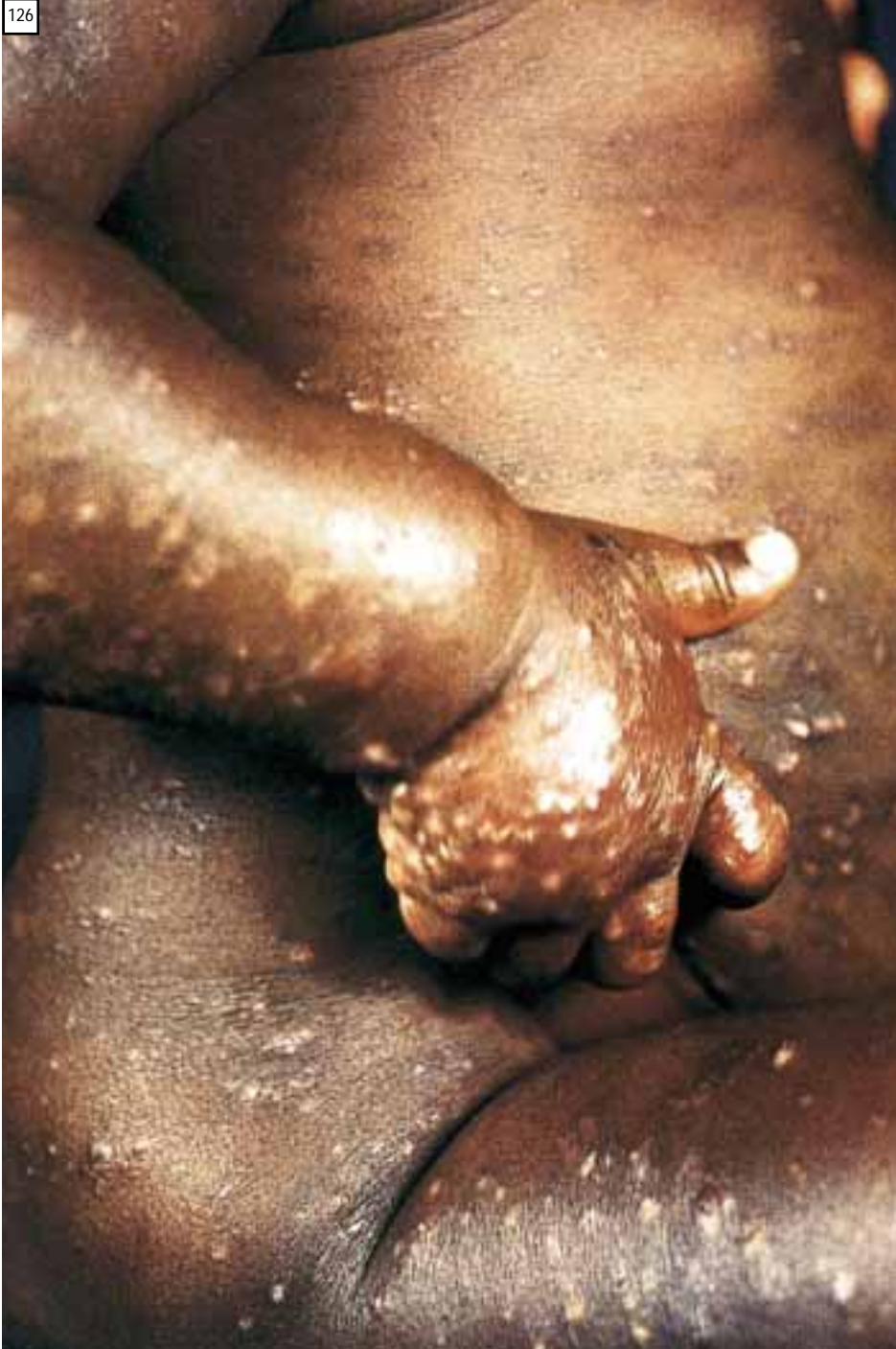Fig. 126. Papular urticaria in an infant.



Management of urticaria / papular urticaria

- Avoid or treat the cause if possible. A thorough history is essential.
- Calamine lotion or phenol-zinc lotion.
- Antihistamines, a low or high dose may be required, this varies per patient.
- Topical steroids if necessary.
- Avoid the use of aspirin.
- Papular urticaria: Insect repellents and impregnated bednets.

126



Present affiliations of the authors:

*Colette van Hees: Consultant dermatologist at the Reinier de Graaf Groep Delft / Voorburg,
The Netherlands*

*Ben Naafs: Consultant Dermatologist IJsselmeerziekenhuizen Emmeloord/Lelystad
and the Leiden University (LUMC), The Netherlands.*

*Visiting lecturer Regional Dermatology Training Centre (RDTC)
at the Kilimanjaro Christian Medical College (KCMC),*

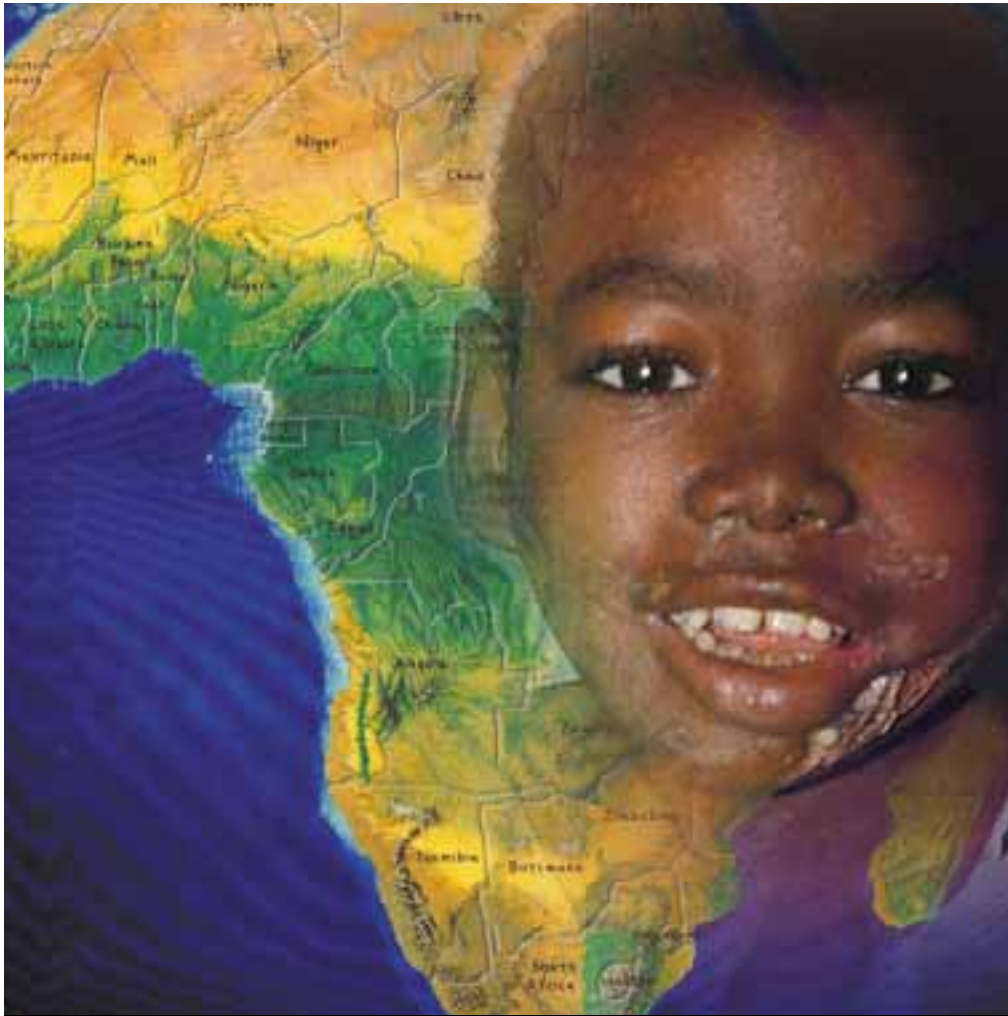
Tumaini University Moshi, Tanzania,

Visiting professor Instituto Lauro de Souza Lima (ILSL) Bauru, SP, Brazil.

Correspondence:

Troderma@hotmail.com

*Colette van Hees, Dep of Dermatology, Reinier de Graaf Groep, locatie Diaconessenhuis Voorburg,
Fonteynenburghlaan 5, 2275 CX Voorburg, The Netherlands.*



Colette van Hees MD was trained to be a dermatovenerologist by prof BJ Vermeer at Leiden University, The Netherlands. She was a consultant dermatologist at Leiden University Hospital before moving to Masvingo, Zimbabwe, where she ran a Dermatology Referral Clinic at Masvingo Provincial Hospital from 1996-1999.



Ben Naafs MD, PhD was trained to be a dermatovenerologist by prof RH Cormane at the Binnengasthuis later AMC in Amsterdam, The Netherlands. He worked in developing countries (Ethiopia, Zimbabwe, Tanzania, Brazil) for over 10 years and was head OPD Dermatology at Dijkzigt Ziekenhuis, Erasmus University, Rotterdam, The Netherlands, for almost 10 years.