

Diagnosis and the clinical spectrum of leprosy

Salvatore Noto, Pieter A. Schreuder

Leprosy mailing list, May 2010

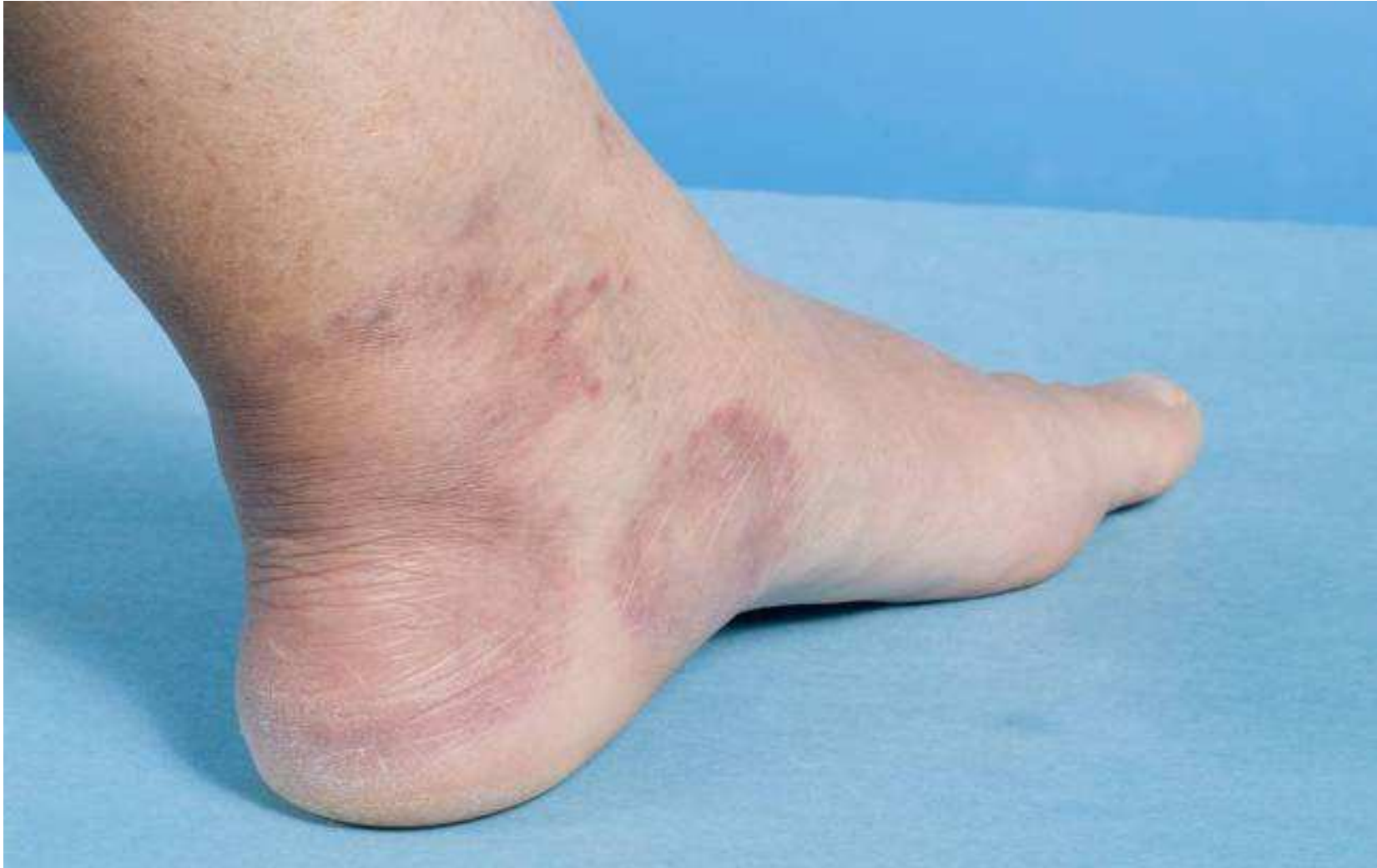Diagnosis and the clinical spectrum of leprosy

While examining the patient the following 4 points are of help for achieving the diagnosis of leprosy:-

- 1.
in some forms of leprosy there is altered sensation in skin patches;**
- 2.
in some forms of the disease the leprosy bacilli are demonstrable by slit-skin smears;**
- 3.
Always systematically examine the peripheral nerves;**
- 4.
In some rare forms of leprosy no cardinal signs are present.**

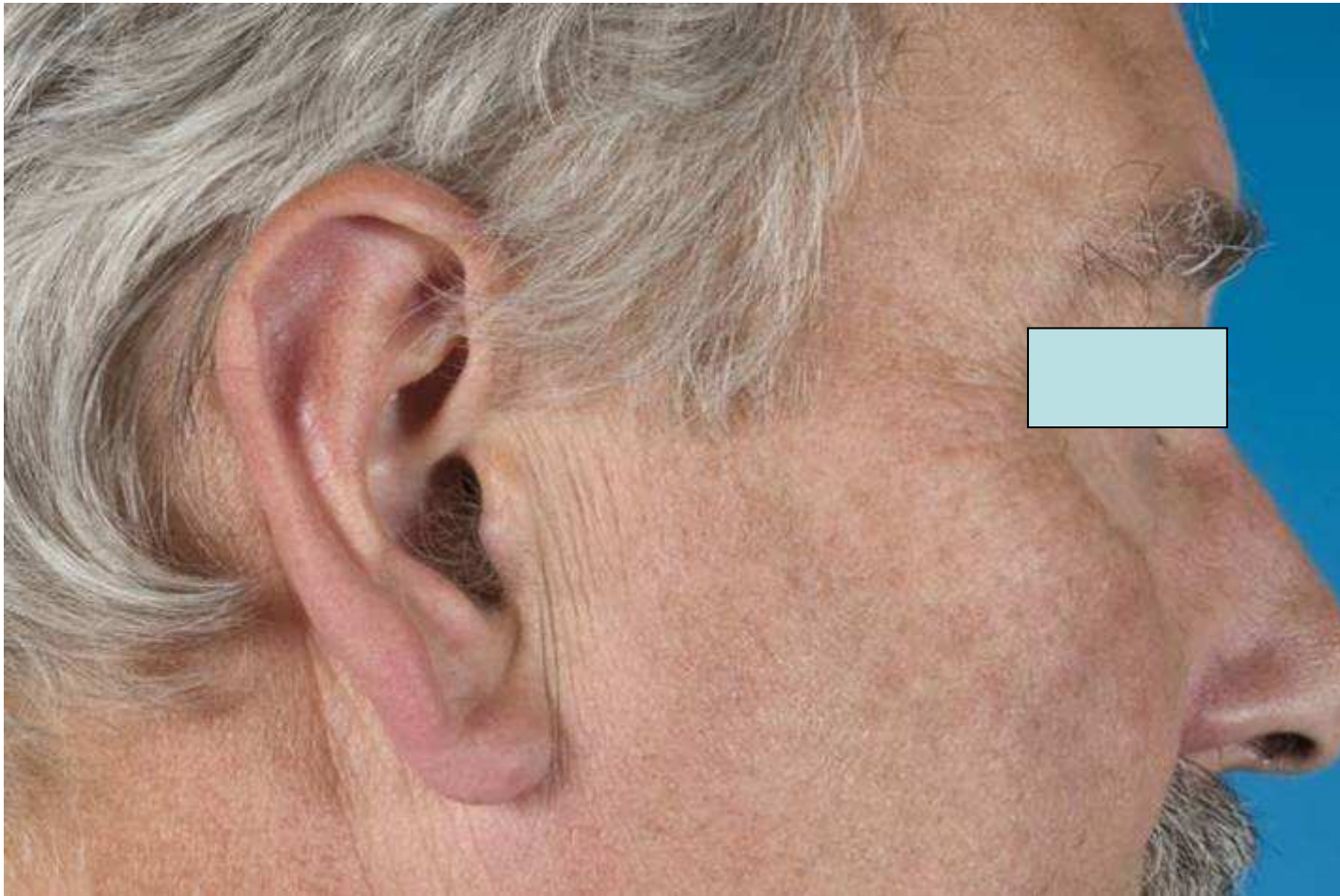
Leprosy BT

In this form of leprosy there is loss of sensation in skin lesions, nerves may be enlarged, skin smear is normally negative. Diagnosis is based on loss of sensation and or enlarged nerves

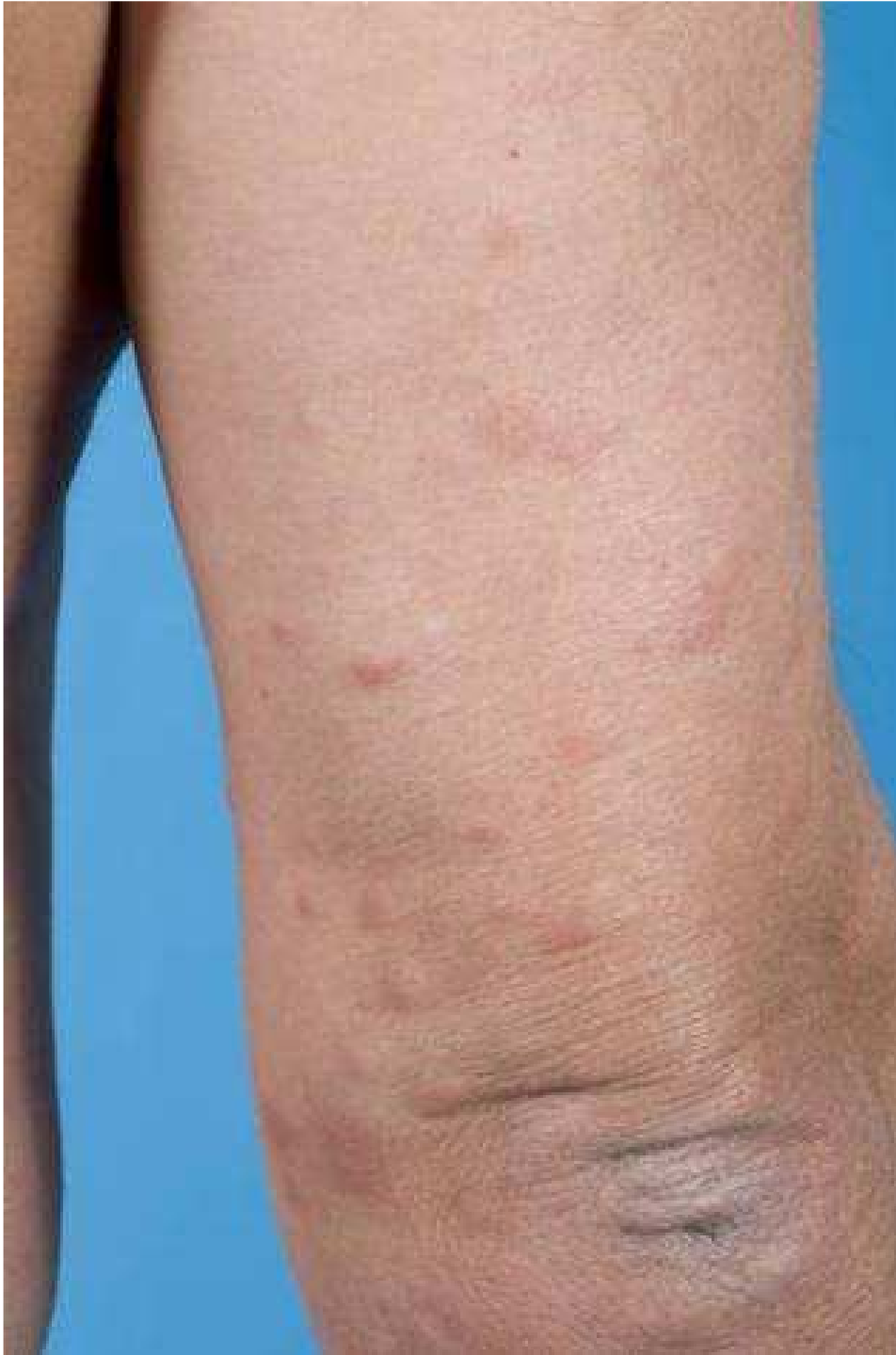

Leprosy BL – LL, infiltrated ears

In these forms of leprosy sensation can be normal, nerves enlarged or normal, slit-skin smear should be positive.



Courtesy of B Naafs

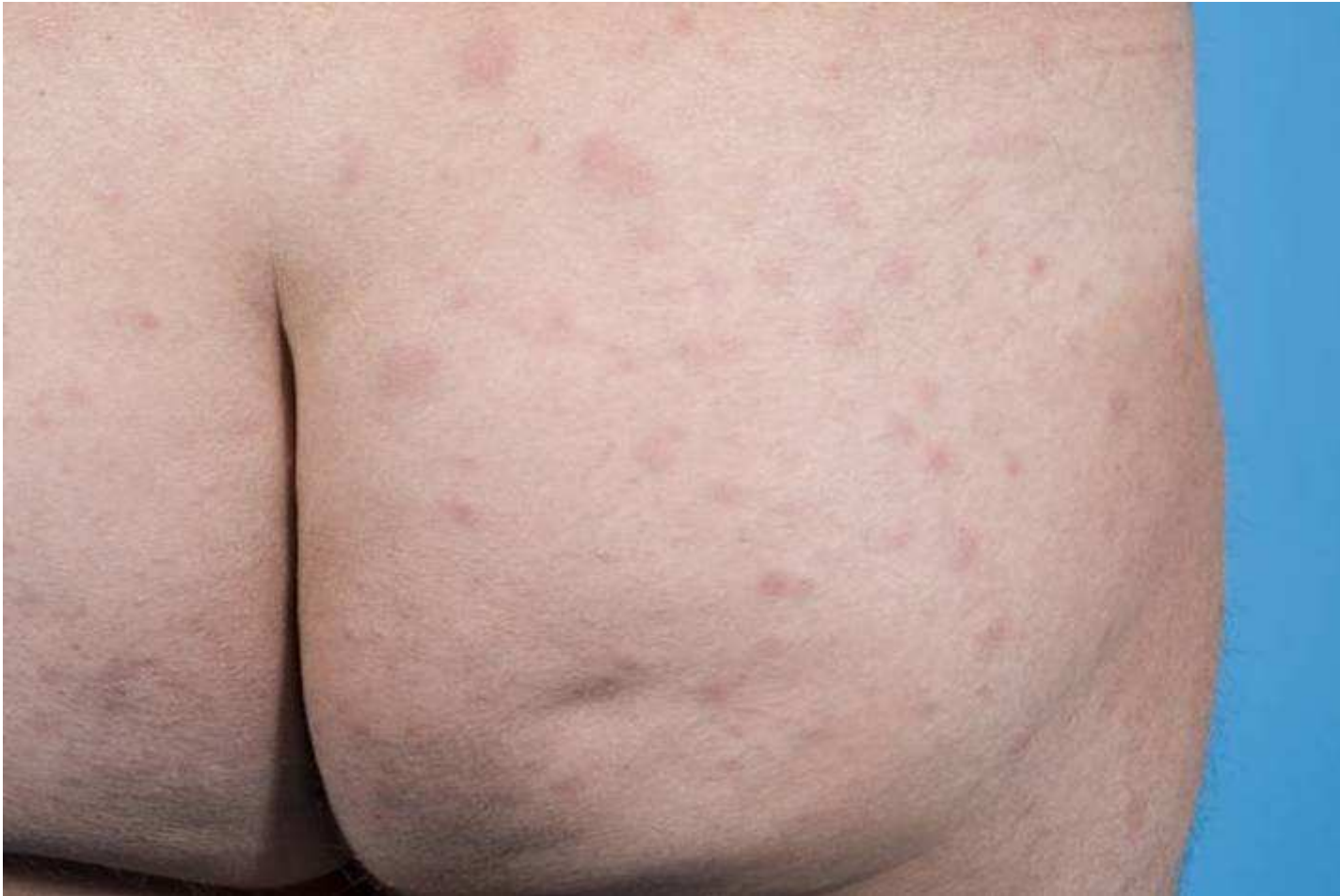

Leprosy BL – LL (reactive)

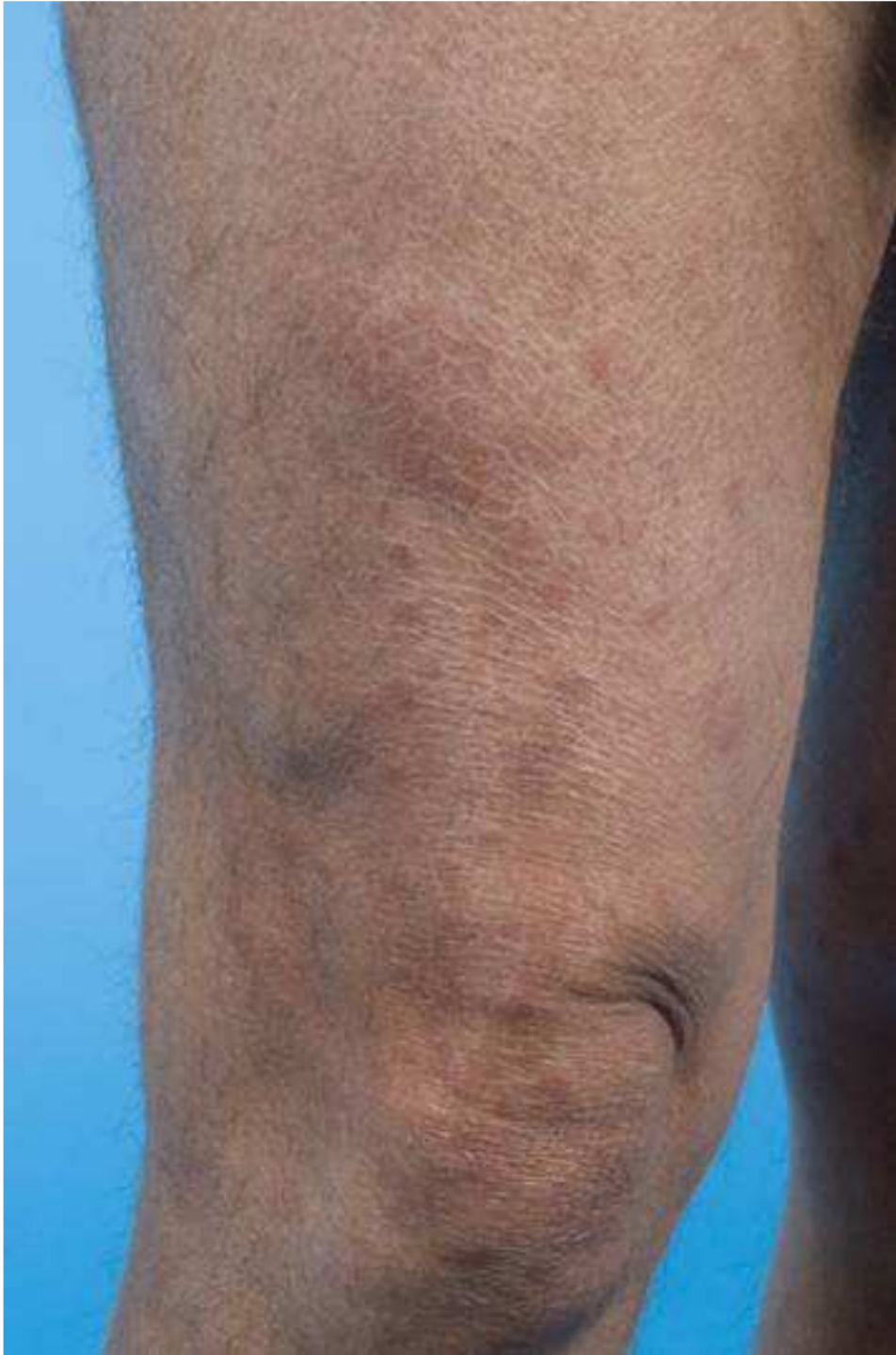In these forms of leprosy sensation can be normal, nerves enlarged or normal, slit-skin smear should be positive

Leprosy BL – LL

In these forms of leprosy sensation can be normal, nerves enlarged or normal, slit-skin smear should be positive



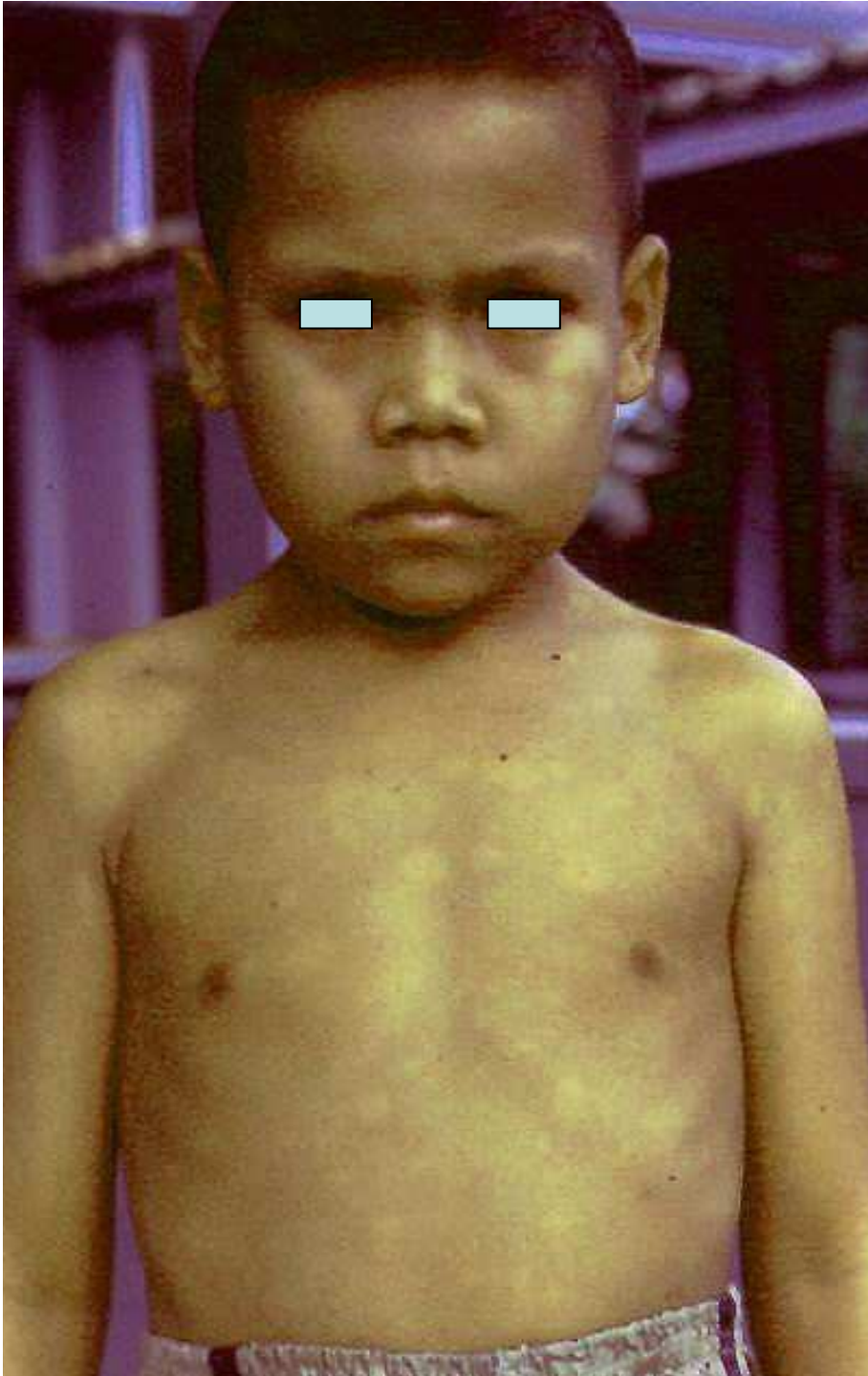Courtesy of B Naafs



Leprosy BL – LL

In these forms of leprosy sensation can be normal, nerves enlarged or normal, slit-skin smear should be positive

Courtesy of B Naafs

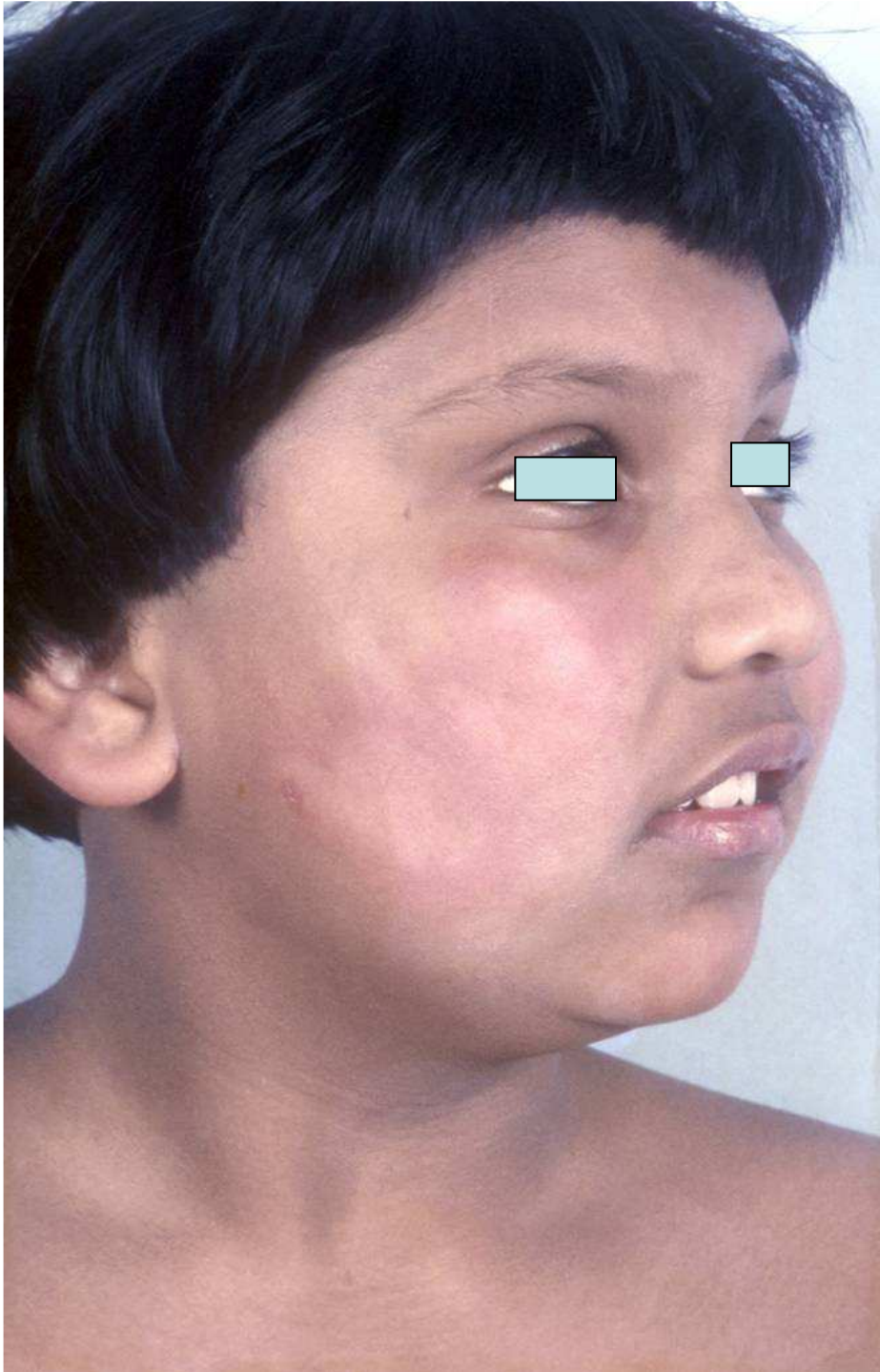

Early Lepromatous leprosy

It causes no discomfort, and the patient does not feel sick. It is “just there”. No signs of nerve damage or large nerves. Many bacilli in some lesions.

Case number 3. in the text

Courtesy of Grace Warren

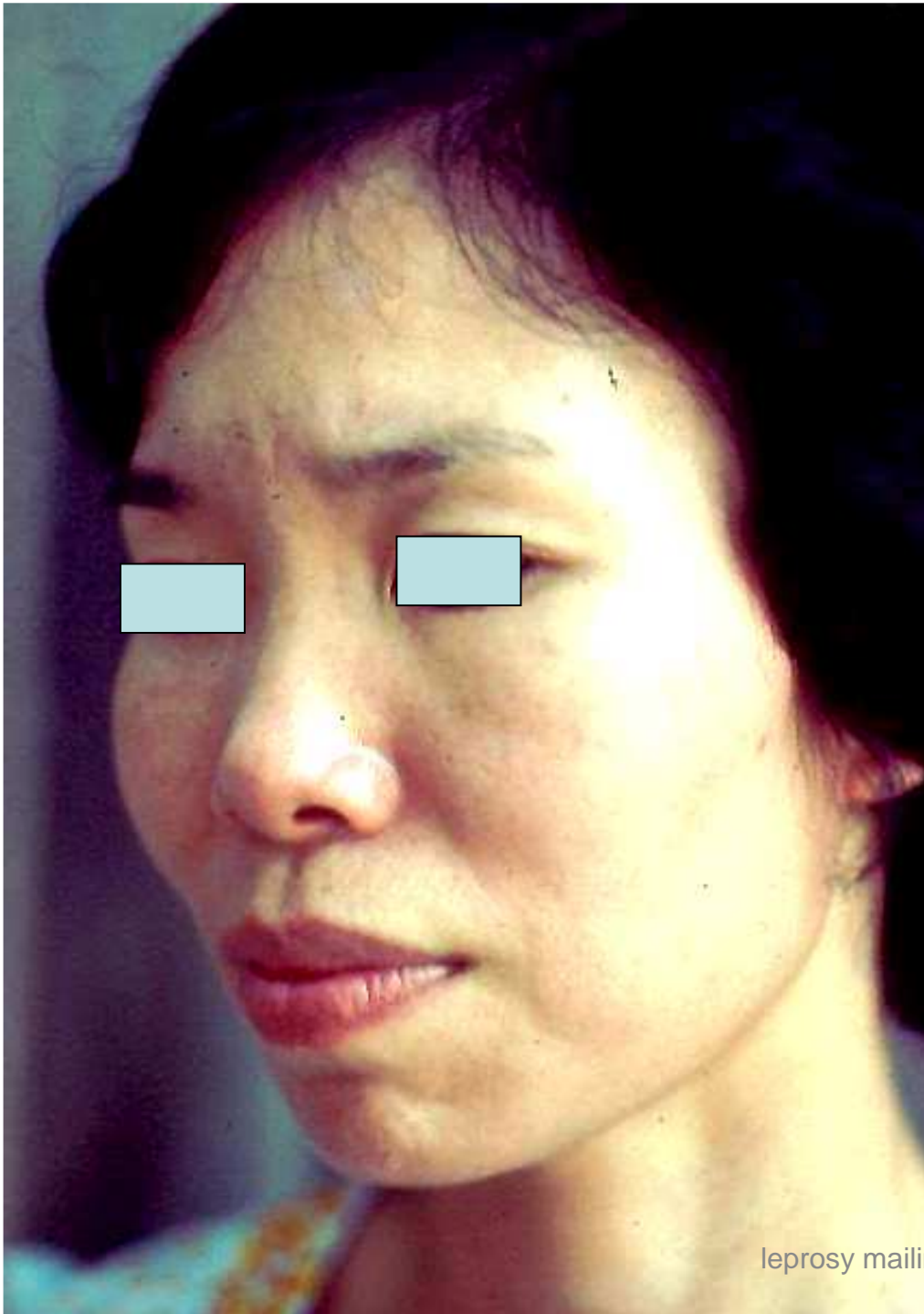


LL leprosy

Infiltrated skin, no loss of sensation, no enlarged nerves. In this case diagnosis is by positive slit-skin smear examination. Mother with LL leprosy.

Courtesy of B Naafs

Difficult cases



Lepromatous leprosy

On palpation diffuse infiltration of the skin of the whole face except upper lip. A vague edge is present along the naso-labial fold. (Upper lip normal skin, rest of face infiltrated.)

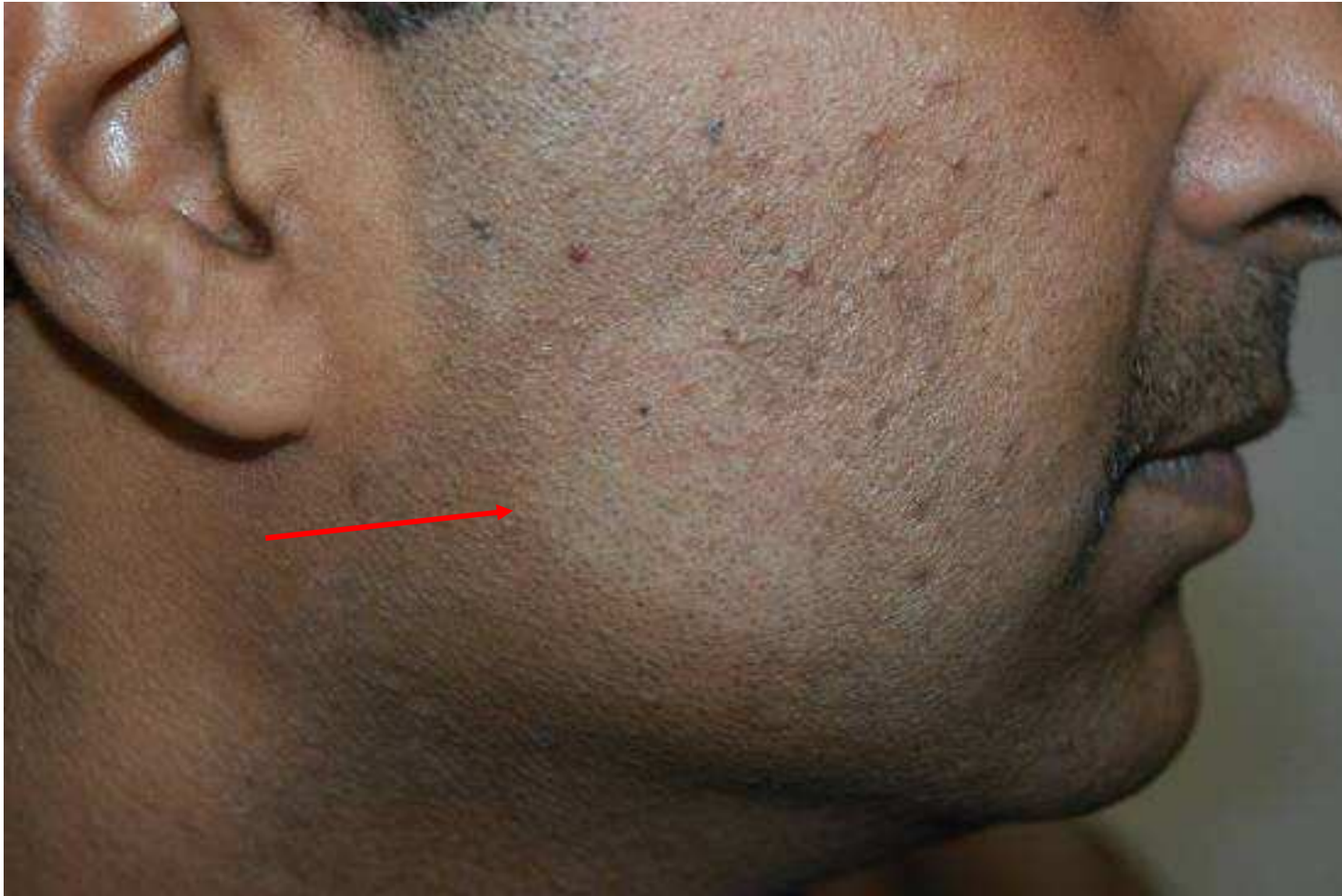Diagnosis was accidentally made on the biopsy of a nodule on the arm.

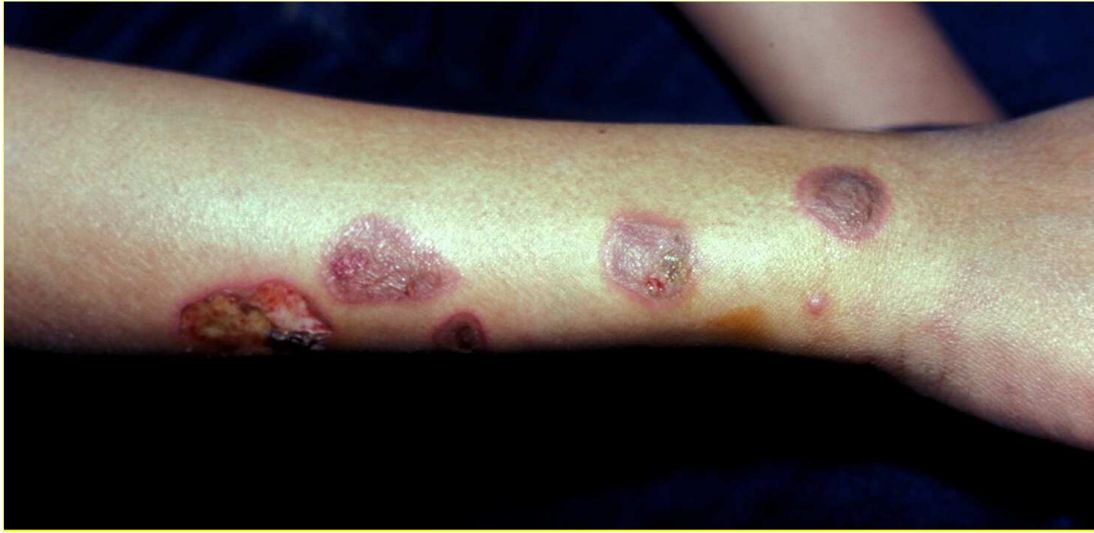**Slit-skin smear: -
bacteriological index 6+ at all
sites!**

Courtesy of Grace Warren

Leprosy, BT

Testing for loss of sensation may be negative on the face. The patient developed BT as immune reconstitution inflammatory syndrome (IRIS) after leflunomide





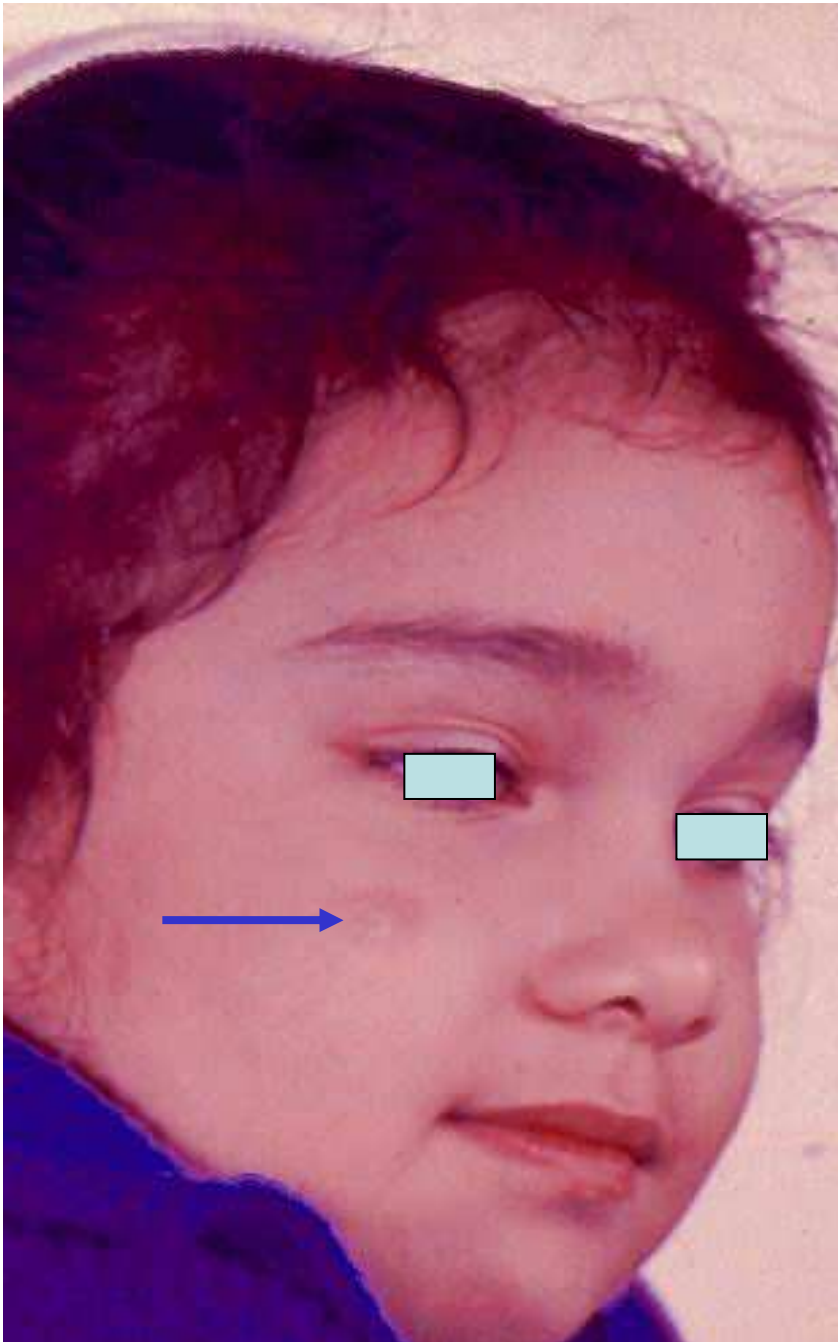
Courtesy of Grace Warren

BB-BL leprosy

Teen aged girl presented with painless burns, not diagnosed as leprosy. On careful examination she had well established disease caught from grandmother. If you look at the arm there is a hypopigmented patch covering a lot of the arm which is fairly well defined at the wrist but not the proximal end of the lesion (G. Warren).

Case 4. in the text.

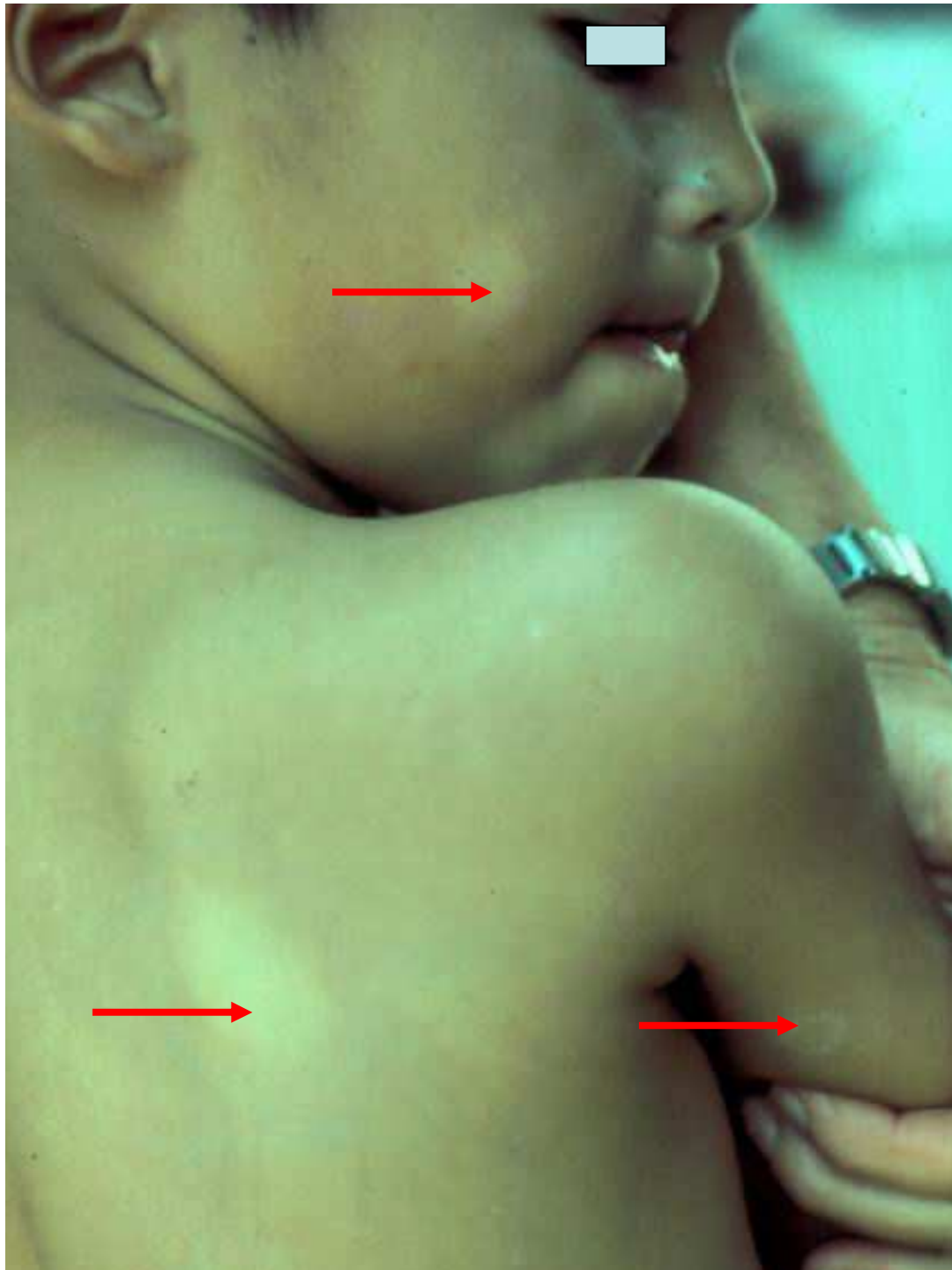
Please think and investigate why there are unusual signs such as NO PAIN.



Indeterminate leprosy

Small European child with a typical lesion. It is basically vague edged, the lesion appearing pinkish against her light coloured skin. It has been there for a few months, there is no detectable sensory abnormality, she appears to feel touch normally. It is not itchy, scaly or irritating. No palpable nerves found and no other lesions. Her general health is good.

She lives in a highly endemic area where there are many untreated cases. It is not reasonable to biopsy a small lesion on the cheek of a small child to diagnose Indeterminate leprosy. So a diagnosis cannot be confirmed but, because of the examination and history I would describe and record fully and treat with routine paucibacillary (PB) therapy for 6 months. However I would not officially register her as leprosy because of the social stigma that could result (G. Warren).

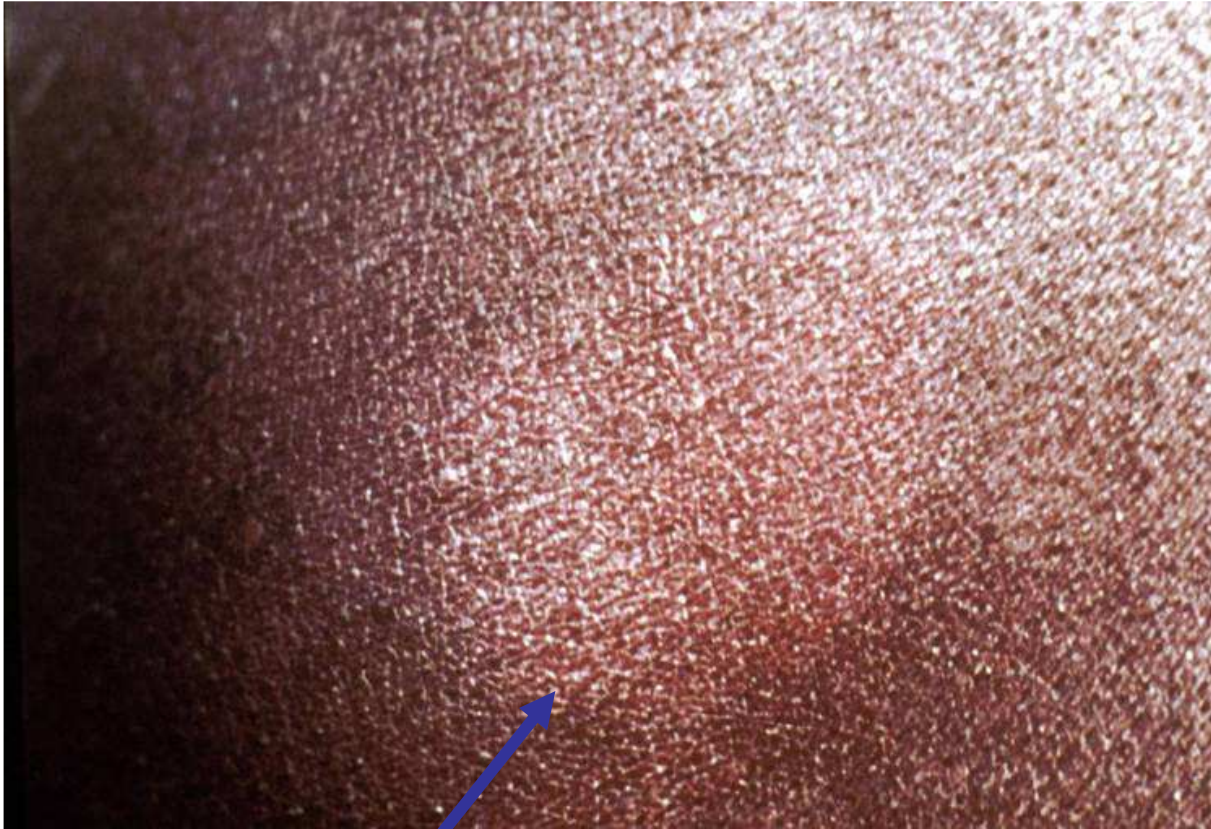

INDETERMINATE LEPROSY

Young boy, son of BL leprosy patient previously untreated with three lesions. One on cheek and one of back are vague edged hypopigmented with apparently no loss in touch on lesion and no abnormal sensation or discomfort typical of leprosy. No abnormal nerves found anywhere.

The lesion on the arm has a well defined infiltrated edge and it is slightly itchy. Skin scrape showed fungus in the arm lesion. Treated with antifungal ointment.

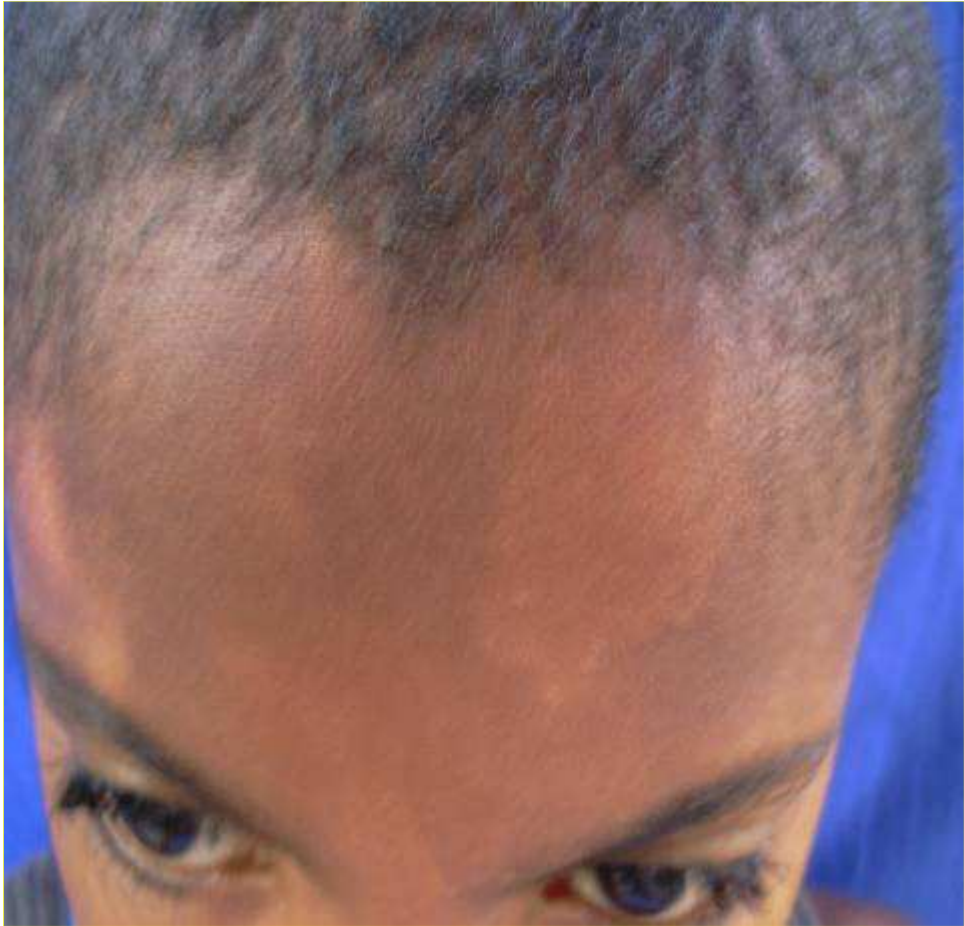Biopsy is an option but a large biopsy would need to be taken from the back and even then one cannot be sure of diagnosing "Indeterminate" by biopsy. So in view of the contact with BL leprosy I would diagnose as leprosy, treat as PB and watch carefully for a prolonged period after medication ceases (G. Warren).



Indeterminate leprosy in darker skin

Courtesy of B Naafs

Typical Indeterminate lesion occurring in endemic areas and in children with contact with active leprosy.
Carefully describe and record the suspect leprosy lesion and see the patient back in 3 months.



Diagnosis of leprosy in children may be difficult

Courtesy of J A da Costa Nery